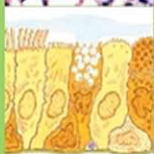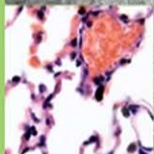

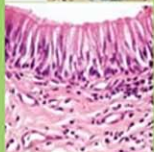
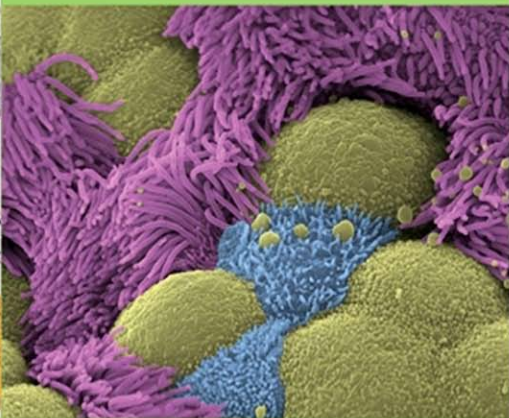
# NETTER'S

## HISTOLOGY FLASH CARDS

### UPDATED EDITION



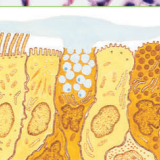
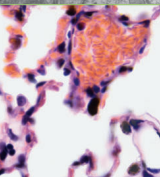
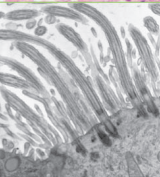
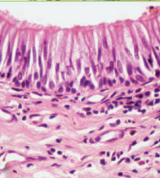
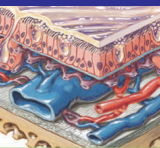
**WILLIAM K. OVALLE**  
**PATRICK C. NAHIRNEY**



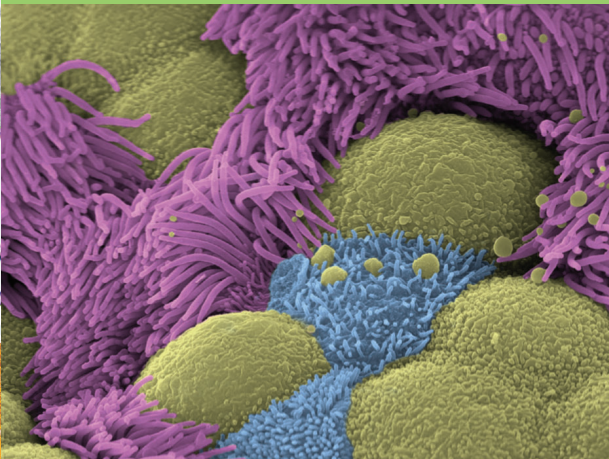
# NETTER'S

## HISTOLOGY FLASH CARDS

### UPDATED EDITION



**WILLIAM K. OVALLE**  
**PATRICK C. NAHIRNEY**



This page intentionally left blank

**N**etter's *Histology Flash Cards, Updated Edition*, the first of its kind for histology, is a comprehensive collection of over 200 cards that supplement standard histology textbooks and atlases used in contemporary courses, including *Netter's Essential Histology, 2nd Edition*. It is a unique educational aid designed to stimulate and reinforce knowledge of key histologic features of cells, tissues, and organs. These flash cards encourage self-directed and group learning, and stress understanding of fundamentals rather than excessive detail with emphasis on correlation of structure to function.

The front of each flash card typically combines gross anatomic views or Netter illustrations for orientation with microscopic images. They are designed to bridge the gap between two- and three-dimensions by asking the user to identify specific structures. On the back are answers, concise explanatory text, and a clinical point relevant to each topic, which is pertinent to human disease. For more information on a topic, a cross-reference to *Netter's Essential Histology, 2nd Edition* is included on each card. The user-friendly format of each 4" × 6" flash card provides an easily portable study guide that is relevant in today's revised, problem-based, integrated curricula for students in medicine, dentistry, and undergraduate science programs and can aid in board review.

Finally, this set of flash cards is intended to inspire and awaken students' interest to the intricacies of the human body and appreciation of the sheer beauty of its cells, tissues, and organ systems.

**William K. Ovalle, PhD**

Professor and Director of Histology  
Faculty of Medicine, Department of Cellular and  
Physiological Sciences  
The University of British Columbia  
Vancouver, British Columbia, Canada

**Patrick C. Nahirney, PhD**

Assistant Professor in Anatomy and Histology  
Division of Medical Sciences  
University of Victoria  
Victoria, British Columbia, Canada

# SAUNDERS ELSEVIER

1600 John F. Kennedy Blvd.  
Ste 1800  
Philadelphia, PA 19103-2899

Netter's Histology Flash Cards

ISBN: 978-1-4557-7656-6

**Copyright © 2013, 2008 by Saunders, an imprint of Elsevier Inc.**

**All rights reserved.** No part of this book may be produced or transmitted in any form or by any means, electronic or mechanical, including photocopying, recording or any information storage and retrieval system, without permission in writing from the publishers.

Permissions for Netter Art figures may be sought directly from Elsevier's Health Science Licensing Department in Philadelphia PA, USA: phone 1-800-523-1649, ext. 3276 or (215) 239-3276; or email H.Licensing@elsevier.com.

## Notice

Neither the Publisher nor the Authors assume any responsibility for any loss or injury and/or damage to persons or property arising out of or related to any use of the material contained in this book. It is the responsibility of the treating practitioner, relying on independent expertise and knowledge of the patient, to determine the best treatment and method of application for the patient.

The Publisher

978-1-4557-7656-6

*Acquisitions Editor:* Elyse O'Grady  
*Developmental Editor:* Marybeth Thiel  
*Publishing Services Manager:* Linda Van Pelt  
*Project Manager:* Priscilla Crater  
*Design Direction:* Louis Forgione  
*Illustrations Manager:* Karen Giacomucci  
*Marketing Manager:* Megan Poles

Printed in China

Last digit is the print number: 9 8 7 6 5 4 3 2 1

Working together to grow  
libraries in developing countries

[www.elsevier.com](http://www.elsevier.com) | [www.bookaid.org](http://www.bookaid.org) | [www.sabre.org](http://www.sabre.org)

ELSEVIER BOOK AID International Sabre Foundation

# Table of Contents

## Section 1: Cells and Tissues

1. The Cell
2. Epithelium and Exocrine Glands
3. Connective Tissue
4. Muscle Tissue
5. Nervous Tissue
6. Cartilage and Bone
7. Blood and Bone Marrow

## Section 2: SYSTEMS

8. Cardiovascular System
9. Lymphoid System
10. Endocrine System
11. Integumentary System
12. Upper Digestive System
13. Lower Digestive System
14. Liver, Gallbladder, and Exocrine Pancreas
15. Respiratory System
16. Urinary System
17. Male Reproductive System
18. Female Reproductive System
19. Eye and Adnexa
20. Special Senses

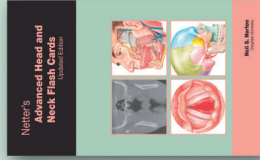This page intentionally left blank

**More exquisitely illustrated sets to help you review!**

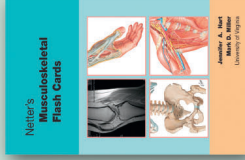
## ***The Netter Flash Cards Series***



**Netter's Anatomy  
Flash Cards, 3rd Edition  
(978-1-4377-1675-7)**



**Netter's Advanced Head  
and Neck Flash Cards –  
Updated Edition  
(978-1-4557-4523-4)**



**Netter's Musculoskeletal  
Flash Cards  
(978-1-4160-4630-1)**



**Netter's Neuroscience  
Flash Cards, 2nd Edition  
(978-1-4377-0940-7)**

The logo for Netter, featuring the name 'Netter' in a stylized, cursive font with a lightning bolt symbol above the 'e'.

Look for these and other great **Netter Flash card sets** at your local medical bookstore or visit [www.elsevierhealth.com](http://www.elsevierhealth.com).



This page intentionally left blank

## Section 1: Cells and Tissues

### The Cell

- 1-1** The Cell
- 1-2** Cell Junctions
- 1-3** Nucleus
- 1-4** Nucleus
- 1-5** Mitochondria
- 1-6** Ribosomes
- 1-7** Golgi Complex
- 1-8** Cytoplasm
- 1-9** Inclusions
- 1-10** Cytoplasmic Vesicles
- 1-11** Cytoskeleton

### Epithelium and Exocrine Glands

- 2-1** Classification of Epithelia
- 2-2** Simple Squamous Epithelium
- 2-3** Simple Columnar and Pseudostratified Epithelia
- 2-4** Simple Columnar Epithelium
- 2-5** Stratified Squamous Keratinized Epithelium
- 2-6** Stratified Epithelium
- 2-7** Transitional Epithelium
- 2-8** Classification of Exocrine Glands
- 2-9** Serous Cells
- 2-10** Mucous Cells
- 2-11** Mammary Gland

## Section 1: Cells and Tissues

### Connective Tissue

- 3-1** Loose Connective Tissue
- 3-2** Dense Connective Tissue
- 3-3** Fibroblasts
- 3-4** Collagen
- 3-5** Elastic Connective Tissue
- 3-6** Reticular Connective Tissue
- 3-7** Mast Cells
- 3-8** Plasma Cells
- 3-9** Macrophages
- 3-10** Adipose Tissue

### Muscle Tissue

- 4-1** Skeletal Muscle
- 4-2** Skeletal Muscle
- 4-3** Sarcomere
- 4-4** Satellite Cells
- 4-5** Neuromuscular Junction
- 4-6** Cardiac Muscle
- 4-7** Cardiac Muscle
- 4-8** Cardiac Conduction System
- 4-9** Smooth Muscle
- 4-10** Smooth Muscle

# Section 1: Cells and Tissues

## **Nervous Tissue**

- 5-1** Meninges
- 5-2** Cerebrum
- 5-3** Cerebellum
- 5-4** Neuron
- 5-5** Neuron
- 5-6** Synapse in the CNS
- 5-7** Blood-brain Barrier
- 5-8** Choroid Plexus
- 5-9** Spinal Cord
- 5-10** Peripheral Nerve
- 5-11** Peripheral Nerve
- 5-12** Peripheral Ganglia

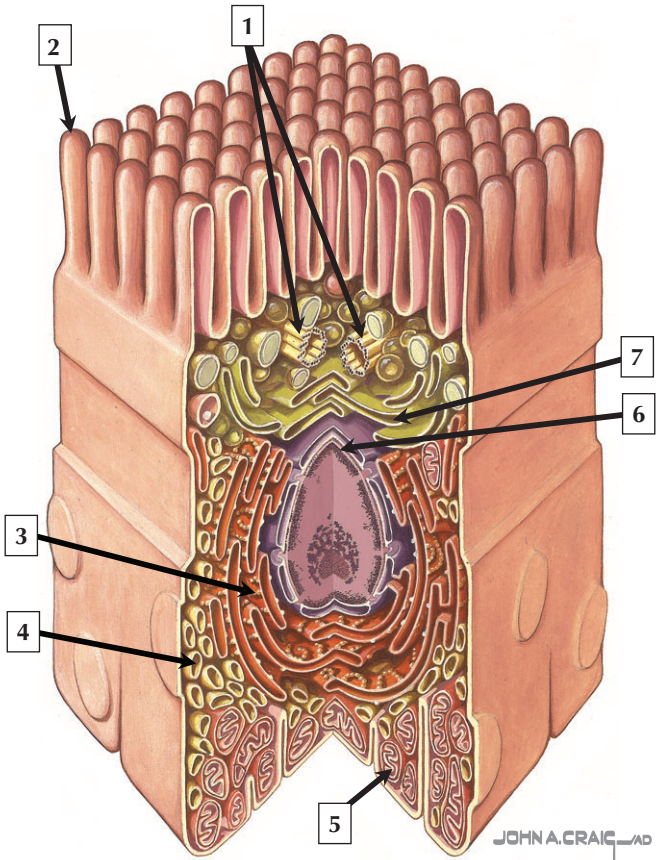
## **Cartilage and Bone**

- 6-1** Articular Hyaline Cartilage
- 6-2** Hyaline Cartilage
- 6-3** Fibrocartilage
- 6-4** Elastic Cartilage
- 6-5** Chondrocyte
- 6-6** Growth Plate
- 6-7** Spongy Bone
- 6-8** Cells of Bone
- 6-9** Compact Bone
- 6-10** Synovium

# Section 1: Cells and Tissues

## **Blood and Bone Marrow**

- 7-1** Formed Elements of Blood
- 7-2** Erythrocytes and Platelets
- 7-3** Neutrophil
- 7-4** Eosinophil
- 7-5** Basophil
- 7-6** Lymphocyte
- 7-7** Monocyte
- 7-8** Bone Marrow
- 7-9** Megakaryocyte
- 7-10** Erythropoiesis and Granulocytopoiesis



## The Cell

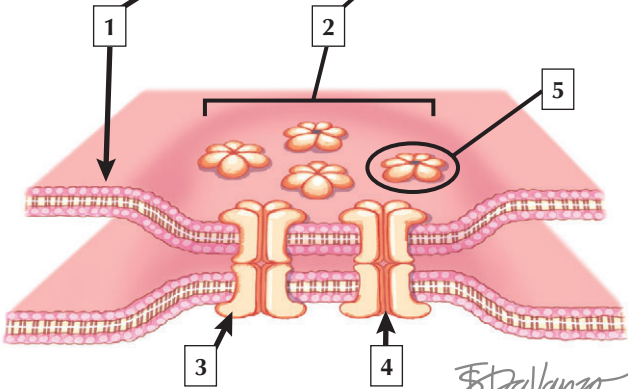
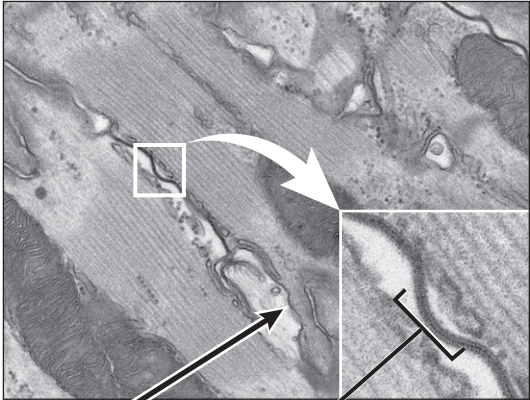
---

1. Centrioles
2. Microvillus
3. Rough endoplasmic reticulum
4. Smooth endoplasmic reticulum
5. Mitochondrion
6. Nucleus
7. Golgi complex

**Comment:** The cell is the fundamental structural and functional unit of all living organisms. The body contains about  $60 \times 10^{12}$  cells, of which there are approximately 200 different types. Cells vary widely in size and shape. A typical cell has polarized compartments and surface specializations; internal cell structure is modified to reflect function. The centrally placed nucleus is surrounded by endoplasmic reticulum. Mitochondria occupy the basal compartment, and the apical compartment contains the Golgi complex and a centriole. Apical microvilli increase the plasma membrane surface area for absorption.

**Electron microscopy (EM)**, as an adjunct to conventional histology, has advanced our knowledge of the cell and its organelles, and is an important tool in **ultrastructural pathology**. In many cases, EM is essential for definitive diagnosis of disease, such as the detection and recognition of some **neoplastic tumors**. It also provides valuable information on **infectious diseases, metabolic disorders**, and helps to determine the ultimate course of medical treatment.

*A composite cell cut open to show organization of its main components as seen via electron microscopy*



*F. Palvanzo* CMI



## Cell Junctions

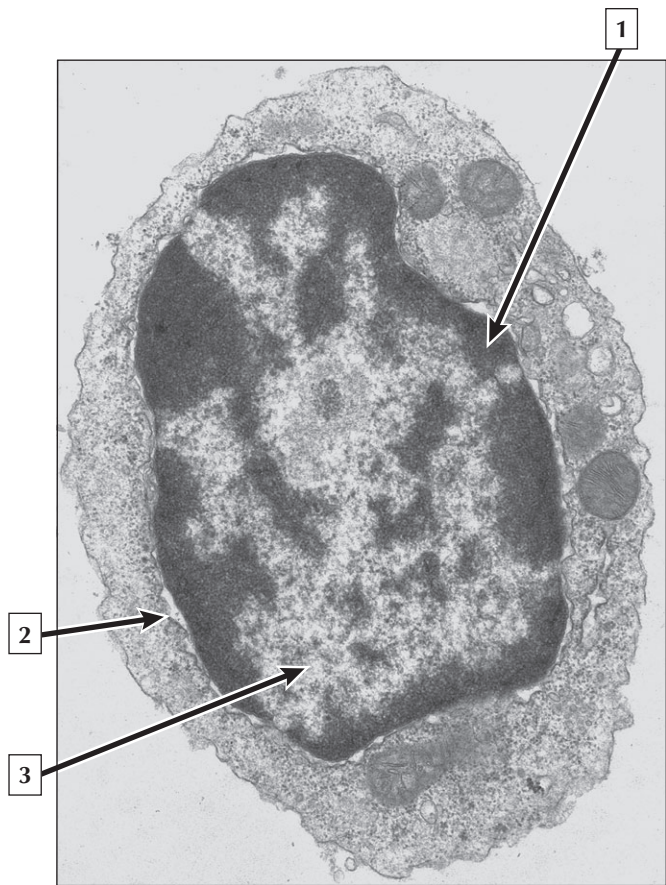
---

1. Plasma (cell) membrane
2. Gap (communicating) junction
3. Connexin monomer
4. Hydrophilic channel (pore)
5. Connexon (hexamer)

**Comment:** Metabolic, ionic, and low-resistance electrical communication occurs between adjacent cells via gap (communicating) junctions, in which a narrow gap of about 2 nm separates opposing cell membranes. They are specialized sites composed of large, tightly packed intercellular channels, which connect cytoplasm of adjacent cells. Each cylindrical channel, 10-12 nm long and 2.8-3.0 nm in diameter, consists of a pair of half-channels, termed connexons, which are embedded in the cell membranes. Each connexon comprises six symmetric protein subunits, called connexins, that are transmembrane proteins surrounding a small central aqueous pore (diameter: 1.5-2.0 nm).

Several diseases result from mutations in genes encoding **connexins**, which are named according to molecular size. Recessive mutations in connexin-26, with a molecular size of 26 kD, lead to the most common cause of **inherited human deafness**, which often affects the elderly. Connexin-26 is usually involved in K<sup>+</sup> transport in cells that support cochlear hair cells.

*EM of a gap junction in cardiac muscle at low and high magnification, and schematic of a gap junction*



# Nucleus

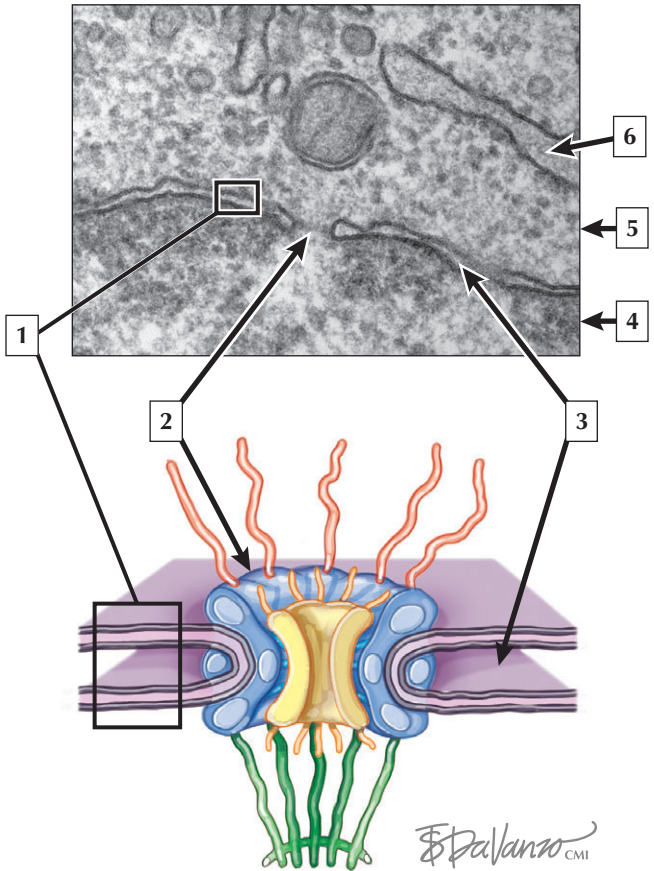
---

1. Heterochromatin
2. Nuclear envelope
3. Euchromatin

**Comment:** The nucleus is the largest, most conspicuous structure in the cell. Most cells have 1 nucleus. The nucleus consists of the nucleolus, chromatin, nuclear matrix, and nuclear envelope. A nuclear envelope encloses the nucleus of interphase cells and separates nucleus from cytoplasm. The nucleus contains genetic material (DNA) that is either packed or unpacked. Heterochromatin is the packed form, whereas euchromatin is the unpacked form. Histone proteins are involved in packaging of DNA into heterochromatin. Euchromatin represents unwound DNA in the process of transcription. The proportion of heterochromatin to euchromatin gives an indication of the general activity of the cell. Mature erythrocytes of most mammals do not contain nuclei since they are extruded during development.

**Histopathology** uses changes in nuclear morphology as diagnostic features. Many cellular disorders show an increase in nuclear-to-cytoplasmic ratio, nuclear indentation, ground glass appearance, crystalloid inclusions, or abnormal multinucleation. Aberrant nuclear location in a cell may also indicate cellular pathology or injury, such as the presence of centrally located nuclei in skeletal muscle fibers of patients with **muscular dystrophy**.

*EM of a lymphocyte*



# Nucleus

---

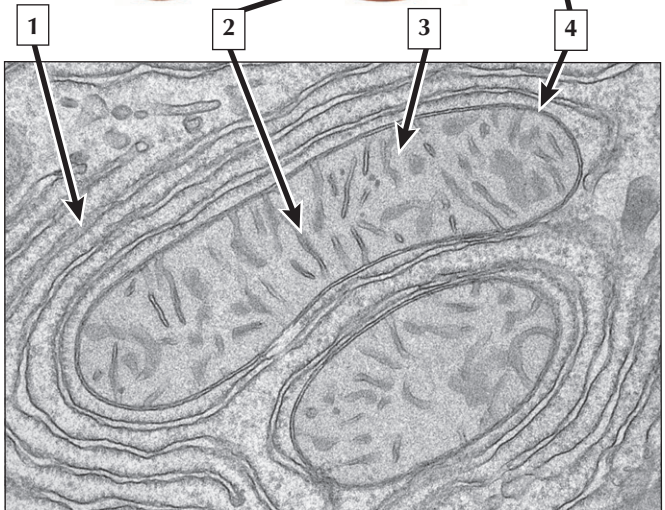
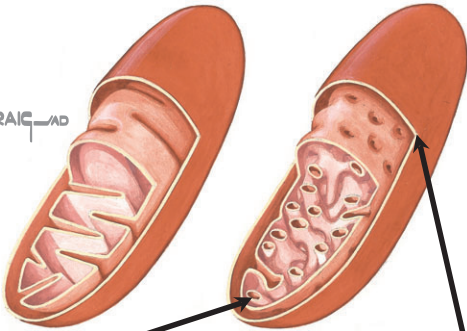1. Nuclear envelope
2. Nuclear pore (complex)
3. Perinuclear space
4. Nucleus (with heterochromatin)
5. Cytoplasm (Cytosol)
6. Rough endoplasmic reticulum (RER)

**Comment:** A nuclear envelope encloses the nucleus of interphase cells and separates nucleus from cytoplasm. It consists of two parallel unit membranes separated by a narrow space (10-70 nm wide) termed the *perinuclear space (cisterna)*. Many small octagonal apertures, called nuclear pores, perforate the envelope. About 100 nm in diameter, they permit selective, bidirectional exchange of small molecules, ribosomal subunits, and other substances between nucleus and cytoplasm. The outer rim of each pore forms by fusion of outer and inner nuclear membranes. A nuclear pore complex spanning the opening of each pore consists of eight proteins, or *nucleoporins*, around a central plug or granule.

The number and distribution of nuclear pore complexes vary widely according to activity and type of cell; they are especially numerous in metabolically active cells. Genetic mutations in the nucleoporin, *ALADIN*, have been linked to the autosomal recessive **Triple-A (Allgrove) syndrome**, also known as *Achalasia-Addisonianism-Alacrimia syndrome*.

*EM of a nuclear envelope, and schematic of a nuclear pore complex*

JOHN A. CRAIG AD



## Mitochondria

---

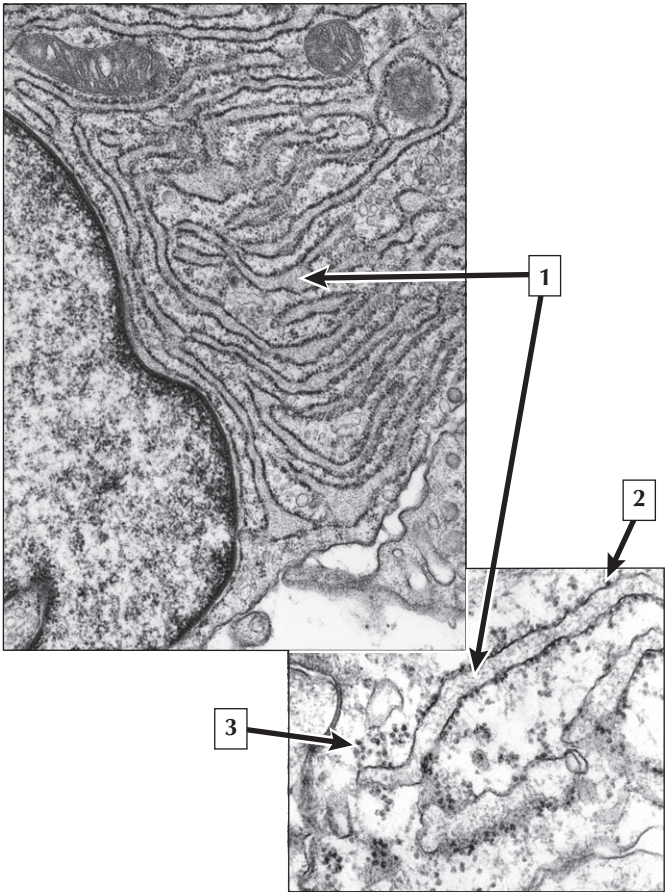
1. Rough endoplasmic reticulum (RER)
2. Cristae
3. Mitochondrial matrix
4. Outer mitochondrial membrane

**Comment:** Mitochondrial shape varies with plane of section and type of cell. Each organelle has thin, shelf, or tubular cristae that project into the mitochondrial matrix. The outer mitochondrial membrane has a smooth contour. It consists mostly of the large channel-forming protein—porin—which increases membrane permeability for passage of molecules and metabolites required for ATP synthesis. The inner mitochondrial membrane is thrown into a series of transverse shelf-like or tubular folds known as cristae. The mitochondrial matrix has an increased electron density that is finely granular.

**Mitochondrial myopathies** are a group of diseases that result primarily in muscle weakness and dysfunction. They are typically inherited disorders, which vary from mild to life threatening. They are caused by mutations in mitochondrial DNA, of which there are over 50 harmful mutations. The most common symptoms are severe muscle weakness, cramps, spasm, and cardiac involvement.

*Schematic of mitochondria and EM of mitochondria in a hepatocyte*

# Ribosomes





## Ribosomes

---

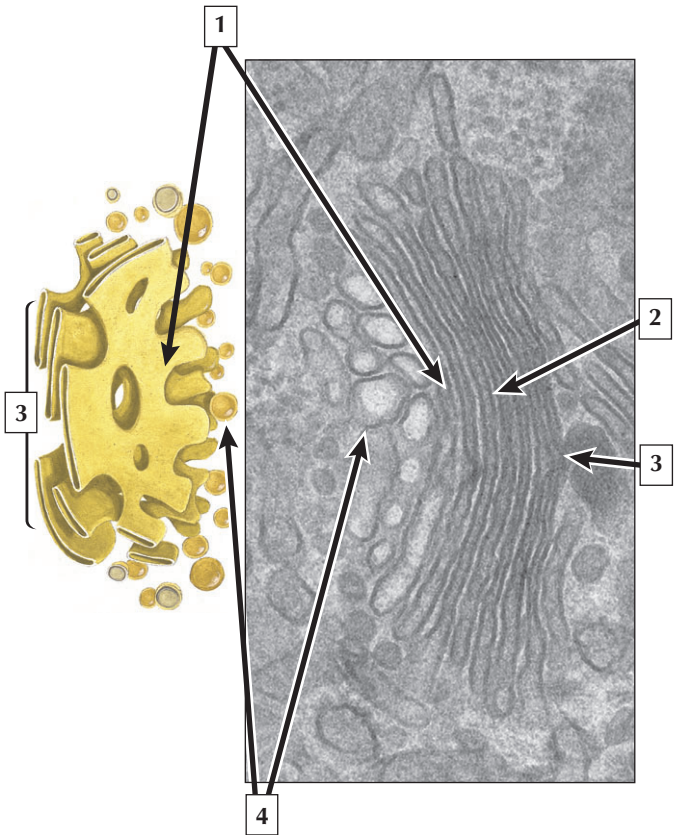
1. Cisterna of rough endoplasmic reticulum (RER)
2. Ribosome
3. Polyribosome

**Comment:** Ribosomes are small, spherical, electron-dense particles that synthesize proteins. They are uniform in size, about 15 to 20 nm in diameter, and consist mostly of RNA and associated proteins. Free ribosomes in the cytoplasm occur as single particles or rosette-like clusters, known as polyribosomes, which consist of several ribosomes arranged along a thread of messenger RNA (mRNA). Single ribosomes are inactive, whereas polyribosomes are active in protein synthesis, where they assemble specific amino acids into polypeptides. Ribosomes may be attached to membranes of the rough-surfaced endoplasmic reticulum (RER) or to the outer nuclear membrane. Polyribosomes synthesize proteins for internal use by the cell, whereas ribosomes attached to the RER engage in protein synthesis for export from the cell or for proteins destined for lysosomes.

**Antibiotics** are used clinically to treat **bacterial infections**. Many such pharmaceuticals inhibit the proliferation of infectious bacteria by targeting the ribosome. They bind to specific regions of the large or small subunit, interfering with translation and protein synthesis in the pathogen. Antibiotic resistance has become a serious public health problem around the world.

*EM of part of an active fibroblast and higher magnification EM of part of a protein-synthesizing cell*

# Golgi Complex



# Golgi Complex

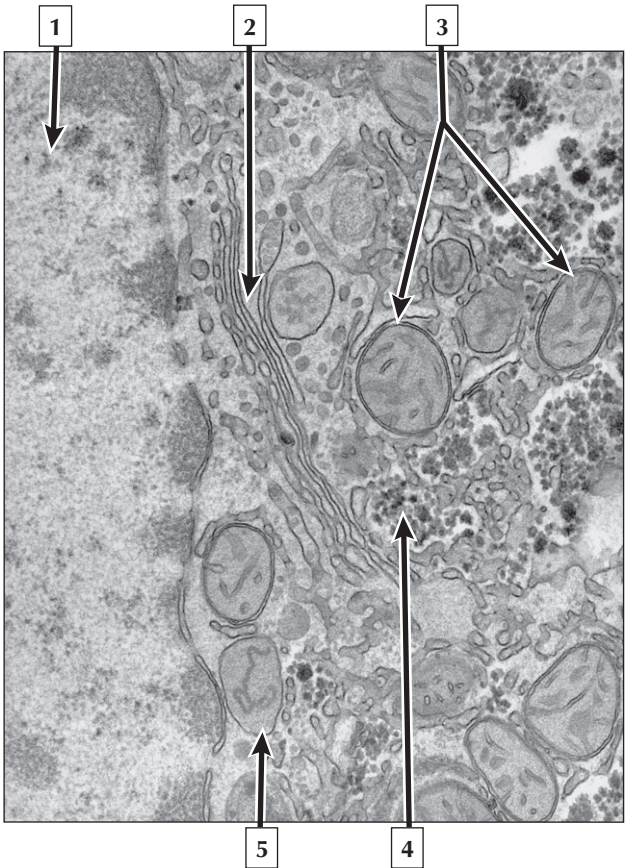
---

1. Trans-surface of Golgi complex
2. Saccule of medial compartment
3. Cis-surface of Golgi complex
4. Golgi vesicles

**Comment:** The Golgi complex (or apparatus) is a complex array of flattened, slightly curved, closely packed membrane-bound sacs. This highly polarized, compartmentalized organelle has convex and concave sides and 3 functionally distinct compartments: a *cis*-Golgi network of vesicles on the convex side, a medial compartment of stacks of flattened saccules, and on the concave side a *trans*-Golgi network of vesicles and vacuoles for distribution and sorting of secretory products. Each saccule in the medial compartment contains a different group of processing enzymes that reside in its membranes as integral membrane proteins. Some cells have 1 Golgi complex; others, which actively synthesize proteins and polysaccharides, have many. The Golgi complex adds proteins to sugars to form glycoproteins, assembles polysaccharides, elaborates membrane lipids, and produces lysosomes that are kept by cells.

**Disassembly of the Golgi complex** occurs in cells undergoing apoptosis (or programmed cell death) whereby extensive and irreversible fragmentation of this organelle forms small tubulo-vesicular components. This feature is probably due to a caspase-related cleavage of integral Golgi tethering proteins. Caspases are proteases in the cytoplasm that become activated early in apoptosis.

*Schematic and high-magnification EM of the Golgi complex showing its functional compartments*



# Cytoplasm

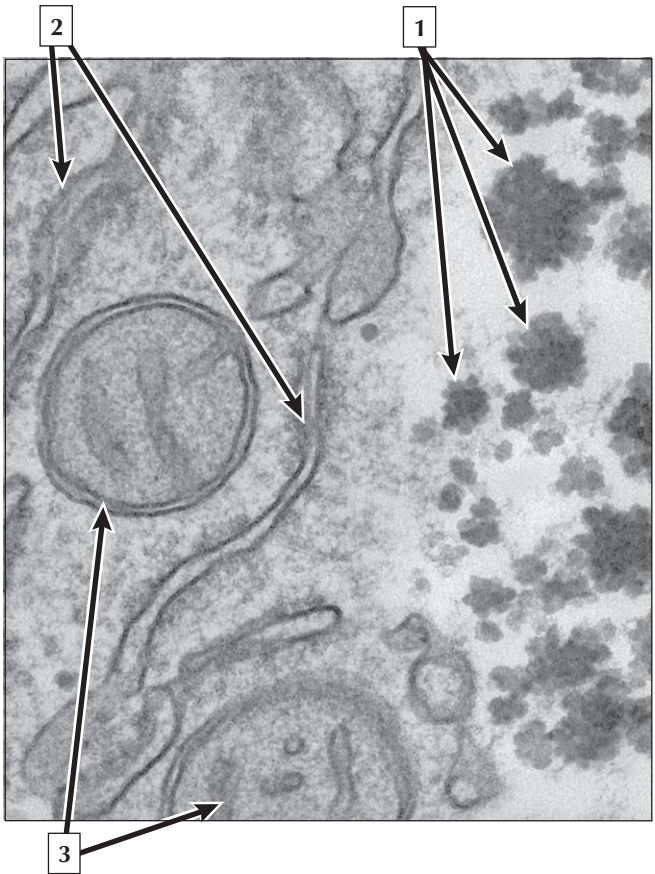
---

1. Nucleus
2. Golgi complex
3. Mitochondria
4. Glycogen
5. Peroxisome

**Comment:** The cytoplasm is a complex aqueous gel made of water (about 70%), proteins, lipids, carbohydrates, and organic and inorganic molecules. Organelles and inclusions are in the cytoplasm. Electron-dense glycogen particles within the cytoplasm form aggregates and are not membrane-bound. Peroxisomes are enveloped by a single membrane and contain crystalline or strand-like deposits. Mitochondria are distinguished from peroxisomes by an inner and outer membrane.

**Zellweger (or cerebrohepatorenal) syndrome** is a peroxisomal disorder that usually leads to abnormalities in the brain, kidneys, and liver. Affected infants die soon after birth, which is most likely due to faulty neural cell myelination *in utero*.

*EM of peroxisomes in a liver hepatocyte*



## Inclusions

---

1. Glycogen rosettes
2. Rough endoplasmic reticulum (RER)
3. Mitochondria

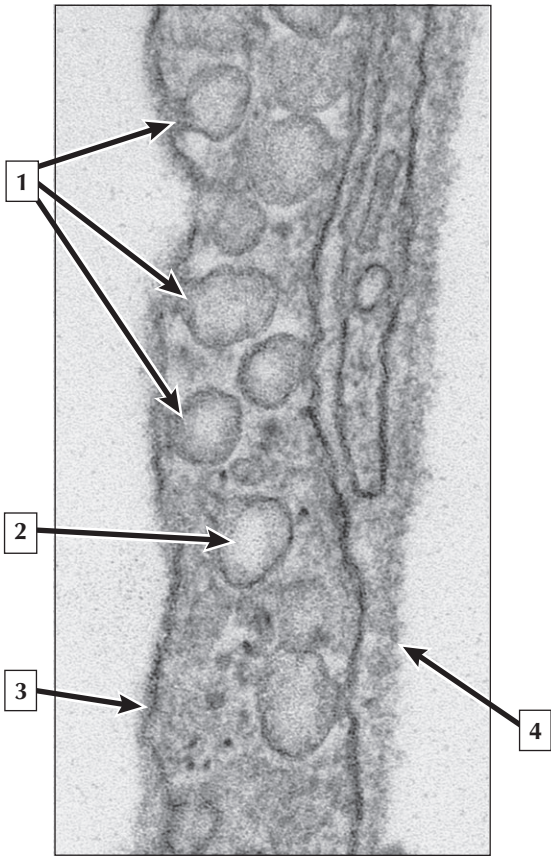
**Comment:** Glycogen—a cytoplasmic inclusion—appears as small, electron-dense particles (20 to 40 nm in diameter). They are free in the cytoplasm and are not membrane-bound. Aggregates of glycogen particles form irregular patches known as alpha particles (or rosettes). Glycogen—a d-glucose polymer—is stored mostly in the cytoplasm of hepatocytes of the liver and skeletal muscle fibers. It also occurs in smaller amounts in cells of other tissues. Synthesis, storage, and breakdown of glycogen occur rapidly according to need. By light microscopy, glycogen can be visualized with the *periodic acid-Schiff* stain.

**Glycogen storage disease (GSD)** is a group of more than 10 inherited “inborn errors of metabolism” that affect the synthesis or breakdown of glycogen. These **autosomal recessive disorders** typically occur in childhood.

**von Gierke disease (or Type I GSD)** is a deficiency of the enzyme glucose-6-phosphatase. It leads to an abnormal accumulation of glycogen in muscle and liver cells, which causes clinically significant end-organ disease and morbidity.

*High-magnification EM of glycogen rosettes in a hepatocyte*

# Cytoplasmic Vesicles





# Cytoplasmic Vesicles

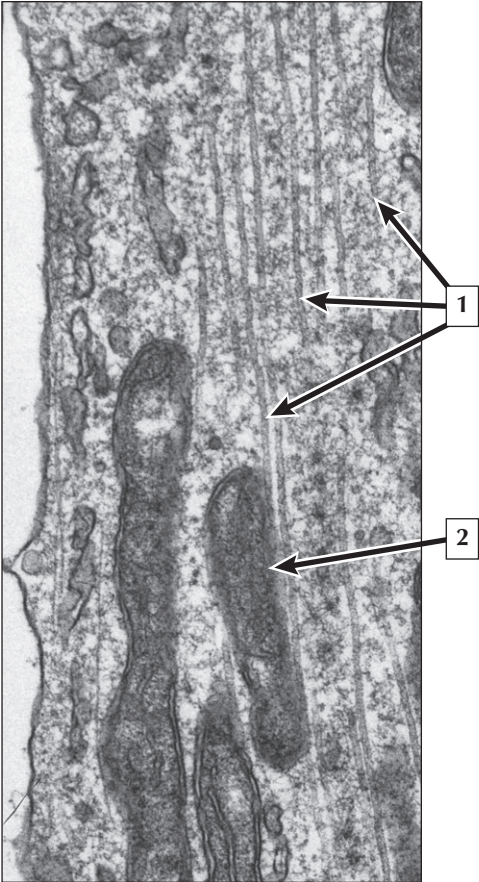
---

1. Caveolae
2. Cytoplasmic vesicle
3. Plasma membrane
4. Basement membrane

**Comment:** Cells have several kinds of membrane-bound vesicles that form by invaginations of plasma membrane. They then enter the cytoplasm by pinching off from the surface and are transported to other parts of the cell. Many caveolae in endothelial cells mediate transcytosis, whereby vesicles derived from caveolae are taken across a cell and release their contents at another surface. Other kinds of cytoplasmic vesicles, most derived from the Golgi complex, engage in exocytosis. Vesicles move to the cell surface, fuse with plasma membrane, and discharge contents to the cell exterior.

**Familial hypercholesterolemia** is an autosomal dominant disorder caused by a mutation in the gene on chromosome 19 that encodes the LDL receptors. The defective receptors lose their affinity for coated pits, and cellular uptake of cholesterol is blocked. This causes a severe elevation in serum cholesterol, which may lead to premature atherosclerotic lesions in the walls of blood vessels, such as the coronary arteries.

*EM of caveolae and vesicles in an endothelial cell of a capillary*



# Cytoskeleton

---

1. Microtubules
2. Mitochondrion

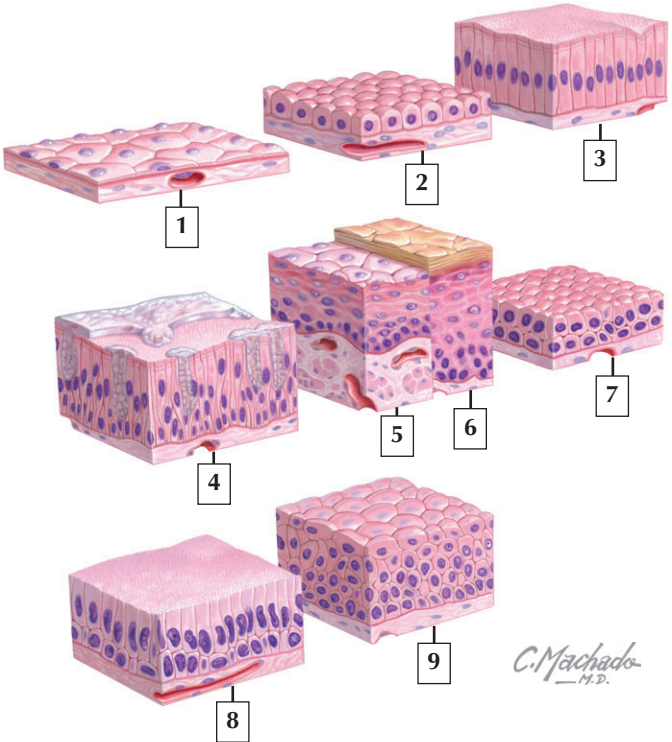
**Comment:** Microtubules are hollow, semirigid cylindrical organelles of uniform diameter (25 nm) but extremely variable in length and are particularly abundant in neurons, platelets, leukocytes, and dividing cells. They form a major component of the cytoskeleton by helping to provide mechanical strength and establish cell shape. They engage in intracellular transport of organelles (such as mitochondria and cytoplasmic vesicles), ciliary and flagellar motility, mitotic spindle formation, chromosome translocation, and cytokinesis during cell division. They are not bound by a membrane, and their walls are composed of linear polymers (or protofilaments) of the globular protein, tubulin. Microtubules are the main constituent of cilia, flagella, and centrioles.

**Microtubule targeting drugs**, such as Taxol and Vinblastine, are used in **cancer therapies** to treat many human **malignancies**. They prevent mitotic spindle formation in tumor cells by inhibiting cell division at the metaphase/anaphase transition. Whereas taxol mainly acts to stabilize microtubules, vinblastine blocks mitosis by depolymerizing microtubules.

*EM of microtubules in a cultured cell*

# Classification of Epithelia

Identify the types of epithelium.



## Classification of Epithelia

---

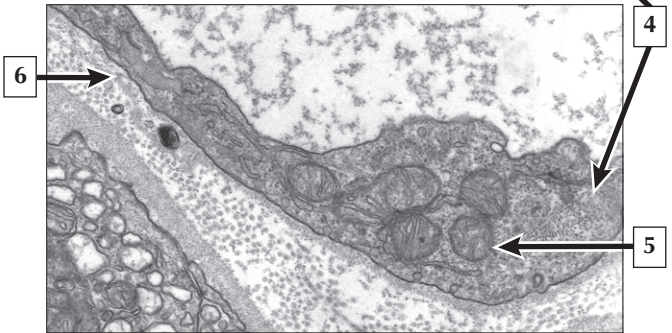
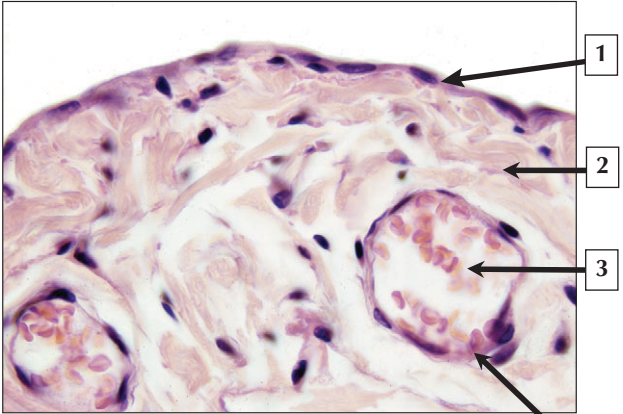
1. Simple squamous
2. Simple cuboidal
3. Simple columnar
4. Pseudostratified columnar
5. Stratified squamous nonkeratinized
6. Stratified squamous keratinized
7. Stratified cuboidal
8. Stratified columnar
9. Transitional (Urothelium)

**Comment:** Epithelium is composed of continuous sheets of cells that line internal cavities and exposed surfaces of the body. It can also form glands within underlying connective tissue. The main function of epithelium is to serve as a selective barrier that protects tissues. Epithelial cells can engage in synthesis, secretion, absorption, and sensory reception. They have a high mitotic index due to mechanical stress and trauma at their free surface.

Epithelium is exposed to surfaces where it may be freely accessible to carcinogens. Thus, the most common types of **cancerous tumors** (or **neoplasms**) in adults originate from epithelial cells. Neoplasms that are slow growing are **benign tumors**, whereas those that invade (or metastasize) to distant tissues and organs are **malignant tumors**.

*Schematic of the various types of covering and lining epithelia*

# Simple Squamous Epithelium



## Simple Squamous Epithelium

---

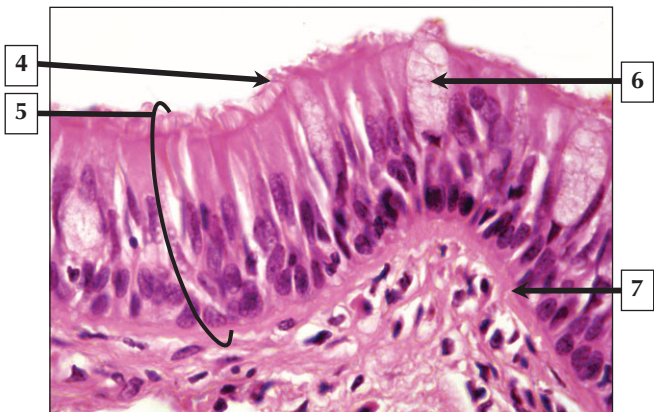
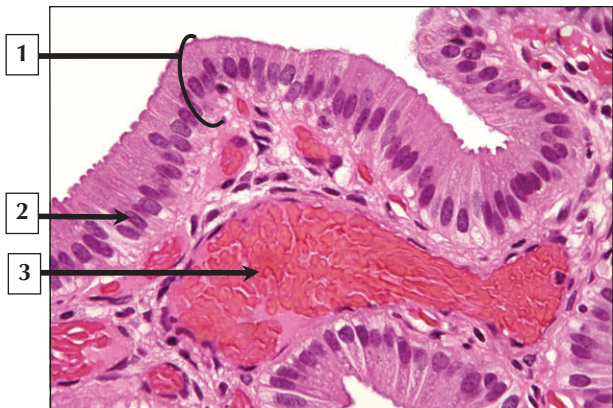
1. Mesothelium
2. Connective tissue
3. Lumen of venule
4. Endothelial cell (endothelium)
5. Mitochondrion
6. Basal lamina

**Comment:** Simple squamous epithelium lines visceral cavities, lumina of vessels, and tubules of the body. The epithelium is extremely thin and delicate and is susceptible to histologic artifact during preparation. It serves as an active barrier for rapid diffusion of many substances such as water in the loop of Henle, air diffusion in the lung, endothelium of blood, and lymphatic vessels. It also lines the organs and mesenteries of the thoracic and peritoneal cavities, where it is known as mesothelium.

**Malignant mesotheliomas** are rare and aggressive tumors that can arise from the parietal and visceral serous membranes of the pleural, peritoneal, and pericardial cavities. **Pleural mesothelioma**—the most common type—is usually caused by occupational exposure to asbestos and can have a long latency period from initial exposure to onset of symptoms.

*LM of the serosa of the urinary bladder and EM of a capillary endothelial cell.*

## Simple Columnar and Pseudostratified Epithelia





## Simple Columnar and Pseudostratified Epithelia

1. Simple columnar epithelium
2. Nucleus of columnar epithelial cell
3. Lumen of venule
4. Ciliated border
5. Pseudostratified ciliated columnar (respiratory) epithelium
6. Goblet cell
7. Basement membrane

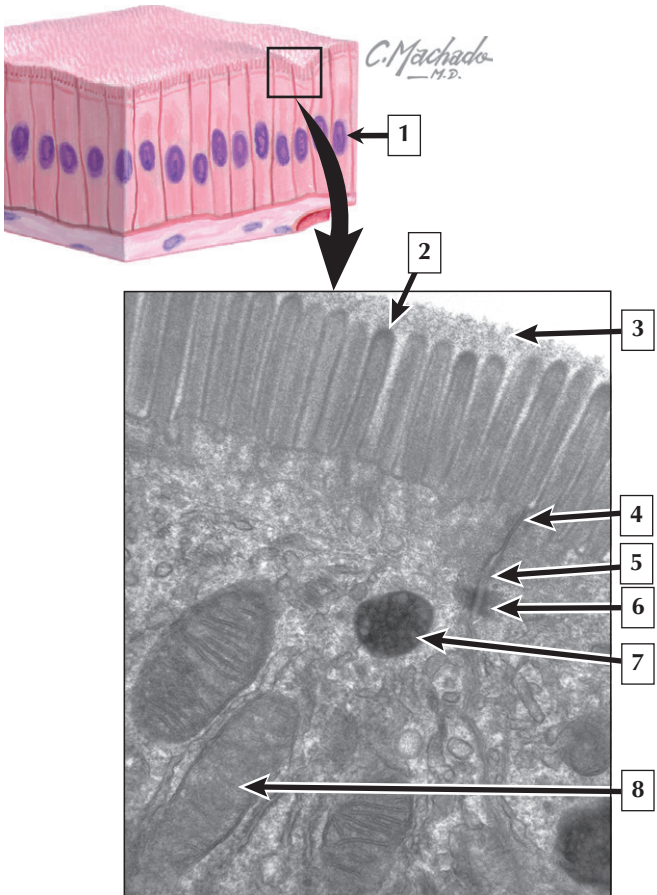
**Comment: Simple columnar epithelium** lines the small and large intestines, inner lining of the stomach, major ducts of glands, convoluted tubules of the kidney, gallbladder, small bronchi of the lungs, and parts of the male and female reproductive tracts. The base of each cell rests on a basement membrane, and the apical surface contacts a lumen. The nucleus is ovoid in shape and is centrally or basally placed. This epithelium is mainly found in sites engaged in protection of wet surfaces, absorption of nutrients, and secretion.

**Pseudostratified (respiratory) epithelium** consists of more than one type of epithelial cell that show variation in size, shape, and function. The basal layer belongs to replacement (stem) cells that retain mitotic potential. The more apical layer of nuclei belongs to tall columnar cells, many of which bear cilia on their surface. Whereas all cells contact a basement membrane, only some reach the free surface. Mucous goblet cells are usually present in this epithelium.

**Epithelial metaplasia** occurs when one type of mature differentiated epithelium is converted to another adult form. In the airways, metaplasia of respiratory epithelium to a stratified squamous epithelium frequently occurs as a protective response to chronic cigarette smoking.

*LM of the inner lining of the gallbladder and LM of pseudostratified ciliated columnar epithelium with goblet cells lining the upper respiratory tract*

# Simple Columnar Epithelium



## Simple Columnar Epithelium

---

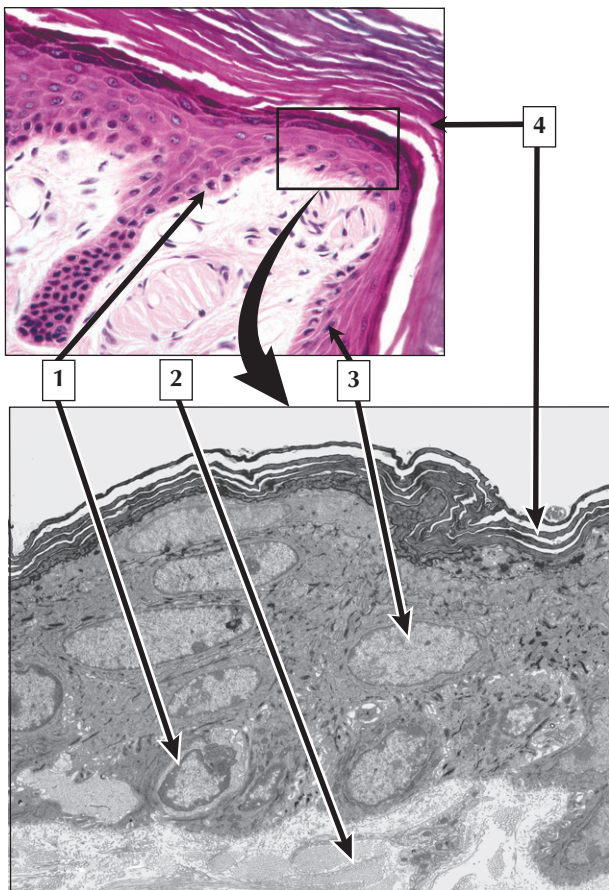
1. Nucleus of columnar epithelial cell
2. Microvillus
3. Glycocalyx
4. Tight junction
5. Intermediate junction
6. Desmosome
7. Lysosome
8. Mitochondrion

**Comment:** Simple columnar epithelium consists of a single layer of cells that are taller than they are wide. To increase their surface area, the free surfaces of the cells often bear microvilli, which are thin, finger-like cellular projections. When microvilli are prominent, uniform in size, and tightly packed, they constitute a striated or brush border. Brush borders that consist purely of microvilli are found at the apical borders of enterocytes in the small intestine and proximal tubule cells of the kidney. The major function of these cells is absorption.

**Malabsorption** of nutrients, vitamins, and metabolites can result from damage to microvilli of the small and large intestine. **Microvillus inclusion disease** is a congenital disorder that is characterized by improper incorporation of microvilli into the apical membrane of enterocytes.

*Schematic of columnar epithelium and EM of the brush border of two enterocytes in the small intestine.*

## Stratified Squamous Keratinized Epithelium



## Stratified Squamous Keratinized Epithelium

---

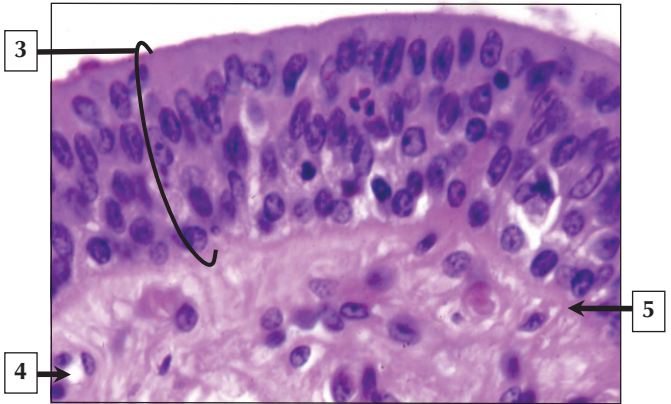
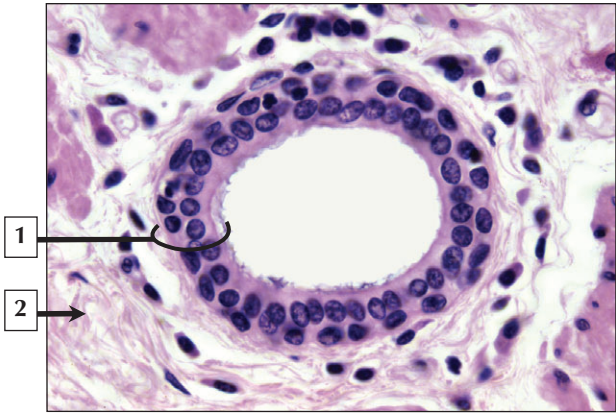
1. Basal cell
2. Dermis (collagen)
3. Nucleus of keratinocyte
4. Keratin

**Comment:** Stratified squamous keratinized epithelium is a tough and resilient epithelium that is mainly protective against abrasion and dehydration. It also prevents invasion of pathogens, bacteria, and other infectious agents. In the epidermis of skin, the surface layer contains dead cells devoid of nuclei. Their cytoplasm is transformed into plates of the protein keratin, which strengthens and waterproofs the tissue. This epithelium has a dry and scale-like surface. It also lines the outer surface of the tympanic membrane, parts of the oral cavity, and mucocutaneous junctions. The keratinized epithelium that constitutes the epidermis of skin is renewed every 15 to 30 days.

**Basal cell** and **squamous cell carcinoma** are the most common types of **skin cancer**. These malignant growths can be caused by overexposure to the sun, chemicals, burns, or genetic disease. Diagnosis can usually be made by a simple biopsy of the affected area, and tumors are often removed surgically.

*LM and EM of stratified squamous keratinizing epithelium of the epidermis*

# Stratified Epithelium



## Stratified Epithelium

---

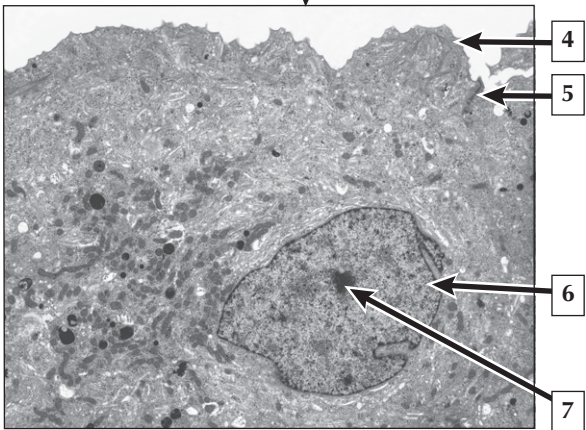
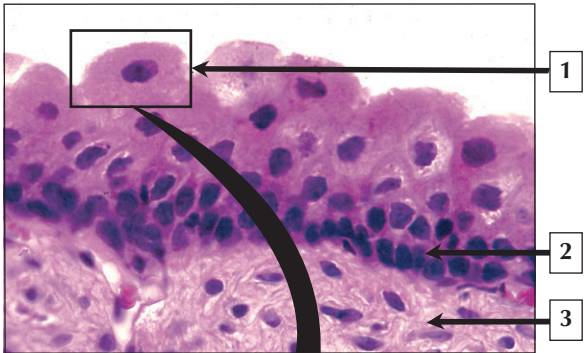
1. Stratified cuboidal epithelium (duct of mucous gland)
2. Connective tissue (stroma)
3. Stratified columnar epithelium (of male urethra)
4. Capillary
5. Basement membrane

**Comment:** Stratified cuboidal and stratified columnar epithelia have a limited distribution in the adult. They both contain 2 or more layers of cells, and because they are stratified, they are primarily protective and better suited to withstand wear-and-tear than simple epithelia. Stratified cuboidal epithelium is usually made of 2 layers of cuboidal cells. It lines the ducts of sweat glands and other exocrine glands. Stratified columnar epithelium is in the pharynx and larynx, conjunctiva of the eyelids, major ducts of exocrine glands, and parts of the male urethra. It also occurs at sites of epithelial transition, where it is interposed between 2 other types of epithelia. Such epithelial interfaces are abrupt and occur in the epiglottis and recto-anal junction.

**Urethritis** is an inflammation of the urethral lining that can be caused by viral or bacterial infection, or reactions to substances. The infection or irritation causes infiltration of white blood cells and swelling of the submucosa. Without treatment, infections may travel up the urinary tract to the bladder, ureter, or kidneys.

*LM of stratified cuboidal epithelium lining the duct of a mucous gland and stratified columnar epithelium of the male urethra*

# Transitional Epithelium





# Transitional Epithelium

---

1. Umbrella cell
2. Nucleus of basal cell
3. Lamina propria (loose connective tissue)
4. Apical plasma membrane
5. Junctional complex (tight junction)
6. Nucleus
7. Nucleolus

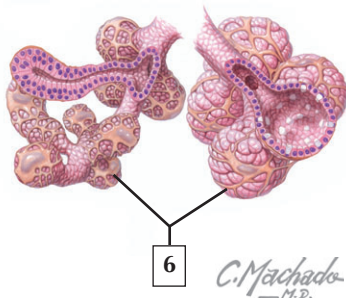
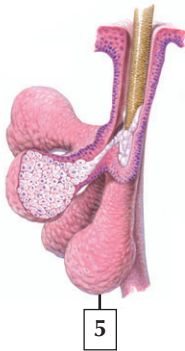
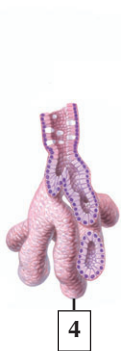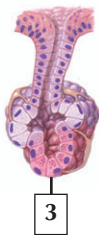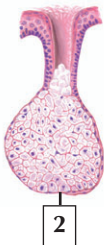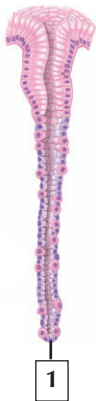**Comment:** Transitional epithelium (urothelium) is a multilayered epithelium found in the lower urinary tract, where it lines the renal pelvis, ureters, urinary bladder, and part of the urethra. The appearance of urothelium is not static. It rapidly adapts to distention and contraction by changing from a tall epithelium, which is many cells thick (5 to 7 cells) in the empty bladder, to a thinner epithelium, which is only a few layers thick (2 to 3 cell layers) in the distended state. Umbrella cells are highly dynamic cells at the luminal surface that are able to cycle apical membrane components to accommodate the change in cell surface area.

**Transitional cell carcinoma (TCC)** is a common **malignant neoplasm** of the urinary tract arising from the urothelium of the renal pelvis, ureter, or bladder. It is usually fatal unless treated. **Hematuria** (blood in the urine) and pain due to gradual obstruction to urination are common presenting symptoms.

*LM of the urinary bladder in a distended bladder and EM of an umbrella cell lining the bladder*

# Classification of Exocrine Glands

Identify the types of exocrine glands.



C. Machado  
— M.D.

## Classification of Exocrine Glands

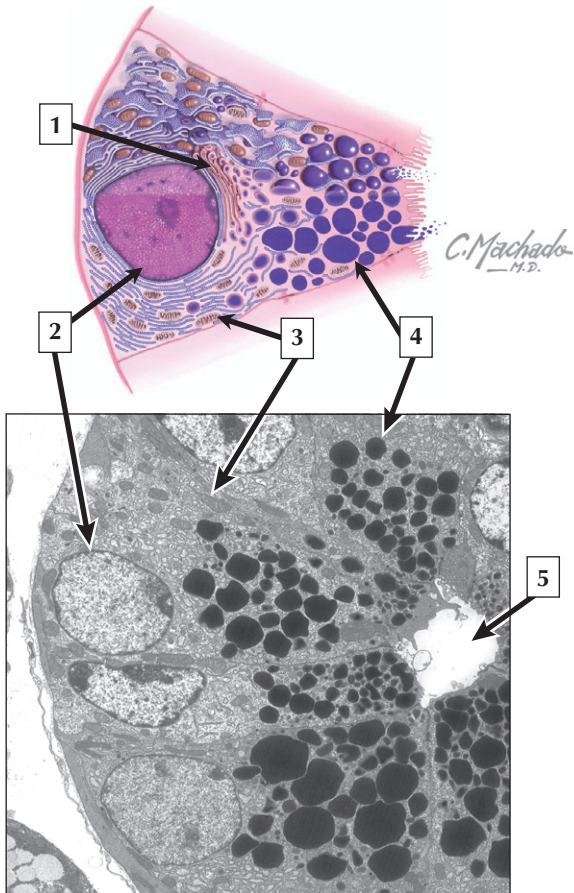
---

1. Simple tubular
2. Simple acinar
3. Simple tubulo-acinar
4. Compound tubular
5. Compound acinar
6. Compound tubulo-acinar (-alveolar)

**Comment:** Multicellular exocrine glands are classified by the shape and arrangement of their secretory units. They may be **tubular**, **acinar (alveolar)**, or **tubulo-acinar (i.e., mixed)**. They may be further classified by the structure of their duct system: **simple** or unbranched, as in sweat glands, and **compound** or branched, as in most organs such as the pancreas and liver. Glands may be classified by the nature of their secretions. They may be **mucous**, when the secretion is a viscous glycoprotein known as mucus, **serous**, when the secretion is watery and enzyme-rich, or **mixed seromucous**, when the same gland produces both secretions. Glands may also be classified by their mode of secretion. **Merocrine secretion**—the most common type—involves the release (or exocytosis) of secretory vesicles from the cell by fusion with its plasma membrane. **Apocrine secretion**, such as in the mammary gland, involves the release of the apical cytoplasm of the cell. **Holocrine secretion** in the sebaceous glands of the skin involves the disintegration and release of whole cells.

**Malignant tumors** of glandular epithelial cells are known as **adenocarcinomas**. Such tumors have glandular (secretory) properties, and include cancers of the breast, prostate, colon, stomach, pancreas, thyroid, and uterine cervix.

*Schema of the various types of exocrine glands*



## Serous Cells

---

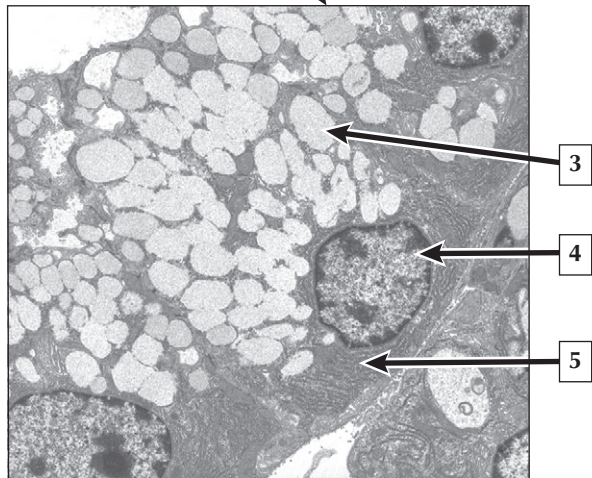
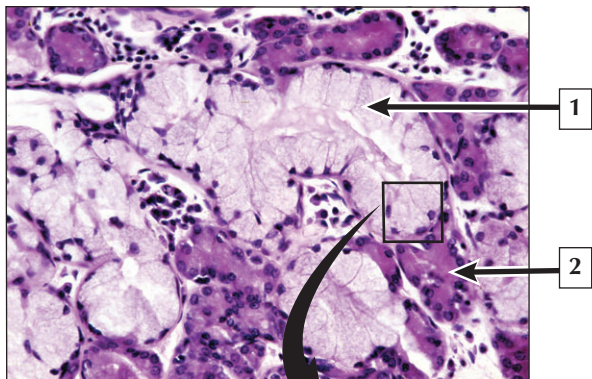
1. Golgi complex
2. Nucleus
3. Mitochondrion
4. Secretory vesicle
5. Lumen of serous acinus

**Comment:** Serous cells are polarized secretory cells that produce a watery proteinaceous secretion that typically contains enzymes. They are found in secretory units of pure serous glands such as the parotid, lacrimal gland, and exocrine pancreas. They are also present in mixed sero-mucous glands such as the major and minor salivary glands of the digestive tract and in the walls of the upper airways of the respiratory tract. Ultrastructurally, serous cells contain condensing vacuoles that concentrate the secretory product and give rise to electron-dense vesicles (also known as zymogen granules). They accumulate in the apical cytoplasm for temporary storage prior to release. The contents of the mature secretory vesicles are discharged from the apical part of the cell by the mechanism of exocytosis.

**Parotitis**, a painful swelling of the glandular tissue in the parotid gland, is commonly caused by the contagious viral disease **mumps (paramyxovirus)**, or by bacterial infection, and can cause destruction of the serous acinar cells. Recovery is usually complete, and immunity to the disease persists over a lifetime.

*Schematic of a typical serous cell and EM of a portion of a serous acinus*

## Mucous Cells



## Mucous Cells

---

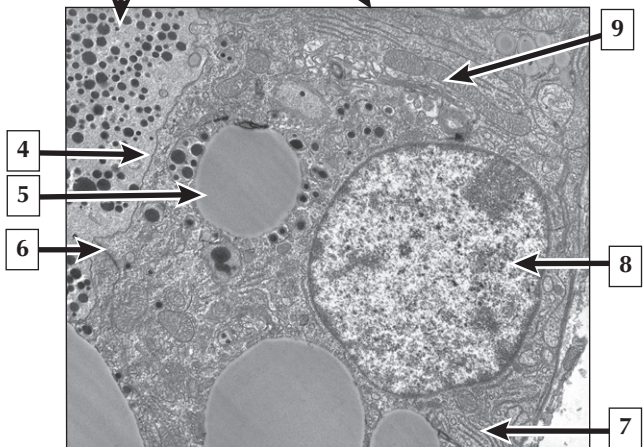
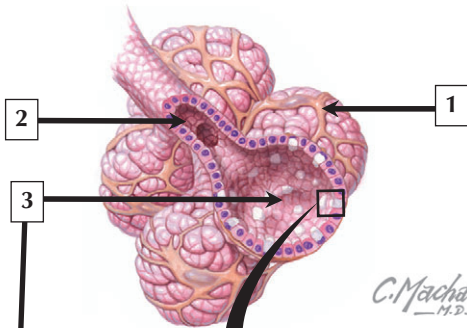
1. Mucous acinus
2. Serous acinus
3. Secretory vesicle or mucous droplet
4. Nucleus
5. Rough endoplasmic reticulum (RER)

**Comment:** Mucus (or mucin) is a highly viscous glycoprotein that provides protection and lubrication to surfaces. Cells that produce mucus have a wide distribution in the body. They are found either singly as goblet cells in the epithelium of the digestive, respiratory, and reproductive tracts or in groups organized as tubules or acini. Most notably, they are encountered in the major and minor salivary glands of the oral cavity that are either purely mucous or mixed sero-mucous in composition. Because mucus droplets that dominate in the cytoplasm are dissolved out by most histologic methods, the cytoplasm is typically pale staining and vacuolated in routine hematoxylin and eosin sections.

**Excessive mucus production** in the respiratory system can be caused by an immune response to allergens (e.g., **asthma**), **chronic obstructive pulmonary disease (COPD)**, pollutants, infection, or by genetic diseases such as cystic fibrosis. Excess mucus blocks airway passages and leads to wheezing and dyspnea.

*LM of a seromucous gland in the trachea and EM of a mucous acinus in a mixed salivary gland*

# Mammary Gland





# Mammary Gland

---

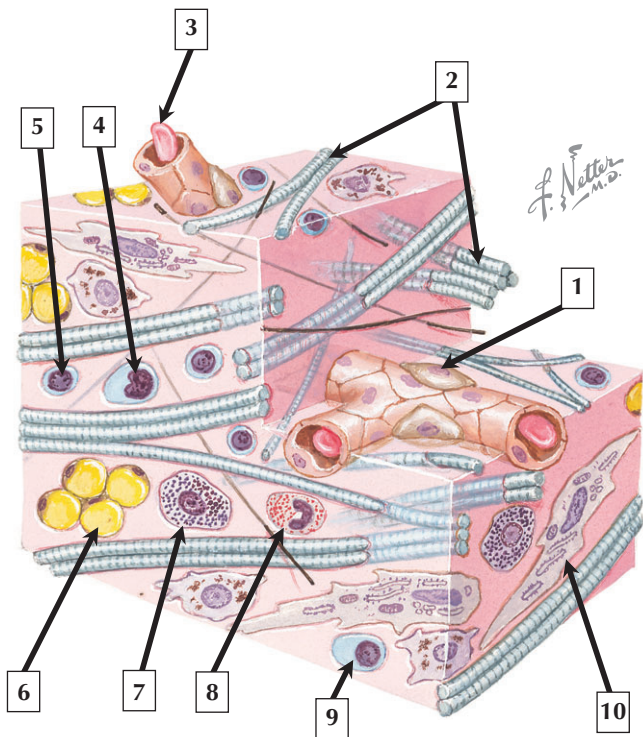
1. Myoepithelial cell
2. Duct
3. Lumen of alveolus
4. Apical plasma membrane
5. Lipid droplet
6. Intercellular (tight) junction
7. Rough endoplasmic reticulum (RER)
8. Nucleus euchromatin
9. Mitochondrion

**Comment:** Each mammary gland consists of 12 to 20 irregular lobes, each lobe consisting of a compound tubulo-alveolar gland. The size, shape, and histologic structure of these glands change with age and functional status of the reproductive system. During pregnancy, the simple cuboidal epithelium that lines the alveoli undergoes hyperplasia and hypertrophy under stimulation of prolactin. Branching myoepithelial cells that enwrap the alveoli contract in response to oxytocin to eject milk.

**Breast cancer**, or **mammary carcinoma**, is the most common malignancy in women, and usually occurs after menopause. Most invasive primary breast cancers are **adenocarcinomas**. They arise from the epithelium of the lactiferous ducts, and may penetrate the basement membrane and proliferate into the surrounding stroma.

*Schematic of a tubulo-alveolar gland and EM of part of a secretory alveolus in a lactating mammary gland*

# Loose Connective Tissue



## Loose Connective Tissue

---

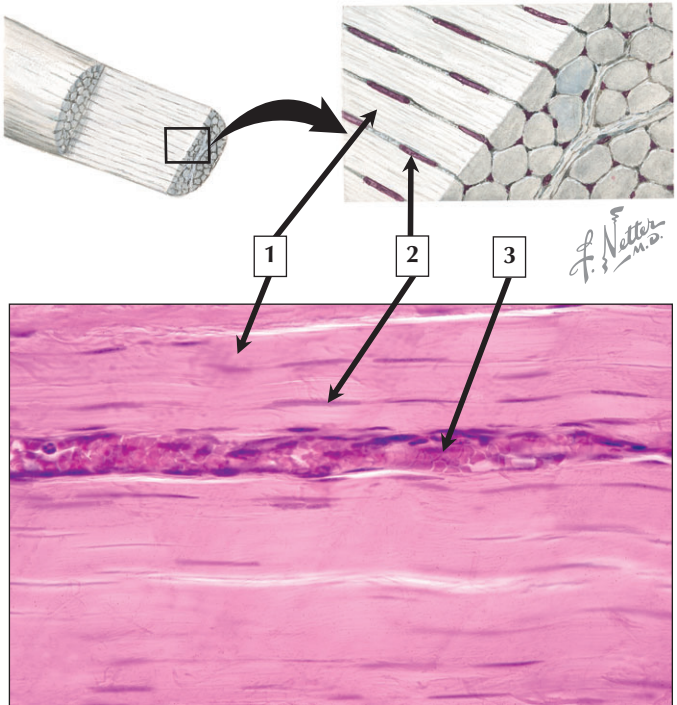
1. Pericyte
2. Collagen fibers
3. Erythrocyte in capillary
4. Monocyte
5. Lymphocyte
6. Adipocyte
7. Mast cell
8. Eosinophil
9. Plasma cell
10. Fibroblast

**Comment:** Connective tissue, one of the 4 basic bodily tissues, serves many functions including providing support and form to the body and organs, aiding in defense and protection, serving as a medium of exchange of nutrients between tissues, storage of fat, and thermoregulation. Connective tissue proper consists of cells and an extracellular matrix composed of fibers embedded in an amorphous ground substance. The proportion and density of fibers in the extracellular matrix (ECM) defines whether it is classified as loose (areolar) or dense connective tissue. Cells of connective tissue include fibroblasts, mast cells, macrophages, adipocytes, plasma cells, and pericytes.

**Tumors** of connective tissue or its mesenchymal precursors are known as **sarcomas**. The most common soft tissue sarcoma in adults is **malignant fibrous histiocytoma**.

*Schematic of loose connective tissue*

# Dense Connective Tissue



4 The image above is a section of \_\_\_\_\_.

## Dense Connective Tissue

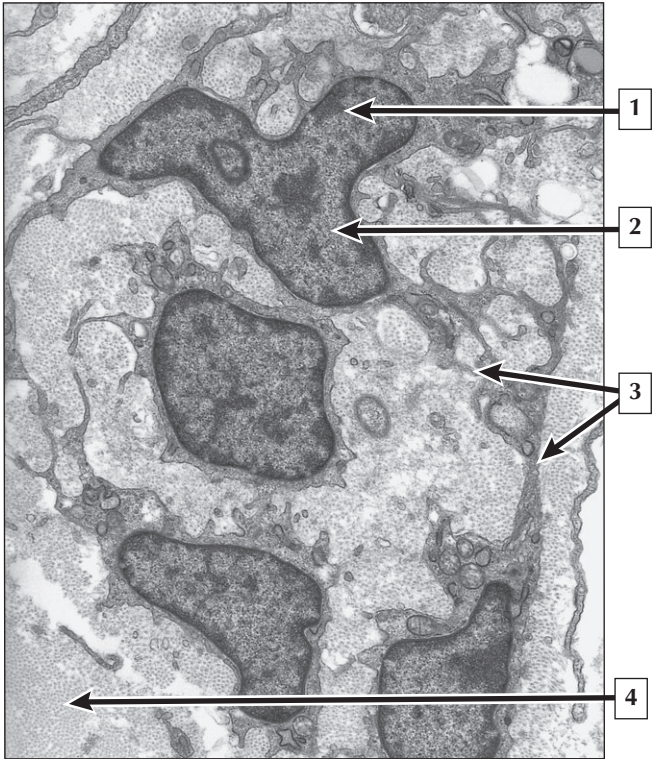
---

1. Collagen bundle
2. Nucleus of fibroblast
3. Capillary
4. Tendon (dense regular connective tissue)

**Comment:** Connective tissue is the most versatile of the basic tissues and consists of connective tissue proper and specialized forms such as bone, cartilage, and blood. Connective tissue proper includes a range of recognizable histologic types and can be classified as loose or dense connective tissue. Dense connective tissue may have a regular arrangement, as in tendon, or an irregular arrangement, as in the dermis of skin. The main function of the collagen fibers is to impart tensile strength to the tissue.

**Tendinopathies** are commonly associated with **rheumatoid arthritis**. Tendons can become inflamed, weakened, and “click,” or even rupture.

*Schematic and LM of a tendon sectioned in the longitudinal plane*



## Fibroblasts

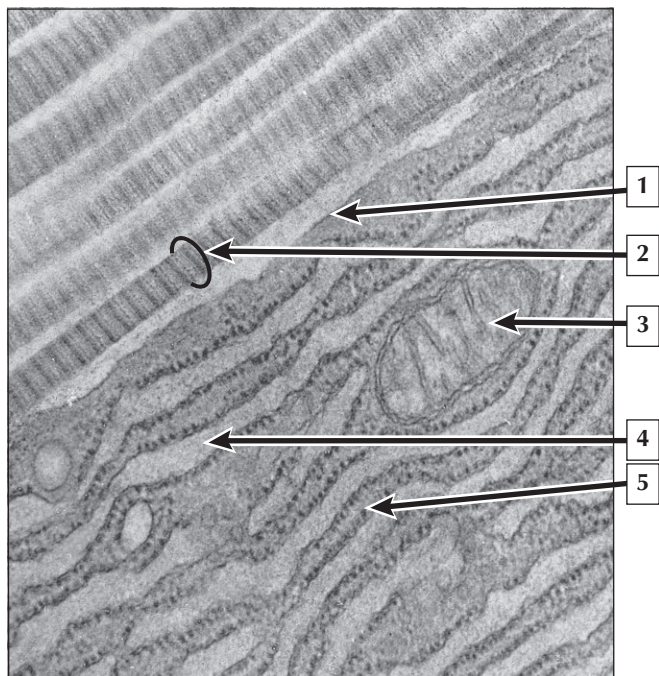
---

1. Heterochromatin (of fibroblast)
2. Euchromatin (of fibroblast)
3. Cell processes (of fibroblasts)
4. Collagen

**Comment:** Fibroblasts are the principal cell type of connective tissue. They are responsible for the synthesis and secretion of the ground substance and the connective tissue fibers in the extracellular matrix (ECM) including collagen, elastic, or reticular fibers. In mature connective tissue, these cells are relatively inactive and immobile, where they are often known as fibrocytes. Following injury and during wound repair, they rapidly proliferate and become active fibroblasts to synthesize new extracellular fibers and ground substance. Fibroblasts are the most common cell of loose (areolar) and virtually the only cell of dense regular connective tissue such as tendon.

**Inherited collagen disorders** such as **Ehlers-Danlos syndrome** involve a defect in the synthesis or assembly of collagen fibrils leading to inadequate strength and hyperextensible skin and hypermovable joints.

*EM section of a growing tendon during the adolescent growth spurt*





# Collagen

---

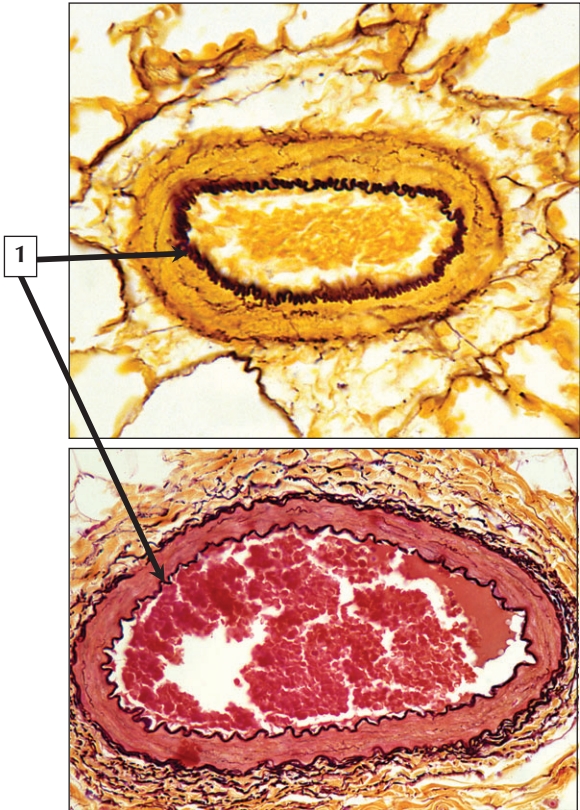
1. Plasma membrane of fibroblast
2. Collagen fibril
3. Mitochondrion
4. Cisterna of rough endoplasmic reticulum (RER)
5. Ribosome

**Comment:** At 30% to 35% of the body's dry weight, collagen is the most abundant, ubiquitous structural protein. At least 20 genetically distinct types of collagen exist that differ mainly in amino acid composition. Type I collagen, the most common type, and found in dermis, exhibits a distinct axial periodicity when its fibrils are sectioned in the longitudinal plane. The repeating dark and light segments every 67 nm along the length of each fibril are due to the staggered arrangement of their constituent tropocollagen molecules. The cytoplasm of the adjacent fibroblast contains multiple and closely packed RER cisternae.

**Dietary deficiency** of vitamin C (L-ascorbic acid) leads to **scurvy**, a condition of impaired collagen synthesis. Typical manifestations occur in dentin of teeth, osteoid of bone, connective tissues, and the tunica adventitia of blood vessel walls. Vitamin C is an essential cofactor for hydroxylation of proline to hydroxyproline. Nonhydroxylated collagen fibrils are unstable, fail to form a triple helix, and have low tensile strength.

*EM of collagen fibrils beside a fibroblast*

## Elastic Connective Tissue



2 In these special stains, the dark staining structures consist predominantly of \_\_\_\_\_ and \_\_\_\_\_.

# Elastic Connective Tissue

---

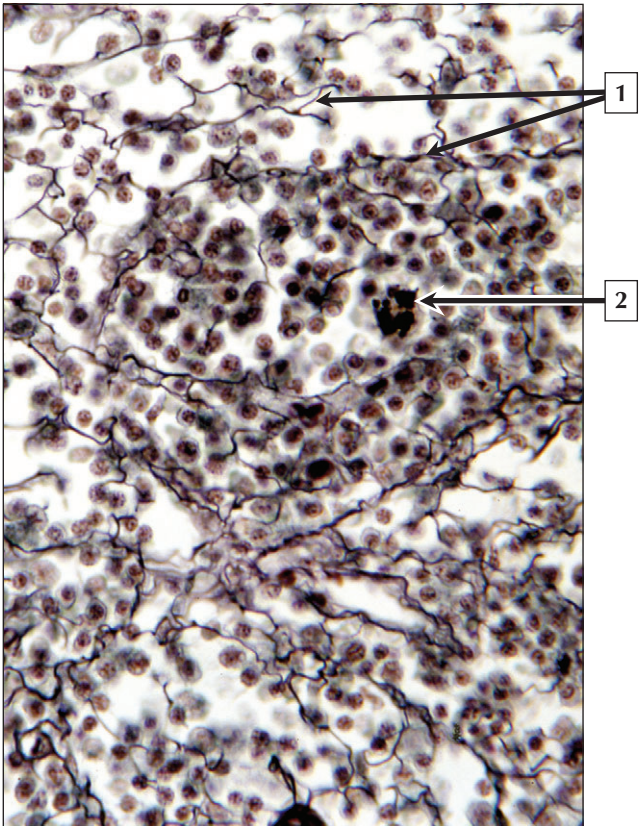
1. Internal elastic lamina (of arteriole)
2. Microfibrils and elastin

**Comment:** Elastic fibers contain bundles of microfibrils that function as a scaffold during development and consist of the glycoprotein, fibrillin. Elastin, an amorphous component, is added to the microfibrils and forms the major part of the elastic fiber. Organs containing elastic fibers (e.g., lung, skin, blood vessels, urinary bladder) can undergo considerable expansion and return passively to their original shape. In walls of arteries and arterioles, they form concentric laminae or sheets. In these sites, smooth muscle cells produce the elastic fibers, although in other areas they are produced by fibroblasts. Elastic fibers cannot be distinguished with conventional methods and require special stains.

**Marfan syndrome** is an inherited connective tissue disorder resulting from molecular defects in the FBN-1 gene that encodes the glycoprotein, fibrillin-1. This disease is marked by impairment of elastic tissues throughout the body including the aorta, where aneurysms can occur and potentially cause sudden death if they tear or rupture.

*Gomori aldehyde fuchsin stain of an arteriole in lung tissue and Van Gieson stain of an arteriole (elastic fibers are darkly stained)*

# Reticular Connective Tissue



# Reticular Connective Tissue

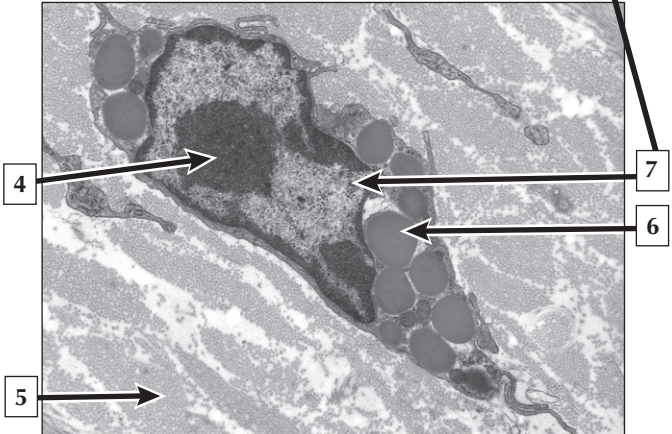
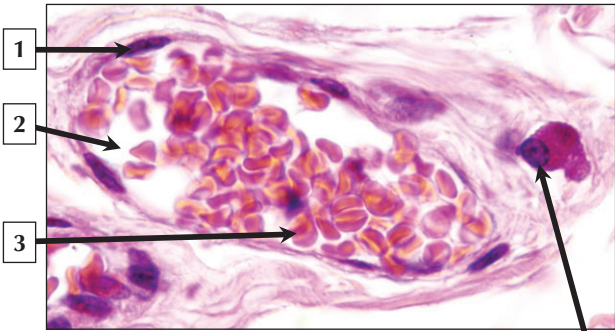
---

1. Reticular fibers
2. Macrophage

**Comment:** Reticular connective tissue, a specialized loose connective tissue, consists of reticular fibers that form the supportive stroma of many tissues and organs. They are long, thin, extracellular fibers, measuring 100 to 150 nm in diameter. They do not form bundles like collagen fibers but appear as a felt-like aggregation of branching fibers. Once believed to possess a different composition from collagen, they are now known to be thin type III collagen fibers. Like elastic fibers, reticular fibers stain poorly with conventional methods and require special light microscopic stains. Their selective staining with metallic silver visualized by light microscopy is most likely due to precipitation of reducible silver salts on an external coating of bound proteoglycans.

**Reticular fibers** are first to be synthesized by fibroblasts during **wound healing** in connective tissue and are later replaced by type I collagen fibers.

*LM section of the medulla of a lymph node stained with modified Bielschowsky ammoniacal silver stain*



## Mast Cells

---

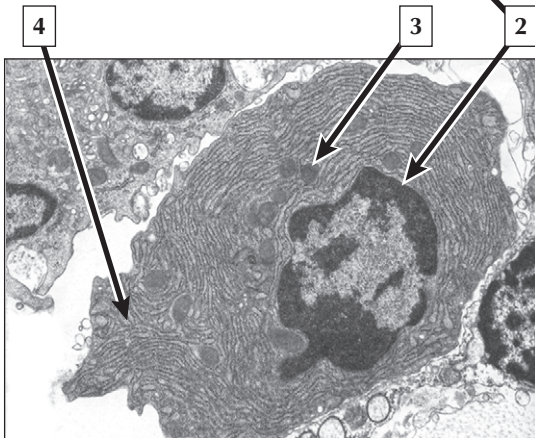
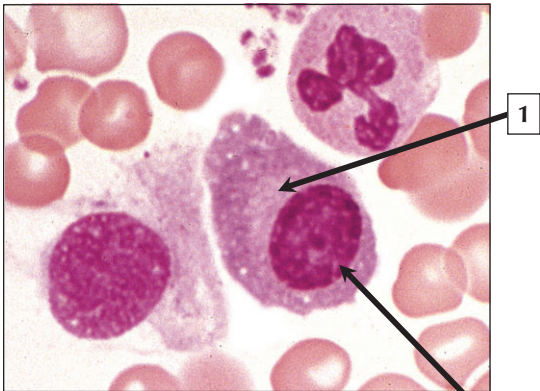
1. Nucleus of endothelial cell
2. Lumen of venule
3. Erythrocyte
4. Nucleolus
5. Collagen
6. Granule
7. Mast cell nucleus

**Comment:** Mast cells are normal elements of the connective tissues and lamina propria of mucous membranes, where they trigger or maintain inflammatory and immune responses. They are found at sites of inflammation and neoplastic foci and play a central role in immediate allergic reactions. Mast cells are able to release potent inflammatory mediators such as histamine, heparin, chemotaxic factors, cytokines, and metabolites of arachidonic acid that act on the vasculature, smooth muscle, connective tissue, mucous glands, and inflammatory cells. Histamine is a vasodilator and proteolytic enzyme that can destroy tissue or cleave complement components. Heparin is an anticoagulant. Chemotaxic factors are important regulators of eosinophil and neutrophil function.

**Anaphylaxis** is a life-threatening allergic reaction. It occurs when IgE antibodies bind with allergens and cause mast cells to release histamine and other molecules stored in these cells.

*LM and EM of mast cells in connective tissue*

## Plasma Cells



5 What is the major function of this cell?



## Plasma Cells

---

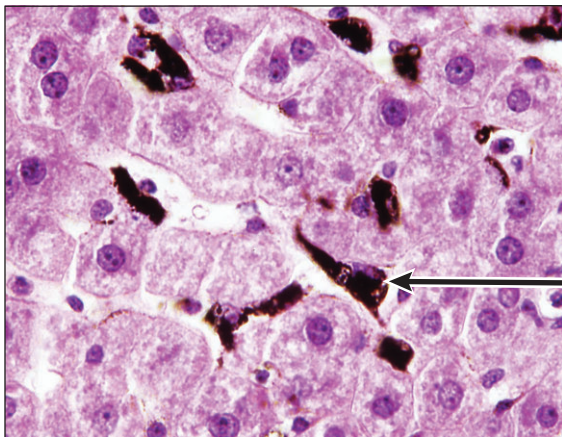
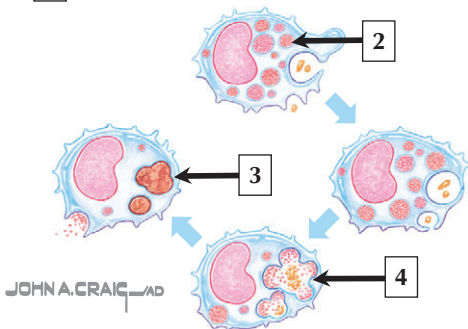
1. Juxtannuclear halo (Golgi complex)
2. Plasma cell nucleus
3. Mitochondrion
4. Rough endoplasmic reticulum (RER)
5. Production of antibodies

**Comment:** Plasma cells are mature B-lymphocytes that are specialized for antibody (immunoglobulin) production. Their relatively large cytoplasm appears basophilic due to the high content of RER. Plasma cells are free cells of the connective tissues, able to move slowly through them. Most are distributed widely in the connective tissues throughout the body, especially in the lamina propria of the gastrointestinal tract and in lymphatic organs. They are occasionally found in the peripheral blood and also normally comprise 0.2% to 2.8% of the bone marrow leukocyte count. Mature plasma cells are typically oval shaped, measuring 10 to 20  $\mu\text{m}$  in diameter.

**Multiple myeloma** is a disorder that exhibits abnormal plasma cells, known as myeloma cells, which accumulate in the bone marrow and form multiple tumors, mostly within bones.

*LM of a blood smear and EM of plasma cell in connective tissue*

1 Name the cellular process illustrated below.



*Rat liver 1 hr after exposure to india ink*

# Macrophages

---

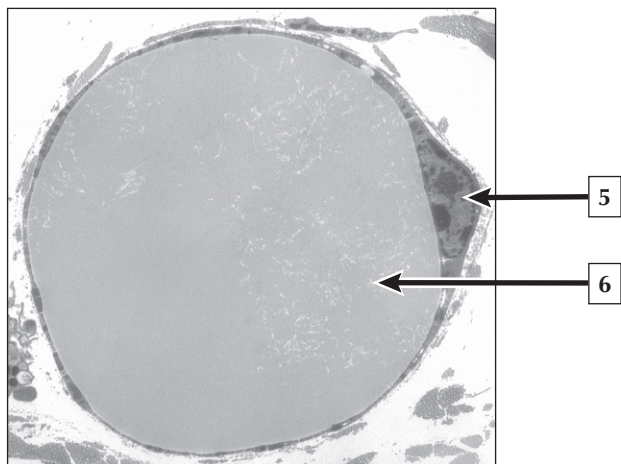
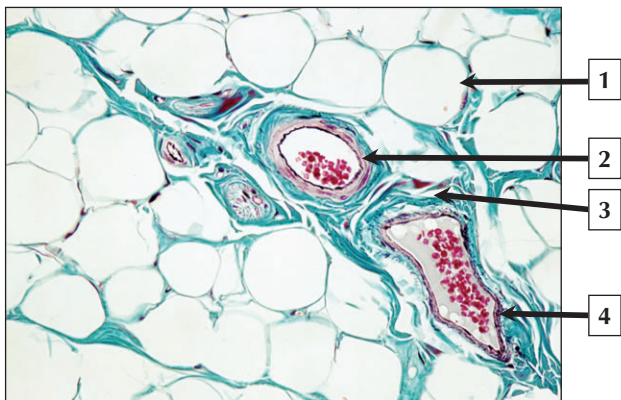
1. Phagocytosis
2. Primary lysosome
3. Tertiary (residual) lysosome
4. Secondary lysosome
5. Kupffer cell of liver

**Comment:** After fibroblasts, macrophages (or histiocytes) are the most numerous cell type in loose connective tissue. Macrophages are a family of phagocytic cells that may be fixed cells attached to connective tissue fibers of the matrix or wandering cells that are motile and migratory. Macrophages are named Kupffer cells in the liver, alveolar dust cells in lung, microglia in brain, Langerhans cells in epidermis, dendritic cells in lymphatic tissue, and osteoclasts in bone. Phagocytosis involves engulfment of a particle (e.g., micro-organism) and fusion of primary lysosomes with a phagocytic vacuole, which extrudes enzymes into the resulting digestive vacuole.

**Whipple's disease**, a rare disorder, is characterized by the accumulation of foamy periodic acid-Schiff (PAS)-positive macrophages in the lamina propria. Symptoms of this disease involve malabsorption in the intestine, weight loss, and a wide variety of other manifestations in the body. It is thought to be caused by the gram-positive bacterium, *Tropheryma Whippelii*.

*Schematic of phagocytosis and antigen processing by a macrophage with LM of rat liver showing macrophages that have ingested India ink*

## Adipose Tissue



## Adipose Tissue

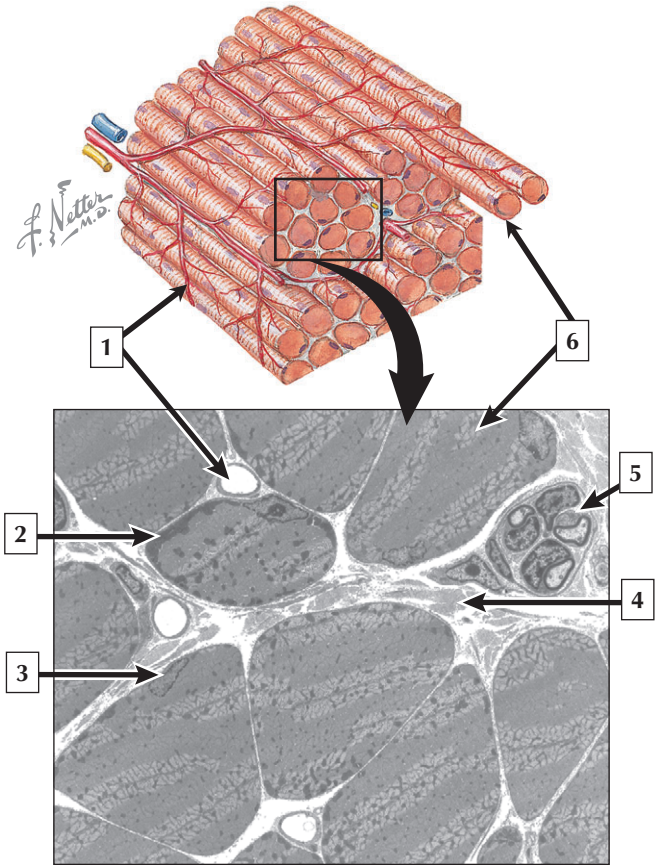
---

1. Adipocyte
2. Arteriole
3. Connective tissue
4. Venule
5. Nucleus of adipocyte
6. Lipid droplet

**Comment:** Adipose tissue is a specialized loose connective tissue that contains large numbers of adipocytes. Adipocytes are specialized for the synthesis, storage, and mobilization of neutral fats known as triglycerides. Lipoprotein lipase, an enzyme produced by the adipocyte, releases fatty acids and monoglycerides from chylomicrons and very low density lipoproteins (VLDLs) that are then transported into the adipocyte cytoplasm. Re-esterification into triglycerides occurs in the smooth endoplasmic reticulum of the adipocyte, followed by their storage in the lipid droplet. Hormones, such as insulin, and the sympathetic nervous system, which innervates adipose tissue, control these activities.

**Obesity** is an increase in adipose tissue beyond the normal requirements of the body. It has a multifactorial etiology, and there is a global epidemic of this condition. Excess calories are stored as triglycerides in adipocytes.

*LM of adipose tissue and EM of an adipocyte*



# Skeletal Muscle

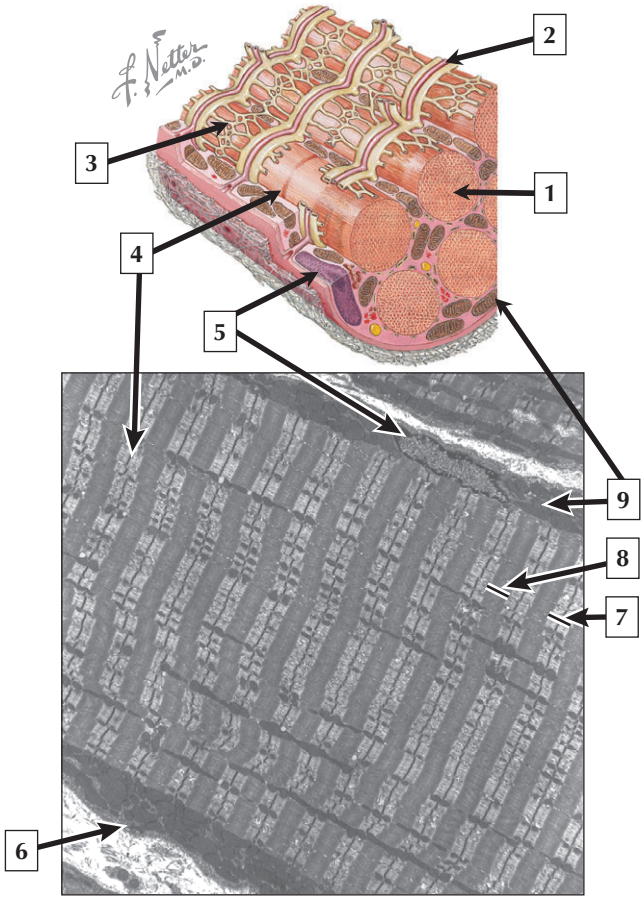
---

1. Capillary
2. Mitochondria
3. Nucleus
4. Perimysium (collagen)
5. Nerve fascicle
6. Skeletal muscle fiber

**Comment:** Muscle tissue is classified into one of three major categories according to structure, function, and location. Skeletal muscle is the most common and characteristic type; the other two types are cardiac muscle and smooth muscle. Skeletal muscles contain elongated cylindrical-shaped muscle fibers that have multiple, peripherally located subsarcolemmal nuclei and a sarcoplasm filled with contractile filaments. Varying amounts of mitochondria are present depending on fiber type. Slow fibers are smaller in diameter and contain more mitochondria than fast fibers. Capillaries and nerves course between muscle fibers in the perimysium.

**Myotonic dystrophy** is the most common form of adult muscular dystrophy, commonly occurring in early adulthood. It is a rare hereditary disorder characterized by progressive weakness and wasting of skeletal muscle and delayed relaxation after contraction (myotonia). A defect in a regulatory protein kinase is implicated in one form of myotonic dystrophy.

*Schematic and EM of skeletal muscle in transverse section*





## Skeletal Muscle

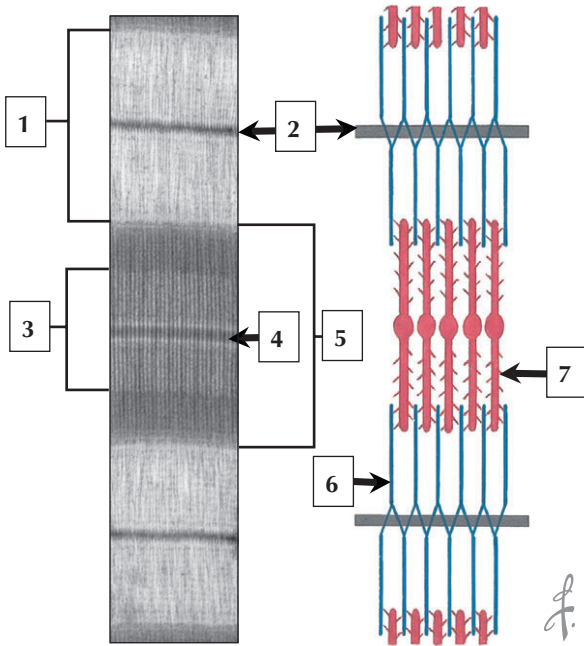
---

1. Myofibril
2. T-tubule
3. Sarcoplasmic reticulum
4. Z band
5. Nucleus
6. Sarcolemma
7. I band
8. A band
9. Mitochondria

**Comment:** When viewed in the longitudinal plane, skeletal muscle fibers show an alternating series of transverse bands or striations. Striations are due to adjacent myofibrils in lateral register with each other across the width of the fiber. The cylindrical myofibrils are surrounded by a membranous network, collectively termed the sarcotubular system that is involved in excitation-contraction coupling. Transverse tubules are sarcolemmal invaginations that allow membrane depolarizations to travel deep into the muscle fiber and stimulate calcium release from the sarcoplasmic reticulum.

**Duchenne muscular dystrophy** is an X-linked genetic disorder caused by a deficiency of dystrophin, a large sarcolemmal-associated cytoskeletal protein. Dystrophin is required to maintain mechanical integrity of the cell during contraction by anchoring elements of the cytoskeleton. Young boys are mainly affected, and myodegeneration progresses with age.

*Schematic and longitudinal EM view of a skeletal muscle fiber*



*F. Netter M.D.*

# Sarcomere

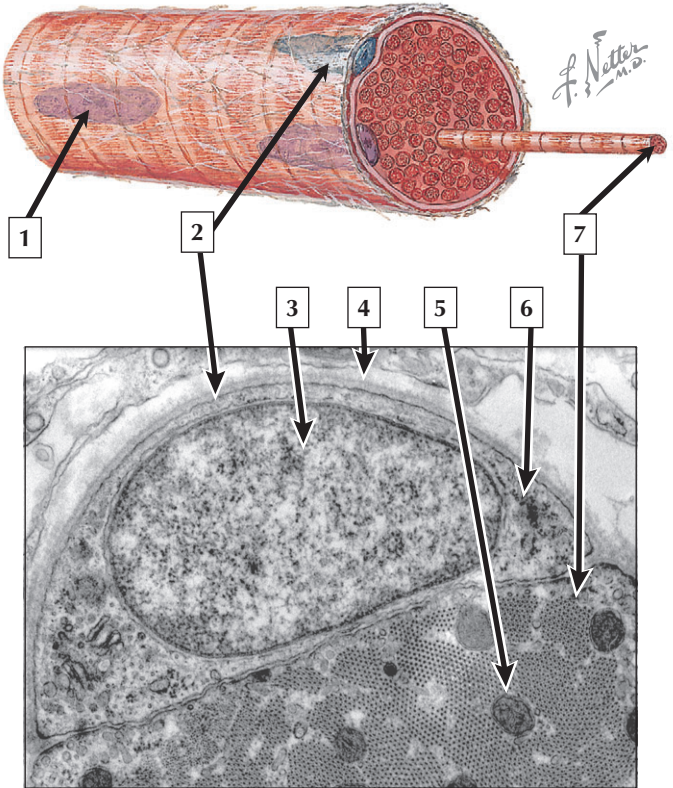
---

1. I band
2. Z band
3. H zone
4. M band
5. A band
6. Thin filament
7. Thick filament

**Comment:** The repeating unit of striated muscle is called the sarcomere and is delimited by successive Z bands. The banded appearance of striated muscle arises from highly oriented sets of overlapping myosin-containing thick filaments (A band) and actin-containing thin filaments (I band). Z bands are the sites where oppositely oriented thin filaments are anchored. During contraction, myosin heads located on the thick filament bind to actin in the thin filament and pull the sets of filaments past one another. The distance from Z band to Z band shortens as well as the widths of the I bands and H zone. The A band remains a constant width.

**Nemaline myopathy** is a rare inherited congenital disorder that causes muscle weakness in the face, neck, upper limbs, and respiratory muscles. Atypical fiber inclusions called **nemaline** (or rod) **bodies** consisting of Z band material typify this disorder. Mutations in the genes encoding thin filament proteins are associated with this disease.

*EM of a relaxed sarcomere in longitudinal section and schematic of myofilament arrangement in a sarcomere*



## Satellite Cells

---

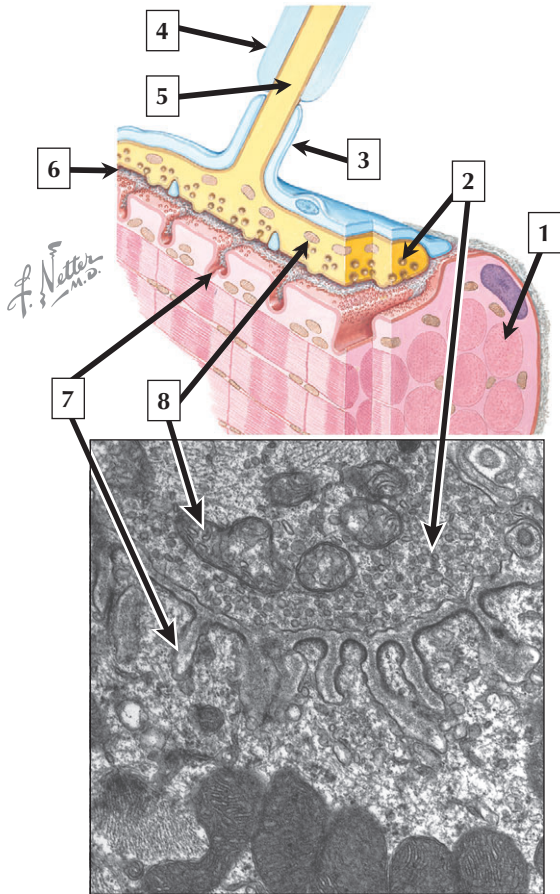
1. Nucleus of skeletal muscle fiber
2. Satellite cell
3. Euchromatin
4. External lamina
5. Mitochondrion
6. Ribosomes
7. Myofibril

**Comment:** Satellite cells are small, flattened, mononucleated cells located between the sarcolemma of a skeletal muscle fiber and the external lamina. Their euchromatic nucleus is typical of active, protein-synthesizing cells. The cytoplasm of the satellite cell contains scattered free ribosomes and a few profiles of rough and smooth-surfaced endoplasmic reticulum. A narrow gap separates it from the muscle fiber where the plasma membranes of the 2 cells are parallel to each other, making them identifiable by electron microscopy or by immunocytochemical staining and molecular markers. The underlying muscle fiber contains tightly packed myofibrils and a few mitochondria. Both the satellite cell and the muscle fiber share the same external lamina.

**Muscle injury** stimulates the activation of satellite cells and leads to several rounds of proliferation, followed by differentiation and fusion either to form new muscle fibers or to repair damaged ones.

*Schematic of a skeletal muscle fiber and EM of a satellite cell in fetal skeletal muscle*

# Neuromuscular Junction



# Neuromuscular Junction

---

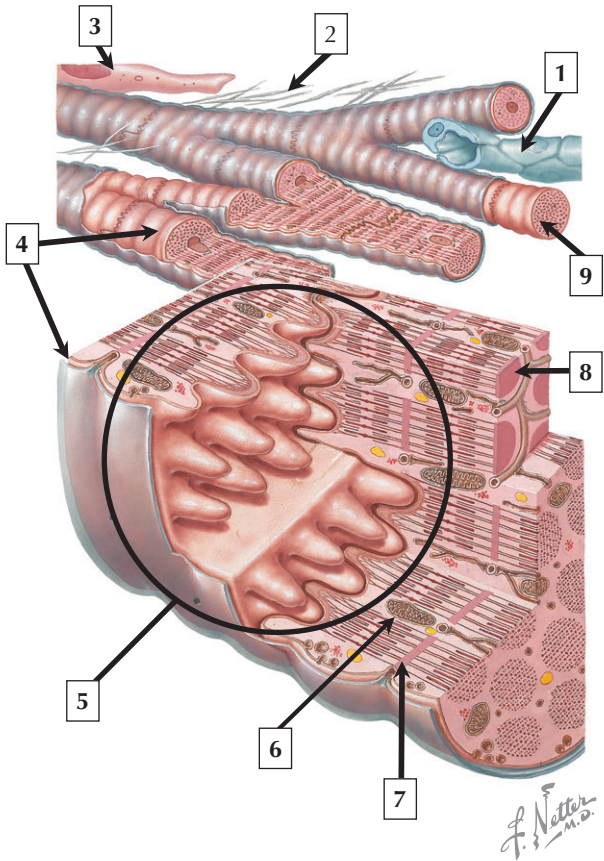
1. Myofibril
2. Synaptic vesicles
3. Schwann cell
4. Myelin sheath
5. Axoplasm
6. Synaptic cleft
7. Postsynaptic membrane (junctional fold)
8. Mitochondrion in presynaptic nerve terminal

**Comment:** The neuromuscular junction (motor endplate) in skeletal muscle has five principal components: Schwann cell, presynaptic nerve (axon) terminal, synaptic cleft, postsynaptic membrane, and postjunctional sarcoplasm. The Schwann cell covers the presynaptic nerve terminal, which is filled with vesicles containing acetylcholine. The synaptic cleft contains a basement membrane that plays a role in development and regeneration of the neuromuscular junction. The postsynaptic membrane has numerous infoldings of the sarcolemma with a high concentration of acetylcholine receptors on their surface. The postjunctional sarcoplasm is critical for structural and metabolic support of the junction.

**Myasthenia gravis**, the most common hereditary disorder of neuromuscular transmission, is typified by a reduction in the concentration of acetylcholine receptors on the postsynaptic membrane due to an autoimmune response.

*Schematic and EM of the neuromuscular junction in skeletal muscle*

# Cardiac Muscle





# Cardiac Muscle

---

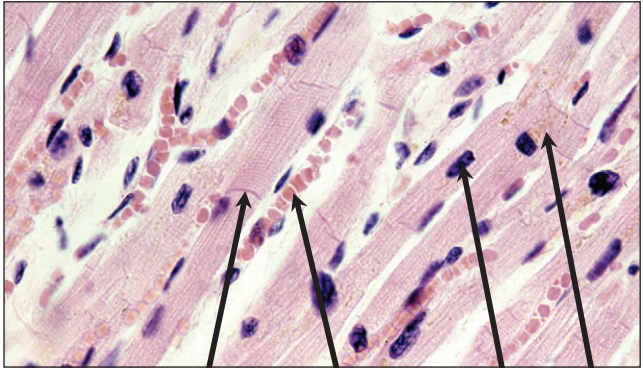
1. Capillary (endothelial cell)
2. Collagen
3. Fibroblast
4. Sarcolemma
5. Intercalated disc
6. Mitochondrion
7. Z band
8. Myofibril
9. Cardiac muscle cell

**Comment:** Cardiac muscle is striated, involuntary muscle in the myocardium of the heart wall. Cardiac muscle cells (also known as myocardial cells or cardiomyocytes) contain the same basic organization of myofibrils, myofilaments, and cross-striations as in skeletal muscle. Unlike skeletal muscle, cardiac muscle cells are smaller and contain a single centrally placed nucleus, although they may sometimes be binucleated. Cells are joined together by specialized junctions called intercalated discs.

**Hypertrophic cardiomyopathy** is a primary disorder of the myocardium, often resulting in sudden cardiac death. It is most often a familial disorder (55%), with an autosomal dominant transmission. Abnormal growth and hypertrophy of cardiac muscle cells results in ventricular wall thickening, and the myocardial cells are disarrayed instead of displaying a normal arrangement.

*Schematic showing the basic organization of cardiac muscle*

# Cardiac Muscle




1

2

3

4



5

6

7

# Cardiac Muscle

---

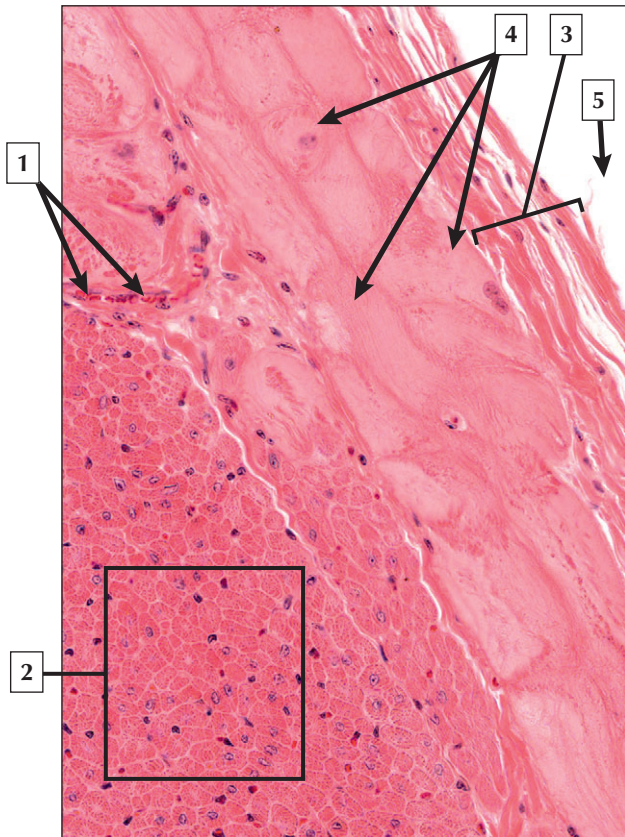
1. Intercalated disc
2. Erythrocyte in capillary
3. Nucleus of cardiac muscle cell
4. Lipofuscin
5. A band
6. Z band
7. Mitochondrion

**Comment:** The size of cardiac muscle cells is intermediate to that of the cells of skeletal muscle and smooth muscle. Their cytoplasm is eosinophilic in H&E stained sections due to the high content of contractile proteins. The interstitium contains numerous capillaries filled with erythrocytes. Intercalated discs mechanically and electrically link the cells, allowing them to function in a coordinated fashion. The disc is an aggregate of three junctional specializations: desmosomes, fascia adherens, and gap junctions.

In familial **dilated cardiomyopathy (DCM)**, a heritable form of heart failure, mutations exist mostly in cytoskeletal proteins that disrupt intercalated disc morphology by dissociating junctions between myocardial cells and disrupting myofibrillar organization and contractile function. Weakened junctions lead to overstretching and thinning of the ventricular wall.

*LM and EM of cardiac muscle sectioned longitudinally*

# Cardiac Conduction System



# Cardiac Conduction System

---

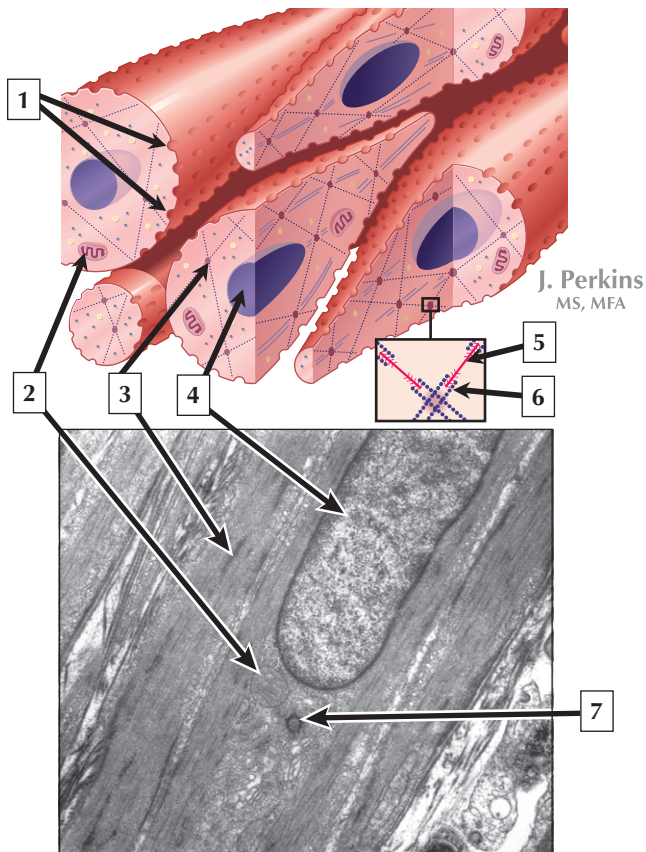
1. Blood vessel (capillary)
2. Myocardium (cardiac muscle fibers)
3. Endocardium
4. Purkinje fibers
5. Ventricular lumen (cardiac chamber)

**Comment: Purkinje fibers**, which are modified cardiac muscle cells, are scattered along the innermost part of the myocardium adjacent to the endocardium. They are found especially in the interventricular septum, organized into discrete bundles and embedded in connective tissue. They are part of the cardiac conduction system, which includes fibers specialized for conduction of electrical impulses. Purkinje fibers are larger and thicker than ordinary cardiac muscle cells and have scattered myofibrils around the cell periphery. Their glycogen content is greater than that in ordinary cardiac muscle cells. Purkinje fibers thus appear pale and washed-out in routine H&E.

**Ventricular tachycardia** (faster than normal heart rhythm originating in one of the ventricles) is a cardiac conduction disturbance that may lead to more severe **ventricular fibrillation** (abnormal disorganized heart rhythm). Many *ventricular arrhythmias* are initiated by Purkinje fibers via enhanced *automaticity* because of their unique propagation properties and anatomic distribution.

*LM of Purkinje fibers in the subendocardium of ventricle.*

# Smooth Muscle



## Smooth Muscle

---

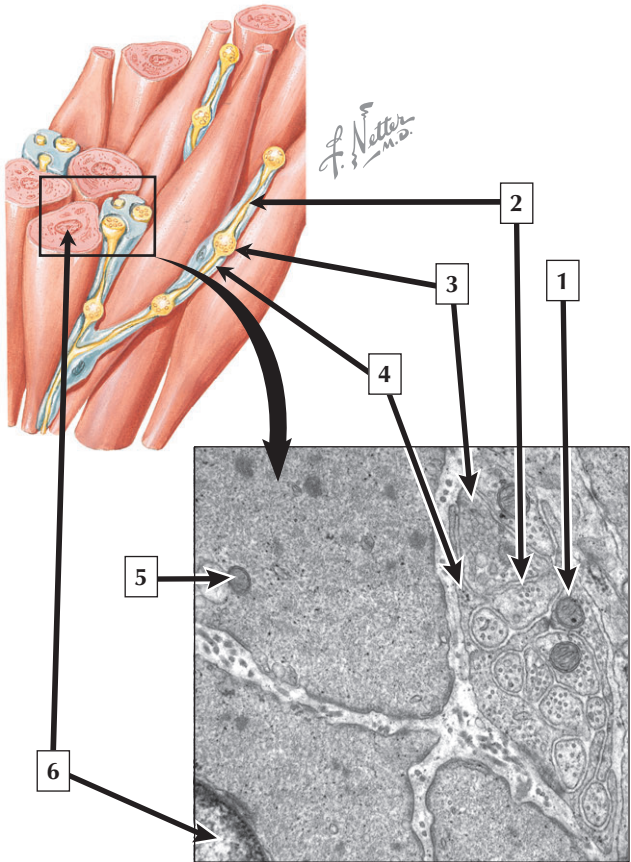
1. Caveolae
2. Mitochondrion
3. Dense body
4. Nucleus
5. Myosin (thick filament)
6. Actin (thin filament)
7. Centriole

**Comment:** Smooth muscle has a much slower and more variable speed of contraction, which can be sustained for long periods. It lacks visible striations but can produce contractile force comparable to that of skeletal muscle. Myosin- and actin-containing filaments predominate in the sarcoplasm along with a network of intermediate filaments including desmin or vimentin. Dense bodies are unique to smooth muscle and are found throughout the cytoplasm or attached to the undersurface of the sarcolemma where they link thin and intermediate filaments to the cell membrane. The attachment of thin filaments to dense bodies and their content of the protein, alpha-actinin, is reminiscent of that found at Z bands of skeletal muscle.

**Asthma and hypertension** are commonly due to redundant contraction of bronchial and vascular smooth muscle, respectively. Smooth muscle cells surrounding these passages can undergo hyperplasia and/or hypertrophy that contribute to the lumen obstruction.

*Schematic and longitudinal EM of smooth muscle*

# Smooth Muscle





## Smooth Muscle

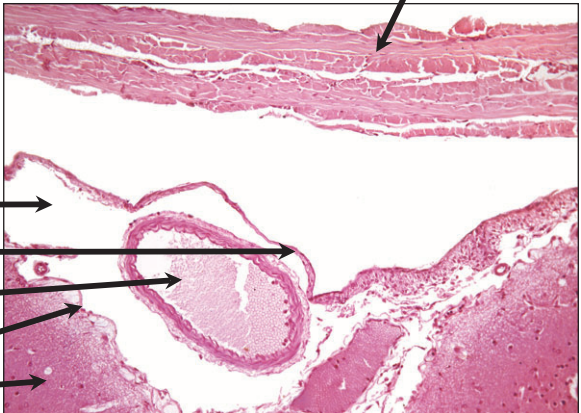
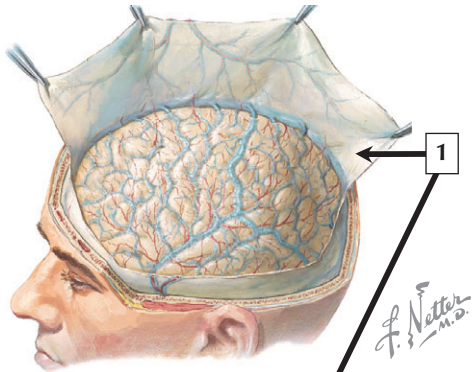
---

1. Mitochondrion of Schwann cell
2. Unmyelinated axon
3. Axonal varicosity
4. Schwann cell
5. Mitochondrion of smooth muscle cell
6. Nucleus of smooth muscle cell

**Comment:** Most smooth muscle activity is regulated by the autonomic (involuntary) nervous system. Axonal varicosities are focal sites that contain vesicles filled with neurotransmitters such as acetylcholine and norepinephrine, or a variety of other neurotransmitters. Gap junctions between smooth muscle cells allow excitation to spread between adjacent cells, resulting in synchronous contractions. Extrinsic factors such as circulating hormones can also stimulate contraction (e.g., oxytocin in the uterus during parturition). Moreover, local substances such as histamine and serotonin or physical factors like stretch can influence smooth muscle activity.

**Vasoconstriction** of vascular smooth muscle is stimulated by norepinephrine binding to adrenergic receptors on the surface of the smooth muscle cells. **Alpha blockers** are used to inhibit binding of norepinephrine to its receptor and act to decrease smooth muscle tone and increase vessel diameter.

*Schematic of the innervation pattern of smooth muscle and EM of smooth muscle cells in close proximity to nerve axons*



# Meninges

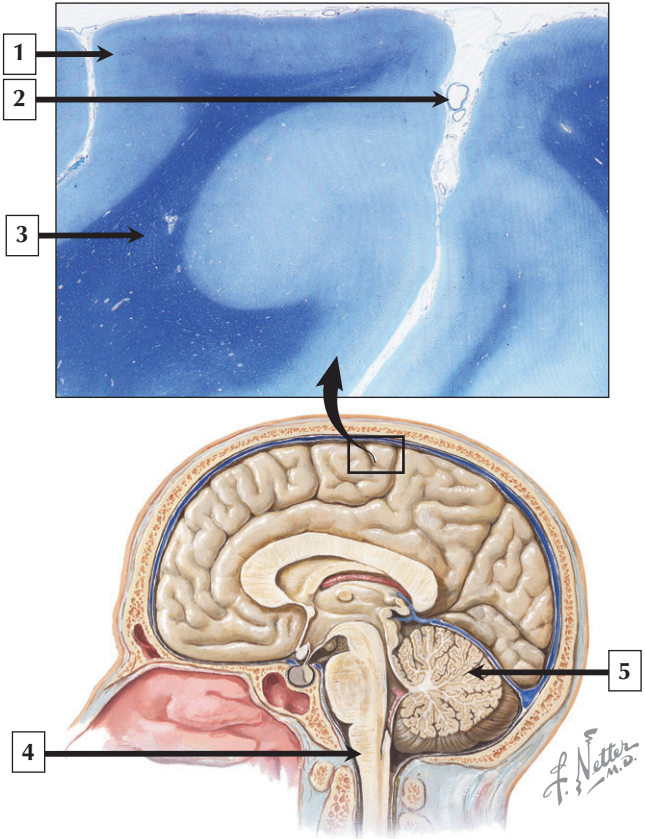
---

1. Dura mater
2. Subarachnoid space
3. Arachnoid mater
4. Lumen of cerebral artery
5. Pia mater
6. Nervous tissue

**Comment:** The dura mater invests the brain, spinal cord, and optic nerves. It is a dense, fibrous, connective tissue consisting of interlacing bundles of collagen and elastic fibers in association with flattened fibroblasts. The arachnoid and pia mater are thinner and more delicate than the dura, and, together, are known as the leptomeninges. The subarachnoid space is filled with cerebrospinal fluid and also contains branches of cerebral arteries and veins.

**Meningitis** is an inflammation of the meninges. Most frequently caused by bacteria or viruses, it may also be due to other pathogens, such as fungi or parasites. Bacterial meningitis is less common than the viral form, and can be life threatening. Bacterial meningitis is characterized by exudates of polymorphonuclear leukocytes in the central nervous system (CNS), whereas viral hepatitis is marked mostly by an infiltration of lymphocytes in the brain and elevated numbers of T cells in the cerebrospinal fluid (CSF).

*Schematic of dura mater reflected back and LM of meninges covering the monkey brain*



# Cerebrum

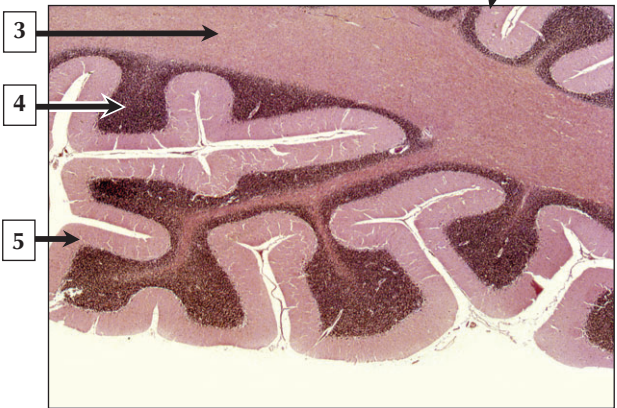
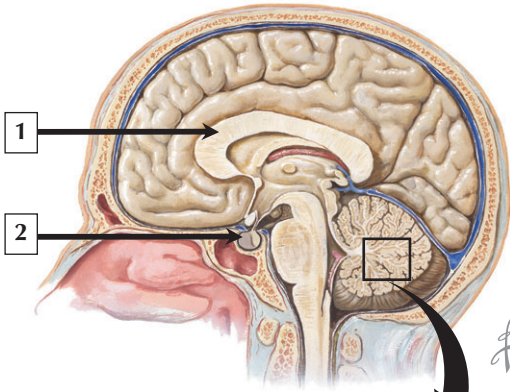
---

1. Gray matter
2. Blood vessel
3. White matter
4. Medulla oblongata
5. Cerebellum

**Comment:** The cerebrum consists of two hemispheres with an outer cortex of gray matter and a central region of white matter. The cerebral cortex is 1.5 to 4.5 mm thick. Gray matter consists mostly of nerve cell bodies, unmyelinated neuronal processes, and glial cells, whereas white matter consists of tracts of myelinated nerve fibers and associated glia. The CNS contains a rich vascular supply consisting of a profuse network of capillaries, which are typically more abundant in the gray matter. In the spinal cord, gray matter is localized internally and enveloped by an external layer of white matter.

**Damage to myelin** is a common feature of neurologic diseases, leading to blocked axonal conduction, secondary damage to axons, and possible permanent neurologic deficits. **Multiple sclerosis** is a demyelinating disease that is caused by an autoimmune reaction to the myelin sheath. Destruction of the sheath leads to slower axonal conduction and inflammatory reactions at sites of degeneration.

*LM of cerebrum (luxol fast blue stain) and schematic of midsagittal section of the head*



# Cerebellum

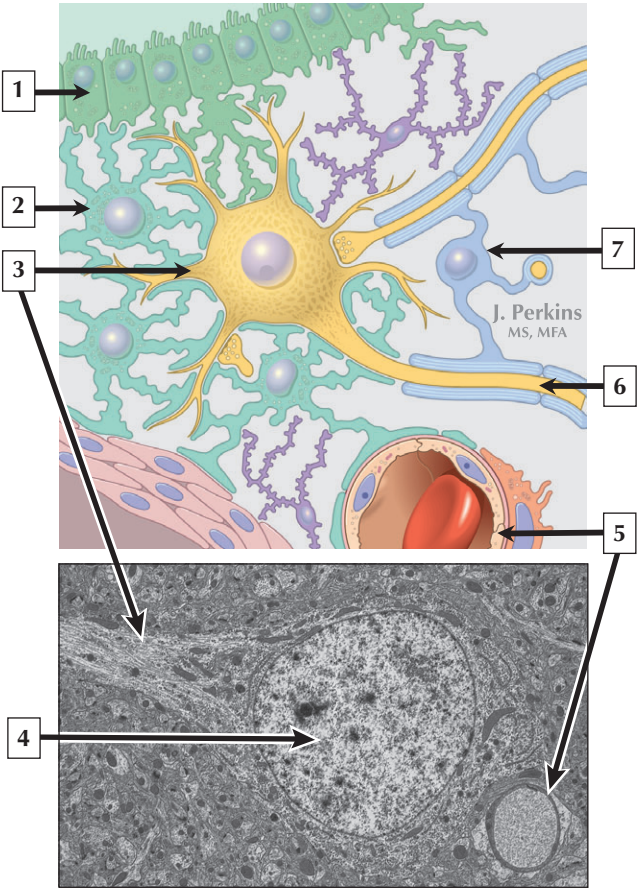
---

1. Corpus callosum
2. Pituitary gland
3. White matter
4. Granular cell layer
5. Molecular layer

**Comment:** The cerebellum is a bilaterally symmetric part of the brain. Its surface is extensively folded and possesses thin, transverse folds known as folia, which resemble the leaves of a tree. It consists of a surface layer of cortex of gray matter and a medullary center of white matter. The outer cortex has a remarkably uniform trilaminar organization and consists of an outer molecular layer, an inner granular layer, and a middlemost monolayer of large, pear-shaped neurons known as Purkinje cells. The molecular layer is a pale-stained zone with relatively few nerve cell bodies. It contains a network of profusely branching dendrites of Purkinje cells and represents mainly a synaptic field.

**Huntington disease** is an autosomal dominant hereditary disease that affects nerve cells and causes atrophy of the caudate nuclei and putamen. Enlargement of the fluid-filled ventricles of the brain is also a common finding in this disease. Clinical symptoms include spasmodic movements, speech difficulties, and psychologic disorders.

*Schematic of midsagittal section of the head and LM of cerebellum*





# Neuron

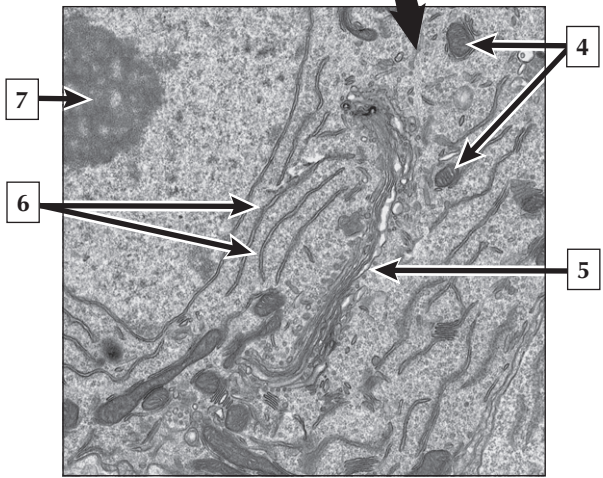
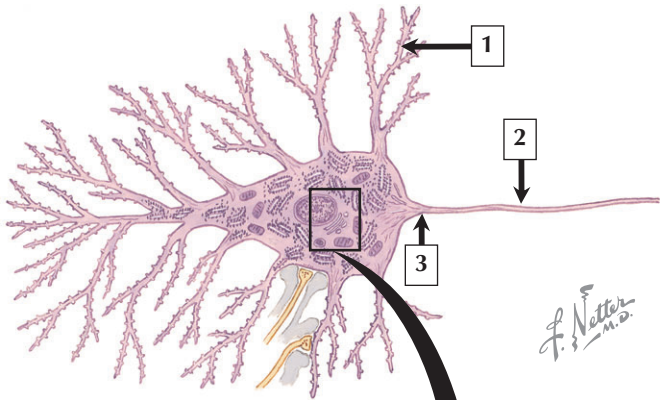
---

1. Ependyma
2. Astrocyte
3. Dendrite of neuron
4. Nucleus euchromatin
5. Endothelium of capillary
6. Axon
7. Oligodendrocyte

**Comment:** The neuronal cell body is the trophic center of the nerve cell and varies considerably in size and shape depending on the type of neuron and its specific location in the CNS. Reflecting its role in genetic regulation and transcription, the nucleus of a typical neuron is euchromatic with small patches of peripherally displaced heterochromatin immediately under the nuclear envelope. The nucleus is usually spherical to ovoid in shape, and its size is large relative to the surrounding perikaryon.

**Senile dementia** of the Alzheimer's type, or **Alzheimer disease**, is characterized by progressive memory loss. The histopathologic hallmark of Alzheimer disease is an increased number of **neuritic**, or "**senile**" **plaques**, occurring mostly in the cerebral cortex. They are composed of tortuous neuritic processes formed mainly by degenerative presynaptic endings, which surround a central amyloid core. Other histologic features include proliferation of intracytoplasmic neurofibrillary tangles.

*Schematic of the main types of cells in the brain and EM of cerebral cortex showing a neuron in the gray matter*



# Neuron

---

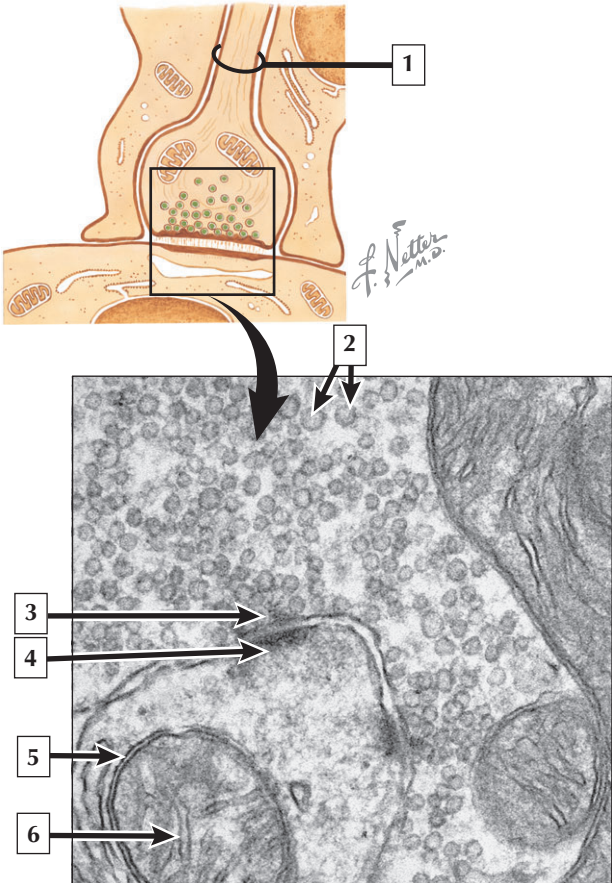
1. Dendrite
2. Axon
3. Axon hillock
4. Mitochondria
5. Golgi complex
6. Rough endoplasmic reticulum
7. Nucleolus

**Comment:** Dominating the cytoplasm of neurons are multiple, flattened cisternae of rough endoplasmic reticulum with numerous free ribosomes between the cisternae. They correspond to the basophilic Nissl substance seen in light micrographs. Their major function is protein synthesis for internal use as well as export. A highly developed Golgi complex with multiple stacks of flattened sacs and associated vesicles and vacuoles are commonly found close to the nucleus. This organelle is responsible for packaging and concentration of secretory products as well as post-translational modification of macromolecules. It is also the source of lysosomes, which accumulate wear-and-tear lipofuscin pigment in these long-lived cells with advancing age.

**Parkinson disease** affects motor neurons in the central nervous system. Primary symptoms involve a decrease in function and activity of dopaminergic neurons in the brain. Although most cases are idiopathic (of unknown origin), others can be caused by toxicity, drugs, trauma, or genetic mutation.

*LM and EM of a neuron cell soma in the cerebral cortex*

## Synapse in the CNS



# Synapse in the CNS

---

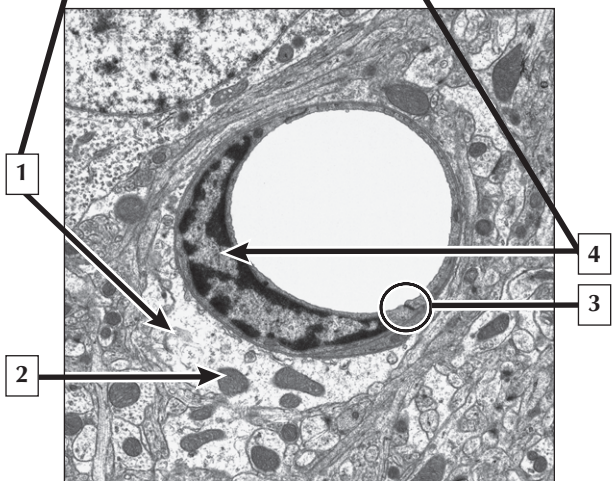
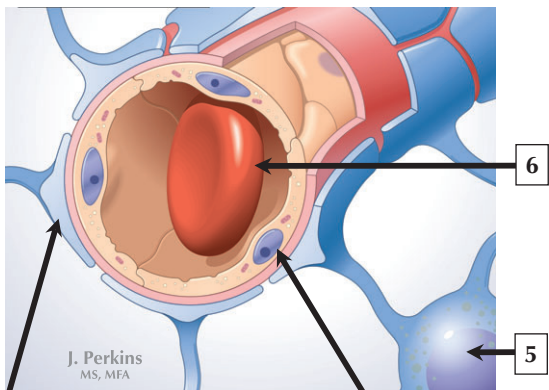
1. Axon
2. Synaptic vesicles
3. Presynaptic terminal
4. Postsynaptic terminal
5. Outer membrane of mitochondrion
6. Crista of mitochondrion

**Comment:** Synapses are specialized sites for chemical or electrical transmission between neurons or between a neuron and another effector cell. In chemical synapses, presynaptic and postsynaptic membrane specializations contain electron-dense material that extends into the underlying cytoplasm and is usually thicker on the postsynaptic side of the synapse. With arrival of the action potential, synaptic vesicles fuse with the presynaptic membrane and discharge their content of neurotransmitter into the synaptic cleft.

Neurotransmitter then diffuses across the cleft to interact with receptor molecules on the postsynaptic membrane, leading to a change in membrane conductance of the postsynaptic membrane.

**Monoamine oxidase inhibitors** are commonly used to treat depression—they act at the level of the synapse to block the enzyme that normally breaks down the monoamine transmitters, norepinephrine, dopamine, or serotonin, thus prolonging the activity of these neurotransmitters in the brain.

*Schematic and high magnification EM of a synapse in the brain*



## Blood-brain Barrier

---

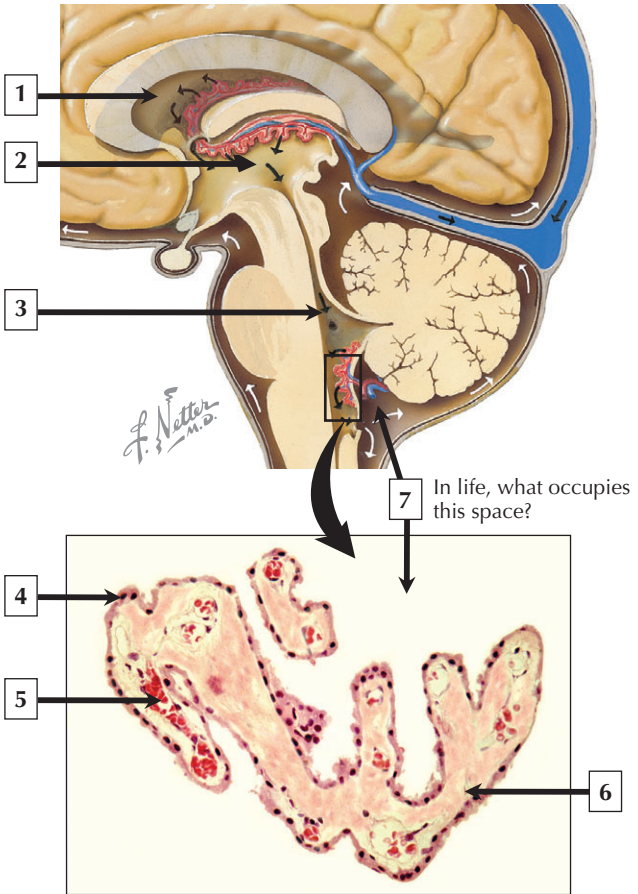
1. Astrocyte foot process
2. Mitochondrion
3. Tight junction between endothelial cells
4. Nucleus (euchromatin) of endothelial cell
5. Nucleus of astrocyte
6. Erythrocyte in lumen of capillary

**Comment:** While the blood-brain barrier restricts the passage of large molecules from the capillary lumen to the surrounding tissue, it allows free passage of gases and selected molecules such as glucose. The barrier protects neurons in the CNS from toxins, drugs, and other potential harmful substances that may enter the bloodstream. Most antibiotics such as penicillin do not cross the barrier in sufficient quantities due to their large molecular weight and low degree of lipid solubility. A few regions of the brain are devoid of a blood-brain barrier and contain capillaries that are highly permeable and of the fenestrated variety. These areas include the pineal gland, posterior pituitary, and parts of the hypothalamus.

**Encephalitis** is an inflammation of the parenchyma of the brain. Acute encephalitis is most commonly a viral infection, whereas a form that leads to abscess formation usually implies a highly destructive bacterial infection of brain tissue.

*Schematic of blood-brain barrier and EM of a capillary in the cerebral cortex*

# Choroid Plexus





## Choroid Plexus

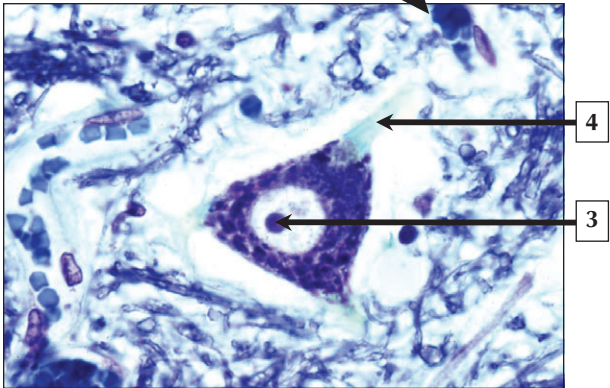
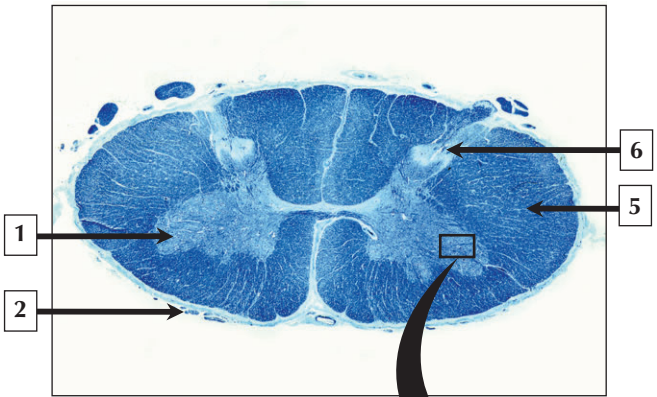
---

1. Lateral ventricle
2. Third ventricle
3. Fourth ventricle
4. Ependyma (modified); simple cuboidal epithelium
5. Capillary (fenestrated)
6. Loose connective tissue
7. Cerebrospinal fluid

**Comment:** The choroid plexus is a specialized tissue in the roof of the third and fourth ventricles and the walls of the lateral ventricles. It produces cerebrospinal fluid (CSF), which circulates within the ventricles, central canal of the spinal cord, and subarachnoid space. The choroid plexus consists of highly branched, leaf-like folds of vascularized pia mater covered by a modified ependyma (simple cuboidal or low columnar), which is a highly secretory and ion-transporting epithelium. It rests on a thin basement membrane. A core of loose connective tissue of the pia contains large, fenestrated capillaries that are highly permeable.

**Ependymomas** are glial tumors arising from ependymal cells within the CNS. They are classified into 1 of 4 subtypes and represent 6% to 9% of primary CNS neoplasms. Intracranial lesions usually occur in children, arising from the roof of the 4th ventricle, whereas spinal cord ependymomas typically occur in adults.

*Hemisection schematic of the CNS and LM of a tuft of the choroid plexus*



## Spinal Cord

---

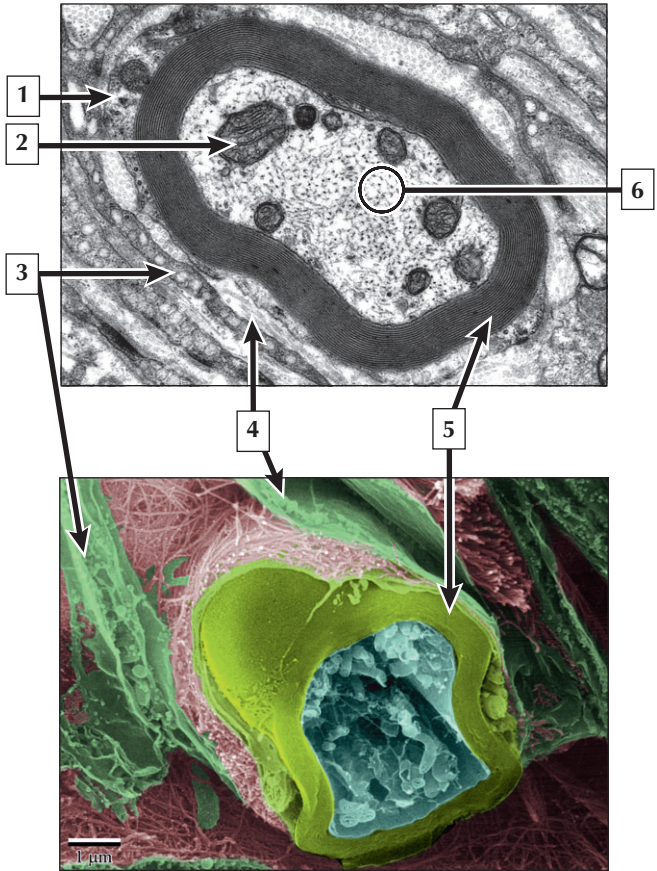
1. Ventral (anterior) horn
2. Pia mater
3. Nucleolus of motor neuron
4. Axon
5. White matter
6. Dorsal (posterior) horn

**Comment:** White matter of the spinal cord consists of ascending and descending tracts of myelinated nerve fibers, whereas the gray matter consists chiefly of cell bodies and unmyelinated nerve fibers. The gray matter has two ventral horns and two dorsal horns connected at the center by an isthmus of gray commissures. The cell bodies of motor neurons are easily identified in the anterior horn due to their relatively large size and Nissl substance within their cytoplasm. Sensory nerve fibers enter the spinal cord via the dorsal horns, and motor nerve fibers exit from the ventral horns as spinal nerves.

**Amyotrophic lateral sclerosis**, also known as **Lou Gehrig disease**, is a progressive neuromuscular disorder caused by a destruction of specific nerve cells in the brain and spinal cord. It belongs to a class of disorders known as **motor neuron diseases** and results in the loss of nervous control of skeletal muscles, leading to degeneration and atrophy of the muscle fibers. Ultimately, the respiratory muscles are affected, leading to death due to an inability to breathe.

*LM of spinal cord at low and high magnification*

# Peripheral Nerve



## Peripheral Nerve

---

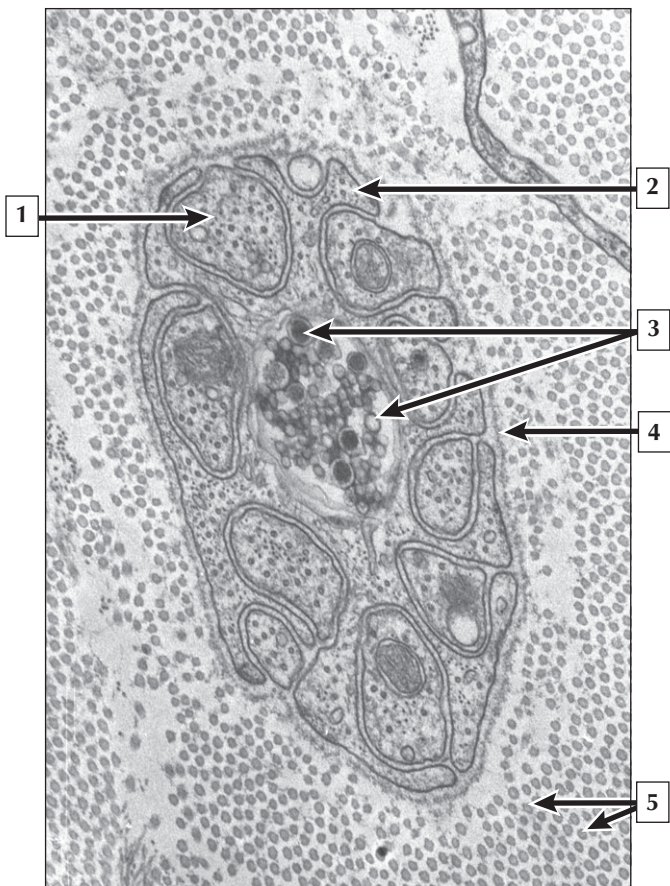
1. Schwann cell
2. Mitochondrion
3. Perineurial cell
4. Collagen fibrils of endoneurium
5. Myelin sheath
6. Neurofilaments

**Comment:** Internodal regions of myelinated nerves in the peripheral nervous system (PNS) are surrounded by concentric layers of Schwann cell plasma membrane that wrap around the nerve during development. Myelin is a lipoprotein wrapping with a high proportion of lipid to protein. The high lipid component of myelin consists of phospholipids, glycolipids, and cholesterol. Surrounding nerves, the perineurium consists of a supportive connective tissue and metabolically active perineurial cells that restrict the passage of a wide range of macromolecular substances, thereby regulating the internal microenvironment of the nerve.

**Guillain Barré Syndrome** is a rare, rapidly progressive acute **polyneuropathy** characterized by motor, sensory, and autonomic dysfunction. It is an **autoimmune disorder**, and may occur after a respiratory or gastrointestinal **viral infection**, or following vaccination. Most patients have profoundly delayed conduction in nerve fibers due to demyelination of axons.

*EM and HRSEM of a myelinated nerve fiber in the PNS*

## Peripheral Nerve



## Peripheral Nerve

---

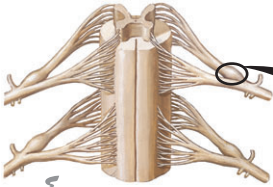1. Unmyelinated nerve fiber
2. Schwann cell
3. Synaptic vesicles
4. Basal lamina of Schwann cell
5. Collagen fibrils

**Comment:** The association of Schwann cells to nerve fibers differs between myelinated and unmyelinated nerve fibers. In the PNS, nerve fibers of small diameter composed of both axons and dendrites are grouped together by a Schwann cell that either completely or partially envelops them in groove-like invaginations that are open to the surface. Schwann cells associated with unmyelinated fibers may invest as many as 20 nerve fibers, and their entire outer surface is covered by a basal lamina. The surrounding endoneurial connective tissue contains collagen fibrils. Unmyelinated fibers have conduction speeds of 0.2 to 2 m per second.

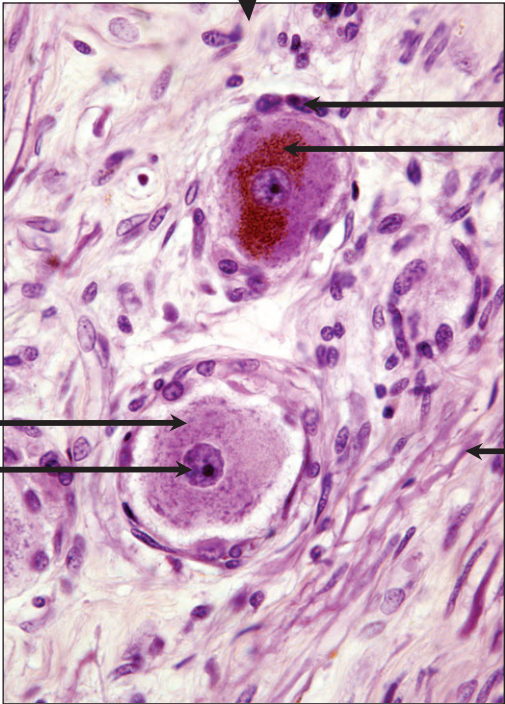
**Regeneration** of peripheral nerve after injury appears to be highly dependent on the Schwann cell and its basal lamina. At the distal segment, Schwann cells divide and, when contacted by an axonal sprout from the proximal end of the nerve, differentiate, and undergo myelin production. Signals from the axon to the Schwann cell determine whether an axon will be myelinated or unmyelinated.

*EM of a Schwann cell associated with several unmyelinated nerve fibers and axonal varicosity*

# Peripheral Ganglia



*F. Netter  
M.D.*



1

2

3

5

4



# Peripheral Ganglia

---

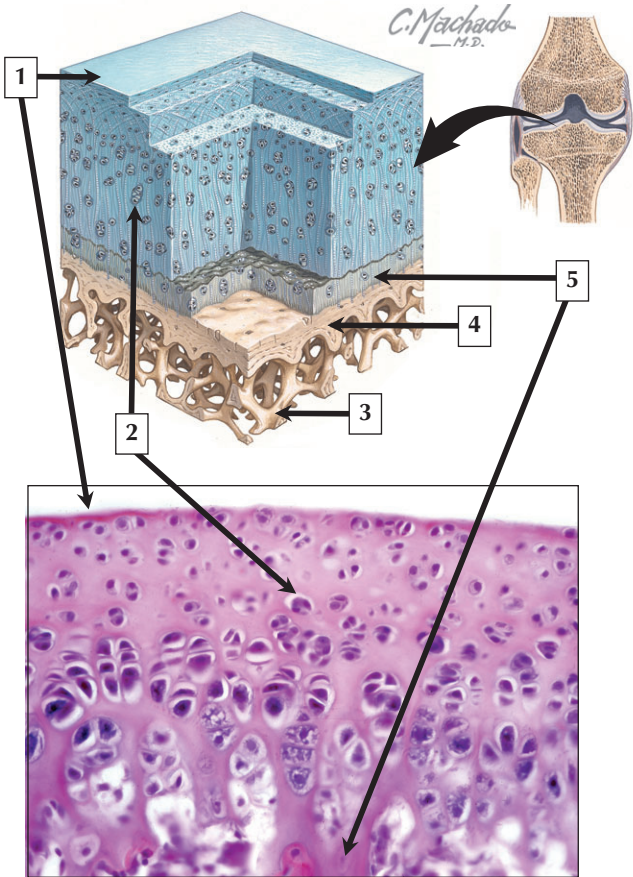
1. Satellite cell
2. Lipofuscin in perikaryon
3. Nerve fiber (axon)
4. Nucleus of neuron
5. Nissl substance

**Comment:** Ganglia are aggregations of nerve cell bodies located outside the CNS. They include sensory ganglia of cranial nerves, dorsal root ganglia of spinal nerves, and autonomic ganglia located at various sites in the periphery. They are all derived from neural crest. Nerve cell bodies within the cranial or spinal sensory ganglia are typically pseudounipolar in shape, whereas those in autonomic ganglia are commonly multipolar. Autonomic ganglia usually contain cholinergic synapses between preganglionic and postganglionic neurons, whereas synapses do not occur in the spinal ganglia. Within the ganglion, a single layer of neural crest-derived satellite cells usually surrounds each nerve cell body. Satellite cells are modified Schwann cells and form a continuous investment around the cell bodies of ganglion cells.

**Nerve blocks** are administered locally to selectively block the neural transmission in sensory nerves or ganglia as a treatment for pain. Short- or long-acting anesthetics as well as other agents such as corticosteroids, opioids, or alcohol are used for nerve block therapies.

*Schematic of spinal cord and LM of a dorsal root ganglion*

# Articular Hyaline Cartilage



## Articular Hyaline Cartilage

---

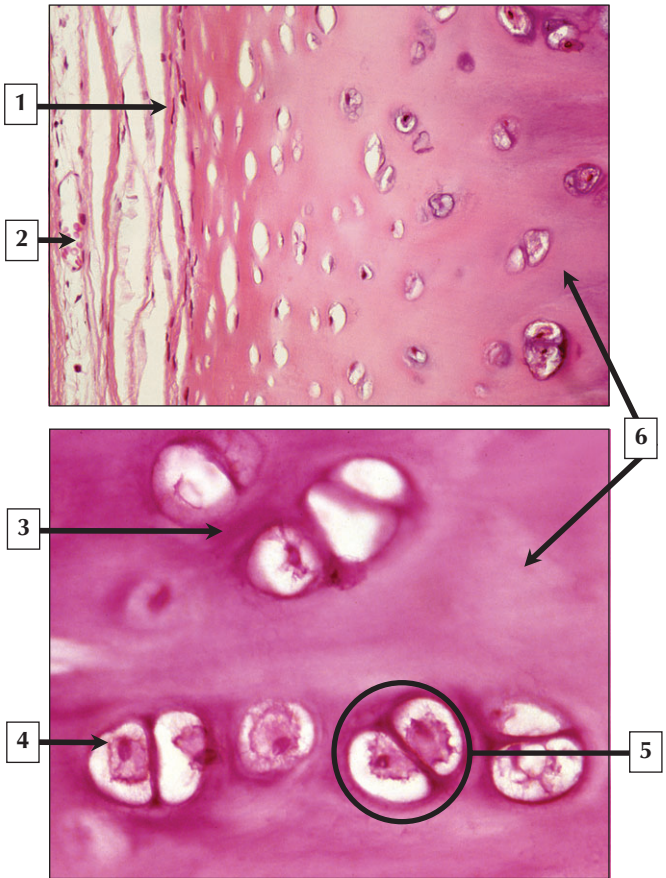
1. Articular surface
2. Chondrocyte
3. Spongy bone
4. Subchondral bone
5. Calcified cartilage zone

**Comment:** Cartilage is a specialized connective tissue consisting of three types: hyaline, elastic, and fibrocartilage. Hyaline cartilage is the most common and characteristic type. It is associated with joints, growth plates, and sutures of bones and provides a semirigid support to the walls of the upper airways in the respiratory tract. Articular hyaline cartilage consists of 4 poorly demarcated zones. The uppermost superficial zone of cartilage forms the gliding surface of the joint. Small rounded chondrocytes are oriented parallel to the surface, whereas in deeper zones the chondrocytes are larger, more rounded, and arranged in vertical columns. The deepest zone contains calcified cartilage, which separates the hyaline cartilage from subchondral bone.

**Osteoarthritis** is the most common form of arthritis and is primarily a disease of articular cartilage. It is marked by **degradation of the cartilage matrix** and altered chondrocyte metabolism due to a decreased glycosaminoglycan content in the matrix accompanied by increased water content. Enhanced matrix metalloproteinase enzyme activity appears to play a role in the degradation of the cartilage.

*Schematic of articular hyaline cartilage and LM of articular hyaline cartilage from a developing rat knee joint*

# Hyaline Cartilage



# Hyaline Cartilage

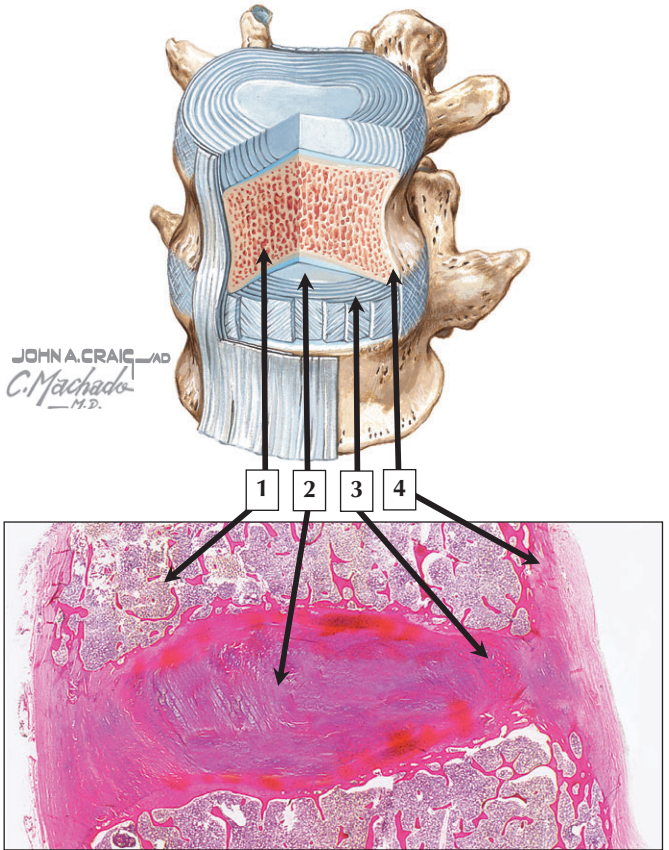
---

1. Perichondrium
2. Blood vessel (capillary) in perichondrium
3. Territorial matrix
4. Chondrocyte
5. Isogenous nest
6. Interterritorial matrix

**Comment:** Besides the articular surfaces of joints, hyaline cartilage is also found at the ends of the ribs, where they join the sternum, and in the upper respiratory airways (tracheal and bronchial segments). At these sites a perichondrium surrounds the cartilage. Blood vessels in the perichondrium provide oxygen and nutrients, which diffuse into the avascular cartilage. Chondrocytes in hyaline cartilage are often arranged in pairs or groups of 4 to 6. The cells of each group make up an isogenous cell nest because they are the progeny of a single chondrocyte during development. Type II collagen fibers, water, and ground substance constitute the matrix. The collagen fibers impart eosinophilia to the matrix, but are not visible by light microscopy because they have a similar refractive index to that of the ground substance. The basophilia in the interterritorial matrix of hyaline cartilage is due to the presence of glycosaminoglycans (GAGs), such as chondroitin sulfate, in the ground substance.

**Hyaline cartilage lesions** require accurate differential diagnosis for prognosis and treatment. Whereas **chondromas** are benign neoplasms of cartilage, **chondrosarcomas** (of which there are different types) are **malignant tumors**. They are diagnosed by **biopsy, computed axial tomography (CAT scan), and magnetic resonance imaging (MRI)**. Current treatment is radical surgery combined with **chemotherapy**.

*Low and high magnification LMs of hyaline cartilage in the trachea*



## Fibrocartilage

---

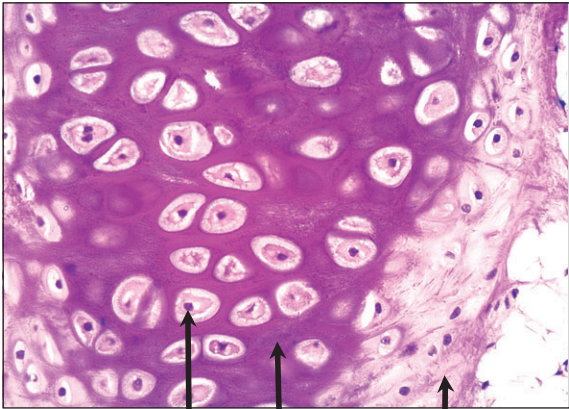
1. Spongy bone of vertebra
2. Nucleus pulposus
3. Annulus fibrosis
4. Compact bone of vertebra

**Comment:** Fibrocartilage is found in the annulus fibrosis of intervertebral discs, symphysis pubis, menisci of synovial joints, and at points of attachment of tendons to bone. It is a mixture between dense regular connective tissue, similar in many respects to tendon or ligament, and hyaline cartilage. Functionally, it combines the tensile strength, firmness, and durability of tendon and the resistance to compression of cartilage. In contrast to the other two types of cartilage, fibrocartilage is devoid of a distinct perichondrium, blending imperceptibly with surrounding connective tissue or hyaline cartilage. Its matrix is intensely eosinophilic due to the presence of numerous collagen fibers.

A **herniated (slipped) disc** is a common condition that affects the intervertebral disc and can cause severe pain or numbness if the protruding disc impinges on a nerve or the spinal cord. It results from an overall loss of elasticity of the disc and subsequent rupture of the annulus fibrosis, which allows the protrusion of the nucleus pulposus through the annulus fibrosis into the surrounding area of the spinal column.

*Schematic and LM of the intervertebral disc*

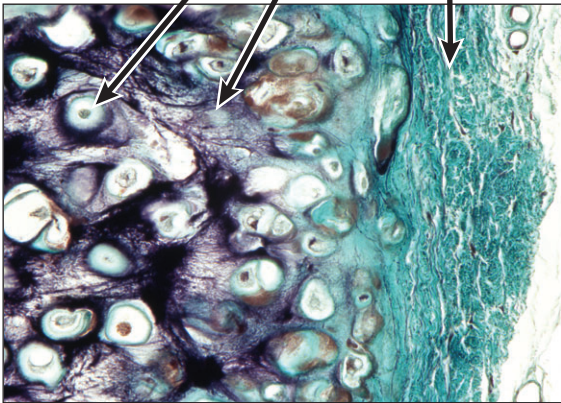
## Elastic Cartilage



1

2

3





# Elastic Cartilage

---

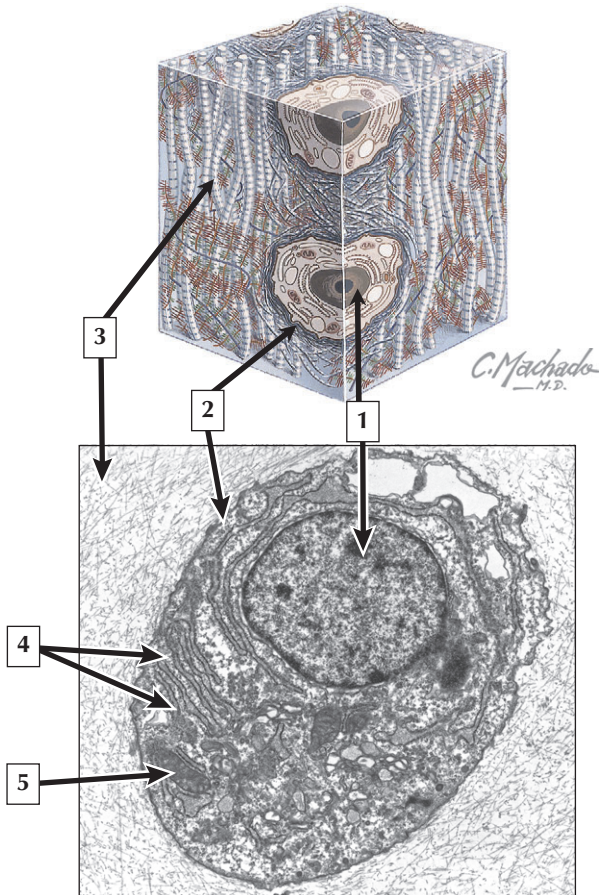
1. Chondrocyte
2. Matrix
3. Perichondrium

**Comment:** Elastic cartilage provides structural integrity to the auricle of the ear, epiglottis, and eustachian (auditory) tube. It is resilient, easily returning to its original shape after bending or distortion, and has more flexibility and elasticity than the other 2 types of cartilage. Its matrix contains a dense, interwoven network of elastic fibers embedded in a small amount of amorphous extracellular ground substance. The elastic fiber network is more dense in the interior than at the periphery. Chondrocytes in elastic cartilage are spherical in shape and are contained in lacunae. They are similar in appearance to chondrocytes of hyaline cartilage, except that they are more closely packed and commonly found singly in lacunae. Only a few isogenous nests of chondrocytes are present. The high refractive index of elastic fibers imparts a lightly eosinophilic staining pattern in conventional preparations. With special methods that selectively stain for elastin, the branching and anastomosing nature of the elastic fibers is demonstrated more clearly.

**Disorders of elastic cartilage** are uncommon. However, **pseudocysts** (or **cystic chondromalacia**) affect elastic cartilage in the auricle of the ear or the epiglottis. It is a benign, non-inflammatory intracartilagenous swelling accompanied by fibrosis and formation of granulation tissue. Although etiology is unknown, it is probably caused by **ischemia** to the perichondrium, which normally harbors the blood supply to this cartilage.

*LM of elastic cartilage in the epiglottis stained with hematoxylin and eosin and stained with Van Geisen elastin stain*

# Chondrocyte



# Chondrocyte

---

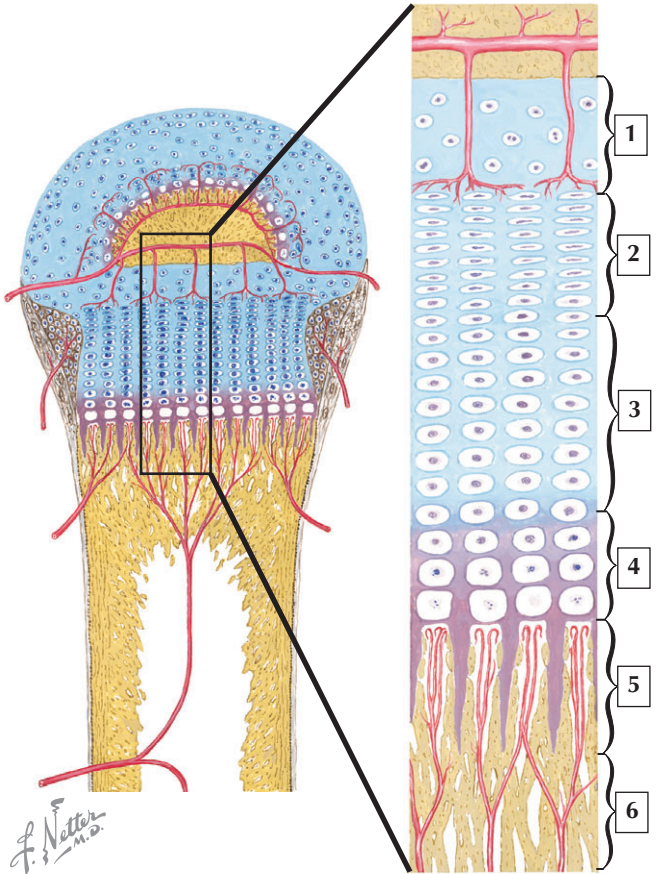
1. Nucleus
2. Plasma membrane of chondrocyte
3. Matrix
4. Rough endoplasmic reticulum
5. Mitochondrion

**Comment:** Chondrocytes share similar fine structural features of other connective tissue cells, such as fibroblasts and osteoblasts. They synthesize and secrete proteins (e.g., collagen) and ground substance (e.g., proteoglycans, glycosaminoglycans, glycoproteins). In hyaline cartilage, type II collagen fibrils predominate in the matrix and form a loose three-dimensional network. At least two other collagens, types IX and XI, assist in stabilizing the type II collagen fibrils.

**Growth and activity of chondrocytes**, especially those in the growth plate of bones, are highly responsive to growth factors such as insulin-like growth factor 1 (IGF-1). Growth hormone (somatotropin) secreted by the anterior pituitary stimulates the production of IGF-1 by liver cells. In **growth hormone deficiency**, the production of IGF-1 is compromised, resulting in the slowing of bone elongation and maturation. Synthetic growth hormones can be used for treatment to activate IGF-1 production and subsequent growth of chondrocytes.

*Schematic of hyaline cartilage and EM of a chondrocyte in hyaline cartilage of the trachea*

# Growth Plate



## Growth Plate

---

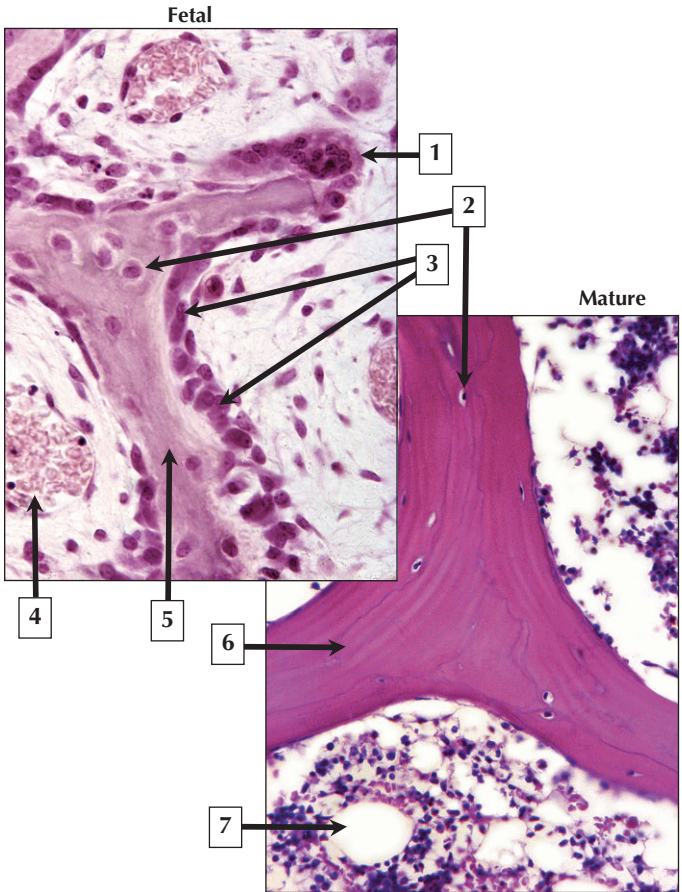
1. Reserve zone
2. Proliferative zone
3. Zone of maturation and hypertrophy
4. Zone of provisional calcification
5. Zone of ossification (primary spongiosa)
6. Zone of ossification (secondary spongiosa)

**Comment:** In the fetus, hyaline cartilage forms a provisional skeleton, which is replaced by endochondral bone formation. Soon after fetal life and up to adolescence, hyaline cartilage at epiphyseal growth plates is responsible for the growth, elongation, and shape of long bones. The cartilagenous growth plates in a typical long bone are confined to its 2 ends and provide temporary scaffolding on which new bone is laid down. The growth plate promotes apposition of new hyaline cartilage at the end facing the epiphysis. This is followed by cartilage destruction in lower regions and its replacement to primary spongy bone in the deepest region, the metaphysis.

**Achondroplasia** is a rare, autosomal dominant disorder of epiphyseal growth plates of developing long bones. Chondrocytes in the growth plates fail to proliferate in endochondral ossification, resulting in premature fusion of the epiphyses with the diaphyses. Because the bones of the face and skull normally develop by intramembranous ossification, they are not affected. Failure of long bones to elongate results in a form of **dwarfism** characterized by short limbs but normal body size.

*Schema of the growth plate from a long bone*

# Spongy Bone



## Spongy Bone

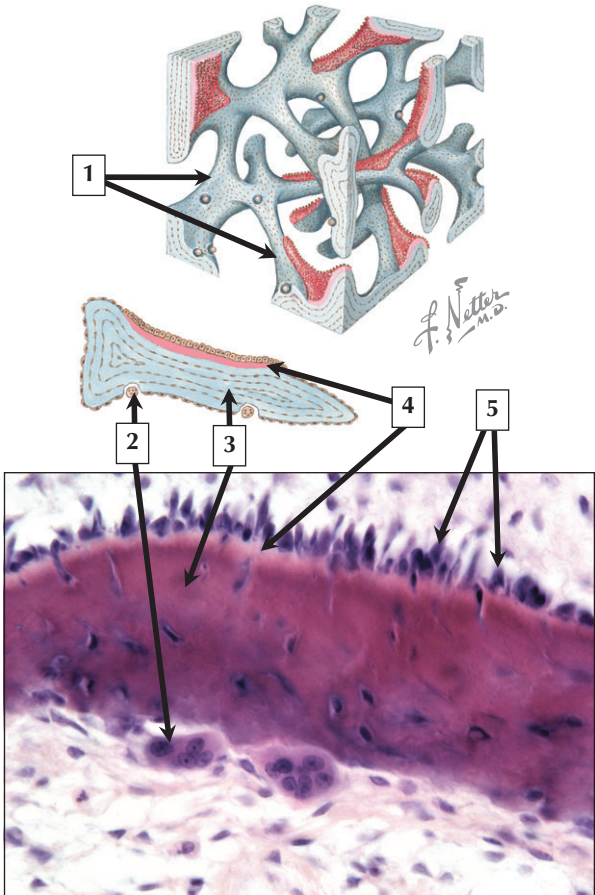
---

1. Osteoclast
2. Osteocyte
3. Osteoblasts
4. Blood vessel
5. Woven bone (trabecula)
6. Lamellar bone (trabecula)
7. Fat cell adipocyte

**Comment:** Depending on the orientation of collagen fibers in the bony matrix, bone tissue is organized as either primary (woven) or mature (lamellar) bone. Woven bone is present in bones of fetuses and young children and is characterized by coarse collagen fibers that are oriented randomly. Lamellar bone begins to form shortly after birth and actively replaces woven bone by age 4. Trabecula in mature bone is made up of lamellar bone and is intensely eosinophilic. Embedded in the matrix are osteocytes and their lacunae, which are small and spindle shaped.

**Osteomalacia** is a metabolic disorder of bone caused by **vitamin D deficiency**. It is known as **rickets** in children and is characterized by excessive amounts of unmineralized osteoid, where bone mineral fails to be deposited in normally formed bone matrix. While osteoid comprises less than 5% of normal bone, it can account for 40% to 50% of bone in osteomalacia and rickets. Consequently, bone strength is reduced, resulting in fractures and bone pain.

*LM of fetal bone showing a developing bony trabecula and LM of a trabecula in mature spongy bone*





## Cells of Bone

---

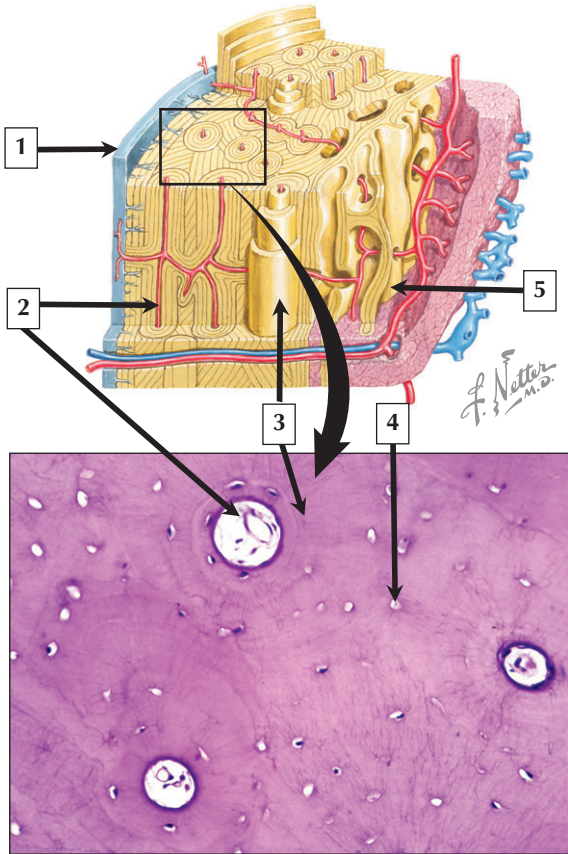
1. Trabeculae of spongy bone
2. Osteoclast
3. Bony matrix
4. Osteoid (newly synthesized bone)
5. Osteoblasts

**Comment:** Osteoblasts are bone-forming cells derived from progenitor cells present in the surrounding connective tissue and bone marrow. They are polarized cells that synthesize and secrete unmineralized osteoid, which later becomes mineralized. Its main components include type I collagen and the glycoproteins, osteocalcin and osteopontin. Osteoblasts also synthesize alkaline phosphatase, a cell surface protein that promotes mineralization and formation of hydroxyapatite in the bony matrix. As ossification proceeds, osteoblasts become entrapped in the bony matrix and are termed osteocytes. Osteoclasts are specialized multinucleated cells whose major role is to resorb bone by maintaining a low pH in the resorption cavity.

**Paget's disease (osteitis deformans)** of bone results from an imbalance in activity of osteoclasts and osteoblasts in the bone-remodeling process. New bone that is laid down is soft and porous, and can easily bend and break. Only a small number of bones are typically affected in this disease.

*Schematic of spongy (trabecular) bone and LM of a trabecula in spongy bone*

# Compact Bone



## Compact Bone

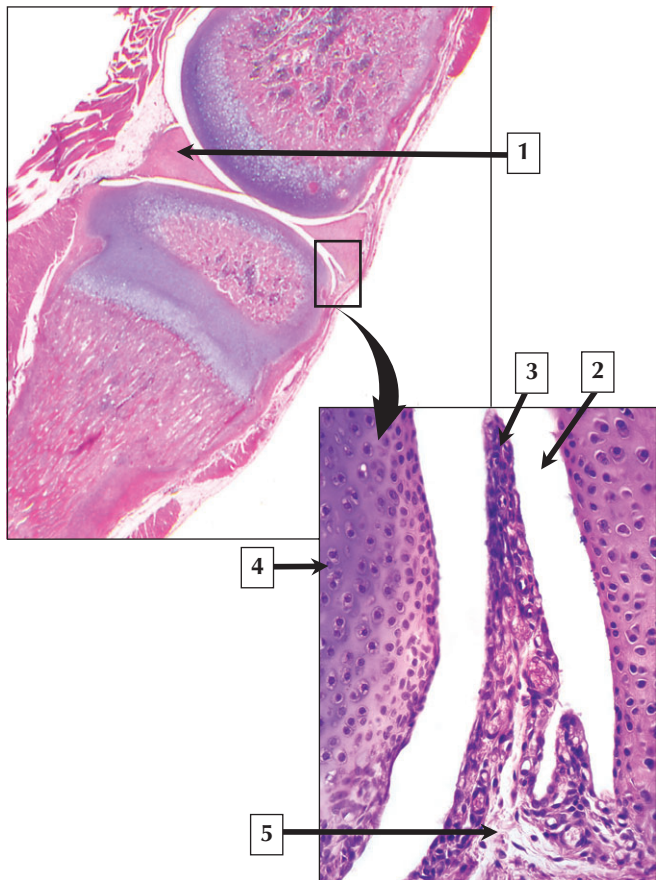
---

1. Periosteum
2. Capillary in Haversian canal
3. Concentric lamella
4. Osteocyte
5. Trabecula

**Comment:** Most bones contain both compact (cortical) and spongy (trabecular) bone. Their relative amounts and distribution within bone varies with age and according to function. Compact bone is limited to the outer shell or cortex of the bone. It is composed of many adjacent Haversian systems, or osteons, that appear round to oval in transverse section and are usually oriented in the long axis of the bone. Each osteon is a cylindrical unit measuring about 250  $\mu\text{m}$  in diameter. It consists of a central Haversian canal, which contains small blood vessels and nerves, and is surrounded by 4 to 20 concentrically arranged lamellae.

**Osteoporosis** is a systemic skeletal disease characterized by low bone mass and microarchitectural deterioration of bone tissue with a consequent increase in bone fragility and susceptibility to fracture. An imbalance between bone resorption and bone formation causes the disease. While **hormone replacement therapy (HRT)** in postmenopausal women is effective in slowing the rate of bone loss, there are potentially deleterious side effects of HRT on the cardiovascular system. Administration of calcitonin also inhibits bone resorption and can prevent postmenopausal bone loss.

*Schematic of the cortical region of bone and LM of compact bone*



## Synovium

---

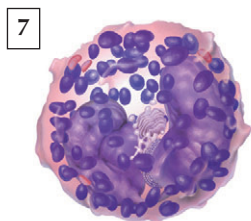
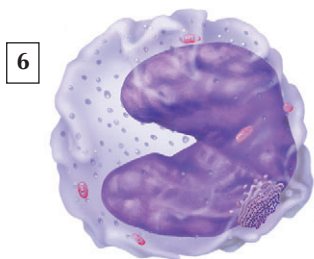
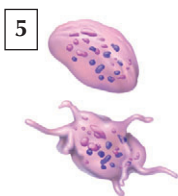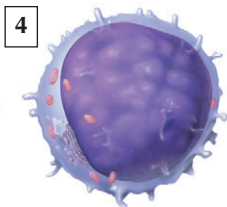
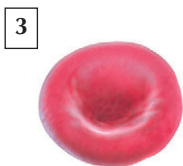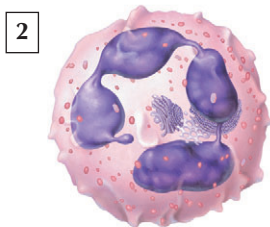
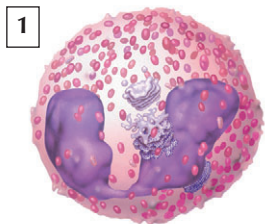
1. Meniscus
2. Synovial cavity
3. Synovial villus of synovium
4. Articular cartilage
5. Subintimal layer loose connective tissue

**Comment:** The synovium is a delicate and highly vascularized lining of the synovial joint. The intimal lining cells, known as synoviocytes, are modified connective tissue cells rather than epithelial cells. They form 1 or 2 cellular layers concentrated along the luminal surface, giving the false impression of a continuous cellular “membrane” characteristic of epithelia. However, the synoviocytes are not joined by intercellular junctions and are devoid of a basement membrane. Two types of cells are present in the lining cells: Type A synoviocytes (20% to 30%), which are modified phagocytes derived from blood monocytes, and Type B synoviocytes, which are modified fibroblasts that synthesize glycosaminoglycans and glycoproteins. Synovial fluid is mainly an ultrafiltrate of blood and secretions of type B synoviocytes.

**Rheumatoid arthritis** is a chronic, inflammatory, systemic disease that manifests predominantly in diarthroidal joints. The earliest changes are injury to the synovial microvasculature, endothelial swelling, and hyperplasia of type A and type B synoviocytes. Aggregates of CD4<sup>+</sup> T lymphocytes and diffuse infiltrates of CD8<sup>+</sup> cells characterize the subintimal layer.

*LM of rat knee joint and high magnification LM of synovium*

## Formed Elements of Blood



*C. Machado*  
—M.D.

## Formed Elements of Blood

---

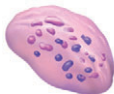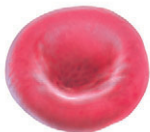1. Eosinophil
2. Neutrophil
3. Erythrocyte
4. Lymphocyte
5. Platelets
6. Monocyte
7. Basophil

**Comment:** The formed elements of blood constitute about 45% of the volume of blood in the adult—plasma makes up the remaining 55% and consists of several proteins such as fibrinogens, globulins, and albumin, and a ground substance known as serum. Erythrocytes (or red blood cells), granular (neutrophils, eosinophils, basophils) and agranular leukocytes (monocytes, lymphocytes), and circulating cytoplasmic fragments known as platelets (or thrombocytes) make up the cellular elements.

A **complete blood count (CBC)** is a valuable screening test that measures the number of erythrocytes, number of leukocytes, total amount of hemoglobin in blood, and fraction of erythrocytes, known as the **hematocrit**. It also includes other information about the erythrocytes such as mean corpuscular hemoglobin (MCH) and mean corpuscular hemoglobin concentration (MCHC). Also included in the CBC is the platelet count. The CBC is used to diagnose and manage many conditions and diseases such as **acute** and **chronic** forms of **infection**, **allergies**, and various types of **anemias**.

*Schema of the formed elements in blood*

# Erythrocytes and Platelets



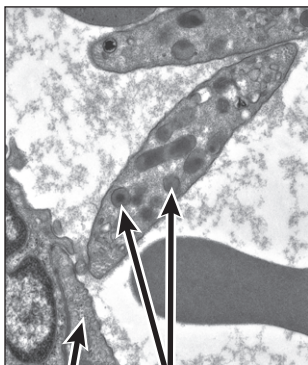
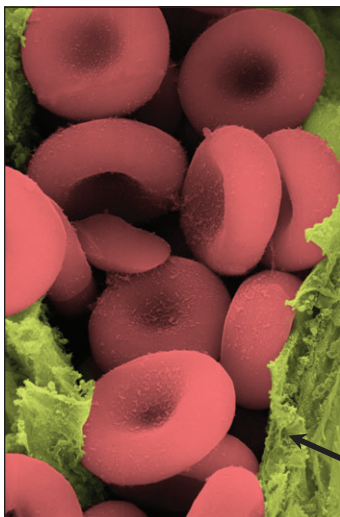
*C. Machado*  
—M.D.

1 What protein accounts for the red color in erythrocytes?

3 What function is associated with platelets?

2 What is the approximate lifespan of erythrocytes?

4 From what cell are platelets derived?



5

6



## Erythrocytes and Platelets

---

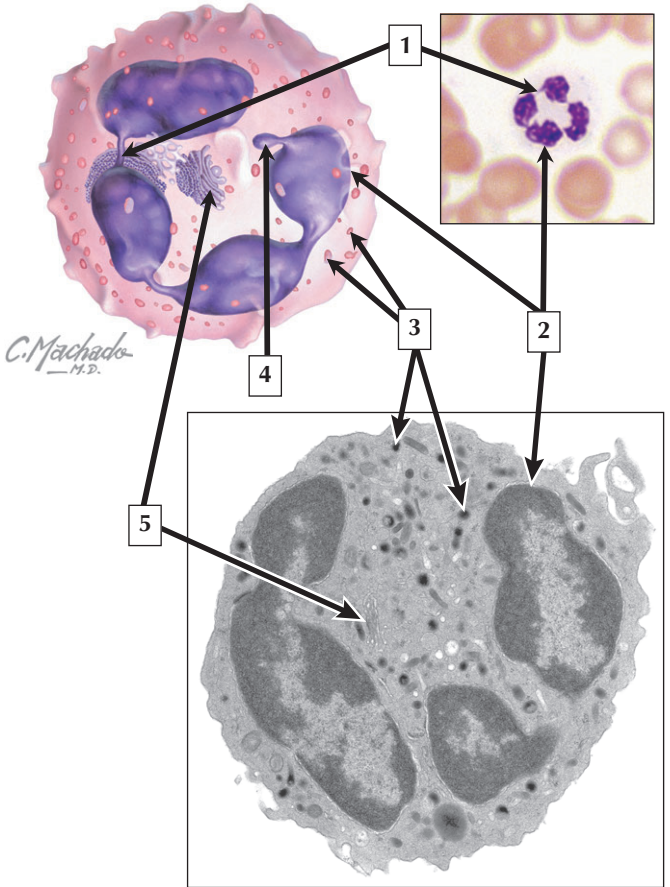
1. Hemoglobin
2. 120 days
3. Blood coagulation (clotting)
4. Megakaryocyte
5. Endothelial cell
6. Dense granules of platelet

**Comment:** Erythrocytes are anucleate biconcave discs with an average diameter of  $7.5\ \mu\text{m}$ . They represent 99% of the formed elements. Their normal numbers per liter of blood average  $5 \times 10^{12}$  in men and  $4.5 \times 10^{12}$  in women. Its biconcave shape provides a large surface area to carry out its primary function in transporting  $\text{O}_2$  from the lungs to the tissues and returning  $\text{CO}_2$  from the tissues to the lungs for elimination. The iron-containing protein, hemoglobin, accounts for their red color and rapidly binds to  $\text{O}_2$  for transport. Platelets are motile cytoplasmic fragments enveloped by a cell membrane that arise from megakaryocytes in the bone marrow. They are the smallest formed elements in blood and appear as plate-like structures devoid of nuclei. They are 2 to 3  $\mu\text{m}$  in diameter and number 250,000 to 350,000 per  $\text{mm}^3$ .

**Anemia** is a deficiency of erythrocytes, of which there are many different types. Calculating the number of RBCs in peripheral blood, determining the concentration of hemoglobin, and examining the morphology of erythrocytes in blood smears contribute to the correct diagnosis.

*Schema of an erythrocyte and platelet, SEM of erythrocytes, and EM of platelets in a venule*

# Neutrophil



# Neutrophil

---

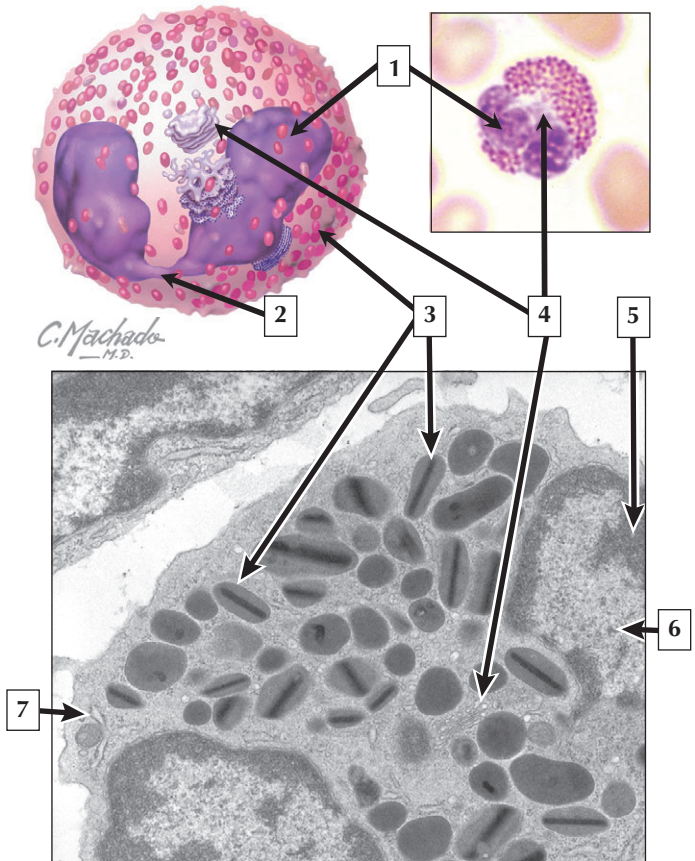
1. Chromatin strand (interconnecting lobes of nucleus)
2. Lobe of nucleus
3. Specific granules
4. Barr body (present in females only)
5. Golgi complex

**Comment:** Neutrophils are the most numerous of leukocytes, constituting 60% to 70% of the leukocyte count. They are also known as polymorphonuclear leukocytes due to their distinctive nuclear morphology. They measure 9 to 12  $\mu\text{m}$  in diameter, and their nucleus displays many forms, has a clump-like pattern, and consists of 3 to 5 lobes connected by fine strands of chromatin. In females, a small separate lobe shaped like a small drumstick called a Barr Body is often present. It is not seen in males and may be useful in determining the chromosomal sex of a person. Neutrophils are avidly phagocytic—their lifespan may reach 4 days—they engulf bacteria, cellular debris, and foreign matter. Their membrane-bounded specific granules contain bactericidal enzymes engaged in receptor-mediated phagocytosis.

**Neutropenia** is an abnormal decrease in the neutrophil count in peripheral blood, and patients with this condition have an inadequate number of neutrophils to defend against **bacterial infections**. While neutropenia may be caused by genetic, drug-induced, or other factors, it is often associated with **autoimmune diseases** and is a common feature of **acquired immune deficiency syndrome (AIDS)**.

*Schematic, LM of a neutrophil in a blood smear, and EM of a neutrophil*

# Eosinophil



# Eosinophil

---

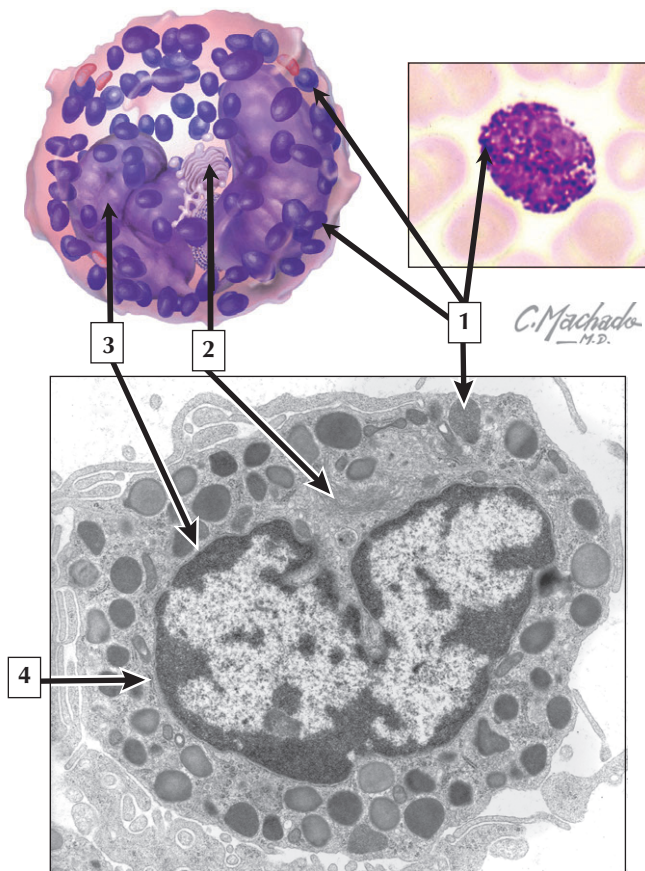
1. Lobe of nucleus
2. Chromatin strand
3. Specific granules
4. Golgi complex
5. Heterochromatin
6. Euchromatin
7. Rough endoplasmic reticulum

**Comment:** Eosinophils make up 1% to 3% of the leukocyte count. They are slightly larger than neutrophils, with a diameter of 12 to 15  $\mu\text{m}$ . Their nucleus is typically bilobed, and their specific granules are distinctive, uniform in size, and highly refractile. They have an affinity for acid dyes and stain dark pink to crimson in coloration. Specific granules contain a variety of hydrolytic enzymes. They also secrete histaminase, which inactivates the histamine produced by basophils and mast cells. By electron microscopy, the specific granules of the eosinophil are membrane-bounded and irregular in outline, ranging from ellipsoid to football-shaped, and contain an internal crystalloid core.

**Eosinophilia** is an increase in the absolute number of circulating eosinophils above normal levels. It occurs in allergic reactions, parasitic infestations, and some malignancies. Eosinophils play a central role in controlling parasitic diseases such as **schistosomiasis**. They kill parasitic helminth worms at the larval stage by releasing toxic molecules from their specific granules.

*Schematic, LM of an eosinophil in a blood smear, and EM of a portion of an eosinophil*

# Basophil



# Basophil

---

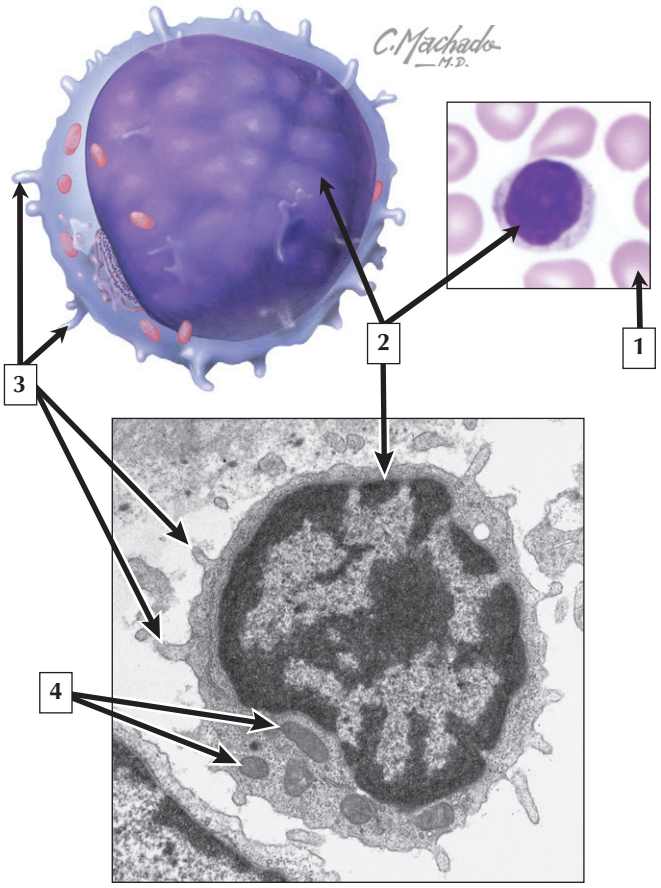
1. Specific granules
2. Golgi complex
3. Nucleus
4. Rough endoplasmic reticulum

**Comment:** Basophils are the least numerous of leukocytes, comprising less than 1% of the normal leukocyte count. They are the smallest of the granulocytes and measure 8 to 10  $\mu\text{m}$  in diameter. They possess large and distinctive specific granules that are intensely basophilic and fill the cytoplasm of the cell. The nucleus of each cell is often irregular in shape or bilobed. In blood smears, it is commonly obscured by the many closely packed basophilic granules, which are often more deeply stained than the chromatin of the nucleus. The granules contain histamine and heparin; basophils also produce platelet-activating and eosinophilic chemotaxic factors that exert powerful pharmacologic effects outside the circulation.

**Basophilia**—an elevated basophil count in peripheral blood—rarely occurs in most benign conditions. Mild basophilia may be part of a generalized inflammatory response to some infections, for example, **smallpox, chicken pox, or influenza**. It also occurs in allergic disorders or autoimmune inflammation such as **rheumatoid arthritis** or **ulcerative colitis**.

*Schematic, LM of a basophil in a blood smear, and EM of a basophil*

*C. Machado*  
— M.D. —





# Lymphocyte

---

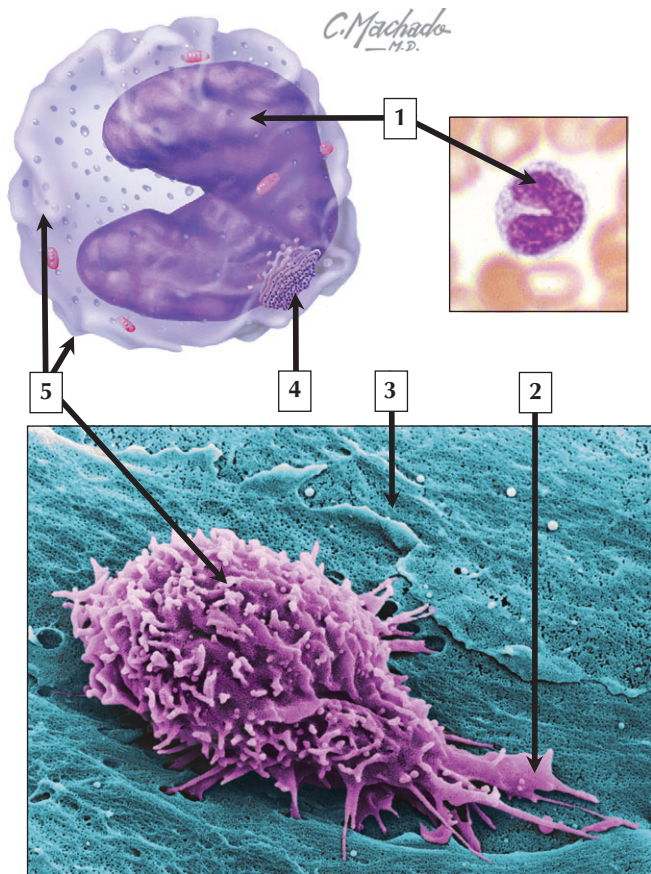
1. Erythrocyte
2. Nucleus
3. Microvilli
4. Mitochondria

**Comment:** Lymphocytes are the most numerous of the agranular leukocytes, constituting 20% to 30% of the leukocyte count. They range in size from 7 to 16  $\mu\text{m}$  and are classified into small (7 to 10  $\mu\text{m}$ ) and medium-to-large (11 to 16  $\mu\text{m}$ ) lymphocytes. They are spherical cells with a densely stained nucleus and a thin rim of blue-gray cytoplasm. Whereas all lymphocytes are derived from bone marrow stem cells, those that differentiate and mature in the thymus are called T cells; those that develop in the bone marrow, where they acquire specific cell surface antigens, are known as B cells. T cells are involved in cell-mediated immunity as opposed to B cells, which are engaged in humoral (antibody) immunity. The lifespan of lymphocytes ranges from days to many years.

**Lymphocytosis** is an increase in the absolute number of lymphocytes in peripheral blood. It often occurs in infants and adolescents in response to **infections** that, in adults, would typically produce a neutrophil response. While there are many causes, the most common is a primary infection with the **Epstein-Barr virus (EBV)**. The condition, otherwise known as **infectious mononucleosis**, causes a rise in circulating T lymphocytes in response to EBV infection of B cells.

*Schematic, LM of a large lymphocyte in a blood smear, and EM of a lymphocyte*

# Monocyte



# Monocyte

---

1. Nucleus (horseshoe shaped)
2. Pseudopod
3. Endothelial cell
4. Rough endoplasmic reticulum
5. Membrane ruffles

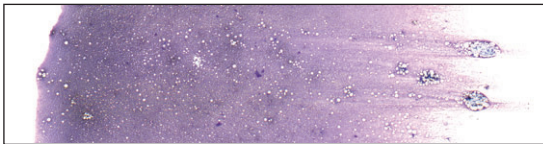
**Comment:** Monocytes are agranular leukocytes that serve as immediate precursors to cells of the mononuclear phagocytic system. They constitute 3% to 8% of the total leukocyte count and are the largest of the leukocytes in blood smears. They measure 12 to 20  $\mu\text{m}$  in diameter. They normally circulate in the bloodstream for only 1 to 3 days and perform virtually all their functions outside the circulation. They are actively motile and leave the circulation to enter the connective tissues to become macrophages (or phagocytes). Each cell possesses a nucleus that is variable in form and may be ovoid, kidney, or horseshoe shaped. In contrast to the coarse and darkly stained nuclear chromatin of lymphocytes, the nuclear chromatin of monocytes is finely granular, pale stained, and indented.

**Monocytosis** is an abnormal rise in the blood monocyte count above  $0.8 \times 10^9/\text{L}$ . Although monocytosis is rare, there are many conditions that may cause it. They include **chronic bacterial infections, bacterial endocarditis, typhoid, malaria, syphilis, and protozoan infections.**

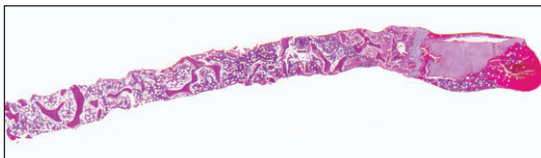
*Schematic, LM of a monocyte in a blood smear, and SEM of a monocyte invading endothelium of venule*

Identify the type of bone marrow preparations shown in 1 and 2.

1



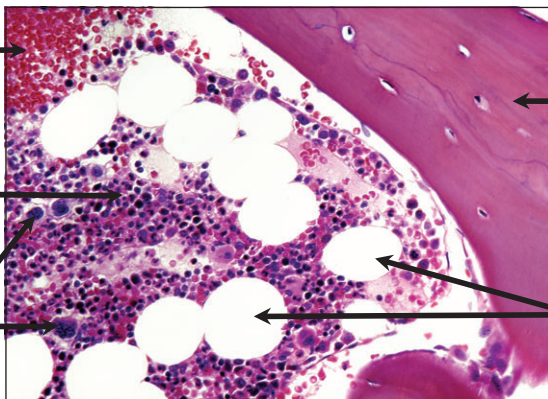
2



3

4

5



7

6

## Bone Marrow

---

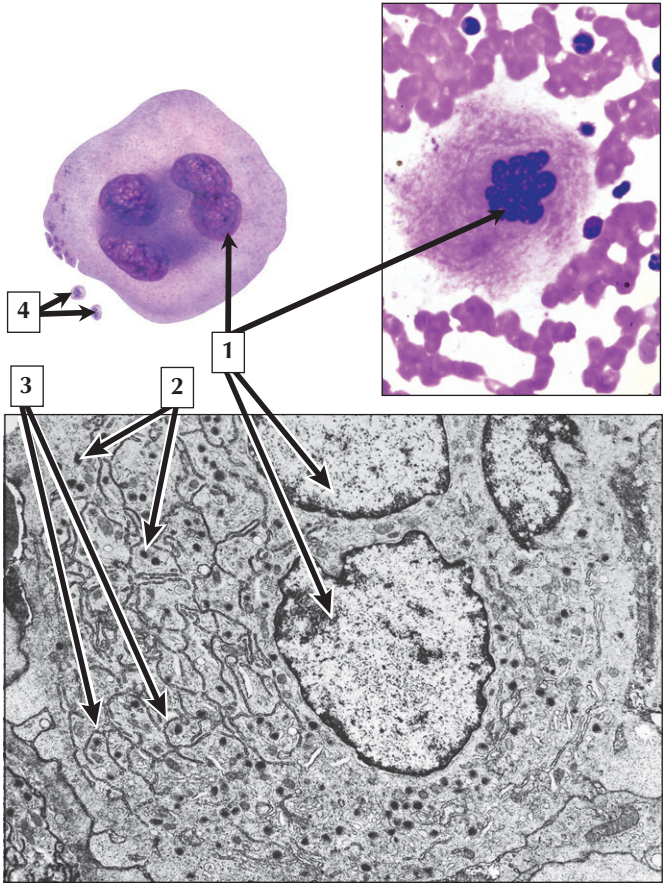
1. Bone marrow smear
2. Trehine needle biopsy section
3. Venous sinusoid filled with erythrocytes
4. Hematopoietic tissue
5. Megakaryocytes
6. Fat cells (adipocytes)
7. Bone trabecula

**Comment:** Bone marrow is a special form of connective tissue. It consists of a stroma of loose reticular connective tissue and a parenchyma of hematopoietic cells arranged as irregular cellular cords or islands separated by thin-walled venous sinusoids. Two methods used to sample and examine bone marrow are smears and trephine needle biopsies for preparation of bone marrow sections. The optimal site for both bone marrow aspiration and needle biopsy is the posterior iliac crest. Other sites include the sternum and tibia. Bone marrow is the site of hematopoiesis after birth. It can be divided into erythropoiesis, granulocytopoiesis, monocytopenoiesis, lymphocytopoiesis, and thrombocytopoiesis.

**Bone marrow transplantation** is a valuable tool in medicine. Stem cell transplants are used to reconstitute the marrow after **chemotherapy** or to replace primary loss of stem cells in disease. Transplantation can be either **autologous** (own marrow saved before treatment) or **allogenic** (MHC matched donor marrow).

*LM of bone marrow smear, section of bone marrow biopsy, and high-magnification LM of bone marrow section*

# Megakaryocyte



# Megakaryocyte

---

1. Nuclei
2. Dense granules
3. Demarcation channels between forming platelets
4. Platelets

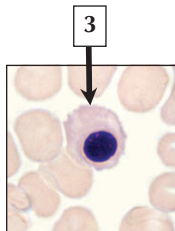
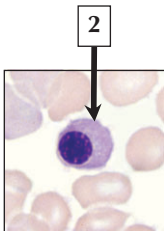
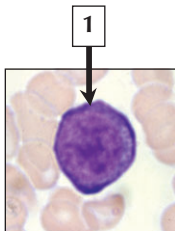
**Comment:** Megakaryocytes are the largest cells in bone marrow, measuring 50 to 100  $\mu\text{m}$  in diameter. Their lobulated nucleus is highly convoluted and displays coarse chromatin. Its uniquely polyploid nucleus is due to multiple replication of nuclear DNA without division of the cytoplasm. By LM, its homogeneous cytoplasm is lightly basophilic due to the presence of large numbers of free ribosomes and many small azurophilic granules. Platelets are formed by fragmentation of the cytoplasm along demarcation channels at the periphery of these cells.

**Thrombocytopenia** is a condition characterized by an abnormal depletion of platelets in blood. Because platelets are critical for blood clotting, the disorder results in **hemorrhage** if not treated. It may be caused by failure of the bone marrow to produce adequate numbers of platelets or by an increased rate of removal of platelets in the blood. Low platelets are a common side effect of **radiation treatment** and **chemotherapy** for **lymphoma** and other **cancers**, which destroy their cellular precursors in the bone marrow.

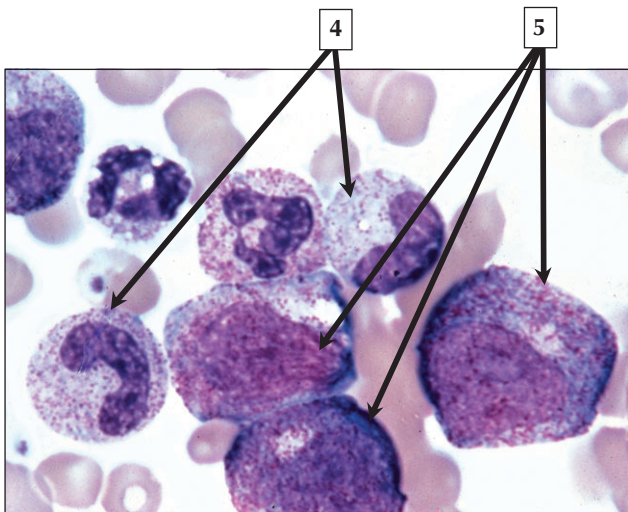
*Schematic, LM of megakaryocyte in a bone marrow smear, and EM of part of a megakaryocyte*

# Erythropoiesis and Granulocytopenesis

## Erythropoiesis



## Granulopoiesis





# Erythropoiesis and Granulopoiesis

---

1. Proerythroblast
2. Polychromatophilic erythroblast
3. Normoblast (orthochromatic erythroblast)
4. Metamyelocytes
5. Promyelocytes

**Comment:** All the mature cells of blood are ultimately derived from pluripotential stem cells in bone marrow. They have capacity for prolonged self-renewal, asymmetric replication, and differentiation. Four types of colony-forming units (CFU) are committed to the production of granulocytes and monocytes, erythrocytes, platelets, and lymphocytes, respectively. The erythroid developmental sequence includes the proerythroblast, basophilic erythroblast, polychromatophilic erythroblast, normoblast, and erythroblast. The myeloid sequence includes myeloblast, promyelocyte, myelocyte, metamyelocyte, band cell, and mature granular leukocyte (e.g., neutrophil, eosinophil, or basophil).

**Aplastic anemia** is a hematologic disorder caused by failure of the bone marrow. It is usually defined as a **pancytopenia** or reduction in the blood cell count of all the major cell lines of the erythroid and myeloid series. Common clinical signs are **bruising** or **bleeding** due to a low platelet count, **infection** due to diminished production of white blood cells, and **lethargy** due to reduction in red blood cells and low hemoglobin.

*LMS of bone marrow smears showing cells from erythropoiesis and from granulocytopenia*

## Section 2: Systems

### Cardiovascular System

- 8-1** Atrium
- 8-2** Heart Wall and Pericardium
- 8-3** Aorta
- 8-4** Coronary Artery
- 8-5** Arteriole
- 8-6** Arteriole and Venule
- 8-7** Small Vein
- 8-8** Endothelium
- 8-9** Tight Capillary
- 8-10** Fenestrated Capillary
- 8-11** Lymphatic Vessel

### Lymphoid System

- 9-1** Lymphoid Tissue
- 9-2** Lymphatic Vessel
- 9-3** Lymph Node
- 9-4** Lymph Node
- 9-5** High Endothelial Venule
- 9-6** Tonsil
- 9-7** Thymus
- 9-8** Spleen
- 9-9** White Pulp
- 9-10** Red Pulp

## Section 2: Systems

### Endocrine System

- 10-1** Pituitary
- 10-2** Intermediate Lobe
- 10-3** Anterior Pituitary
- 10-4** Posterior Pituitary
- 10-5** Thyroid
- 10-6** Parathyroid
- 10-7** Adrenal
- 10-8** Adrenal
- 10-9** Spongiocyte
- 10-10** Pancreas
- 10-11** Islet of Langerhans
- 10-12** Pineal

### Integumentary System

- 11-1** Thin Skin
- 11-2** Thick Skin
- 11-3** Epidermis
- 11-4** Keratinocytes
- 11-5** Melanocytes
- 11-6** Langerhans Cells
- 11-7** Vasculature of the Dermis
- 11-8** Eccrine Sweat Gland
- 11-9** Pilosebaceous Unit
- 11-10** Hair and Its Follicle

## Section 2: Systems

**11-11** Sebaceous Gland

**11-12** Nails

### Upper Digestive System

**12-1** Lip

**12-2** Gingiva

**12-3** Tongue

**12-4** Palate

**12-5** Teeth

**12-6** Salivary Glands

**12-7** Striated Ducts

**12-8** Esophagus

**12-9** Esophagus

**12-10** Esophago-Gastric Junction

**12-11** Enteric Nervous System

### Lower Digestive System

**13-1** Stomach

**13-2** Stomach

**13-3** Parietal Cells

**13-4** Chief Cells

**13-5** Enteroendocrine Cells

**13-6** Duodenum

**13-7** Jejunum

**13-8** Gastroduodenal Junction

**13-9** Enterocytes

## Section 2: Systems

- 13-10** Goblet Cells
- 13-11** Paneth Cells
- 13-12** Appendix
- 13-13** Rectoanal Junction

### **Liver, Gallbladder, and Exocrine Pancreas**

- 14-1** Liver
- 14-2** Hepatic Lobule
- 14-3** Portal Tract and Central Vein
- 14-4** Liver Acinus
- 14-5** Hepatocyte
- 14-6** Hepatocyte
- 14-7** Hepatic Sinusoid
- 14-8** Biliary Duct System
- 14-9** Gallbladder
- 14-10** Gallbladder Epithelium
- 14-11** Pancreas
- 14-12** Pancreatic Acinus

### **Respiratory System**

- 15-1** Respiratory Mucosa
- 15-2** Epiglottis
- 15-3** Larynx and Vocal Cord
- 15-4** Trachea
- 15-5** Tracheal Epithelium

## Section 2: Systems

- 15-6** Respiratory Cilia
- 15-7** Bronchus
- 15-8** Bronchiole
- 15-9** Clara Cells
- 15-10** Pulmonary Alveoli
- 15-11** Blood-Air Barrier
- 15-12** Type II Pneumocyte

### Urinary System

- 16-1** Kidney
- 16-2** Uriniferous Tubule
- 16-3** Renal Corpuscle
- 16-4** Renal Corpuscle and Podocytes
- 16-5** Renal Filtration Barrier
- 16-6** Proximal Tubule
- 16-7** Collecting Duct
- 16-8** Ureter
- 16-9** Urinary Bladder
- 16-10** Urethra

### Male Reproductive System

- 17-1** Male Reproductive System
- 17-2** Testis and Seminiferous Tubule
- 17-3** Spermatozoa
- 17-4** Seminiferous Epithelium
- 17-5** Epididymis

## Section 2: Systems

**17-6** Vas (ductus) Deferens

**17-7** Prostate

**17-8** Prostatic Epithelium

**17-9** Seminal Vesicle

**17-10** Urethra and Penis

### **Female Reproductive System**

**18-1** Female Reproductive System

**18-2** Ovaries

**18-3** Ovarian Follicles

**18-4** Corpus Luteum

**18-5** Uterine (fallopian) Tubes

**18-6** Uterus

**18-7** Endometrium

**18-8** Uterine Cervix

**18-9** External Genitalia and Vagina

**18-10** Placenta

**18-11** Umbilical Cord

**18-12** Mammary Gland

### **Eye and Adnexa**

**19-1** Eyeball

**19-2** Cornea

**19-3** Iris

**19-4** Lens

**19-5** Ciliary Body

## Section 2: Systems

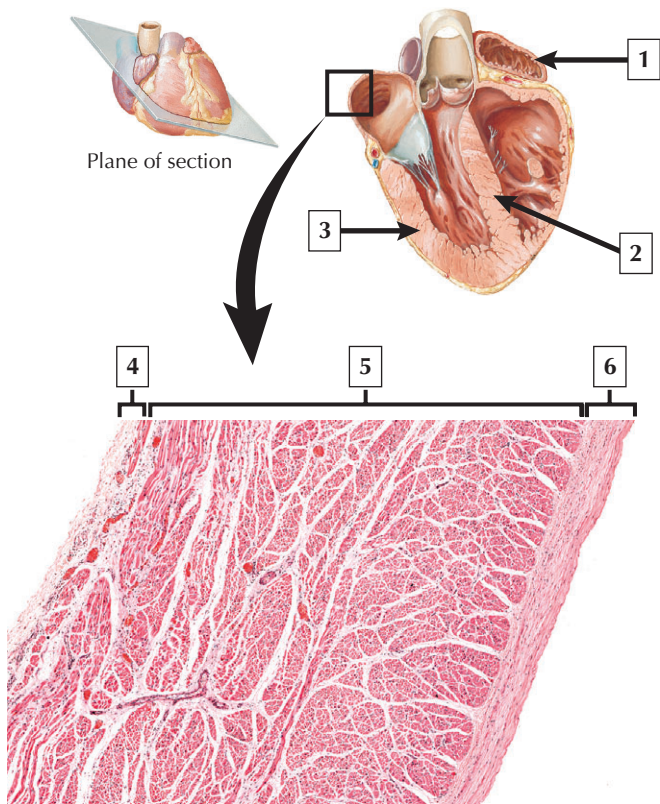
- 19-6** Canal of Schlemm and Aqueous Humor
- 19-7** Retina
- 19-8** Photoreceptors
- 19-9** Retinal Pigment Epithelium
- 19-10** Eyelid
- 19-11** Lacrimal Gland

### Special Senses

- 20-1** Ear
- 20-2** External Acoustic Meatus
- 20-3** Middle Ear and Auditory Tube
- 20-4** Cochlea
- 20-5** Organ of Corti
- 20-6** Vestibular Receptors
- 20-7** Olfactory Mucosa
- 20-8** Taste Buds
- 20-9** Merkel Cells
- 20-10** Cutaneous Receptors
- 20-11** Carotid Body and Carotid Sinus
- 20-12** Muscle Spindles
- 20-13** Muscle and Joint Receptors



This page intentionally left blank



# Atrium

---

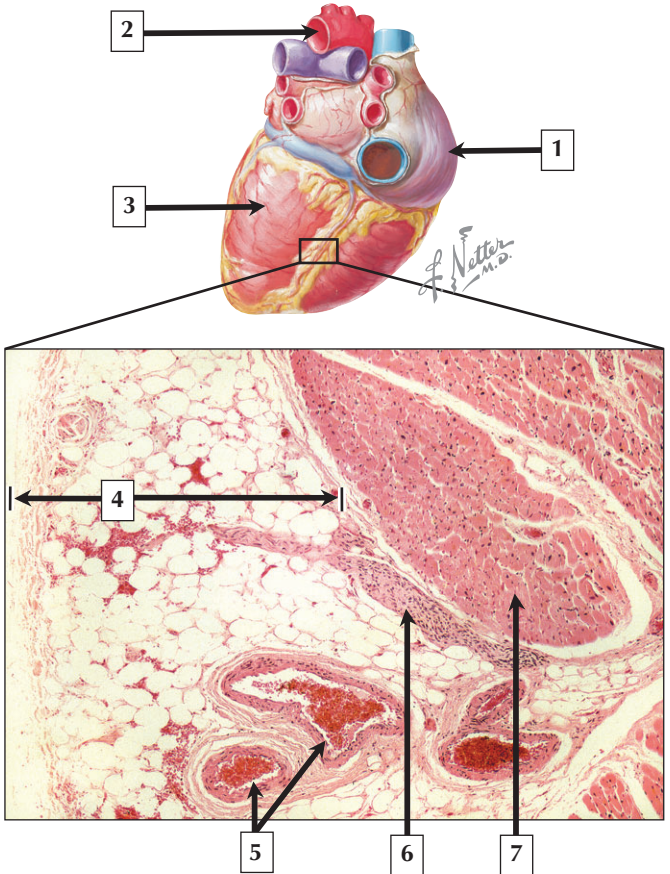
1. Right atrium
2. Interventricular septum (myocardium)
3. Left ventricle (myocardium)
4. Epicardium
5. Myocardium
6. Endocardium

**Comment:** The heart is a 4-chambered muscular pump that distributes blood through a series of closed vessels in the body. It has 2 atria and 2 ventricles, which contain 3 basic tunics in their walls—the innermost endocardium, middlemost myocardium, and outermost epicardium. The endocardium consists of a lining endothelium and an underlying layer of connective tissue. The myocardium forms the bulk of the heart wall and is composed of cardiac muscle. The myocardium is much thicker in the ventricles than in the atria, which reflects differences in the workload of the heart chambers. The epicardium consists of loose fatty connective tissue covered externally by a mesothelium.

The **cardiovascular system** is the first to develop and begin functioning in the embryo, signifying the importance relative to other systems. **Congenital heart defects**, ranging from minor to severe, are the most common anomalies at birth. They include **septal** and **valve defects**, or **transposition of the great vessels**.

*Schematic of heart cut open and LM of atrial wall*

# Heart Wall and Pericardium



# Heart Wall and Pericardium

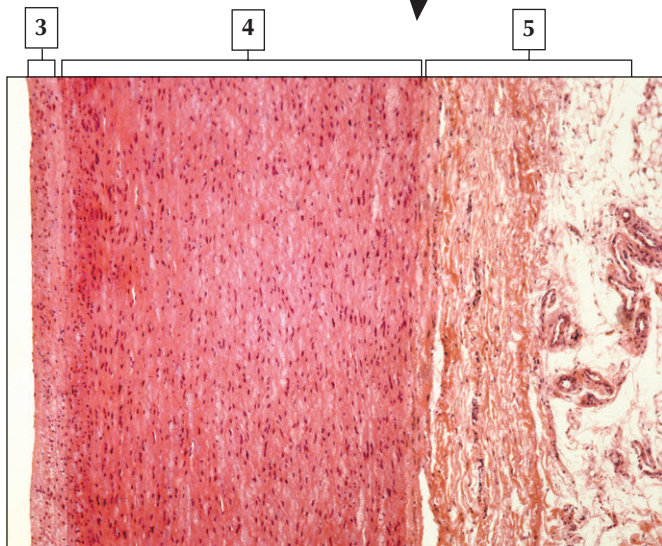
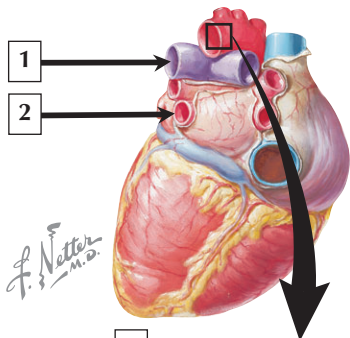
---

1. Right atrium
2. Aorta
3. Left ventricle
4. Epicardium (Visceral pericardium)
5. Coronary blood vessels: arteriole and venule
6. Nerve fibers
7. Cardiac muscle

**Comment:** The epicardium, also known as visceral pericardium, consists of 2 layers. A deep layer of loose, fatty, connective tissue functions as a shock absorber to support the branches of the coronary arteries, veins lymphatics, nerve fascicles, and ganglia within the epicardium. On the surface, a covering epithelium consisting of simple squamous to cuboidal mesothelial cells resting on a basal lamina serves to protect and lubricate the heart surface. These cells resemble mesothelial cells that line the pleural and peritoneal cavities, and are mainly secretory. The heart is suspended in a fibroelastic, fluid-filled pericardial sac made of a parietal pericardium that reflects onto the heart surface as the visceral pericardium.

**Pericarditis** is an inflammation of the thin mesothelial cell lining of the pericardial surfaces. It is commonly characterized by sharp pain behind the sternum or in the neck or left shoulder and, if left untreated, can lead to accumulation of fluid within the pericardial sac and **cardiac tamponade**. A **pericardiocentesis** can be performed to aspirate the fluid from the pericardial cavity.

*Schematic of the posterior aspect of the heart, and LM of the epicardial region of the ventricle*



# Aorta

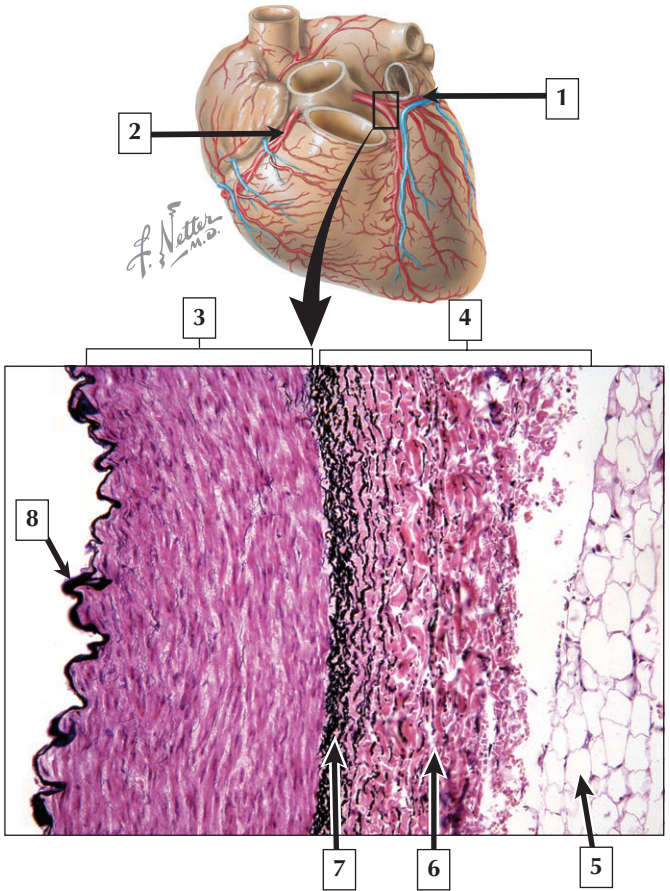
---

1. Left pulmonary artery
2. Left inferior pulmonary vein
3. Tunica intima
4. Tunica media
5. Tunica adventitia

**Comment:** Elastic arteries conduct blood from the heart to the muscular arteries. They have a large lumen relative to the thickness of their walls. The media constituting the wall of these vessels is the most prominent of the 3 layers. It has an abundance of elastic fibers organized as multiple, concentric, and fenestrated laminae, which are interspersed by scattered, circularly arranged smooth muscle cells. The intima of the elastic artery is relatively thick and makes up as much as 20% of the thickness of its wall. The luminal surface is lined internally by an endothelium made of flattened cells resting on a basal lamina. A deeper, subendothelial layer of connective tissue consists mostly of a mixture of collagen and elastic fibers in ground substance.

An **aneurysm** is an abnormal localized dilatation in the weakened wall of an artery. In the aorta, an aneurysm occurs when the diameter of a portion of this vessel has increased by 50% or more. A **true aneurysm** develops when all 3 tunics create a large bulge in the aortic wall. When rupture occurs, fatal bleeding may ensue within a few minutes. **Atherosclerosis** is a major cause of most aortic aneurysms.

*LM of part of the aortic wall and schematic of the posterior aspect of the heart*





## Coronary Artery

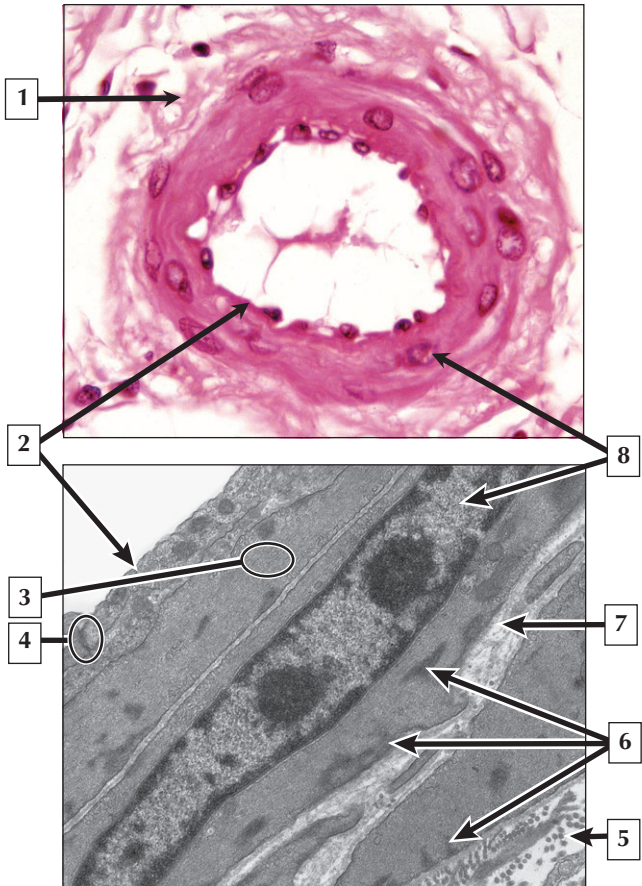
---

1. Circumflex branch of left coronary artery
2. Right coronary artery
3. Tunica media
4. Tunica adventitia
5. Adipocyte (adipose tissue)
6. Collagen
7. External elastic lamina
8. Internal elastic lamina

**Comment:** Coronary arteries supply oxygenated blood to the cardiac muscle in the myocardium of the heart. From their epicardial location, coronary arteries give rise to arterioles, which supply blood to an extensive network of capillaries in the myocardium. Compared to other muscular arteries, coronary arteries have an extremely thick tunica adventitia rich in collagen, adipose tissue, and elastic fibers. Smooth muscle cells in the media are richly innervated by sympathetic nerves.

Coronary arteries are frequently involved in **atherosclerosis** and **coronary artery disease**, which can lead to ischemia and **myocardial infarction**. Elevated circulating levels of low-density lipoproteins cause damage to arterial endothelium, which leads to the formation of atherosclerotic plaques. Cholesterol laden foam cells are a characteristic feature of plaques—these cells are transformed macrophages and smooth muscle cells.

*Schematic of the sternocostal surface of the heart and LM of the wall of the coronary artery in transverse section (Verhoeff-Van Gieson stain)*



## Arteriole

---

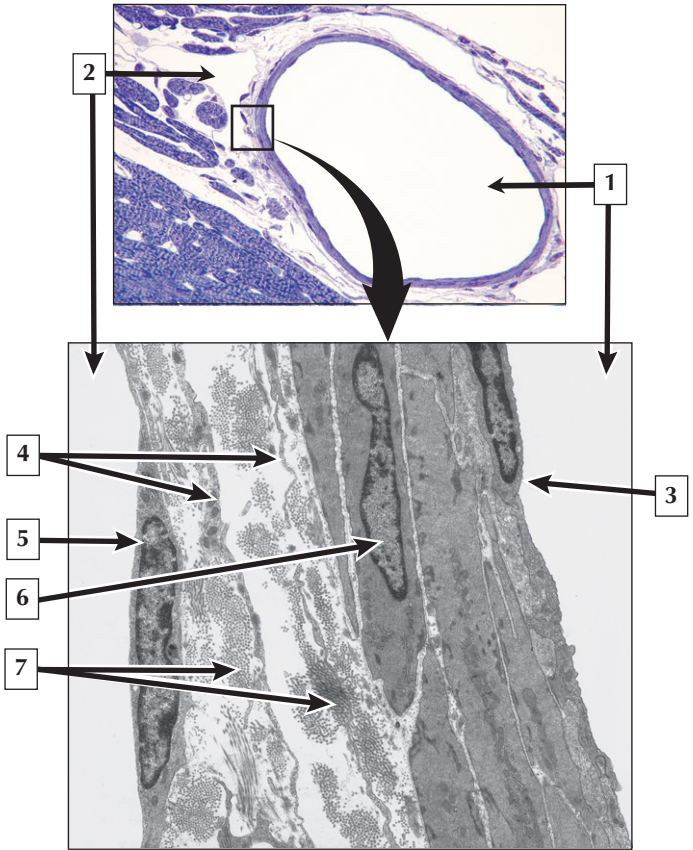
1. Tunica adventitia
2. Endothelium
3. Contractile filaments in smooth muscle cell
4. Intercellular (tight) junction
5. Collagen
6. Dense bodies
7. Basal lamina
8. Nucleus of smooth muscle cell

**Comment:** Arterioles are resistance vessels and are able to undergo vasoconstriction or vasodilatation in response to a variety of neural and non-neural stimuli. They mainly control systemic blood pressure by the action of the smooth muscle in the media. The tunica intima is similar to that of other blood vessels and consists of flattened endothelial cells resting on a thin basal lamina. Vascular smooth muscle cells are found in all blood vessels except capillaries. They perform 2 basic functions in vessel walls. When they contract, they regulate the caliber of the lumen, causing vasoconstriction. Smooth muscle cells also produce the elastic tissue in arterial walls as well as other connective tissue components of the extracellular matrix, such as collagen fibers and ground substance.

A **thrombus**, or **blood clot**, can either reduce or completely block the flow of blood through a blood vessel. **Atherosclerotic plaques** in the tunica intima of the blood vessel can trigger the development of thrombi.

*LM of an arteriole and EM of the wall of an arteriole*

# Arteriole and Venule



## Arteriole and Venule

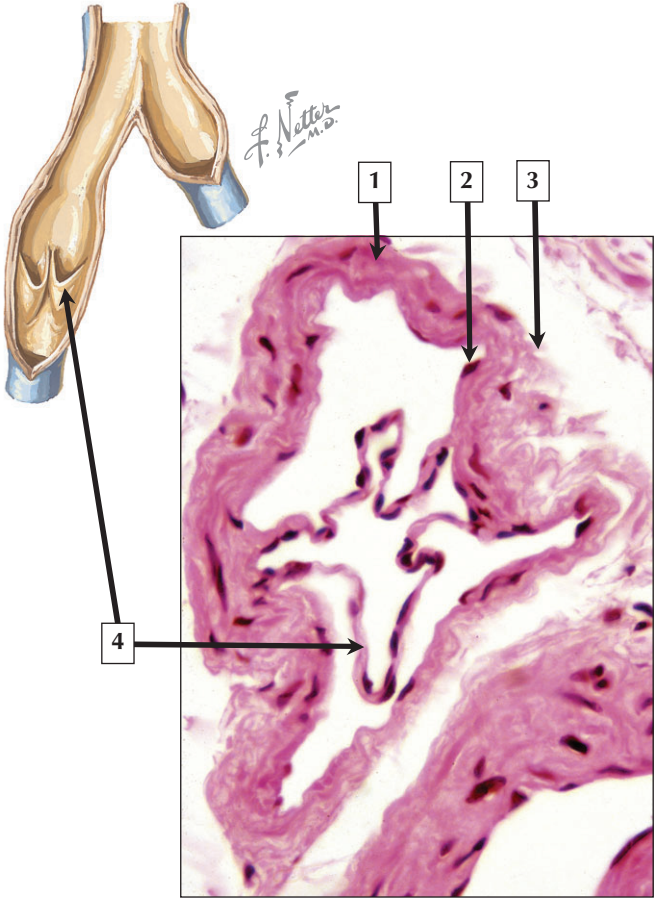
---

1. Lumen of arteriole
2. Lumen of venule
3. Endothelial cell of arteriole
4. Fibroblast processes
5. Endothelial cell nucleus
6. Smooth muscle cell nucleus
7. Collagen

**Comment:** Since arterioles and venules travel close together, obtaining views of them in the same section is common. Both vessels are lined by a continuous endothelium, although the endothelium of venules is generally looser than that of arterioles. The wall of the venule is also thinner than that of its companion arteriole. Due to intraluminal pressure differences, venules often appear collapsed in section and with an irregular contour, whereas arterioles usually appear as circular profiles due to the relatively high elastin content in their walls. Smooth muscle is the distinguishing feature of arterioles consisting of 1 to 2 layers of closely packed and helically arranged smooth muscle cells.

**Chronic elevation of blood pressure, or hypertension,** is a condition that can lead to cardiac hypertrophy, atherosclerosis, heart attack, or stroke. In **essential hypertension,** the activity of phospholipase C, a critical membrane-associated effector enzyme in growth factor and vasoconstrictor signaling, is enhanced in vascular smooth muscle cells.

*LM and EM of an arteriole and venule in transverse section*



## Small Vein

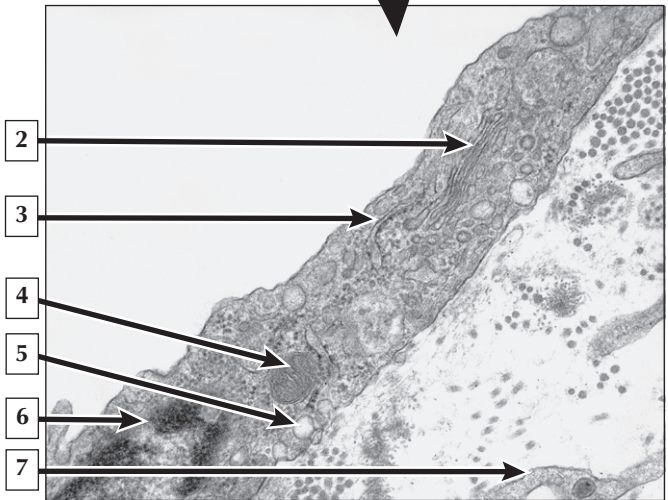
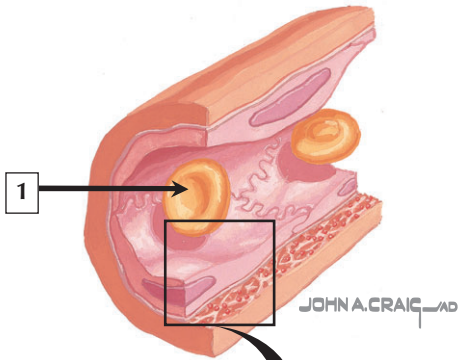
---

1. Tunica media
2. Endothelium
3. Tunica adventitia
4. Leaflet of a venous valve

**Comment:** Valves are a characteristic feature of small and medium-sized veins, particularly those in the lower extremity. They prevent the backflow of blood on its return to the heart against the force of gravity. They are local infoldings of the tunica intima that form semilunar folds that project into the lumen in the direction of blood flow. Valves are usually arranged in pairs, or bicuspid leaflets, and are commonly found just distal to where minor venous tributaries join to form larger veins. Each leaflet is covered externally by a thin endothelium that is continuous with the lining of the vessel and is reinforced internally by a thin core of connective tissue consisting of a mixture of collagen and elastic fibers.

**Varicose veins** are abnormally dilated and tortuous veins that occur when the valves become weakened and incompetent. Those most commonly affected are the superficial veins of the upper and lower parts of the legs. Varicose veins may also develop in the esophagus as a result of cirrhosis of the liver or in the hemorrhoidal venous plexus at the recto-anal junction.

*Schematic of a venous valve and LM of a small vein and its valve in transverse section*





# Endothelium

---

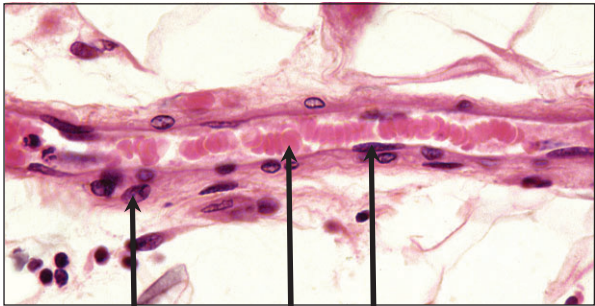
1. Erythrocyte
2. Golgi Complex
3. Rough endoplasmic reticulum
4. Mitochondrion
5. Vesicle
6. Nucleus
7. Fibroblast process

**Comment:** Endothelium is a simple squamous epithelium that lines the entire cardiovascular system. Endothelial cells serve as a selective permeability barrier, regulate hemostasis, and perform many metabolic and secretory functions including secreting prostaglandins and releasing nitric oxide, as well as actively mediating leukocyte adhesion and transmigration. Endothelial cells rest on a thin basal lamina that they secrete and that separates them from surrounding tissues. Ultrastructurally, their attenuated cytoplasm contains a small Golgi complex, scattered free ribosomes, a few mitochondria, and a sparse rough endoplasmic reticulum. Membrane-bounded vesicles and caveolae, measuring 70 to 90 nm in diameter, are numerous.

A defect in the **endothelium nitric oxide system** has been implicated in a number of cardiovascular diseases, especially in **hypertension** and development of **atherosclerosis**. Nitric oxide gas is a bioactive molecule that is an important mediator of vascular dilator tone and blood pressure.

*Schematic and EM of part of a vascular endothelial cell*

# Tight Capillary



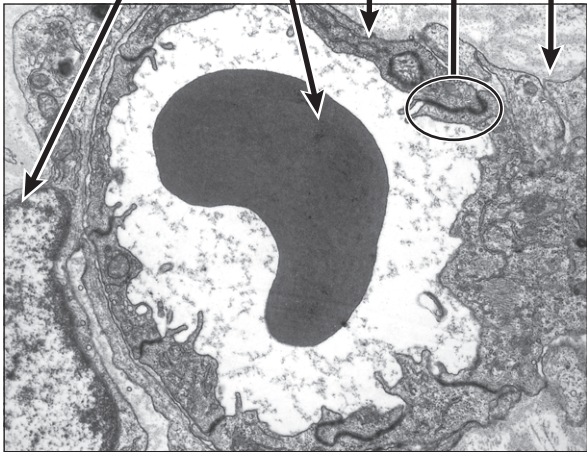
1

2

3

4

5



## Tight Capillary

---

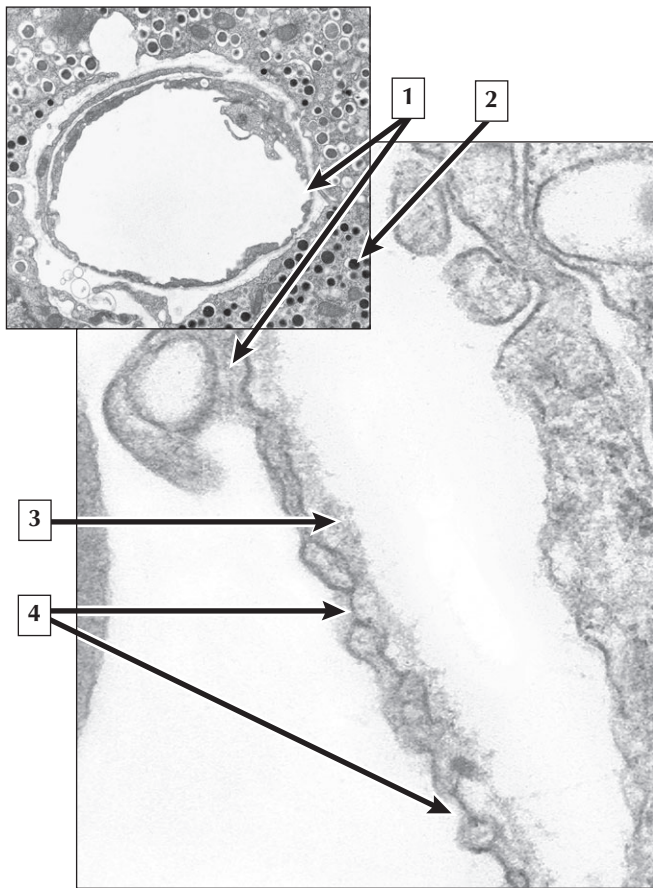
1. Nucleus of pericyte
2. Erythrocyte
3. Endothelial cell
4. Intercellular (tight) junction
5. Basal lamina

**Comment:** Tight capillaries, the most common type of capillary, are found in muscle tissues and in regions where a blood tissue barrier exists. These include the blood-brain barrier, blood-air barrier in the lungs, and the blood-thymus, blood-ocular, and blood-testis barriers. Tight capillaries have an uninterrupted endothelium that selectively restricts the indiscriminate passage of material from capillary lumen to surrounding tissues. Numerous tight junctions, as well as desmosomes and gap junctions, link the endothelial cells in tight capillaries. Although lipids and lipid-soluble molecules, including gases, diffuse freely across the endothelial cell membrane, water-soluble molecules are shuttled across the endothelial cell by small, spherical transcytotic vesicles.

**Pericytes** and their branching processes partially surround capillaries. These mesenchymally derived **pleuripotential stem cells** are able to differentiate into endothelial cells, fibroblasts, or smooth muscle cells in the walls of capillaries and other blood vessels, particularly in response to injury or when stimulated by growth factors.

*LM of a capillary in longitudinal section and EM of a tight capillary in the CNS in transverse section*

## Fenestrated Capillary



## Fenestrated Capillary

---

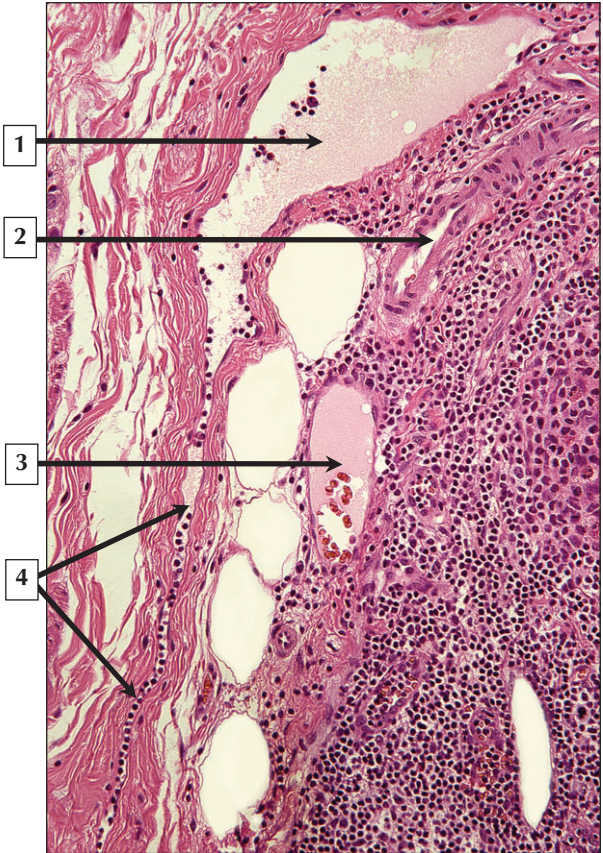
1. Endothelium
2. Secretory granule (dense granule)
3. Basal lamina
4. Fenestrae

**Comment:** Because fenestrated capillaries are highly permeable, they are found in areas engaged in fluid transport and secretion of hormones. They occur mainly in the lamina propria of the intestines, glomeruli of renal corpuscles, choroid plexus of the brain, choriocapillaris of the eye, and all endocrine organs. Although their endothelial cells resemble those of tight capillaries in their content of transcytotic vesicles and other cytoplasmic organelles, their endothelium is extremely thin, often measuring  $0.1\ \mu\text{m}$  or less, and contains numerous fenestrae (60 to 80 nm in diameter) usually spanned by a thin diaphragm. Fenestrae are important to allow the rapid diffusion of fluid and larger molecules (e.g., hormones) from secretory cells to the bloodstream. Glomerular capillaries in the kidney are devoid of diaphragms but are surrounded by a thick basal lamina.

**Membranous glomerulopathy**, the most common **nephrotic syndrome** in Caucasian adults, is characterized by proteinuria and decreased glomerular filtration rate in the kidneys. Accumulation of immune complexes and thickening of the basement membrane in the walls of fenestrated glomerular capillaries are pathologic features of this disease.

*EM of a fenestrated capillary in the endocrine pancreas seen at low and high magnification*

# Lymphatic Vessel



# Lymphatic Vessel

---

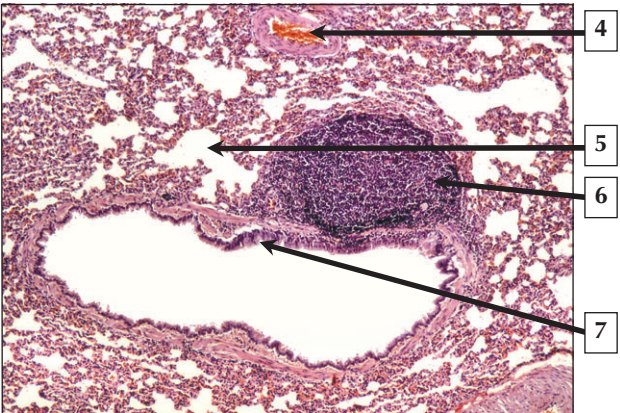
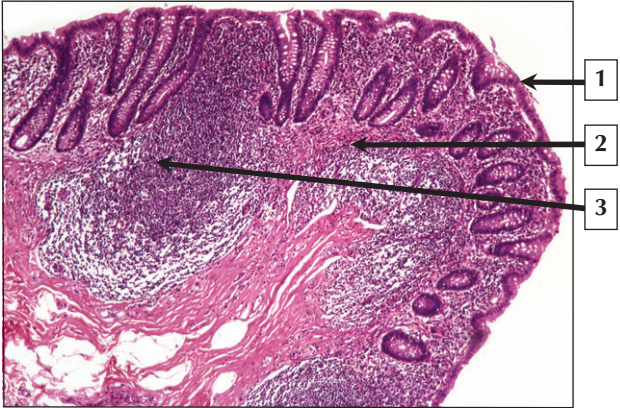
1. Lymphatic channel
2. Arteriole
3. Venule
4. Lymphatic capillary

**Comment:** Lymphatic capillaries are delicate, anastomosing channels. They begin as blind-ended dilatations (10 to 50  $\mu\text{m}$  wide) and are often found close to blood capillaries. They constitute a drainage system. They absorb lymph, which is a protein-rich exudate of blood, as well as electrolytes and water, from the blood capillaries. This fluid normally fills the extracellular connective tissue spaces, and some of it is reabsorbed back into the venous end of blood capillaries. However, excess fluid, together with wandering lymphocytes and other cells, are continually taken up by lymphatic capillaries and eventually added back to the systemic circulation. They thus play a role in homeostasis by regulating interstitial fluid pressure and maintaining plasma volume.

**Lymphedema** is a condition in which protein-rich fluid accumulates in the interstitial spaces of tissues. It often involves the swelling of the extremities and results from blockage of lymphatic vessels. These complications typically occur after lymph node resection, surgical procedures on blood vessels in limbs, and in radiation therapy of lymph nodes to treat cancer.

*LM of a lymphatic capillary in longitudinal section*

# Lymphoid Tissue





# Lymphoid Tissue

---

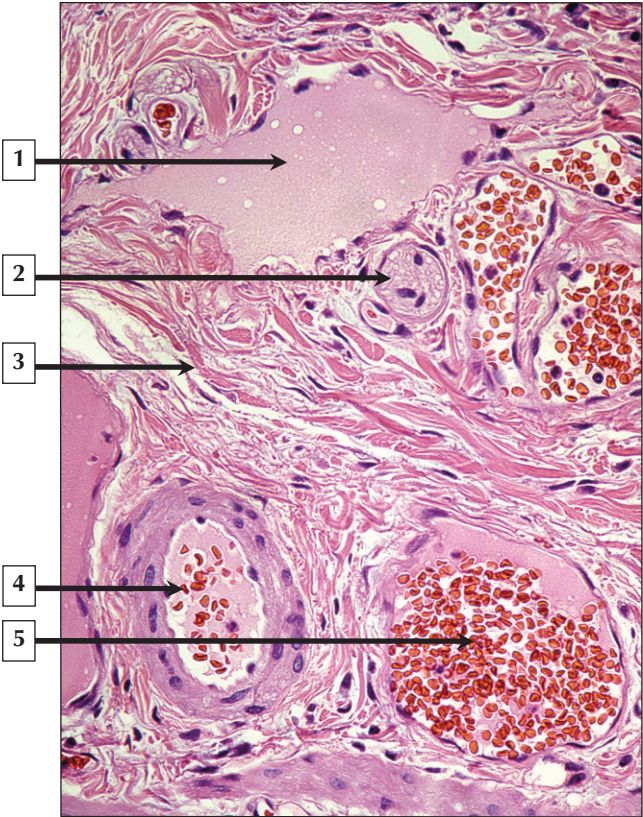
1. Intestinal epithelium
2. Lamina propria
3. Gut-associated lymphatic tissue (GALT)
4. Blood vessel
5. Alveolus of lung
6. Bronchiolar associated lymphatic tissue (BALT)
7. Bronchiolar epithelium

**Comment:** The lymphoid (or immune) system protects the body against the potentially harmful effects of pathogenic organisms, foreign substances, infectious agents (i.e., bacteria and viruses), and abnormal cells. It consists of lymphoid tissues and organs in which the principal constituents are aggregations of lymphocytes and other cells of the mononuclear phagocyte system. Diffuse subepithelial aggregates of lymphocytes are the most ubiquitous and occur throughout the gastrointestinal, respiratory, and genitourinary tracts as mucosa-associated lymphoid tissue. More densely packed, spherical clusters of lymphocytes, known as lymphoid nodules (or follicles), may also be found in these and other sites.

**Rubella**, commonly called **German measles**, is a contagious illness caused by the rubella virus entering the respiratory tract and associated lymphoid tissue. It occurs mainly in children and young adults, and its hallmark is an erythematous maculopapular rash accompanied by fever and swollen lymph nodes.

*LM of appendix and LM of lung bronchiole*

# Lymphatic Vessel



## Lymphatic Vessel

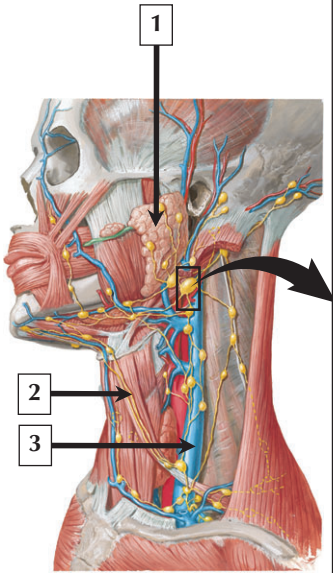
---

1. Lymphatic vessel
2. Nerve fascicle
3. Connective tissue
4. Arteriole
5. Venule

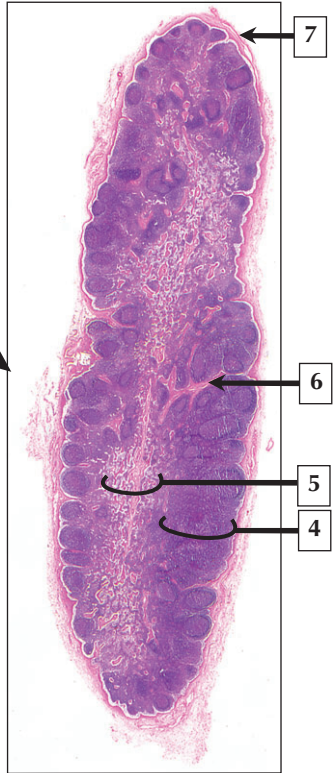
**Comment:** Cells of the lymphoid system are found in connective tissues throughout the body and can travel in the bloodstream or in lymphatic channels—the lymph-draining part of the circulatory system. By light microscopy, they are similar to capillaries and veins. Lymphatic vessels have wide distribution in many, but not all, body regions. Originating as blind-ended channels in connective tissue spaces, they are then thin-walled lymphatic capillaries (100  $\mu\text{m}$  in diameter) that anastomose and become larger. Lymphatic capillaries look similar to blood capillaries except that they lack a basal lamina. Small anchoring filaments connect endothelial cells to adjacent collagen fibers and help prevent vessel collapse. Lymphatic capillaries are most abundant in connective tissue of the skin (dermis); beneath mucous membranes of the respiratory, gastrointestinal, and genitourinary tracts; and in connective tissue spaces of the liver.

**Congenital lymphedema** is an inborn deficit of lymphatic vessels (usually in the lower limbs) that results in accumulation of lymph in the interstitial spaces of tissues. Swelling occurs when the volume of lymph exceeds the flow capacity of vessels.

*LM of a lymphatic vessel, arteriole, venule, and nerve fascicle in transverse section*



*F. Netter M.D.*



## Lymph Node

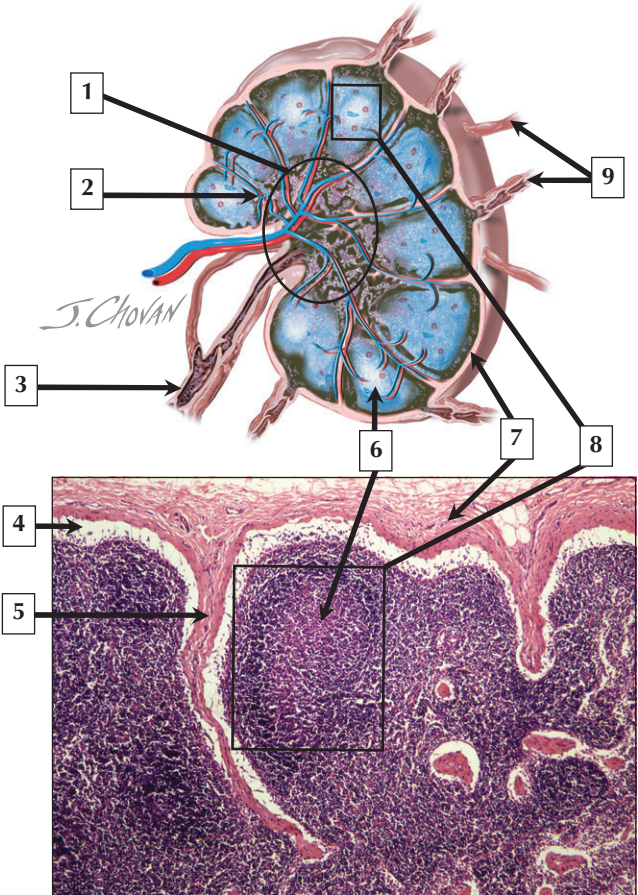
---

1. Parotid Gland
2. Lymphatic vessel
3. Internal jugular vein
4. Cortex
5. Medulla
6. Trabecula
7. Capsule

**Comment:** Lymph nodes are bean- or kidney-shaped lymphoid organs, 2 to 20 mm in diameter; 500 to 600 nodes are found in the body. They are seen along lymphatic vessels, and lymph percolates through them. They occur, often as chains or groups, in strategic regions such as the neck, groin, mesenteries, axillae, and abdomen. The main functions of lymph nodes are filtration of lymph before its return to the thoracic duct; production of lymphocytes that are added to lymph; synthesis of antibodies (mainly IgG); and recirculation of lymphocytes by their selective reentry from blood to lymph across walls of specialized postcapillary venules.

**Adenopathy** is an abnormal enlargement of lymph nodes. It may be due to an increase in lymphocytes and macrophages within the node during antigenic stimulation in a **bacterial** or **viral infection**. It may also be caused by **metastasis**, whereby **neoplastic tumor cells** spread from their local site of development to distant locations.

*Schematic of lymph nodes and vessels and LM of a lymph node*



## Lymph Node

---

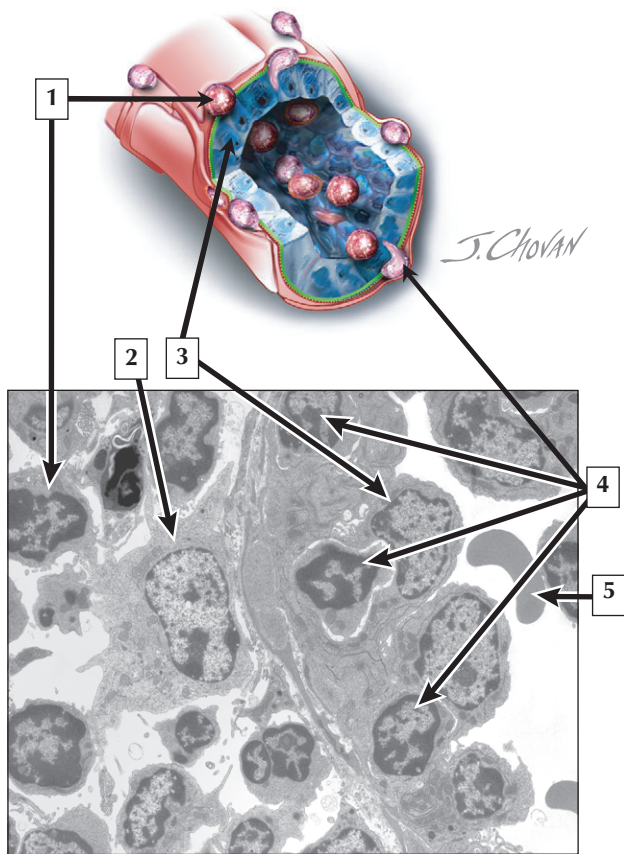
1. Medulla
2. Paracortex
3. Efferent lymphatic
4. Subcapsular sinus
5. Trabecula
6. Germinal center
7. Capsule
8. Lymphoid nodule in cortex
9. Afferent lymphatics

**Comment:** Lymph nodes contain aggregates of lymphocytes organized into an outer cortex, a paracortex, and an inner medulla. The darkly stained cortex just under the capsule consists of lymphoid nodules. B cells occupy lymphoid nodules in the cortex, and T cells are in the paracortex, or thymus-dependent region. An outer capsule of dense fibrous connective tissue that typically merges with surrounding tissues and fat invests each node. It sends delicate, radiating collagen-containing partitions called trabeculae into the interior of the nodes. Afferent lymphatic vessels merge with the capsule and empty into the subcapsular space; the lymph percolates through the sinuses to the medulla, where it is collected by the efferent vessel.

**Lymphomas** are localized lymphocyte malignancies that often form solid tumors, mainly affecting lymph nodes. **Hodgkin disease** is a major type of lymphoma distinguished by the presence of *Reed-Sternberg cells* in lymph nodes.

*Schematic of a lymph node and LM of lymph node cortex*

## High Endothelial Venule





## High Endothelial Venule

---

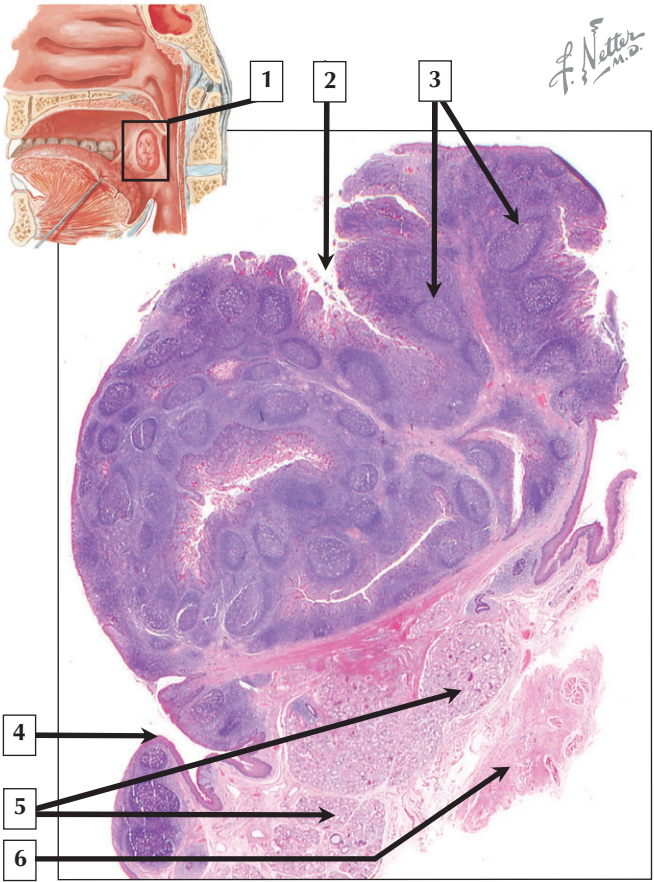
1. Lymphocyte
2. Plasma cell
3. High endothelial cell
4. Lymphocytes in wall of venule
5. Erythrocyte

**Comment:** Since lymphocytes are intrinsically mobile, they can leave the bloodstream by preferential migration across the walls of specialized blood vessels called high endothelial venules (HEVs). These vessels are located in the paracortical zone of the lymph node. They are 30 to 50  $\mu\text{m}$  in diameter and are specialized for the passage, by selective diapedesis, of B cells and T cells from the blood into perivascular areas. HEVs possess cell adhesion molecules on their endothelial cells, which facilitate a highly specific transmigration of T and B cells. They squeeze between adjacent endothelial cells of HEVs and penetrate the underlying basement membrane. On gaining access to the surrounding lymphoid parenchyma, T cells typically remain in the paracortex, whereas B cells migrate to lymphoid nodules.

**Human immunodeficiency virus (HIV)** is an RNA retrovirus that can infect CD4+ helper T cells and macrophages expressing CD4 surface marker. HIV infection, a chronic infectious disease, can cause a broad spectrum of clinical manifestations, ranging from an asymptomatic carrier state to **AIDS**, or **acquired immunodeficiency syndrome**.

*Schematic and EM of a high endothelial venule in a lymph node*

*F. Netter M.D.*



# Tonsil

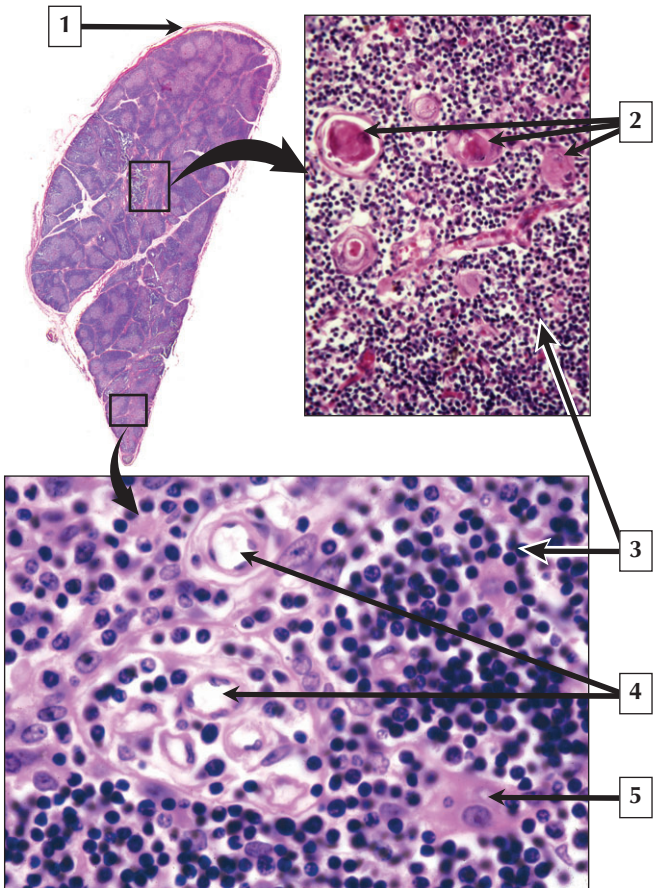
---

1. Palatine tonsil
2. Tonsillar crypt
3. Lymphoid nodules
4. Surface epithelium
5. Mucous gland
6. Connective tissue

**Comment:** Tonsils are discrete aggregates of lymphoid nodules under the epithelium-lining entrances to the digestive and respiratory tracts. They can be seen with the naked eye as 3 separate masses. In the wall of the oropharynx lies a bilateral pair of palatine tonsils. At the base of the tongue sit 2 lingual tonsils, and 1 pharyngeal tonsil is in the posterior part of the nasopharynx. These tonsils together form a prominent ring of strategically located lymphoid tissue called Waldeyer's ring. The tonsils are partly encapsulated structures that lack afferent lymphatic vessels but are drained by efferent lymphatic channels.

**Tonsillitis**, or inflammation of the tonsil, is especially common in children, and it often accompanies pharyngitis. It results from either a **bacterial infection**, such as that caused by **Streptococcus**, or a **viral infection**, such as that caused by the **Epstein Barr virus**.

*Schematic of oral cavity and pharynx and low-magnification LM of the palatine tonsil*



# Thymus

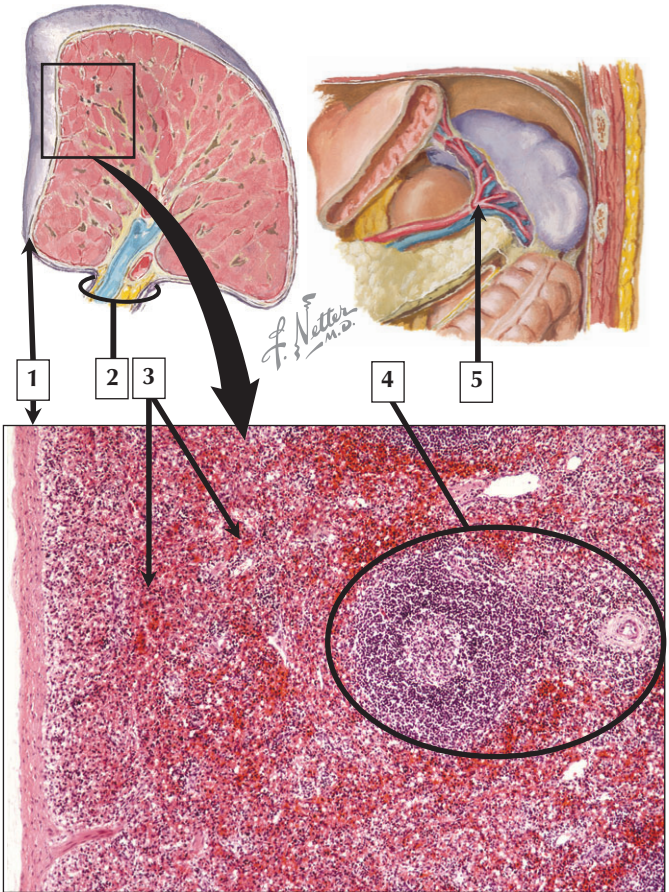
---

1. Capsule
2. Hassal's corpuscles
3. Lymphocytes
4. Capillaries
5. Epithelial reticular cell

**Comment:** The thymus gland is a flat, bilobed primary lymphoid organ found in the anterior mediastinum of the thorax, behind the upper part of the sternum. It weighs 12 g to 15 g at birth and reaches maximal size, up to 30 g to 40 g, at puberty. After puberty, it undergoes involution (or atrophy) with slow replacement of its lymphoid parenchyma by adipose connective tissue. During fetal development, immature lymphocytes from mesenchyme-derived bone marrow migrate among epithelial reticular cells in the outer cortex of the thymus to become pre-T lymphocytes that make up thymic parenchyma. The cortex contains mainly small lymphocytes that are so densely and uniformly packed that they often obscure the epithelial reticular cells. The main function of the thymus is antigen-independent maturation of T lymphocytes.

**DiGeorge syndrome**, also known as **thymic aplasia**, is a rare congenital disorder involving failure of the thymus to develop properly. The syndrome is due to a defect on chromosome 22, and selective T cell deficiency leads to **immunodeficiency** with **recurrent opportunistic infections**.

*Low-magnification LM of thymus and high-magnification LMs of medulla and cortex*



# Spleen

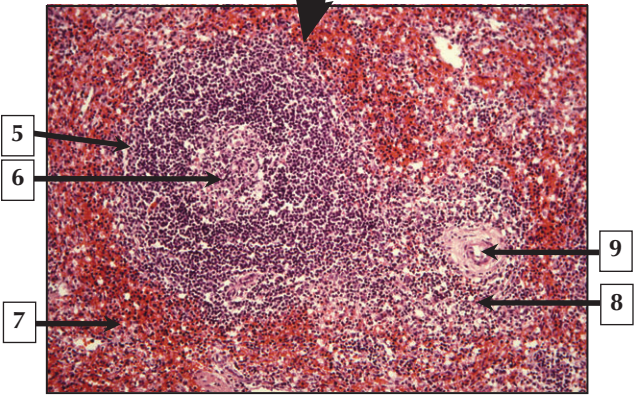
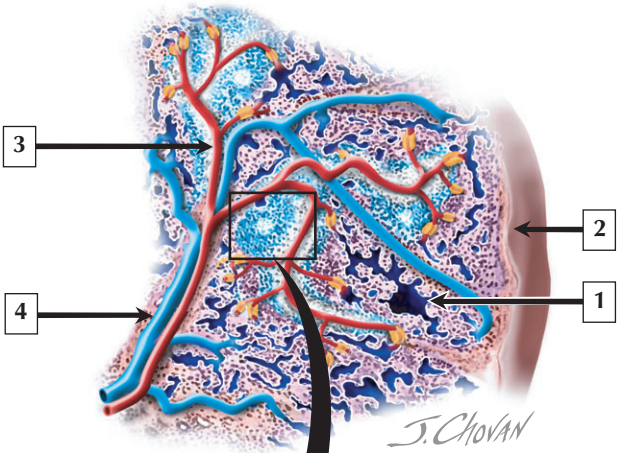
---

1. Capsule
2. Hilum
3. Red pulp
4. White pulp
5. Splenic artery

**Comment:** The spleen lies in the upper left quadrant of the abdomen, behind the stomach and just below the diaphragm. In adults, this largest lymphoid organ is the size of a clenched fist and weighs 180 g to 250 g. At the hilum on the medial surface, the splenic artery and nerves enter and the splenic vein and lymphatics leave. The spleen is a major repository for mononuclear phagocytic cells, accounts for 25% of the total number of lymphocytes, and stores about a third of the body's platelets. The organ filters blood by clearing particulate matter, infectious organisms, and aged or defective erythrocytes and platelets. It recycles iron from worn-out erythrocytes. Primarily macrophages perform these functions. The spleen is also a secondary lymphoid organ: lymphocytes respond to blood-borne antigens by initiating an immune reaction that activates T and B cells.

**Splenomegaly**, or abnormal enlargement of the spleen, is caused by many clinical conditions. A common cause is **portal hypertension** resulting from **cirrhosis** of the liver. The spleen of affected patients is modestly enlarged, weighing 300 g to 800 g, and the capsule becomes thick and fibrotic.

*Schematics of spleen and low-magnification LM of spleen*





## White Pulp

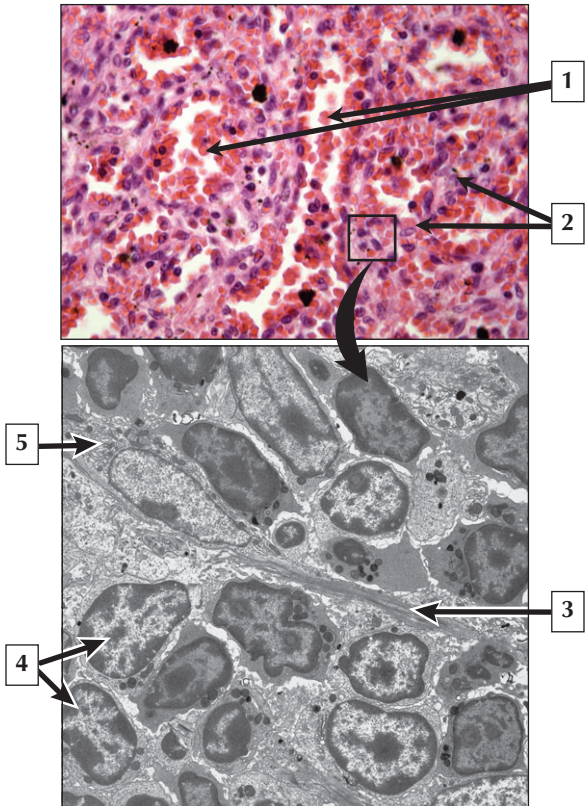
---

1. Venous sinus
2. Capsule
3. Trabecular artery
4. Trabecular vein
5. Secondary lymphoid nodule
6. Germinal center
7. Red pulp
8. Periarteriolar lymphatic sheath
9. Central arteriole

**Comment:** The spleen is covered by an outer dense irregular connective tissue capsule, which sends radiating trabeculae into the organ's interior. Unlike other lymphoid organs, the spleen does not have a cortex and medulla. It consists of white pulp and red pulp, so named because of their color in the fresh state. White pulp is made of grayish white islands of lymphoid tissue, most surrounding a central arteriole to form periarteriolar lymphatic sheaths (PALS). Associated with PALS are occasional lymphoid nodules with germinal centers that seem to push arterioles to an eccentric location.

**Splenectomy**, or removal of the spleen, is used as therapy for some chronic disorders or an emergency procedure for traumatic rupture of the spleen. Splenectomy in adults usually has no clinical consequence, but in children it leads to increased occurrence and severity of infections.

*Schematic of splenic circulation and LM of white pulp in spleen*



## Red Pulp

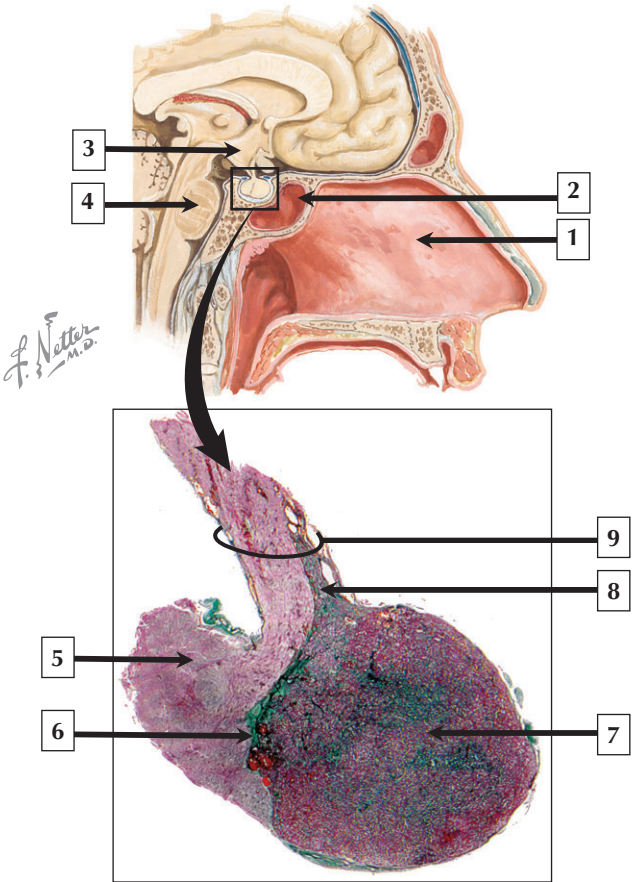
---

1. Venous sinuses
2. Splenic cords
3. Reticular fibers
4. Lymphocytes
5. Reticular cell

**Comment:** Red pulp constitutes most of the spleen, its color being due mostly to abundant erythrocytes. Found around white pulp, it consists of many thin-walled venous sinusoids and intervening cellular, or splenic, cords (of Billroth). The term splenic cords is misleading, in that these are labyrinthine spaces between sinusoids containing a scaffold of reticular fibers. Many closely packed fixed or wandering cells—reticular cells, lymphocytes, plasma cells, macrophages, and all formed elements of circulating blood—occupy these spaces. Venous sinusoids are a tortuous network of thin-walled vessels with irregular lumina. With diameters of 30 to 50  $\mu\text{m}$ , they have a unique structure related to high permeability. They are made of spindle-shaped, longitudinally oriented endothelial cells.

During early fetal development, the spleen is temporarily an organ of **hematopoiesis**. This role is taken over by the liver and then bone marrow. However, in severe cases of **anemia** or **myeloproliferative disorders** in children and adults, the spleen may produce new blood cells, a condition referred to as **extramedullary hematopoiesis** (occurs outside of the bone marrow).

*LM of red pulp in spleen and EM of a splenic cord*



## Pituitary

---

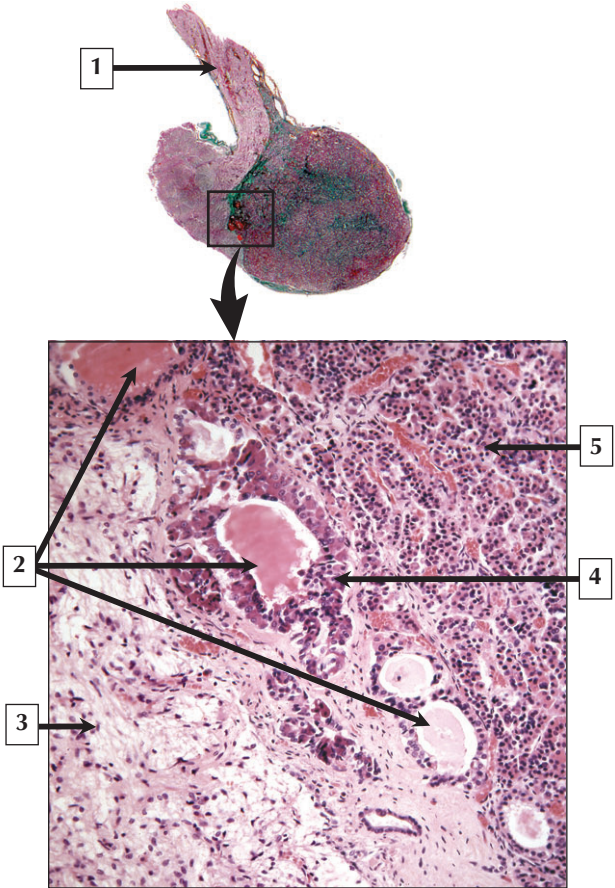
1. Nasal septum
2. Sphenoid sinus
3. Hypothalamus
4. Brain stem (pons)
5. Posterior lobe
6. Intermediate lobe
7. Anterior lobe
8. Tuberalis
9. Infundibular stalk

**Comment:** The pituitary gland is often called the “master” endocrine gland because its secreted hormones directly or indirectly control growth, differentiation, and functions of many tissues and organs in the body. Shaped like a flattened pea or grape, it weighs 500 to 900 mg in the adult and lies in a midline depression of the sphenoid bone called the sella turcica. It is connected to the hypothalamus of the brain by the infundibular stalk. In general, the pituitary is divided into an anterior and a posterior portion, which are derived from oral and neural ectoderm, respectively.

**Pituitary tumors** can be either secretory or nonsecretory **adenomas**. One type of secretory adenoma causes **acromegaly** in adults and **gigantism** in children. It is due to an overproduction of growth hormone. Another type of adenoma causes **Cushing disease**—an excess of adrenocorticotropic hormone—that leads to overproduction of cortisol by the adrenal glands.

*Schematic showing anatomy and relations of pituitary gland and survey LM of pituitary (Masson trichrome stain)*

# Intermediate Lobe



## Intermediate Lobe

---

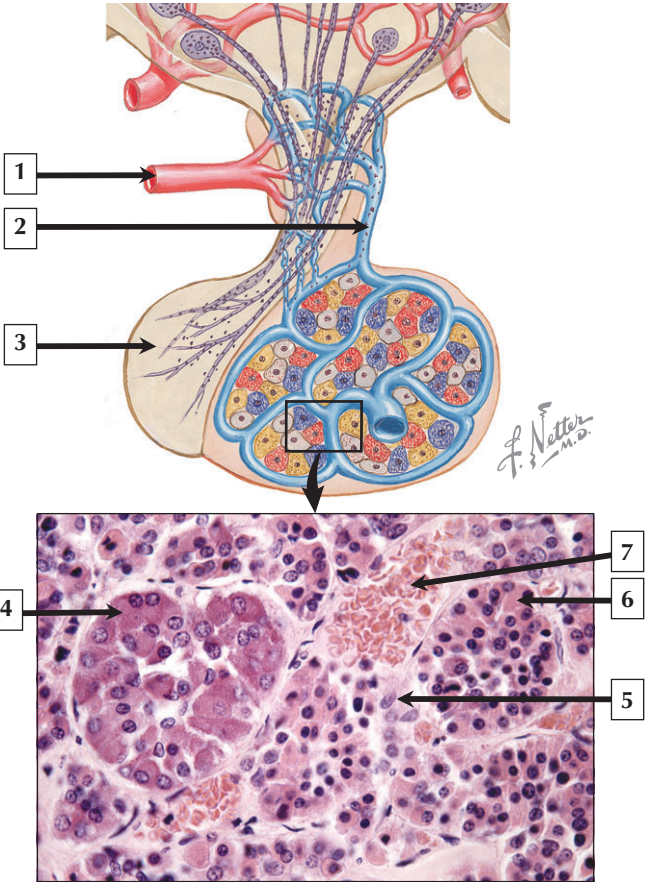
1. Infundibular stalk
2. Colloid-filled cysts (Rathke's cysts)
3. Posterior lobe
4. Intermediate lobe
5. Anterior lobe

**Comment:** At the junction between the anterior and posterior lobe, the contrasting histologic structure is evident at low magnification. The anterior lobe is a glandular epithelium, which appears darkly stained because its nucleated parenchymal cells are numerous and tightly packed. Conversely, the posterior lobe is more lightly stained because it is made of nervous tissue. In the region of the intermediate lobe, rudiments of Rathke's pouch persist as accumulations of small colloid-filled cysts at the border with the posterior lobe. The intermediate lobe constitutes less than 2% of the pituitary in the adult human. Basophilic cells from the intermediate lobe often invade the pars nervosa. Cells of the intermediate lobe produce melanocyte-stimulating hormone and the opiate peptide, beta-endorphin.

**Rathke's cyst** (a rudiment of Rathke's pouch) is an epithelial-lined cyst that may become symptomatic due to enlargement and compression of the pituitary gland or stalk, optic chiasm, or hypothalamus. It is usually benign, ranging in size from 2 to 4 cm, and can be removed by microsurgical methods.

*Survey LM of pituitary and LM showing the 3 lobes of the pituitary at low magnification*

# Anterior Pituitary





## Anterior Pituitary

---

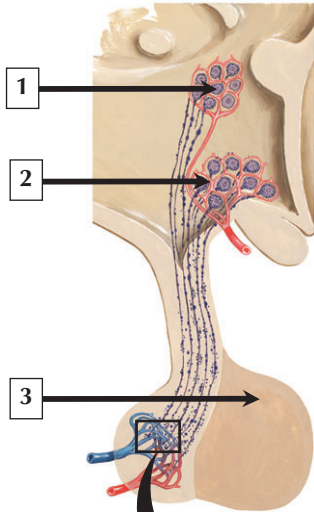
1. Superior hypophyseal artery
2. Hypophyseal portal vein
3. Posterior lobe
4. Basophil
5. Chromophobe
6. Acidophil
7. Sinusoidal capillary

**Comment:** The anterior lobe of the pituitary gland contains clumps or cords of glandular epithelial cells that secrete hormones into a network of sinusoidal capillaries with large or irregular lumina, all of which is supported by a delicate reticular fiber stroma. Glandular epithelial cells can be classified into chromophils (which are large, possess secretory granules, and stain intensely), and chromophobes (which are smaller and stain faintly). Chromophils are subdivided into acidophils and basophils. In routine stains, the proportion of glandular cell types has been estimated to be about 40% acidophils, 10% basophils, and 50% chromophobes. More precise identification of cell types by immunocytochemistry has made it possible to identify their hormone content.

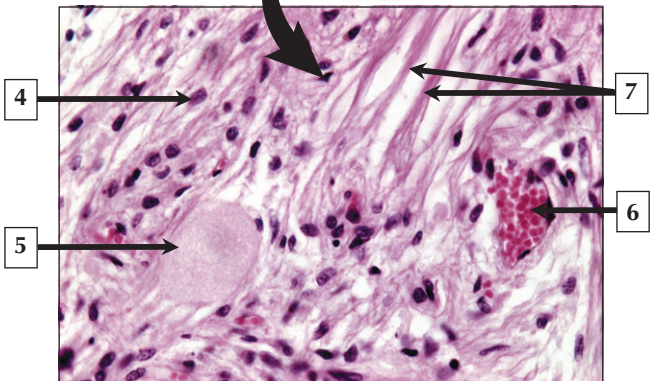
**Transphenoidal microsurgery** is a commonly used technique to remove small pituitary tumors confined to the sella turcica. The sphenoid air sinus lies inferior and anterior to the pituitary, which can be accessed through the nasal cavity and sinuses.

*Schematic of pituitary gland and LM of the anterior lobe*

# Posterior Pituitary



*F. Netter M.D.*



## Posterior Pituitary

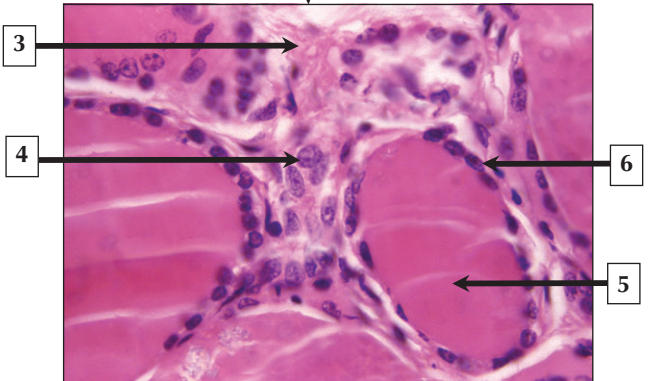
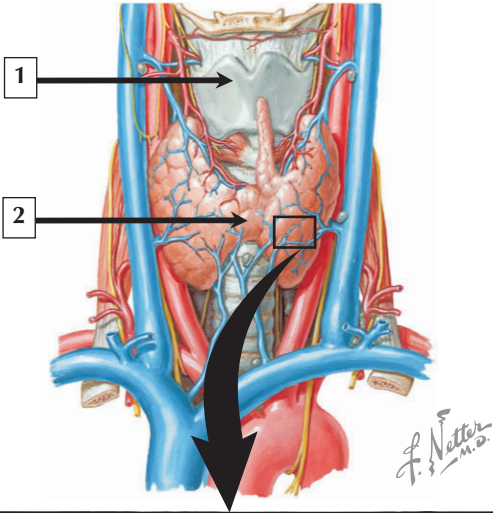
---

1. Paraventricular nucleus
2. Supraoptic nucleus
3. Anterior lobe
4. Pituicyte
5. Herring body
6. Sinusoidal capillary
7. Axon bundles of hypothalamo-hypophyseal tract

**Comment:** The two peptide hormones released in the posterior lobe of the pituitary are oxytocin and antidiuretic hormone (also known as vasopressin). Synthesized in the supraoptic and paraventricular nuclei of the hypothalamus, these peptides are conveyed by axoplasmic transport in the hypothalamo-hypophyseal tract to the pars nervosa and are stored in Herring bodies. Here, in response to arrival of an action potential, they are discharged by exocytosis of neurosecretory granules directly to thin-walled sinusoidal capillaries with fenestrae.

Damage to the supraoptic and paraventricular nuclei of the hypothalamus or destruction of the hypothalamo-hypophyseal tract may interfere with the production of antidiuretic hormone, leading to the rare condition known as **diabetes insipidus**. It is characterized by **polyuria** whereby copious amounts (15 to 20 L) of hypotonic urine are produced daily, and **polydipsia**, or extreme thirst, with a tendency to drink large quantities of fluid.

*Schematic of hypothalamo-hypophyseal tract and LM of the posterior lobe*



# Thyroid

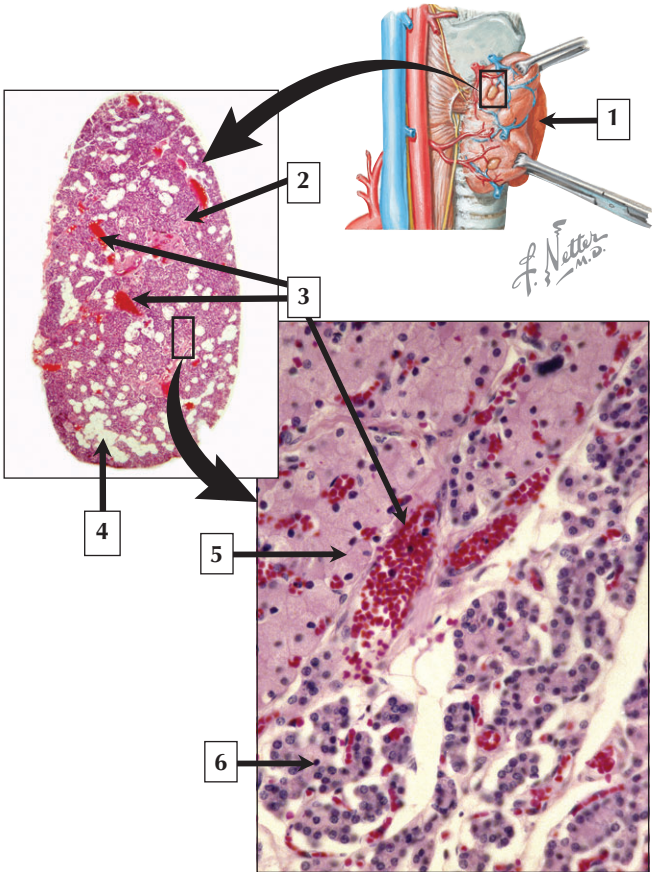
---

1. Thyroid cartilage
2. Isthmus of thyroid gland
3. Stroma
4. Parafollicular (C) cell
5. Colloid in thyroid follicle
6. Follicular cell

**Comment:** The thyroid lies in the lower part of the front of the neck in contact with the upper part of the trachea. It consists of 2 lobes and a connecting isthmus, with the right lobe often twice as large as the left. Each is the size of a flattened chestnut. The glandular parenchyma contains spherical follicles of varying size (50 to 500  $\mu\text{m}$  in diameter). Their total number may exceed 20 million. The lumen of each follicle is filled with a thyroglobulin-containing gelatinous colloid. Follicles are lined by a simple cuboidal epithelium that varies in height with functional activity. Small numbers of larger and paler parafollicular (C) cells are situated between the basement membrane of the follicles and the follicular cells, and lie singly or in small groups among the follicular cells. They can also be present in an interfollicular position.

**Goiter**, a nonspecific term for chronic enlargement of the thyroid, may occur in various diseases of this organ. **Hyperthyroidism** results in many thyroid diseases, the most common being exophthalmic goiter (or **Graves' disease**). This is an autoimmune disorder caused by antibodies to the thyroid-stimulating hormone (TSH) receptor on follicular cells.

*Schematic of the thyroid and LM of part of the thyroid*



## Parathyroid

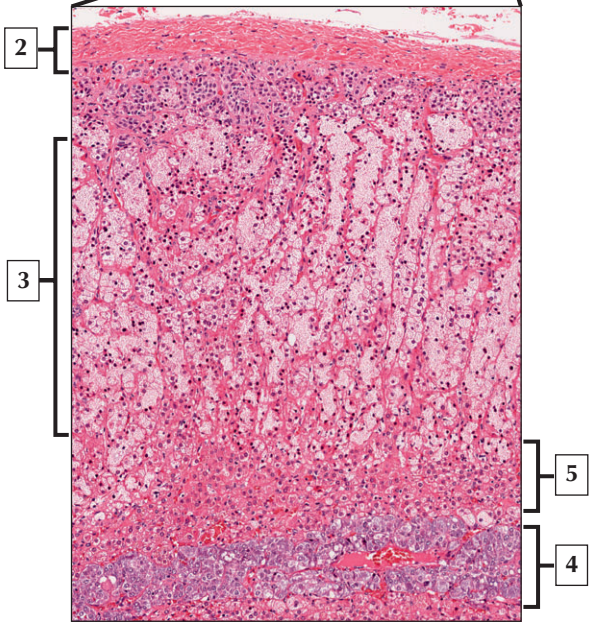
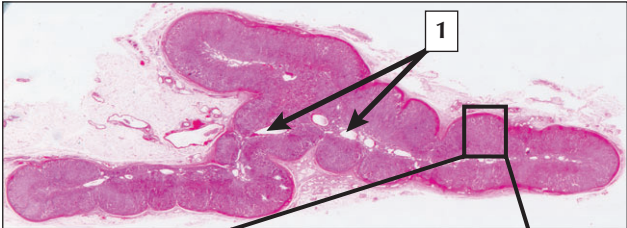
---

1. Right lobe of thyroid gland
2. Trabecula
3. Blood vessels
4. Fat cells (adipocytes)
5. Oxyphil
6. Chief cell

**Comment:** The parathyroid synthesizes and secretes parathyroid hormone (PTH), which maintains calcium levels in the blood by increasing the rate of osteoclastic activity, thereby mobilizing calcium from bone. The parenchyma is composed of 2 types of cells in the adult—chief cells and oxyphils. Chief cells are more numerous, whereas oxyphils appear after the first decade of life. Chief cells are polyhedral in shape and slightly eosinophilic. They form irregular, anastomosing cords supported by delicate connective tissue. They are the source of PTH and have features of other endocrine secretory cells, being closely related to an extensive network of surrounding capillaries. Oxyphils are larger, more acidophilic cells, which are irregularly distributed and occur singly or in clumps. They are thought to be nonsecretory cells.

**Primary hyperparathyroidism** is usually caused by an **adenoma** of 1 or more parathyroid glands. These tumors are composed of tightly packed sheets of predominantly chief cells, which are interspersed with multinuclear giant cells.

*Schematic of parathyroid location (right lateral view) and low- and medium-magnification LMs of the parathyroid*





## Adrenal

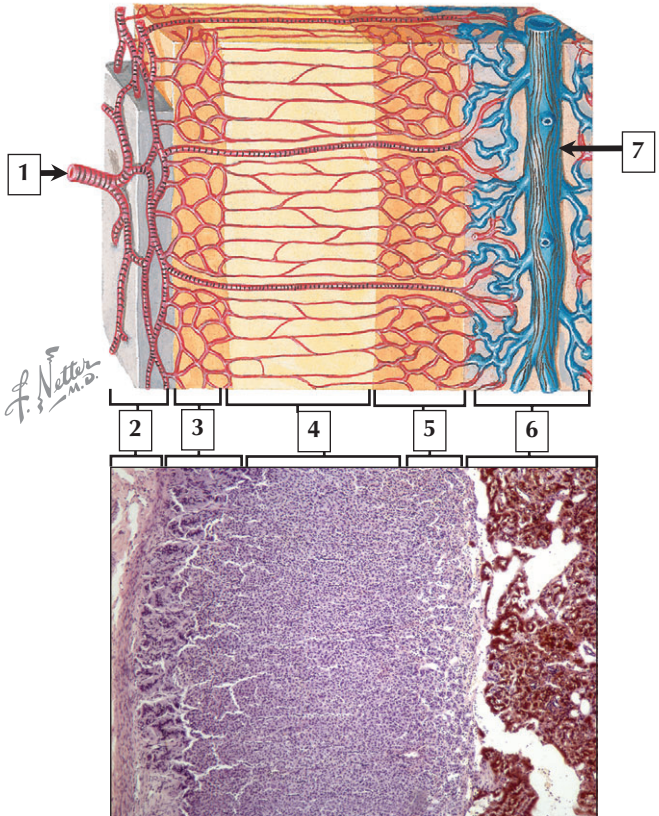
---

1. Vascular channels in medulla
2. Capsule
3. Zona fasciculata
4. Medulla
5. Zona reticularis

**Comment:** The paired adrenal glands are located on the superior pole of each kidney. They are roughly triangular, flattened, encapsulated glands. They are about 7 cm long, 3 cm high, and 1 cm thick. Their combined weight is about 10 g. Each is a composite organ composed of 2 distinct portions—a cortex and medulla—that differ structurally, functionally, and developmentally. Although the adrenal cortex is essential to life, the medulla is not. The outer cortex comprises 90% of the gland. It has a yellow color to the naked eye, and its secretory cells produce mineralocorticoids (e.g., aldosterone), corticosteroids (e.g., cortisol), and androgens (e.g., testosterone). The inner medulla contains chromaffin cells, which are the source of the catecholamines—epinephrine and norepinephrine—and are stored in their secretory granules.

**Conn's disease, or hyperaldosteronism,** is a disorder of the adrenal cortex that occurs predominantly in women. It is often caused by a tumor of the adrenal gland (**adrenal adenoma**). Symptoms include increased aldosterone secretion and subsequent sodium retention resulting in **hypertension**.

*LM of the whole adrenal in the midsagittal plane and low-magnification LM of adrenal*



## Adrenal

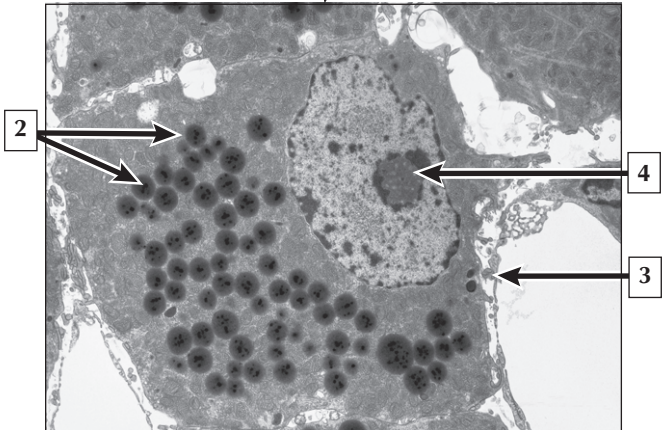
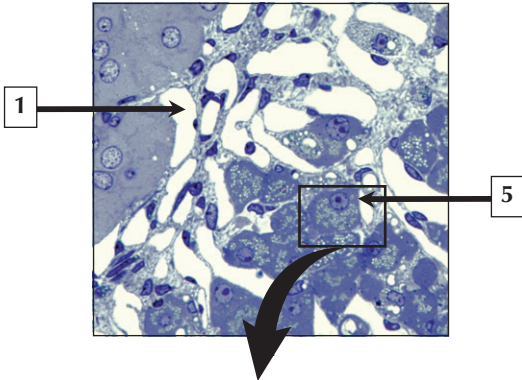
---

1. Suprarenal artery
2. Capsule
3. Zona glomerulosa
4. Zona fasciculata
5. Zona reticularis
6. Medulla
7. Central vein of medulla

**Comment:** The adrenals have a rich vascular supply. The cortex receives blood from arterioles in the capsule that enter the gland and branch into sinusoidal fenestrated capillaries; these pass downward into all 3 layers of the cortex. At the corticomedullary junction, they drain into veins that enter the medulla. Some arterioles from the capsule pass directly into the medulla and drain into sinusoidal fenestrated capillaries, which subsequently lead into collecting veins. Thus, the medulla has a dual blood supply from cortical capillaries and from medullary vessels. Venous blood from both the cortex and medulla is eventually drained by a large central vein, which exits at the hilus of the gland as the adrenal (or suprarenal) vein.

**Pheochromocytoma** is a neoplasm of the adrenal medulla that occurs mostly in adults. The **neoplasm** arises from the catecholamine-producing cells of the adrenal medulla, and the ensuing elevated levels of epinephrine and norepinephrine in the blood lead to sustained or intermittent **high blood pressure**.

*Schematic of adrenal intrinsic circulation and LM of adrenal (chromaffin stain)*



# Spongiocyte

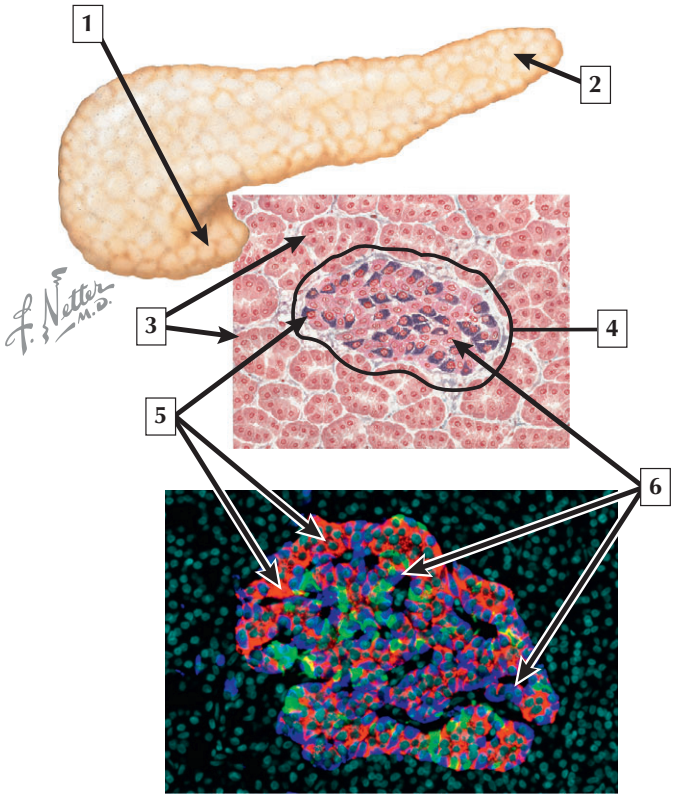
---

1. Sinusoidal capillary
2. Lipid droplets
3. Endothelium (fenestrated)
4. Nucleolus of spongiocyte
5. Spongiocyte of zona reticularis

**Comment:** Spongiocytes of the adrenal cortex contain nonmembrane-bound lipid droplets that are storage sites for cholesterol, a precursor to corticosteroid hormones. Cholesterol is shuttled to mitochondria, where it is further processed and modified. Mitochondria in these cells play a role in the cleavage of cholesterol, and the surface area of their internal cristae is increased to accommodate catalytic enzymes involved in this process. The membranes of the smooth endoplasmic reticulum (SER) also contain enzymes involved in subsequent modification and synthesis of hormone. As a general rule, these steroid-secreting cells do not store their secretory products, but synthesize them only when needed. Lipid-soluble hormones are released into the bloodstream in adjacent fenestrated capillaries.

**Addison disease, or primary adrenocortical insufficiency,** is a disorder of the adrenal cortex leading to inadequate production of glucocorticoid and mineralocorticoid hormones. It may result from incomplete development of the adrenal cortex or its progressive destruction by autoimmune disease or severe infection, such as **tuberculosis** or **idiopathic atrophy**.

*LM of adrenal cortico-medullary junction and EM of a spongiocyte in the adrenal cortex*



# Pancreas

---

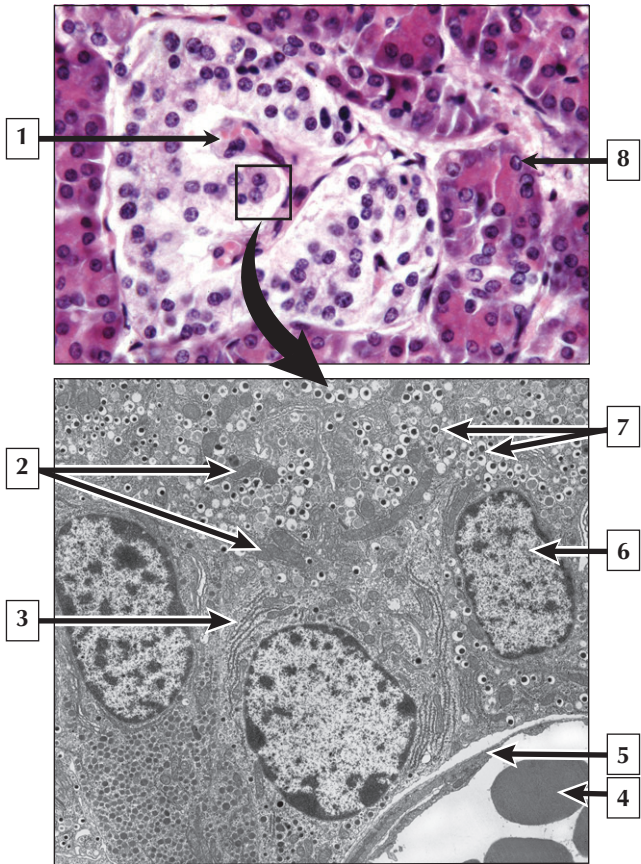
1. Pancreas (head)
2. Pancreas (tail)
3. Serous acinar cells of exocrine pancreas
4. Islet of Langerhans
5. Beta cells
6. Alpha cells

**Comment:** Although the pancreas is a major exocrine gland of the digestive tract, it also has an important endocrine portion consisting of the **islets of Langerhans**. Islets are ~300  $\mu\text{m}$  or less in diameter. Developmentally, they arise from the ends of the endodermally derived ducts and become scattered throughout the entire pancreas. Totalling ~1 million in the normal adult, they are twice as numerous in the tail of the gland as in other parts. The hormone-secreting (parenchymal) cells in the islet are closely packed, richly vascularized polygonal cells arranged in cordlike clusters. The two main islet cell types are *alpha cells*, which produce glucagon, and *beta cells*, which synthesize *insulin*.

**Type I**, or **insulin-dependent diabetes mellitus**, is caused by an autoimmune destruction of beta cells in the islets. In early stages, the islets are infiltrated with lymphocytes and, later, islets fail to produce insulin and show fibrosis and accumulation of amyloid. In **type II**, or **non-insulin-dependent diabetes mellitus**, islets usually appear normal but produce inadequate amounts of insulin and there is an abnormality in target cell receptors to insulin.

*Gross and microscopic schematics of the pancreas, and immunostained (triple-labeled) islet of Langerhans.*

## Islet of Langerhans





## Islet of Langerhans

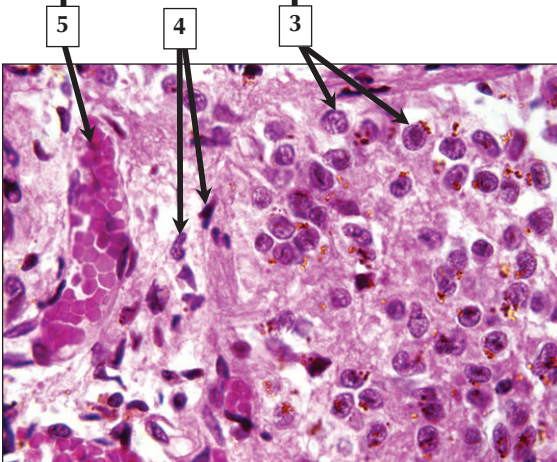
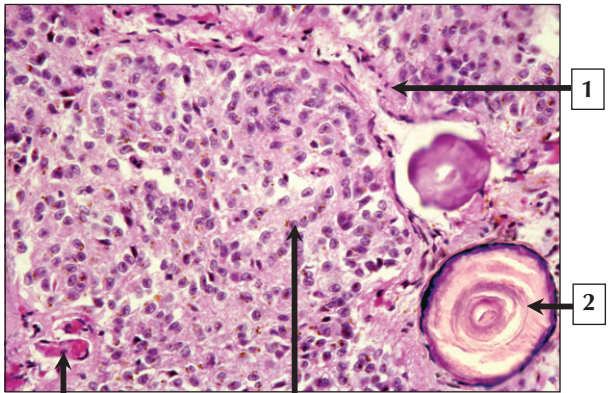
---

1. Capillary
2. Mitochondria
3. Rough endoplasmic reticulum
4. Erythrocyte
5. Endothelium (fenestrated)
6. Euchromatin of nucleus
7. Secretory vesicles
8. Serous acinar cell of exocrine pancreas

**Comment:** The predominant feature of islet cells is the abundance of membrane-bounded secretory vesicles of varying size and internal density within their cytoplasm. Islet cells are arranged in cords with their free surfaces in close contact with fenestrated capillaries. Their location in the islet, size, and internal morphology of secretory vesicles permit islet cells to be separated into at least four main types with specific hormone associations—**alpha cells:** *glucagon*; **beta cells:** *insulin*; **delta (D) cells:** *somatostatin*; and **F-cells:** *pancreatic polypeptide*.

**Islet transplantation** has been used with varying success as a therapeutic technique to restore the insulin secretion in **type 1 diabetes**. However, because of the high numbers of islets required, limited donor pool, and the risk of rejection from donors, it remains limited in use. Further advances in tissue engineering of islets may provide a future for this technique.

*LM of pancreatic islet and EM of mouse pancreatic islet*



# Pineal

---

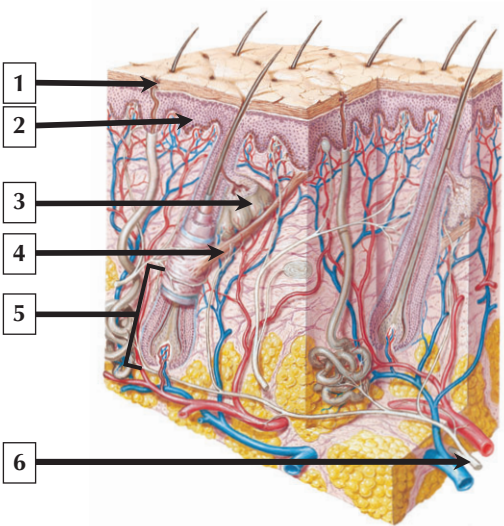
1. Stroma
2. Corpora aranacea (brain sand)
3. Pinealocytes
4. Glial cells
5. Sinusoidal capillary

**Comment:** The pineal is a small, cone-shaped, and richly vascularized neuroendocrine organ. It is ~7 mm long and weighs less than 0.2 g. It projects from the roof of the third ventricle in front of the midbrain and is supplied by both sympathetic and parasympathetic nerves. It is subdivided into poorly defined lobules by delicate connective tissue septae and stroma that extend inward from the capsule formed around the gland by pia mater. The pineal has a predominantly glandular architecture and consists mainly of closely packed and pale stained cells, known as pinealocytes. They are the source of the hormone melatonin, which is released from long terminal expansions of the cells into closely associated fenestrated capillaries. This hormone exerts powerful effects on circadian rhythms and, in some species, regulates reproductive activity. After puberty, mineralized extracellular concretions, called corpora aranacea (or “brain sand”), are a salient feature in the gland.

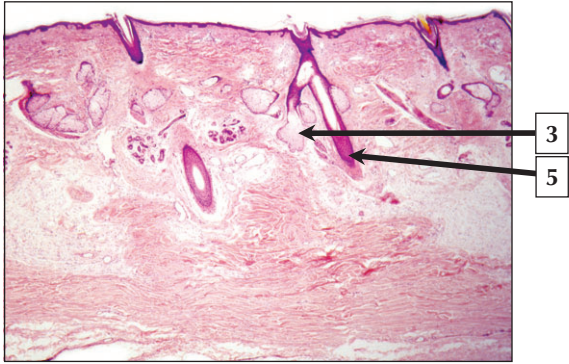
In children, the pineal may control gonadal development before puberty via the hypothalamic-pituitary axis by suppressing growth hormone and gonadotropin. **Childhood tumors of the pineal** result in **gonadal hypertrophy** and **precocious puberty**.

*Medium and high-magnification LMs of the pineal*

# Thin Skin



*F. Netter M.D.*



## Thin Skin

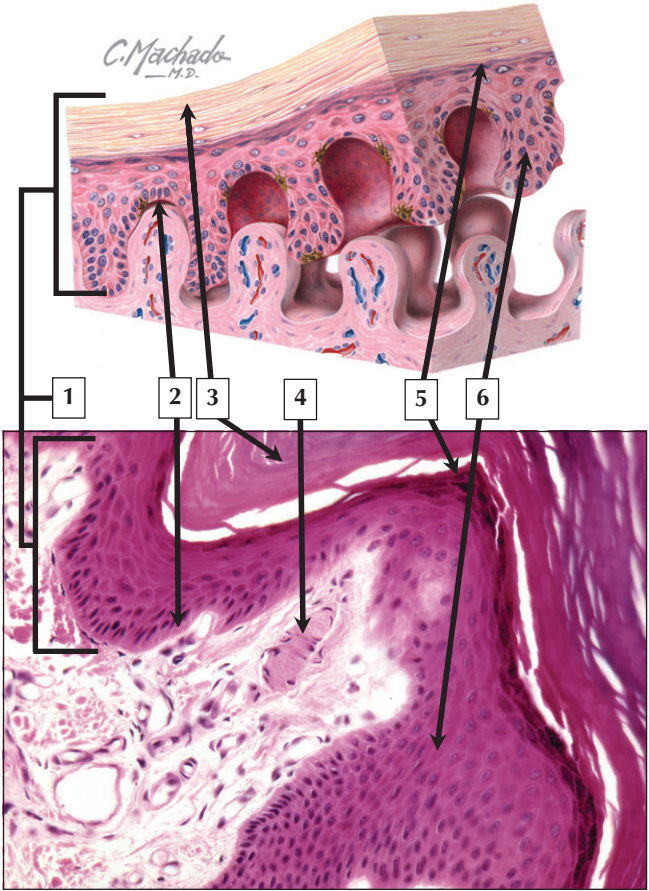
---

1. Duct of eccrine sweat gland
2. Stratified squamous epithelium (epidermis)
3. Sebaceous gland
4. Arrector pili muscle
5. Hair bulb
6. Cutaneous nerve

**Comment:** The integument is the largest organ of the body. It consists of skin, skin appendages, nails, hair, sweat glands, and sebaceous glands. The total weight and surface area of skin in the adult is 3 to 5 kg and 1.5 to 2 m<sup>2</sup>, respectively. Skin is a protective barrier against injury, infectious pathogens, and ultraviolet radiation. Skin also assists in body temperature regulation, ion excretion, sensory reception, and vitamin D synthesis. It has a remarkable regenerative capacity. Skin may be classified as thick or thin depending on structural complexity and thickness of the epidermis. Thin skin covers most of the body surface, whereas thick skin is restricted to the palms of the hands and soles of the feet. Dermis of thin skin normally contains most skin appendages, such as hair follicles, sweat, and sebaceous glands.

**Skin cancer** is the most common malignant disease in North America. The 3 major types are **basal cell** and **squamous cell carcinoma** (arise from keratinocytes) and **melanoma** (originates from melanocytes). **Basal cell carcinoma** accounts for more than 90% of all skin cancers. It grows slowly and seldom spreads to other parts of the body.

*Schematic of skin and its appendages that shows the epidermis, dermis, and subcutaneous connective tissue*



## Thick Skin

---

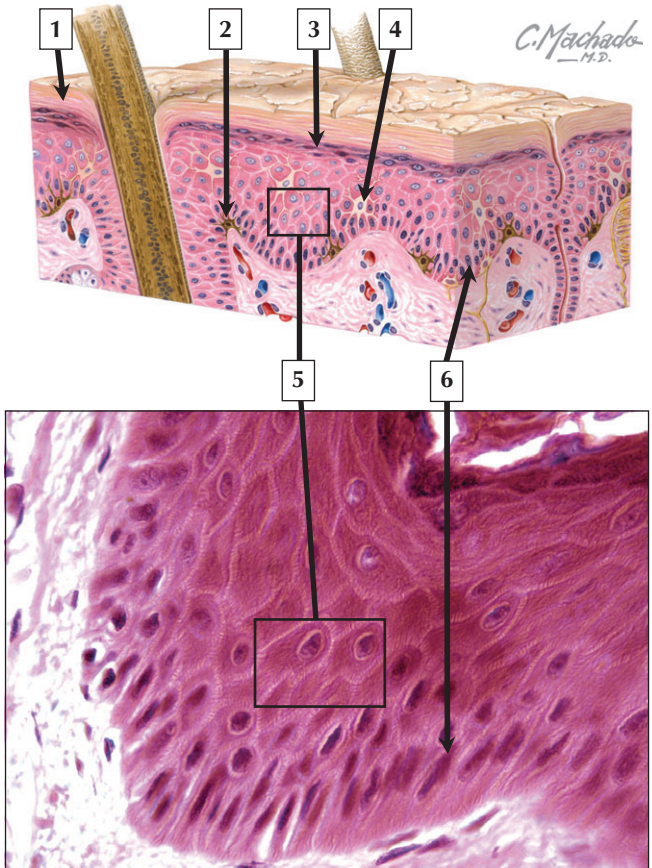
1. Epidermis (stratified squamous keratinized epithelium)
2. Stratum basale of epidermis
3. Keratin (stratum corneum)
4. Meissner's corpuscle
5. Stratum granulosum of epidermis
6. Keratinocytes in stratum spinosum

**Comment:** Dermis of thick skin is devoid of pilosebaceous units and is divided into 2 layers, a superficial papillary layer of loose connective tissue and a deeper reticular layer of dense irregular connective tissue. Thick skin typically has a thicker layer of keratin and deeper epidermal ridges than thin skin. The epidermis is stratified squamous epithelium, which consists mostly of keratinocytes organized into 4 to 5 distinct layers (or strata): stratum basale, spinosum, granulosum, and corneum. A poorly defined stratum lucidum, interposed between granulosum and corneum, is often found in thick skin but absent in thin skin. The papillary layer of the dermis is loose, richly vascularized connective tissue. Sensory receptors, such as Meissner's corpuscles, are typically found in dermal papillae.

**Squamous cell carcinoma** is associated with long-term exposure to sun and has a greater likelihood of **metastasis** than **basal cell carcinoma**. It is the second most common form of skin cancer, and usually occurs in people over the age of 50.

*Schematic and LM of thick skin at the dermoepidermal junction*

# Epidermis





# Epidermis

---

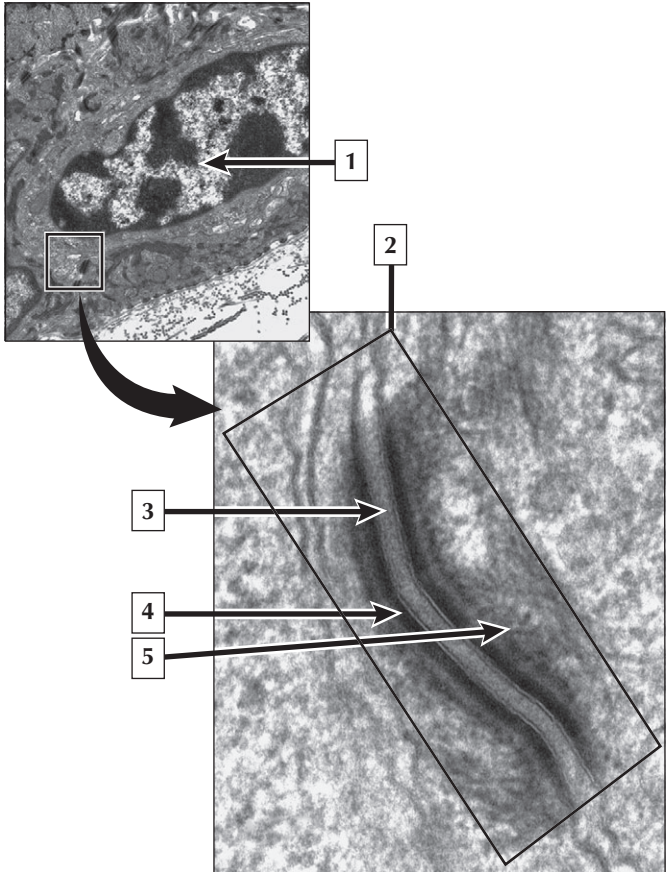
1. Stratum corneum (keratin)
2. Melanocyte
3. Stratum granulosum
4. Langerhans cell
5. Keratinocytes in stratum spinosum
6. Stratum basale (germinativum)

**Comment:** The epidermis consists of cells that undergo mitosis, differentiation, maturation, and keratinization as they are displaced outward toward the skin surface to be shed. Four or five distinct layers constitute the epidermis: stratum basale, spinosum, granulosum, lucidum, and corneum. The most superficial cells are continuously shed in a process known as keratinization. Besides keratinocytes, which make up 90% of the cell population, other epidermal cell types are melanocytes, Langerhans cells, and Merkel cells.

**Pigmentation disorders** of skin can result from a change in the number of melanocytes or a decrease or increase in their activity.

**Leukoderma** in association with inflammatory disorders of the skin, such as **atopic dermatitis**, and **vitiligo**, are 2 more common disorders of hypopigmentation.

*Schematic and LM showing layers (or strata) of the epidermis of skin*



# Keratinocytes

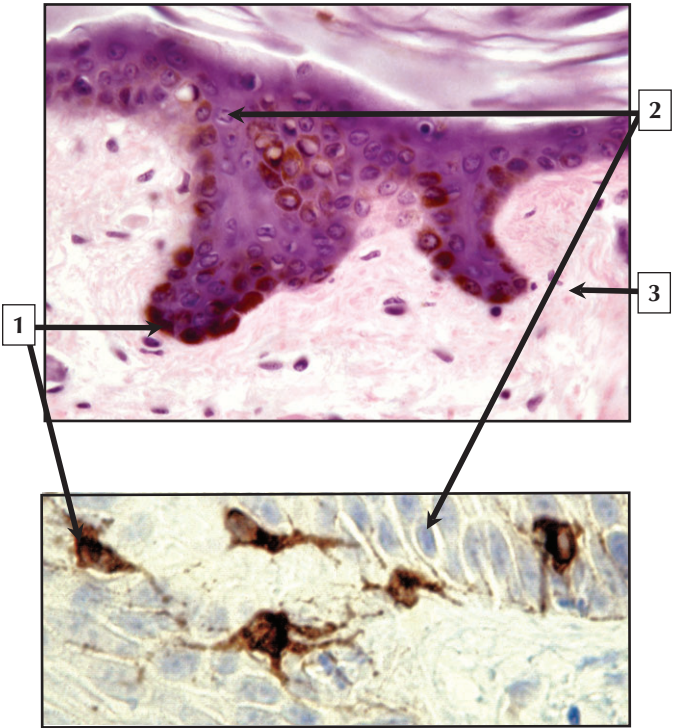
---

1. Nucleus of keratinocyte
2. Desmosome
3. Central core region
4. Plaque
5. Tonofilaments [intermediate (keratin) filaments]

**Comment:** All epithelial cells contain keratins, and almost 50 different types of keratins are found in skin. Keratinocytes of the strata basale and spinosum are connected by desmosomes. These complex intercellular junctions mediate and enhance cellular adhesion by anchoring keratin filaments to keratinocyte plasma membranes. A desmosome between 2 adjacent keratinocytes consists of a central core region that bridges the gap between cells and separates 2 identical electron-dense plaques. The tonofilaments of the cytoskeleton are associated with the cytoplasmic plaque regions. By linking tonofilament bundles of adjacent cells, desmosomes provide the epidermis with structural continuity and mechanical strength.

Some debilitating **blistering disorders** of skin result from disrupted epidermal adhesion and attachment. **Pemphigus** is the most common disease with anti-keratinocyte cell surface antibodies; the related **bullous pemphigoid** causes subepidermal blisters.

*EMs of keratinocyte and a desmosome in the epidermis of skin*



- 1 Name the cell and give its embryonic derivation.
- 2 Name the cell and give its embryonic derivation.
- 3 What is at the tip of the pointer and what is its embryonic derivation?

# Melanocytes

---

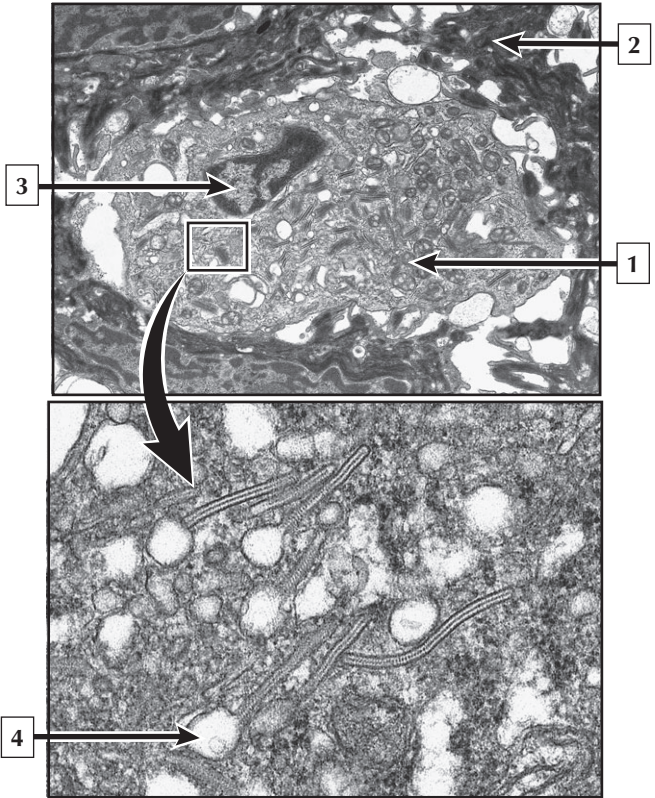
1. Melanocyte, neural crest ectoderm
2. Keratinocyte, surface ectoderm
3. Dermis, mesoderm

**Comment:** Melanocytes are melanin pigment-producing cells that determine skin and hair color. Melanin is produced in membrane-bound organelles known as melanosomes. Darkly pigmented skin, hair, and eyes have melanosomes that contain more melanin than in more lightly pigmented areas. Melanin protects against damaging effects of ultraviolet radiation on DNA. Two major forms of melanin in humans, eumelanin and pheomelanin, are both derived from tyrosine.

**Tanning** caused by ultraviolet exposure represents an increased eumelanin content of the epidermis. **Malignant melanoma** causes more than 75% of deaths from **skin cancer**. If it is diagnosed early, treatment is usually effective; melanoma diagnosed at a late stage is more likely to **metastasize** and cause death.

*Hematoxylin and eosin, and immunostained LMs of thick skin showing melanocytes in the epidermis*

# Langerhans Cells



5 Langerhans cells are derived embryonically from \_\_\_\_\_.

## Langerhans Cells

---

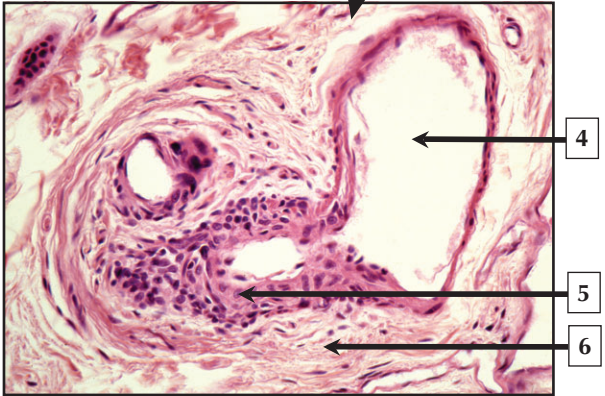
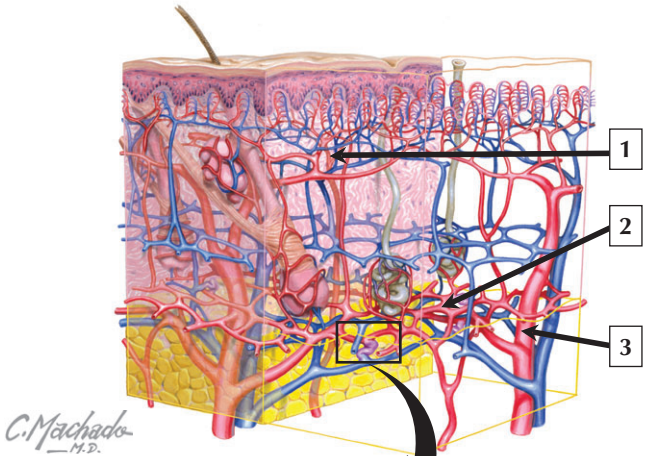
1. Cytoplasm of Langerhans cell
2. Keratinocyte
3. Nucleus (euchromatin) of Langerhans cell
4. Birbeck granule
5. Monocytes

**Comment:** Langerhans cells are monocyte-derived dendritic cells found in superficial layers of the stratum spinosum and stratum granulosum of the epidermis of skin. They account for 2% to 8% of the total epidermal cell population. They require special stains or electron microscopy to positively identify them. They have a single, highly indented nucleus. Their cytoplasm contains a Golgi complex, lysosomes, and unique inclusions known as Birbeck granules. They are phagocytic and antigen-processing cells of the immune system.

Langerhans cells increase in number in various **inflammatory conditions**, such as **contact dermatitis**. The rare autoimmune **histiocytosis X** also involves Langerhans cells. In addition, these cells are depleted in late stages of acquired immunodeficiency syndrome (**AIDS**), where human immunodeficiency virus (HIV) particles are located.

*EMs of epidermal Langerhans cells*

# Vasculature of the Dermis





## Vasculature of the Dermis

---

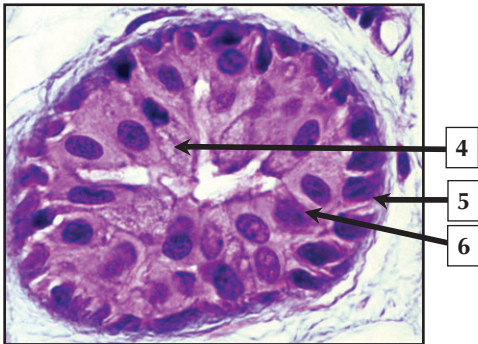
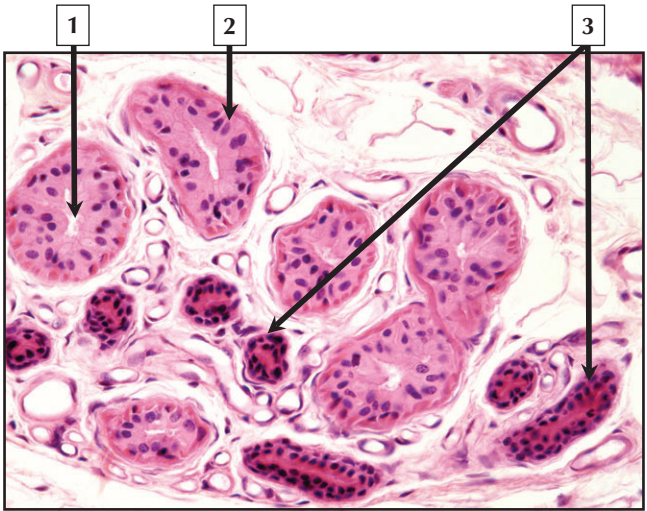
1. Superficial (subpapillary) plexus
2. Deep (cutaneous) plexus
3. Musculocutaneous artery
4. Lumen of venule
5. Cells of glomus body
6. Dense irregular connective tissue of dermis

**Comment:** The dermis, a richly vascularized connective tissue, provides mechanical support, pliability, and tensile strength to skin. Cutaneous blood vessels furnish nutrients to skin and are involved in thermoregulation. Large muscular arteries in the subcutaneous connective tissue that supply the skin are accompanied by muscular veins. A network of smaller vessels constitutes the deep (cutaneous) plexus. It communicates with a more superficial (subpapillary) plexus immediately under dermal papillae. Many arteriovenous anastomoses are in deep layers of the dermis. These specialized structures, known as glomus bodies, are involved in peripheral temperature regulation.

**Scleroderma** is a rare chronic disorder of dermal connective tissue, and is characterized by tightening of skin and extensive deposition of collagen. Its “histologic picture” includes occluded microvasculature and lymphocytic infiltration into subcutaneous connective tissue.

*Schematic of the vasculature of the dermis and LM of an arteriovenous anastomosis (glomus body)*

# Eccrine Sweat Gland



## **Eccrine Sweat Gland**

---

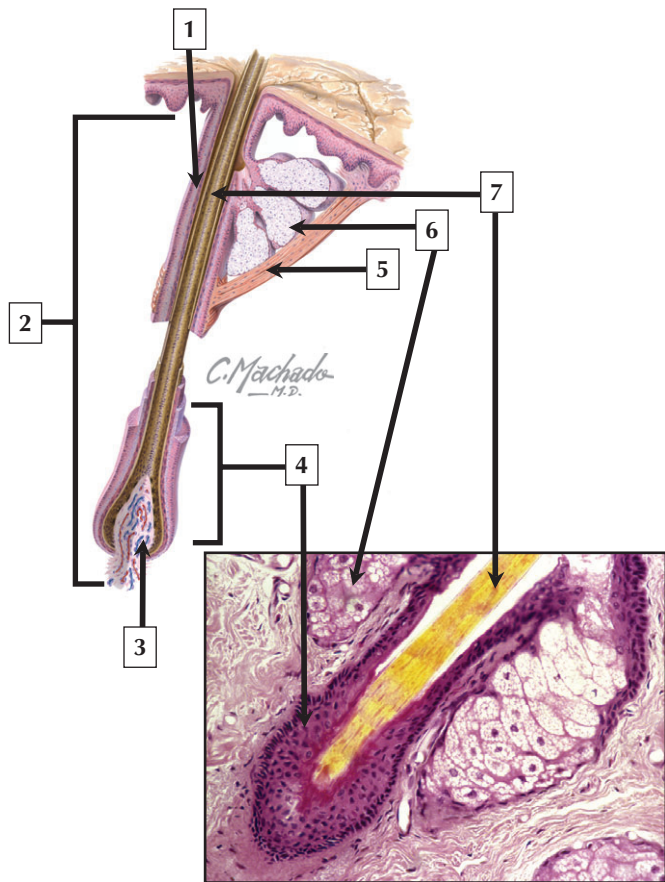
1. Lumen of secretory acinus of sweat gland
2. Secretory cell
3. Duct of sweat gland
4. Clear cell
5. Myoepithelial cell
6. Dark cell

**Comment:** Eccrine sweat glands are simple, coiled tubular glands consisting of a secretory (acinar) portion and a narrower excretory duct portion. They mainly serve a thermoregulatory role and may produce as much as 500 mL–750 mL of sweat daily in response to thermal and emotional stimuli. Two types of secretory cells—clear and dark—comprise the secretory acini. Clear cells primarily secrete water and electrolytes, whereas dark cells contribute macromolecular substances, such as glycoproteins, to sweat. Small, intensely eosinophilic myoepithelial cells at the base of the acinus help expel sweat into the lumen of the gland.

**Cystic fibrosis** (CF) is characterized by defective ion reabsorption by excretory ducts of eccrine sweat glands. The gene responsible for this autosomal recessive congenital disease encodes a membrane-associated protein, which usually resides in apical membranes of epithelial cells.

*LMs of eccrine sweat glands in the dermis*

## Pilosebaceous Unit



## Pilosebaceous Unit

---


1. External root sheath
2. Hair follicle
3. Dermal papilla
4. Hair bulb
5. Arrector pili muscle
6. Sebaceous gland
7. Hair shaft

**Comment:** The pilosebaceous unit consists of the hair, hair follicle, and an arrector pili muscle accompanied by a sebaceous gland. The long axis of the hair follicle is situated obliquely to the plane of the epidermal surface. Except for lips, palms, soles, and a few other sites, hairs cover most of the body surface. Hair growth occurs in cycles and consists of anagen, catagen, and telogen phases. Contraction of the arrector pili muscle erects the hair and depresses the adjacent skin, resulting in “goose flesh.”

**Acne vulgaris**—a chronic inflammatory disease of the pilosebaceous unit—is common during adolescence and results in increased sebum production and distention of the hair follicle. Acne affects both sexes, but males tend to have more severe disease. Systemic antibiotics and temporary use of topical steroids are treatments.

*Schematic and LM of a pilosebaceous unit*

## Hair and its Follicle



# Hair and Its Follicle

---

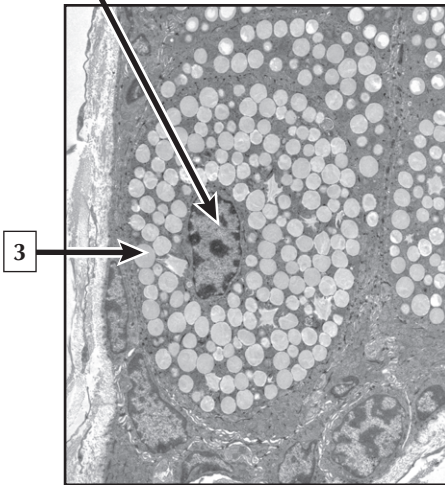
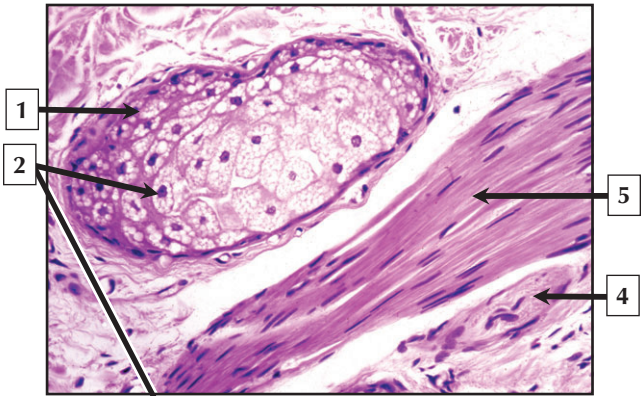
1. External root sheath
2. Internal root sheath
3. Hair cuticle
4. Medulla
5. Cortex
6. Huxley layer
7. Henle layer

**Comment:** Hair follicles are responsible for production of hair. They arise as thickenings of epidermis that proliferate as cords and penetrate the dermis. Cylindrical hair follicles are composed of an epithelial root sheath originating from epidermis and an outermost connective tissue sheath derived from dermis. The epithelial root sheath consists of an external and internal root sheath. The latter, in turn, comprises 3 layers that help secure hair within a follicle: an outer Henle sheath, a Huxley layer of flattened keratinized cells, and a cuticle, which surrounds the cortex and medulla of the hair shaft.

**Baldness (alopecia)** occurs in both sexes when there is a change in the hair growth cycle. The most common type of hair loss is **androgenetic alopecia**, which is caused by genetic and environmental factors. In this progressive disorder, hair follicles gradually become miniaturized in response to the androgen hormone, dihydrotestosterone (DHT), resulting in hair loss over the top (vertex) of the scalp. Treatments include surgical approaches, such as hair follicle transplantation, and use of topical and systemic medications that promote hair growth.

*LM and EM of hair and its follicle in transverse section*

# Sebaceous Gland





## Sebaceous Gland

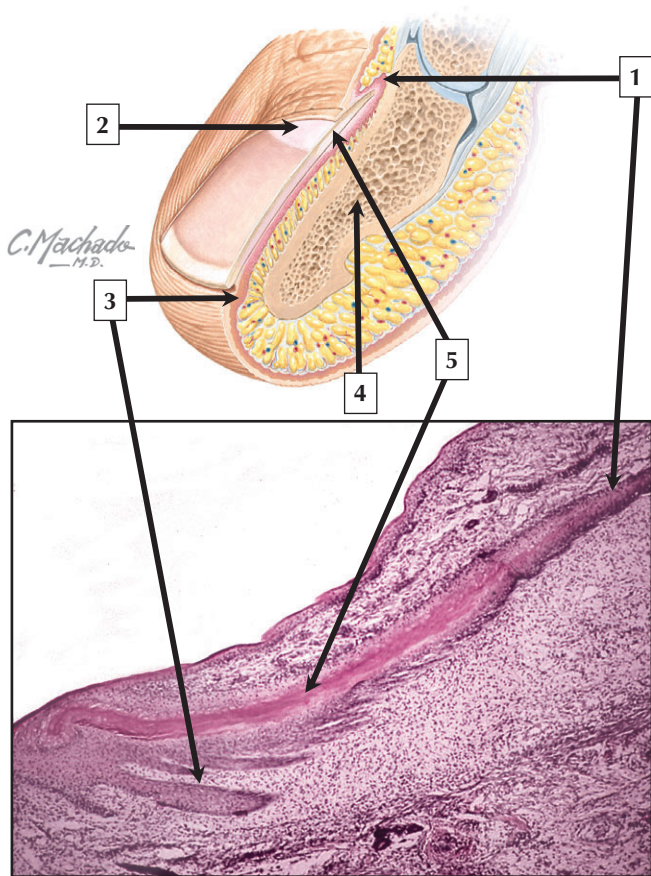
---

1. Peripheral cell of sebaceous gland
2. Nucleus of sebaceous gland cell
3. Lipid droplet
4. Nerve fascicle
5. Arrector pili muscle

**Comment:** Sebaceous glands are usually associated with hair and are located between a hair follicle and its arrector pili muscle in the dermis. They are holocrine glands in which part of the secretory product, known as sebum, is made of lipid-rich decomposed cells. These simple or branched alveolar glands are pale staining and ovoid. The lipid of sebum is synthesized in abundant smooth endoplasmic reticulum, and aggregates as lipid droplets in well-developed Golgi complex. Holocrine secretion involves breakdown of the entire sebaceous cell: lysosomal enzymes are responsible for this autolysis. Sebum is a complex oily mixture of lipids (glycerides, free fatty acids, and cholesterol). It reduces water loss from the skin surface and lubricates hair. It may also protect skin from **infection** and **bacteria**.

Sebaceous glands are under hormonal control and enlarge during puberty, when they produce a substantial amount of sebum, which may lead to development of **acne** in adolescents.

*LM and EM of sebaceous glands*



# Nails

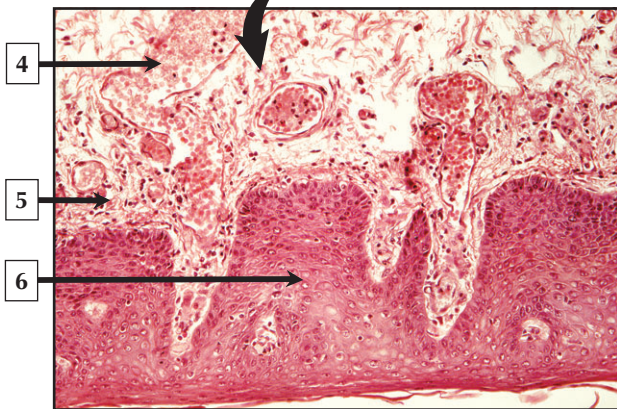
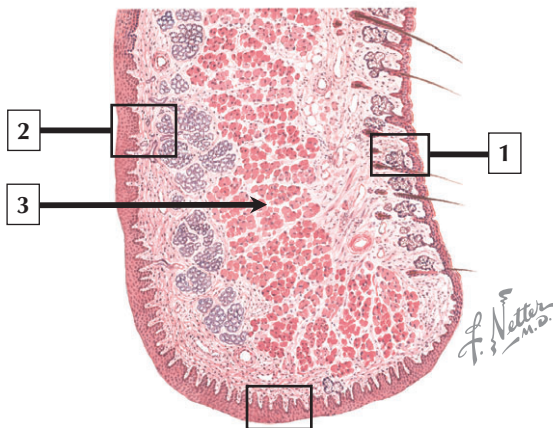
---

1. Nail matrix
2. Lunula
3. Hyponychium (nail bed)
4. Bone (distal phalanx)
5. Nail plate

**Comment:** Nails are modifications of the stratum corneum on the dorsum of terminal phalanges of fingers and toes. The eponychium is a superficial layer of epidermis that eventually degenerates during early development, except at the base, where it persists as the cuticle. The nail plate consists of keratin, which is intensely eosinophilic in hematoxylin and eosin sections. It is derived from germinative cells in the nail matrix. The nail bed, or hyponychium, underlies the nail plate. It is similar to the epidermis, except its dermal papillae are aligned parallel to the nail surface. This longitudinal orientation allows the nail plate to move outward.

**Onychomycosis** is a **fungal infection** of the nail plate that causes fingernails and toenails to thicken, discolor, disfigure, and split. It is difficult to treat because nails grow slowly and receive very little blood supply.

*Schematic of a nail in sagittal section and LM of a fetal nail in longitudinal section*



# Lip

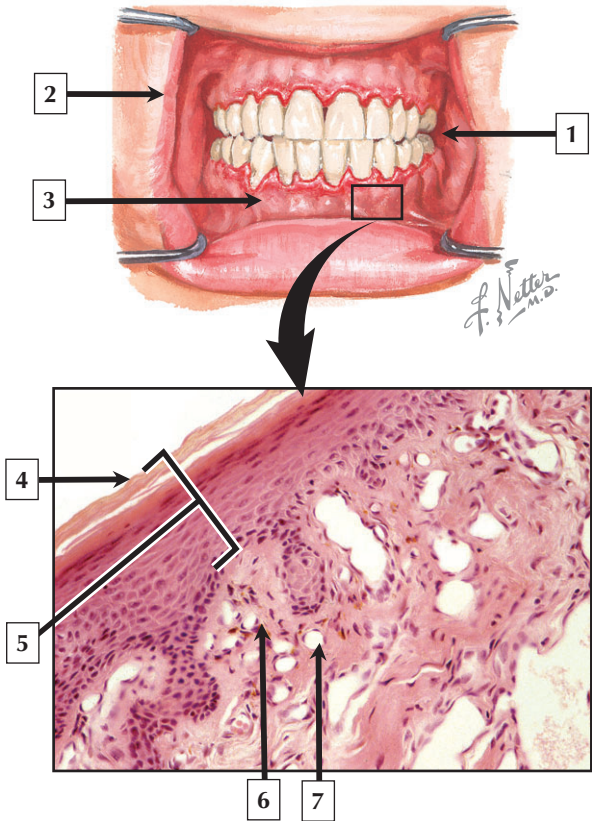
---

1. Outer (cutaneous) part of lip
2. Oral mucosa
3. Skeletal muscle (orbicularis oris)
4. Lumen of blood vessel
5. Lamina propria (loose connective tissue)
6. Stratified squamous keratinized epithelium

**Comment:** Lips constitute a mucocutaneous junction between the body exterior and digestive system. They guard the entrance to the digestive tract. Each lip has 3 parts: a cutaneous portion, red (vermilion) border, and innermost oral mucosa. The vermilion border—the free edge of the lip—is a transitional zone between skin and oral mucosa. It is composed of a thick, stratified squamous epithelium that either is poorly keratinized or lacks keratin. Tall connective tissue papillae immediately under the epithelium are close to the surface. The relatively translucent epithelium and the blood in capillaries in the papillae cause the vermilion border to be pinkish red in color.

The most common type of **malignancy** of the oral cavity is **carcinoma** of the lip, and nearly 95% of lip cancers are **squamous cell carcinomas**. They are often due to chronic sun exposure. In contrast to other head and neck cancers, lip carcinoma is readily curable.

*Schematic of the lip and LM of the vermilion border*



## Gingiva

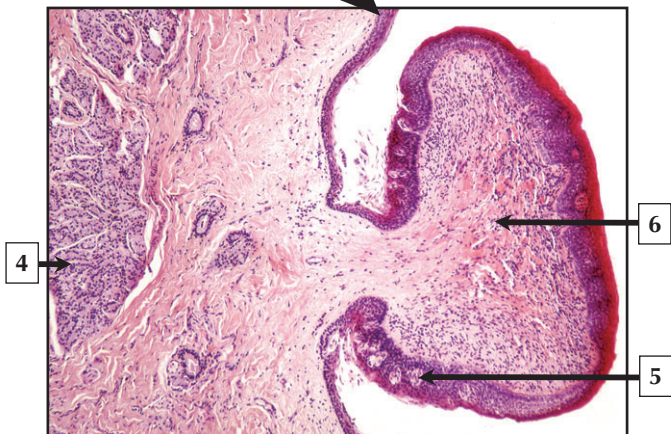
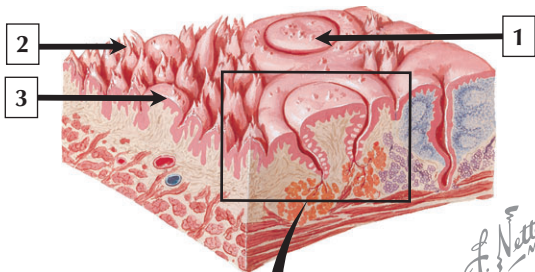
---

1. Oral mucosa of cheek
2. Vermilion border of the lip
3. Gingiva (or gum)
4. Keratin
5. Stratified squamous keratinized epithelium
6. Lamina propria
7. Capillary

**Comment:** The oral mucosa is regionally modified to reflect differences in function and ability to withstand friction. It is classified into 3 types: lining mucosa (lips, cheeks, and soft palate), masticatory mucosa (gingiva and hard palate), and specialized mucosa (dorsum of the tongue). The gingiva is a mucous membrane that lacks glands. It surrounds each tooth and envelops outer and inner surfaces of the alveolar processes of the maxilla and mandible.

**Gingivitis**—an inflammation of the gums—may be due to poor or inadequate oral hygiene. It is the most common dental pathology in children and adults and is usually caused by accumulation of plaque or calculus (tartar), containing large numbers of bacteria. Untreated gingivitis may lead to more serious complications such as **periodontitis**, which involves destruction of the alveolar bone and ultimately tooth loss.

*Schematic of part of the oral cavity and LM of the gingiva*





# Tongue

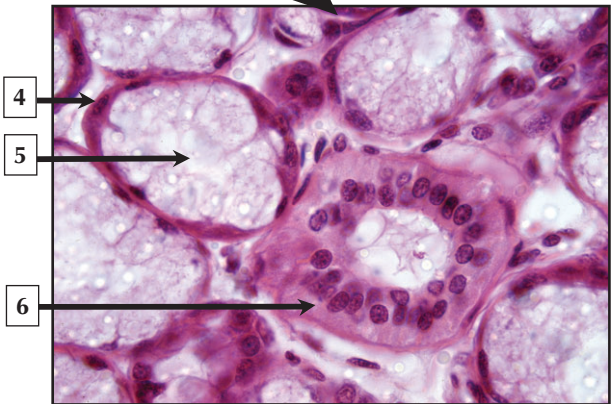
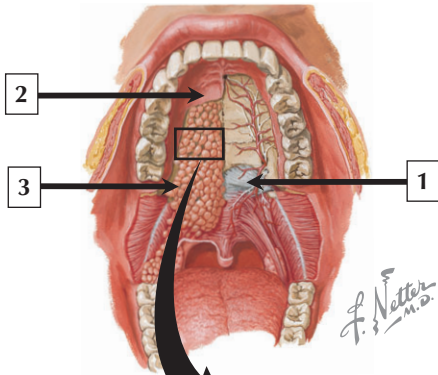
---

1. Circumvallate papilla
2. Filiform papilla
3. Fungiform papilla
4. Serous gland of von Ebner
5. Taste bud
6. Lamina propria of circumvallate papilla

**Comment:** The tongue is a mobile, muscular organ covered externally by a mucous membrane. Smooth nonkeratinized stratified squamous epithelium covers its undersurface, but keratinized mucosa covers the roughened dorsal surface on the anterior two-thirds of the tongue. Three main types of surface projections—lingual papillae—are seen. Due to differences in form, they are called filiform, fungiform, and circumvallate papillae. Circumvallate papillae are the largest with a diameter of up to 3 mm. They are either keratinized or incompletely keratinized. Each is countersunk beneath the surface and is surrounded by a trench-like circular furrow. Serous glands of von Ebner deep in the lamina propria drain into the base of each furrow, their watery secretions clearing it of debris.

Although **oral cancers** are relatively rare, major risk factors for the development of **squamous cell carcinoma** of the tongue are alcohol consumption and tobacco use. Lingual carcinomas are more common in men than in women.

*Schematic of the dorsum of the tongue with LM of a circumvallate papilla and underlying serous glands of von Ebner*



## Palate

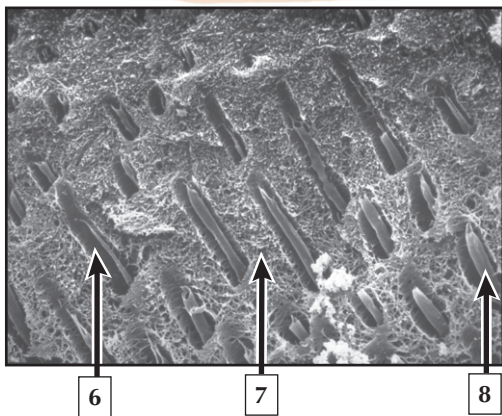
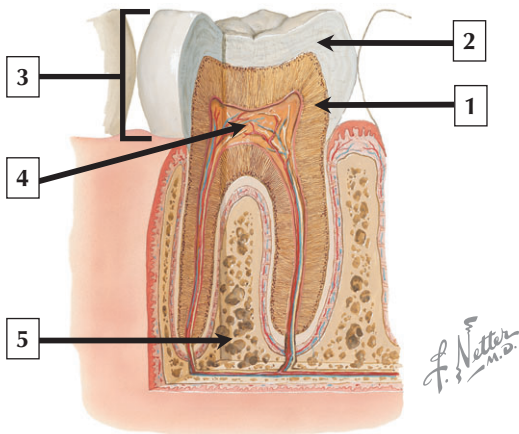
---

1. Soft palate
2. Hard palate
3. Palatine glands
4. Myoepithelial cell at the base of a mucous acinus
5. Lumen of mucous acinus of palatine gland
6. Columnar epithelial cell of duct of palatine gland

**Comment:** The palate forms the roof of the mouth and separates oral and nasal cavities. The anterior part is the hard palate; the posterior, the soft palate. Masticatory mucosa covers the rigid hard palate that serves as a working surface for the tongue as it presses against the palate during mastication and swallowing. Ducts connect small mucus-secreting palatine glands in the submucosa to the epithelial surface. The soft palate—a mobile fold with a conical projection, called the uvula—closes off the nasopharynx from the oropharynx during swallowing. Unlike the hard palate, the soft palate lacks bone. Mucous glands in the submucosa of the soft palate are near the oral surface. In contrast, mixed seromucous glands are on the nasopharyngeal side.

**Cleft palate** is a congenital deformity caused by failure of fusion of the palatine processes during gestation. Surgical treatment shortly after birth has highly successful results.

*Schematic of the roof of the mouth and LM of part of a palatine gland*



# Teeth

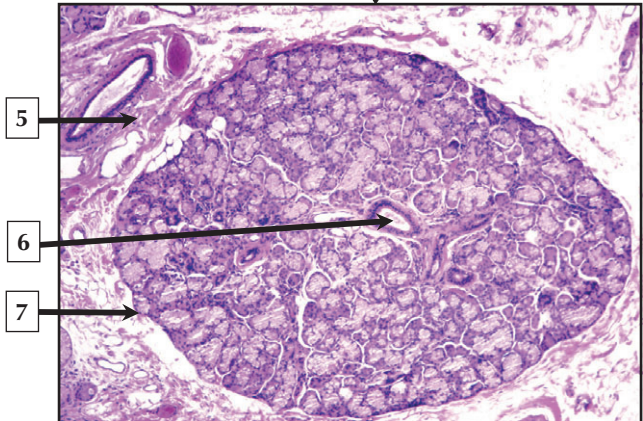
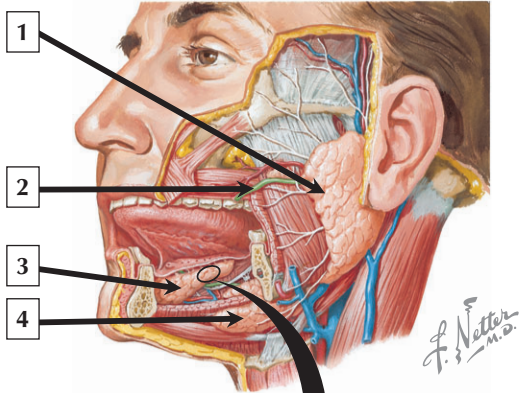
---

1. Dentin and dentinal tubules
2. Enamel
3. Crown of tooth
4. Dental pulp containing vessels and nerves
5. Bone
6. Dentinal tubule
7. Dentin matrix
8. Process of odontoblast

**Comment:** Each tooth consists of a free crown, which projects above the gingiva, and 1 or more roots that are embedded in a bony socket (or alveolus) of the jaws. A central pulp chamber extends into root canals, and dental pulp contains blood vessels, lymphatics, and nerves that enter and leave via apical foramina. Three mineralized tissues—dentin, enamel, and cementum—constitute tooth walls. Dentin surrounds the pulp cavity and comprises the bulk of the tooth. It is a hard yet resilient tissue, appearing radially striated because of dentinal tubules. The lumen of a dentinal tubule contains the apical cytoplasmic process of an odontoblast.

**Tooth decay** or **dental caries** is caused by acid-forming bacteria that dissolve enamel. The bacteria may penetrate deeper layers of teeth into the pulp, leading to pain, local infection, and tooth loss. Fluoridation has dramatically reduced the incidence of caries.

*Schematic of a tooth and high-resolution scanning electron micrograph (HRSEM) of dentinal tubules*



## Salivary Glands

---

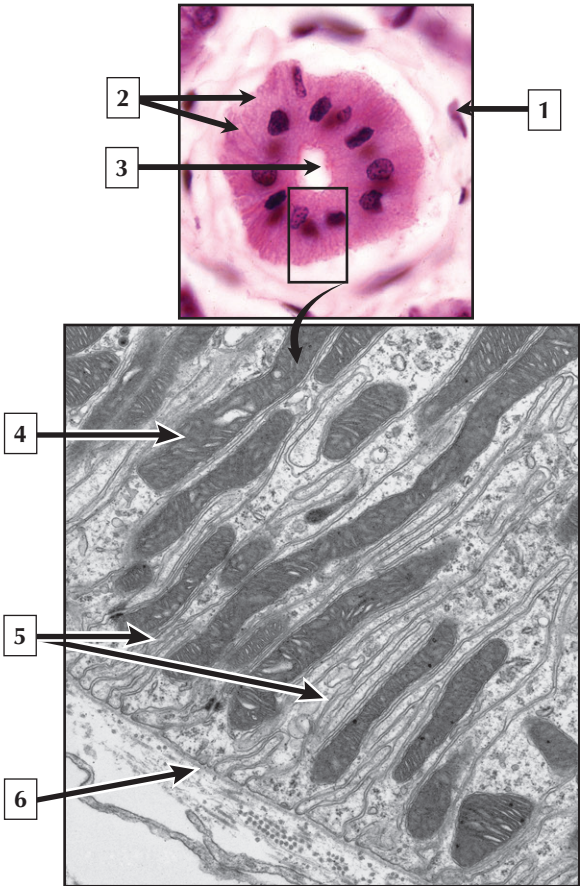
1. Parotid gland
2. Parotid (Stensen's) duct
3. Sublingual gland
4. Submandibular gland
5. Stroma (loose connective tissue)
6. Intralobular duct
7. Lobule of a mixed (seromucous) salivary gland

**Comment:** Three pairs of major salivary glands—parotid, submandibular, and sublingual—and several minor salivary glands produce saliva, and empty secretory products via ducts in the oral cavity. Saliva is a watery, viscous suspension of mucus, enzymes, inorganic ions, and antibodies. It lubricates and protects oral tissues and is an aqueous solvent for taste. It also aids control of microbial flora in the oral cavity (via immunoglobulins) and inhibits dental caries (via bacterial lysozyme). The parenchyma of salivary glands is organized into lobules of varying size, which are separated by intervening stroma made of connective tissue.

The oral mucosa is the point of entry for **pathogens** and **irritants** from the outside into the digestive and respiratory tracts. Repair of oral mucosa in response to **disease** or **infection** is much more efficient than that of skin because there is almost no scar formation after injury.

*Schematic showing the major salivary glands and LM of a lobule of the sublingual gland*

# Striated Ducts





## Striated Ducts

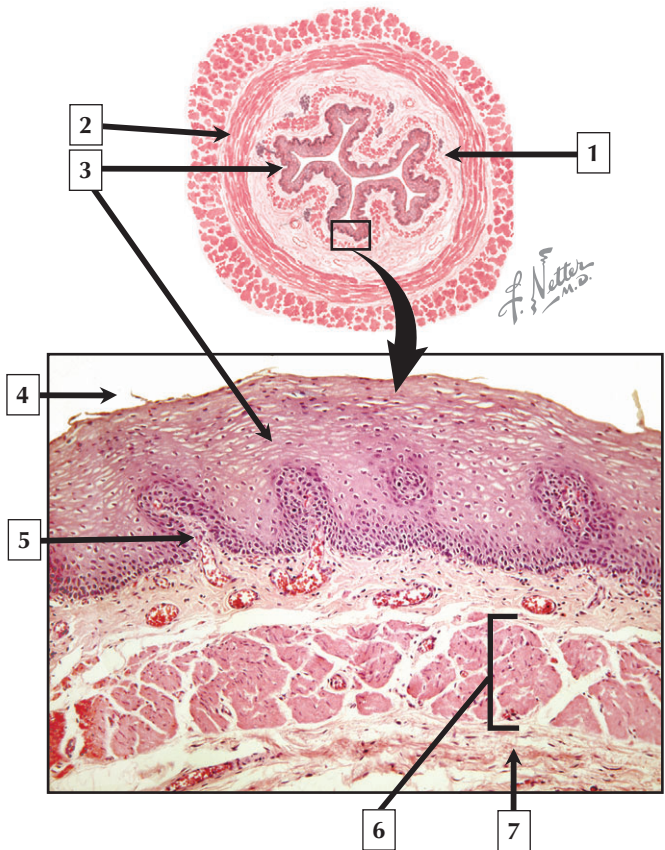
---

1. Fibroblast in stroma
2. Basal striations
3. Lumen of striated duct
4. Mitochondrion
5. Infoldings of basal plasma membrane
6. Basal lamina

**Comment:** Striated ducts are unique to salivary glands. They modify the composition of saliva, making it hypotonic. Basal striations in the simple columnar epithelial cells forming these ducts set them apart from other parts of the duct system. In hematoxylin and eosin sections, the ductal cells are intensely eosinophilic due to high concentrations of mitochondria. The basal striations represent infoldings of the plasma membrane. The ultrastructure of striated ducts is consistent with their role as an ion-transporting epithelium. Basal infoldings of the plasma membrane, which are perpendicular to the base of the cells, dramatically increase surface area for function. Elongated mitochondria are organized in parallel rows between these infoldings. This arrangement facilitates active ion transport by providing energy as ATP at sites where sodium ions ( $\text{Na}^+$ ) are actively resorbed.

**Oncocytoma**—a rare **benign neoplasm** usually occurring in the parotid—is thought to arise from striated duct cells. Such **tumors** are composed of oncocytes with granular eosinophilic cytoplasm and a large number of atypical mitochondria.

*LM and EM of striated ducts of salivary glands*



# Esophagus

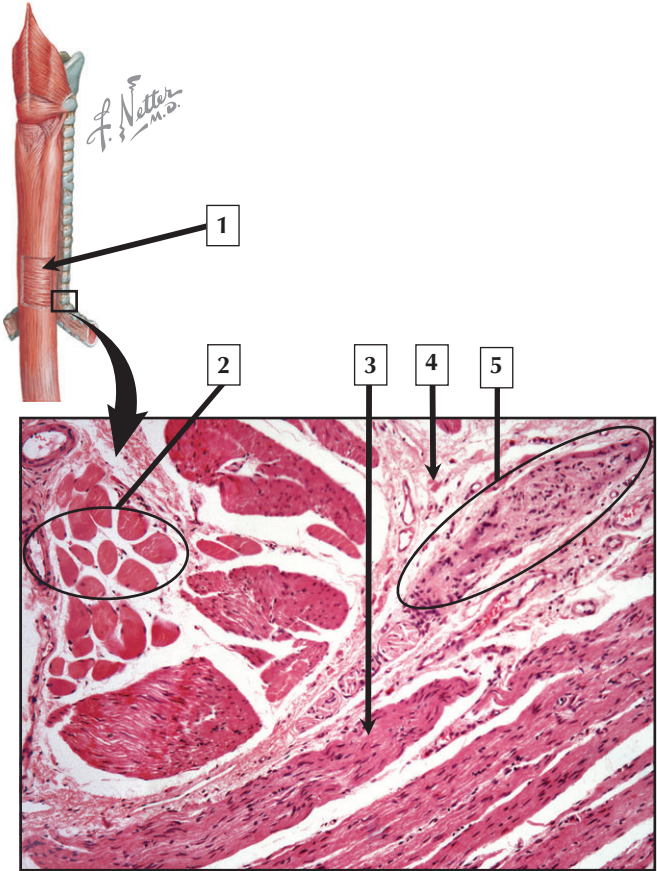
---

1. Submucosa
2. Circular muscle
3. Stratified squamous nonkeratinized epithelium
4. Lumen of esophagus
5. Connective tissue papilla
6. Muscularis mucosae
7. Submucosa

**Comment:** The esophagus—a hollow tube about 25 cm long in adults—propels partially digested food from the pharynx to the stomach. Its wall is composed of 4 concentric layers: mucosa, submucosa, muscularis externa, and adventitia. The esophageal mucosa consists of stratified squamous nonkeratinized epithelium, underlying lamina propria, and prominent muscularis mucosae.

**Barrett esophagus** is characterized by **metaplasia** of the esophageal epithelium whereby simple columnar epithelium similar to that of the stomach replaces the usual stratified squamous epithelium. A burning pain, known as **heartburn**, is a common symptom.

*Schematic of the esophagus showing its 4 concentric layers and LM of the esophageal mucosa*



# Esophagus

---

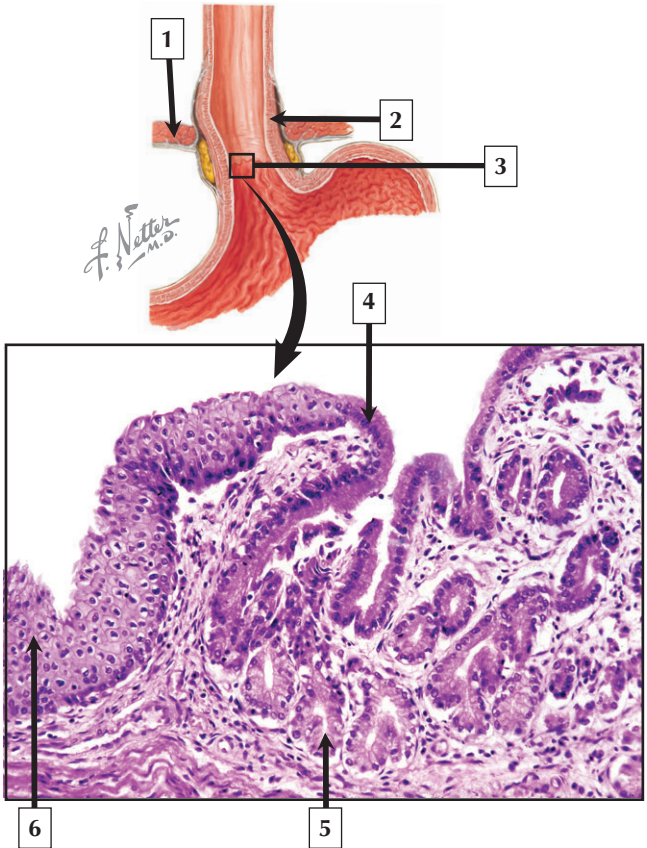
1. Circular smooth muscle layer
2. Skeletal muscle (transverse section)
3. Smooth muscle (longitudinal section)
4. Loose connective tissue
5. Auerbach (myenteric) plexus

**Comment:** The muscularis externa of the esophagus, 0.5 to 2 mm thick, is made of inner circular and outer longitudinal layers of muscle. In the upper third of the esophagus, both layers contain only skeletal muscle fibers on which nerve fibers of cranial nerves IX and X end as motor endplates. These muscle fibers are unique, however, because their contraction is involuntary. In the middle third of the esophagus, smooth muscle cells are internal to skeletal muscle, and their number gradually increases distally.

Abnormally dilated submucosal veins—known as **esophageal varices**—may occur in the lower third of the esophagus. They are often associated with **cirrhosis** of the liver and **portal hypertension**. The varices are susceptible to rupture and **hemorrhage**, which may be life threatening.

*Schematic of the musculature of the esophagus and LM of part of the muscularis externa showing the myenteric plexus*

# Esophago-gastric Junction



## Esophago-gastric Junction

---

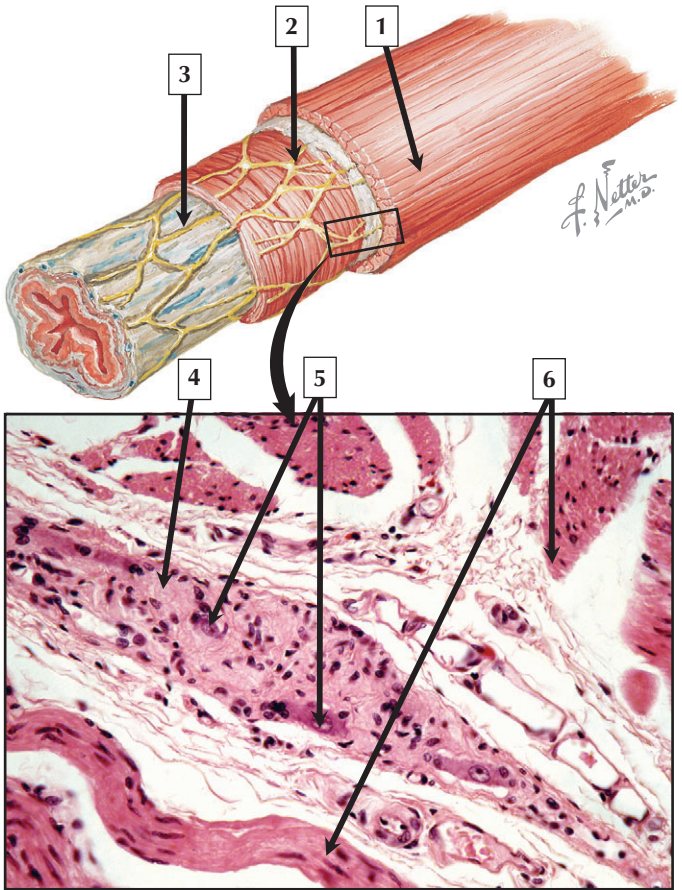
1. Diaphragm
2. Muscularis externa (lower esophageal sphincter)
3. Z line (gastroesophageal junction)
4. Gastric surface (simple columnar) epithelium
5. Cardiac gland
6. Stratified squamous nonkeratinized epithelium of esophagus

**Comment:** An abrupt histologic transition occurs at the esophago-gastric junction. The epithelial lining constitutes a squamocolumnar junction, which is clinically important as it is the most common site of esophageal carcinoma. Known as the Z line, this serrated border is easily identified by endoscopy and shows a typical change in color from pale, above, to deep red, below. Nonkeratinized stratified squamous epithelium changes to simple columnar epithelium of the stomach. Lymphoid tissue aggregates also occur in the lamina propria near the junction.

**Inflammation** of the esophagus with damage to the epithelium is called **esophagitis**. Its most common cause is reflux of gastric contents into the lower esophagus, which impairs reparative capacity of esophageal mucosa. **Gastroesophageal reflux disease**, a common chronic condition, usually affects adults older than 40 years.

*Schematic and LM of the esophago-gastric junction*

# Enteric Nervous System





# Enteric Nervous System

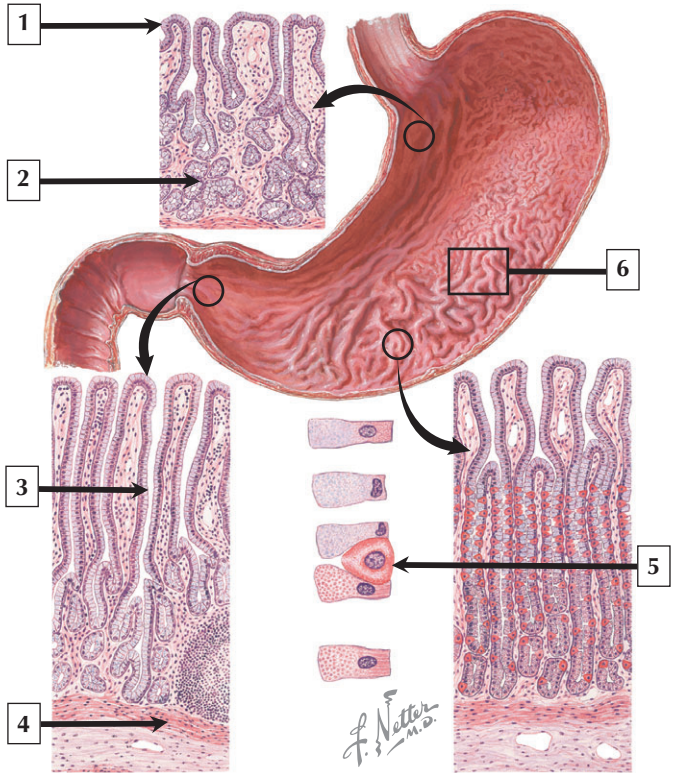
---

1. Longitudinal (outer) layer of smooth muscle
2. Auerbach (myenteric) plexus
3. Meissner (submucosal) plexus
4. Nerve fibers of myenteric plexus
5. Ganglion cells of myenteric plexus
6. Smooth muscle

**Comment:** The digestive tract, from the esophagus to the anus, has its own intrinsic nerve supply. Known as the enteric nervous system (ENS), it consists of an extensive network of nerve fibers, nerve cell bodies (ganglion cells), and their supportive (glial) cells. Derived embryonically from the neural crest, the ENS consists of 2 distinct yet connected parts within the wall of the digestive tract. The larger myenteric (Auerbach) plexus is between inner and outer layers of smooth muscle in the muscularis externa. It mainly regulates smooth muscle contraction, peristalsis, and gastrointestinal motility. The smaller submucosal (Meissner) plexus mostly regulates glandular secretion and local blood flow.

**Hirschsprung disease** is a developmental disorder characterized by an absence of ganglion cells of the ENS. It leads to uncoordinated peristalsis, constipation, and functional obstruction. Surgical removal of the affected region followed by anastomosis of unaffected areas is the mode of treatment.

*Schematic of the enteric nervous system showing innervation of the esophagus and LM of a myenteric plexus*



# Stomach

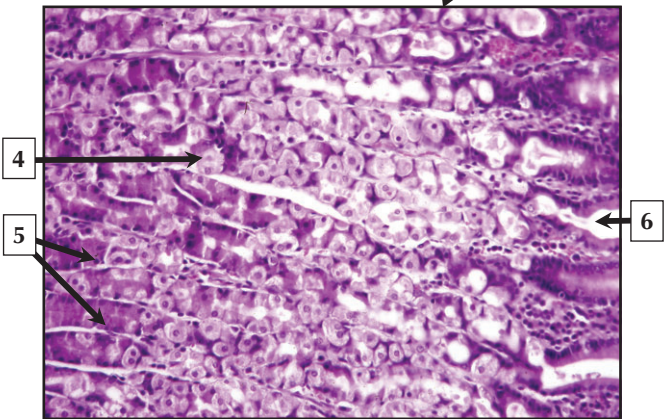
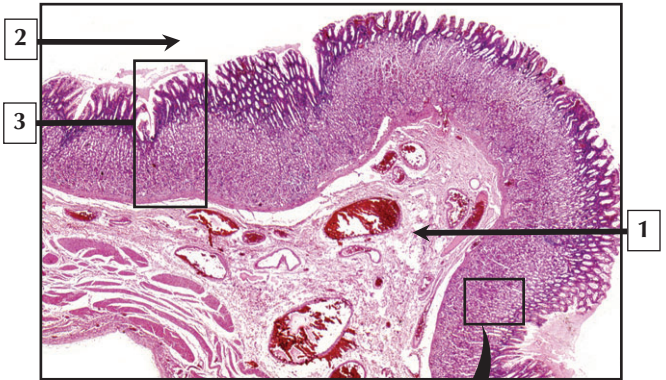---

1. Surface mucous cell
2. Cardiac (mucus-secreting) gland
3. Gastric pit
4. Muscularis mucosae
5. Parietal cell
6. Rugae

**Comment:** The stomach is an expandable fibromuscular sac that stores and mixes food. It has a capacity of 1.5 L to 3 L when distended. It comprises 4 anatomic regions: cardia, fundus, body, and pylorus. As in other parts of the digestive tract, its wall has 4 concentric layers: mucosa, submucosa, muscularis externa, and serosa. The mucosa—the thickest layer—is 0.3 mm-1.5 mm deep, and shows irregular longitudinal folds, known as rugae, which flatten as the stomach expands. The epithelium regularly dips to form small gastric pits, or foveolae, which lead to long tubular gastric glands.

**Hiatus (diaphragmatic) hernia** is a common clinical condition in which the upper part of the stomach prolapses into the mediastinum through the opening (hiatus) of the diaphragm. It is common in people over the age of 60, and affects more women than men. Although usually asymptomatic, it may interfere with reflux barrier mechanisms, resulting in reflux of gastric contents into the esophagus.

*Schematic of the mucous membrane of the stomach*



## Stomach

---

1. Submucosa
2. Lumen of stomach
3. Gastric mucosa
4. Parietal cell
5. Gastric chief cells
6. Gastric pit

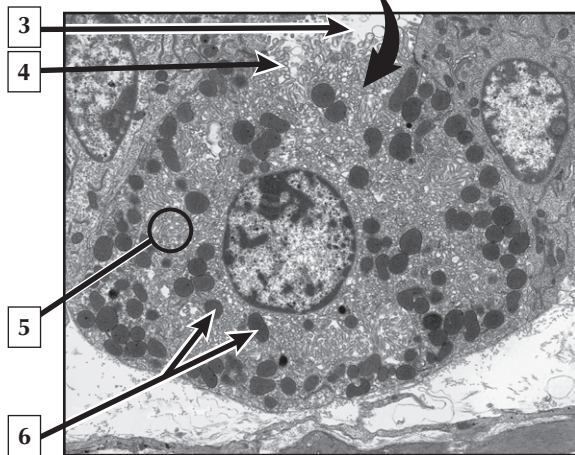
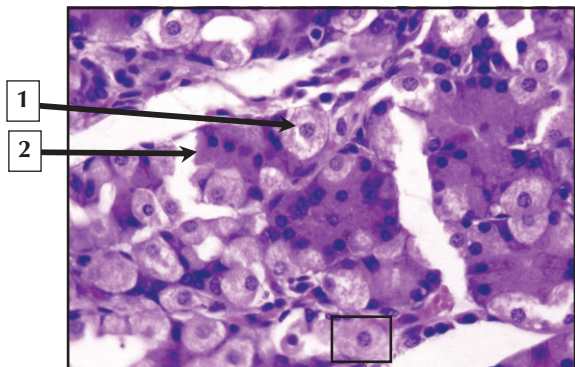
**Comment:** Gastric mucosa is highly cellular and consists of simple columnar epithelium, underlying lamina propria, and deeper muscularis mucosae. Surface mucous cells extend into gastric pits, which lead into long, tubular gastric glands. The glands are so tightly packed that the lamina propria is difficult to distinguish and often appears scanty. Each gland shows 3 regions: an apical isthmus, neck, and body (main part) with a slightly dilated, coiled base. Mucous neck cells, parietal cells, chief cells, and enteroendocrine cells comprise the main gastric glands of the body and fundus of the stomach.

**Stomach cancer** may develop in any part of the organ, but the most frequent site of occurrence is close to the esophago-gastric junction.

**Gastric adenocarcinoma**—the most common type—is a **malignant tumor** originating in the glandular epithelium of the gastric mucosa. Diagnosis is by endoscopic examination and biopsy. It has a tendency to invade the gastric wall and metastasize to other organs.

*LMs of the stomach wall and gastric mucosa*

## Parietal Cells



## Parietal Cells

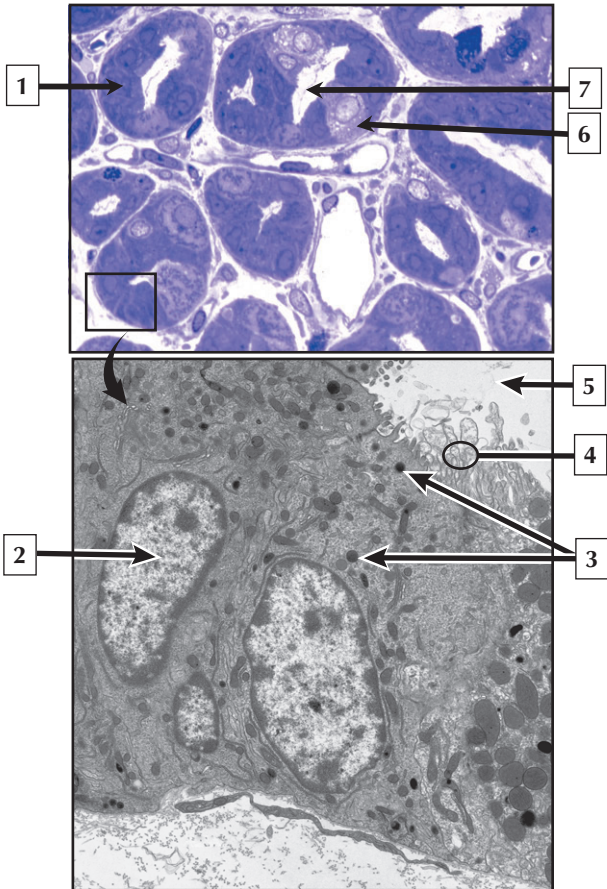
---

1. Parietal cell
2. Gastric chief cell
3. Lumen of gastric gland
4. Microvilli of parietal cell
5. Canaliculi
6. Mitochondria

**Comment:** Parietal cells—the most numerous cell type in the body of gastric glands—produce hydrochloric acid and vitamin B<sub>12</sub> intrinsic factor. They are large, rounded, or pyramidal shaped cells with a single, central nucleus. In hematoxylin and eosin sections they are either washed out (due to preparation artifact) or have a deeply eosinophilic cytoplasm (due to high concentrations of mitochondria). By electron microscopy they contain an extensive canalicular system (infoldings of the apical plasma membrane) lined by microvilli, a small, basal Golgi complex, and rough endoplasmic reticulum (RER).

**Pernicious anemia** is a chronic disease caused by impaired vitamin B<sub>12</sub> absorption. It is usually due to failure of parietal cells to produce intrinsic factor. Antibodies to parietal cells occur in 90% of patients. Lack of vitamin B<sub>12</sub> causes **neurologic deficits** as well as **megaloblastic anemia**, whereby erythrocyte formation in the bone marrow is abnormal. Treatment is by oral intake or intramuscular injection of supplementary vitamin B<sub>12</sub> (cyanocobalamin).

*LM and EM of parietal cells in the gastric mucosa*





## Chief Cells

---

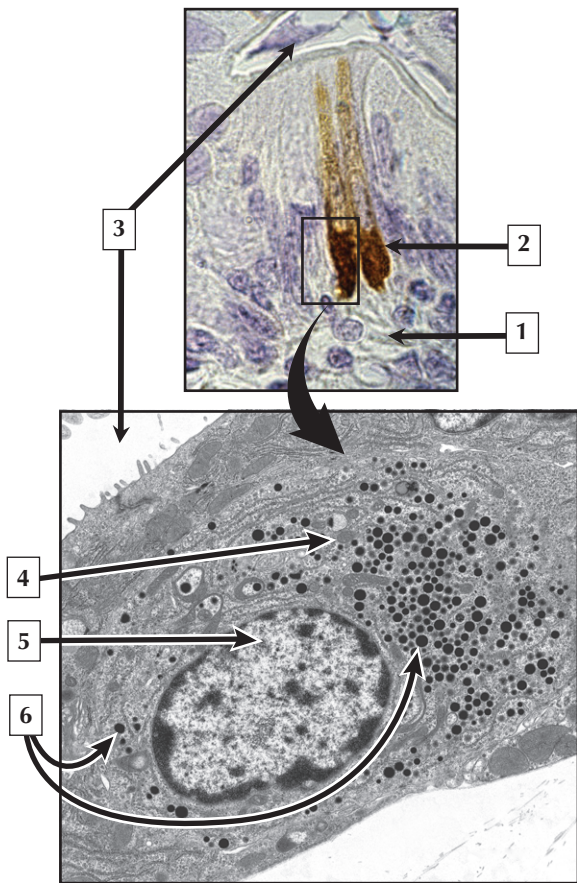
1. Gastric chief cell
2. Nucleus (euchromatin) of gastric chief cell
3. Zymogen granules
4. Microvilli
5. Lumen of gastric gland
6. Parietal cell
7. Lumen of gastric gland

**Comment:** Gastric chief cells are mostly seen in the basal parts of gastric glands in the stomach. They are typical protein-synthesizing cells that produce 2 types of proteolytic enzymes (pepsinogen I and II) as well as lipase, another digestive enzyme. Chief cells are cuboidal to columnar in shape. They have a round basal nucleus and an apical cytoplasm with many zymogen granules. Their ultrastructure closely resembles that of pancreatic acinar cells. Zymogen granules are large membrane-bound secretory vesicles derived from the Golgi complex. They discharge their contents by exocytosis at the apex of the cell.

Type of diet, alcohol consumption, smoking, and infection with *Helicobacter pylori* bacteria play major roles in the development of **gastric adenocarcinoma**. To determine whether it has spread to other sites, staging of this type of **stomach cancer** is done by computed tomography scans and blood tests for tumor markers (such as carcinoembryonic antigen).

*LM of gastric glands stained with toluidine blue, and EM of gastric chief cells*

## Enteroendocrine Cells



## Enteroendocrine Cells

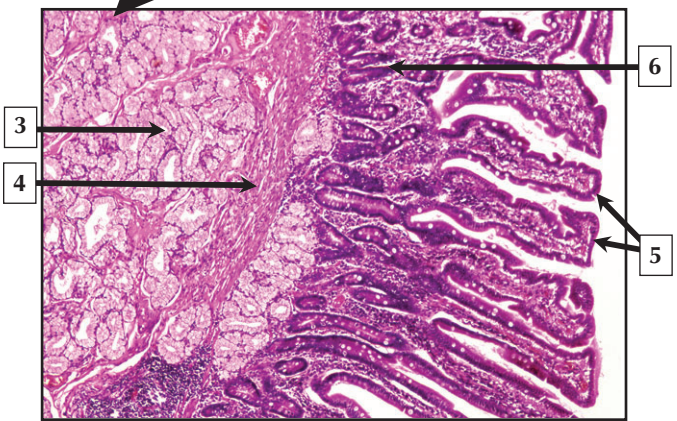
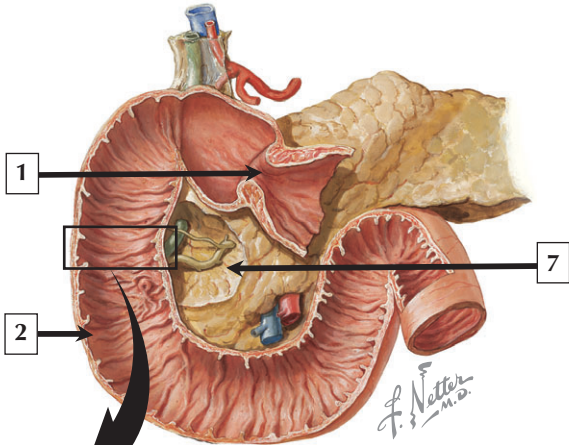
---

1. Lamina propria
2. Basal part of enteroendocrine cell
3. Lumen of digestive tract
4. Mitochondrion
5. Nucleus (euchromatin) of enteroendocrine cell
6. Secretory vesicles

**Comment:** More than 30 gastrointestinal hormones are produced by enteroendocrine cells in the digestive tract. These cells are diffusely scattered in the epithelium from esophagus to colon. While difficult to see in routine sections, immunocytochemistry and electron microscopy can reveal them. They make up a family of cells comprising the neuroendocrine system that produce powerful effects on target cells and tissues. Small membrane-bound secretory vesicles abound in their cytoplasm.

Rare and slow-growing **carcinoid tumors** develop from hormone-producing cells of the gastrointestinal tract. The most common sites of origin are the appendix, small intestine, and rectum. Since they arise from enteroendocrine cells, such tumors retain the capacity to produce hormones in large quantities. According to the type of hormone produced by the tumor cells, carcinoid tumors cause a wide variety of signs and symptoms.

*LM of enteroendocrine cells in the small intestine stained to detect vasoactive intestinal polypeptide hormone and EM of an enteroendocrine cell in the stomach*



## Duodenum

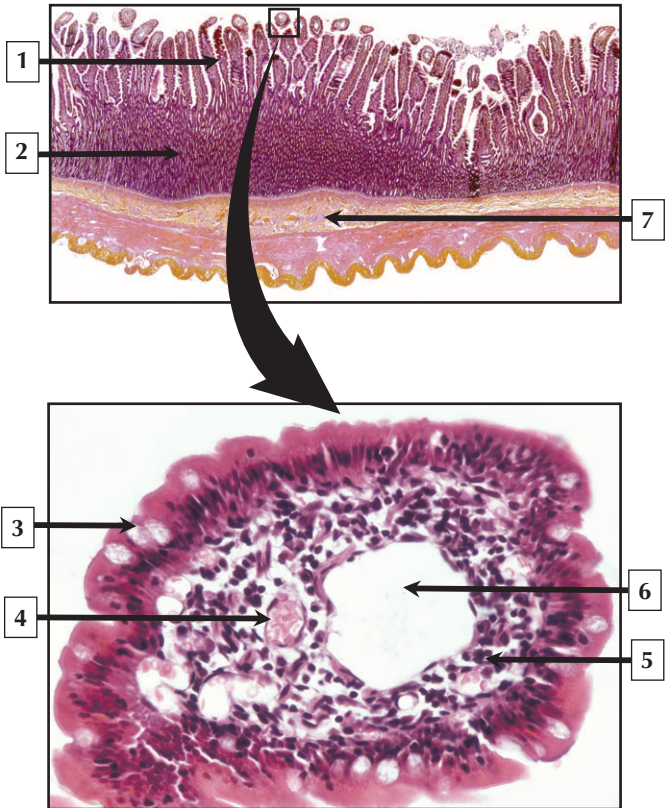
---

1. Pyloric orifice
2. Mucosal surface
3. Brunner's (submucosal) gland
4. Muscularis mucosae
5. Intestinal villi
6. Crypt of Lieberkuhn (intestinal gland)
7. Head of pancreas

**Comment:** The horseshoe-shaped duodenum is the shortest of the 3 segments of the small intestine. The mucosa has broad, leaf-shaped villi, and crypts are lined by simple columnar epithelium made of enterocytes and goblet cells. Mucus-secreting glands of Brunner are in the proximal duodenum. These compound tubular glands have secretory acini located in the submucosa. They pierce the muscularis mucosae and drain via short ducts into bases of the crypts in the mucosa. Alkaline mucus produced by the glands protects the mucosa from damage or erosion.

Most **peptic ulcers** affect the proximal part of the duodenum. They begin in the mucosa and, in chronic states, extend into underlying layers, where they may perforate the serosa. They may be caused by exposure to acid and proteolytic enzymes, infection with *Helibacter pylori* bacteria, or use of nonsteroidal anti-inflammatory drugs (NSAIDs).

*Schematic of the duodenum and LM of its mucosa and submucosa*



# Jejunum

---

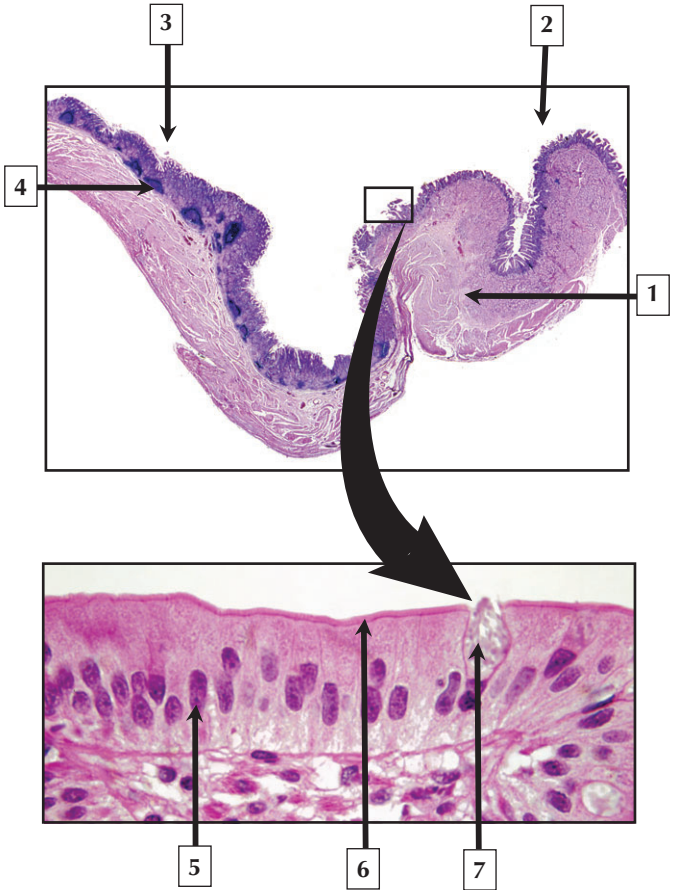
1. Intestinal villus
2. Intestinal crypts (of Lieberkuhn)
3. Goblet cell
4. Erythrocytes in lumen of capillary
5. Lamina propria
6. Lumen of lacteal
7. Submucosa

**Comment:** In contrast to other parts of the small intestine, the jejunum has the most extensive surface area for luminal secretion and absorption. The total thickness of the jejunal mucosa is 0.5 mm to 1.5 mm. In addition, plicae circulares are thicker, taller, and more numerous in the jejunum than in the duodenum or ileum. Villi of the jejunum are tall, slender, and finger-shaped. The highly cellular lamina propria underlying the simple columnar epithelium of each villus typically contains a lymphatic lacteal and smaller systemic capillaries.

**Inflammatory bowel disease** may affect the small intestine and colon. **Ulcerative colitis** and **Crohn's disease**—the most common forms—lead to bleeding, diarrhea, and abdominal pain. Histologic alterations in Crohn's disease include deep ulcerations, prominent lymphoid aggregates, and dilated lymphatics.

*LMs of the wall of the jejunum at low magnification and an intestinal villus in transverse section*

# Gastroduodenal Junction





## Gastroduodenal Junction

---

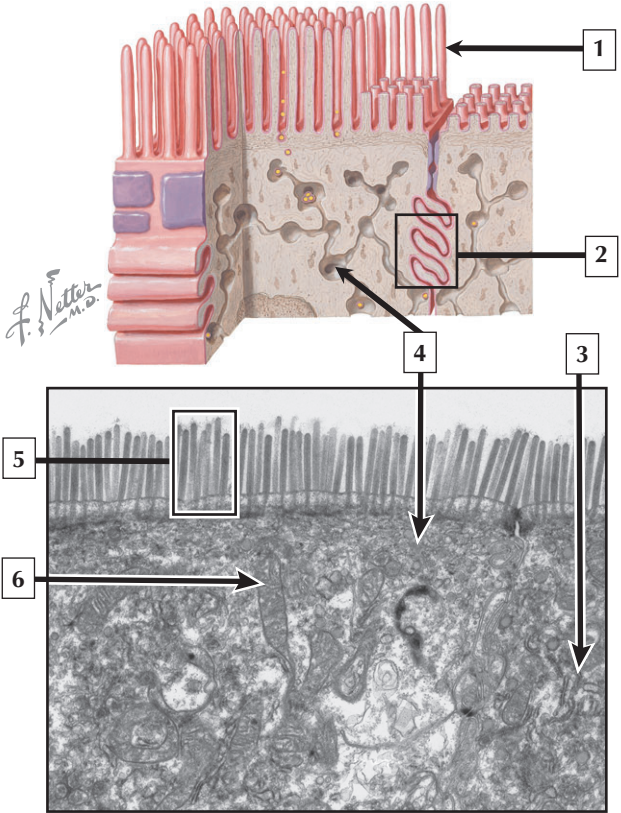
1. Pyloric sphincter (smooth muscle)
2. First part of duodenum
3. Pylorus of stomach
4. Lymphoid nodule with germinal center
5. Nucleus of enterocyte
6. Striated border (microvilli) of enterocyte
7. Goblet cell

**Comment:** The gastroduodenal junction is a broad transitional zone where the pylorus of the stomach contacts the first part of the duodenum. Histologically, it shows a gradual transition from gastric mucosa of the pylorus to the characteristic villous epithelium of the duodenal mucosa. Whereas gastric surface epithelium is lined by 1 type of surface mucous cell, simple columnar epithelium of the duodenum has 2 types of cells (enterocytes and goblet cells). The middle layer of smooth muscle in the muscularis externa of the pylorus is thickened to form the pyloric sphincter.

**Zollinger-Ellison syndrome** (or **gastrinoma**) is a disorder often caused by a tumor of enteroendocrine cells in the pylorus of the stomach or proximal duodenum. It leads to overproduction of the hormone, gastrin, and increased production of hydrochloric acid from parietal cells, leading to peptic ulcers. Usual mode of treatment is medication to reduce acid and heal the ulcers or surgical intervention in more severe cases.

*LMs of the gastroduodenal junction and duodenal mucosa*

# Enterocytes



7 The primary function of the cell above is \_\_\_\_\_.

# Enterocytes

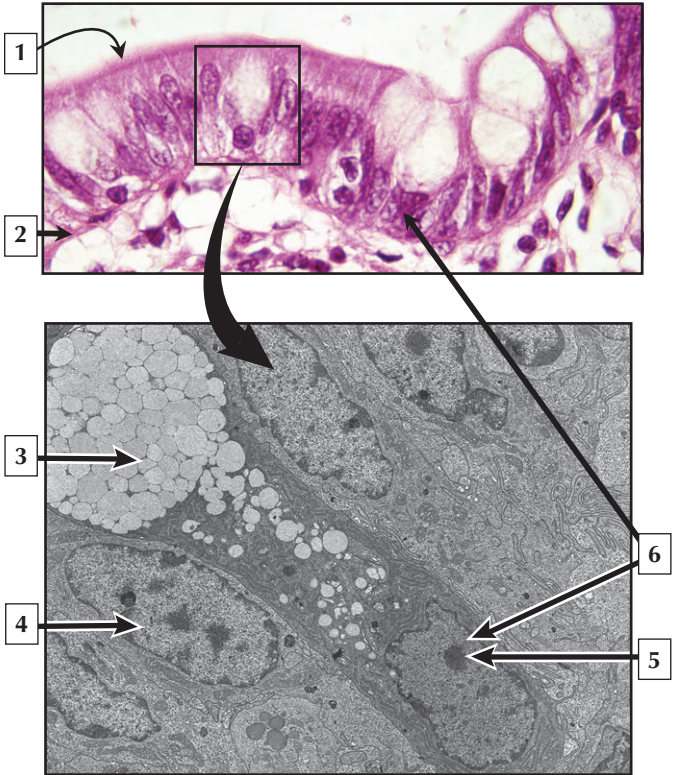
---

1. Microvillus
2. Interdigititation of lateral borders of enterocytes
3. Rough endoplasmic reticulum (RER)
4. Smooth endoplasmic reticulum (SER)
5. Striated border (microvilli)
6. Mitochondrion
7. Absorption

**Comment:** Enterocytes are cells that line the lumen of the small and large intestine. To enhance surface area, the apical plasma membrane is studded with microvilli. Interdigitating lateral borders of cells contain intercellular junctions that provide a permeability barrier. The cytoplasm contains a wide assortment of tightly packed organelles engaged in many functions such as breakdown of ingested nutrients, absorption, intracellular processing, and active transport.

Many congenital and acquired **malabsorption syndromes** affect the ability of enterocytes in the small intestine to adequately absorb, hydrolyze, and transport nutrients across the mucosa. **Celiac disease** (or **gluten enteropathy**) is the most common malabsorption syndrome occurring worldwide. It is caused by damage to enterocyte microvilli, which leads to abnormal villous architecture.

*Schematic and EM of the striated (microvillous) border of enterocytes*



## Goblet Cells

---

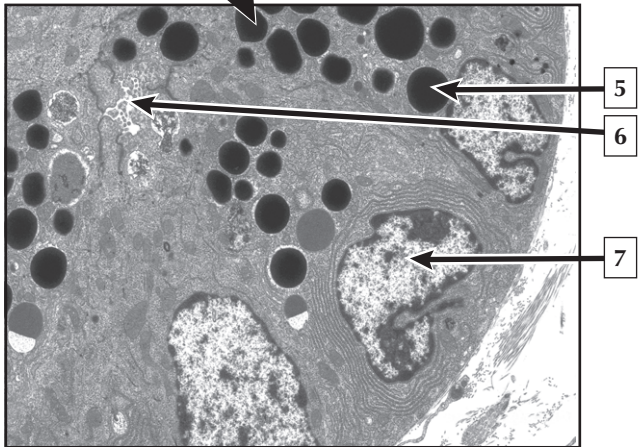
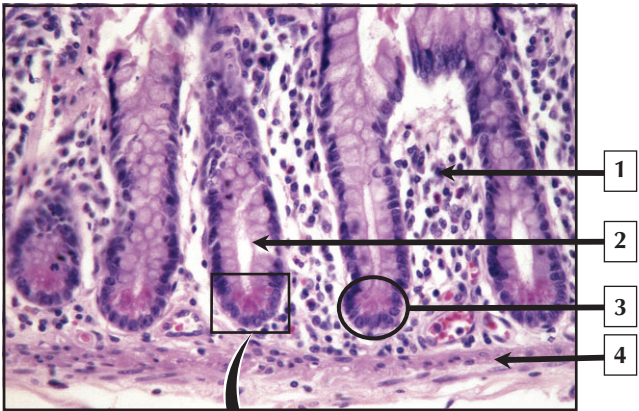
1. Striated border of enterocyte
2. Basement membrane
3. Mucin granules
4. Nucleus (euchromatin) of enterocyte
5. Nucleolus of goblet cell
6. Nucleus of goblet cell

**Comment:** Goblet cells produce mucus that covers the mucosa of the small and large intestine. Their number increases progressively from proximal duodenum to distal colon. In hematoxylin and eosin sections, they are flask-shaped cells with washed out cytoplasm and a basally located nucleus. Mucus is a highly viscous lubricant that also has antibacterial properties. Goblet cells synthesize, store, and discharge mucus by compound exocytosis. Large secretory vesicles (or mucin granules), which are derived from the Golgi complex, fill the apical cytoplasm prior to discharge of secretory product onto the luminal surface.

**Colonoscopy**—used by gastroenterologists to screen for colon cancer—enables the entire colon and terminal ileum to be evaluated at one examination. **Polyps** may be removed by therapeutic colonoscopy. They are abnormal elevations of colonic mucosa, which may progress from **adenomas** to **carcinomas**.

*LM of the epithelium of the ileum and EM of a goblet cell insinuated between enterocytes*

# Paneth Cells



## Paneth Cells

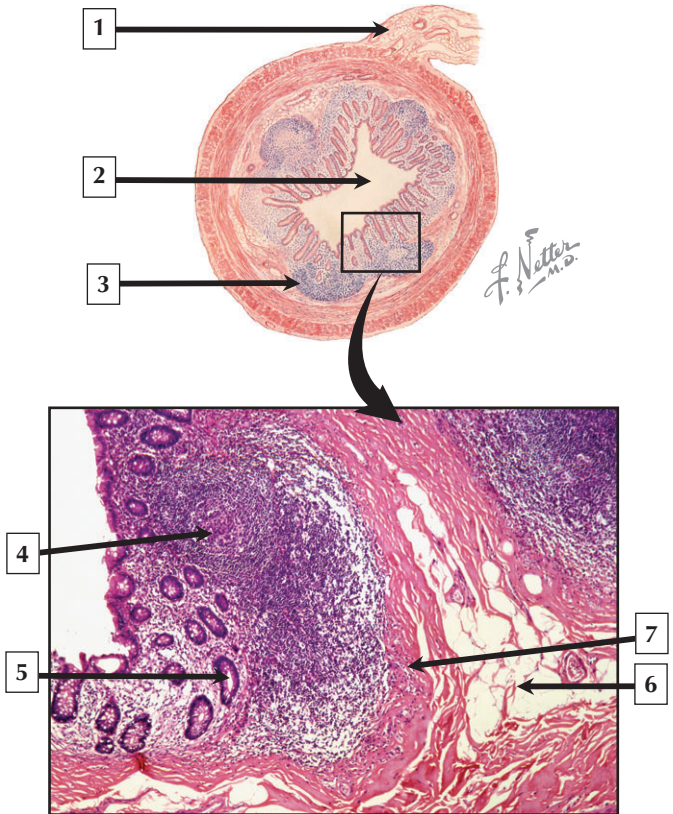
---

1. Lamina propria
2. Lumen of intestinal crypt
3. Paneth cells
4. Muscularis mucosae
5. Secretory vesicle (granule)
6. Microvilli projecting into lumen of intestinal crypt
7. Nucleus (euchromatin) of Paneth cell

**Comment:** Paneth cells are in the bases of crypts in the small intestine and appendix. They are most numerous in the ileum, and originate from undifferentiated stem cells, having a lifespan of 20 to 30 days. They mainly produce lysozyme, which regulates bacterial flora in the crypts. In hematoxylin and eosin sections, a distinct feature is the presence of prominent eosinophilic granules in the apical cytoplasm. Ultrastructurally, Paneth cells resemble other protein-secreting cells. The cytoplasm has many tightly packed and polarized organelles above a single, basal nucleus. Golgi-derived secretory vesicles are large and electron-dense. Vesicle contents are discharged by exocytosis by fusion of the vesicle's limiting membrane with the apical plasma membrane.

In **ulcerative colitis**, distal **metaplasia** of Paneth cells accompanies leukocyte infiltration of the lamina propria and distorted architecture of intestinal mucosa. Conversely, a loss of Paneth cells occurs in **adult immune enteropathy**.

*LM of bases of crypts in the ileum and EM of Paneth cells*





## Appendix

---

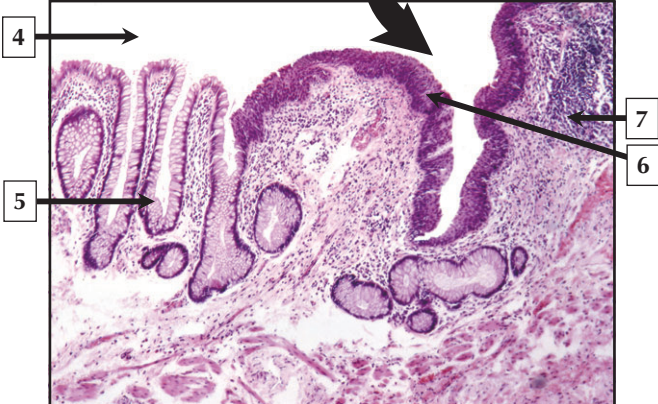
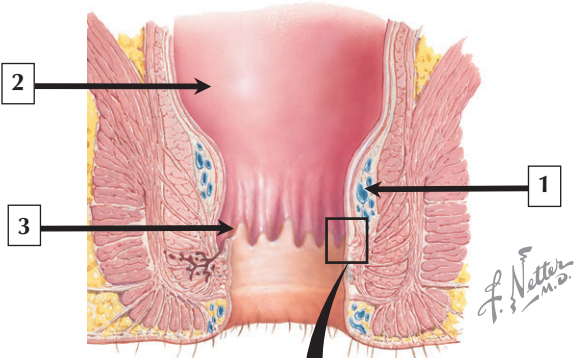
1. Mesoappendix
2. Lumen of appendix
3. Lymphoid nodule
4. Germinal center of lymphoid nodule
5. Intestinal crypt
6. Adipose tissue in submucosa
7. Muscularis mucosae

**Comment:** The appendix—a slender worm-shaped tube—projects from the blind end of the cecum. It is attached to the mesentery of the terminal ileum by the mesoappendix. Its lumen is wide and patent in early childhood, but may become obliterated with age. A distinctive feature of the appendicular wall is the presence of large numbers of lymphoid nodules in the mucosa and submucosa. They are part of gut-associated lymphoid tissue (GALT), which functions in immunologic defense. Germinal centers in these nodules are sites of B-lymphocyte production.

Obstruction of the narrow lumen of the appendix may lead to **appendicitis**—an inflammation that may cause pain in the lower right quadrant. **Acute appendicitis**, which initially affects the mucosa, may lead to abscess, necrosis, penetration into the peritoneal cavity, and a complication known as **peritonitis**. Benign and malignant tumors of the appendix may also occur. The most common are known as **carcinoid tumors**.

*Schematic of the appendix and LM of its mucosa and submucosa*

# Rectoanal Junction



## Rectoanal Junction

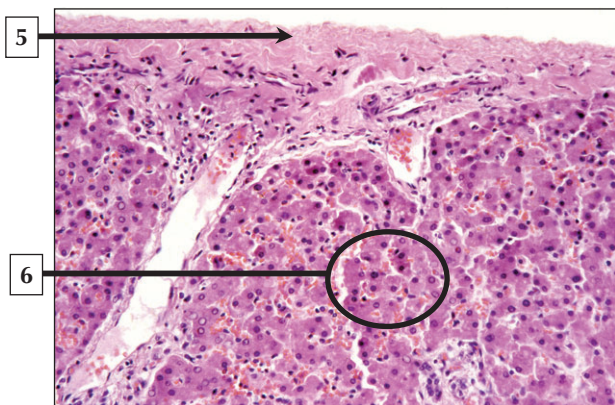
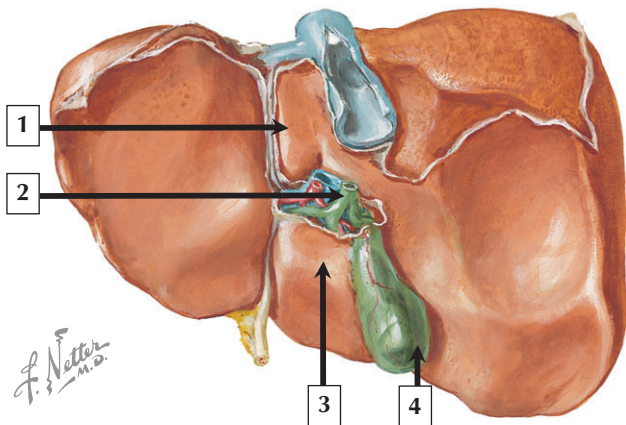
---

1. Superior hemorrhoidal venous plexus
2. Mucosal surface of rectum
3. Pectinate line
4. Lumen of rectum
5. Goblet cells in rectal crypt
6. Stratified squamous epithelium of anal canal
7. Lymphoid nodule

**Comment:** The rectal mucosa resembles that of the colon. It lacks villi and is lined by simple columnar epithelium with an abundance of goblet cells. Intestinal (rectal) crypts are longer than those elsewhere in the colon, and many solitary lymphoid nodules are in the lamina propria. The rectoanal junction is marked by a serrated area of mucosa, known as the pectinate line, where an abrupt change to stratified squamous nonkeratinized epithelium occurs. Submucosa above and below the pectinate line has a plexus of superior and inferior hemorrhoidal veins, respectively.

**Hemorrhoids** are varicosities in the plexus of hemorrhoidal veins that protrude into the rectum and anal canal, and are classified as either **internal** or **external hemorrhoids**. The most common type of rectal cancer is **adenocarcinoma**. Prognosis and treatment depend on how deeply it invades the rectal wall and surrounding lymph nodes. A high-fat, low-fiber diet is implicated in the development of most **colorectal cancers**.

*Schematic and LM of the rectoanal junction*



# Liver

---

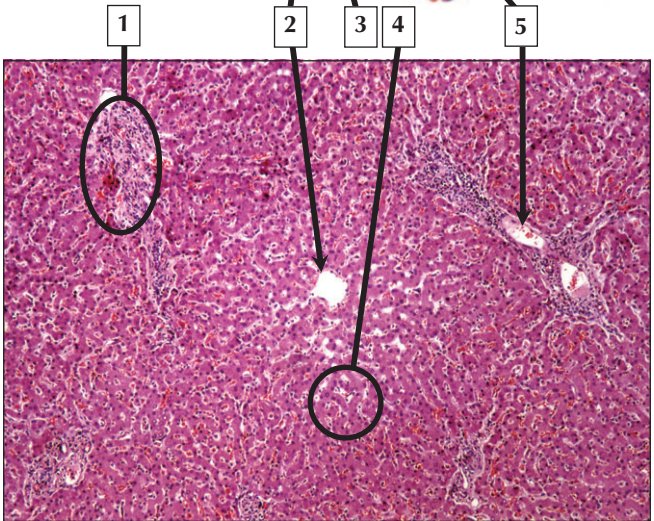
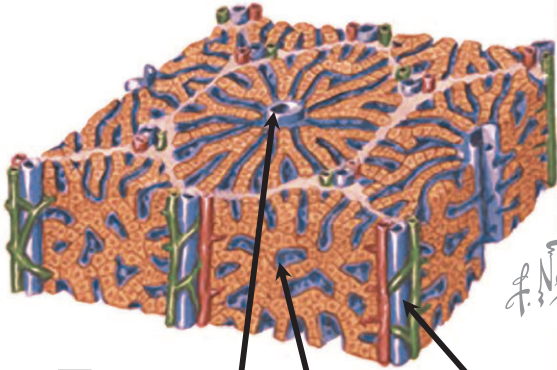
1. Caudate lobe
2. Common bile duct
3. Quadrate lobe
4. Gallbladder
5. Glisson capsule (dense irregular connective tissue)
6. Hepatic parenchyma

**Comment:** The liver—the largest and heaviest internal organ—is the most versatile and vascular. It is an accessory organ of the digestive tract—both exocrine and endocrine. It is wedge-shaped and situated immediately below the diaphragm in the upper right quadrant of the abdominal cavity. It has two main lobes—right and left. Two smaller lobes—caudate and quadrate—on the inferior (visceral) surface are poorly demarcated. The porta hepatis on the visceral surface is the gateway for the common bile duct, portal vein, and hepatic artery.

**Liver transplantation** is life-saving therapy for patients with chronic **end-stage liver disease**, advanced **cirrhosis**, **hepatocellular carcinoma**, and **acute liver failure**. In addition to the use of cadaver livers, improved surgical techniques have led to successful live-donor liver transplantation, whereby a part of the organ (commonly the right lobe) from a living donor is transplanted into a recipient (usually a family member).

*Schematic of the visceral surface of the liver and low-power LM of the liver showing Glisson capsule*

# Hepatic Lobule



## Hepatic Lobule

---

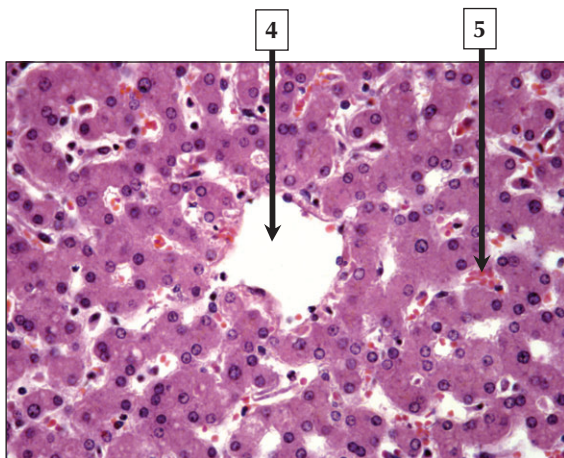
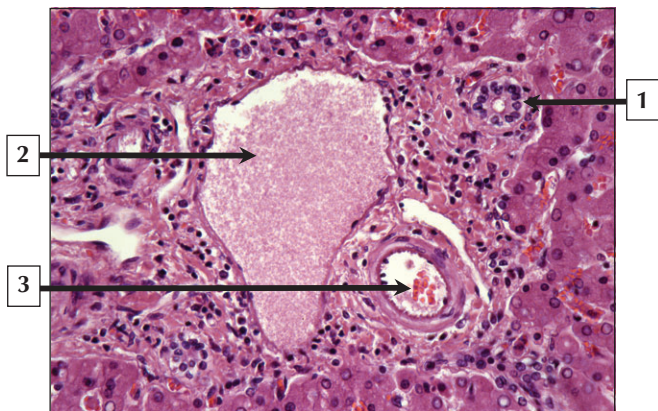
1. Portal tract
2. Central vein
3. Hepatic sinusoid
4. Hepatic parenchyma
5. Branch of portal vein

**Comment:** Hepatic lobules look like a mosaic of interlocking tiles within the substance of the liver. Each classic hepatic lobule takes the form of a prism and is about 1 mm in diameter and 2 mm long. The corners of each lobule contain portal triads surrounded by small amounts of connective tissue. In cross section, each lobule consists of plates of hepatocytes, 1 or 2 cells thick. Hepatocytes are separated by hepatic sinusoids and appear to radiate out from a small central vein. Hepatocyte arrangement resembles that of a sponge, with sinusoids represented by the spaces.

**Hepatocellular carcinoma**—the most common primary **malignant tumor** of the liver—arises from hepatocytes. Although it is relatively rare in developed countries, **chronic infection** with the hepatitis B and hepatitis C virus increases the risk of developing this **cancer**. While definitive diagnosis is made by core or fine-needle biopsy, blood alpha-fetoprotein is a useful diagnostic marker. Staging of this carcinoma helps predict prognosis and aids in choice of therapy. If the tumor is small, surgery and liver transplantation are potentially curative.

*Schematic of the liver acinus and low-power LM of the liver*

## Portal Tract and Central Vein





## Portal Tract and Central Vein

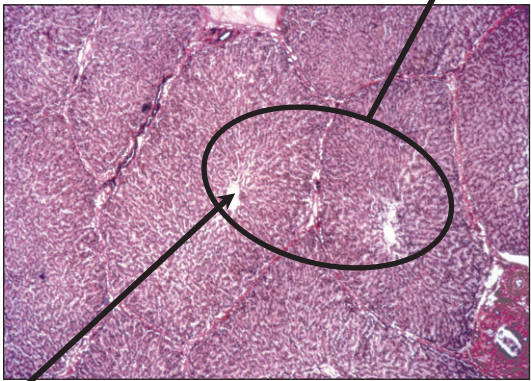
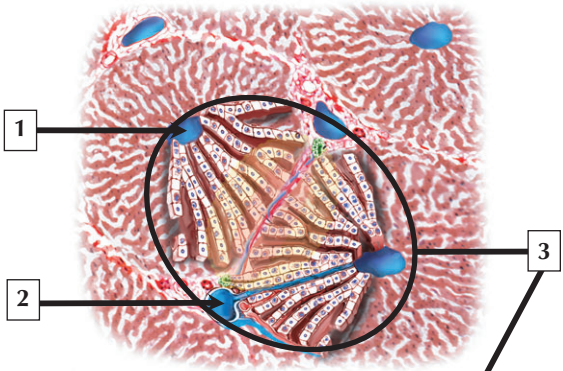
---

1. Bile ductule
2. Lumen of portal vein (venule)
3. Lumen of hepatic artery (arteriole)
4. Lumen of central vein
5. Erythrocytes in hepatic sinusoid

**Comment:** Each triad consists of a branch of the bile duct, portal vein, and hepatic artery, which progressively divide into smaller branches. The portal vein has terminal branches, which regularly give off inlet venules. They, in turn, empty directly into hepatic sinusoids that are in close contact with hepatocytes. Terminal branches of hepatic arteries, which ramify with portal vein branches, end as arterioles that also drain into sinusoids. Sinusoids converge toward a central vein, also known as a terminal hepatic venule, which unites with other central veins to form sublobular veins. They lead into larger hepatic veins that travel alone and branch repeatedly. The main drainage route of blood from the liver is the inferior vena cava.

Many clinical conditions can cause **hepatitis**—an inflammation of the liver. **Viral hepatitis** is caused by several different hepatotropic viruses, the most common of which are types A, B, and C. **Hepatitis A** is transmitted mainly via a fecal-oral route, and is especially common in poorly developed countries. It is characterized by hepatocellular injury, detection of serum IgM and anti-HAV antibody, and elevated serum aminotransferases.

*LMs of the liver showing a portal tract and a central vein*



4 This structure is in the center of a \_\_\_\_\_.

# Liver Acinus

---

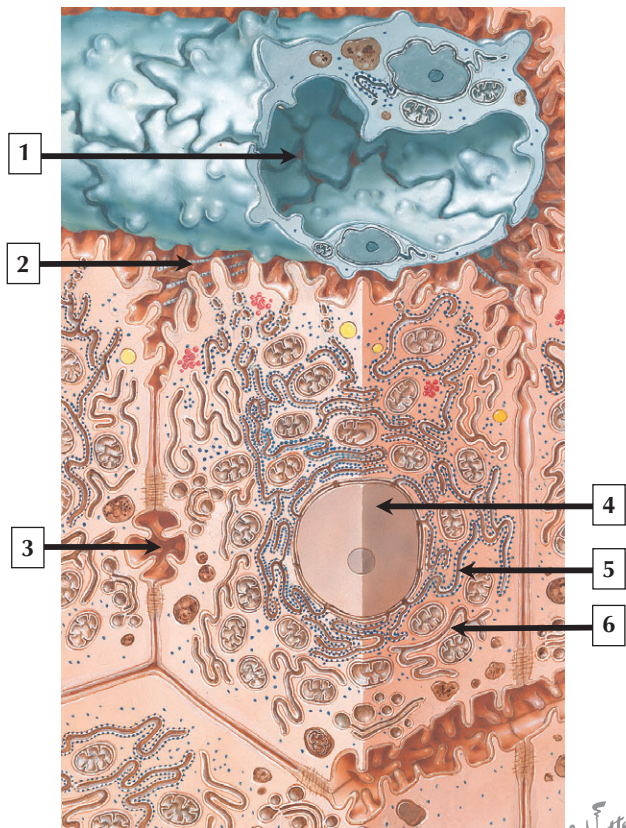
1. Central vein
2. Portal vein
3. Liver acinus
4. Classic hepatic lobule

**Comment:** The liver acinus—an oval to diamond-shaped area of liver parenchyma—is defined mainly in relation to blood supply. Although harder to visualize than the classic hepatic lobule, it is important functionally because it best describes metabolic changes that occur in relation to many diseases. The short axis is defined by distributing branches of the portal vein and hepatic artery that run along the border of 2 classic hepatic lobules. The long axis is a line drawn between the 2 central veins closest to the short axis. In contrast to the classic hepatic lobule, which has at its center the venous drainage (central vein), the liver acinus has at its center the portal and hepatic blood supply to liver parenchyma.

**Drug-induced liver injury** is a significant clinical problem because it often leads to liver failure, which may be life threatening. Knowledge of the zonation of the liver acinus is important in diagnosis of drug-induced liver injury. Overuse of acetaminophen – one of the most widely used analgesic medications worldwide – may cause profound liver toxicity. Manifestations of **acetaminophen poisoning** include abnormal elevation of liver enzymes and inflammatory damage to hepatic parenchyma. Biopsies of such cases show hepatocellular necrosis in zone 3 – the outermost peripheral zone of the liver acinus.

*Schematic of the liver acinus and low-power LM of the liver*

# Hepatocyte



*F. Netter  
M.D.*

# Hepatocyte

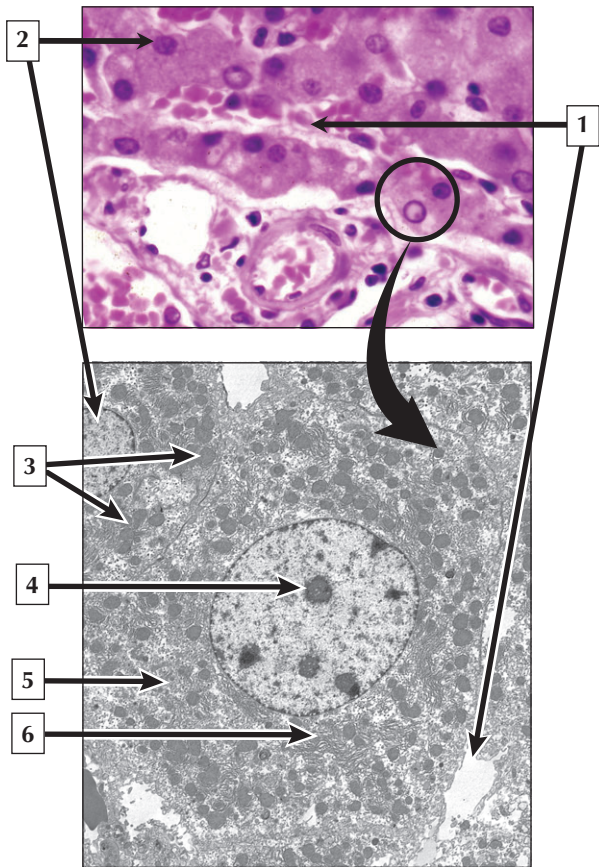
---

1. Lumen of hepatic sinusoid
2. Perisinusoidal space of Dissé
3. Bile canaliculus
4. Nucleus of hepatocyte
5. Rough endoplasmic reticulum
6. Smooth endoplasmic reticulum

**Comment:** Hepatocytes are polyhedral parenchymal cells derived from foregut endoderm. They comprise a network of interconnecting plates, 1 or 2 cells thick. Hepatic sinusoids are suspended within spaces between the hepatocytes. Narrow fluid-filled perivascular spaces—the perisinusoidal spaces of Dissé—are interposed between the endothelial lining of the sinusoids and the hepatocyte surfaces. These spaces allow exchange of soluble noncellular substances between blood and parenchyma. Apposing membranes of 2 adjoining hepatocytes form an intercellular channel—the bile canaliculus. Hepatocytes secrete bile into canaliculi. Hepatocyte lateral borders are reinforced with desmosomes and tight junctions that sequester contents of canalicular lumina and prevent bile leakage into the bloodstream.

**Alpha-1 antitrypsin deficiency**—a common **genetic liver disease** in infancy and childhood—is caused by a selective defect in the migration of secretory protein from the rough endoplasmic reticulum to the Golgi complex in the hepatocyte. It may cause **hepatitis** in newborns and often leads to **cirrhosis**.

*Schematic of a hepatocyte and hepatic sinusoid in the liver*



# Hepatocyte

---

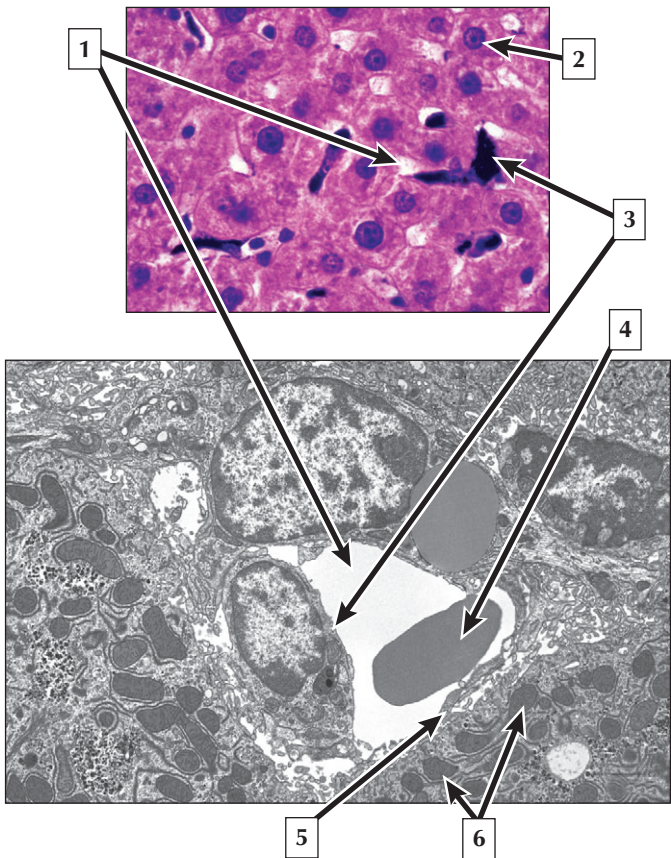
1. Hepatic sinusoid
2. Nucleus of hepatocyte
3. Mitochondria
4. Nucleolus
5. Golgi complex
6. Rough endoplasmic reticulum

**Comment:** Hepatocytes usually have a single, centrally placed, spherical nucleus, but binucleated cells and polyploid nuclei are common. One or more prominent nucleoli are often present. The hepatocyte has 3 functional surfaces: a canalicular (secretory) surface, a sinusoidal (absorptive) surface, and a surface between 2 closely apposed cells. The hepatocyte cytoplasm is densely packed with many organelles and inclusions. Mitochondria that provide energy as adenosine triphosphate (ATP) are abundant. Free ribosomes, multiple stacks of rough and smooth endoplasmic reticulum, and many Golgi complexes are also in the cytoplasm. Variable numbers of glycogen deposits, lysosomes, lipid droplets, and peroxisomes are also present.

**Excessive alcohol consumption** is toxic to the liver. Hepatocytes in the **alcoholic liver** accumulate large amounts of fat and show other morphologic changes, such as enlarged mitochondria, and distended smooth endoplasmic reticulum. Inclusions known as **Mallory bodies** may be scattered in damaged hepatocytes.

*LM of the parenchyma of the liver and EM of a hepatocyte*

## Hepatic Sinusoid





## Hepatic Sinusoid

---

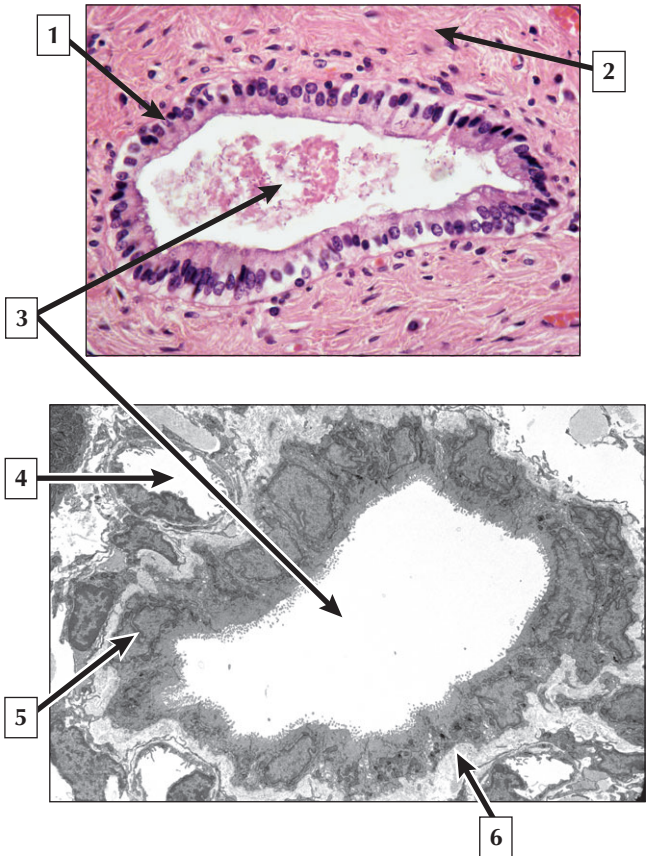
1. Lumen of hepatic sinusoid
2. Nucleus of hepatocyte
3. Kupffer cell
4. Erythrocyte
5. Endothelial cell of hepatic sinusoid
6. Mitochondria of hepatocyte

**Comment:** Hepatic sinusoids are in intimate contact with hepatocytes and are highly permeable for rapid exchange. They are drained by terminal branches of hepatic arteries and portal veins, so a mixture of arterial and venous blood is provided to them. Hepatic sinusoids have a diameter of 9-15  $\mu\text{m}$  and are larger and less regular in shape than capillaries. Their attenuated walls are lined by flattened endothelial cells interspersed with plumper Kupffer cells. Derived from blood monocytes, Kupffer cells contain numerous endocytotic vesicles, lysosomes, and phagocytosed particulate matter. Kupffer cells remove viruses, bacteria, tumor cells, and parasites from the circulation.

Cirrhosis of the liver, the end stage of chronic liver disease, is usually caused by alcohol abuse, viral hepatitis, or biliary obstruction. It is characterized by excessive deposition of connective tissue stroma leading to persistent liver cell necrosis and marked disruption in microscopic architecture of the liver. Progression of disease may cause portal hypertension and liver failure.

*LM of Kupffer cells in the liver after ingestion of carbon particles, and EM of a hepatic sinusoid.*

## Biliary Duct System



## Biliary Duct System

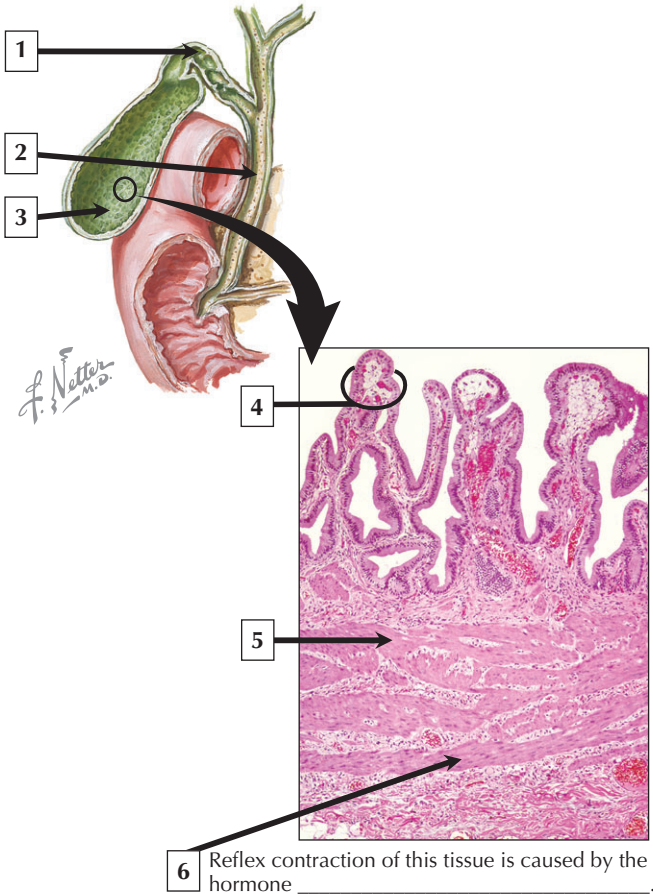
---

1. Simple columnar epithelium of bile duct
2. Dense irregular connective tissue (stroma)
3. Lumen of bile duct
4. Lumen of capillary
5. Nucleus (euchromatin) of simple cuboidal epithelial duct cell
6. Basement membrane

**Comment:** Bile is secreted by hepatocytes into bile canaliculi—the first and smallest biliary passages (about 1  $\mu\text{m}$  in diameter). About 0.5 ml of bile is produced by hepatocytes each minute. Canaliculi, which are intercellular channels between adjacent hepatocytes, are best seen with electron microscopy. Canaliculi, in turn, converge at the periphery of each hepatic lobule to form small intrahepatic bile ducts lined by a single layer of cuboidal epithelial cells. Larger bile ducts with a simple columnar epithelium around a central lumen are, in turn, surrounded by dense irregular connective tissue.

Reduced bile flow or formation is known as **cholestasis**. It may occur within (intrahepatic) or outside (extrahepatic) the liver, and often leads to **jaundice**—a yellowing of the skin and sclera of the eyes. Many different causes of **extrahepatic cholestasis** may lead to partial or complete obstruction of the duct system. **Intrahepatic cholestasis** is a pathologic condition of reduced bile formation. It may be due to an ionic pump abnormality, permeability defect, or altered contractility of canaliculi and bile ducts.

*LM and EM of intrahepatic bile ducts in transverse section*



# Gallbladder

---

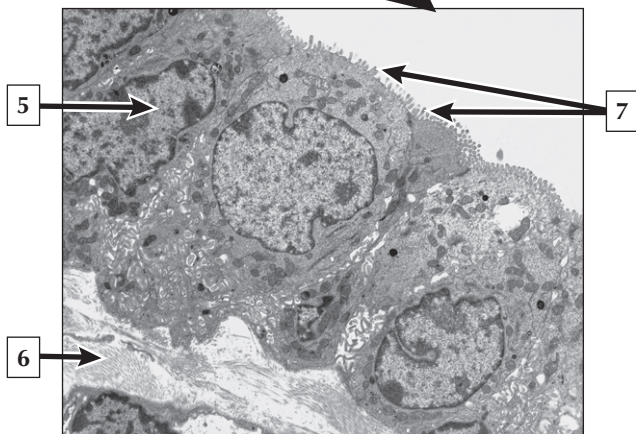
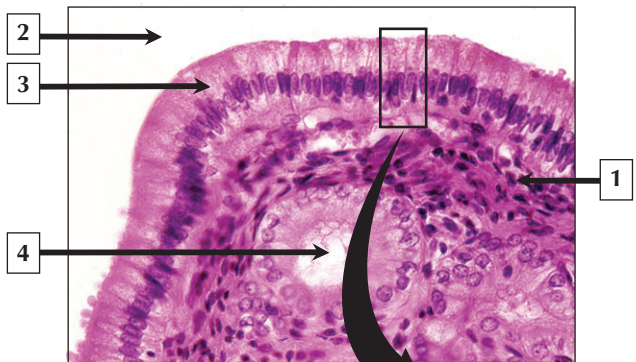
1. Cystic duct
2. Common bile duct
3. Body (corpus) of gallbladder
4. Mucosal fold
5. Muscularis (smooth muscle)
6. Cholecystokinin

**Comment:** The gallbladder is a pear-shaped hollow organ that measures 3 to 5 cm in diameter and 10 cm long. It stores bile and concentrates it by absorbing water and electrolytes. The organ has a capacity of about 50 ml and drains through the cystic duct, which connects to both the liver and duodenum by the biliary duct system. Histologically, the gallbladder wall consists of 3 layers: a mucosa, a muscularis, and an adventitia or serosa. The mucosa of an empty or contracted gallbladder shows many folds lined by simple columnar epithelium, which flatten out when the organ fills with bile.

**Cancers** arising from the epithelium of the gallbladder and the biliary tract are rare. Definitive diagnosis is difficult, and overall prognosis is usually poor. In most patients, **chronic gallbladder inflammation** typically caused by **gallstones** is a major contributing factor. At diagnosis, most patients have regional lymph node **metastasis** and tumor invasion to adjacent organs.

*Schematic of the gallbladder and bile ducts and low-power LM of part of a nondistended gallbladder*

## Gallbladder Epithelium



## Gallbladder Epithelium

---

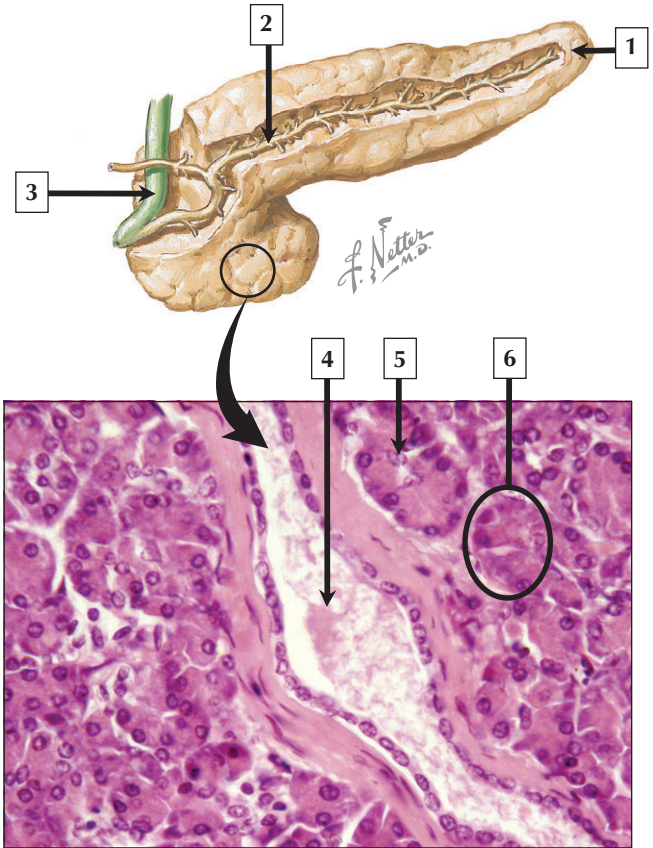
1. Lamina propria
2. Gallbladder lumen
3. Simple columnar epithelium
4. Mucous gland
5. Nucleus (euchromatin) of gallbladder epithelial cell
6. Connective tissue (lamina propria)
7. Microvilli on apical cell surface

**Comment:** The gallbladder lumen is lined by simple columnar epithelial cells with many microvilli on their apical surface. Each cell has a single spherical nucleus, usually situated toward the base of the cell. Basal infoldings of the plasma membrane and lateral interdigitations of adjacent cell membranes reflect the role of these cells in ion transport. The epithelium rests on a delicate basement membrane that separates it from underlying lamina propria. The gallbladder stores bile, which is released by reflex contraction of smooth muscle cells in the underlying muscularis in response to the hormone cholecystokinin.

**Cholelithiasis** is the presence of stones in the gallbladder or extrahepatic biliary ducts. Gallstones may also cause gallbladder inflammation known as **cholecystitis**, characterized by mucosal inflammation with abnormal thickening of the muscularis layer.

**Laparoscopic surgery** is the most common treatment for gallstones.

*LM of gallbladder mucosa in the neck region and EM of gallbladder epithelium*





# Pancreas

---

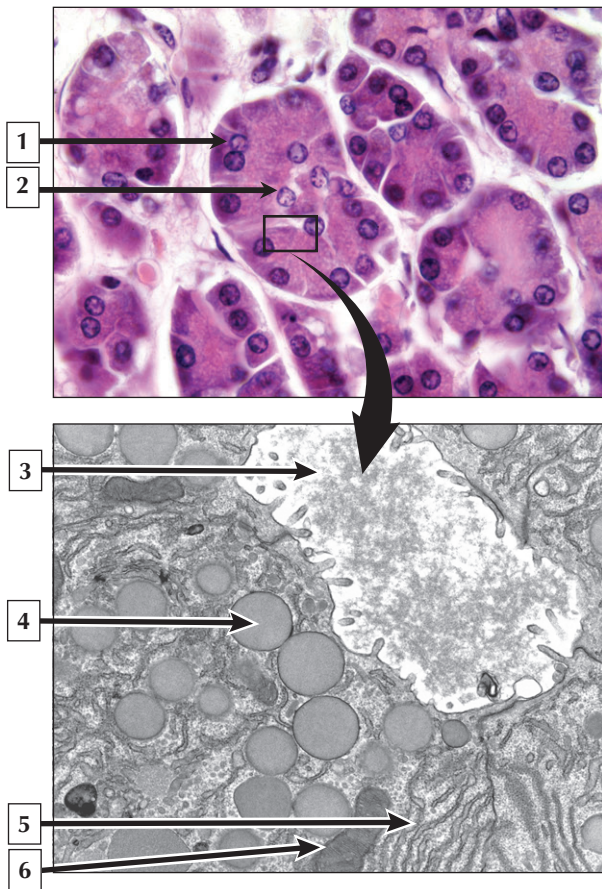
1. Tail of the pancreas
2. Principal pancreatic duct (Wirsung)
3. Common bile duct
4. Lumen of intralobular duct
5. Centroacinar cell
6. Pancreatic acinus

**Comment:** The parenchyma of the pancreas develops embryonically from foregut endoderm. In the adult, it is an accessory digestive gland, 18 cm to 20 cm long and about 100 g in weight. It has a head, neck, body, and tail. It is covered by a thin connective tissue capsule, which sends inward septae that subdivide the gland into indistinct lobules. The pancreas has both exocrine and endocrine parts; the exocrine part is about 99% of the gland by weight. Secretory acini and their associated ducts constitute the parenchyma of the exocrine pancreas. Two cell types—acinar and centroacinar cells—with different functions comprise each acinus.

Of all malignancies of the digestive tract, **pancreatic adenocarcinoma** is the second leading cause of death from **cancer**. **Tumors** arise from pancreatic ducts or acinar cells and have a tendency to spread rapidly. Signs and symptoms usually appear when the disease is already well advanced. High-protein and high-fat diets, cigarette smoking, and exposure to industrial carcinogens are thought to be causative factors.

*Schematic of the pancreas and low-power LM of the pancreas showing acini and a duct*

## Pancreatic Acinus



## Pancreatic Acinus

---

1. Pancreatic acinar cell
2. Centroacinar cell
3. Lumen of pancreatic acinus
4. Secretory vesicle of pancreatic acinar cell
5. Rough endoplasmic reticulum
6. Mitochondrion

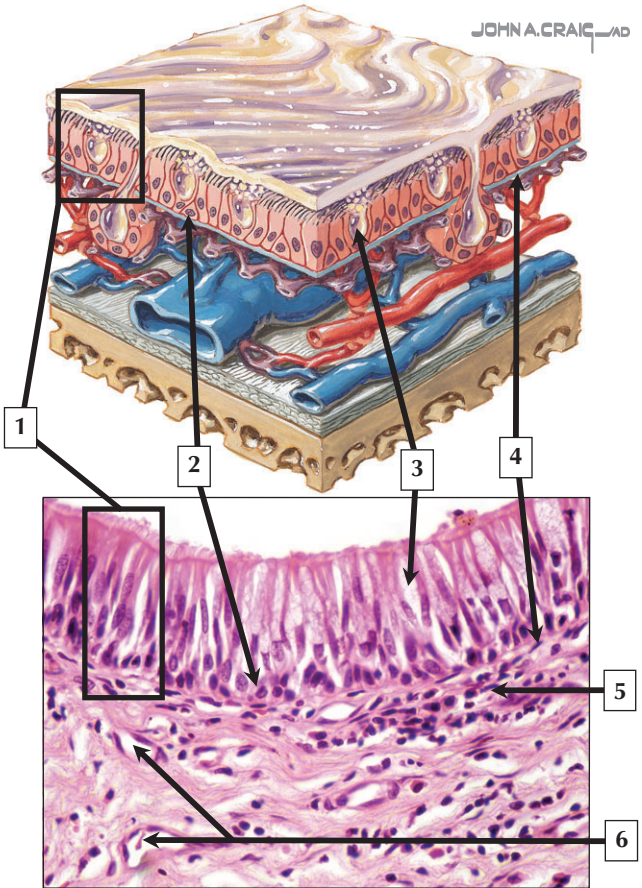
**Comment:** The pancreas is a compound tubulo-acinar gland. Each acinus has a single layer of cuboidal-to-pyramidal shaped acinar cells around a central lumen. The cells secrete several digestive enzymes or their inactive precursors. A salient feature is the presence of initial parts of the excretory duct system, composed of centroacinar cells, which partially protrude into the acinar lumen. Acinar cells are polarized cells with all the organelles needed for protein synthesis for export. Many membrane-bound secretory vesicles are in the apical cytoplasm prior to discharge by exocytosis into the acinar lumen.

An **acute inflammatory disorder** of the exocrine pancreas, known as **acute pancreatitis**, is often associated with **alcoholism** or excessive alcohol consumption. It may have mild to life-threatening clinical manifestations. Acinar cell injury or pancreatic duct obstruction leads to elevated serum amylase and lipase levels, which are diagnostic markers for this disorder.

*LM of pancreatic acini and EM of the apical parts of several acinar cells*

# Respiratory Mucosa

JOHN A. CRAIG AD



# Respiratory Mucosa

---

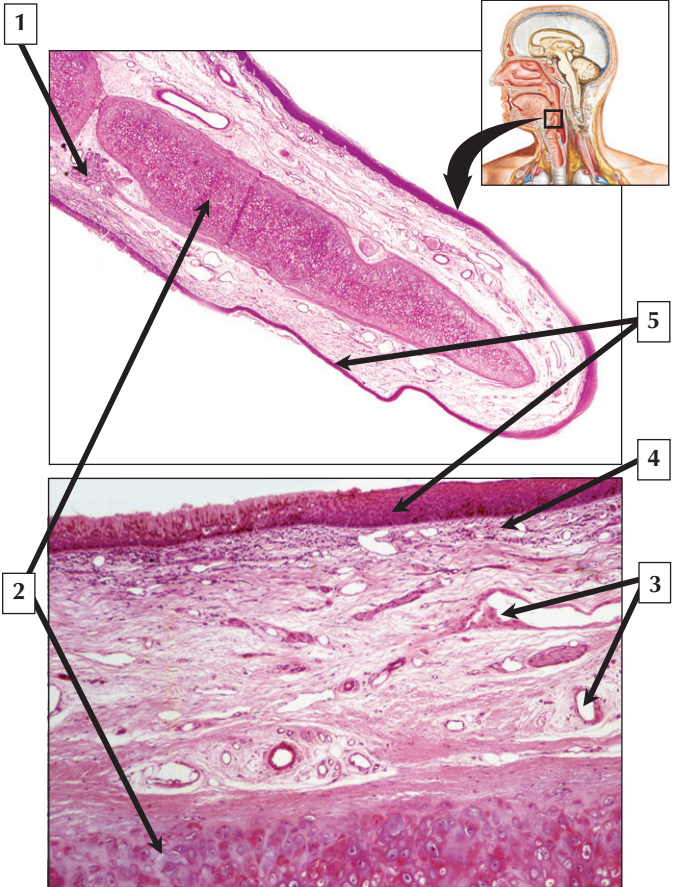
1. Respiratory (pseudostratified) epithelium
2. Basal cell
3. Goblet cell
4. Basement membrane
5. Lamina propria
6. Capillaries

**Comment:** The upper airways comprise the conducting (conveys air from outside the body to the lungs) part of the respiratory system. The conducting passageways consist of the nose and paranasal sinuses, pharynx, larynx, trachea, bronchi, and bronchioles. They are lined by respiratory mucosa, which consists of pseudostratified ciliated columnar epithelium with goblet cells and an underlying, richly vascularized lamina propria. Goblet cells produce mucus, which entraps foreign particles. Basal cells in the epithelium rest on a basement membrane and serve as stem cells for continual replacement of the other cells in the epithelium.

**Acute or chronic infections**, such as those associated with the common cold, may lead to swelling of the respiratory mucosa (mucous membrane) and respiratory congestion. **Sinusitis** is a common clinical condition involving inflammation of the mucous membrane of the sinuses. Inflamed sinuses become blocked with mucus and can become infected.

*Schematic of the nasal or sinus wall and LM of respiratory mucosa lining the nasal cavity*

# Epiglottis



# Epiglottis

---

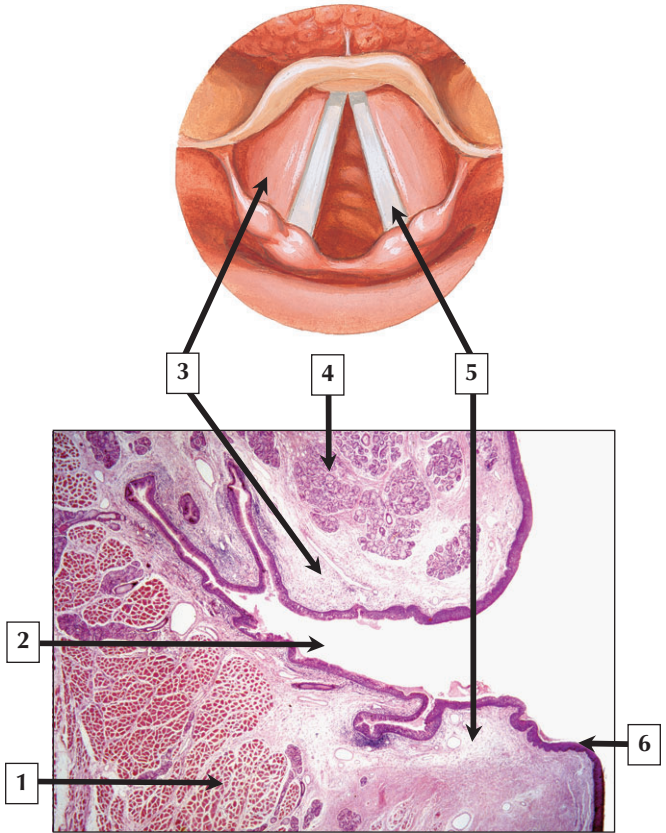
1. Seromucous gland
2. Elastic cartilage
3. Blood vessels
4. Loose connective tissue (lamina propria)
5. Stratified squamous nonkeratinized epithelium

**Comment:** The epiglottis is an unpaired leaf-shaped structure that covers the entrance to the larynx during swallowing. Highly flexible elastic cartilage in the central core forms a supportive framework. Because the lingual surface of the epiglottis is subject to wear-and-tear, it is covered by stratified squamous nonkeratinized epithelium. It changes to a stratified columnar, and, then, pseudostratified epithelium on the laryngeal surface. Small seromucous glands are scattered in the underlying connective tissue. At rest, the epiglottis is usually upright and allows air to pass into the larynx and the rest of the lower respiratory airways. During swallowing, it folds back like a flap to cover the entrance to the larynx, to prevent food and liquid from entering the trachea.

A common **congenital anomaly** of infancy is **laryngomalacia**—an abnormal flaccidity of the epiglottis due to faulty maturation of its cartilage. It leads to epiglottal prolapse and partial upper airway obstruction during inspiration. Rarely life threatening, it is the most common cause of noisy breathing (**stridor**) in infants.

*Schematic of the upper respiratory tract and LMs of the epiglottis at low and medium magnification*

# Larynx and Vocal Cord





## Larynx and Vocal Cord

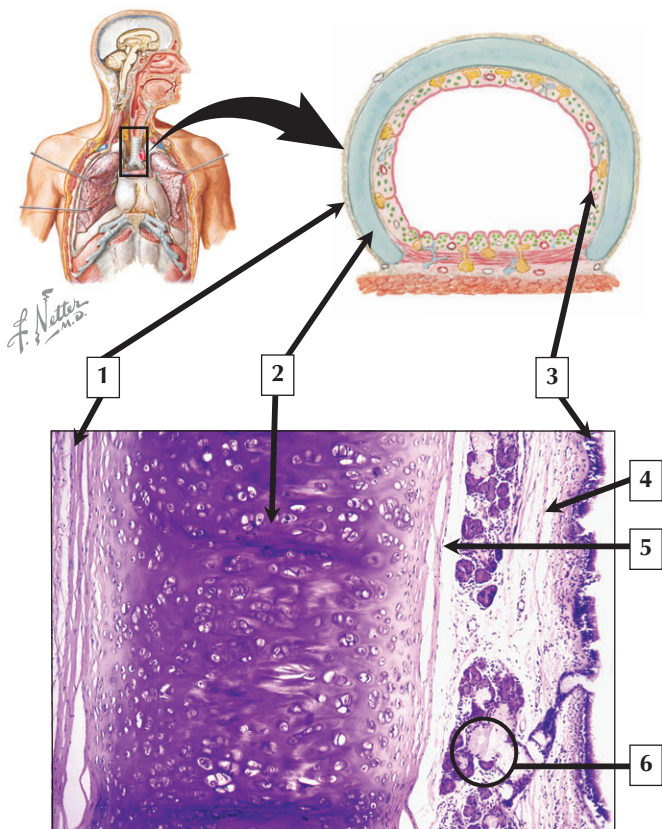
---

1. Vocalis (skeletal) muscle
2. Laryngeal ventricle
3. False (or ventricular) folds
4. Seromucous gland
5. True vocal folds (or cords)
6. Stratified squamous nonkeratinized epithelium

**Comment:** The larynx, which plays a critical role in phonation (speech), lies between pharynx and trachea and is 4 cm to 5 cm long. Part of the conducting part of the respiratory system, it contains 2 sets of prominent folds—the false (or ventricular) and true vocal folds (or cords). Whereas false vocal folds contain mixed seromucous glands, true vocal cords contain elastic fibers into which skeletal muscle fibers of the vocalis muscle insert. Stratified squamous nonkeratinized epithelium normally covers the true vocal cords, which are subject to wear-and-tear induced by friction. Vibration of the vocal cords controls airflow and results in the production of sounds during phonation. Closure of the larynx during swallowing also prevents food from entering the lower airways.

Most **cancers** of the larynx are **laryngeal squamous cell carcinomas**. They are usually associated with advancing age and often tend to **metastasize** to distant sites. Cigarette smoking and chronic ingestion of alcohol are risk factors. Symptoms include **hoarseness** or other voice changes and persistent **cough**. Diagnosis is by physical examination and **laryngoscopy**.

*Schematic (frontal section) and low-power LM of the larynx*



# Trachea

---

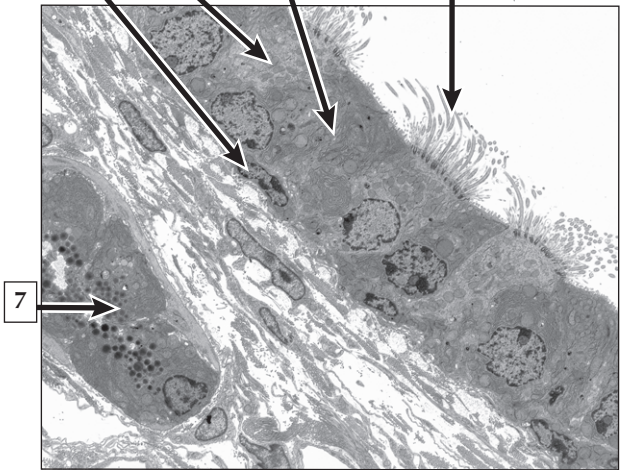
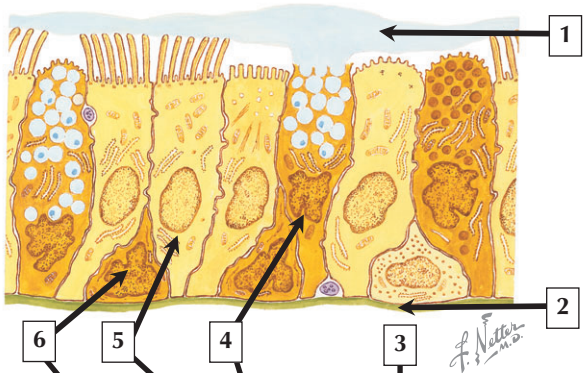
1. Adventitia
2. Hyaline (tracheal) cartilage
3. Respiratory (pseudostratified) epithelium
4. Loose connective tissue (lamina propria)
5. Perichondrium
6. Seromucous gland

**Comment:** The trachea is a semirigid tube, 2 to 3 cm in diameter and 15 to 20 cm long, and has an outermost adventitia of connective tissue. About 16 to 20 crescent-shaped hyaline cartilage rings in the tracheal wall ensure patency of the lumen. They also provide rigidity and maintain shape. The lining epithelium is typical respiratory (pseudostratified) epithelium, which rests on a basement membrane. Most cells are ciliated columnar cells, which are interspersed with a few goblet cells. Metaplasia of the epithelium occurs in response to local friction and chronic coughing. The underlying lamina propria is loose, highly cellular connective tissue. Mixed seromucous glands extend into the submucosa.

In the surgical procedure known as **tracheotomy**, an incision is made in the trachea through the front of the neck to artificially open the airway. A metal, plastic, or silicone **tracheostomy tube** is then inserted into the opening to permit normal breathing. Tracheotomies may be performed in emergencies or for long-term mechanical ventilation of critically ill patients.

*Schematic and LM of the trachea in transverse section*

# Tracheal Epithelium



# Tracheal Epithelium

---

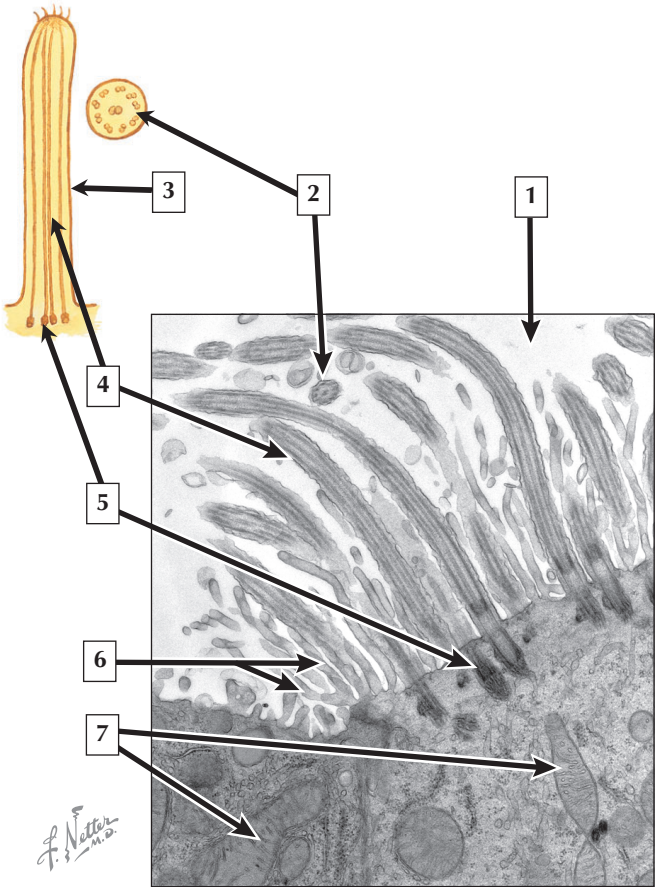
1. Mucus
2. Basement membrane
3. Cilia
4. Goblet cell
5. Ciliated cell
6. Basal cell
7. Seromucous gland

**Comment:** The surface epithelium of the trachea consists mainly of tall, ciliated columnar cells intermixed with goblet-shaped mucous cells (goblet cells) and small, rounded to triangular basal cells. Ciliated columnar cells bear apical cilia, which beat synchronously to sweep entrapped particles toward the oral cavity. Goblet cells have distinctive shapes and produce a surface layer of mucus, which traps foreign particulate matter. Small, basal cells immediately above the basement membrane are stem cells for continuous cellular renewal. A basement membrane supports the epithelium, separating it from underlying lamina propria. Deeply situated seromucous glands deliver secretions via small ducts to the luminal surface.

**Cystic fibrosis** is a genetic disorder caused by defective  $\text{Cl}^-$  ion transport in mucous cells of seromucous glands in the respiratory tract. Resulting thick and sticky mucus predisposes patients to developing severe and life-threatening **lung infections**. **Gene therapy** is a promising curative approach to this disease.

*Schematic and electron micrograph (EM) of the tracheal mucosa*

# Respiratory Cilia



## Respiratory Cilia

---

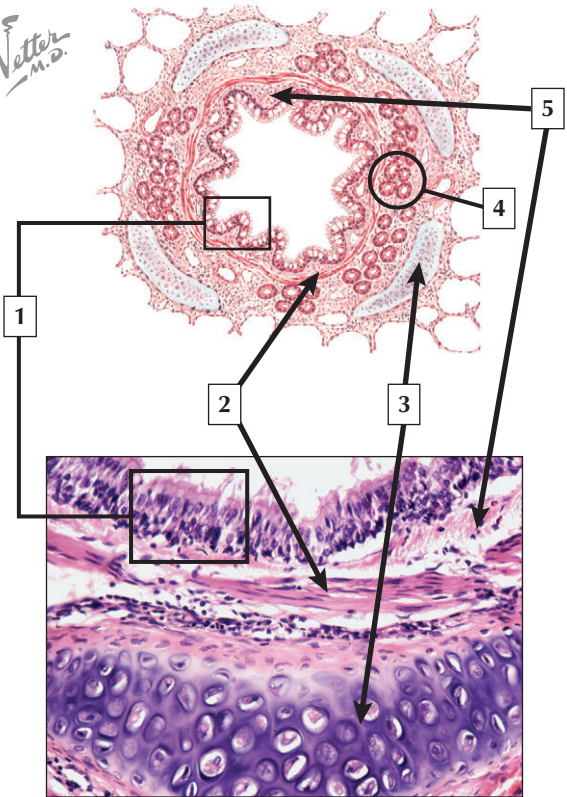
1. Airway lumen
2. Cross section of cilium
3. Longitudinal section of cilium
4. Microtubules
5. Basal body
6. Microvilli
7. Mitochondria

**Comment:** Cilia are luminal surface projections of the cells that extend from the nasal cavity to respiratory bronchioles. One cell may bear several hundred. Their major role is to move mucus and entrapped particulate matter, including dust and dead cells, over the cell surfaces toward the oral cavity, where they are eliminated or swallowed. They are  $0.25\ \mu\text{m}$  in diameter and vary in length from  $5\ \mu\text{m}$  to  $10\ \mu\text{m}$  and are anchored to a basal body. They contain a “9 + 2” arrangement of microtubules and beat rhythmically to move mucus and entrapped material over the cell surface. The beating of cilia, at 10 to 25 beats per second, resembles a breaststroke in swimming with a power and a recovery component.

Cilia may be damaged by heavy cigarette smoking, which may lead to **chronic respiratory infections**. **Immotile cilia (Kartagener) syndrome** is a genetic disorder caused by deficient dynein side arms of ciliary microtubules. It often leads to **sinusitis** and **bronchiectasis** (chronic enlargement of bronchial airways).

*Schematic of a cilium and EM of a ciliated cell of the trachea*

*F. Netter M.D.*





## Bronchus

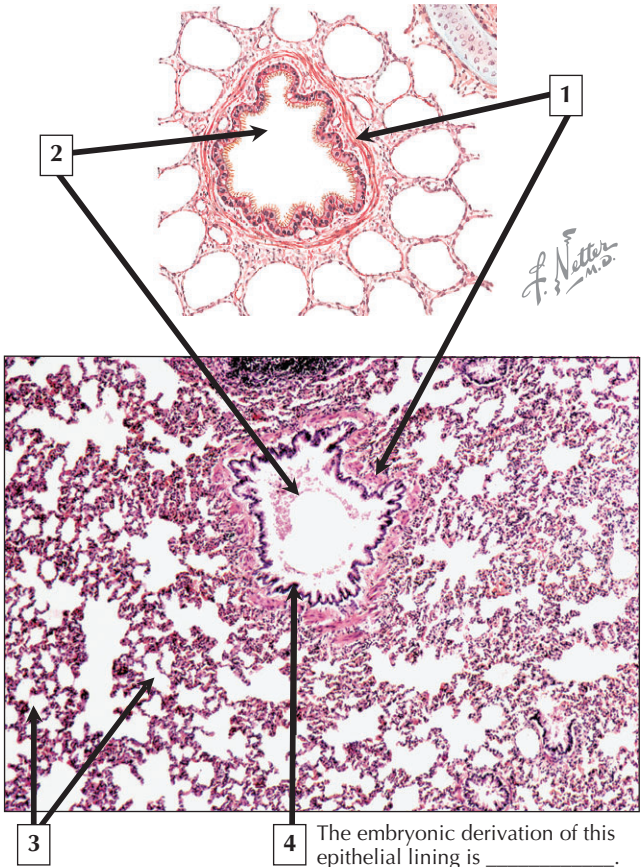
---

1. Respiratory (pseudostratified) epithelium
2. Smooth muscle
3. Hyaline cartilage plate surrounded by perichondrium
4. Submucosal (seromucous) gland
5. Lamina propria (loose connective tissue)

**Comment:** Although bronchi have a smaller diameter compared with the trachea, they closely resemble the trachea histologically and both conduct and condition the air on its way to the lungs. Bronchial walls are held open by hyaline cartilage, which prevents luminal collapse. Bronchial epithelium is pseudostratified and consists mostly of ciliated, goblet, and basal cells. The lamina propria, a loose connective tissue, is separated from the epithelium by a basement membrane. Smooth muscle, situated between the epithelium and cartilage, is under autonomic control. Submucosal glands underneath the smooth muscle release secretory products directly onto the epithelial surface.

**Lung cancer** is a leading cause of mortality worldwide, and most deaths are due to the effects of cigarette smoking. Most **tumors** of the respiratory system are **carcinomas** arising from respiratory epithelium of the tracheobronchial tree or pneumocytes of pulmonary alveoli. **Non-small cell carcinomas**—the most common—grow rapidly and usually metastasize. They respond poorly to **chemotherapy** or radiation. Slow-growing **carcinoid tumors** are neuroendocrine neoplasms from pleuripotential basal cells of respiratory epithelium.

*Schematic and LM section of the wall of a bronchus.*



## Bronchiole

---

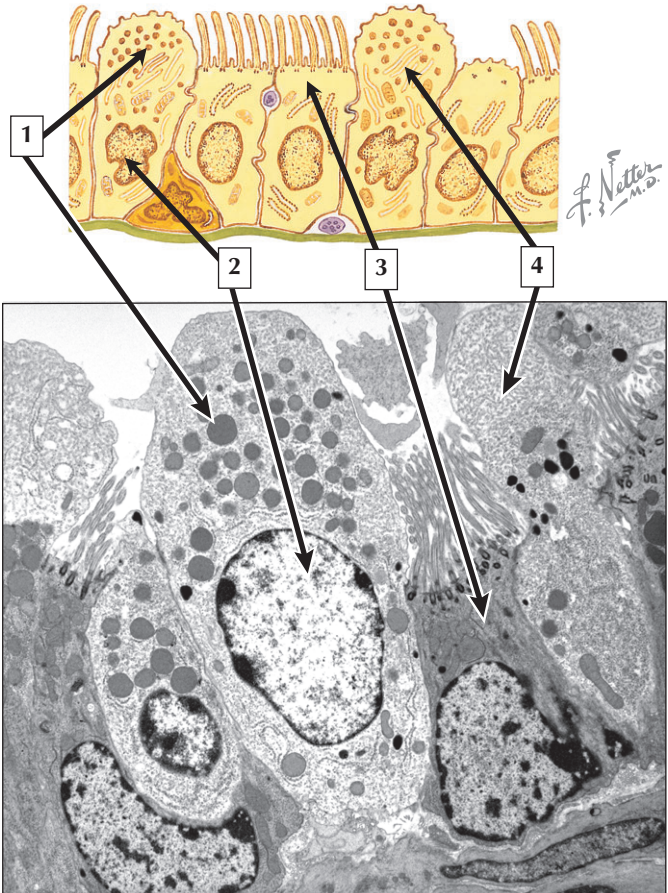
1. Smooth muscle
2. Lumen of bronchiole
3. Pulmonary alveoli
4. Foregut endoderm

**Comment:** Intrapulmonary airways are characterized by successive, dichotomous branching, with about 20 generations extending from the bronchi to the respiratory bronchioles. Terminal bronchioles are distal to bronchi and lead into respiratory bronchioles, which have small, spherical alveolar outpocketings in their walls. Bronchioles are 1 mm or less in diameter and have very thin walls. In contrast to the walls of bronchi, those of bronchioles are devoid of glands and cartilage. Helically arranged smooth muscle, however, is a prominent feature of bronchiolar walls. In addition, bronchioles have an abundance of elastic fibers, which are continuous with those of adjacent pulmonary alveoli.

Bronchioles are affected in **asthma**—a common clinical condition—whereby hypercontraction of bronchiolar smooth muscle causes excessive narrowing of the bronchiolar lumen and increases resistance to airflow. Symptoms of **dyspnea**, **coughing**, **respiratory distress**, and **wheezing** result from bronchial spasm, bronchial wall edema in bronchi and bronchioles, and hypersecretion of mucous glands.

*Schematic and LM of the lung that show a terminal bronchiole at low magnification and in transverse section*

# Clara Cells



## Clara Cells

---

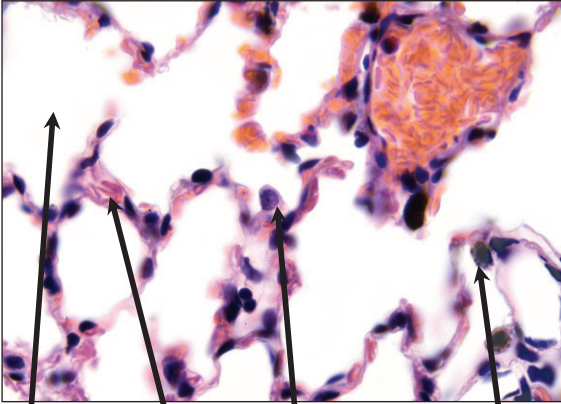
1. Secretory vesicles in apical cytoplasm
2. Nucleus of Clara cell
3. Cytoplasm of ciliated cell
4. Smooth endoplasmic reticulum

**Comment:** Clara cells are nonciliated columnar, secretory cells unique to bronchioles. They constitute the majority of epithelial cells lining the lumina of these airways. They are scattered amongst ciliated cells, and their apical surfaces bulge into the bronchiolar lumen. Their apical cytoplasm has abundant smooth endoplasmic reticulum and electron-dense secretory vesicles. Their secretions are believed to play antiinflammatory roles. Clara cells engage in water and electrolyte balance, detoxify inhaled substances, and elaborate a surfactant-like substance. They are also mitotically active stem cells that respond to bronchiolar injury and provide renewal of nonciliated and ciliated bronchiolar epithelial cells.

**Chronic obstructive pulmonary disease (COPD)**—characterized by partial obstruction of airflow in the airways—is a group of disorders that includes **chronic bronchitis**, **emphysema**, and **chronic asthma**. Commonly due to cigarette smoking and inhalation of other airborne irritants, COPD is not fully reversible. It leads to loss of airway elasticity and increased mucus production.

*Schematic and EM showing salient features of bronchiolar epithelium*

# Pulmonary Alveoli



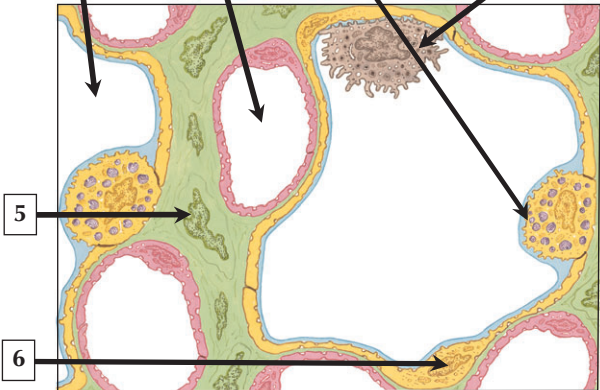
4

3

2

1

*F. Netter M.D.*



5

6

## Pulmonary Alveoli

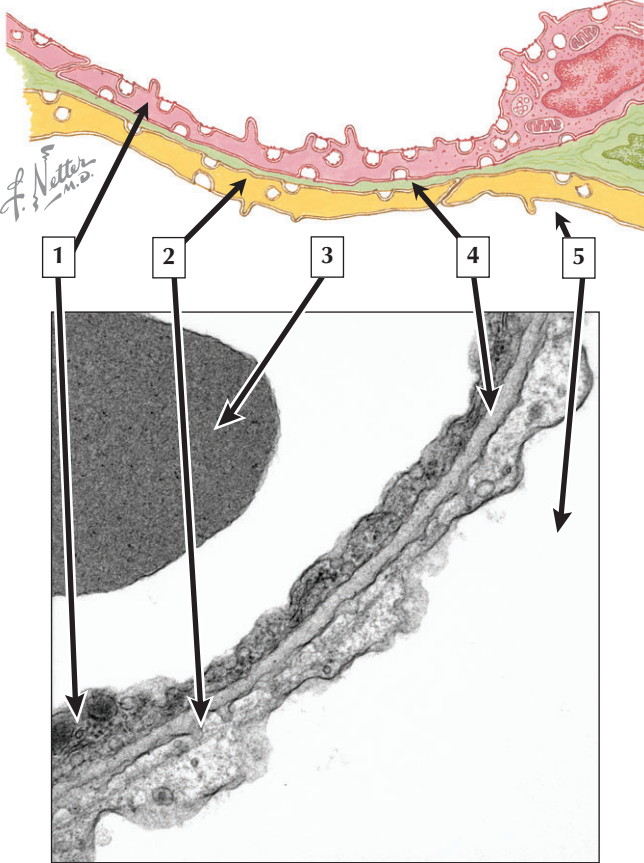
---

1. Alveolar dust cell
2. Type II pneumocyte
3. Pulmonary capillary
4. Lumen of pulmonary alveolus
5. Fibroblast in interalveolar septum
6. Type I pneumocyte

**Comment:** Although poorly appreciated in conventional hematoxylin and eosin sections, pulmonary alveoli give a honeycomb appearance to the lungs. They are cup-shaped air pockets (200  $\mu\text{m}$  to 250  $\mu\text{m}$  in diameter), which are lined by a simple squamous epithelium composed of 2 kinds of pneumocytes. Adjacent alveoli are separated by interalveolar septa, which contain a delicate connective tissue stroma with many elastic fibers. A network of pulmonary capillaries courses in the interalveolar septa. Type I pneumocytes are flattened, and type II pneumocytes are more cuboidal. Alveolar dust cells are monocyte-derived macrophages that engulf dust particles, bacteria, and other pathogens. In adults, each lung contains up to 300 million pulmonary alveoli.

**Pneumonia** is an inflammation of one or both lungs due to infection with bacteria, viruses, or other pathogens. Pulmonary alveoli often become inflamed, and their lumina fill with fluid. Symptoms include cough, difficulty in breathing, fever, and chest pain. **Pneumocystic carinii pneumonia**, caused by a fungus, primarily affects people with immune disorders, such as **acquired immunodeficiency syndrome (AIDS)**.

*LM and schematic of the parenchyma of the lung*





## Blood-Air Barrier

---

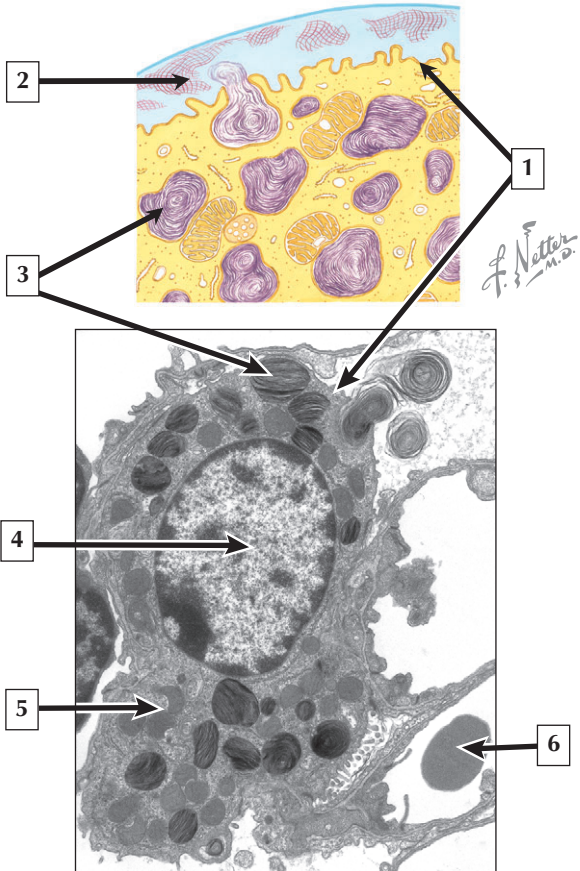
1. Capillary endothelial cell
2. Type I pneumocyte
3. Erythrocyte in pulmonary capillary
4. Fused basal laminae
5. Alveolar lumen

**Comment:** The blood-air barrier (or alveolar-capillary membrane) in the lung is permeable to gaseous diffusion. It consists of capillary endothelial cell, type I pneumocyte, and their fused basal laminae. In this region, a distance of 2  $\mu\text{m}$  or less separates air in the alveolus from blood in the pulmonary capillary. A thin layer of surfactant also covers the alveolar surface. The ends of adjacent type I pneumocytes partially overlap like shingles and are sealed by tight junctions, which prevent fluid leakage. Tight junctions also link adjacent pulmonary capillary endothelial cells. Numerous pinocytotic vesicles in the attenuated endothelium are consistent with active transport of some fluid and solutes.

**Pulmonary tuberculosis (TB)** is a contagious disease spread from person-to-person through the air by coughing or sneezing. It is caused by *Mycobacterium tuberculosis*, an aerobic bacillus, whereby initial infection is anywhere in the lungs and leads to an initial cellular immune response. Diagnosis is by chest radiograph and microscopic demonstration of the bacillus in cultured sputum specimens.

*Schematic and EM of the blood-air barrier at high magnification*

# Type II Pneumocyte



## Type II Pneumocyte

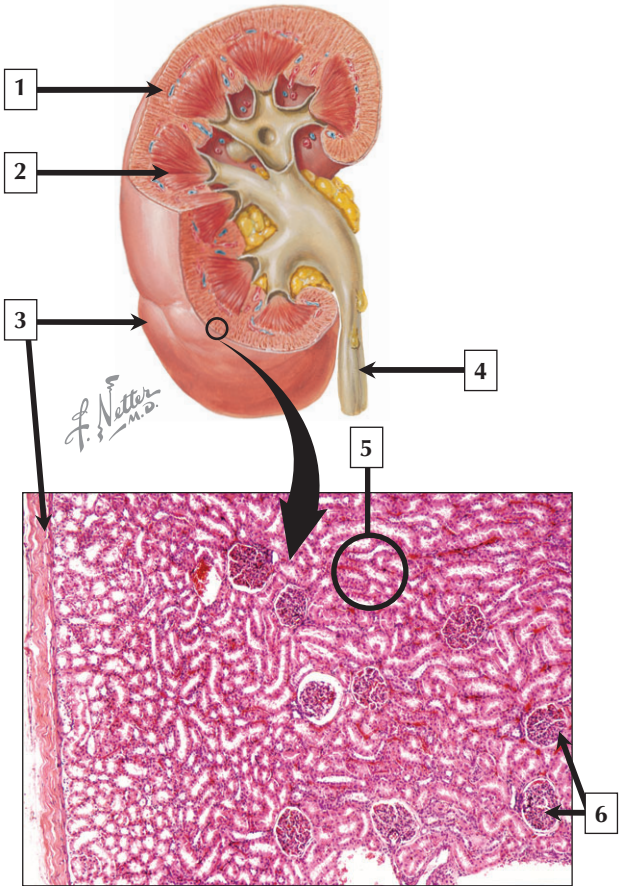
---

1. Plasma membrane
2. Surfactant
3. Multilamellar body
4. Nucleus (euchromatin) of type II pneumocyte
5. Mitochondrion
6. Erythrocyte in pulmonary capillary

**Comment:** Type II pneumocytes are cuboidal cells that measure 10 to 12  $\mu\text{m}$  in diameter. They have a single, centrally placed euchromatic nucleus with 1 or 2 prominent nucleoli. Their cytoplasm contains a well-developed Golgi complex, rough and smooth endoplasmic reticulum, scattered mitochondria, and many large, pleomorphic multilamellar bodies. Surfactant, a mixture of phospholipids and proteins, coats the alveolar surfaces of the lung. It is synthesized and secreted by type II pneumocytes and prevents alveolar collapse at the end of expiration by reducing surface tension. Multilamellar bodies in the cytoplasm of type II cells store the secretory product, which is discharged by exocytosis at the cell surface.

**Respiratory distress syndrome** of the newborn is due to inadequate production of surfactant. It leads to alveolar collapse, cyanosis, and difficulty in breathing. It may be life threatening in some premature infants and is the leading cause of death in preterm infants. Formerly called **hyaline membrane disease**, it is a common disease affecting 10% of premature infants.

*Schematic and EM of a type II pneumocyte*



# Kidney

---

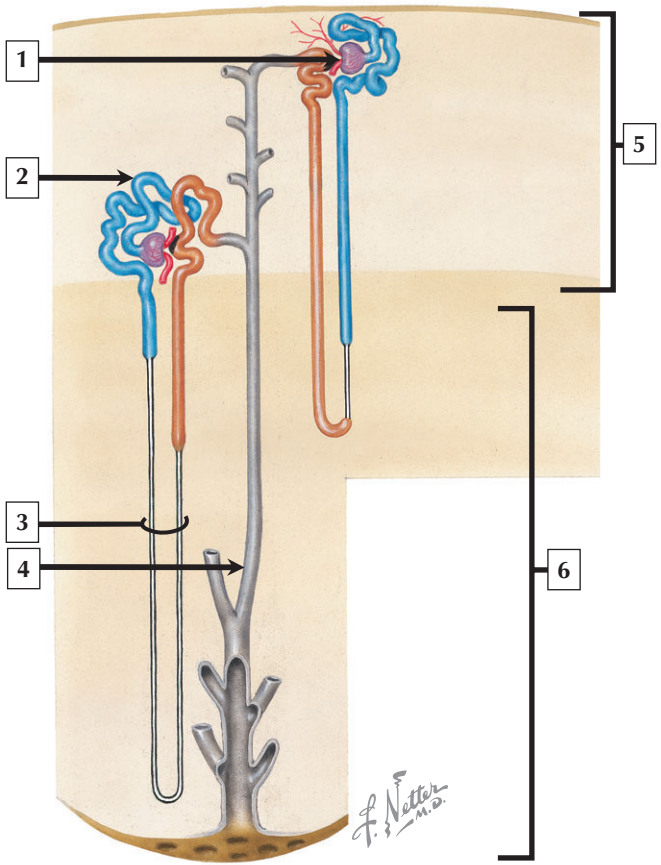
1. Cortex
2. Medulla (pyramid)
3. Fibrous capsule
4. Ureter
5. Renal tubules
6. Renal corpuscles

**Comment:** The kidneys are compound tubular glands covered by a thin fibrous capsule of dense connective tissue. They are flattened and bean-shaped with an indented slit, or hilum, through which blood vessels, ureters, nerves, and lymphatics pass. The kidneys filter blood and produce urine. Urine formation involves filtration, secretion, and reabsorption of fluid by renal corpuscles and tubules. The parenchyma is divided into a dark outer cortex, a lighter striated medulla, and a funnel-shaped pelvis. The medulla has 12 to 15 renal pyramids, which drain urine into minor and major calyces of the pelvis, and subsequently to the ureter.

**Wilms' tumor** (or **nephroblastoma**) is a **malignant tumor** of the kidney in infants and children. Histologically, tumor cells form cords resembling fetal kidney consisting of immature mesenchymal tissue mingled with abortive glomeruli and renal tubules. Loss of the growth-regulating gene WT-1 probably causes the tumor. It is highly responsive to treatment; **surgery** and **chemotherapy** result in fairly effective cures.

*Schematic of the gross structure of the kidney and low-power LM of the outer part of the renal cortex*

# Uriniferous Tubule



## Uriniferous Tubule

---

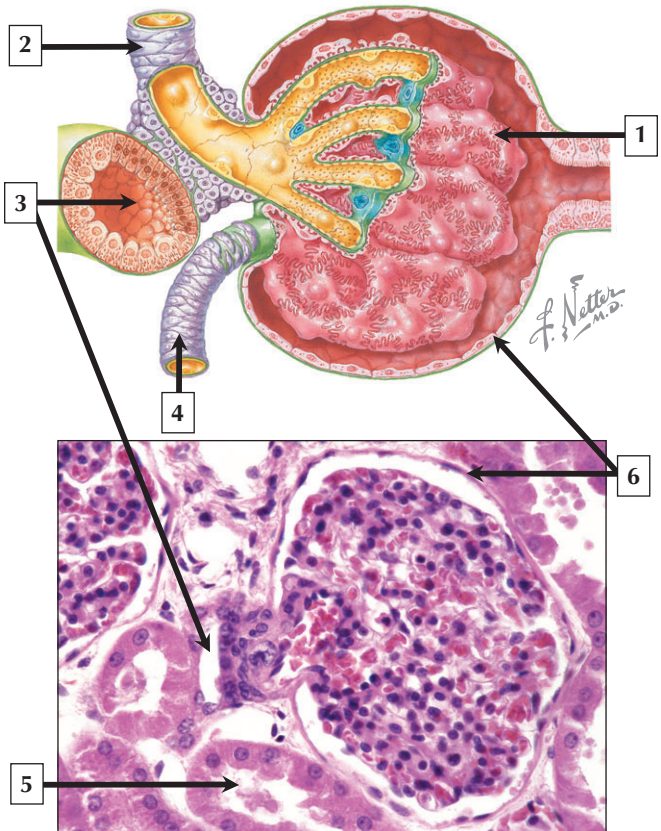
1. Renal corpuscle
2. Proximal convoluted tubule
3. Loop of Henle
4. Collecting duct
5. Renal cortex
6. Renal medulla

**Comment:** The uriniferous tubule consists of the highly coiled nephron (30 to 40 mm long) and excretory collecting ducts (20 mm long). It is the functional unit of the kidney. Each adult kidney has more than 1 million uriniferous tubules. A nephron is a blind-ended tubule composed of renal corpuscle, proximal tubule, loop of Henle, and distal tubule. The histology of each part reflects functional differences. Nephrons empty into collecting tubules, which form larger collecting ducts that convey urine to the renal pelvis. Renal corpuscles and convoluted parts of proximal and distal tubules are in the cortex, whereas Henle's loops and collecting ducts are in the medulla.

The Italian microscopist **Marcello Malpighi** (1628-1694) discovered renal corpuscles and tubules. **Freidrich Henle** (1809-1885) from Germany contributed to the study of the kidney, and the thin, looped part of the nephron bears his name. The English histologist **Sir William Bowman** (1816-1892) identified the capsule of the renal corpuscle—Bowman's capsule.

*Schematic of the uriniferous tubule (nephron and collecting duct)*

# Renal Corpuscle





## Renal Corpuscle

---

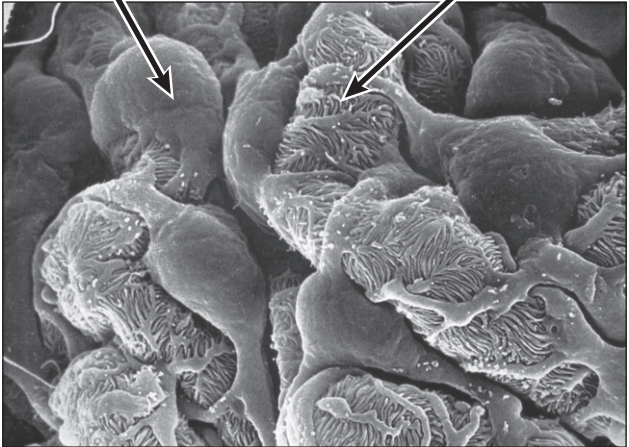
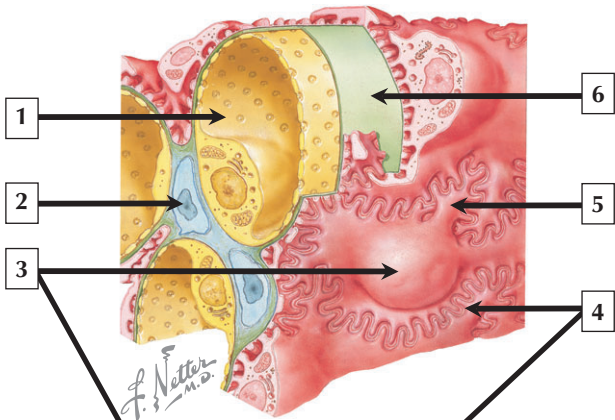
1. Visceral layer of Bowman's capsule (podocytes)
2. Afferent arteriole
3. Distal tubule
4. Efferent arteriole
5. Proximal tubule
6. Parietal layer of Bowman's capsule

**Comment:** The spherical renal corpuscles in the renal cortex are 200  $\mu\text{m}$  in diameter. They have a vascular pole (where afferent and efferent arterioles enter and leave) and a urinary pole (where the proximal tubule begins). Each corpuscle has an epithelial part—the renal corpuscle—and a vascular part—a tuft of glomerular capillaries (formed by an afferent arteriole and drained by an efferent arteriole). Bowman's capsule consists of an outer (parietal) layer of simple squamous epithelium and an inner (visceral) layer of podocytes. A basement membrane intervenes between podocytes and endothelial cells of glomerular capillaries.

**Alport syndrome** is an inherited progressive **nephropathy**, which can be evaluated via biopsy or electron microscopy. A genetic mutation results in abnormal type IV collagen in the glomerular basement membrane and leads to renal failure. Patients have blood (**hematuria**) and protein in urine, which is due to leakage of erythrocytes and plasma proteins across the defective basement membrane.

*Schematic and LM of the renal corpuscle*

# Renal Corpuscle and Podocytes



## Renal Corpuscle and Podocytes

---

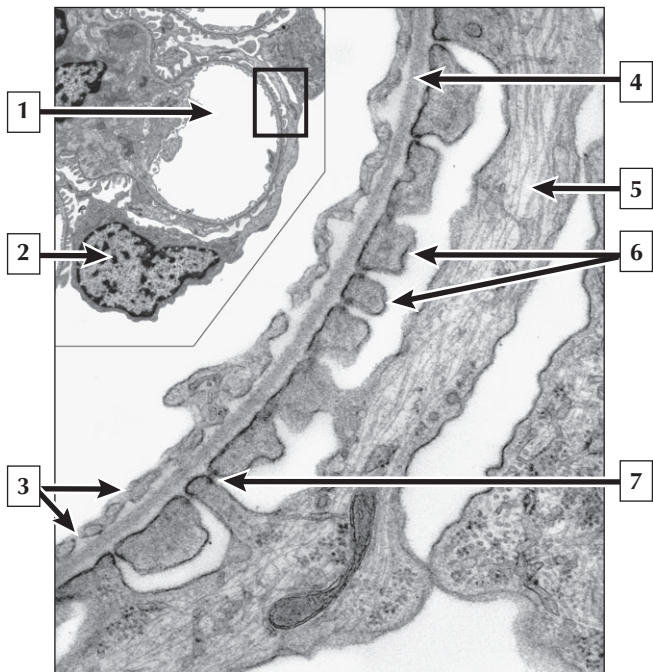
1. Attenuated glomerular endothelial cell with fenestrae
2. Nucleus of mesangial cell
3. Podocytes
4. Pedicels of podocytes
5. Primary process of podocyte
6. Basement membrane

**Comment:** The organization of the renal corpuscle is consistent with its role in glomerular filtration, transport, and permeability. The complex filter through which fluid passes from blood in glomerular capillaries to the urinary (Bowman's) space comprises 3 distinct, closely apposed parts: glomerular capillary endothelium, intervening basement membrane, and visceral layer of Bowman's capsule made of podocytes. Lining glomerular capillaries is an attenuated endothelium with multiple fenestrae that lack diaphragms and are highly permeable. Each podocyte is a highly modified epithelial cell that resembles an octopus perched on the outside of the capillary.

A common type of adult **nephrotic syndrome** is the immune-mediated disease—**membranous glomerulonephritis**. Diagnosis made by biopsy, immunofluorescence microscopy, and electron microscopy shows thickening of the glomerular basement membrane due to the presence of subepithelial immune deposits. Fusion of podocyte processes, also seen in this disorder, alters renal filtration.

*Schematic and SEM of the renal corpuscle and podocytes*

## Renal Filtration Barrier



## Renal Filtration Barrier

---

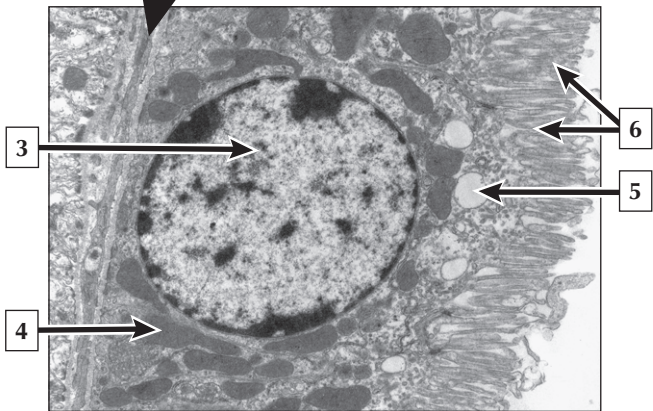
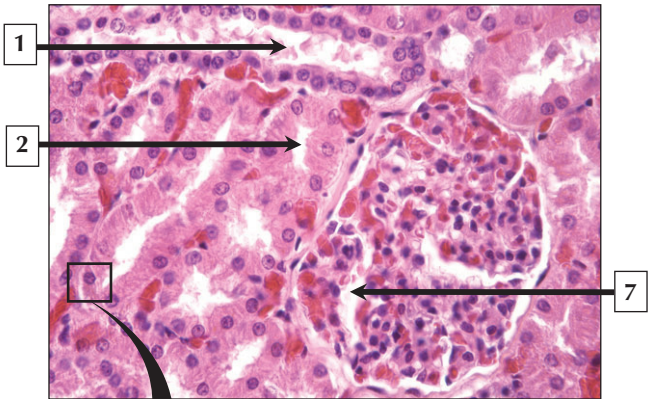
1. Glomerular capillary
2. Nucleus of podocyte
3. Fenestrae of capillary endothelial cell
4. Basement membrane
5. Primary process of podocyte
6. Pedicels of podocyte
7. Slit membrane

**Comment:** The tripartite renal filtration barrier consisting of glomerular capillary endothelium, basement membrane, and podocyte allows water and ions to pass from a capillary lumen to Bowman's space but retains large molecules and cells. Pedicels of podocytes interdigitate and envelop the abluminal aspect of the glomerular capillary. Filtration slits between pedicels are bridged by a ribbon-like filtration slit membrane. The basement membrane between endothelium and podocyte is 320 nm to 340 nm wide in humans. It contains laminin, fibronectin, different types of collagen, proteoglycans, and heparan sulfate.

**Goodpasture syndrome** is a rare antiglomerular basement membrane disease caused by circulating antibodies directed against the glomerular basement membrane. As a severe and progressive **glomerulonephritis**, it is characterized by altered permeability of the renal filtration barrier with rapid destruction of renal corpuscles. Most patients also have hemorrhage in the lungs due to defective capillary-alveolar basement membranes.

*EMs of the renal corpuscle at low and high magnification*

# Proximal Tubule



## Proximal Tubule

---

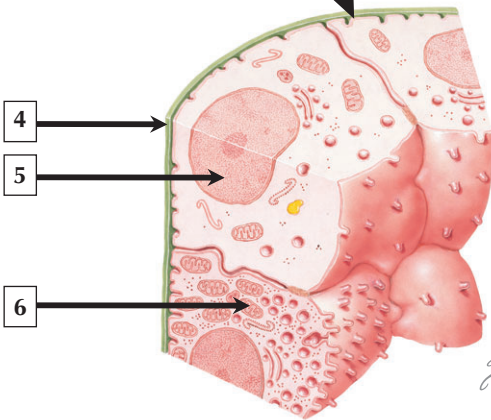
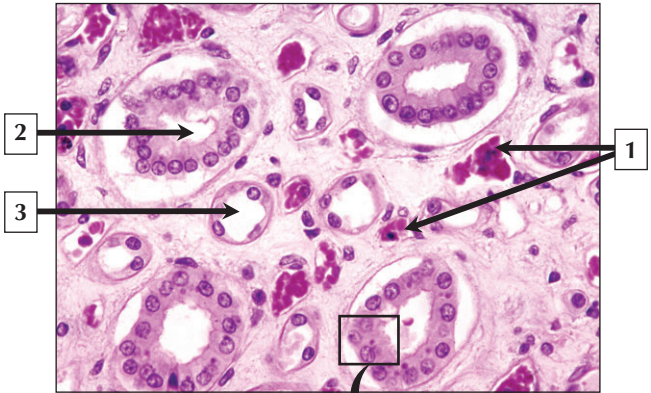
1. Distal tubule
2. Proximal tubule
3. Nucleus (euchromatin) of proximal tubule cell
4. Mitochondrion
5. Vesicle in apical cytoplasm
6. Microvilli (brush border)
7. Bowman's (urinary) space

**Comment:** The proximal convoluted tubule is the longest segment of the nephron and comprises most of the cortical parenchyma. Their walls are made of simple columnar epithelium with a finely granular, eosinophilic cytoplasm and a prominent brush border on the luminal surface. Distal tubules, in contrast, are smaller in diameter, and are devoid of a brush border. Proximal tubule cells resorb more than 60% of the glomerular filtrate, and their ultrastructural features are consistent with active transport. Mitochondria with tightly packed internal cristae are large and numerous. Apical parts of cells show tubular invaginations of the cell membrane and many vesicles and canaliculi in the cytoplasm.

**Acute tubular necrosis**—a serious disorder leading to impaired renal function—is characterized by destruction of epithelial cells of proximal and distal tubules. Proximal tubule cells are vulnerable to toxins and **ischemia** and often show a denuded brush border. This disorder is the most common cause of **acute renal failure**.

*LM of the renal cortex and EM of a proximal tubule cell*

## Collecting Duct





## Collecting Duct

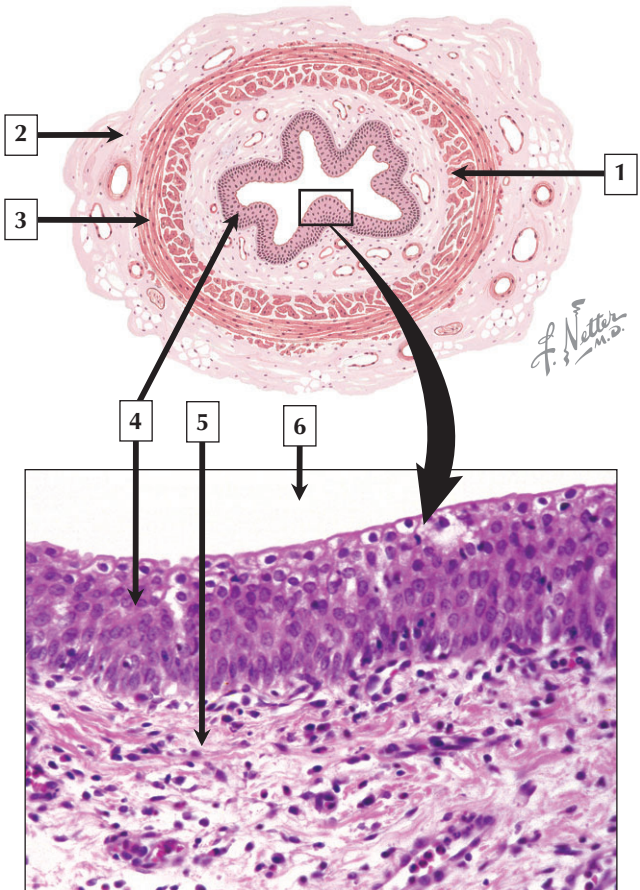
---

1. Erythrocytes in vasa recta
2. Collecting tubule (duct)
3. Loop of Henle
4. Basement membrane
5. Nucleus of light (principal) cell
6. Mitochondrion in dark (intercalated) cell

**Comment:** Collecting tubules are 40 to 200  $\mu\text{m}$  in diameter as they approach the renal pelvis as collecting ducts. Their walls are composed of simple cuboidal to low columnar epithelium. Lining cells bulge into the lumen and have a single, rounded nucleus. Two types of epithelial cells of collecting ducts—light (principal) and dark (intercalated) cells—likely represent different functional stages. Dark cells play a more active role in urine acidification and have more organelles than light cells. Collecting ducts take urine from nephrons to the renal pelvis. Under control of antidiuretic hormone (ADH) from the pituitary, collecting ducts resorb water, regulate acid-base balance, and concentrate urine.

**Renal cell carcinoma** is a diverse group of **malignant tumors** of the kidney, which arise from different parts of the uriniferous tubule in the cortex or medulla. Although rare, **collecting duct carcinoma** is the most aggressive of renal neoplasms. It is a histologically distinct tumor with a tendency to metastasize rapidly. It has a poor prognosis, frequently leading to death.

*LM of the renal medulla showing collecting tubules and loops of Henle and EM schematic of part of a collecting duct*



## Ureter

---

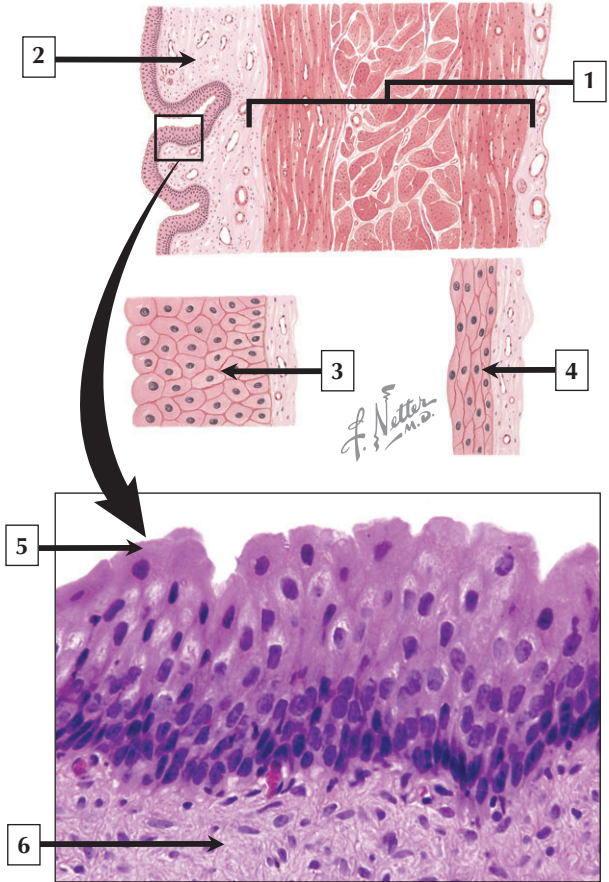
1. Inner longitudinal smooth muscle
2. Adventitia
3. Outer circular smooth muscle
4. Transitional epithelium (urothelium)
5. Lamina propria (loose connective tissue)
6. Lumen of ureter

**Comment:** The ureters are hollow fibromuscular tubes that are 4 to 5 mm in diameter and 14 cm long. They deliver urine via peristaltic smooth muscle contraction from the renal pelvis to the urinary bladder. An expandable transitional epithelium (urothelium) lines the lumen. It consists of 2 to 3 cell layers in the upper part of the ureter and 4 to 5 layers in the lower third. A highly cellular lamina propria supports the epithelium. A muscularis externa is composed of an inner longitudinal and outer circular layer of loosely arranged smooth muscle. Plexuses of nerve fibers are between the muscle layers. An outer adventitia of loose connective tissue blends with that of surrounding structures.

**Renal-ureteral colic** is severe, sporadic **abdominal pain** most commonly due to the passage of **kidney stones (calculi)** down the ureter with acute obstruction of its lumen. The pain is intermittent because it arises from waves of peristaltic contraction of ureteral smooth muscle in response to the calculus. Blood in the urine (**hematuria**) is a usual clinical manifestation, and an abdominal **computed axial tomography (CAT) scan** is the most reliable diagnostic test.

*Schematic of the wall of the ureter and LM of the mucosa*

# Urinary Bladder



# Urinary Bladder

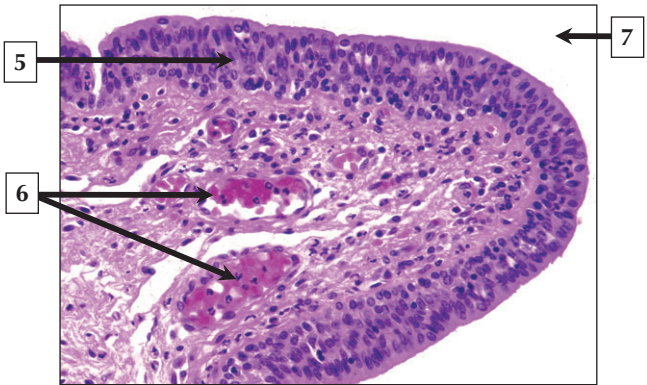
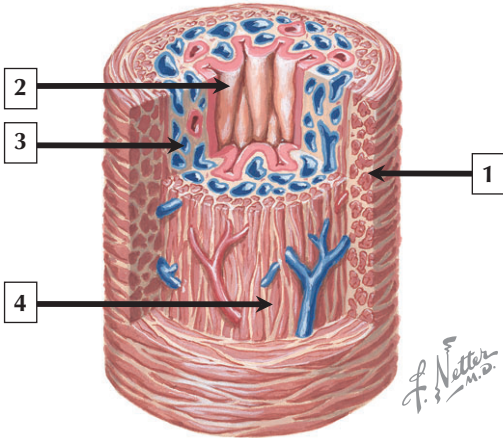
---

1. Muscularis externa (smooth muscle)
2. Lamina propria
3. Transitional epithelium (urothelium) in empty bladder
4. Transitional epithelium (urothelium) in distended bladder
5. Surface cell of transitional epithelium (urothelium)
6. Lamina propria (loose connective tissue)

**Comment:** Like the ureters, the urinary bladder follows a common histologic plan with walls made of 4 concentric layers: mucosa, lamina propria 3 layers of smooth muscle in the muscularis externa, and adventitia (or serosa). The mucosa consists of transitional epithelium (urothelium) whose appearance varies according to degree of distention. The urothelium is a tight permeability barrier due to luminal tight junctions, making the epithelium and underlying tissues impermeable to urine. The bladder has a capacity of about 500 cc, and temporarily stores urine prior to micturition. Although most of the bladder is covered externally by adventitia, part of its superior surface is covered by serosa of peritoneum.

**Urinary incontinence** is common in the elderly and is more prevalent in women than in men. It is involuntary loss of bladder control and voiding of urine. Many **neurologic disorders** and **systemic diseases** may cause it, **urinary tract infection** being a common one. Drugs may also interfere with normal function.

*Schematic of the wall of the urinary bladder and LM of the mucosa of the bladder*



## Urethra

---

1. Outer circular muscle layer
2. Mucosa
3. Lamina propria with vascular plexus
4. Inner longitudinal muscle layer
5. Stratified columnar epithelium
6. Vascular plexus in lamina propria
7. Lumen of penile urethra

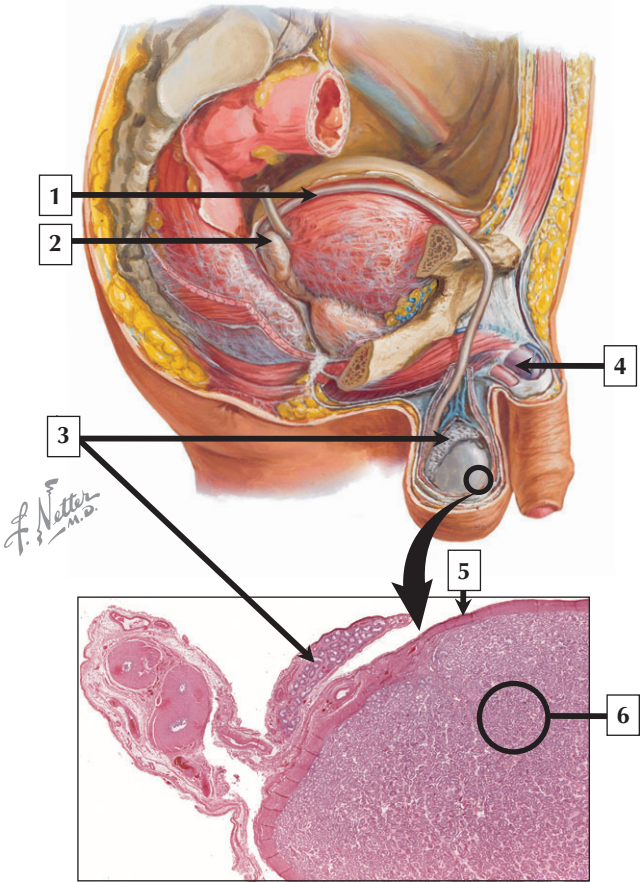
**Comment:** The female urethra is about 4 cm long and 8 mm wide. It has 3 concentric layers: mucosa, muscularis externa, and adventitia. Its crescent-shaped lumen is lined by transitional epithelium that gradually changes to stratified columnar, and then stratified squamous non-keratinized epithelium at its opening into the vestibule. Invaginations of epithelium form mucus-secreting urethral glands, and the lamina propria has an extensive venous plexus. The male urethra, 15 to 20 cm long, is divided into 3 segments: prostatic, membranous, and spongy. Like that in the female urethra, the epithelium of the male urethra shows similar regional changes.

**Urethritis**—an inflammation of the urethra—affects men and women equally. It may be caused by **bacterial** or **viral infection**, and is often associated with **sexually transmitted disease (STD)**.

**Gonococcal urethritis** usually has a shorter incubation period than the **nongonococcal** form of the disease.

*Schematic of the female urethra and LM of the mucosa of the penile urethra in the male*

# Male Reproductive System





# Male Reproductive System

---

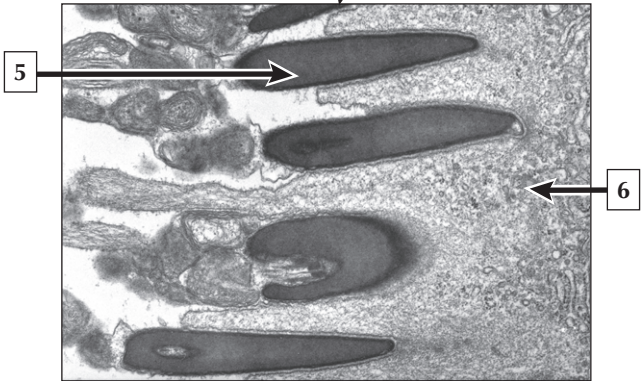
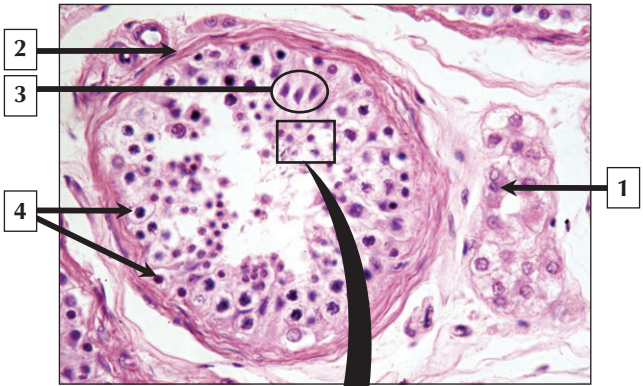
1. Vas (ductus) deferens
2. Seminal vesicle
3. Epididymis
4. Corpus cavernosum of penis
5. Tunica albuginea of testis
6. Seminiferous tubules

**Comment:** The male reproductive system comprises the paired testes, which are the primary sex organs, and several secondary sex organs consisting of excretory ducts and accessory glands (prostate, seminal vesicles, and bulbourethral glands). The testes, which reside outside the body cavity in the scrotum, contain small, convoluted seminiferous tubules whose germinal epithelium provides male germ cells known as spermatozoa. From the seminiferous tubules, spermatozoa travel a long, tortuous route in the rete testis, efferent ductules, epididymis, vas (ductus) deferens, ejaculatory duct, urethra, and penis.

**Male infertility** may be due to specific gene mutations that affect testicular development and spermatogenesis (whereby mature spermatozoa are produced and the number of chromosomes is reduced to the haploid state). **Klinefelter syndrome**—the most common abnormality in sexual development—includes dysgenesis of seminiferous tubules, **azoospermia**, and a 47XXY chromosomal **karyotype** due to chromosome nondisjunction.

*Schematic (paramedian section) showing parts of the male reproductive system and low-power LM of testis and epididymis*

# Testis and Seminiferous Tubule



## Testis and Seminiferous Tubule

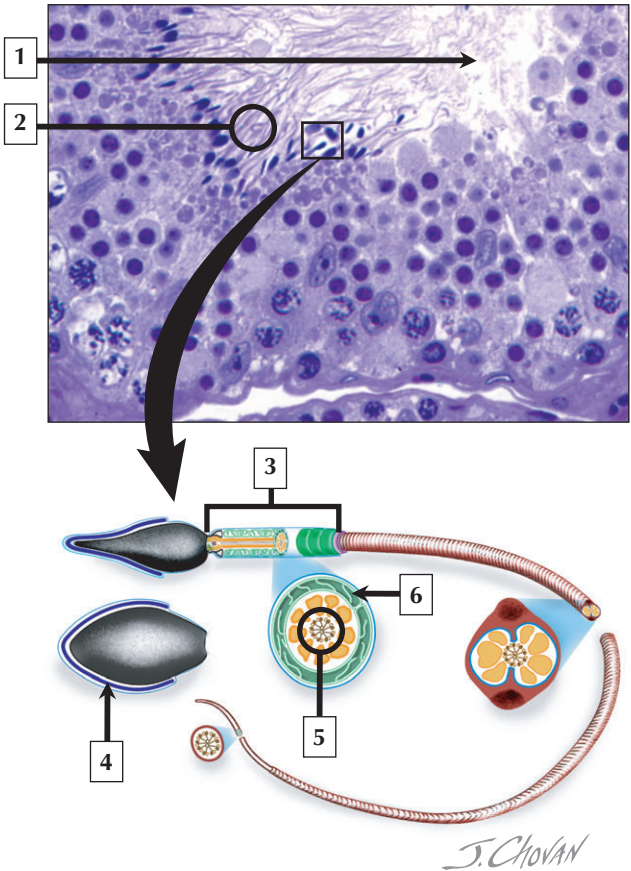
---

1. Leydig cell
2. Capsule of seminiferous tubule
3. Sertoli cells
4. Spermatogonia
5. Nucleus of elongate spermatid
6. Cytoplasm of Sertoli cell

**Comment:** Each testis has about 600 to 1200 seminiferous tubules with a total length of 280 m to 400 m. In the mediastinum testis, they empty into tubuli recti and rete testes. The interstitial connective tissue constitutes 20% to 30% of the substance of the gland, and within it are clumps of Leydig (interstitial) cells, which produce testosterone—the hormone responsible for secondary male characteristics. The seminiferous epithelium is an unusual, complex stratified epithelium with 2 cell populations: spermatogenic (or germ) cells and Sertoli cells. Germ cells are in various stages of spermatogenesis and include spermatogonia, primary and secondary spermatocytes, spermatids, and spermatozoa, which are released into the lumen of the tubules.

**Seminomas** are invasive **germ cell neoplasms** accounting for 95% of solid **testicular tumors** in men 15 to 35 years old. Although testicular tumors in children are rare, **cryptorchidism** (or undescended testes) predisposes boys to develop germ cell tumors.

*LM of a seminiferous tubule and a clump of Leydig cells, and EM of late spermatids at the lumen of a seminiferous tubule*



# Spermatozoa

---

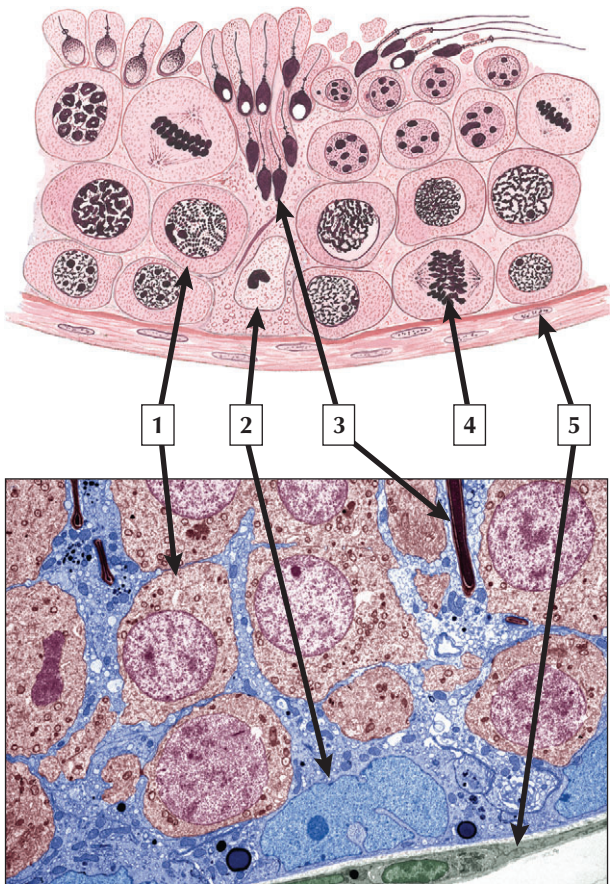
1. Lumen of seminiferous tubule
2. Tails of spermatozoa
3. Middle piece of spermatozoon
4. Acrosome
5. Axoneme (9 + 2 microtubules)
6. Mitochondrial sheath

**Comment:** Spermatogenesis takes 64 to 74 days and occurs in the seminiferous epithelium. It produces spermatozoa—highly specialized, mature germ cells that are 60  $\mu\text{m}$  long. Each spermatozoon with a single flagellum and a small, condensed, conical nucleus is typically divided into 5 distinct regions. The head piece contains the nucleus and acrosome, and a centriole pair occupies the neck piece. A middle piece contains helically arranged mitochondria, and the last 2 regions—principal and end pieces—have the axoneme made of a 9 + 2 bundle of microtubules. After puberty, about 500 million spermatozoa are produced daily.

**Semen analysis**—an assay of spermatozoa and seminal fluid—helps determine reproductive status and **fertility** in men. Important parameters are concentration, morphology and motility of spermatozoa, and detection of antisperm antibodies or nonspermatozoidal cells. Normal values include an ejaculate volume of 2 ml or more, sperm density greater than 20 million/ml, and greater than 50% spermatozoa with forward progression.

*LM plastic section of the wall of a seminiferous tubule (stained with toluidine blue) and schematic of a mature spermatozoon*

# Seminiferous Epithelium



## Seminiferous Epithelium

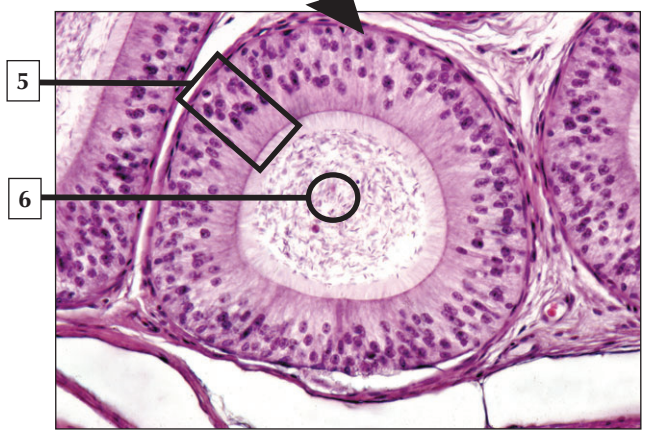
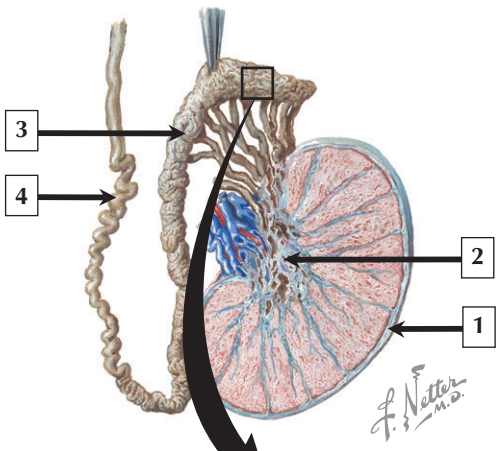
---

1. Spermatocyte (primary)
2. Sertoli cell nucleus
3. Spermatid
4. Dividing spermatogonium
5. Myoid cell

**Comment:** Sertoli cells play a critical role in support and maturation of spermatozoa. After puberty, they constitute about 10% of cells in the seminiferous epithelium. These columnar cells, with borders that are hard to distinguish, extend from the basement membrane to the lumen of the seminiferous tubule. Their apices bear cryptlike recesses that hold spermatids until release of newly formed spermatozoa into the lumen. Each cell has a jagged, euchromatic nucleus with a prominent nucleolus. The cytoplasm contains microtubules and intermediate filaments forming a prominent cytoskeleton, as well as long, slender mitochondria, a conspicuous smooth endoplasmic reticulum, large numbers of lipid droplets, and lipofuscin-laden lysosomes.

**Spermatocytic seminoma**—an uncommon *testicular neoplasm* derived from germ cells but clinically and pathologically distinct from other more classic testicular tumors—usually affects men older than 60 years of age and is rarely malignant. Immunocytochemistry of biopsy samples shows positive staining for markers specific for cells undergoing meiosis in addition to genomic abnormalities on chromosome 9, suggesting that primary spermatocytes are cells of origin of this tumor.

*Schematic and colorized EM of seminiferous epithelium in testis.*





# Epididymis

---

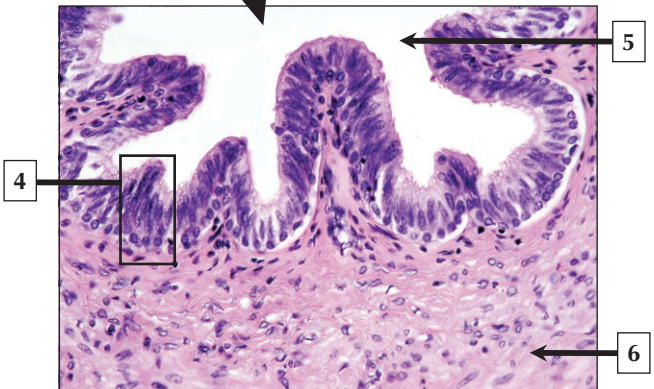
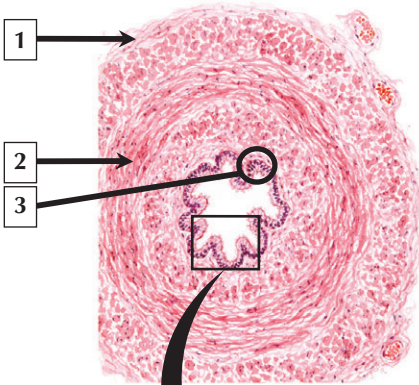
1. Tunica albuginea of testis
2. Rete testis in mediastinum testis
3. Epididymis (tail)
4. Vas (ductus) deferens
5. Pseudostratified epithelium of epididymis
6. Spermatozoa in lumen of duct of epididymis

**Comment:** The epididymis—on the posterior part of each testis—is composed of a tightly packed tortuous duct about 400  $\mu\text{m}$  in diameter and 6 m long. It has 3 parts: an initial (head) segment, a body, and a caudal (tail) region. The head receives efferent ductules and is engaged mainly in absorption of fluid and particulate matter. The wall of the epididymis is a very high pseudostratified epithelium consisting of basal (stem) cells and tall columnar (principal) cells with long apical stereocilia. Loose connective tissue and some circularly arranged smooth muscle are found outside the ducts.

**Epididymitis**—an inflammation of the epididymis—is frequently caused by **bacterial infection**. In young males it usually arises as a complication of gonorrhea or as a sexually acquired infection with Chlamydia. **Acute epididymitis** may be caused by retrograde passage of infected urine from the prostatic urethra via the ejaculatory ducts and vas (ductus) deferens. In severe cases, bilateral epididymitis can lead to **male infertility**.

*Schematic showing testis, epididymis, and vas deferens and LM of the duct of the epididymis in transverse section*

# Vas (ductus) Deferens



## Vas (ductus) Deferens

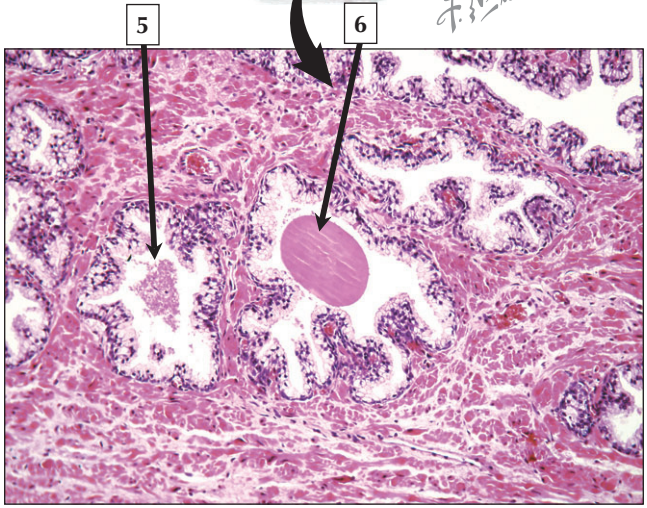
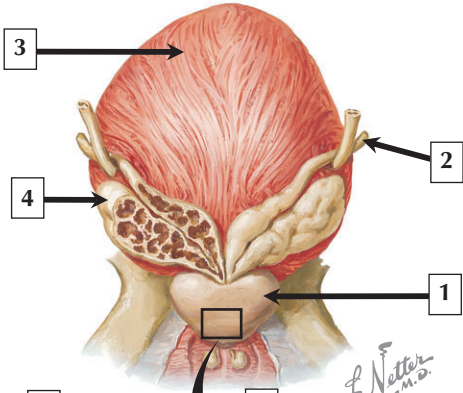
---

1. Adventitia of the vas (ductus) deferens
2. Muscularis
3. Mucosa (epithelium and lamina propria)
4. Pseudostratified epithelium
5. Lumen of vas (ductus) deferens
6. Smooth muscle

**Comment:** The vas (ductus) deferens is a hollow tube, about 5 to 40 cm long, that extends from the tail of the epididymis to the region of the prostate, where it joins the duct of the seminal vesicle to form the ejaculatory duct. Grossly it is divided into several regions, and histologically its wall is composed of mucosa, muscularis, and adventitia. Its lumen, which has a diameter of about 0.5 cm, is lined by pseudostratified columnar epithelium. Tall columnar cells with apical stereocilia and small basal (stem) cells comprise the epithelium. When partially or fully contracted, a thick triple-layered coat of smooth muscle (1 to 1.5 mm thick) appears to throw the mucosa into longitudinal folds.

**Vasectomy** is a minor surgical method that produces permanent **sterility**. When safely performed—usually as an outpatient procedure under local anesthesia—it is a safe method of **male contraception**. Serious acute postoperative complications are very rare. Microsurgery can reverse vasectomy and restore fertility, but is successful in only about 70% of cases.

*Schematic of the vas (ductus) deferens in transverse section and LM of the mucosa*



## Prostate

---

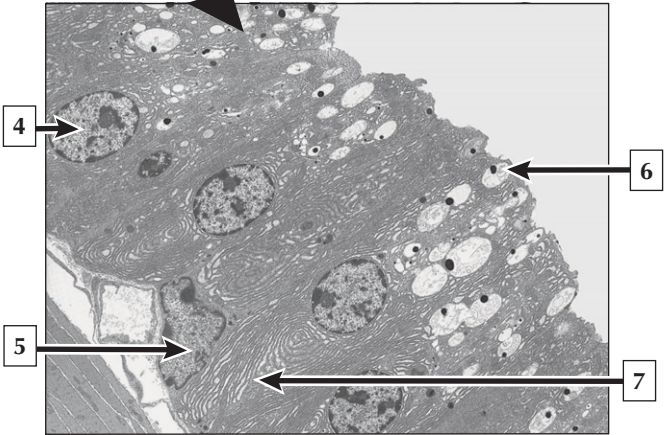
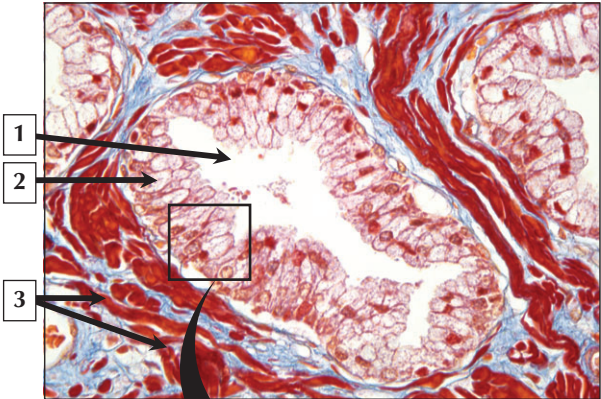
1. Prostate (peripheral zone)
2. Vas deferens
3. Urinary bladder
4. Seminal vesicle
5. Secretory alveolus of prostate
6. Prostatic concretion

**Comment:** The adult prostate—the size of a chestnut—surrounds the urethra immediately below the neck of the urinary bladder. The prostate is invested by a thin connective tissue capsule and comprises a collection of 50 compound tubulo-alveolar glands lined by pseudostratified epithelium. Prostatic secretions are 10% to 20% of the ejaculate volume, and contain the enzyme acid phosphatase, citric acid, zinc, prostate-specific antigen (PSA), and other proteases and fibrolytic enzymes. The subdivision of the prostate into 3 concentric zones is clinically important because most **prostate adenocarcinomas** arise from the peripheral zone.

**Benign prostatic hypertrophy (BPH)**, affecting 30% of men older than 50 years, is caused by hypertrophy and hyperplasia of glandular and stromal cells in the gland. It leads to nonmalignant enlargement of the gland. Its frequency and severity increase with aging. Diagnosis is made by rectal-digital palpation, transrectal ultrasonography, cystoscopy, and measurement of prostate-specific antigen (PSA).

*Posterior schematic view of the prostate and surrounding structures and LM of the prostate*

# Prostatic Epithelium



## Prostatic Epithelium

---

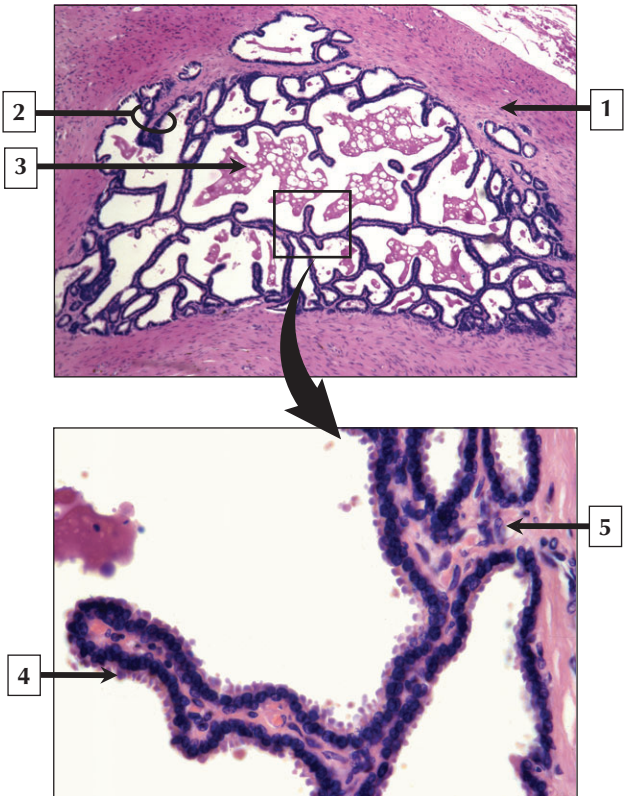
1. Lumen of secretory alveolus
2. Pseudostratified epithelium
3. Smooth muscle
4. Nucleus (euchromatin) of columnar epithelial cell
5. Nucleus (euchromatin) of basal cell
6. Secretory vesicle
7. Rough endoplasmic reticulum

**Comment:** The pseudostratified epithelium of secretory alveoli in the prostate consists of small basal cells and tall columnar cells (whose major role is synthesis and secretion). A supranuclear Golgi complex, multiple cisternae of rough endoplasmic reticulum, and many apical secretory vesicles are in the cytoplasm of columnar cells. The basal cells are most likely reserve stem cells for proliferation of the epithelium. A thin basement membrane separates epithelium from underlying richly vascularized lamina propria.

One of the most common **malignant tumors** in men is **adenocarcinoma** of the prostate in which the serine protease—prostate specific antigen (PSA)—may be elevated. Treatment depends on stage of disease at diagnosis. Prostatectomy, orchidectomy, radiation therapy, hormone treatment with estrogen derivatives, and use of pituitary releasing-hormone agonists are options; however, metastatic disease is incurable.

*LM of a secretory alveolus in the prostate stained with trichrome and EM of prostatic epithelium*

# Seminal Vesicle





## Seminal Vesicle

---

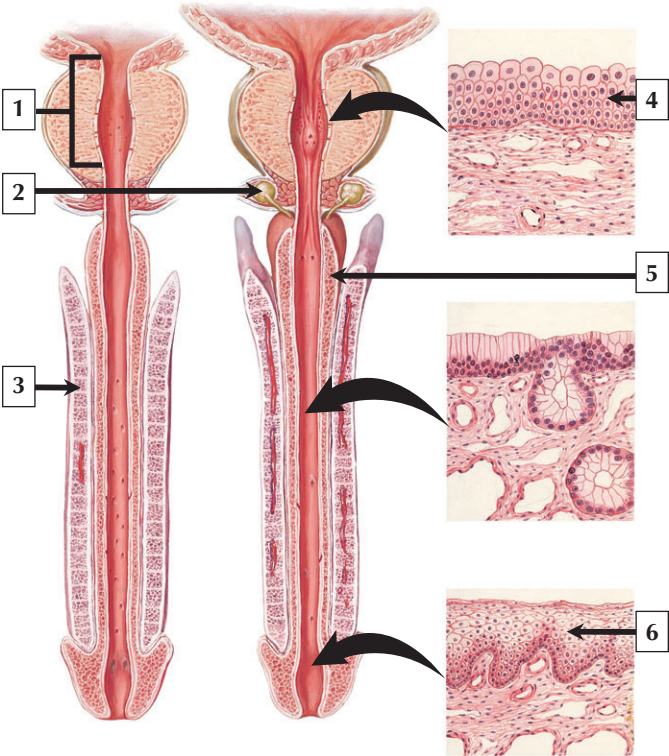
1. Smooth muscle
2. Mucosal fold
3. Flocculent material in lumen of seminal vesicle
4. Columnar epithelial cell
5. Lamina propria

**Comment:** Semen is composed of spermatozoa formed in the testis and seminal fluid, the bulk (70%) of which is secreted by the seminal vesicles. Derived embryonically from mesonephric ducts, the paired seminal vesicles are coiled, sacculated tubular glands situated retroperitoneally at the base of the urinary bladder. Each vesicle can hold 2 to 2.5 ml of seminal fluid and has an elaborately folded mucosa that resembles a honeycomb. The lumen contains eosinophilic coagulated material thought to be stored secretion. Fructose is the main secretory product, in addition to water,  $K^+$  ions, and prostaglandins. The epithelium, like that elsewhere in the reproductive tract, is androgen-dependent pseudostratified epithelium with basal cells and columnar cells. Underlying lamina propria is rich in elastic fibers. Smooth muscle deeper in the wall contracts during ejaculation and semen emission.

**Transrectal ultrasonography** can be used to assess abnormalities of the seminal vesicles. Although **seminal vesicle tumors** are rare, they may arise from epithelium or stroma. **Agenesis** or **congenital aplasia** of seminal vesicles leads to low serum fructose and low ejaculate volume.

*LMs of the seminal vesicle at low and high magnification*

# Urethra and Penis



*F. Netter M.D.*

## Urethra and Penis

---

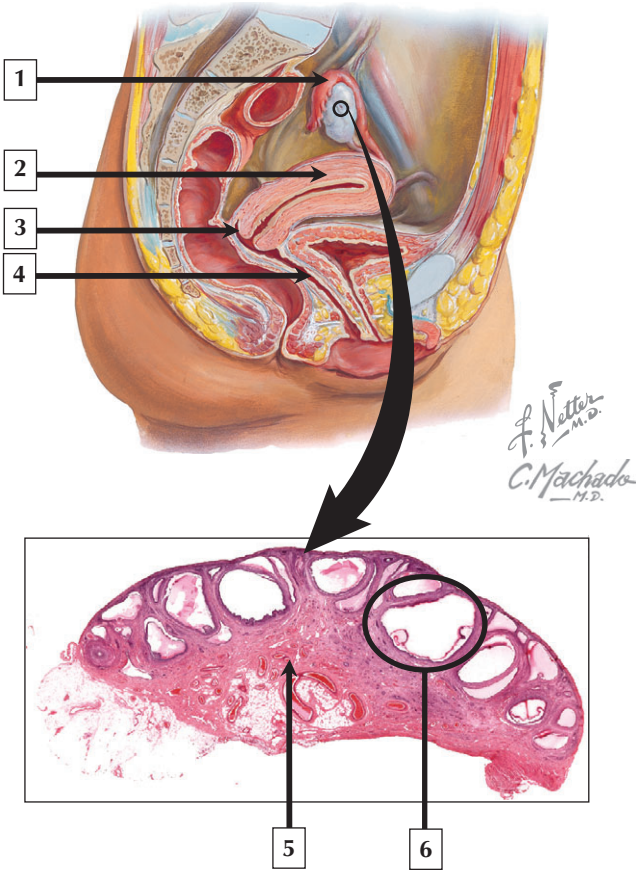
1. Prostatic urethra
2. Bulbourethral (Cowper's) gland
3. Corpus cavernosum of penis
4. Transitional epithelium (urothelium) in prostatic urethra
5. Corpus spongiosum
6. Stratified squamous epithelium in fossa navicularis

**Comment:** The male urethra conducts urine from the urinary bladder to the body's exterior as well as semen during ejaculation. It comprises 3 parts, with mucosa and epithelium varying regionally. The prostatic urethra is lined mostly by transitional epithelium (urothelium) and contains the openings of the paired ejaculatory ducts and ducts from the prostate. The short membranous urethra is lined by stratified columnar epithelium, whereas the mucous membrane of the longer penile (or spongy) urethra changes to stratified squamous epithelium. Erectile tissue is contained within 2 dorsal corpora cavernosa and a single ventral corpus spongiosum. Numerous cavernous vascular sinuses separated by trabeculae and lined by endothelium comprise the erectile tissue.

**Circumcision**—surgical removal of the foreskin—is typically performed on newborns under local anesthesia. Although potential medical benefits remain controversial, it may reduce the incidence of **penile carcinoma, urinary tract infections, and sexually transmitted diseases**, including acquisition and transfer of the **human immunodeficiency virus (HIV)**.

*Schematic of the penis showing its parts*

# Female Reproductive System



## Female Reproductive System

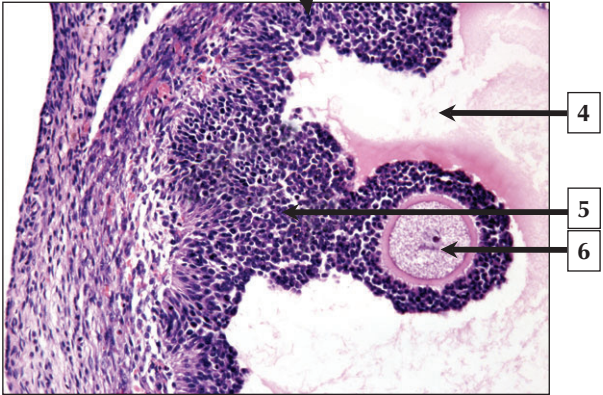
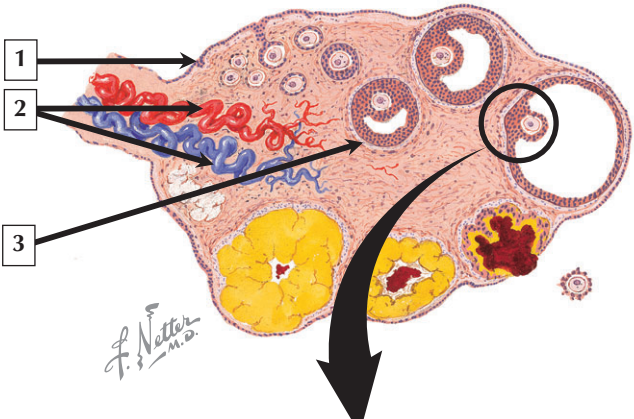
---

1. Uterine tube (Fallopian tube or oviduct)
2. Body of uterus
3. Cervix of uterus
4. Vagina
5. Medulla of ovary
6. Mature (Graafian) ovarian follicle

**Comment:** The female reproductive system comprises the paired ovaries and the genital tract, including the oviducts, uterus, and vagina. External genitalia consist of labia majora, labia minora, and clitoris. In addition, mammary glands and placenta are functionally associated with the genital organs. The ovaries produce female germ cells and steroid hormones. Like the ovaries, the uterus undergoes a regular sequence of changes known as the menstrual cycle. The vagina connects the internal genitalia with the exterior. Embryonic development of the female reproductive system, similar to that in the male, closely parallels that of the urinary system.

A common cause of **female infertility** is **pelvic inflammatory disease (PID)**—an inflammation of the female pelvis caused by spread of vaginal infection into the uterus, oviducts, and ovaries. PID is often a serious complication of **bacterial infection** associated with **sexually transmitted diseases**. Infections with **chlamydia** and **gonorrhea** are the 2 most common causes.

*Schematic (sagittal section) showing parts of the female reproductive system and low-power LM of the ovary*



## Ovaries

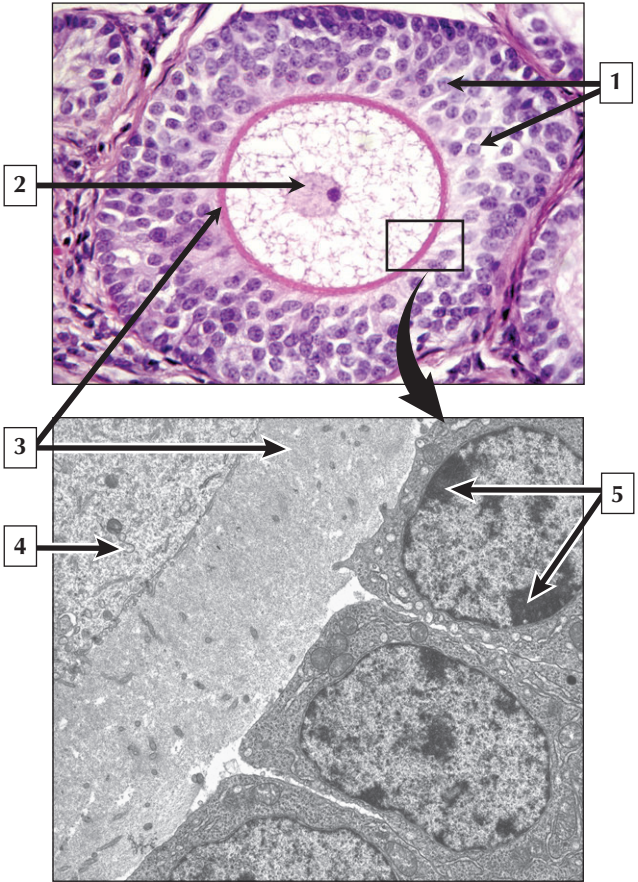
---

1. Ovarian surface (germinal) epithelium
2. Blood vessels entering and leaving hilus of ovary
3. Developing (secondary) ovarian follicle
4. Follicular lumen (antrum)
5. Cumulus oophorus (granulosa cells) of Graafian follicle
6. Oocyte cytoplasm

**Comment:** The ovaries are solid, almond-shaped glands, about 3 cm long and 2 cm wide in the adult. Their size and histologic appearance differ during the menstrual cycle, pregnancy, and postmenopausal period. Each ovary is covered by ovarian surface epithelium—a reflection of visceral peritoneum. An outer cortex harbors oocyte-containing ovarian follicles of various sizes and at different stages of maturation and degeneration. An inner medulla consists of loose connective tissue with many blood vessels, nerves, and lymphatics. Like testes, ovaries have both exocrine (cytogenic) and endocrine functions; they produce the hormones estrogen and progesterone.

**Epithelial ovarian carcinomas** represent nearly 90% of **ovarian malignancies** and commonly arise from ovarian surface epithelium. Predisposing hereditary conditions are risk factors for 10% of women with this **gynecologic cancer**. The risk of ovarian cancer increases with age, so it occurs mostly in postmenopausal women. Ovarian carcinoma has a tendency to **metastasize** to the surrounding peritoneal cavity.

*Schematic of the ovary and LM of a mature (Graafian) follicle*





## Ovarian Follicles

---

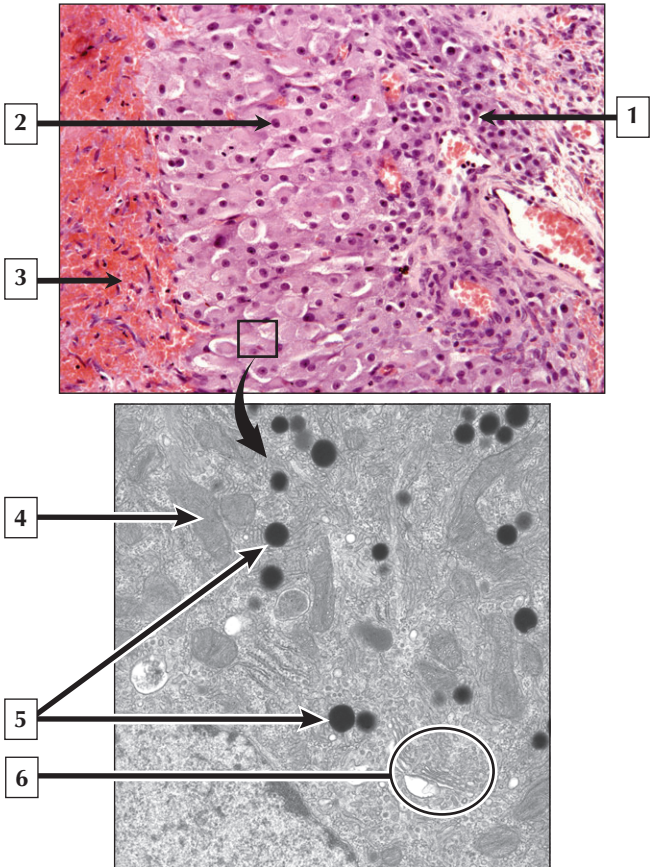
1. Granulosa cells
2. Nucleus of oocyte
3. Zona pellucida
4. Cytoplasm of oocyte
5. Nucleus (heterochromatin) of granulosa cell

**Comment:** Ovaries hold about 400,000 primary oocytes, which develop from oogonia. By puberty, about 40,000 oocytes remain after degeneration or atresia. Follicles in the cortex may be resting or primordial, maturing (primary and secondary follicles), or mature (Graafian). After puberty, about 20 primordial follicles become activated monthly during menstrual cycles, and usually 1 of them becomes dominant to become a primary follicle. This follicle has an oocyte and surrounding, concentrically arranged follicular (or granulosa) cells. Both oocyte and granulosa cells then synthesize an extracellular zona pellucida. Enlargement of the follicle leads to a secondary follicle, which subsequently contains fluid-filled spaces that coalesce to form a follicular antrum. Outermost theca cells produce the steroid androstenedione from which granulosa cells produce estrogens.

**Polycystic ovarian syndrome (PCOS)**—characterized by enlarged ovaries with multiple small cysts—interferes with ovulation, hormonal balance, and menstruation. It affects many women of reproductive age and may lead to **sterility**.

*LM of a secondary ovarian follicle and EM of the zona pellucida between oocyte and granulosa cells of a primary follicle*

# Corpus Luteum



## Corpus Luteum

---

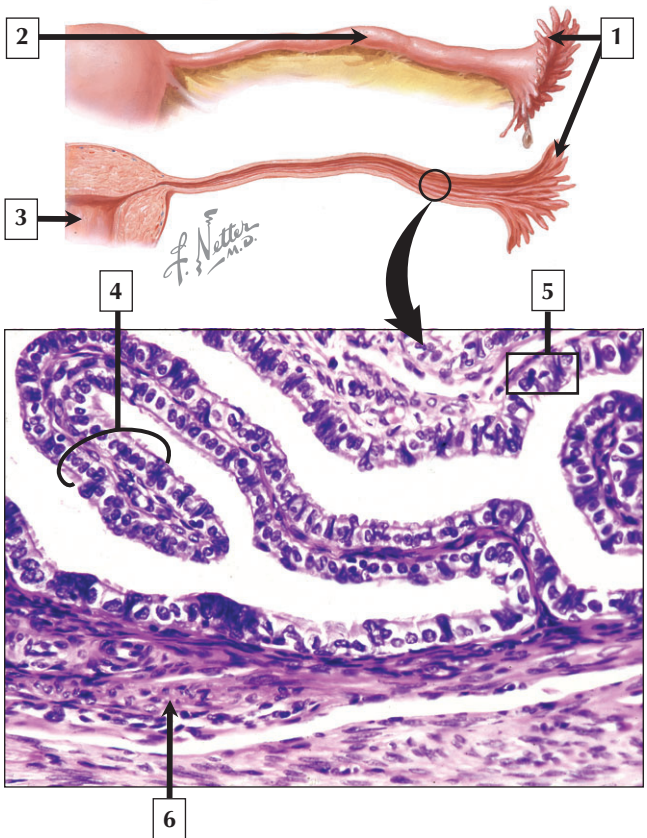
1. Theca lutein cell
2. Granulosa lutein cell
3. Blood-filled and fibrin-containing clot
4. Mitochondrion in granulosa lutein cell
5. Lipid droplets
6. Golgi complex

**Comment:** After the mature follicle has erupted from the ovary at ovulation, a temporary glandular structure—the corpus luteum—forms in the follicular remnant. The follicle collapses, becomes infolded, and the antrum is replaced by scar tissue. Luteinizing hormone from the pituitary causes granulosa and theca interna cells to undergo histologic and functional changes. Both cells have features of steroid-secreting cells, and their cytoplasm accumulates many lipid droplets. Progesterone produced by granulosa lutein cells prepares the endometrium for implantation, and estrogen is produced by theca lutein cells. If pregnancy does not occur, the corpus luteum gradually involutes to become a corpus albicans.

**Ruptured corpus luteum**—a condition characterized by excessive **hemorrhage** at the rupture site of the ovarian follicle—is often accompanied by severe **abdominal pain**, known as **acute abdomen**. Although its cause is unknown, it usually resolves spontaneously. It is potentially life threatening, however, if bleeding persists. Risk factors include abdominal trauma and anticoagulation therapy.

*LM of the corpus luteum and EM of a granulosa lutein cell*

# Uterine (Fallopian) Tubes



## Uterine (Fallopian) Tubes

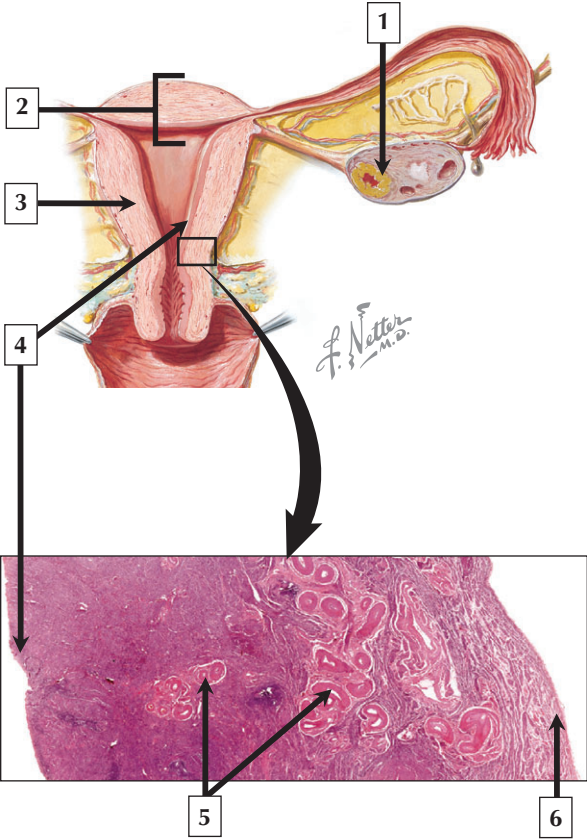
---

1. Fimbria of uterine tube
2. Ampulla of uterine (Fallopian) tube or oviduct
3. Lumen of uterus
4. Mucosal fold of uterine tube
5. Simple columnar epithelium (peg cells and ciliated cells)
6. Smooth muscle

**Comment:** The uterine (Fallopian) tubes, or oviducts, extend from the ovary to the uterus. They are 12 cm to 15 cm long and develop from unfused midregions of Mullerian ducts in the embryo. Each uterine tube—suspended by the mesosalpinx—consists of 4 regions: a fimbriated infundibulum, ampulla, isthmus, and intramural part. The mucosa is thrown into numerous folds that greatly increase surface area. Two types of cells—peg cells and ciliated cells—constitute the lining epithelium, and tubal ciliary movement is directed toward the uterus. Marked histologic changes occur in the epithelium according to the menstrual cycle. The uterine tube also has a highly cellular lamina propria, 2 indistinct layers of smooth muscle, and a rich vascular and nerve supply.

**Ectopic pregnancy** occurs when a fertilized ovum implants in tissue outside the uterus. A common such site is the uterine tube. Most cases are due to conditions that obstruct or slow passage of a fertilized ovum down the tube, such as **salpingitis**—an **inflammation** of the uterine tube commonly caused by **infection**.

*Schematics of the uterine tube and uterus, and LM of part of the wall of the uterine tube*



# Uterus

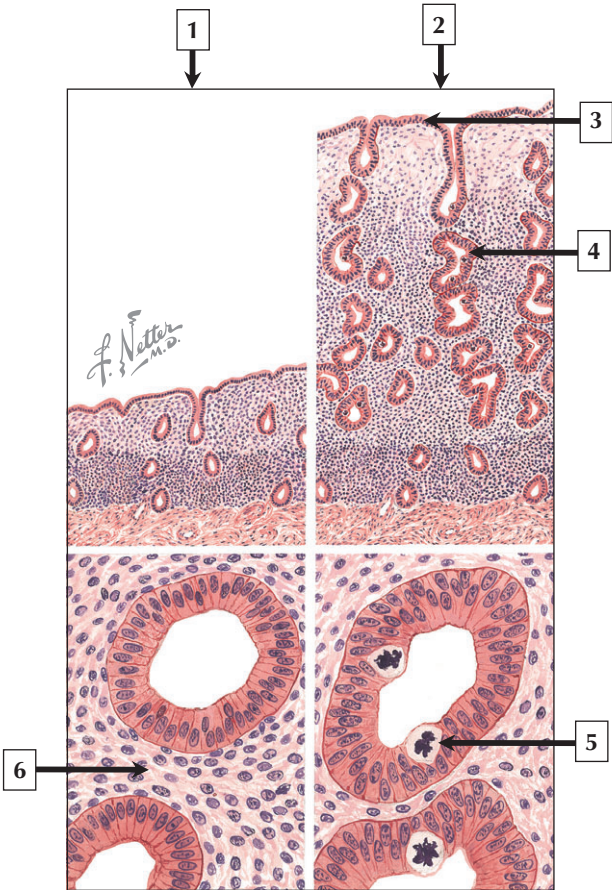
---

1. Corpus luteum of ovary
2. Fundus of uterus
3. Myometrium of body (or corpus) of uterus
4. Endometrium of uterus
5. Blood vessels in stratum vasculare of myometrium
6. Perimetrium

**Comment:** The uterus is a hollow pear-shaped organ in the pelvis between the urinary bladder and rectum. Anatomically it has 3 parts: the dome-shaped fundus, an expanded part called the corpus (or body), and the narrowest part—the cervix—which opens into the vagina. Histologically, the uterine wall consists of 3 layers. The innermost endometrium is specialized mucosa consisting of simple columnar epithelium, which undergoes marked histologic changes during the menstrual cycle. The myometrium is the thickest part and consists mostly of smooth muscle. The outer perimetrium is mainly connective tissue.

**Benign tumors** of the uterus that arise from localized hyperplasia of the myometrium are **leiomyomas**, commonly called **fibroids**. They are the most common tumor in the female pelvis, most likely as a result of endocrine imbalance. A common symptom is prolonged bleeding at menstruation. Treatment options include hormone therapy, uterine artery embolization, and surgical removal of the fibroid or the entire uterus (**hysterectomy**).

*Schematic of the uterus and adnexa, and low-power LM of the uterine wall showing its 3 layers*





# Endometrium

---

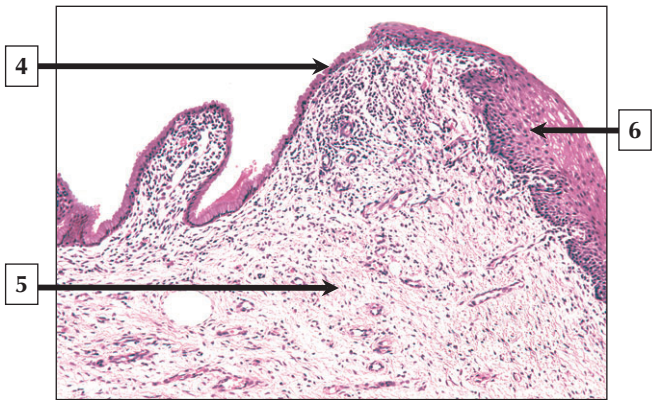
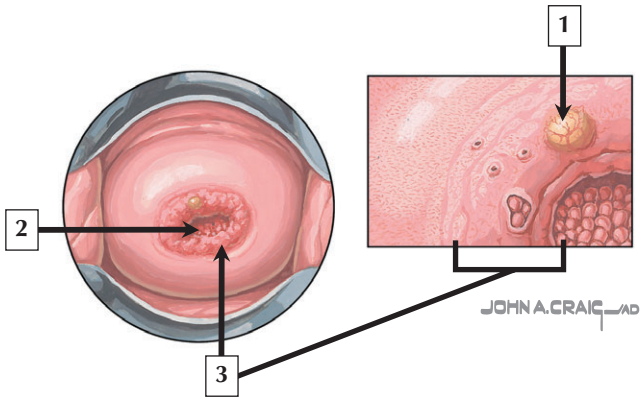
1. Endometrium - early follicular (proliferative) phase
2. Endometrium - late follicular (proliferative) phase
3. Surface (lining) epithelium of endometrium
4. Uterine gland
5. Mitotic figure in epithelium of uterine gland
6. Lamina propria or stroma

**Comment:** The uterine endometrium consists of 2 functional layers with blood supply from different sources. The thicker, more superficial functionalis layer is most affected by menstruation; it is periodically shed and then regenerated. The deeper, basal layer of the endometrium is not affected by hormonal variations or sloughed off during menstruation. Histologic changes during the follicular (or estrogenic) phase of the menstrual cycle are marked by replication and rapid growth of the lining epithelium, glands, and underlying stroma. During the secretory (progestational or luteal) phase, which begins just after ovulation, the endometrium reaches a thickness of 4 mm or more, and epithelial cells of the mucosal surface and glands show intense secretory activity. Secretions are thick and mucoid with high glycogen content.

**Endometriosis** is a common **gynecologic disease** affecting females between puberty and menopause in which endometrial tissue appears at unusual locations in the abdomen and pelvis. Symptoms include **pelvic pain** and **premenstrual bleeding**.

*Schematic views of the endometrium during early (left) and late (right) follicular phases of the menstrual cycle*

# Uterine Cervix



## Uterine Cervix

---

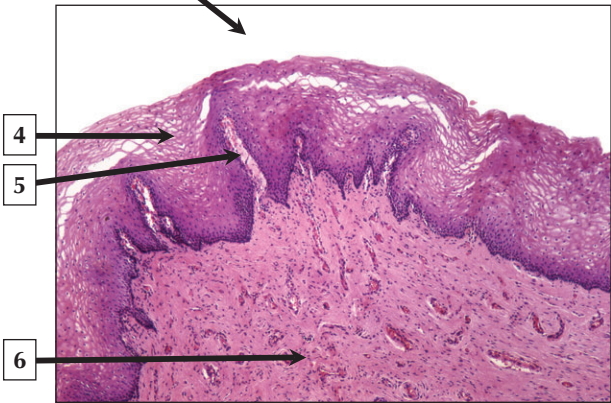
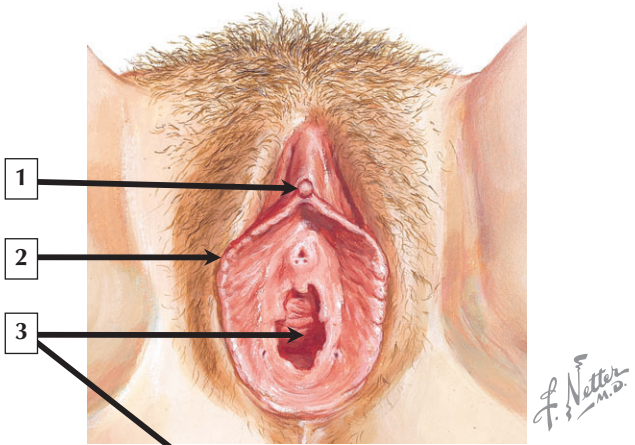
1. Nabothian cyst
2. External os
3. Transformation zone
4. Simple columnar epithelium of endocervix
5. Lamina propria
6. Stratified squamous nonkeratinized epithelium of exocervix

**Comment:** The inferior, tapering end of the uterus is the cervix. The upper part—the cervical canal—is lined by mucous membrane known as endocervix. The lower part—the portio vaginalis—is lined by exocervix, which is continuous with the vaginal mucosa. The cervical canal, lined by simple columnar epithelium, is usually filled with mucus secreted by highly branched glands. Occlusion of the glands may form dilated Nabothian cysts. The exocervix is lined by stratified squamous nonkeratinized epithelium devoid of glands. An abrupt squamocolumnar junction—the transformation zone—is just above the external os of the cervix.

**Cervical cancer**—the second most common cancer in women—is the leading cause of cancer-related death in underdeveloped countries. Most **cervical carcinomas** develop at the squamo-columnar junction of the transformation zone, where metaplastic transformation of the epithelium may occur. A routine cytologic screening test—the **Papanicolaou (Pap) smear**—has markedly reduced the incidence of cervical cancer deaths.

*Low- and high-power colposcopic schematic views of the cervix and low-power LM of the mucosa of the cervix*

# External Genitalia and Vagina



## External Genitalia and Vagina

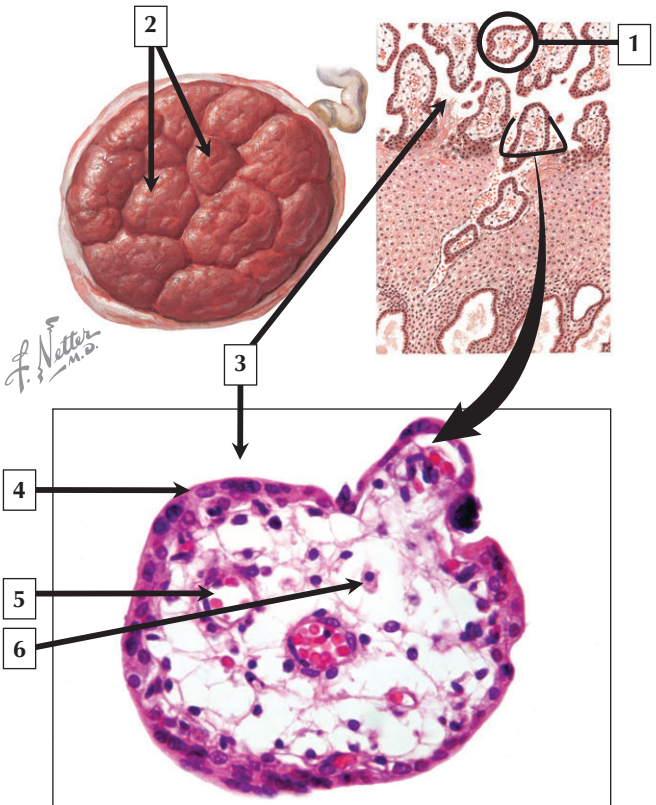
---

1. Glans clitoris
2. Labium minus
3. Vaginal orifice (or lumen)
4. Stratified squamous nonkeratinized epithelium
5. Connective tissue papilla
6. Lamina propria

**Comment:** The external genitalia, or vulva, are the labia majora and minora, clitoris, and vestibular glands. The vagina and urethra open into the vestibule. The vagina is a distensible fibromuscular tube that connects the cervix of the uterus to the body exterior. The vaginal lumen is lined by stratified squamous nonkeratinized epithelium, 150 to 200  $\mu\text{m}$  thick, which lacks glands. Surface cells of the epithelium appear washed out due to variable amounts of glycogen. As in many other parts of the female reproductive tract, this epithelium undergoes cyclic changes during the menstrual cycle.

The most common **vaginal infection** in women of reproductive age is **bacterial vaginosis (BA)**, which leads to painful inflammation and gray or white vaginal discharge. Although etiology is not known, it is probably caused by overgrowth of facultative and anaerobic bacteria in the vaginal lumen. Serious complications during pregnancy are **miscarriage, early (preterm) delivery, and pelvic infection** after childbirth.

*Schematic of the external female genitalia and low-power LM of the vaginal mucosa*



## Placenta

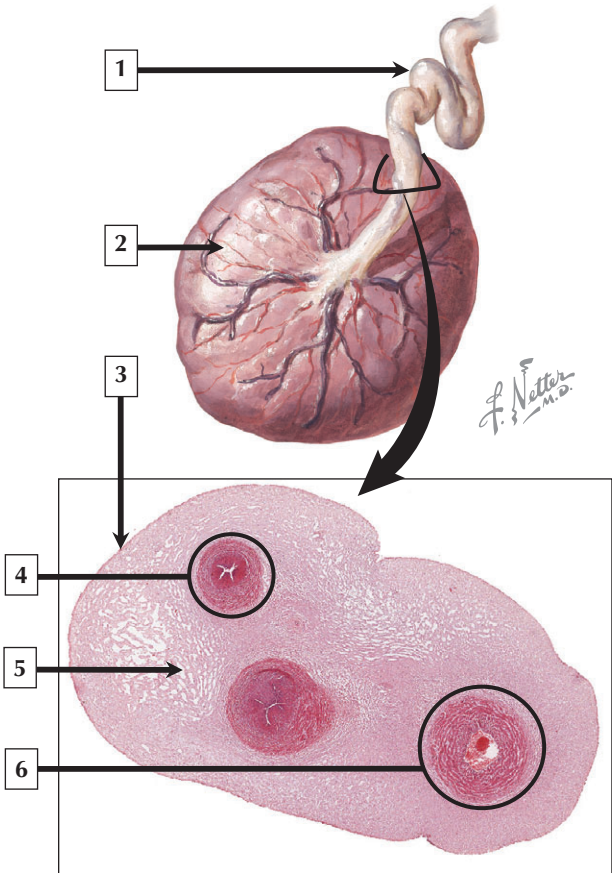
---

1. Placental villus
2. Cotyledons of placenta
3. Intervillous space (containing maternal blood)
4. Syncytiotrophoblast
5. Fetal capillary
6. Hofbauer cell (macrophage)

**Comment:** The disc-shaped placenta—a transitory organ—has both fetal and maternal parts. It weighs 400 to 600 g at birth and has 15 to 20 lobules, or cotyledons. The fundamental units of the organ are chorionic villi. Formed from the fetal chorion, they are lined by 2 types of epithelial cells (cytotrophoblasts and syncytiotrophoblasts). The connective tissue core of each villus has fetal capillaries and macrophages (Hofbauer cells). Maternal blood circulates in intervillous spaces. Fetal and maternal blood are close to each other but follow independent courses and do not mix, being separated by an efficient placental barrier.

Examination of the placenta in the delivery room can yield important information to the physician about the health of mother and infant. Many common and rare lesions may be linked to abnormal fetal development or **perinatal morbidity**. Although **placental tumors** are rare, **choriocarcinoma**—a **malignant neoplasm** of syncytiotrophoblasts and cytotrophoblasts—may invade the uterine wall and **metastasize** to other sites.

*Gross and histologic schematics of the placenta and high-power LM of a 12-week placental villus in transverse section*





## Umbilical Cord

---

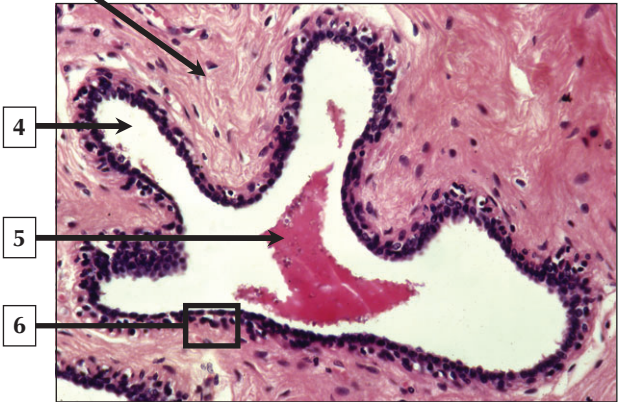
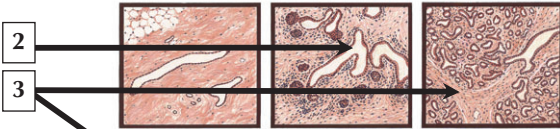
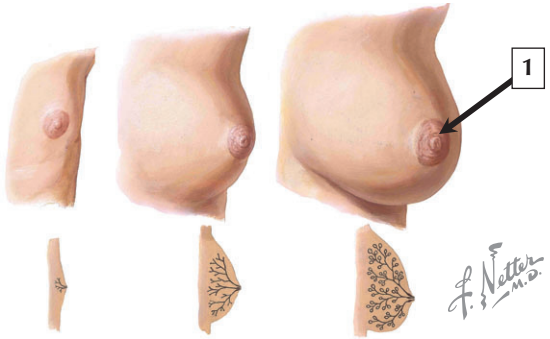
1. Umbilical cord
2. Full-term placenta (fetal aspect)
3. Amniotic epithelium
4. Umbilical artery
5. Wharton's jelly (mucous connective tissue)
6. Umbilical vein

**Comment:** The umbilical cord—about 55 cm long at term—connects the fetus to the placenta. It is covered externally by a single layer of cuboidal epithelium, which is derived from the lining of the amniotic cavity and is known as amniotic epithelium. This epithelium secretes amniotic fluid and also serves a protective role. Within the cord, 2 umbilical arteries and a single umbilical vein are coiled around each other in a matrix of embryonic mucous connective tissue known as Wharton's jelly. The umbilical vein delivers oxygenated blood to the fetus, whereas umbilical arteries carry deoxygenated blood from the fetus to the chorion. Umbilical arteries have thinner walls than typical adult arteries, and umbilical veins have a thick layer of circular smooth muscle but lack valves.

Umbilical cord **blood stem cell transplants** are a potent resource for transplant therapies. The cells may be collected from the umbilical cord at birth before the placenta is discarded. These cells are less prone to rejection than bone marrow stem cells.

*Schematic of the umbilical cord and placenta, and low-power LM of the umbilical cord in transverse section*

# Mammary Gland



# Mammary Gland

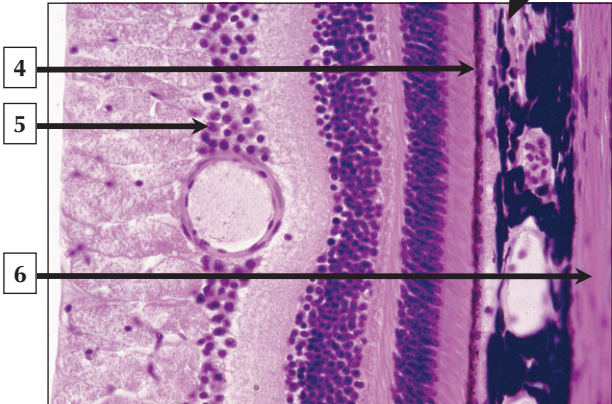
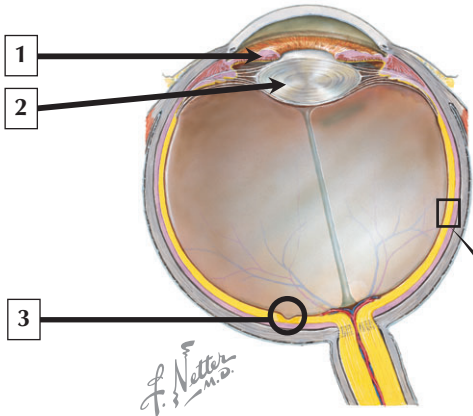
---

1. Areola of nipple
2. Duct (parenchyma) of mammary gland at puberty
3. Stroma (dense irregular connective tissue) at maturity
4. Lumen of lactiferous duct
5. Eosinophilic precipitate (milk components)
6. Stratified cuboidal epithelium

**Comment:** The paired mammary glands are modified apocrine sweat glands present in both males and females. In women who give birth, they are specialized exocrine glands that secrete milk. Each mammary gland consists of parenchyma derived from surface ectoderm and connective tissue stroma that arises from mesenchyme. The parenchyma is formed from a series of ducts that retain their connection to the surface. At puberty, mammary glands in girls undergo histologic changes under the influence of the ovarian hormones estrogen and progesterone. If pregnancy occurs in adulthood, the terminal ends of the ducts develop into hollow secretory alveoli lined by simple cuboidal epithelium.

Since most **breast cancers**, which may occur in both men and women, arise from ductal or alveolar epithelium, they are known as **mammary adenocarcinomas**. Most are invasive lesions called **infiltrating ductal carcinomas**. Prognosis depends on tumor growth pattern, expression of gene products, and hormone receptors, and **metastasis** to regional lymph nodes or other sites.

*Schematic showing developmental and histologic changes in the mammary gland and LM of a lactiferous duct*



# Eyeball

---

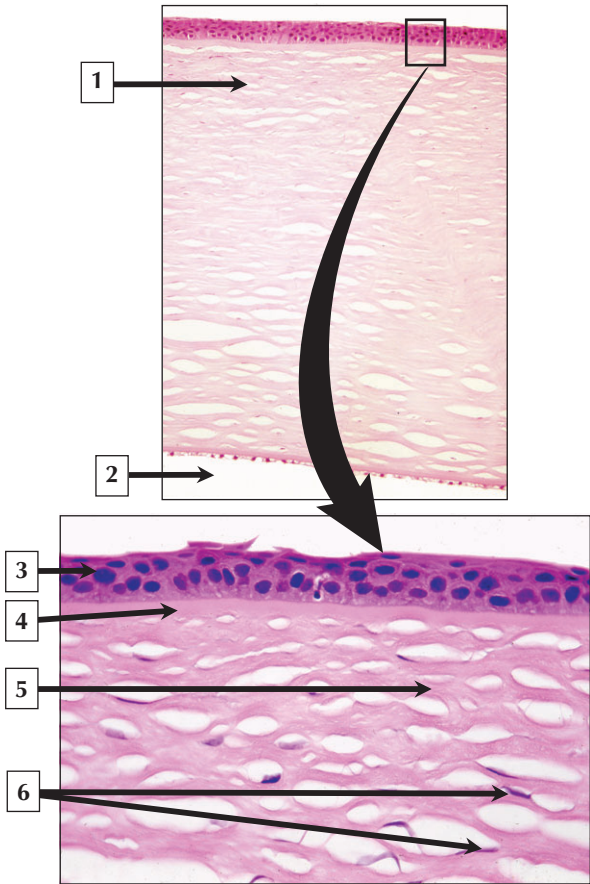
1. Iris
2. Lens
3. Fovea centralis of macula lutea of retina
4. Retinal pigment epithelium
5. Ganglion cells of retina
6. Sclera (dense fibrous connective tissue)

**Comment:** Eyes are roughly spherical and are about 2.5 cm in diameter. They are photoreceptor organs that communicate with the brain via the optic nerve. The wall has 3 concentric coats: an outer sclera and cornea, a middle vascular coat (or uvea), and an innermost retina. Three interior ocular chambers are the small anterior and posterior chambers containing aqueous humor, and the main chamber—the vitreous body—containing a transparent semisolid gel. The choroid, ciliary body, and iris comprise the uvea. The double-layered retina has neural and nonneural regions, and the site of sharpest visual acuity in the neural retina is the fovea centralis of the macula lutea.

The cornea, lens, and ocular axial length determine focusing ability of the eye. **Ametropias** are ocular refractive disorders that interfere with proper focusing of light rays on the macular part of the retina.

**Myopia**, or **nearsightedness**, is the most common type of ametropia. Treatment options are spectacles and contact lenses or **laser surgery** and **corneal transplantation**.

*Schematic (horizontal section) of the eyeball showing its parts and LM showing 3 layers of the eye*



# Cornea

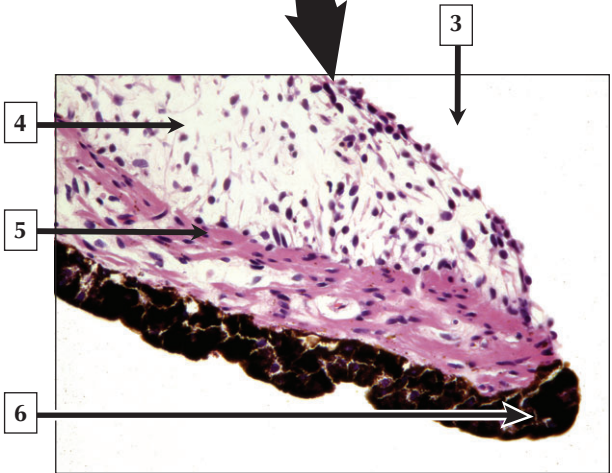
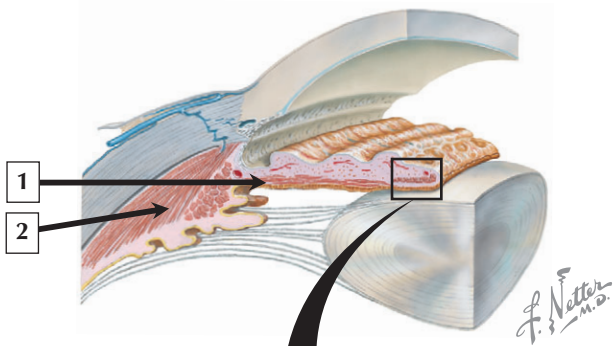
---

1. Substantia propria (stroma) of cornea
2. Anterior chamber (filled with aqueous humor)
3. Stratified squamous nonkeratinized epithelium
4. Bowman's membrane
5. Collagen of corneal stroma
6. Fibroblasts

**Comment:** The cornea, which occupies one-fifth of the ocular surface, is about 0.5 mm thick and 11.5 mm in diameter. It is made of dense fibrous connective tissue with a layer of epithelium on both sides. Its anterior surface is stratified squamous nonkeratinized epithelium, which continuously replicates in response to wear and tear. Deep to the epithelium is Bowman's membrane—a prominent basement membrane that binds the epithelium to underlying connective tissue. The thick, central region—the substantia propria—contains 60 to 70 layers of type I collagen fibers arranged at right angles in successive layers. The posterior surface is covered by simple cuboidal epithelium.

**Corneal transplant surgery**—also known as **keratoplasty**—is a common, minimally invasive procedure usually performed under **local anesthesia**. It is undertaken to restore vision in patients with defective or distorted corneas. Because the cornea is virtually avascular, risk of tissue rejection is extremely low. Tissues for transplant surgery are usually taken from donated corneas obtained shortly after death of the donor.

*LMs of the cornea at low and high magnification*





## Iris

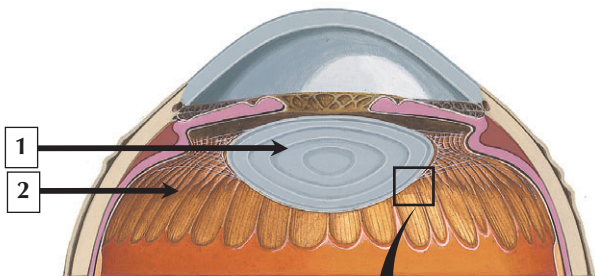
---

1. Dilator pupillae muscle
2. Ciliary muscle
3. Anterior chamber (filled with aqueous humor)
4. Stroma of iris
5. Constrictor pupillae muscle
6. Cuboidal epithelium (double layer and pigmented)

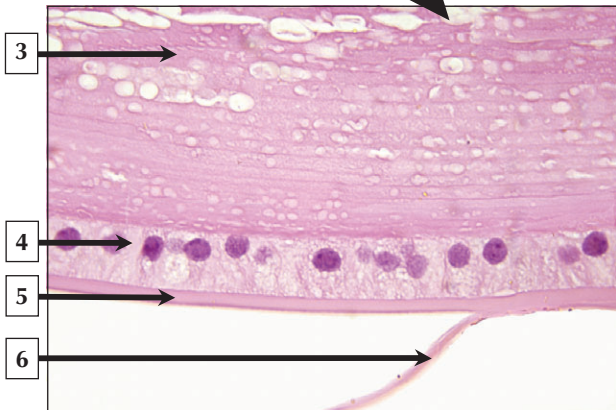
**Comment:** The iris is the most anterior part of the uvea and separates anterior and posterior chambers. It is a circular diaphragm, 10 mm to 12 mm in diameter. It regulates the amount of light reaching the retina by adjusting the size of its central aperture—the pupil. A double layer of pigmented cuboidal epithelium covers the posterior surface, whereas a discontinuous layer of stromal cells—a mixture of fibroblasts and pigment-containing melanocytes—is on the anterior surface. In the stroma near the pupillary margin is the constrictor pupillae muscle consisting of a flat ring of circumferential smooth muscle. Myoepithelial cells of the inner layer of the posterior epithelium constitute the dilator pupillae.

There are many forms of **uveitis**—an inflammation of the uvea—that may lead to **red eye**, pain, and decreased vision. **Anterior uveitis** (or **iritis**), the most common form, usually occurs in healthy people. It may also be associated with **autoimmune diseases** and may be due to **viral** and **bacterial infection**, or **parasitic infestation**, such as **toxoplasmosis**.

*Schematic of the anterior segment of the eye and LM of the iris close to the pupillary margin*



*F. Netter M.D.*



# Lens

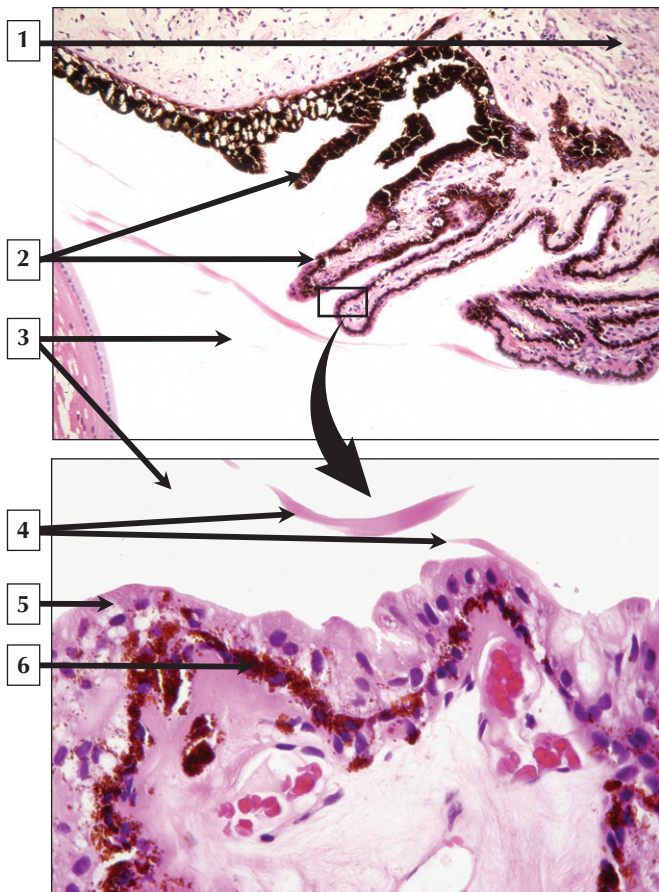
---

1. Lens
2. Ciliary process
3. Lens fiber
4. Simple cuboidal (lens) epithelium
5. Lens capsule
6. Zonular fiber

**Comment:** The lens—between the iris and vitreous body—is 10 mm in diameter and 3.5 mm to 5 mm wide. It is held in fixed position by zonular fibers and the vitreous body. It is an elastic, biconvex structure derived embryonically from surface ectoderm of the lens placode. Tensile forces within it cause its roughly globular shape. A simple cuboidal epithelium and its thick basement membrane, the lens capsule, covers the anterior half of the lens. Lens fibers, the principal cells of the lens, are elongate columnar epithelial cells devoid of viable nuclei and containing distinctive proteins called crystallins. Like the cornea, the lens is avascular and depends on diffusion of aqueous humor for nutrition.

**Cataracts**—lens opacities often associated with advanced age—may interfere with focusing of light on the retina. Cataracts may be surgically removed and replaced by prosthetic lenses. **Presbyopia**—a progressive refractive disorder—is an age-related loss of accommodative ability due to reduced lens flexibility. Corrective lenses and refractive surgery are treatment options.

*Schematic of the anterior segment of the eye and LM of part of the lens*



## Ciliary Body

---

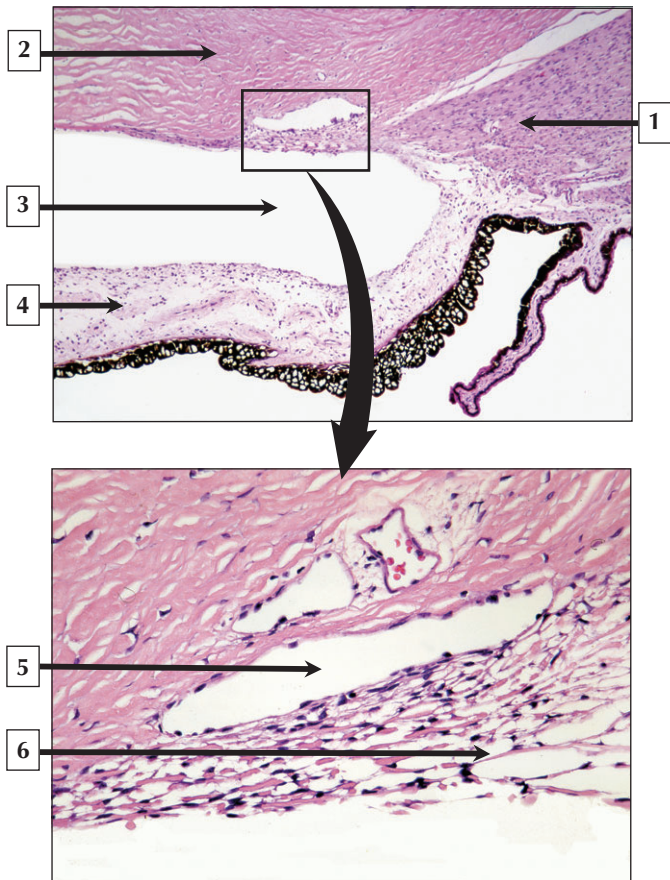
1. Ciliary muscle
2. Ciliary processes
3. Posterior chamber (filled with aqueous humor)
4. Zonular fibers
5. Ciliary epithelium (inner, nonpigmented layer)
6. Ciliary epithelium (outer, pigmented layer)

**Comment:** The ciliary body is a wedge-shaped fibromuscular ring that functions in accommodation and production of aqueous humor. It is a specialized part of the anterior uvea, and its inner surface has 70 to 80 radiating folds, or ciliary processes, covered by a double cuboidal ciliary epithelium. The outer layer is heavily pigmented, and its cells contain melanin. The inner layer is a nonpigmented ion-transporting epithelium, which modifies plasma filtrate that is then secreted into the posterior chamber as aqueous humor. Deep in the ciliary body is the ciliary muscle, which consists of 3 groups of smooth muscle cells oriented in different directions. The muscle contracts in accommodation.

Although **neoplasms** of the eye are rare, **uveal melanoma** is the most common intraocular **malignant tumor** in adults. It may arise from the ciliary body, iris, or choroid. It differs from **cutaneous melanoma** since it is not related to sun exposure, although lightly pigmented people are at risk of getting it. Early detection and treatment with **radiation** may improve survival.

*Low-power LM showing processes of the ciliary body and high-magnification LM of the ciliary epithelium*

## Canal of Schlemm and Aqueous Humor



## Canal of Schlemm and Aqueous Humor

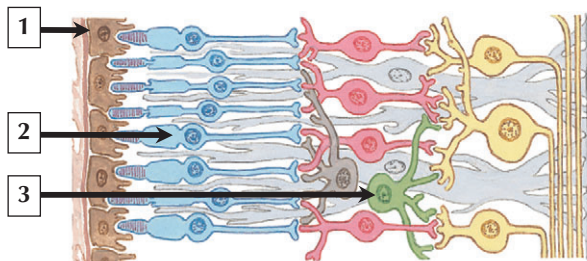
---

1. Ciliary muscle
2. Stroma (substantia propria) of cornea
3. Angle of anterior chamber (filled with aqueous humor)
4. Stroma of iris
5. Canal of Schlemm
6. Trabecular meshwork

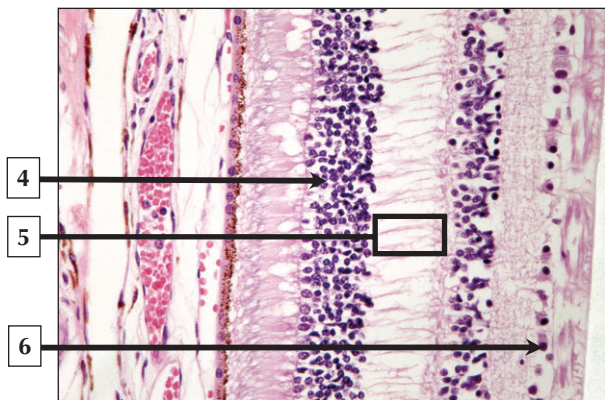
**Comment:** Aqueous humor is a clear fluid produced by processes of the ciliary body that is secreted into the posterior chamber. It circulates around the pupillary aperture, enters the anterior chamber, and reaches the iridocorneal angle (acute angle of the anterior chamber). The aqueous outflow apparatus consists of the trabecular meshwork of loose connective tissue and labyrinthine spaces of Fontana. The canal of Schlemm is anterior and lateral to the spaces and drains aqueous humor that filtered through the spaces. The canal is a thin-walled channel, about 400  $\mu\text{m}$  in diameter that is lined by endothelium and a discontinuous basement membrane.

Obstruction of the canal of Schlemm may lead to **glaucoma**, a common condition involving an abnormal increase in intraocular pressure. The 2 main forms are **primary open-angle** and **closed-angle glaucoma**, both of which may lead to **blindness** if intraocular pressure remains increased above 25 mm Hg (normal levels are 10 mm Hg to 20 mm Hg).

*LM of the acute iridocorneal angle of the anterior chamber and LM of the aqueous outflow apparatus at higher magnification*



*F. Netter*  
M.D.  
JOHN A. CRAIG MD





# Retina

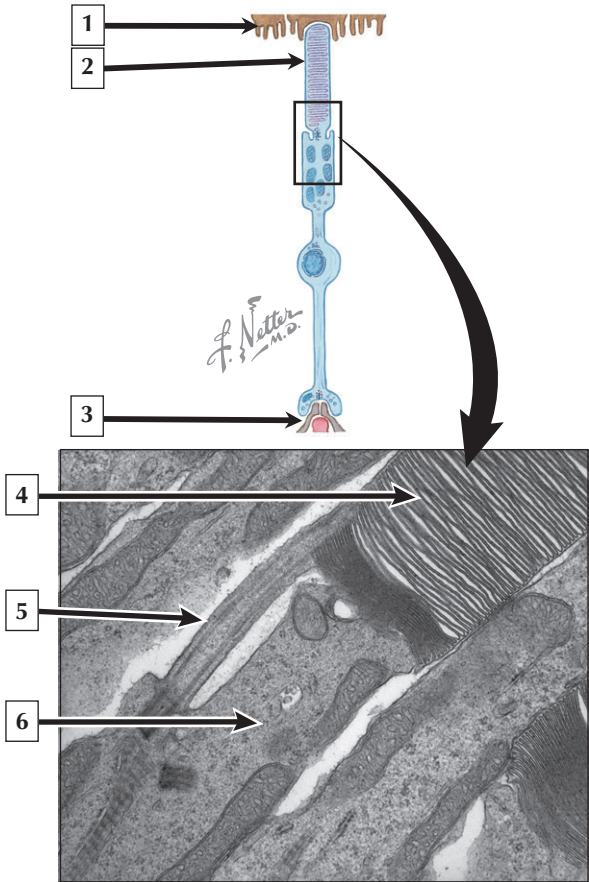
---

1. Retinal pigment epithelial cell
2. Inner segment of cone
3. Amacrine cell (supporting glial cell)
4. Outer nuclear layer (of rods and cones)
5. Outer plexiform layer
6. Ganglion cell

**Comment:** The retina is in the posterior segment of the eye. It is between the vascular choroid and vitreous body and has 2 parts derived embryonically from separate layers of the optic cup. The outer layer is the retinal pigment epithelium, which contains melanin-rich cuboidal cells. The inner stratified part is the neural retina, which contains several distinct layers: a layer of rods and cones, external limiting membrane, outer nuclear layer, outer plexiform layer, inner nuclear layer, inner plexiform layer, ganglion cell layer, nerve fiber layer, and internal limiting membrane. The retina receives blood supply from 2 separate, independent branches of the ophthalmic artery—ciliary and central arteries. A blood-retinal barrier, similar to the blood-brain barrier, is a tight permeability barrier in capillaries of the inner retina.

**Retinal detachment** is a common cause of **blindness** whereby neural retina separates from retinal pigment epithelium. Retinal detachment may occur in **diabetic retinopathy** and **intraocular infection**. Laser treatment has greatly improved the prognosis for this condition.

*Schematic and LM of the retina showing its many layers*



## Photoreceptors

---

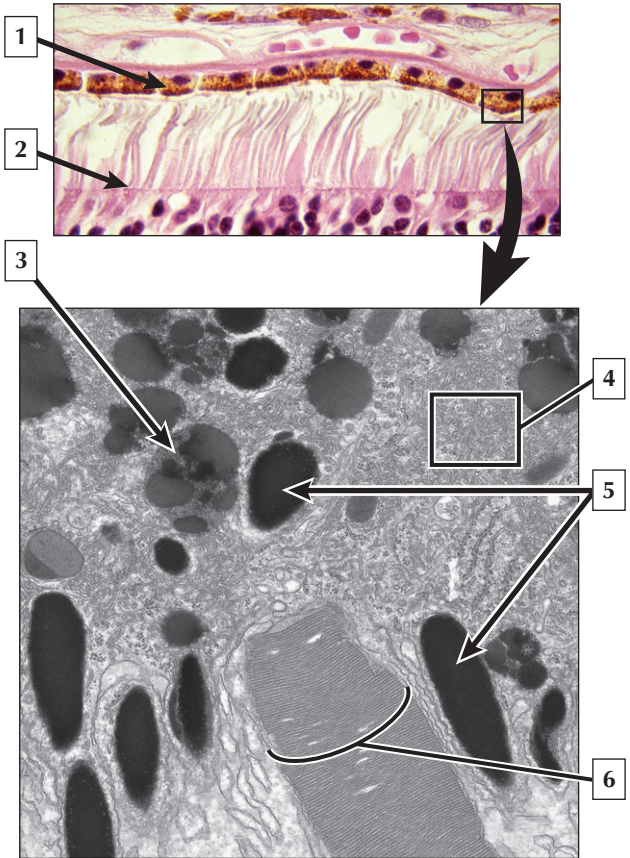
1. Apical process of retinal pigment epithelial cell
2. Outer segment of rod
3. Synaptic ending
4. Membranous disc in outer segment
5. Cilium
6. Inner segment of rod

**Comment:** The neural retina contains 3 sets of modified neurons (photoreceptors, bipolar cells, and ganglion cells) that are linked in series by synapses. Photoreceptors (rods and cones) are polarized sensory cells oriented parallel to each other. Outer segments of both rods and cones are modified cilia and are characterized by many parallel stacks of membranous discs, which contain visual pigments that absorb light and trigger the visual response. The discs are flattened, bilaminar, transverse saccules of plasma membrane, about 1  $\mu\text{m}$  in diameter, that are enclosed by an extension of this membrane. The inner segments of photoreceptors have many organelles such as ribosomes for protein synthesis and mitochondria to produce adenosine triphosphate (ATP) for energy.

**Retinoblastoma**, the most common intraocular **malignancy** in infants and children, is so named because most cells in the **tumor** resemble undifferentiated embryonic retinal cells called retinoblasts. Early detection and subsequent treatment by **surgery** or **chemotherapy** provide favorable results,

*Schematic of a rod and EM of part of a rod at the interface of outer and inner segments*

# Retinal Pigment Epithelium



# Retinal Pigment Epithelium

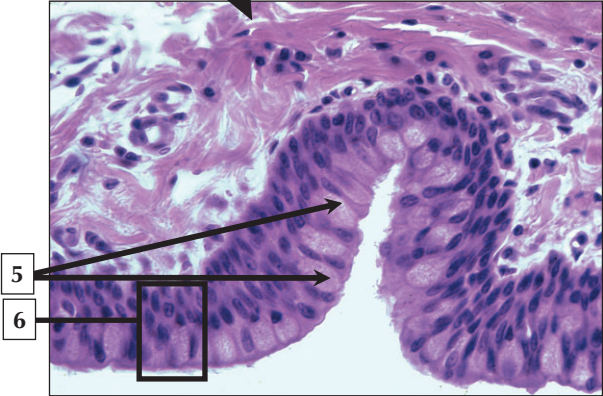
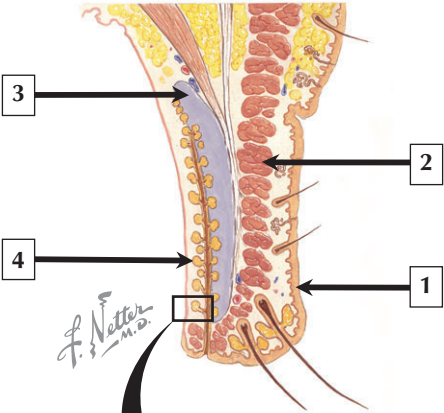
---

1. Retinal pigment epithelial cell
2. External limiting membrane
3. Residual body (tertiary lysosome)
4. Smooth endoplasmic reticulum
5. Melanin granules
6. Photoreceptor outer segment

**Comment:** Retinal pigment epithelium (RPE) is derived from neuroectoderm of the outer layer of the embryonic optic cup and consists of a single layer of melanin-rich cuboidal cells. Separated from the choroid by Bruch's membrane, RPE cells are between the choroid and outer tips of photoreceptors. Because the outer layer of the retina lacks blood vessels, oxygen and nutrients from fenestrated capillaries in the choroid must diffuse across the RPE for metabolic needs of photoreceptor cells. RPE cells have features of ion-transporting epithelium and also contribute to the blood-retinal barrier. Melanin granules in RPE cells respond to light by migrating toward the tips of photoreceptors to protect them from excessive light and increase visual discrimination.

**Retinitis pigmentosa** comprises a group of genetic diseases that lead to progressive **visual loss**. Among the many different forms, 1 subtype leads to photoreceptor cell death in response to genetic alteration in rhodopsin, accompanied by structural changes in retinal pigment epithelial cells. Patients experience tunnel vision and loss of visual acuity and color discrimination.

*LM of the outer part of the retina, and EM of part of an RPE cell*



# Eyelid

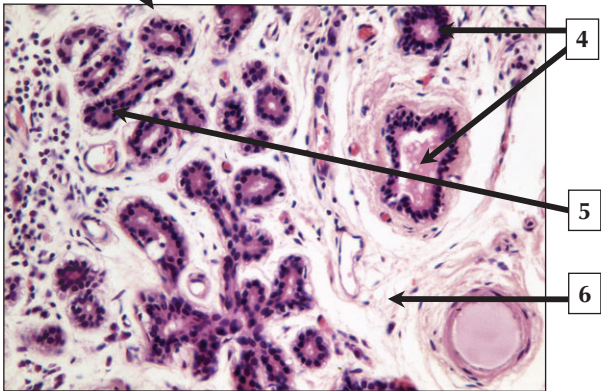
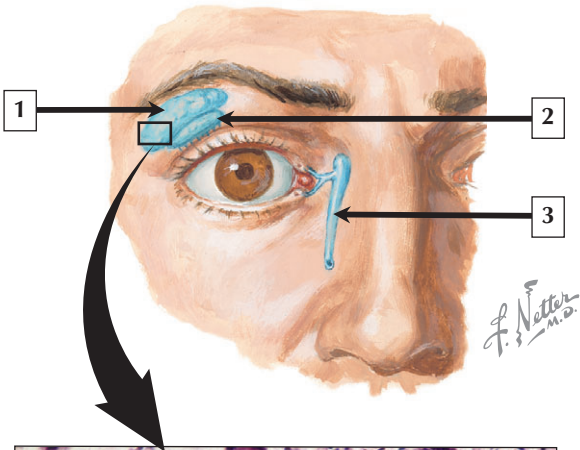
---

1. Stratified squamous keratinized epithelium of thin skin
2. Orbicularis oculi muscle
3. Tarsal plate
4. Meibomian sebaceous gland
5. Goblet cells
6. Stratified columnar epithelium of palpebral conjunctiva

**Comment:** The eyelids are movable folds of skin that cover the eyeballs anteriorly, help keep them moist, and protect them for physical injury and excessive light. Thin skin covers the outer surface, a transparent mucous membrane—the palpebral conjunctiva—internally. Stratified squamous keratinized epithelium covers the skin surface, and the conjunctiva is lined by stratified columnar epithelium, about 2 or 3 cells thick. Dense connective tissue of the tarsal plate provides support and rigidity to the center of each eyelid. The orbicularis oculi is skeletal muscle that closes the eyelid. Large Meibomian sebaceous glands discharge an oily secretion onto the free outer lid margin and prevent tears from evaporating. The palpebral conjunctiva is continuous with the bulbar conjunctiva, which reflects over the front of the eyeball.

**Conjunctivitis**, an inflammation of the bulbar and palpebral conjunctiva, may be caused by **bacterial** and **viral infection**, and **allergic responses**. Obstruction and subsequent infection of Meibomian glands in the eyelid form a hard nodular swelling under the palpebral conjunctiva called a **chalazion**.

*Schematic of the eyelid and LM of the palpebral conjunctiva*





## Lacrimal Gland

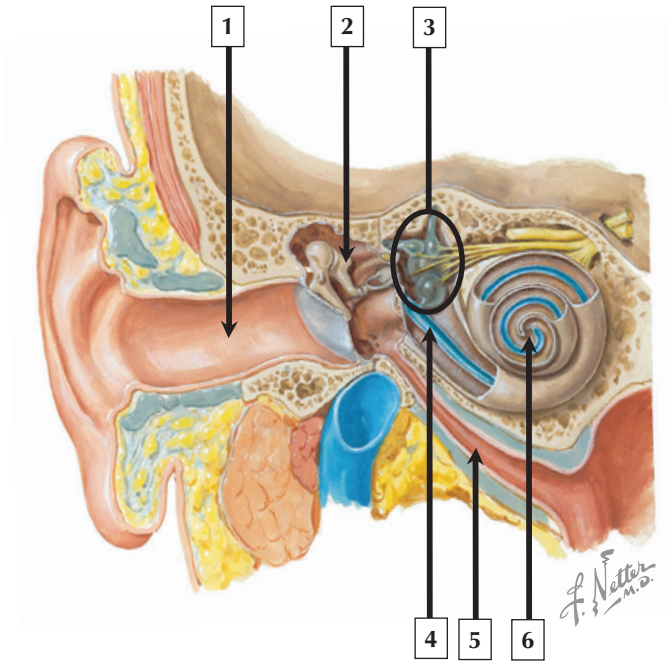
---

1. Orbital part of lacrimal gland
2. Palpebral part of lacrimal gland
3. Nasolacrimal duct
4. Excretory ducts
5. Secretory acinus lined by simple cuboidal epithelium
6. Stroma

**Comment:** The paired lacrimal glands are almond shaped, tubulo-acinar exocrine glands that produce tears. They consist of 2 parts—palpebral and orbital—and drain via 10 to 12 small ducts into the conjunctival sac. The lacrimal drainage apparatus consists of the conjunctival sac and nasolacrimal duct, which collect tears and drain them into the nasal cavity. Tears are produced by parenchymal cells of secretory acini, which are drained by small ducts that lie in a richly cellular connective tissue stroma. Tears moisten and lubricate the anterior cornea, and protect against bacterial infection. Secretion of tears is stimulated by parasympathetic fibers of the facial nerve (cranial nerve VII).

An alteration in the composition of tears or their inadequate production leads to **dry eye syndrome**, a common condition. It may cause eye irritation, sensitivity to light, and blurred vision. It is often associated with advanced age, menopause in women, and side effects of certain medications. Severe **dry eye** occurs in patients with **Sjögren syndrome**, a chronic multiorgan **autoimmune disease**.

*Schematic of the lacrimal apparatus and LM of a lacrimal gland*



# Ear

---

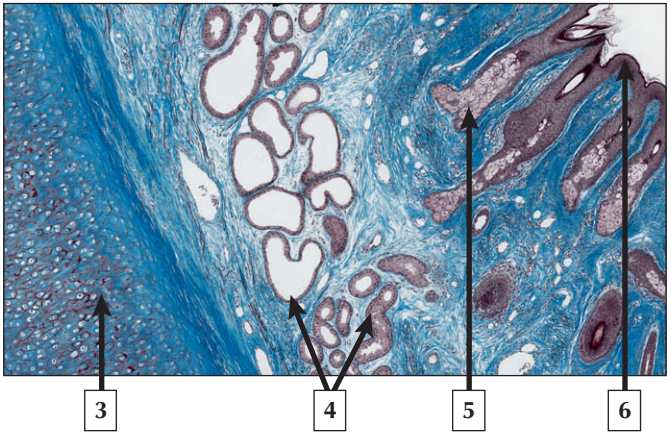
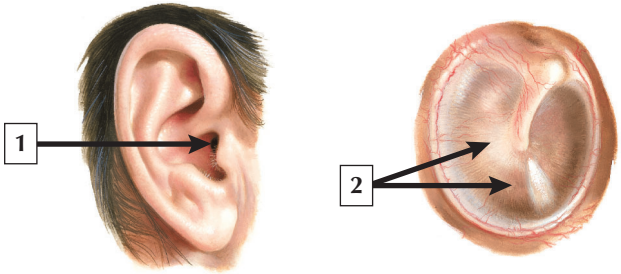
1. External acoustic meatus
2. Incus
3. Semicircular ducts, ampullae, utricle, and saccule
4. Cochlear duct (scala media)
5. Pharyngotympanic (auditory or Eustachian) tube
6. Helicotrema of cochlea

**Comment:** The ear has 3 parts. The external ear, consisting of auricle and external acoustic meatus, conducts sound waves to the tympanic membrane. The middle ear (tympanic cavity) is an air-filled cavity in the petrous temporal bone that transforms sound waves into mechanical vibrations. It contains 3 auditory ossicles and communicates with the nasopharynx via the auditory (Eustachian) tube. The inner ear (labyrinth) has special receptors for hearing and maintenance of equilibrium. The bony labyrinth contains perilymph. Internal to it is the membranous labyrinth, lined by epithelium, which houses endolymph. The saccule, utricle, and semicircular canals comprise the vestibular apparatus; the organ of Corti in the cochlea responds to sounds.

The most serious **ear disorders** are those of the inner ear that lead to **deafness**. **Congenital deafness** may be acquired by intrauterine infection with neurotrophic viruses, such as German measles (rubella). In **fetal rubella syndrome**, rubella virus causes serious damage to the organ of Corti in early embryonic development.

*Schematic (frontal section) of the ear showing its 3 parts*

# External Acoustic Meatus



## External Acoustic Meatus

---

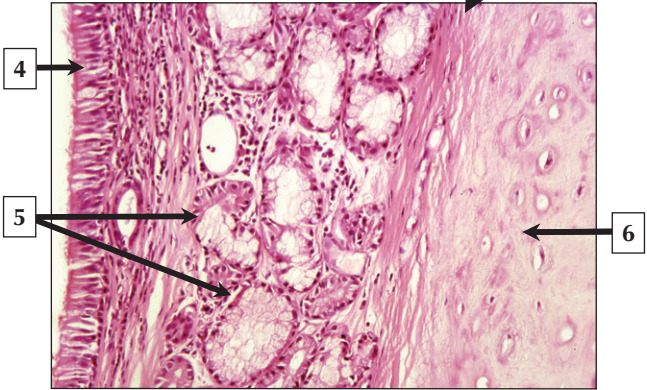
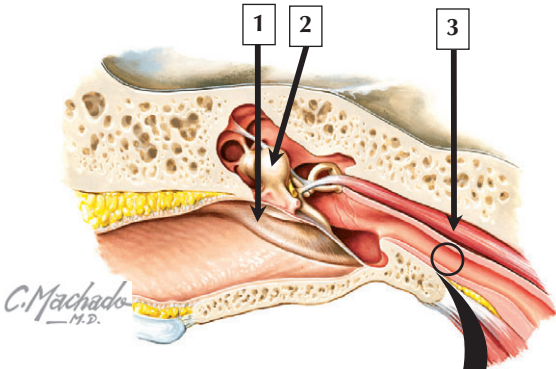
1. External acoustic meatus
2. Pars tensa of tympanic membrane (eardrum)
3. Elastic cartilage
4. Ceruminous gland
5. Sebaceous gland
6. Stratified squamous keratinized epithelium

**Comment:** The **external acoustic meatus** is an S-shaped tubular cul-de-sac about 2.5 cm long. The outer two thirds has elastic cartilage in its wall, which is continuous with that of the auricle. An inner osseous part is a tunnel through temporal bone. Both parts are lined by thin skin composed of stratified squamous keratinized epithelium. Associated with the epithelium are sebaceous glands and ceruminous glands, both of which contribute to yellowish earwax (cerumen). The tympanic membrane (or eardrum), about 0.1 mm thick, separates the external auditory meatus from the tympanic cavity and consists of a pars flaccida and pars tensa. The eardrum is an attenuated layer of connective tissue covered externally by thin skin and internally by mucous membrane.

**Acute otitis externa**, commonly called *swimmer's ear*, is inflammation, often with infection, of the external ear. The usual cause is infection with bacteria and less often fungus. If the canal becomes obstructed, conductive deafness may be a severe complication. Steroids and antibiotics are the usual treatment.

*Schematic views of the auricle and tympanic membrane, and LM of part of the external acoustic meatus (IHAB stain).*

# Middle Ear and Auditory Tube



## Middle Ear and Auditory Tube

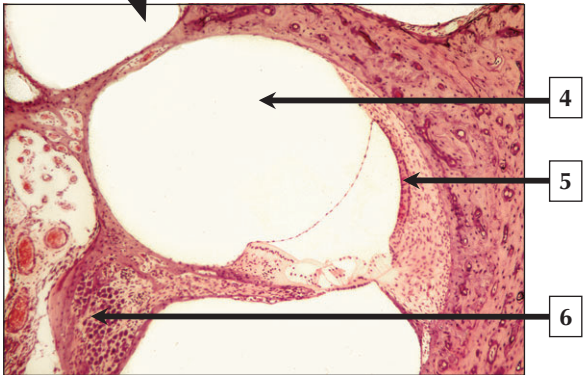
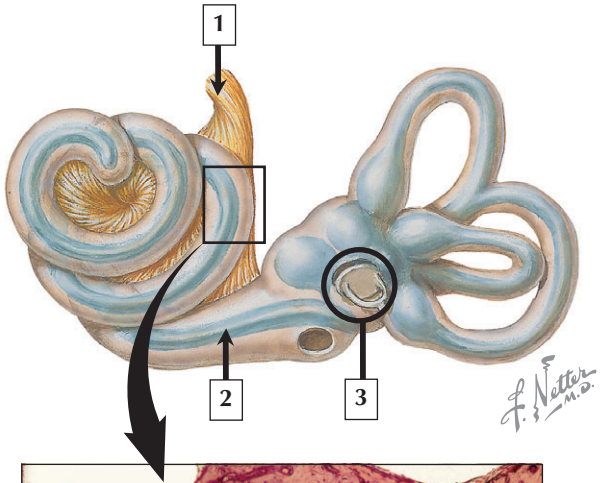
---

1. Tympanic membrane (eardrum)
2. Head of Malleus
3. Tensor tympani muscle
4. Pseudostratified ciliated columnar epithelium with goblet cells
5. Seromucous gland
6. Elastic cartilage

**Comment:** The middle ear (tympanic cavity) is an air space in temporal bone lined by mucous membrane. Its lateral wall is the tympanic membrane, and its medial wall contains the vestibular (oval) and cochlear (round) windows. Three auditory ossicles—malleus, incus, and stapes—are connected by typical synovial joints and extend across the tympanic cavity. Two skeletal muscles—tensor tympani and stapedius—insert into the ossicles, and contract in response to sounds. The auditory (Eustachian) tube connects the tympanic cavity with the nasopharynx. Most of its medial wall contains elastic cartilage. Its lumen is lined by pseudostratified ciliated columnar epithelium with goblet cells. Associated with the epithelium are mixed seromucous glands.

**Otitis media**—an acute **bacterial** or **viral infection** of the middle ear—is common in young children. It is often caused by migration of pathogens from the nasopharynx to the middle ear via the auditory tube. Usual treatment, if needed, is medication for pain and antibiotic therapy.

*Schematic view of the external and middle ear, and LM of the wall of the auditory tube*





# Cochlea

---

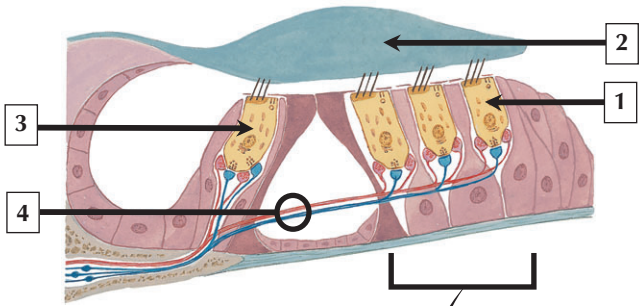
1. Cochlear nerve (part of cranial nerve VIII)
2. Cochlear duct (scala media)
3. Stapes and round window
4. Scala vestibuli (filled with perilymph)
5. Stria vascularis
6. Spiral ganglion

**Comment:** The cochlea resembles a snail shell. It is 30 mm to 35 mm long, forms  $2\frac{3}{4}$  turns from base to apex, and has a lumen with 3 compartments: scala media, vestibuli, and tympani. The scala media (cochlear duct)—a triangular space in cross section—is filled with endolymph. Its lateral border makes up the stria vascularis, which secretes endolymph. The scala vestibuli and tympani are filled with perilymph and communicate through the helicotrema. The basilar membrane forms the floor of the scala media on which is superimposed a highly specialized epithelium—the organ of Corti—consisting of hair cells and supporting cells. Cochlear hair cells are specialized auditory receptor cells. Their bases synapse with nerve fibers of the cochlear part of cranial nerve VIII, whose cell bodies are in the spiral ganglion.

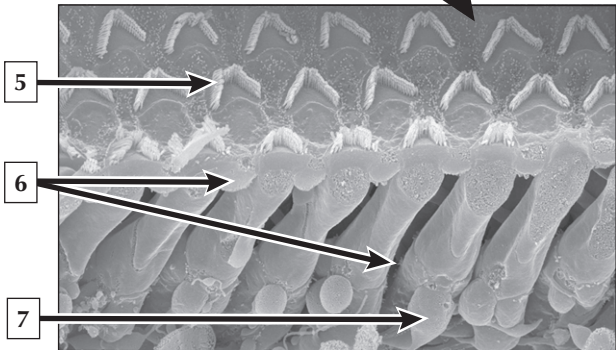
**Deafness** (hearing loss), a common condition often related to advancing age, takes 1 of 2 forms. **Conductive hearing loss** is due to a lesion in the external auditory canal or middle ear; **sensorineural hearing loss** is caused by a lesion in the cochlea or cochlear division of cranial nerve VIII.

*Schematic view of the membranous labyrinth within the bony labyrinth and LM of one of the turns of the cochlea*

# Organ of Corti



*F. Netter  
M.D.*



## Organ of Corti

---

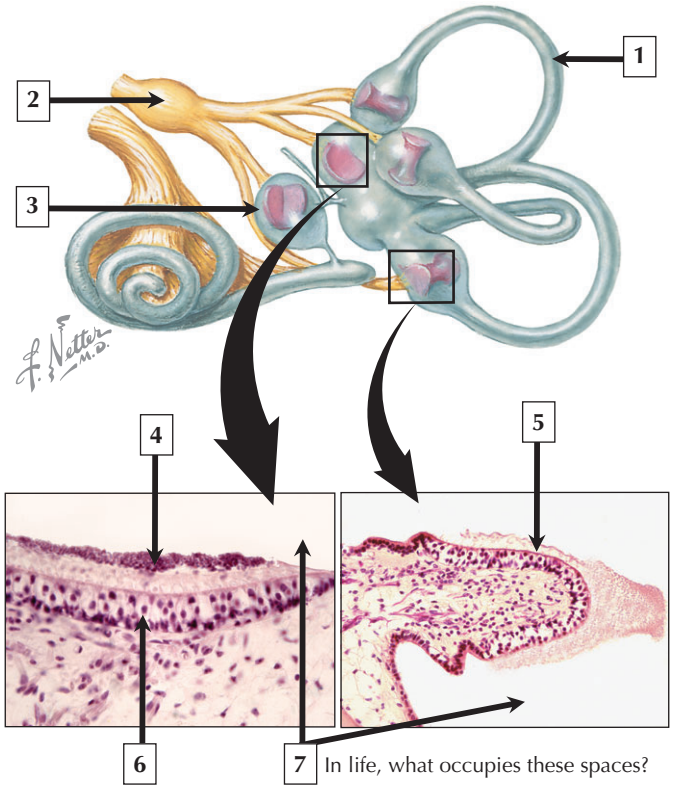
1. Outer hair cell
2. Tectorial membrane
3. Inner hair cell
4. Efferent and afferent nerve fibers
5. Stereocilia
6. Supporting cell processes
7. Nerve terminal

**Comment:** About 15,000 hair cells rest on the basilar membrane in each organ of Corti. Hair cells are arranged segmentally in 2 groups—a single row of inner hair cells and 3 rows of outer hair cells. Ultrastructurally, there are 2 different types of hair cells (I and II). They are polarized cells with apical stereocilia that project into the lumen of the cochlear duct. Stereocilia of the tallest hair cells protrude into the gelatinous and resilient tectorial membrane. Stereocilia of inner hair cells are organized as u-shaped bundles, whereas those of outer hair cells display a v- or w-shaped pattern. Synapsing at their bases are afferent and efferent nerve terminals of cranial nerve VIII. Their bases are also embedded in recesses formed by adjacent supporting cells.

Increased pressure in endolymph may lead to **Ménière's disease** whereby distortion of the membranous labyrinth may lead to degeneration of hair cells in both the vestibule and cochlea. Patients have recurrent episodes of **vertigo** (dizziness), **tinnitus** (ringing) and low-frequency **deafness**.

*Schematic and SEM of the organ of Corti*

# Vestibular Receptors



# Vestibular Receptors

---

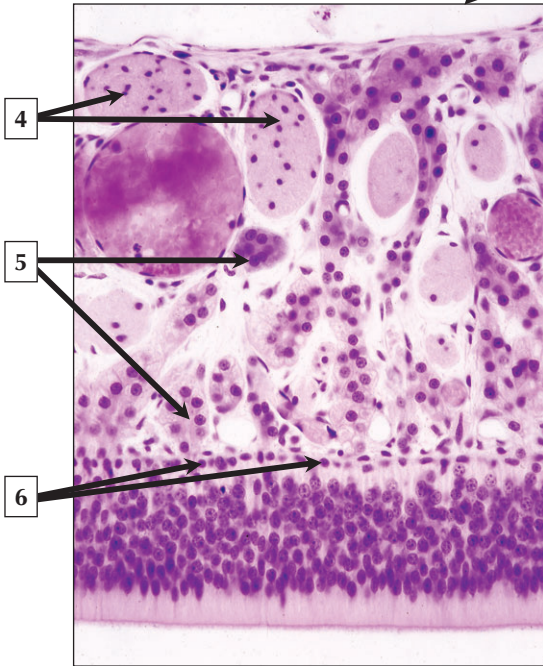
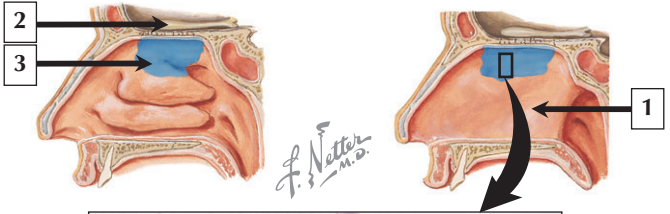
1. Semicircular canal
2. Vestibular ganglion
3. Sacculle
4. Otoconia in otolithic membrane
5. Sensory epithelium of crista ampullaris
6. Sensory epithelium of macula
7. Endolymph

**Comment:** The vestibular apparatus of the membranous labyrinth consists of 3 semicircular canals, a utricle, and a sacculle. The vestibular receptor areas in the utricle and sacculle are the macula; the crista ampullaris is the equivalent receptor area in the semicircular canals. Both the crista and macula have sensory epithelium that conforms to a common histologic plan. Hair cells with apical stereocilia as well as supporting cells constitute the epithelium in these receptors. Stereocilia of hair cells in the crista are embedded in the gelatinous cupula, whereas stereocilia of hair cells in the macula project into the gelatinous otolithic membrane containing crystals of calcium carbonate (otoconia).

**Benign paroxysmal positional nystagmus (BPPN)**, a disorder of the vestibular apparatus, is the most common cause of **vertigo (dizziness)**. It is due to altered displacement of otoliths into the semicircular canals. Common in the elderly or after head trauma, it has limited duration and usually resolves without treatment.

*Schematic of the membranous labyrinth and LMs of the macula (lower left) and crista ampullaris (lower right)*

# Olfactory Mucosa



## Olfactory Mucosa

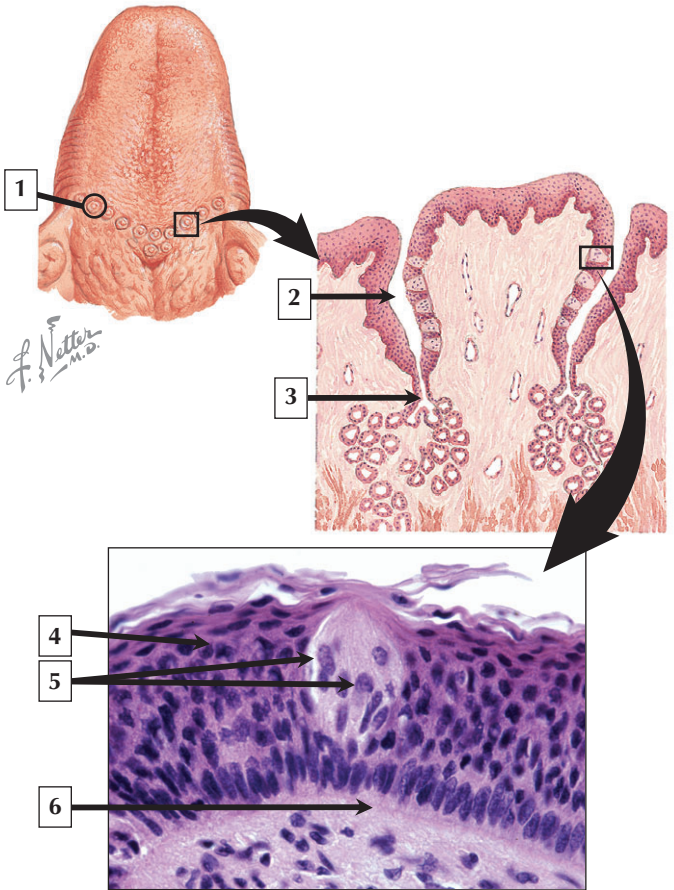
---

1. Nasal septum
2. Olfactory bulb
3. Olfactory epithelium in superior concha of nasal cavity
4. Nerve fascicles (unmyelinated)
5. Bowman's gland
6. Basal cells of olfactory epithelium

**Comment:** Olfactory mucosa is a mucous membrane that is specialized for smell. It is in the roof of the nasal cavity, superior concha, and nasal septum. It is lined by olfactory epithelium, a very thick pseudostratified epithelium that consists of 3 cell types: olfactory cells, sustentacular (supporting) cells, and basal cells. Olfactory cells, slender bipolar neurons spanning the width of the epithelium, are receptor cells that bind odoriferous substances and convert them to nerve impulses. The lamina propria, deep to the epithelium, is loose, highly vascular connective tissue containing many thin-walled blood vessels, unmyelinated nerve fascicles, and branched tubulo-alveolar glands of Bowman. The nerve fascicles converge to end in the olfactory bulb, from which neurons then form the olfactory nerve (cranial nerve I).

**Viral infection** of the olfactory mucosa related to the **common cold** may lead to **anosmia** (loss of smell). It may be partial or complete and may become permanent in chronic infection of the mucous membrane.

*Schematics of lateral nasal wall and septum showing distribution of olfactory epithelium and LM of the olfactory mucosa*





## Taste Buds

---

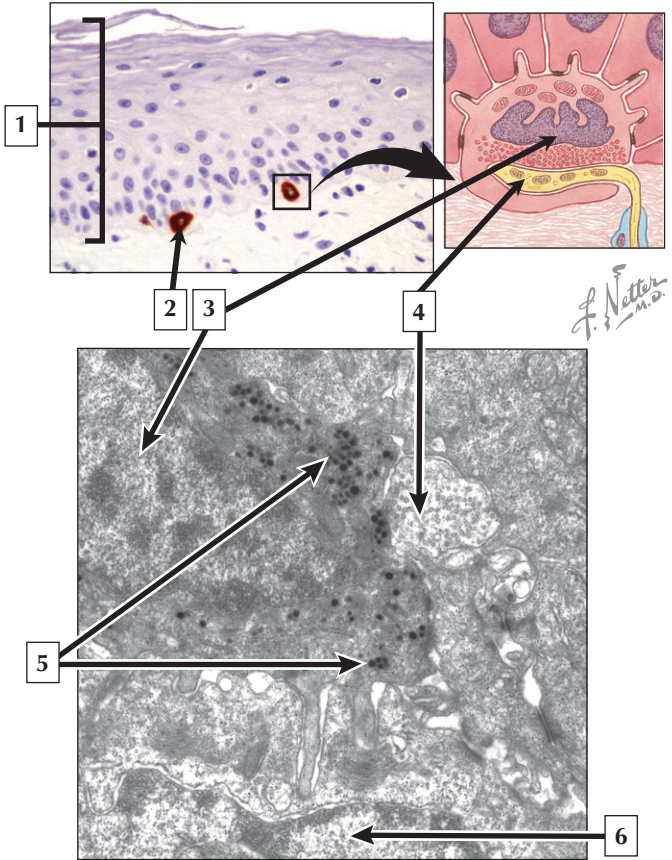
1. Circumvallate papilla
2. Lateral trench-like groove of circumvallate papilla
3. Duct of serous (von Ebner's) gland
4. Stratified squamous epithelium of oral mucosa
5. Cells of taste bud
6. Basement membrane

**Comment:** Taste buds are widely distributed in fungiform, foliate, and circumvallate papillae of the stratified squamous epithelium on the dorsal aspect of the tongue. They are also found on the soft palate, pharynx, and epiglottis. Taste buds are barrel-shaped clusters of pale-staining cells lying vertically in the stratified squamous epithelium. Each taste bud has 50 to 75 cells, whose arrangement resembles segments of a citrus fruit. Three types of cells occupy each taste bud. Taste (gustatory) cells are slender, spindle-shaped, chemoreceptive cells with apical microvilli. These cells are mixed with tall supporting cells that resemble staves of a barrel, and small, rounded basal cells resting on a basement membrane. Afferent nerve fibers contact the bases of taste cells via synapses.

A reduced sense of taste, known as **hypogeusia**, may adversely affect quality of life. **Oral infections** (such as **gingivitis**), oral surgical procedures, and radiation of the head and neck can interfere with taste. Taste deficits in the elderly have been implicated in weight loss, impaired immunity, and malnutrition.

*Schematic of the tongue and a circumvallate papilla, and LM of a taste bud in the oral mucosa*

# Merkel Cells



## Merkel Cells

---

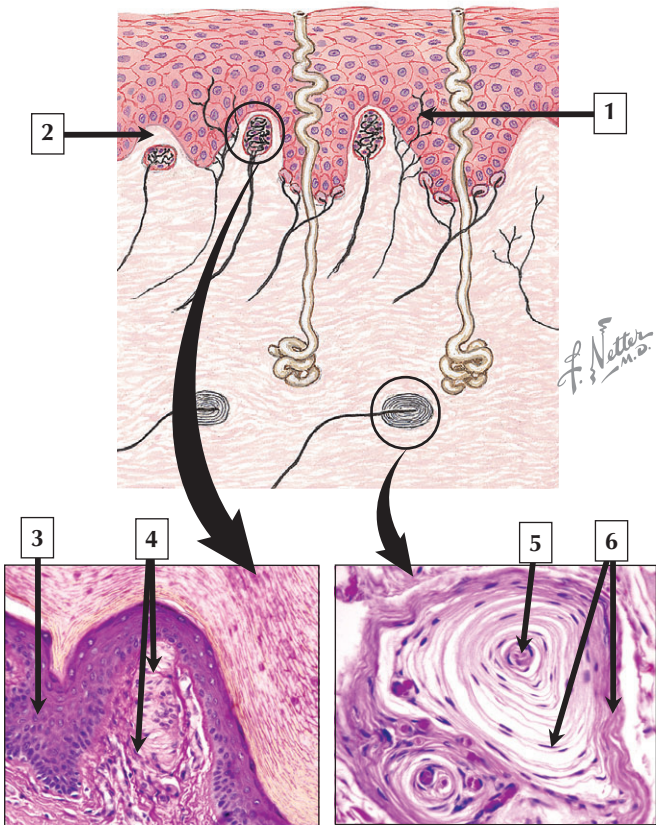
1. Epidermis of skin
2. Merkel cell
3. Nucleus of Merkel cell
4. Afferent nerve terminal
5. Dense core vesicles
6. Nucleus (euchromatin) of keratinocyte

**Comment:** Merkel cells are neural crest-derived cells found in glabrous and hairy skin, as well as some mucous membranes. They express various substances such as neuron-specific proteins and cytokeratin 20. Merkel cells are not seen by usual histologic methods and require special stains (e.g., immunocytochemistry) or electron microscopy. Merkel cell-neurite complexes—slowly adapting touch receptors—consist of enlarged terminal endings of afferent nerve fibers, which form synaptic contacts with Merkel cells that have distinctive dense core vesicles. Merkel cells respond to punctate pressure and bending of hairs and transform mechanical signals into action potentials in the nerve terminals.

**Merkel cell carcinomas**, a rare, aggressive form of **skin cancer**, usually occur in the head and neck, and often affect the elderly. Sun exposure is a risk factor, and these tumors have a tendency to recur locally and **metastasize**. Chromosomal abnormalities, similar to those seen in **neuroblastoma** and **melanoma tumors**, are also associated with Merkel cell tumors.

*LM (immunocytochemistry) showing Merkel cells in skin and schematic and companion EM of Merkel cell-neurite complexes*

# Cutaneous Receptors



## Cutaneous Receptors

---

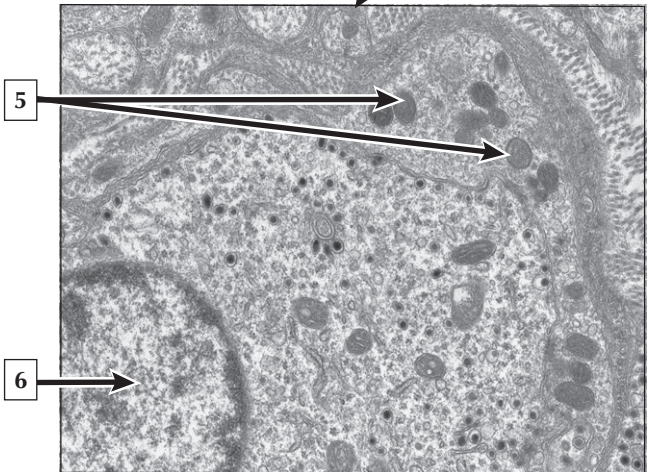
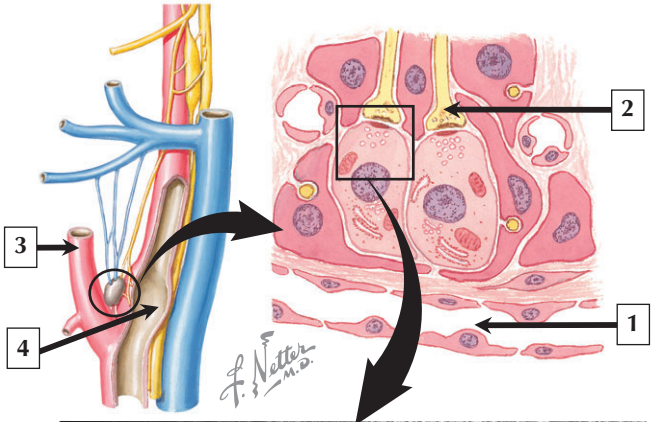
1. Free nerve ending in epidermis
2. Dermal papilla in skin
3. Stratified squamous epithelium of epidermis
4. Capsular lamellae of Meissner's corpuscle
5. Unmyelinated sensory nerve fiber in Pacinian corpuscle
6. Concentric capsular lamellae of Pacinian corpuscle

**Comment:** Meissner's and Pacinian corpuscles are rapidly adapting encapsulated mechanoreceptors in dermis of fingertips, palms of the hands, and soles of the feet. Pacinian corpuscles also occur in mesenteries, periosteum of bone, genital organs, and near tendinous insertions and joint capsules. Meissner's corpuscles in dermal papillae are sensitive to fine tactile stimuli, whereas Pacinian corpuscles, which are usually deep in the dermis and subcutaneous connective tissue of skin, respond to pressure, vibration, and gross tactile stimuli. Both receptors are supplied by a single sensory nerve fiber enveloped by multiple capsular lamellae, which are formed by flattened perineurial cells.

Because the main neural pathway for transmission of sensory information from Meissner's and Pacinian corpuscles to the cerebral cortex is the dorsal column-medial lemniscus, lesions of this system affect 2 point tactile discrimination and sensation of vibration. Such deficits may be due to a **cerebrovascular accident (CVA)**, commonly known as a **stroke**.

*Schematic showing sensory receptors in thick skin and LMs of a Meissner's (lower left) and Pacinian (lower right) corpuscle*

# Carotid Body and Carotid Sinus



## Carotid Body and Carotid Sinus

---

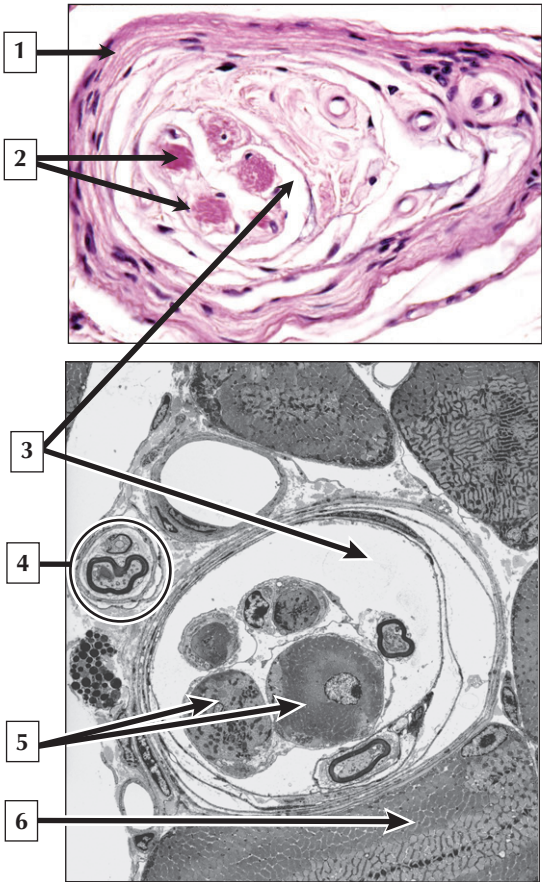
1. Sinusoidal capillary
2. Afferent nerve terminal synapsing on glomus cell
3. External carotid artery
4. Carotid sinus
5. Mitochondria in afferent nerve terminal
6. Nucleus (euchromatin) of glomus cell

**Comment:** Carotid bodies are encapsulated lenticular structures found at the bifurcation of the common carotid artery. They contain chemoreceptors that respond to changes in pH, O<sub>2</sub>, and CO<sub>2</sub> in arterial blood. Each carotid body contains groups of chemoreceptor cells close to sinusoidal capillaries. Type II (sheath) cells surround clusters of type I (glomus) cells. Glomus cells are regarded as paraneurons, which store various substances, such as serotonin and enkephalins, in dense core vesicles. Dendrites of afferent nerve fibers of cranial nerve IX synapse with glomus cells. Acetylcholine and dopamine are neurotransmitters. The carotid sinus, a dilated part of the internal carotid artery, contains free and encapsulated nerve endings that are sensitive to stretch.

The carotid bodies normally undergo **involution** with advancing age, characterized by reduction in the number of glomus cells. On the other hand, people who become acclimatized to high altitude have enlarged carotid bodies due to **hyperplasia** of glomus cells in response to **hyperbaric hypoxia**.

*Schematic views of carotid bodies and EM of a synapse in a carotid body*

# Muscle Spindles





# Muscle Spindles

---

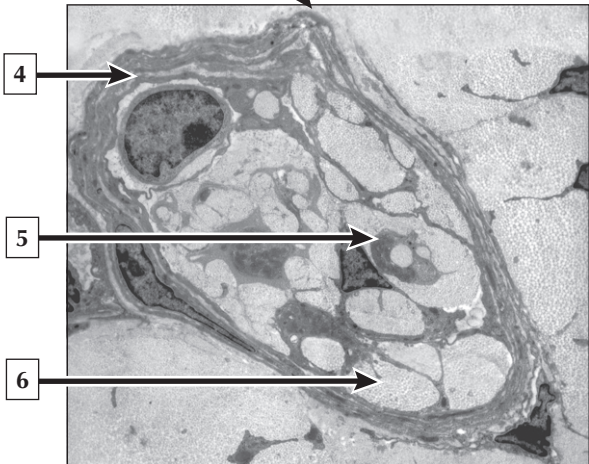
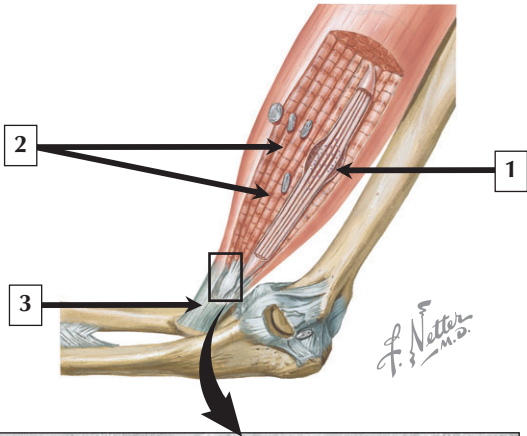
1. Capsule of muscle spindle
2. Intrafusal muscle fibers
3. Periaxial space
4. Nerve
5. Nuclear bag fibers
6. Extrafusal muscle fiber

**Comment:** Muscle spindles are encapsulated sensory receptors found in almost every skeletal muscle in the body. They parallel surrounding extrafusal fibers that make up the bulk of the muscle. As part of the myotatic stretch reflex, they monitor changes in length of the whole muscle. Each muscle spindle has a multilayered outer capsule surrounding a periaxial space, which contains 2 types of intrafusal muscle fibers—nuclear bag and nuclear chain fibers. Polar regions of intrafusal fibers are innervated by motor nerve endings, whereas equatorial regions of the intrafusal fibers are innervated by sensory nerve terminals. When the muscle is stretched, the sensory terminals trigger nerve impulses, which are conveyed to the spinal cord.

The **tendon tap (knee jerk) reflex test**, performed as part of the **neurologic examination**, helps detect the integrity of the myotatic stretch reflex mediated by muscle spindles within a muscle. Using a reflex hammer, the test helps detect abnormalities in the central and peripheral nervous systems, and diagnose **spinal cord injury** and **neuromuscular diseases**.

*LM and EM of muscle spindles in transverse section*

# Muscle and Joint Receptors



## Muscle and Joint Receptors

---

1. Equatorial region of muscle spindle
2. Extrafusal muscle fibers
3. Tendon
4. Capsule of Golgi tendon organ
5. Sensory nerve terminal
6. Collagen fibers

**Comment:** Muscle spindles and Golgi tendon organs provide afferent feedback to the central nervous system from muscles and tendons, respectively. Whereas muscle spindles are encapsulated proprioceptors monitoring stretch in skeletal muscles, tendon organs are encapsulated, slowly adapting mechanoreceptors that sense tension in tendons. Each Golgi tendon organ is innervated by a single myelinated (1b) nerve fiber that penetrates a multilayered capsule and branches into unmyelinated sensory nerve terminals close to encapsulated collagen fiber bundles. Pressure exerted onto the capsule and collagen deforms sensory nerve terminals and stimulates them to generate action potentials.

Since muscle spindles and Golgi tendon organs are the main proprioceptors of joints, tendons, and skeletal muscles, the physiotherapeutic protocol known as **proprioceptive training** is effective in rehabilitation of knee and ankle injuries. Benefits include enhancement of joint position sense, postural stability, and muscle tone, and prevention of injuries to ligaments in joints.

*Schematic of muscle and joint receptors and EM of a Golgi tendon organ in transverse section*

Uploaded by [StormRG]