

611
А 643

КИШИ—СЕНТАГОТАИ

АНАТОМИЧЕСКИЙ АТЛАС
ЧЕЛОВЕЧЕСКОГО ТЕЛА

ТОМ III

ATLAS ANATOMIAE CORPORIS HUMANI

COMPOSUERUNT

DR. MED. FRANCISCUS KISS
PROFESSOR EMERITUS UNIVERSITATIS
BUDAPEST

DR. MED. IOHANNES SZENTÁGOTHAJ
PROFESSOR PUBLICUS ORDINARIUS UNIVERSITATIS
BUDAPEST

TOMUS III.

SYSTEMA NERVOSUM · ANGIOLOGIA
ORGANA SENSUUM

EDITIO VICESIMA QUINTA

28.21

AKADÉMIAI KIADÓ — MEDICINA KÖNYVKIADÓ
AEDES ACADEMIAE SCIENTIARUM HUNGARICAE — AEDES «MEDICINA»
BUDAPESTINI MCMLXV

611
A 643

АНАТОМИЧЕСКИЙ АТЛАС ЧЕЛОВЕЧЕСКОГО ТЕЛА

ПОД РЕДАКЦИЕЙ

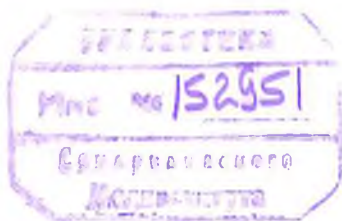
ПРОФЕССОРА
Д-Р ФЕРЕНЦ КИШШ
БУДАПЕШТ

ПРОФЕССОРА
Д-Р ЯНОШ СЕНТАГОТАИ
БУДАПЕШТ

ТОМ III

НЕРВНАЯ СИСТЕМА · СОСУДИСТАЯ СИСТЕМА
ОРГАНЫ ЧУВСТВ

ДВАДЦАТЬ ПЯТОЕ ИЗДАНИЕ



AKADÉMIAI KIADÓ – MEDICINA KÖNYVKIADÓ
ИЗДАТЕЛЬСТВО АКАДЕМИИ НАУК ВЕНГРИИ – ИЗДАТЕЛЬСТВО «МЕДИЦИНА»
БУДАПЕШТ 1965

Сотрудники авторов

д-р Б. З О Л Ь Н А И

д-р И. М У Н К А Ч И

Прежние издания атласа

1. НА ВЕНГЕРСКОМ ЯЗЫКЕ, формат В/5, по ВНА, том	I	1946 г.
	II	1948 г.
	III	1951 г.
2. НА ВЕНГЕРСКОМ ЯЗЫКЕ, формат В/5, по ВНА, том	I—II	1953 г.
	III	1954 г.
3. НА НЕМЕЦКОМ ЯЗЫКЕ, формат В/5, по JNA, том	I—III	1955 г.
4. НА ВЕНГЕРСКОМ ЯЗЫКЕ, формат А/4, по ВНА, том	I—III	1959 г.
5. НА РУССКОМ И БОЛГАРСКОМ ЯЗЫКАХ, формат А/4, по ВНА, том	I—III	1959 г.
6. НА КИТАЙСКОМ ЯЗЫКЕ, формат А/4, по ВНА, том	I—III	1959 г.
7. НА НЕМЕЦКОМ ЯЗЫКЕ, формат А/4, по ВНА, том	I—III	1960 г.
8. НА АНГЛИЙСКОМ ЯЗЫКЕ, формат А/4, по ВНА, том	I—III	1960 г.
9. НА РУССКОМ ЯЗЫКЕ, формат А/4, по ВНА, том	I—III	1960 г.
10. НА НЕМЕЦКОМ ЯЗЫКЕ, формат А/4, по ВНА, том	I—III	1961 г.
11. НА ИСПАНСКОМ ЯЗЫКЕ, формат А/4, по ВНА, том	I—III	1962 г.
12. НА РУССКОМ ЯЗЫКЕ, формат А/4, по PNA, том	I—III	1962 г.
13. НА НЕМЕЦКОМ ЯЗЫКЕ, формат А/4, по PNA, том	I—III	1962 г.
14. НА ЧЕШСКОМ ЯЗЫКЕ, формат А/4, по PNA, том	I—III	1963 г.
15. НА РУССКОМ ЯЗЫКЕ, формат А/4, по PNA, том	I—III	1963 г.
16. НА ВЕНГЕРСКОМ ЯЗЫКЕ, формат А/4, по PNA, том	I—III	1963 г.
17. НА АНГЛИЙСКОМ ЯЗЫКЕ, формат А/4, по PNA, том	I—III	1964 г.
18. НА НЕМЕЦКОМ ЯЗЫКЕ, формат А/4, по PNA, том	I—III	1964 г.
19. НА НЕМЕЦКОМ ЯЗЫКЕ, формат А/4, по PNA, том	I—III	1965 г.
20. НА ФРАНЦУЗСКОМ ЯЗЫКЕ, формат А/4, по PNA, том	I—III	1965 г.
21. НА ИСПАНСКОМ ЯЗЫКЕ, формат А/4, по PNA, том	I—III	1965 г.
22. НА НЕМЕЦКОМ ЯЗЫКЕ, формат А/4, по PNA, том	I—III	1965 г.
23. НА НЕМЕЦКОМ ЯЗЫКЕ, формат А/4, по PNA, том	I—III	1965 г.
24. НА НЕМЕЦКОМ ЯЗЫКЕ, формат А/4, по PNA, том	I—III	1965 г.

SYSTEMA NERVOSUM CENTRALE

Центральный нерв
система.

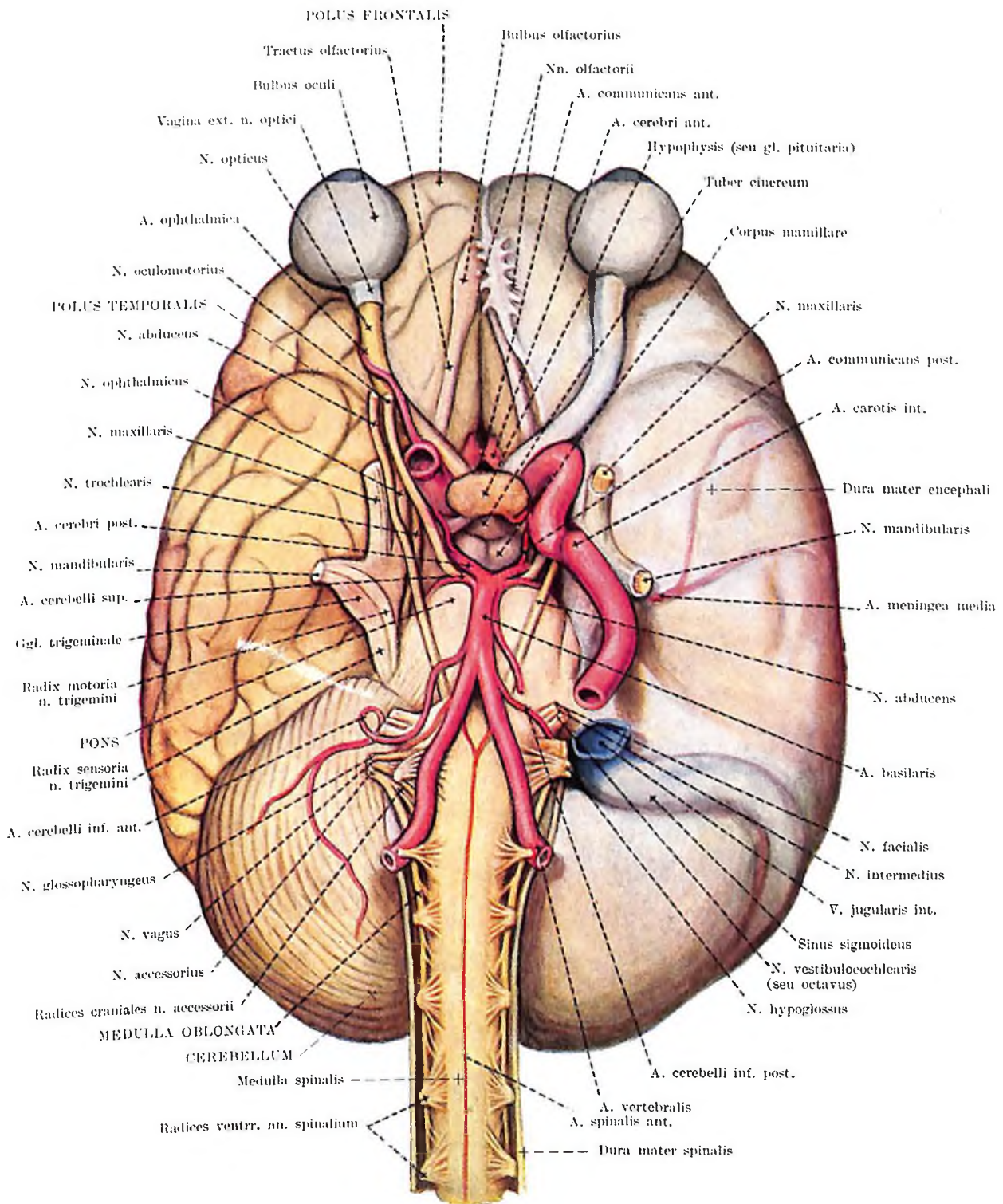


Fig. 1. BASIS CEREBRI
(arteriae baseos cerebri et nervi craniales)

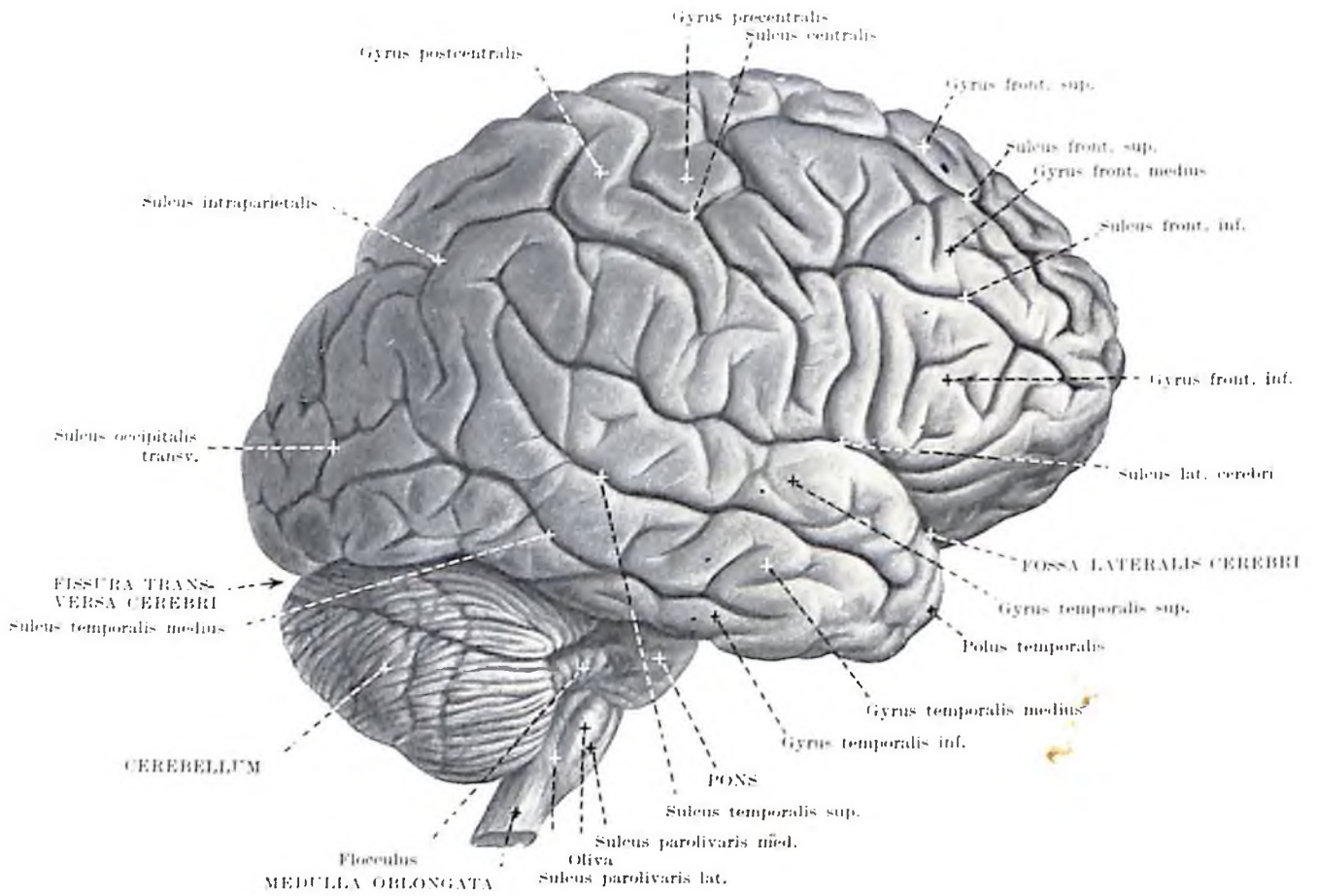


Fig. 2. ENCEPHALON I.
(aspectus lateralis dext.)

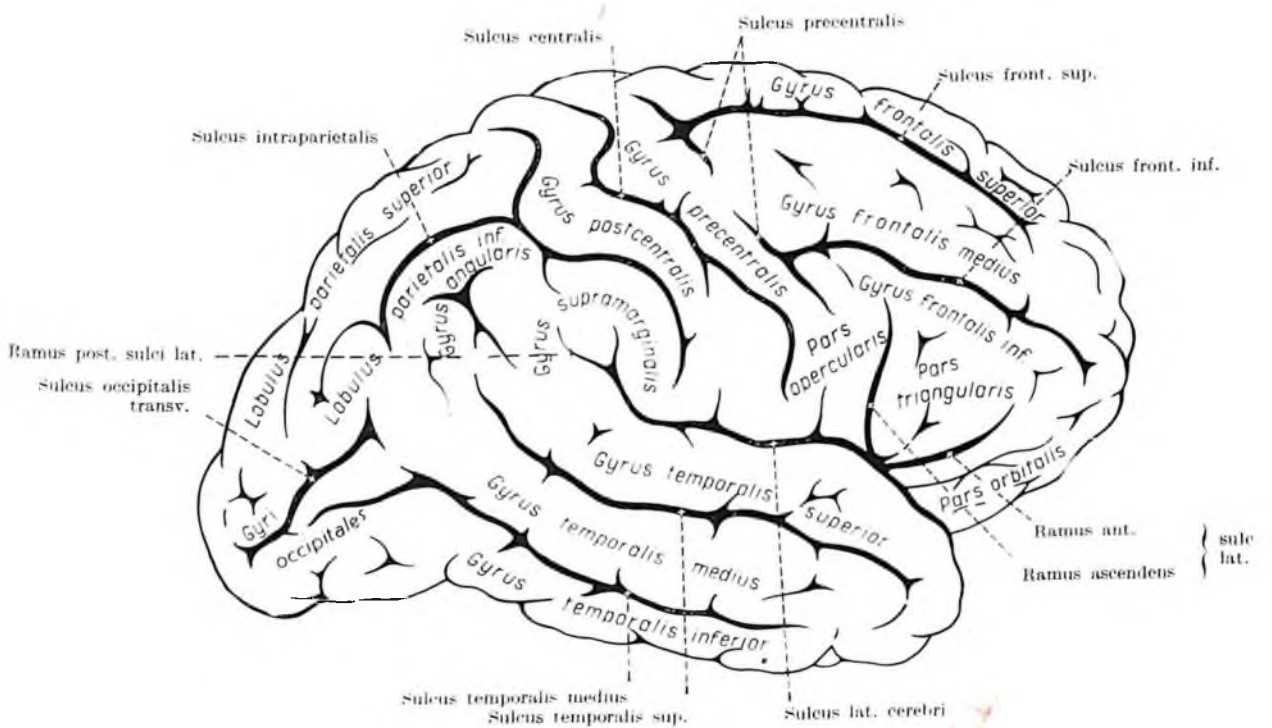


Fig. 3. SULCI ET GYRI CEREBRI I.
(facies supero-lateralis hemispherii, aspectus dext.)

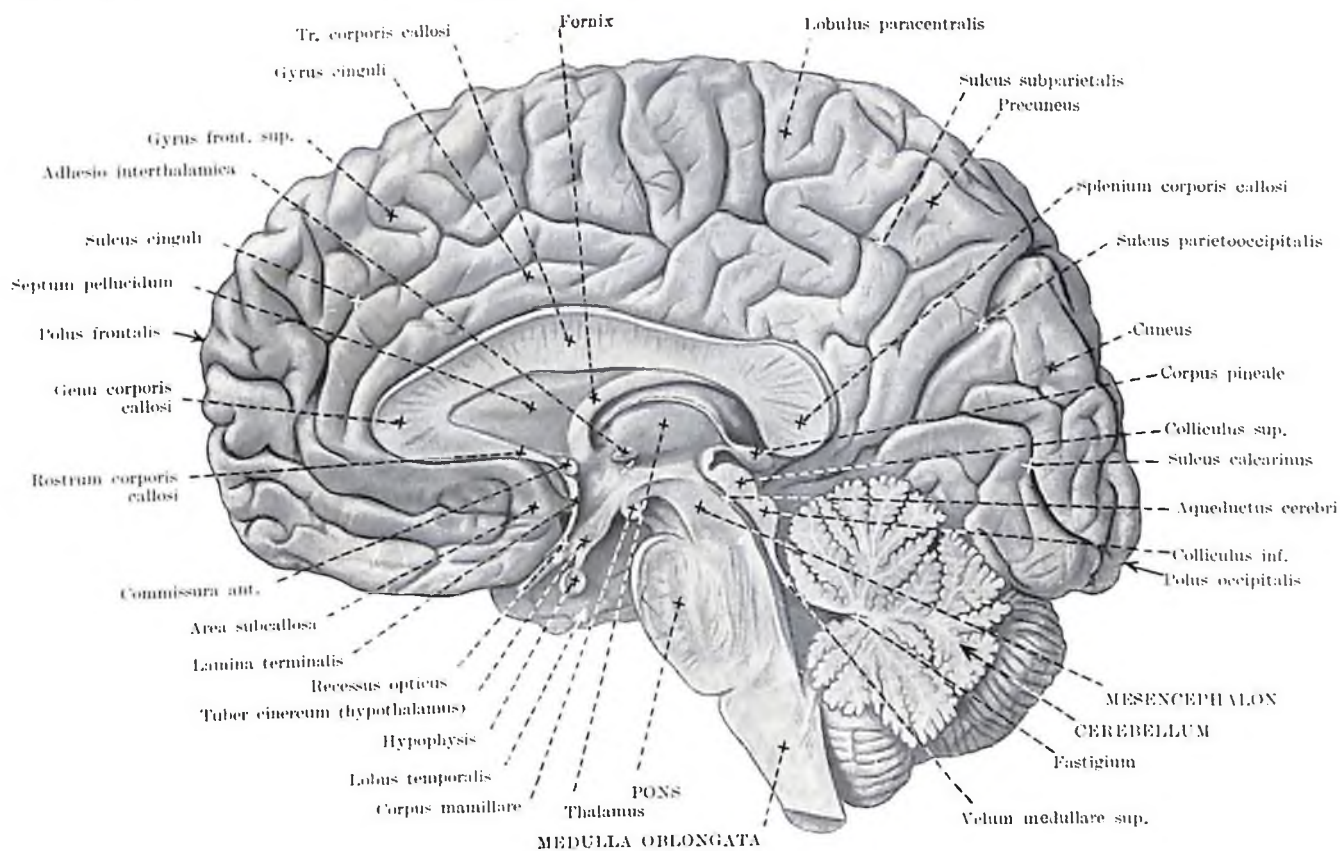


Fig. 4. ENCEPHALON II.
(sectio sagittalis, aspectus medialis, 1. dext.)

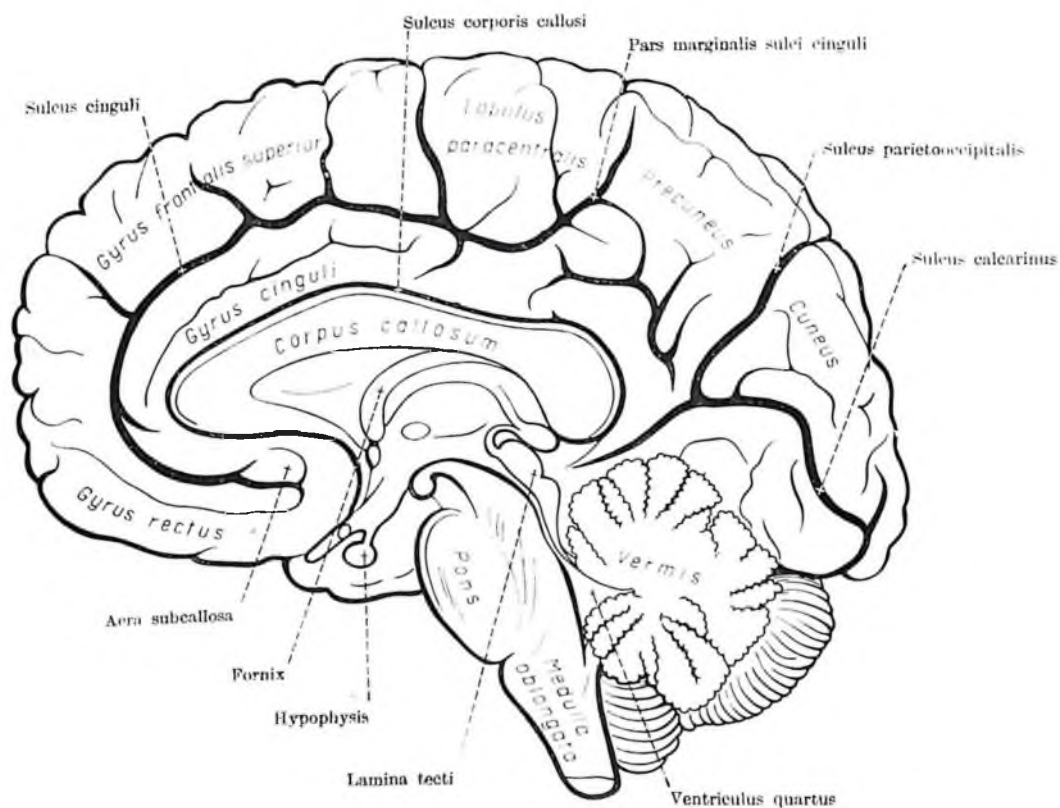


Fig. 5. SULCI ET GYRI CEREBRI II.
(facies medialis hemispherii, sectio sagittalis encephali)

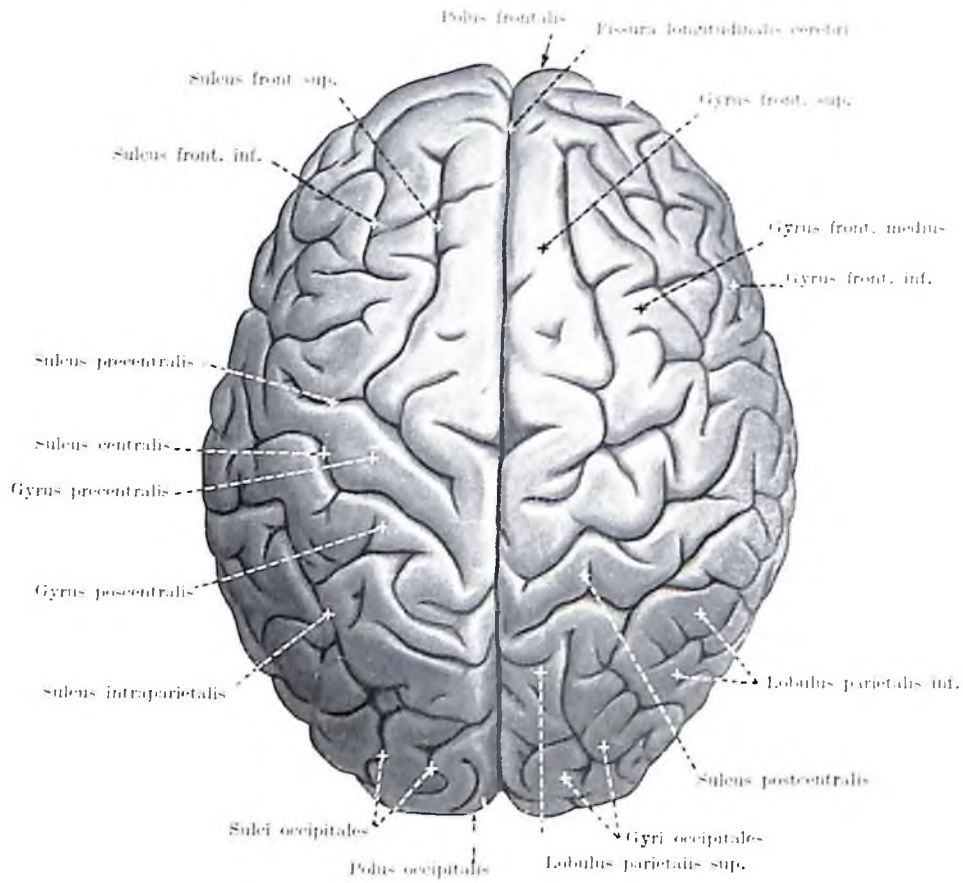


Fig. 6. ENCEPHALON III.
(aspectus superior)

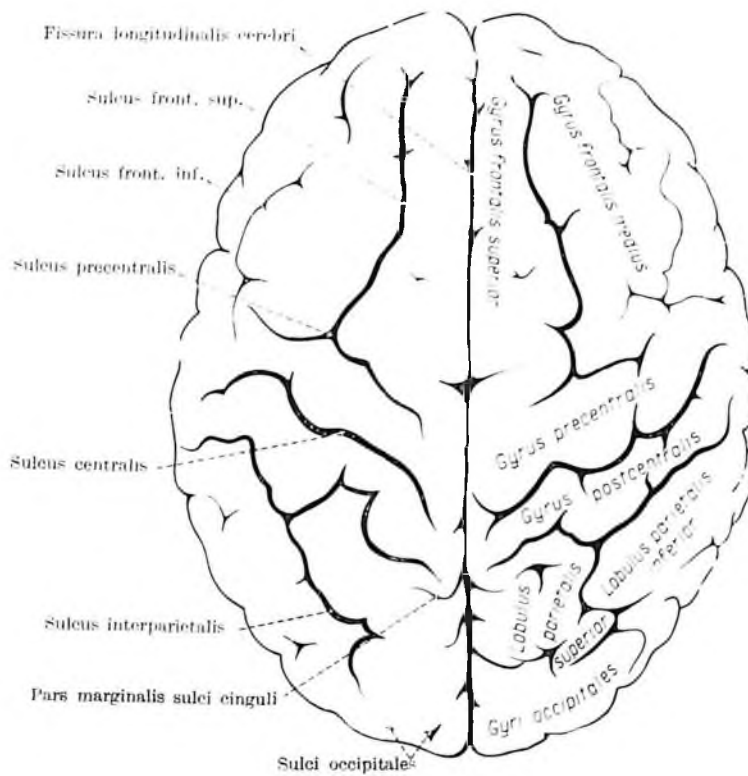


Fig. 7. SULCI ET GYRI CEREBRI III.
(facies supero-laterales hemispheriorum, aspectus superior)

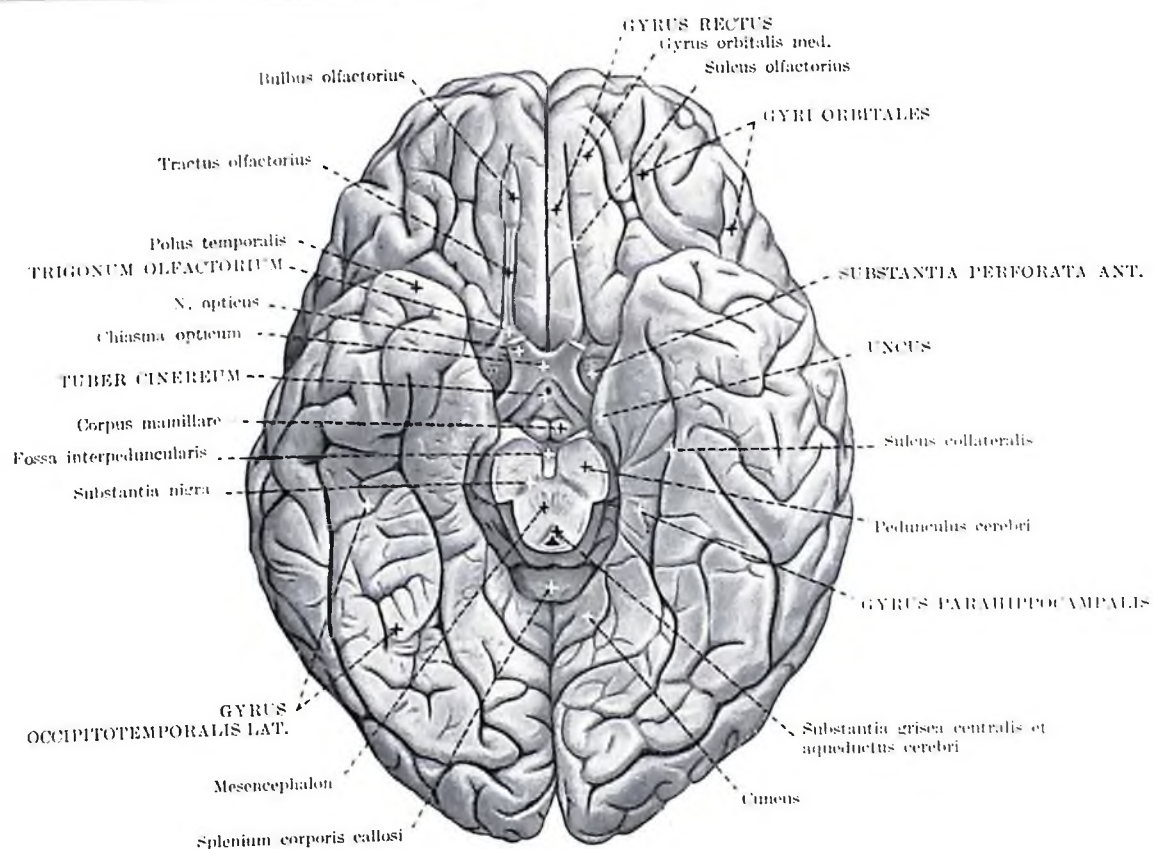


Fig. 8. FACIES INFERIOR CEREBRI
(aspectus inferior)

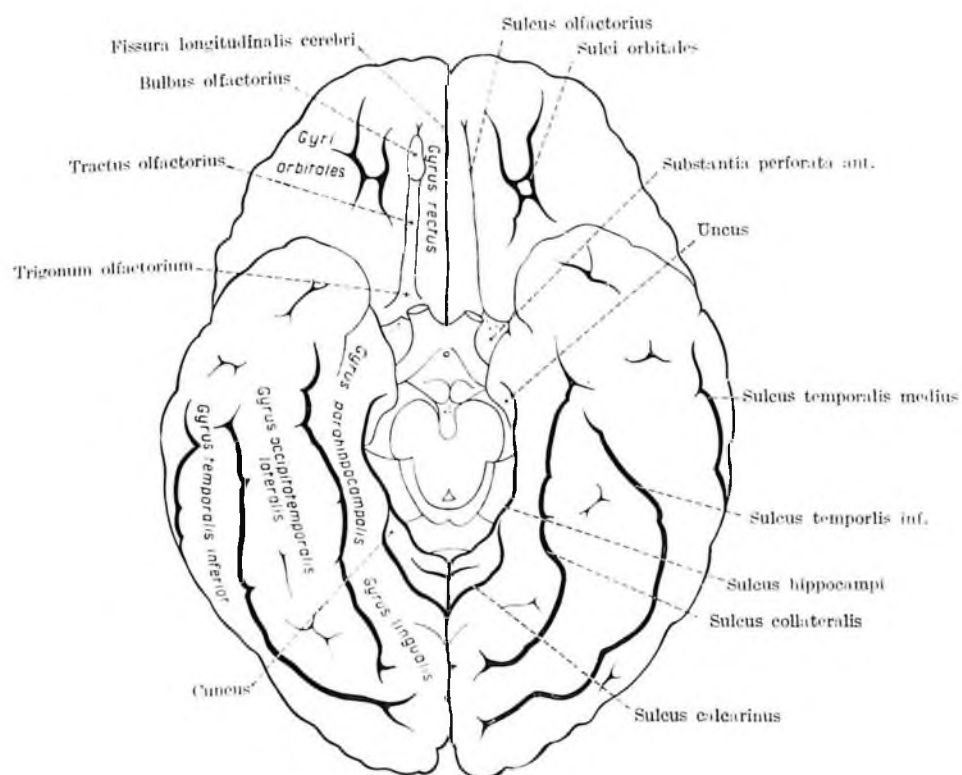


Fig. 9. SULCI ET GYRI CEREBRI IV.
(facies inferiores hemispheriorum)

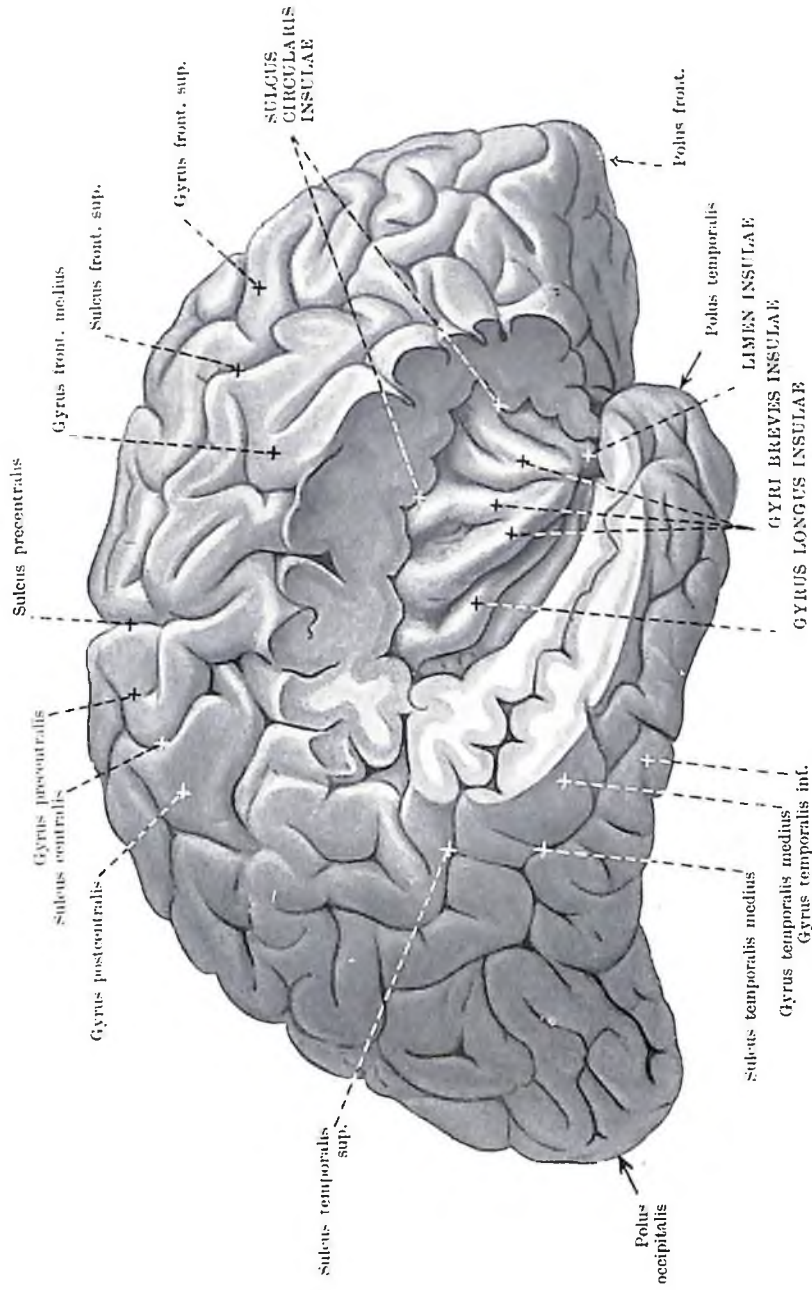


Fig. 11. INSULA
(operetia frontoparietale et temporale ablata)

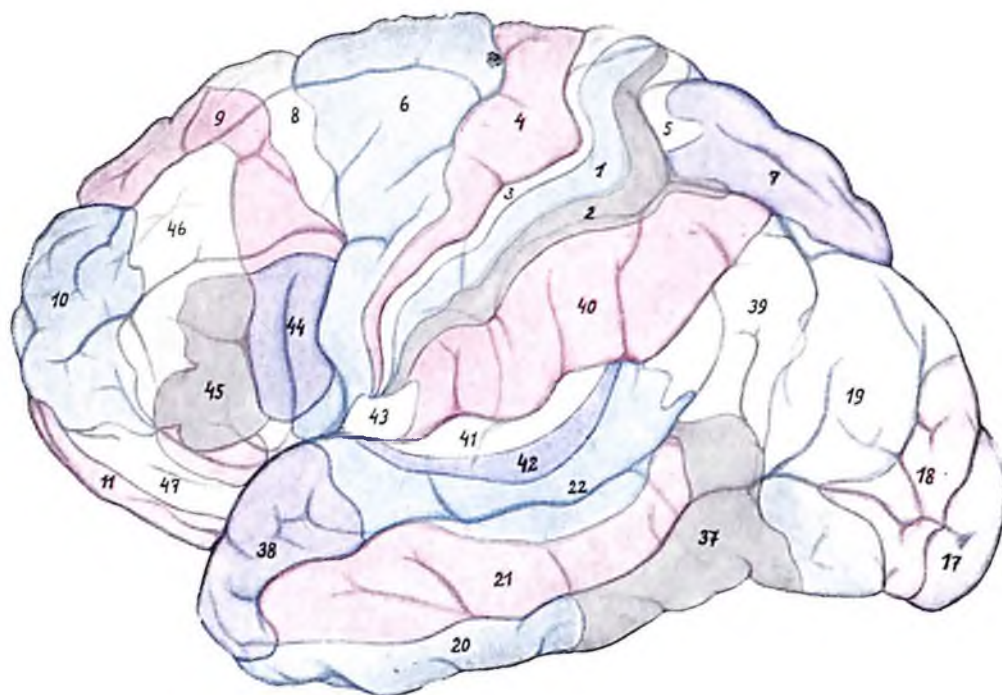


Fig. 12. AREAE CORTICIS CEREBRI I.
(areae cytoarchitectonicae secundum Brodmann, facies supero-lateralis cerebri, hemispherium sin.)

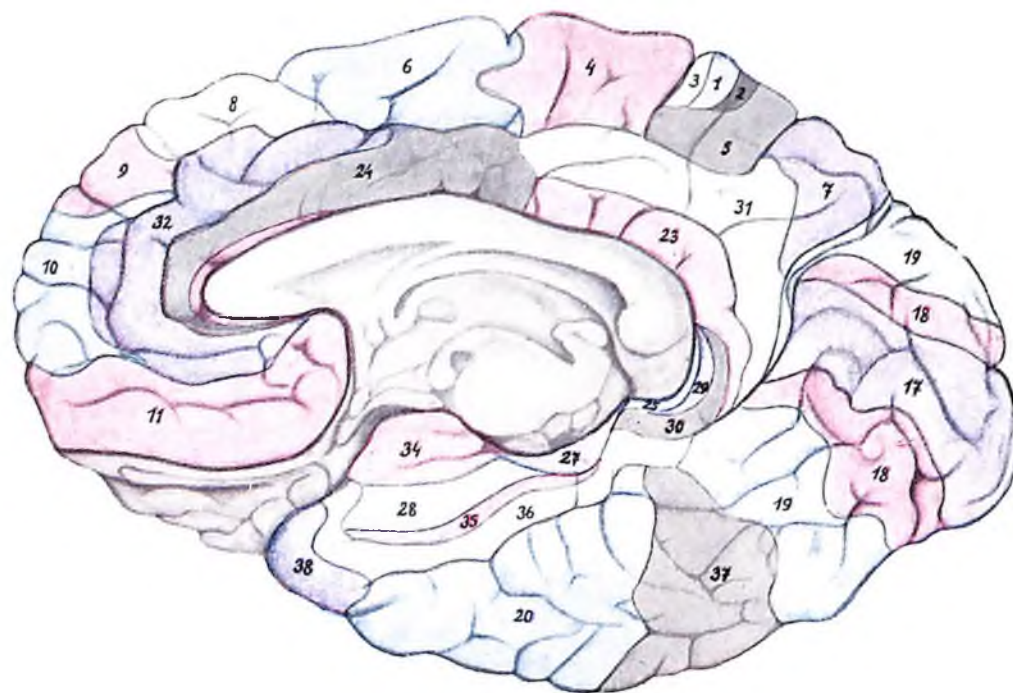


Fig. 13. AREAE CORTICIS CEREBRI II.
(areae cytoarchitectonicae secundum Brodmann, facies medialis et inferior cerebri, hemispherium dext.)

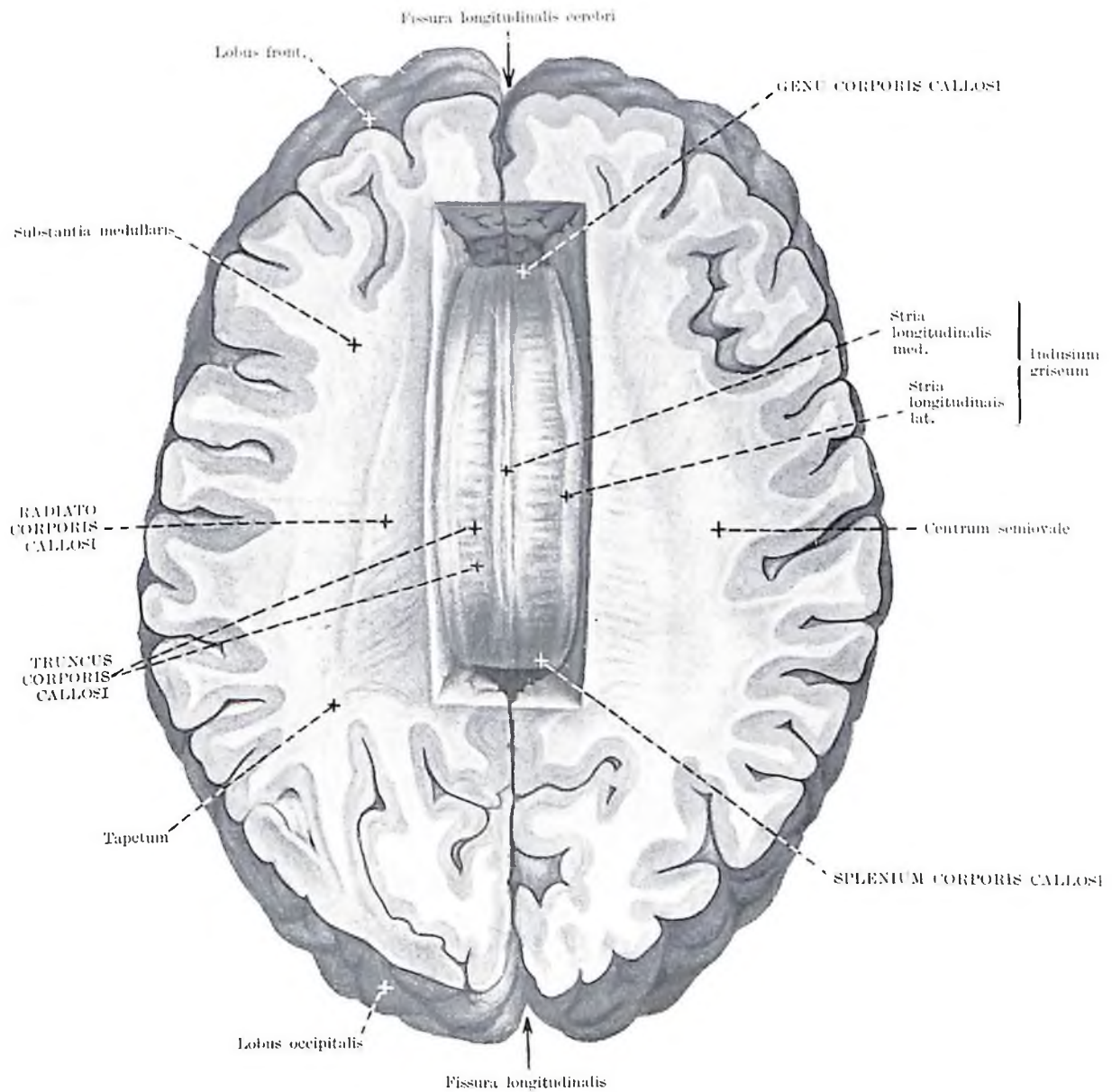


Fig. 14. CORPUS CALLOSUM
(sectio horizontalis cerebri, aspectus superior)

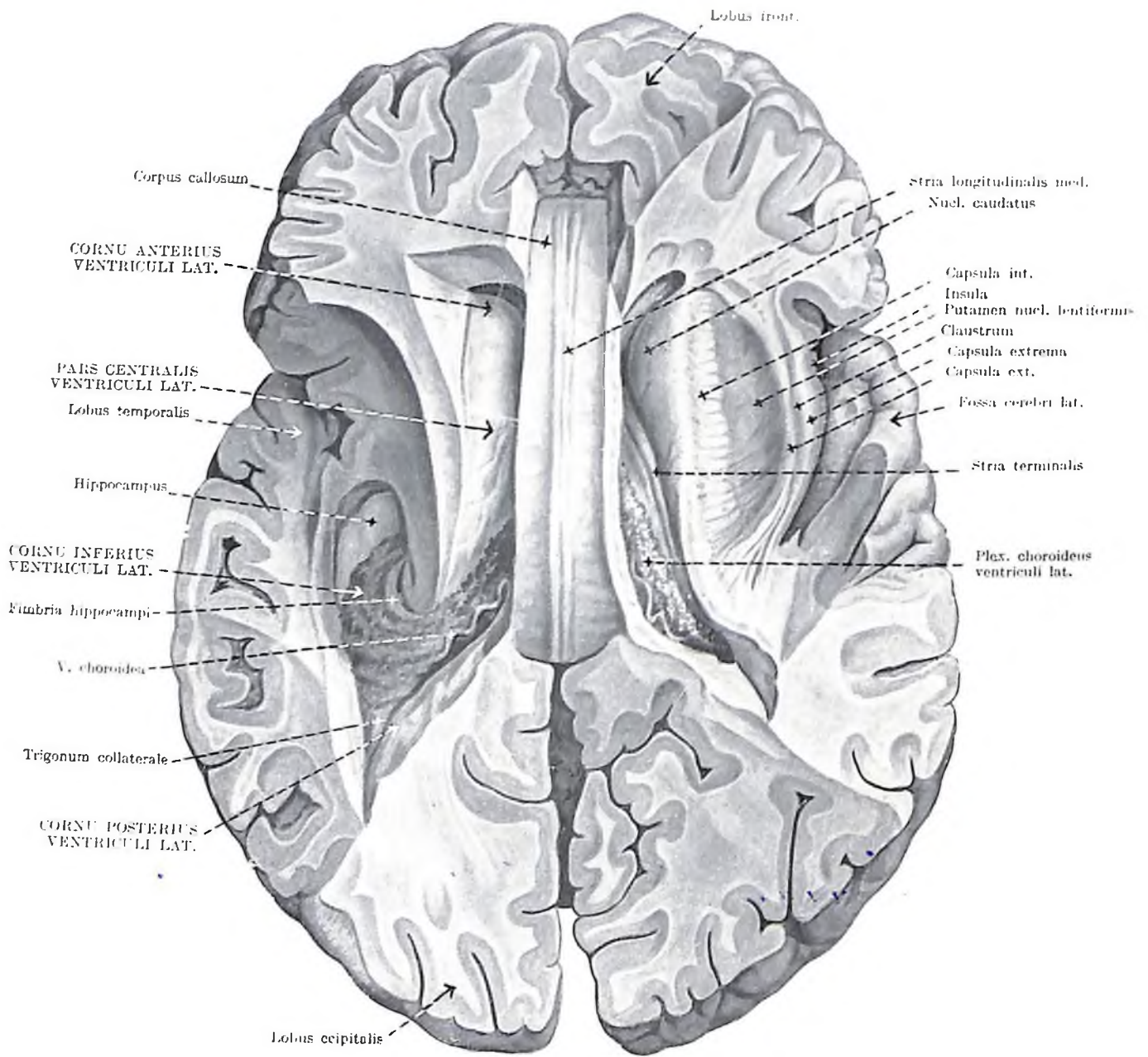
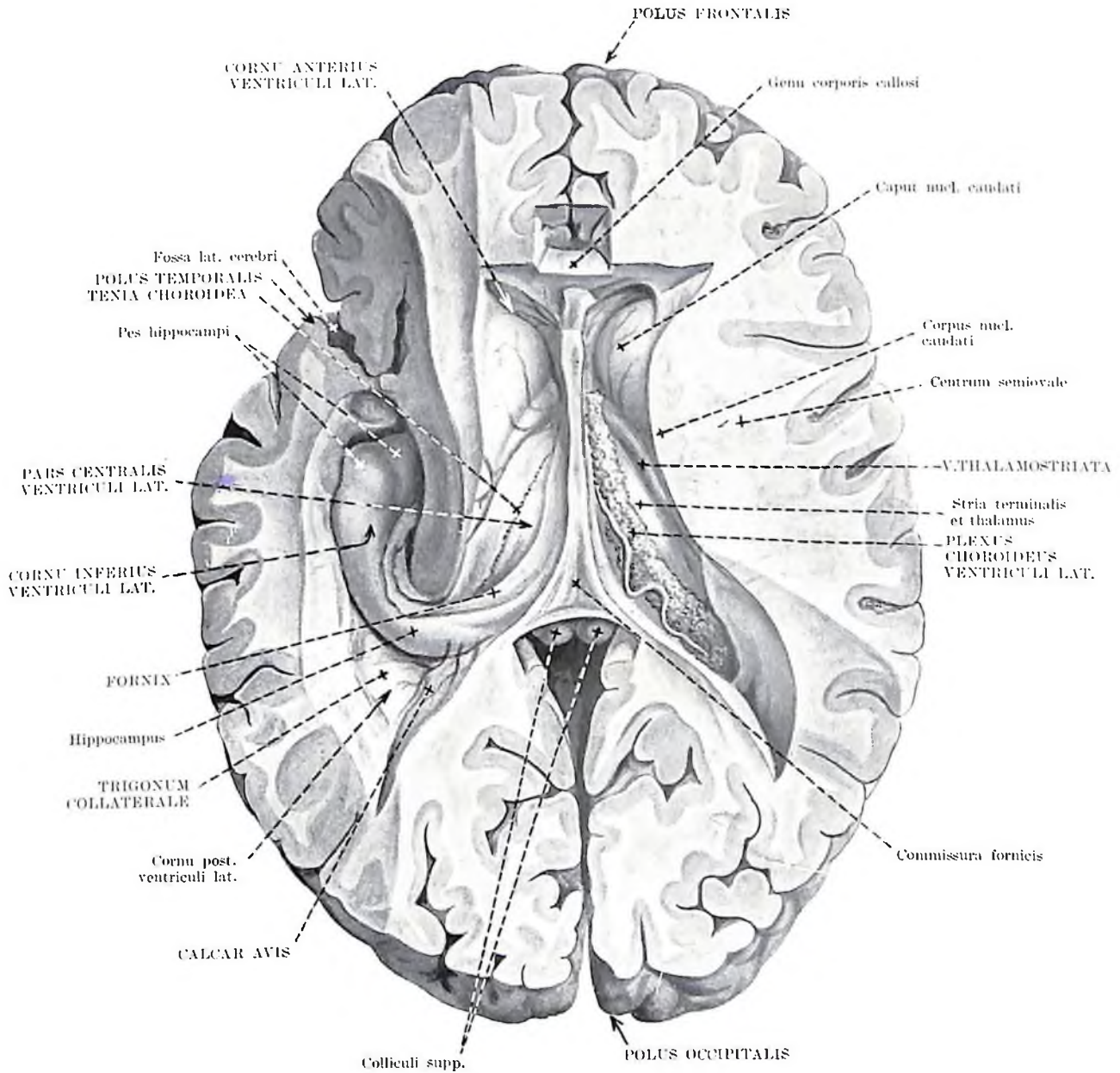


Fig. 15. VENTRICULI LATERALES I.
(aspectus superior)



БИБЛИОТЕКА
 № 15295
 Самарского
 Института

Fig. 16. VENTRICULI LATERALES II.
(aspectus superior, corpus callosum ablatum)

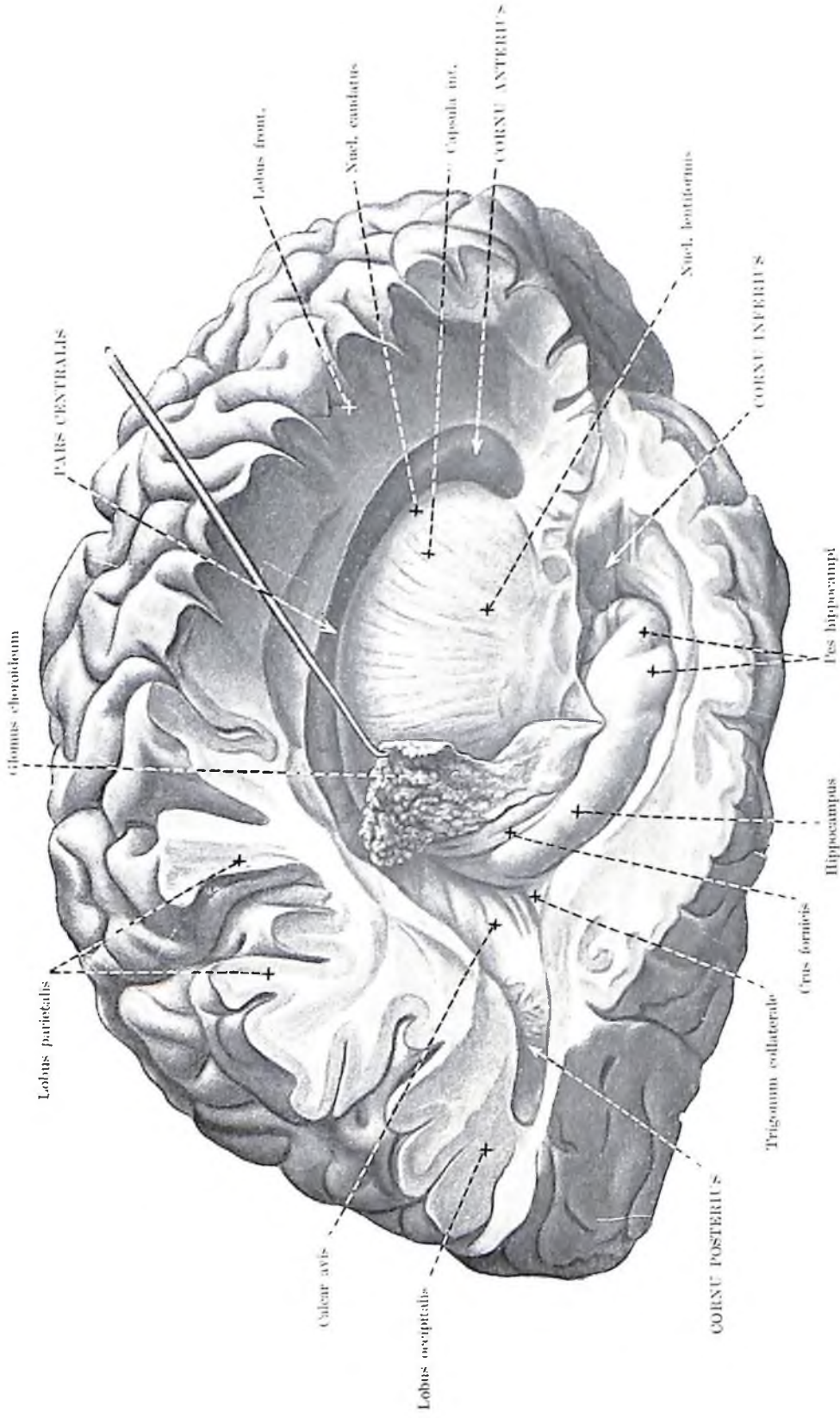
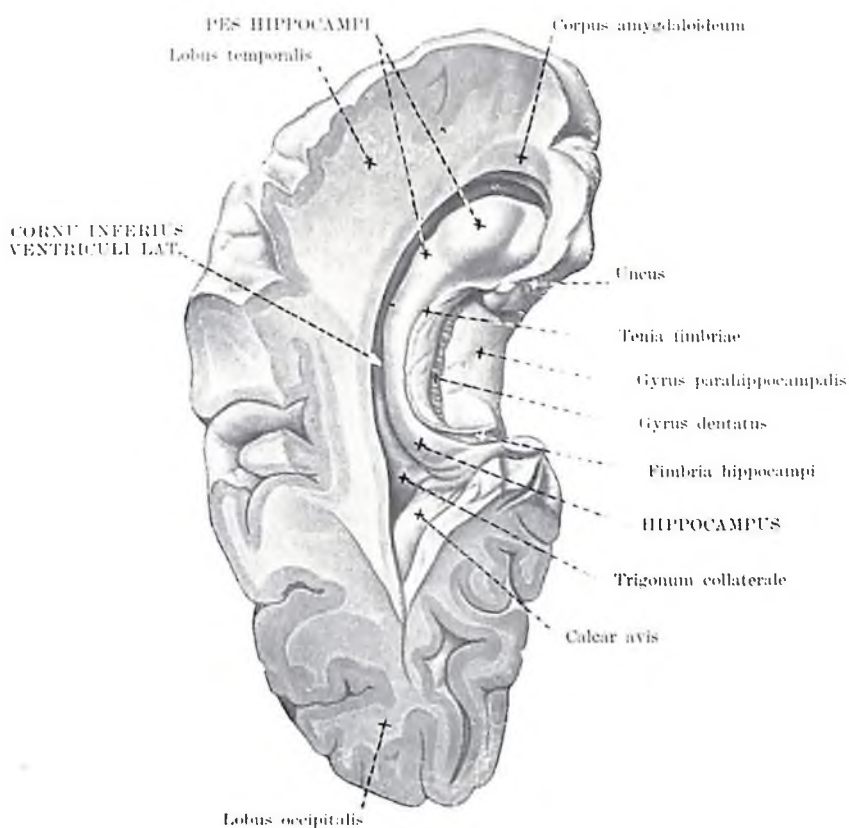
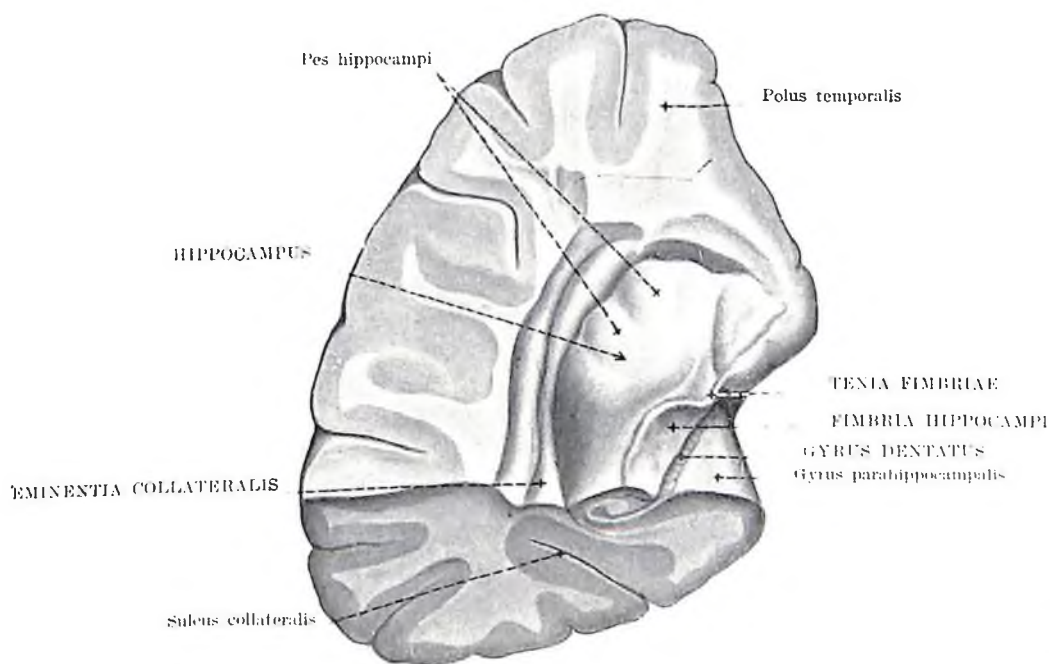


Fig. 17. VENTRICULUS LATERALIS III.
(aspectus lateralis, l. dext.)



3/4

Fig. 18. CORNUS INFERIUS VENTRICULI LATERALIS I.
(aspectus superior, 1. sin.)



4/3

Fig. 19. CORNUS INFERIUS VENTRICULI LATERALIS II.
(apex cornus inferioris)

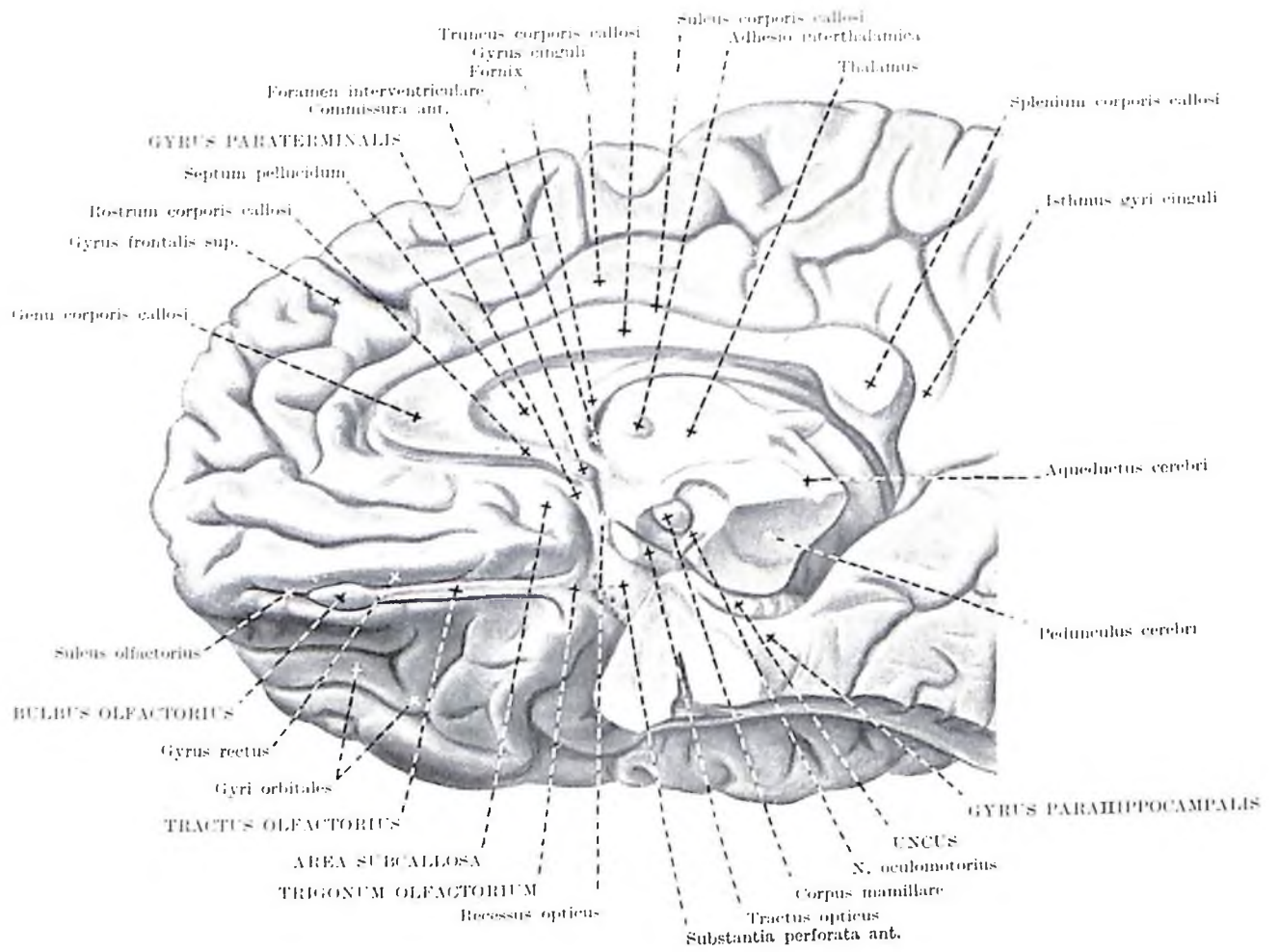
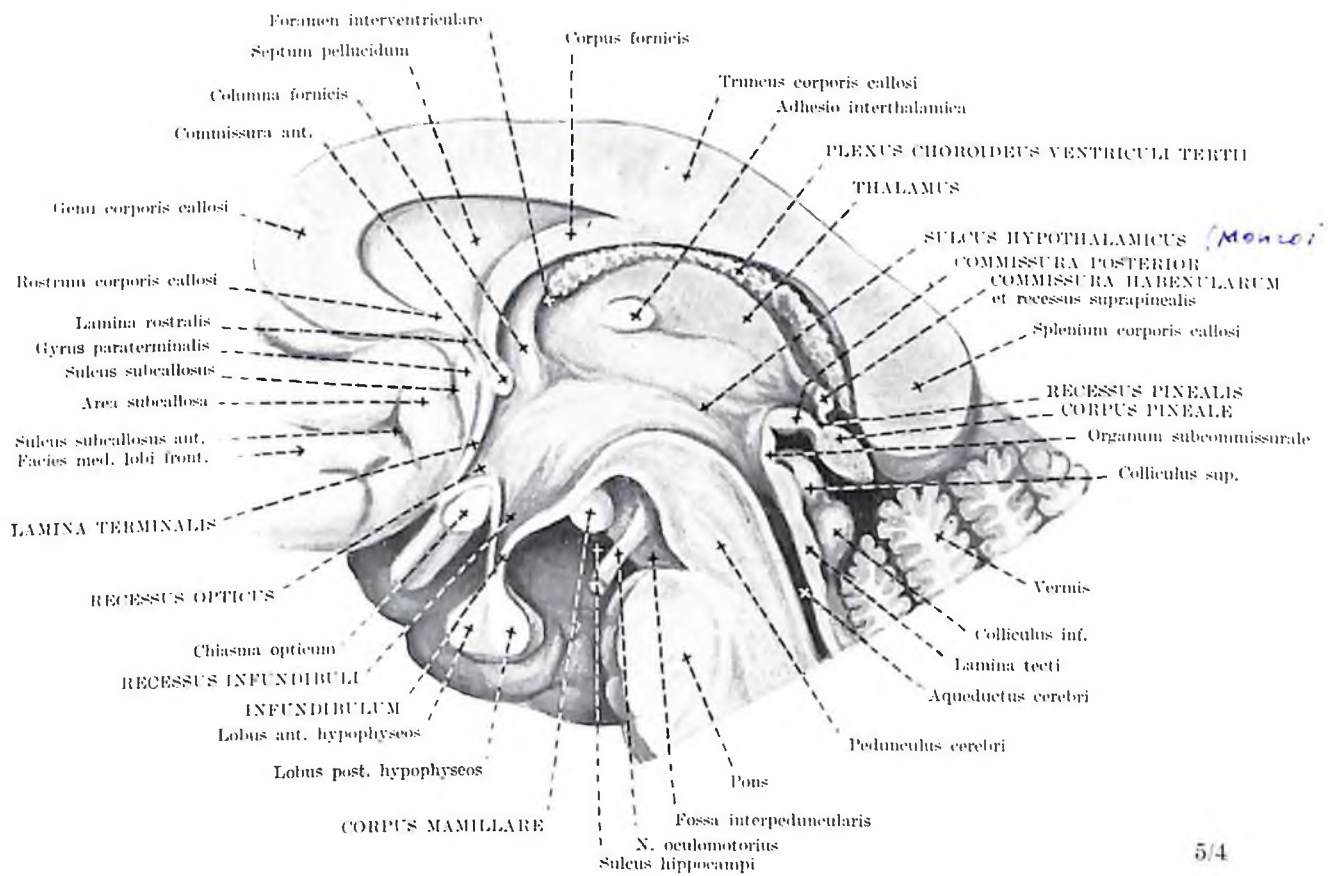
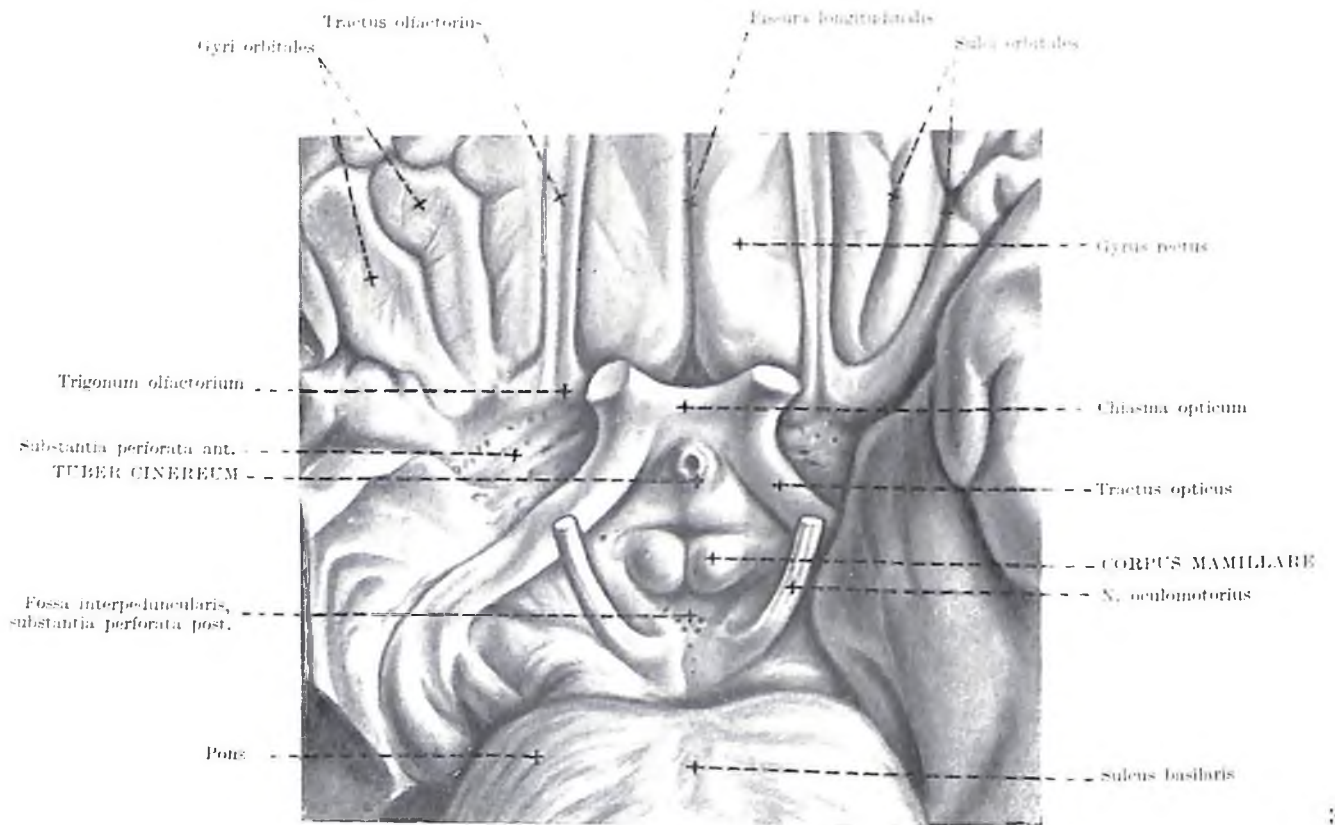


Fig. 20. RHINENCEPHALON
(aspectus infero-medialis, l. dext.)



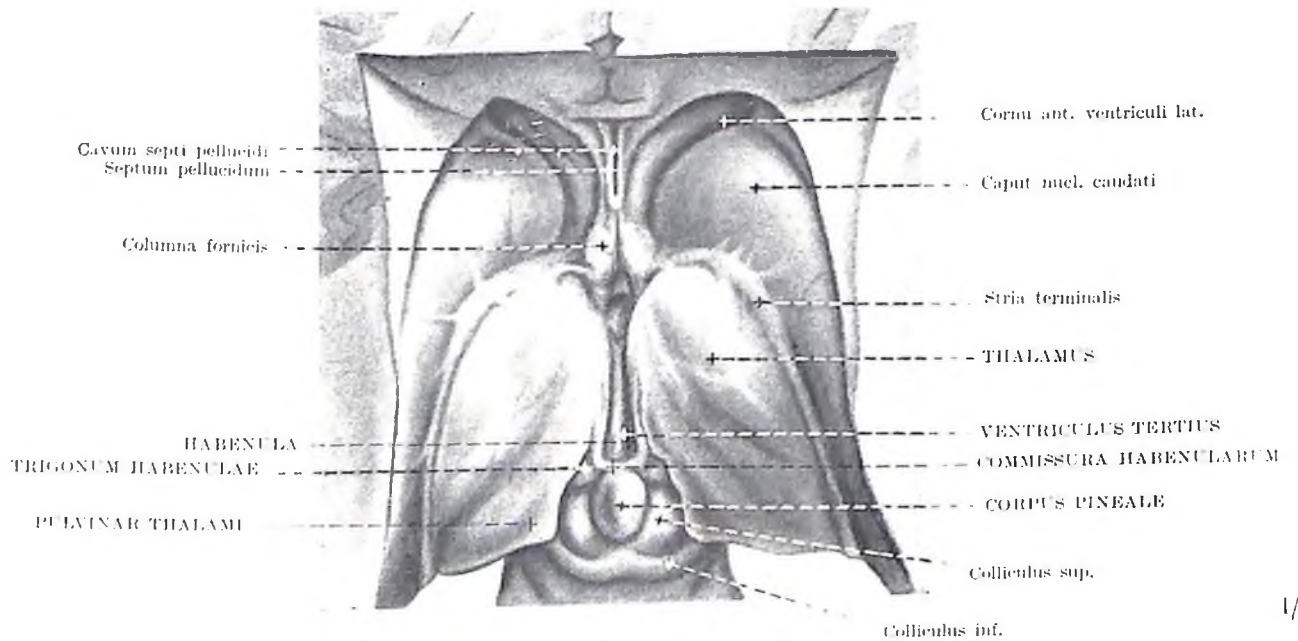
5/4

Fig. 21. DIENCEPHALON
 (ventriculus tertius, thalamus et hypothalamus, sectio sagittalis, l. dext.)



3/2

Fig. 22. CENTRUM BASEOS ENCEPHALI
(diencephalon, hypothalamus, aspectus inferior)



1/1

Fig. 23. VENTRICULUS TERTIUS ET THALAMUS
(thalamencephalon, epithalamus, aspectus superior)

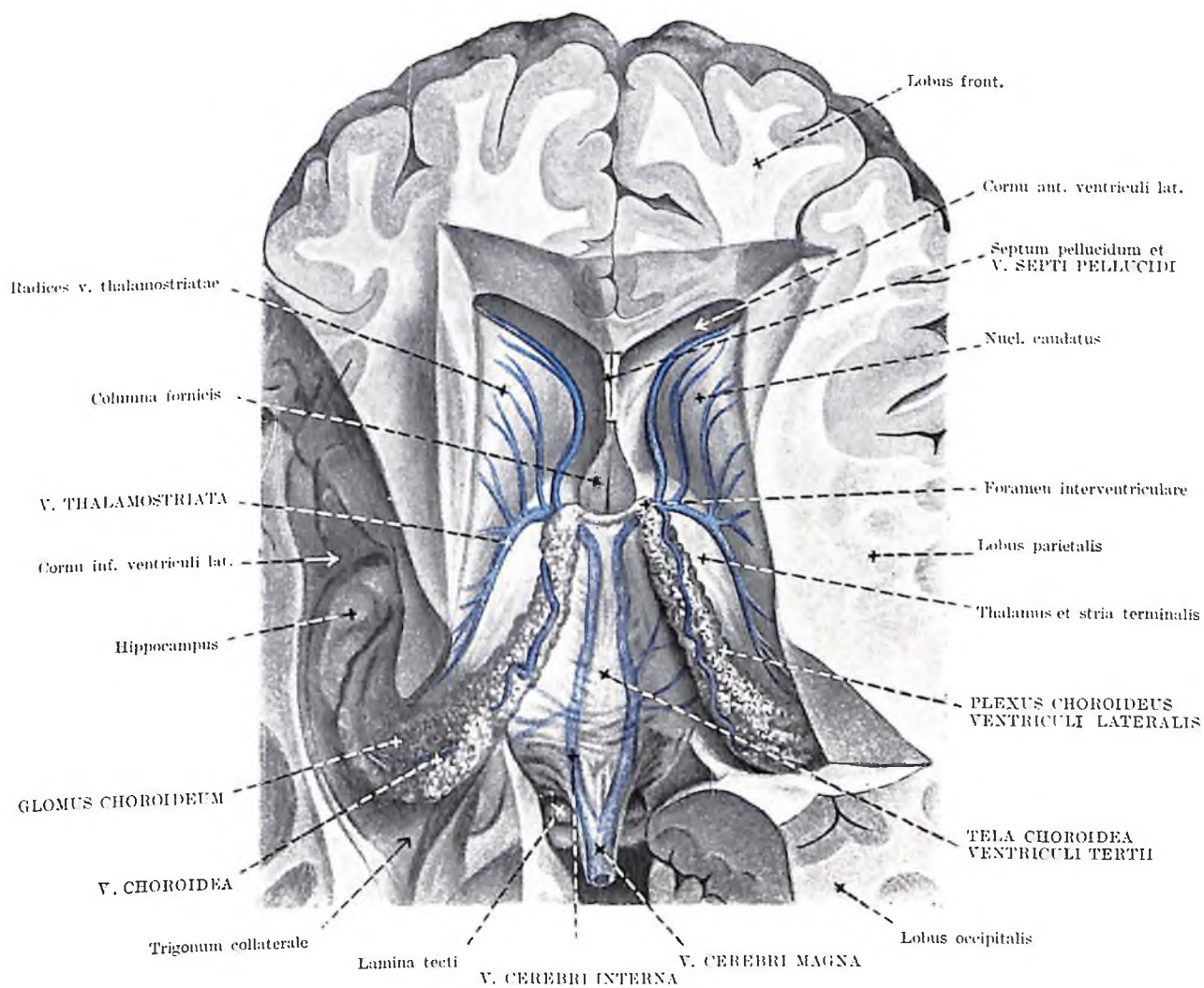


Fig. 24. TELA CHOROIDEA VENTRICULI TERTII
(venae internae cerebri, aspectus superior)

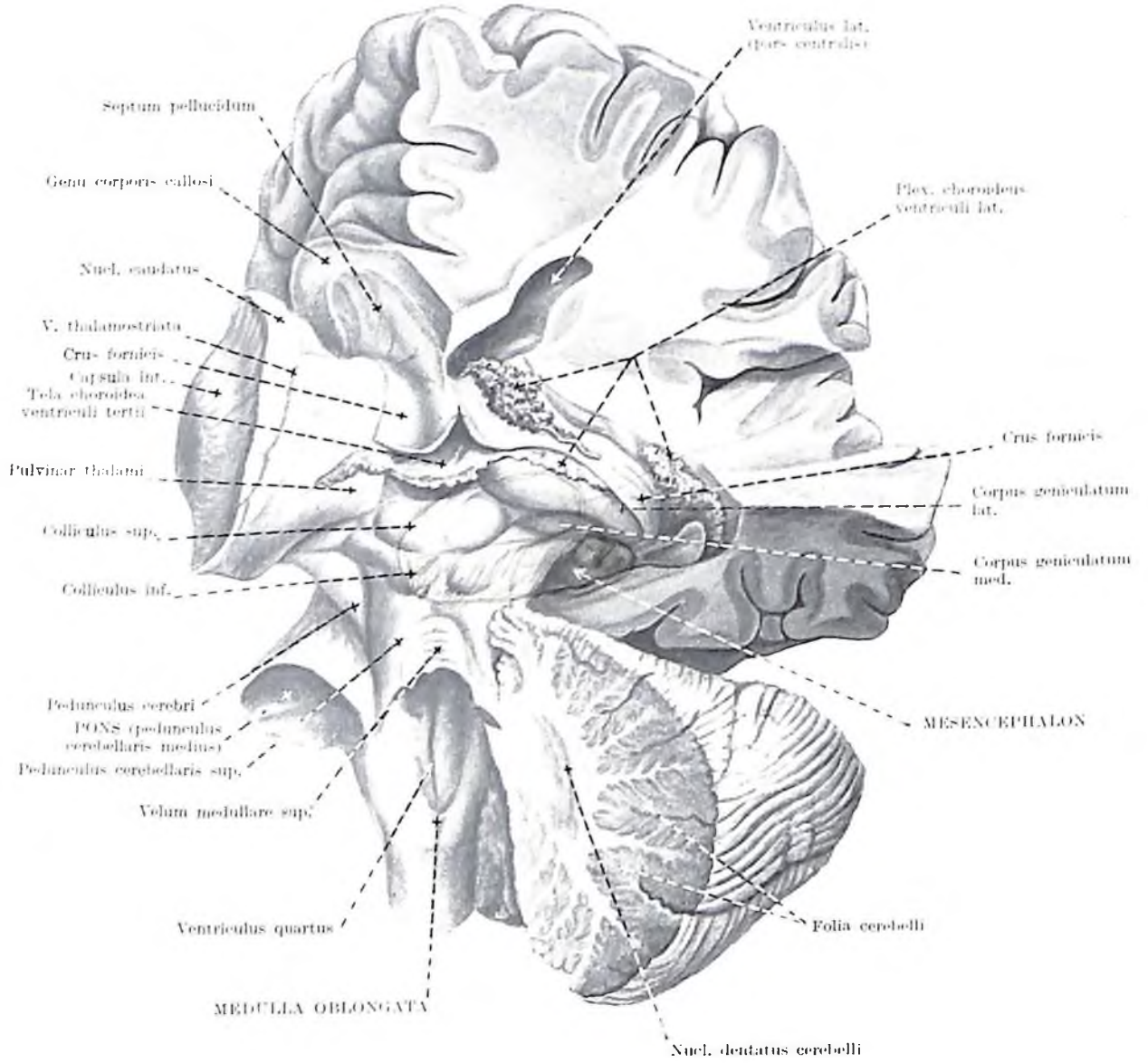


Fig. 25. TRUNCUS CEREBRI I.
(aspectus posterior)

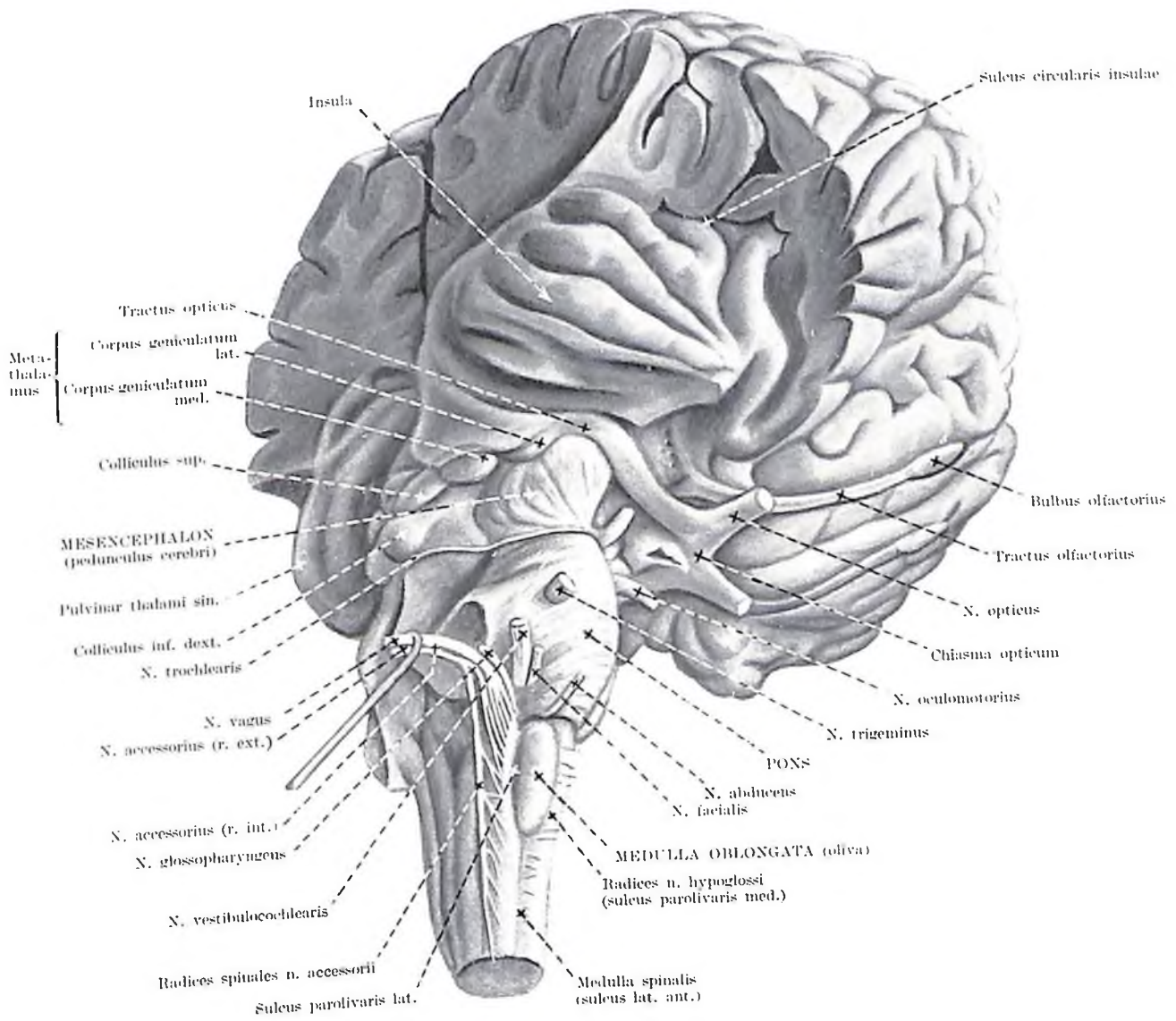


Fig. 26. TRUNCUS CEREBRI II.
(aspectus infero-lateralis dexter)

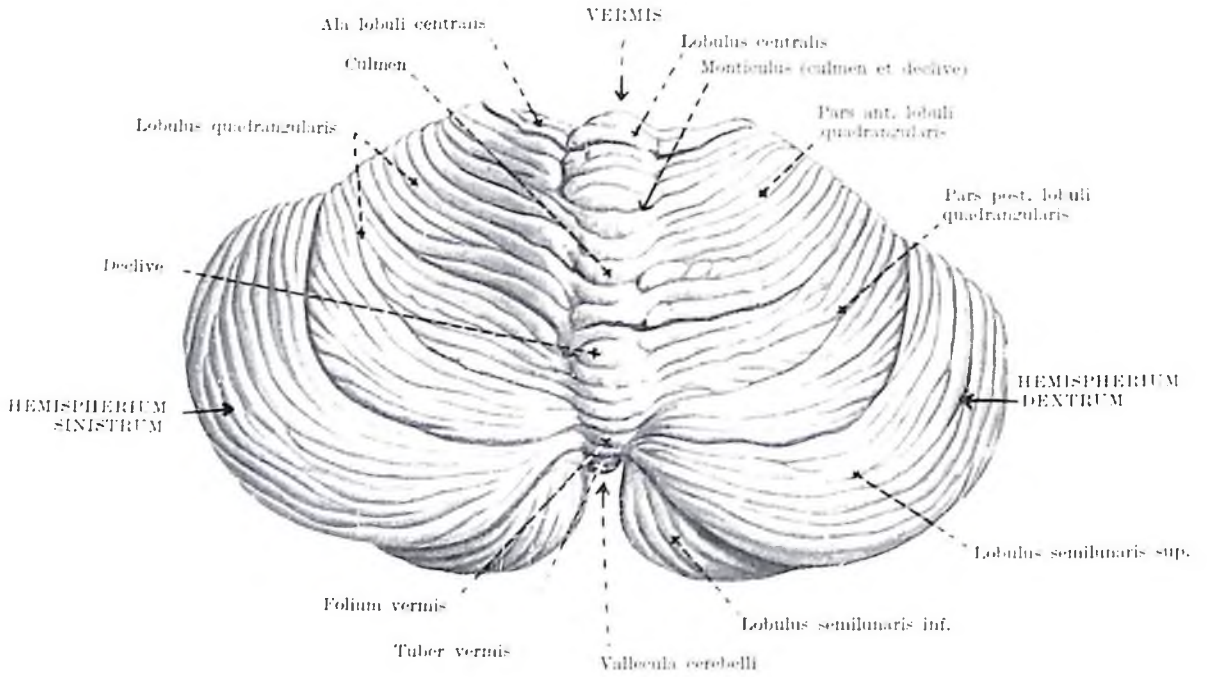


Fig. 27. CEREBELLUM I.
(vermis et facies superiores hemispheriorum, aspectus superior)

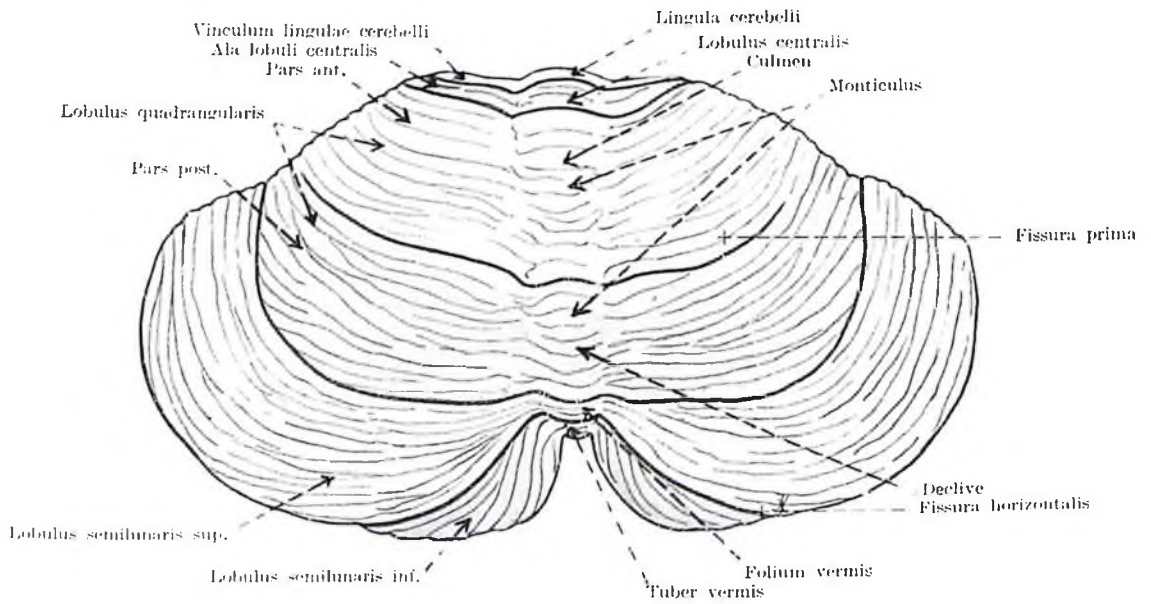


Fig. 28. CEREBELLUM II.
(vermis et lobuli, aspectus superior)

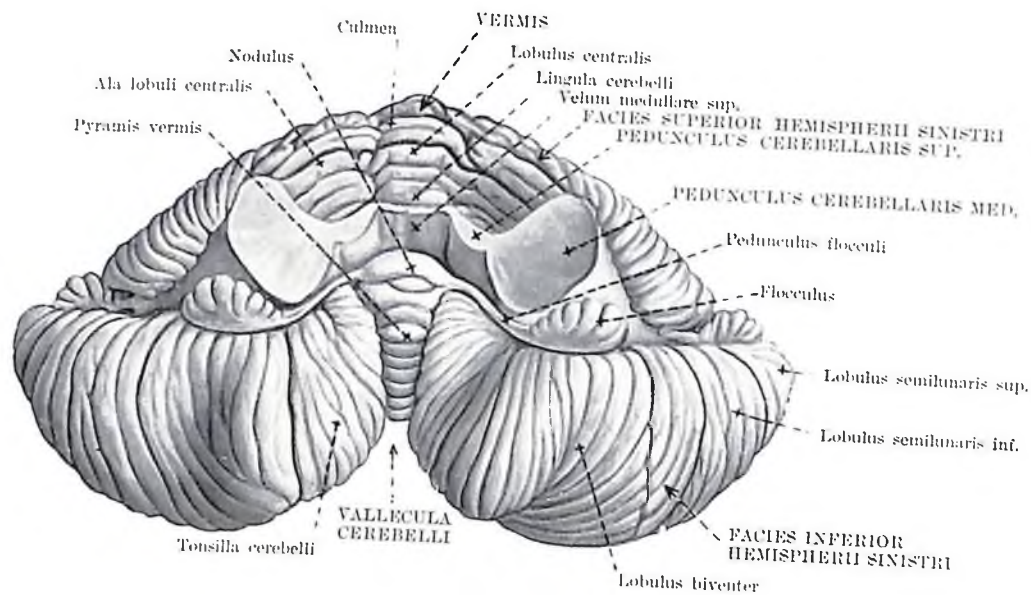


Fig. 29. CEREBELLUM III.
(vermis et hemispherii, aspectus anterior)

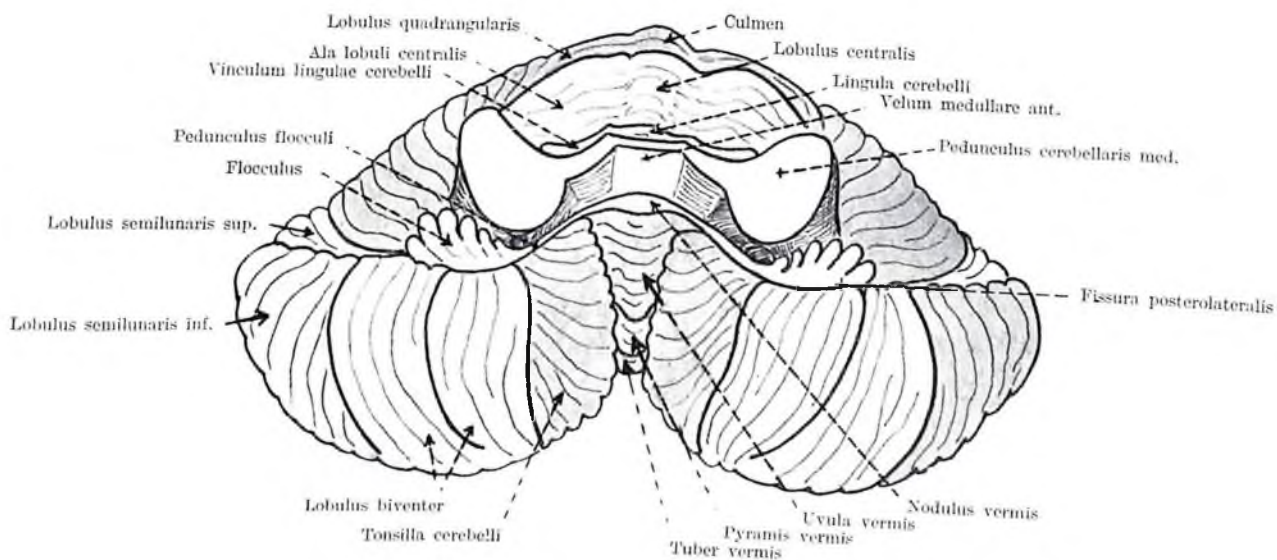


Fig. 30. CEREBELLUM IV.
(vermis et lobuli, aspectus anterior)

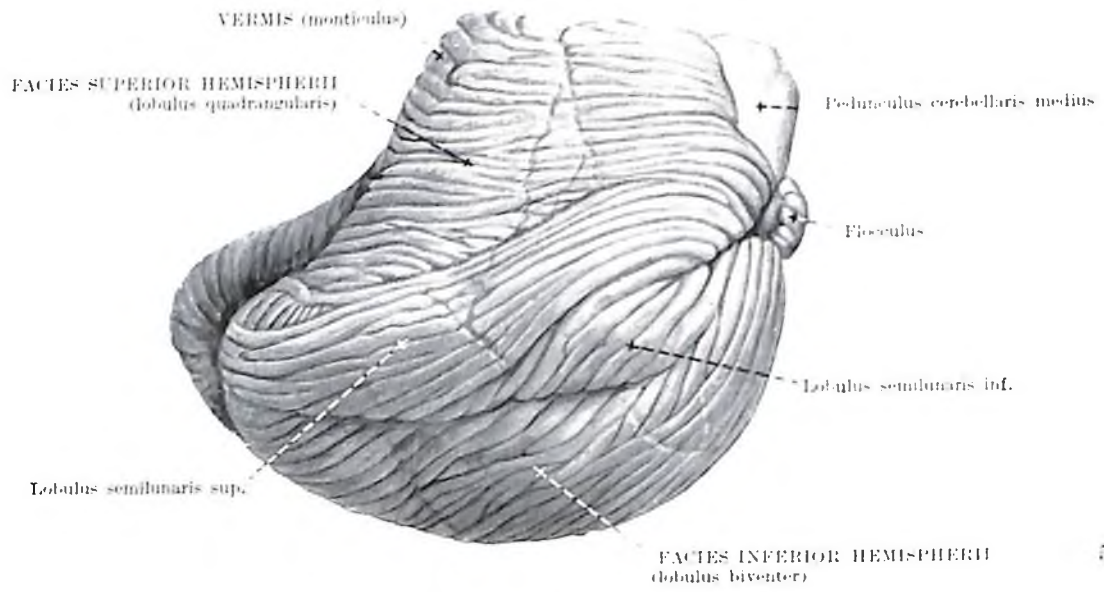


Fig. 31. CEREBELLUM V.
(aspectus dexter)

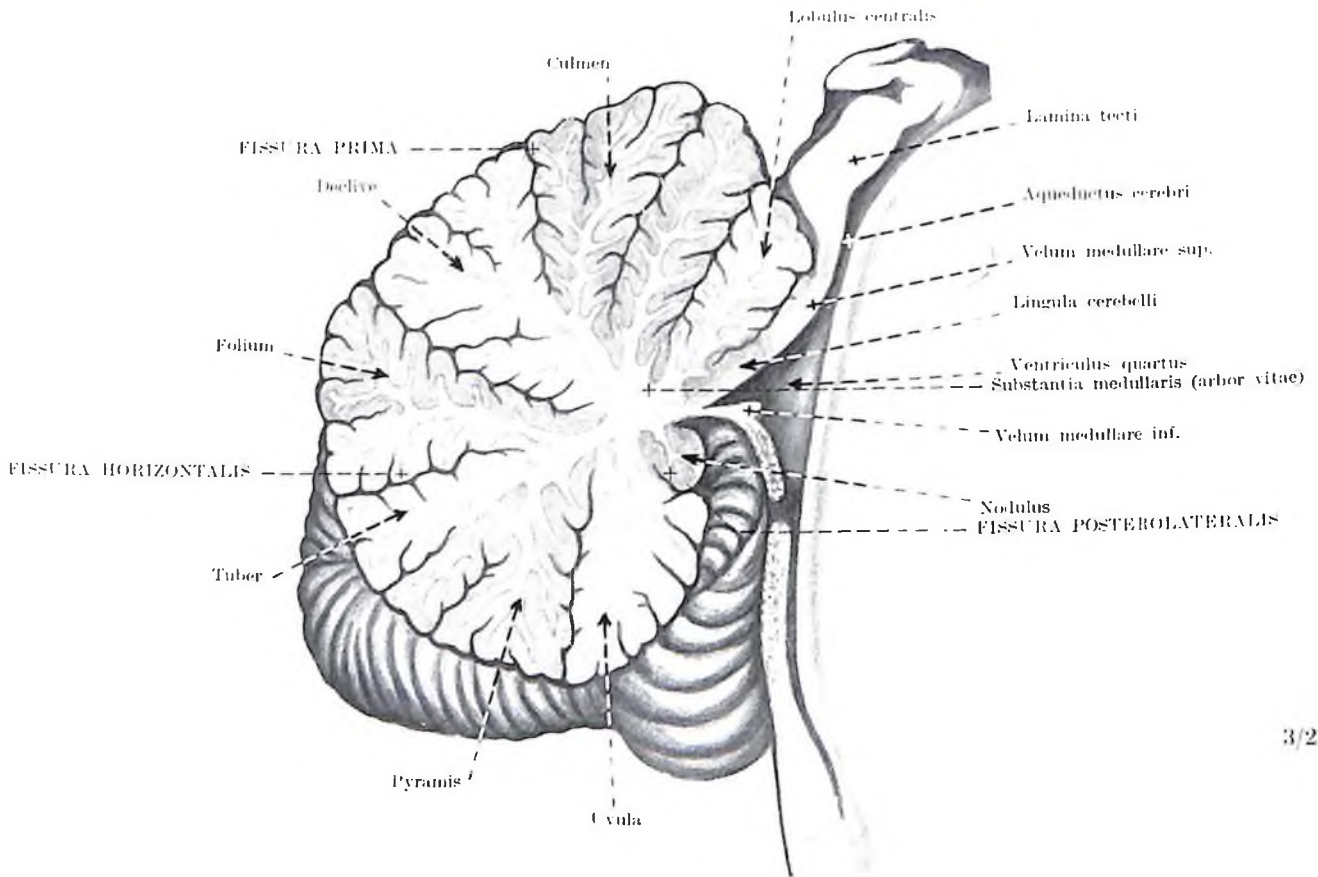
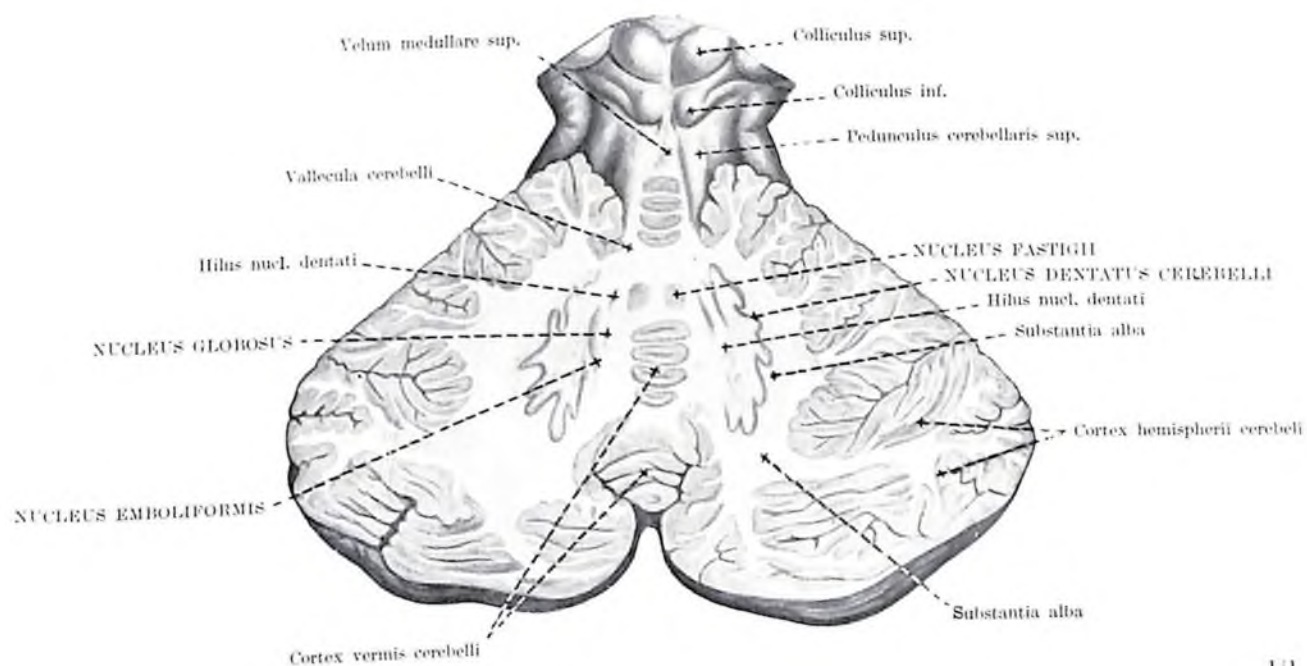
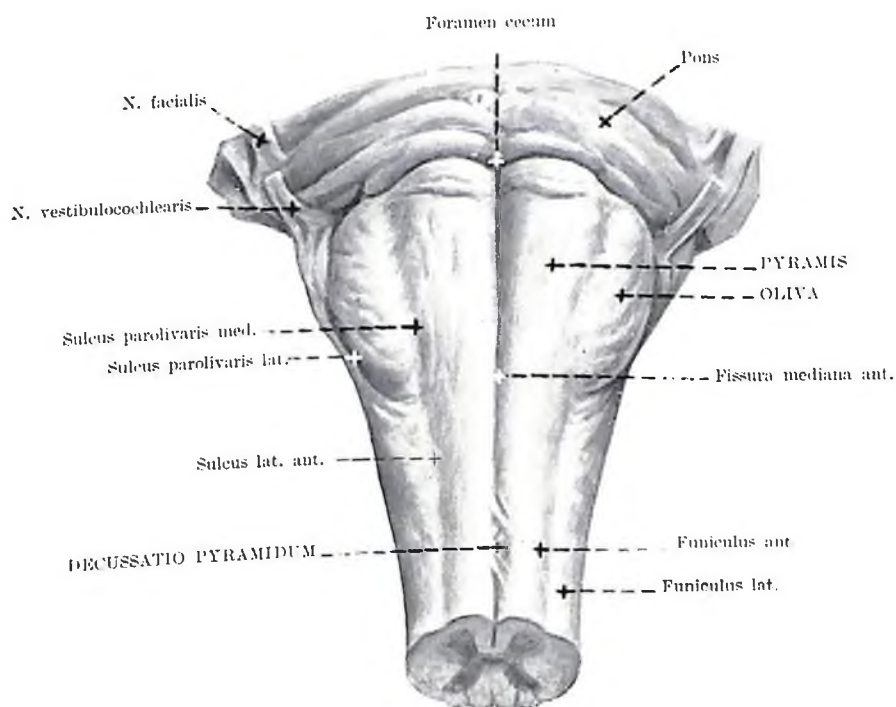


Fig. 32. CEREBELLUM VI.
(vermis, sectio mediana)



1/1

Fig. 33. CEREBELLUM VII.
(nuclei cerebelli, sectio transversalis obliqua, aspectus superior)



2/1

Fig. 34. MYELENCEPHALON
(medulla oblongata, aspectus anterior)

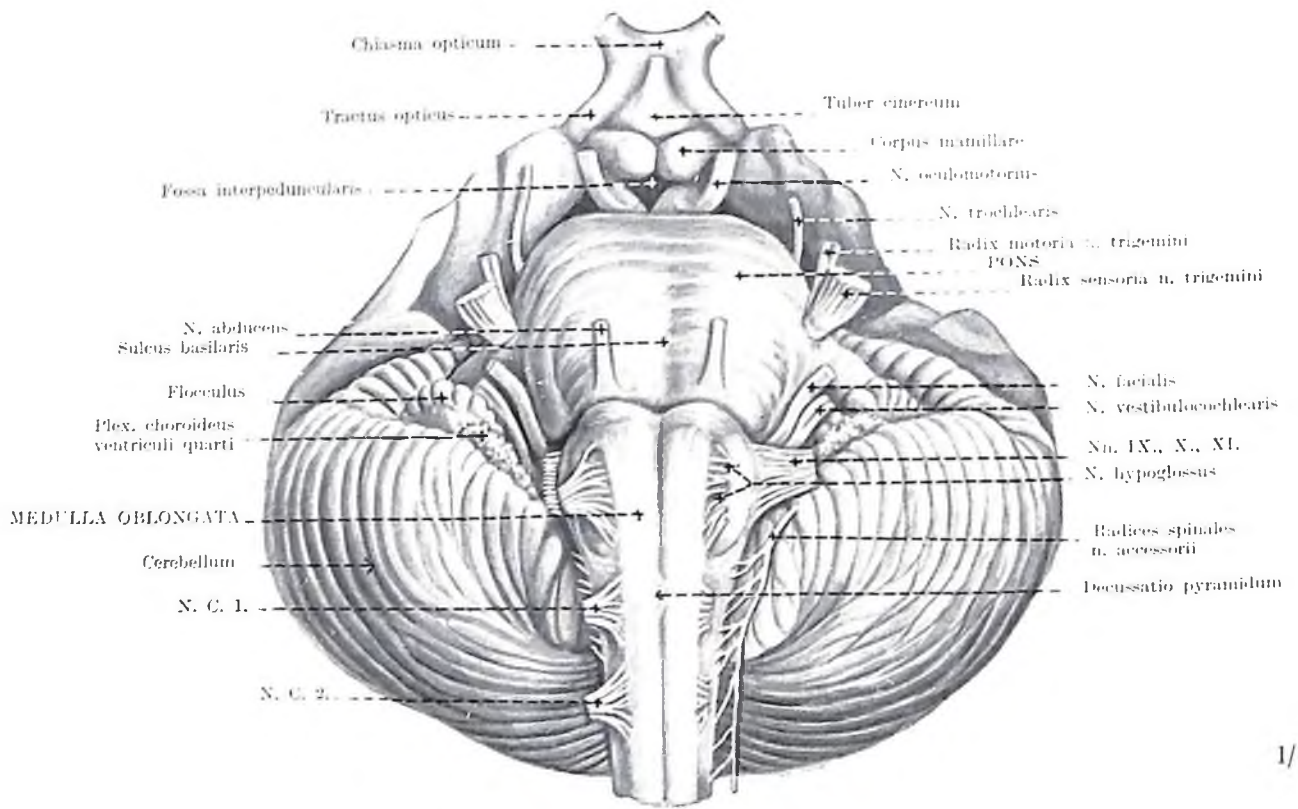
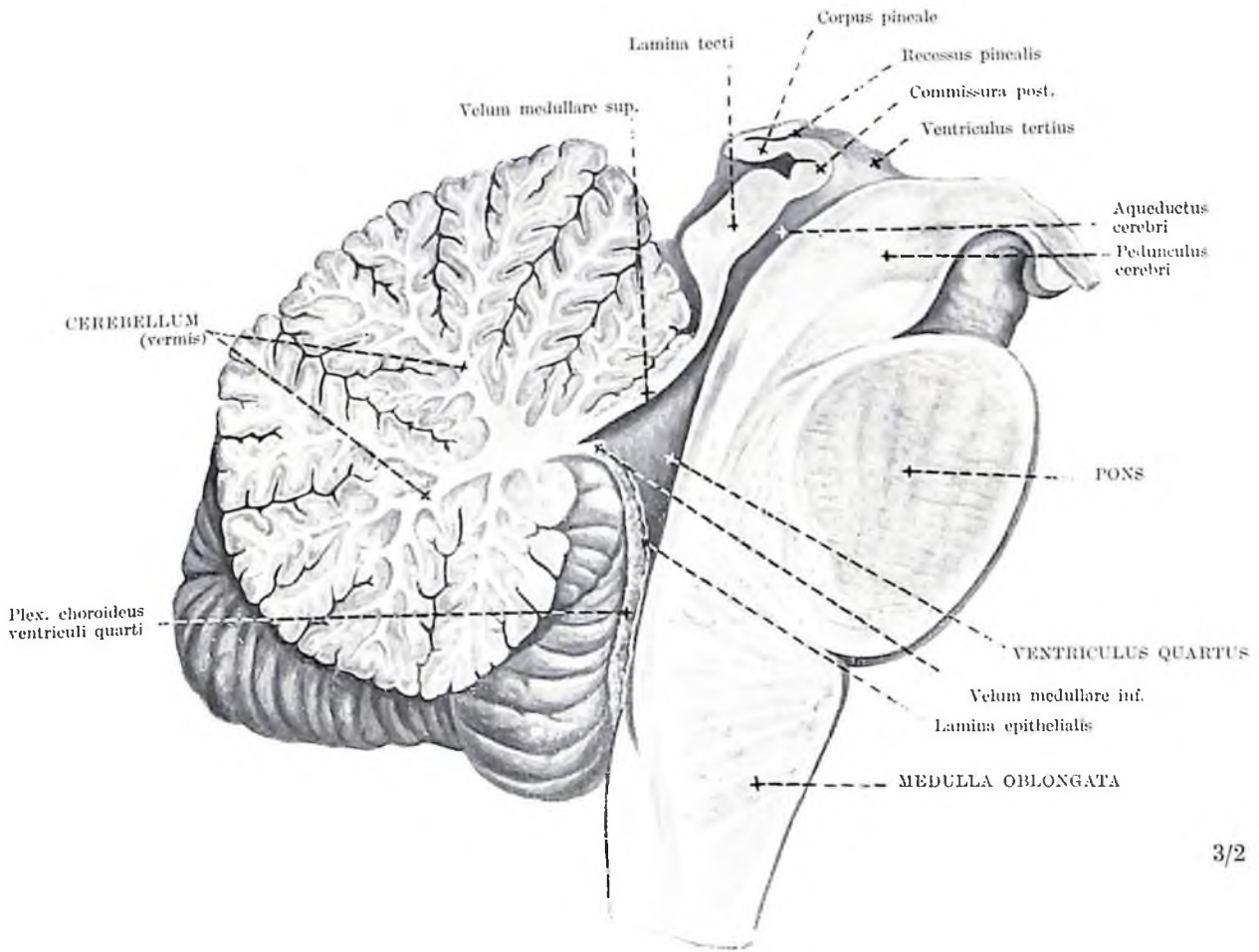


Fig. 35. RHOMBENCEPHALON I.
(cerebellum, pons et medulla oblongata, aspectus antero-inferior)



3/2

Fig. 36. RHOMBENCEPHALON II.
(mesencephalon, metencephalon et myelencephalon, sectio sagittalis mediana, aspectus dexter)

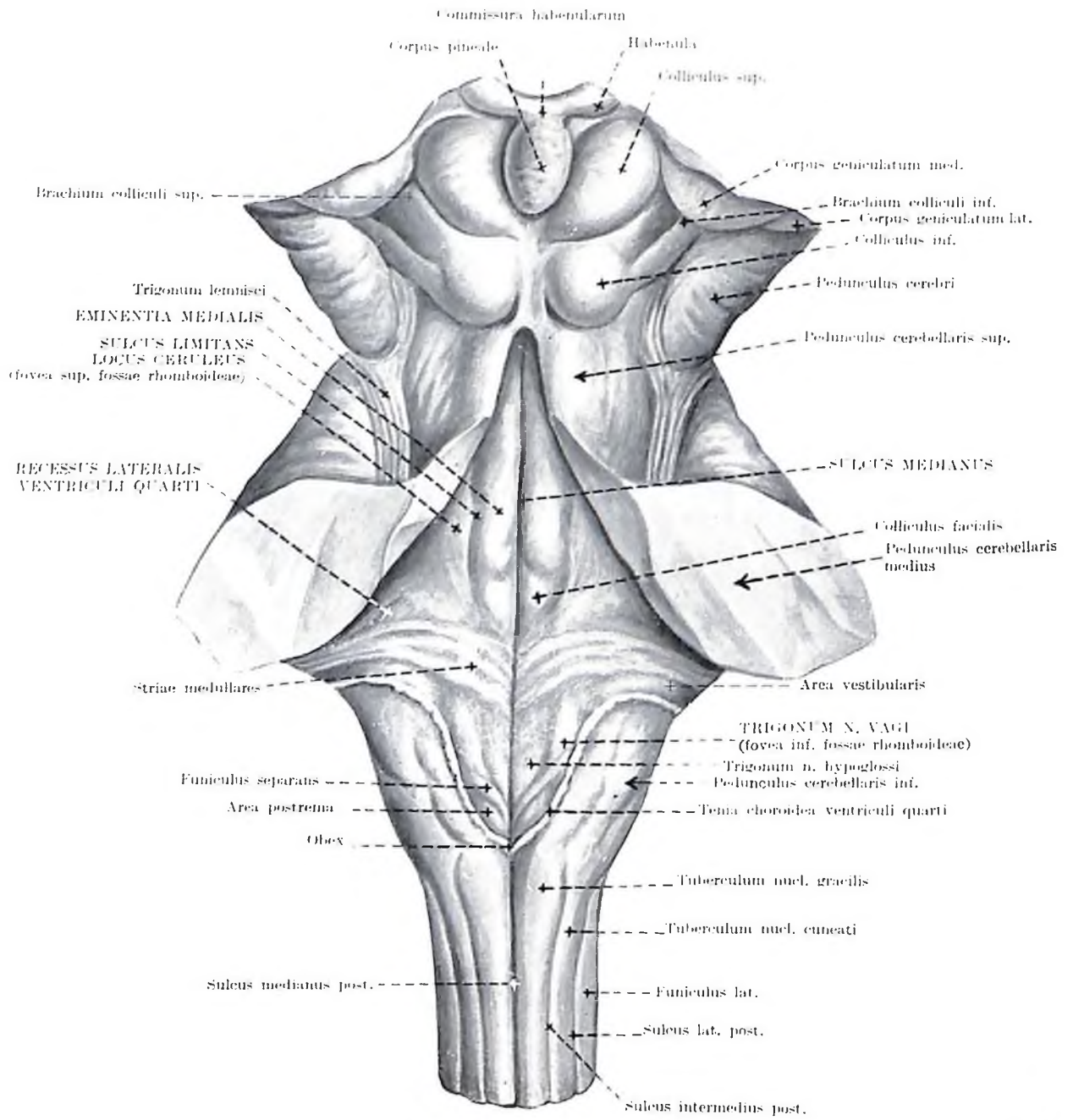


Fig. 37. RHOMBENCEPHALON III.
 (ventriculus quartus, fossa rhomboidea, aspectus posterior)

13

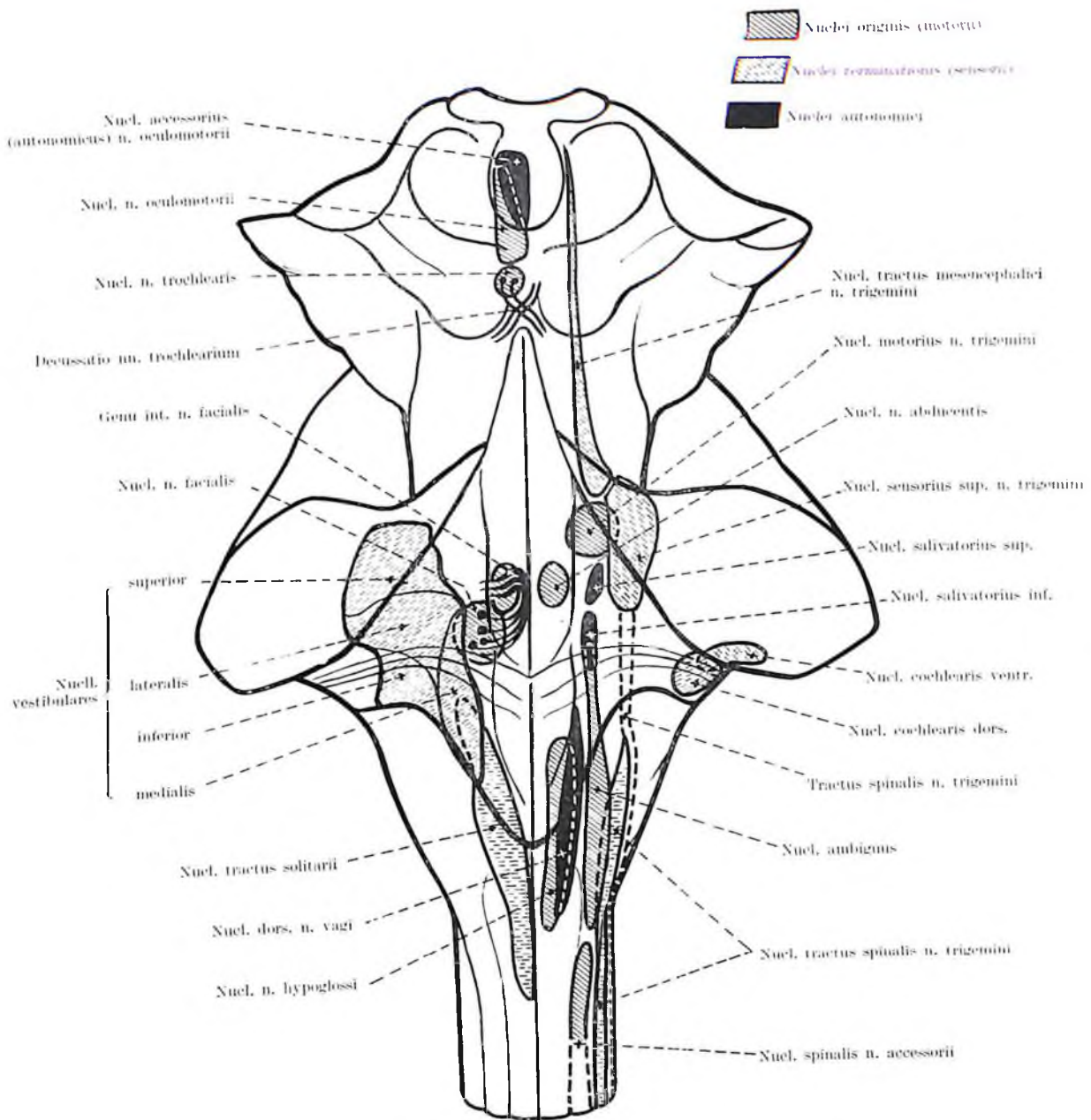
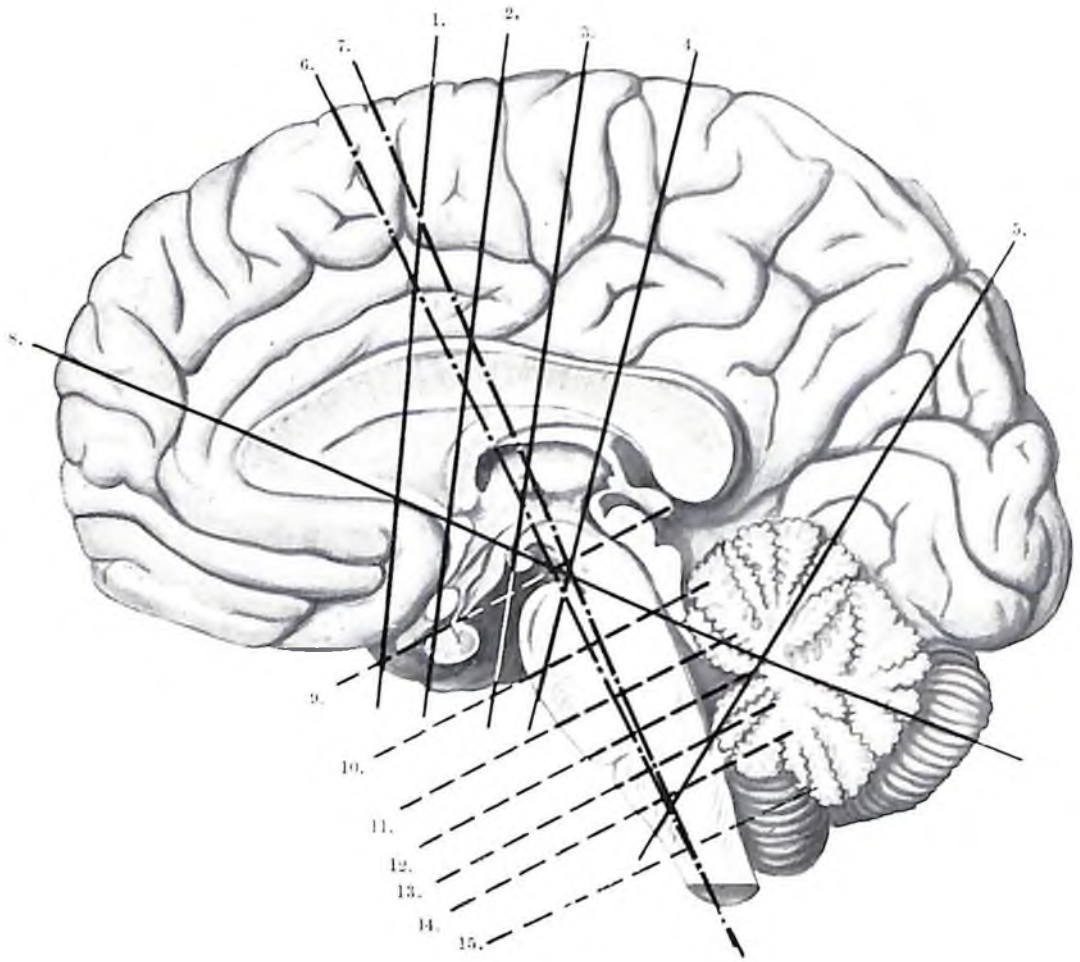


Fig. 38. RHOMBENCEPHALON IV.
(nuclei nervorum cranialium)



1. Sectio frontalis cerebri I. = fig. 40.
2. Sectio frontalis cerebri II. = fig. 41.
3. Sectio frontalis cerebri III. = fig. 42.
4. Sectio frontalis cerebri IV. = fig. 43.
5. Sectio frontalis cerebri V. = fig. 44.
6. Sectio obliqua cerebri I. = fig. 45.
7. Sectio obliqua cerebri II. = fig. 46.
8. Sectio horizontalis cerebri = fig. 48.

9. Sectio transversa mesencephali = fig. 49.
10. Sectio transversa isthmi rhombencephali = fig. 50.
11. Sectio transversa pontis I. = fig. 51.
12. Sectio transversa pontis II. = fig. 52.
13. Sectio transversa medullae oblongatae I. = fig. 53.
14. Sectio transversa medullae oblongatae II. = fig. 54.
15. Sectio transversa medullae oblongatae III. = fig. 55.

Fig. 39. SECTIONES CEREBRI

(sectio sagittalis mediana, aspectus sin., I. dext., ad orientationem figurarum 40–55.)

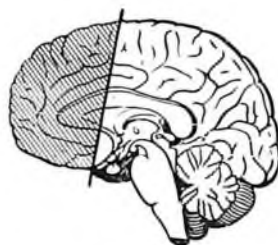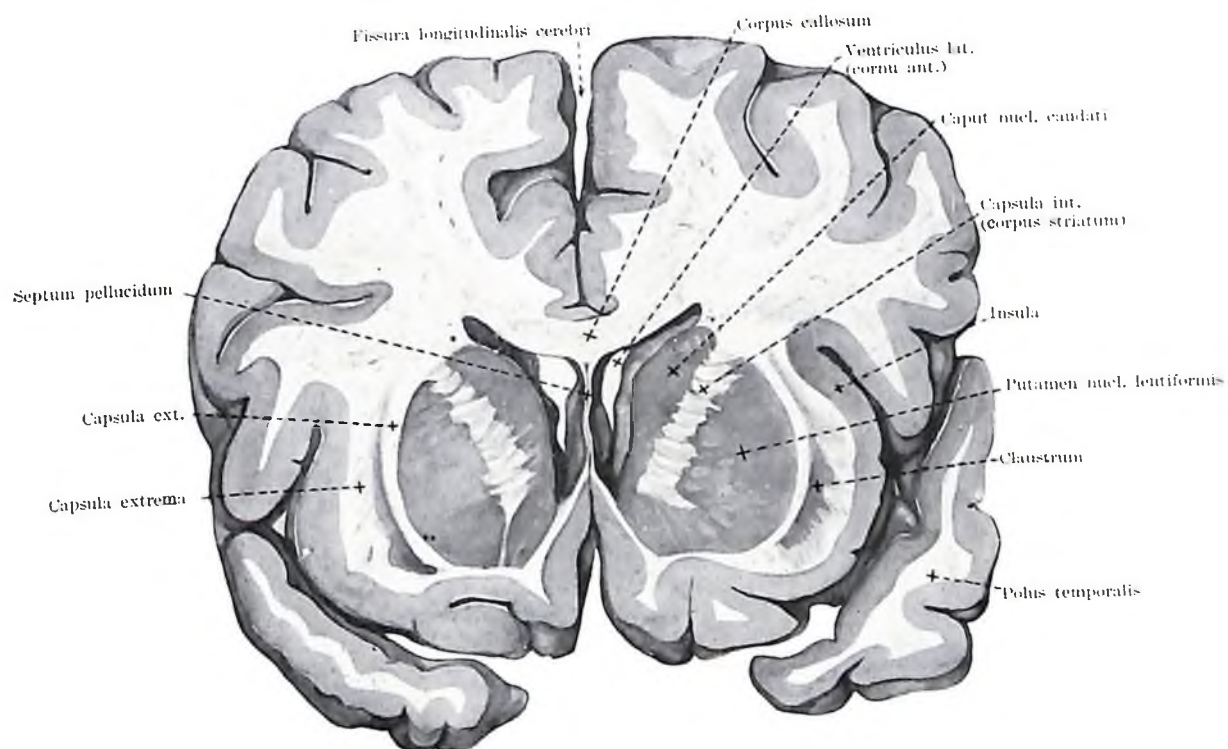


Fig. 40. SECTIO FRONTALIS CEREBRI I.
(aspectus anterior)

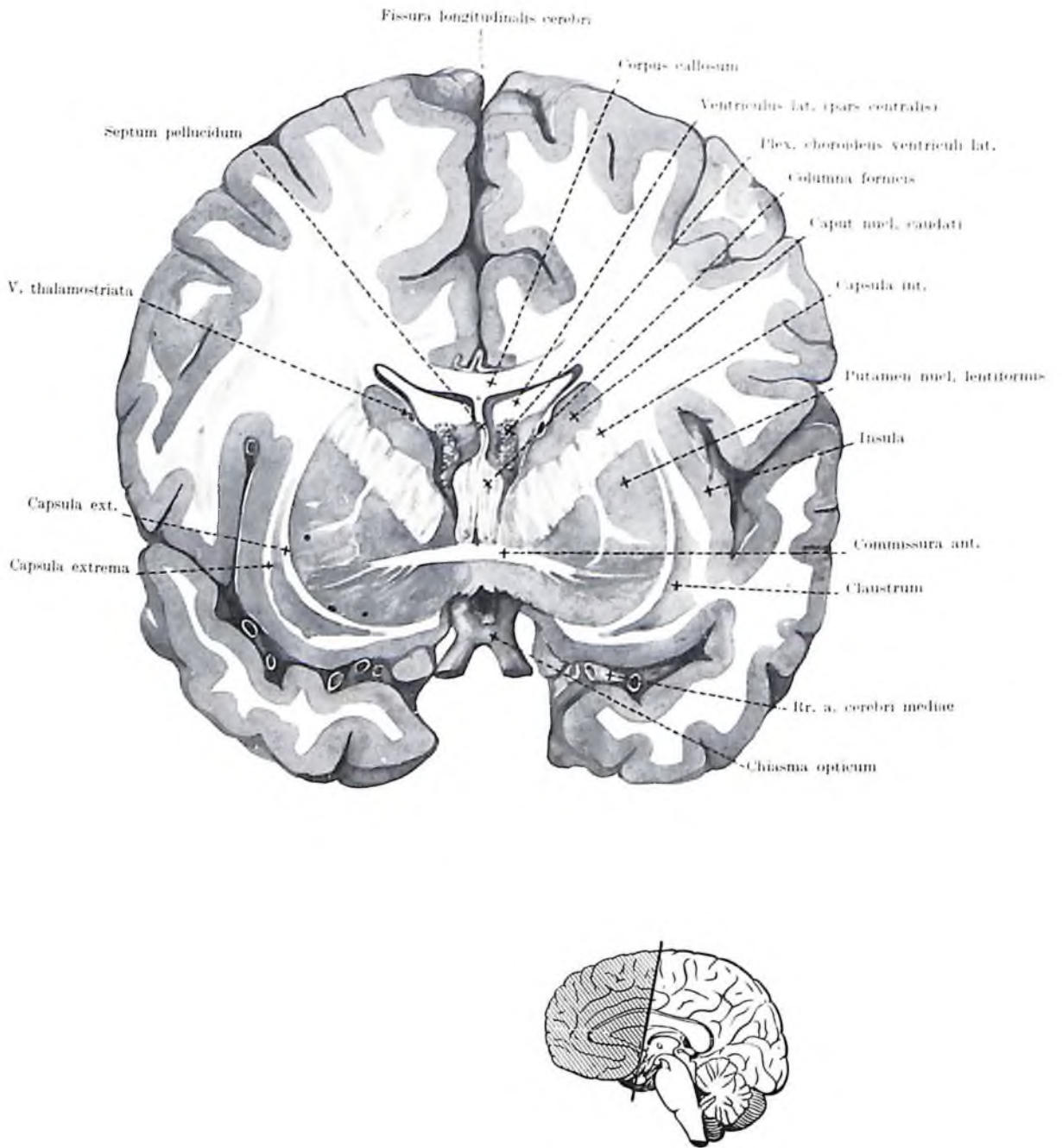


Fig. 41. SECTIO FRONTALIS CEREBRI II.
(aspectus anterior)

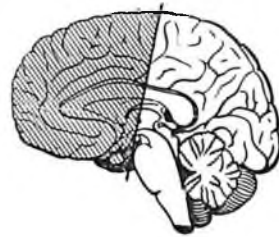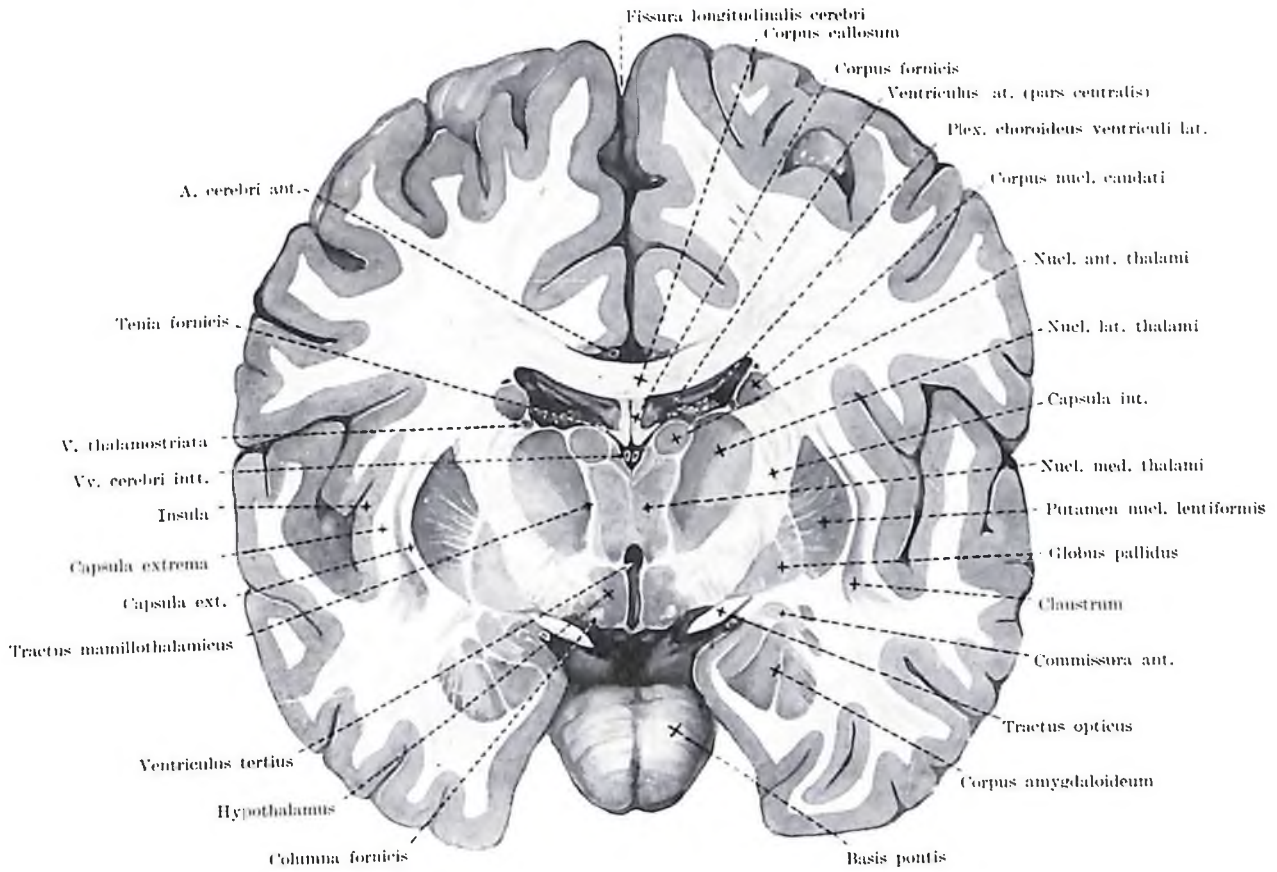


Fig. 42. SECTIO FRONTALIS CEREBRI III.
(aspectus anterior)

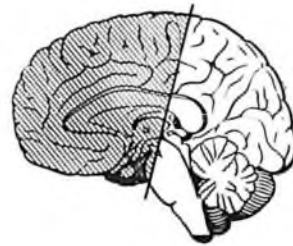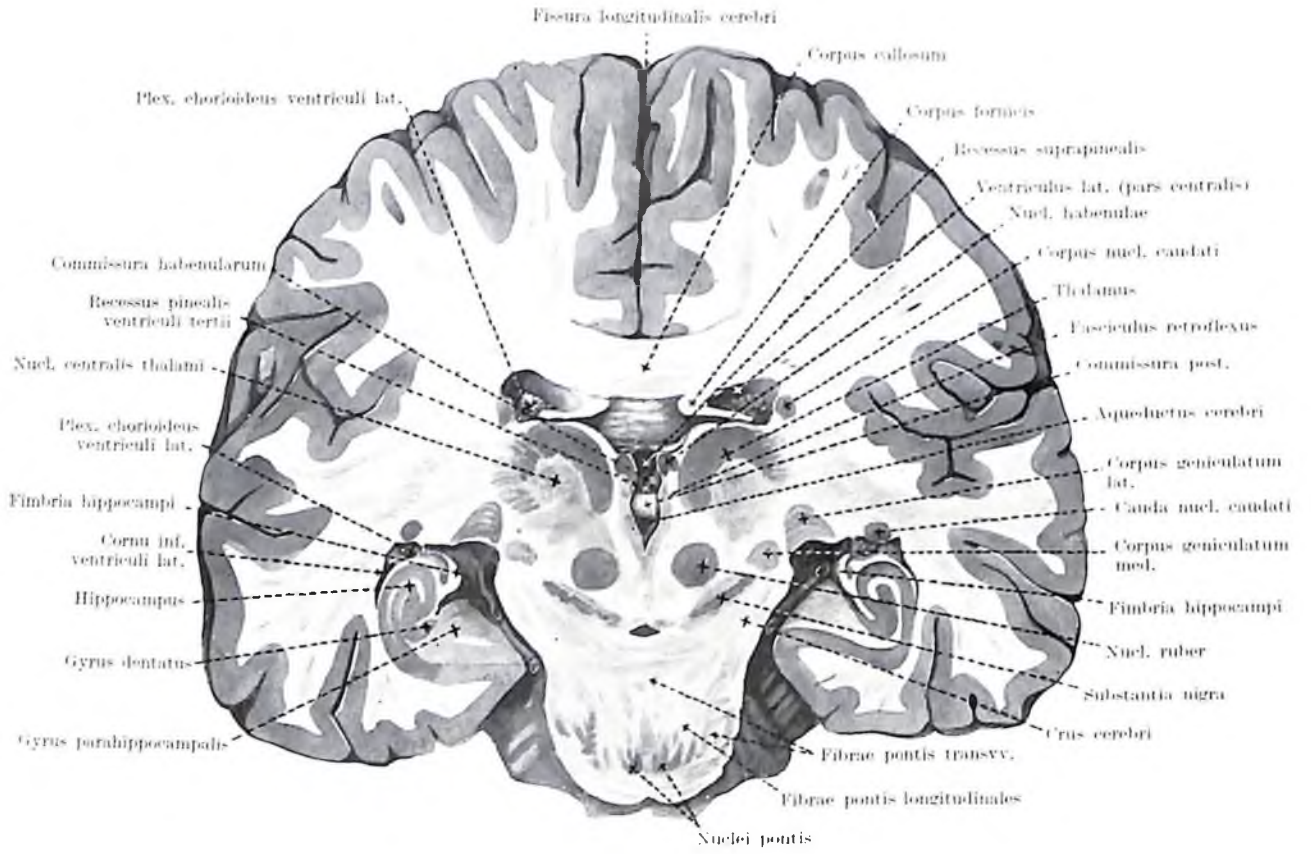


Fig. 43. SECTIO FRONTALIS CEREBRI IV.
(aspectus anterior)

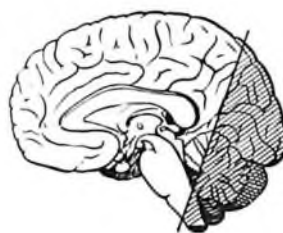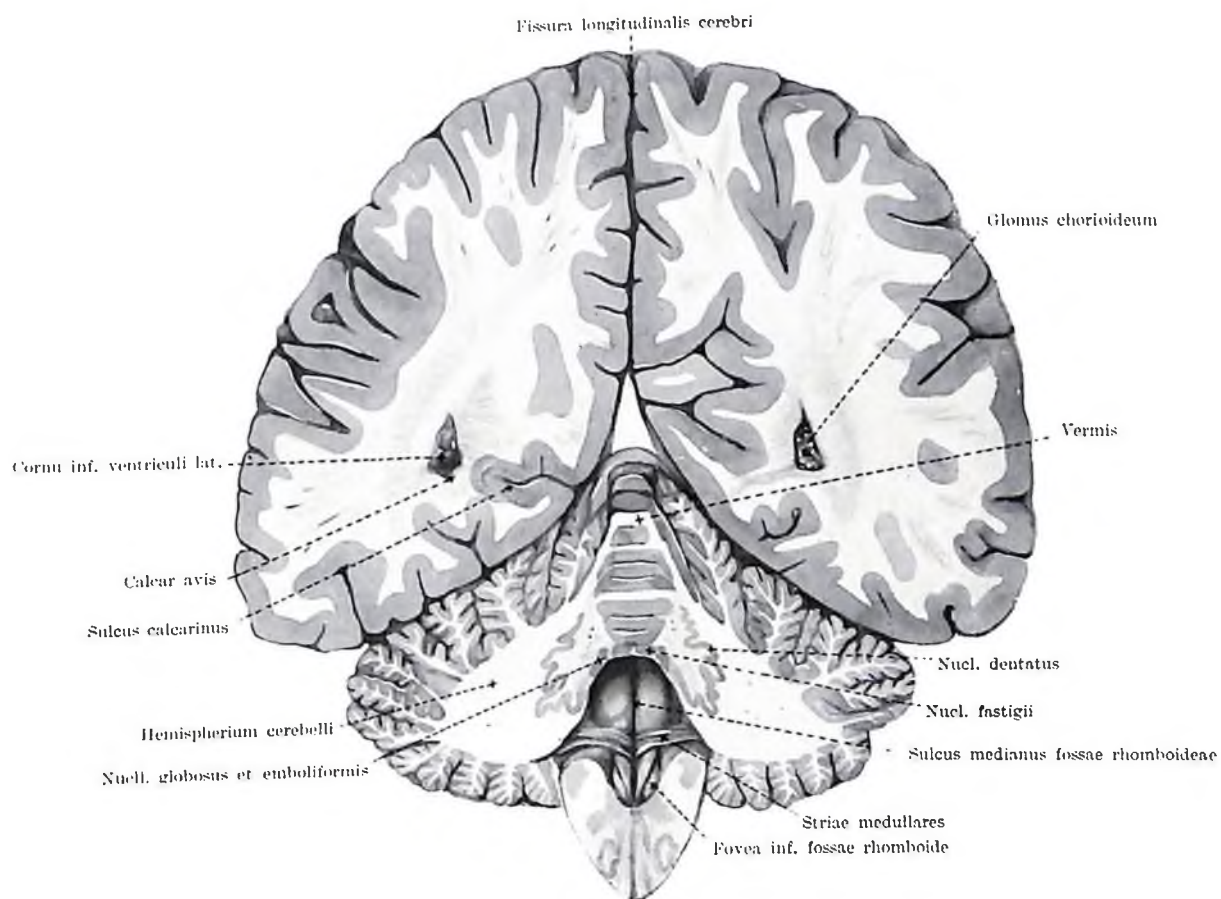


Fig. 44. SECTIO FRONTALIS CEREBRI V.
(aspectus posterior)

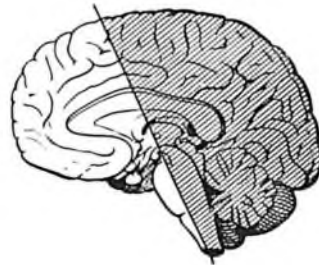
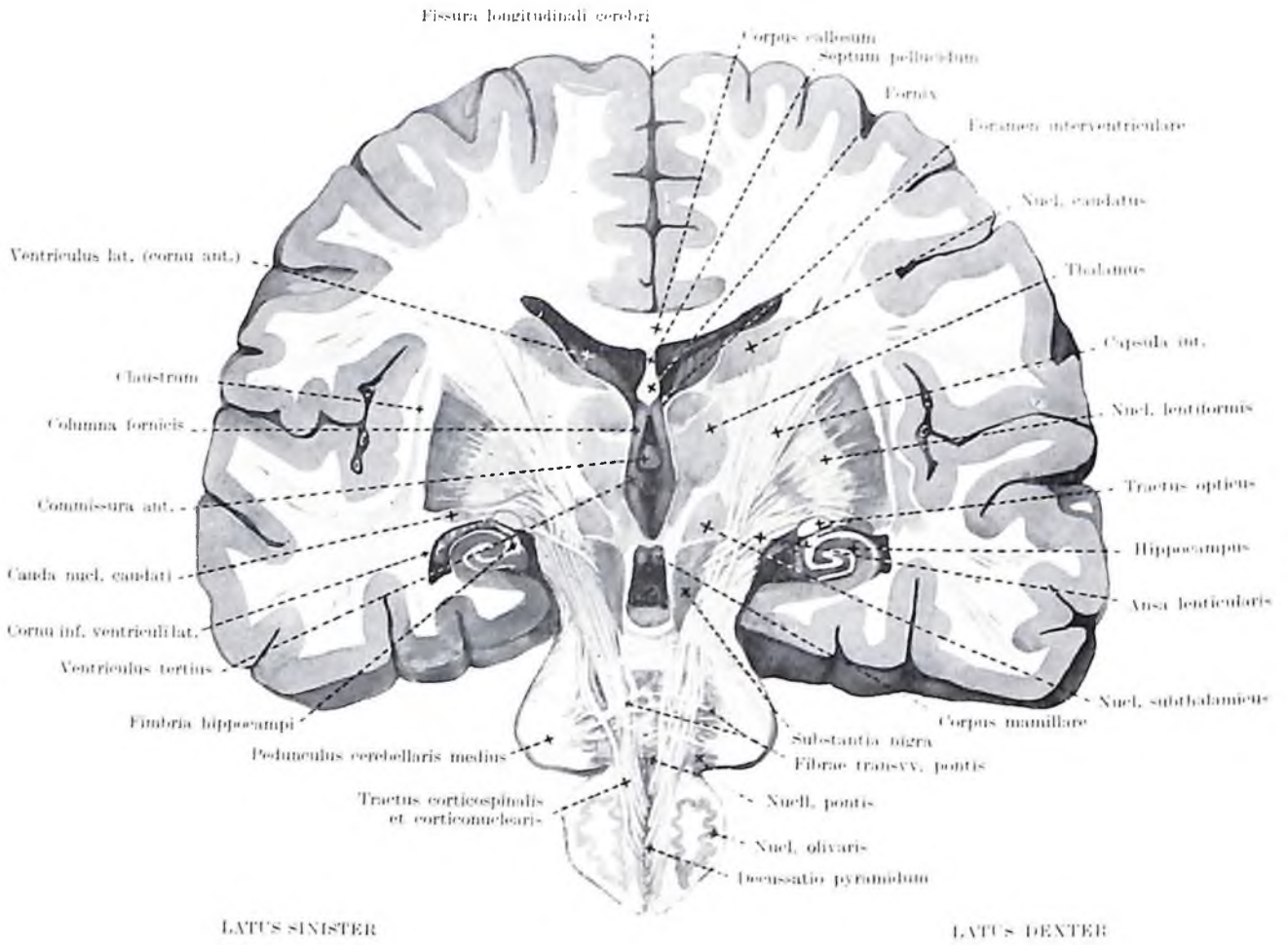


Fig. 45. SECTIO OBLIQUA CEREBRI I.
(sectio fronto-obliqua, aspectus posterior)

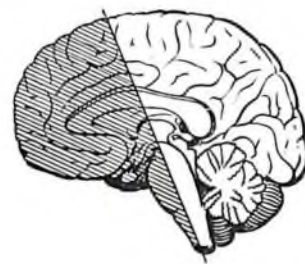
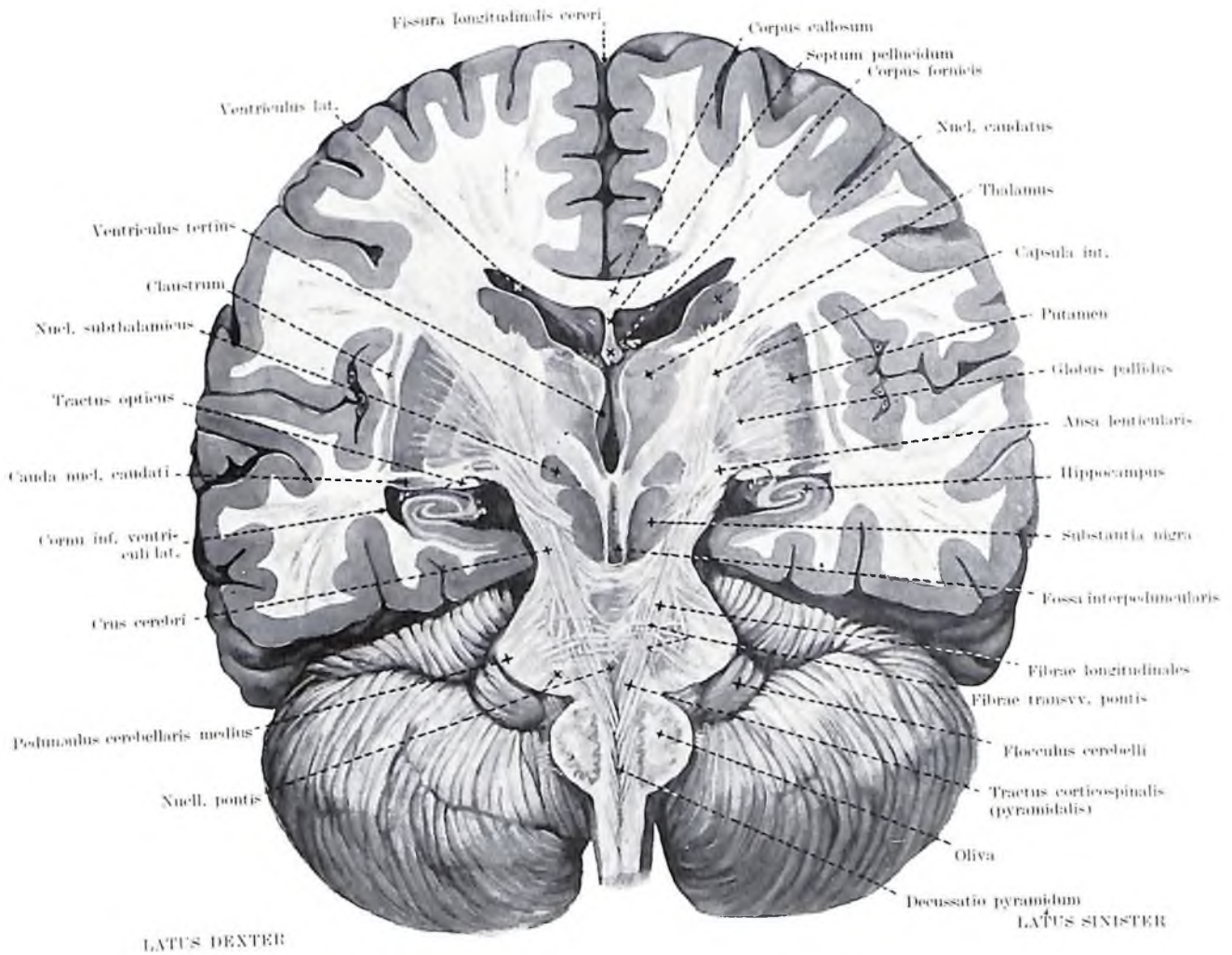


Fig. 46. SECTIO OBLIQUA CEREBRI II.
 (sectio fronto-obliqua, aspectus anterior)

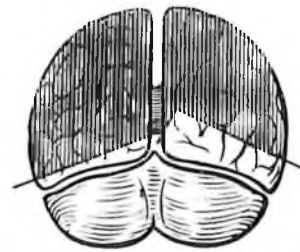
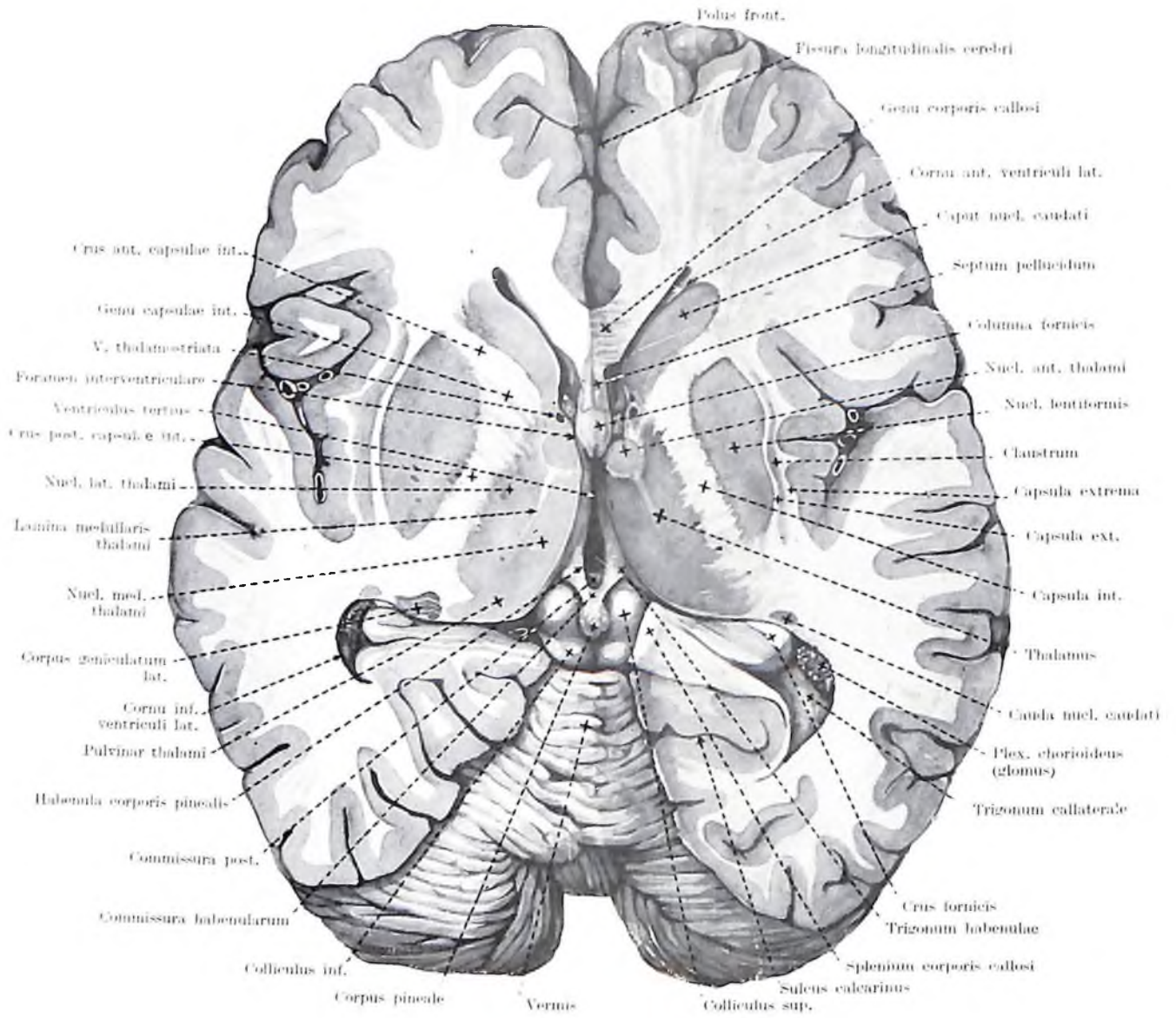


Fig. 47. SECTIO OBLIQUA CEREBRI III.
(sectiones horizonto-obliquae secundum Flechsig, aspectus superior)

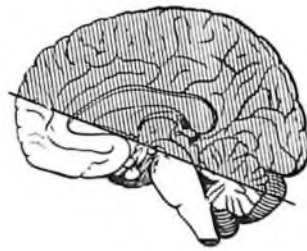
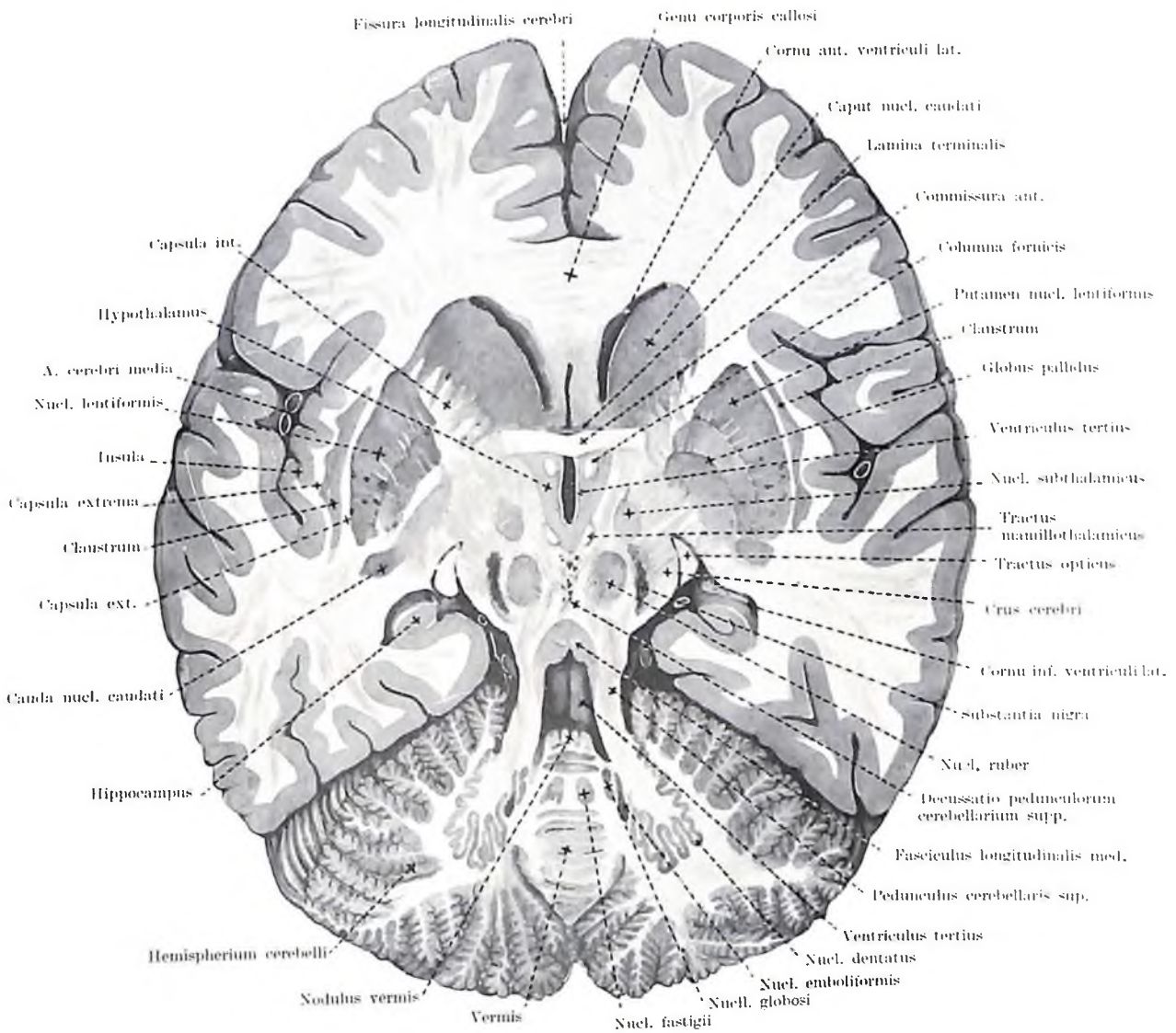
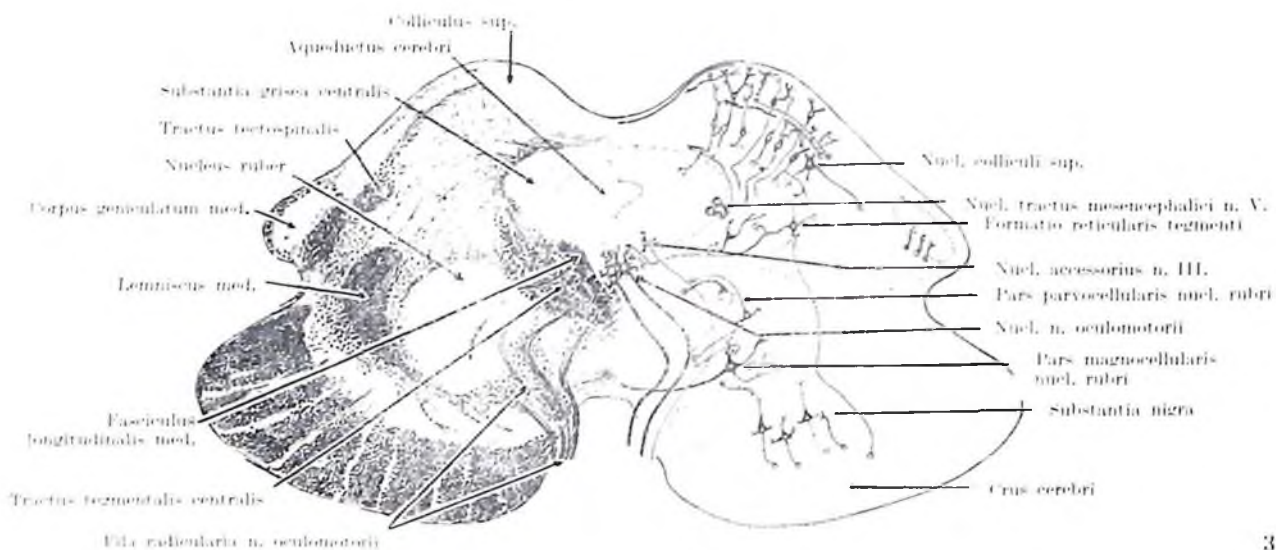
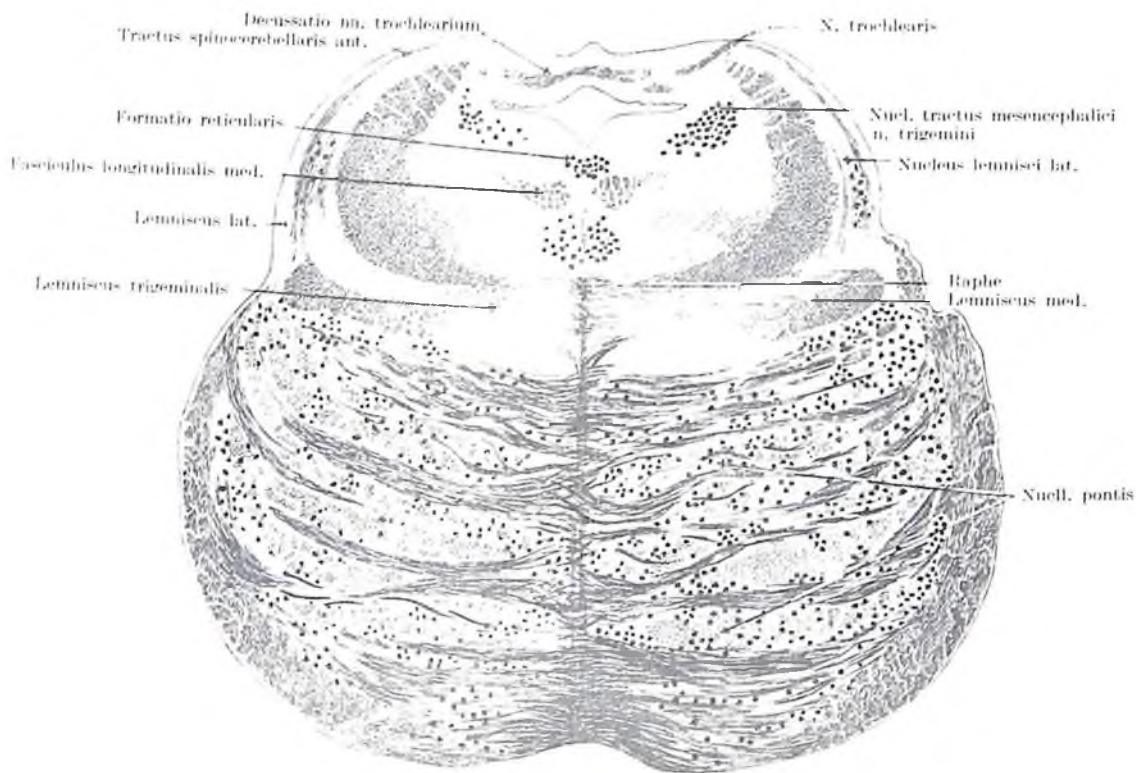


Fig. 48. SECTIO HORIZONTALIS CEREBRI
(aspectus superior)



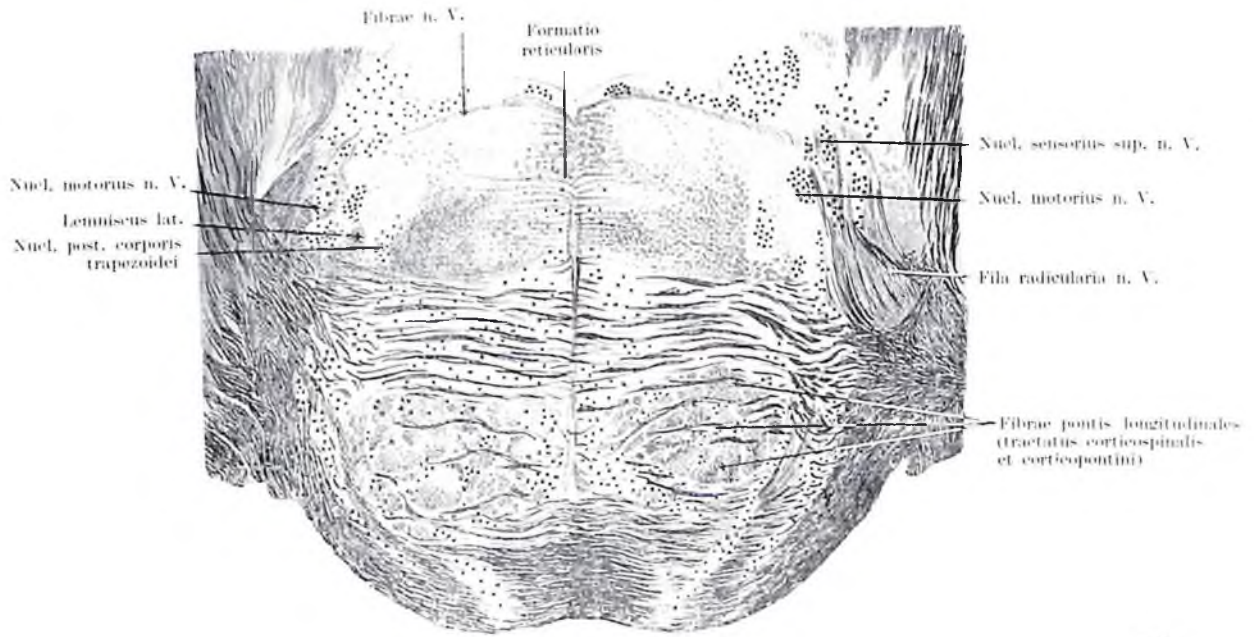
3/1

Fig. 49. SECTIO TRANSVERSA MESENCEPHALI
(l. sin. figurae: myeloarchitectura; l. dext. figurae: cytoarchitectura)



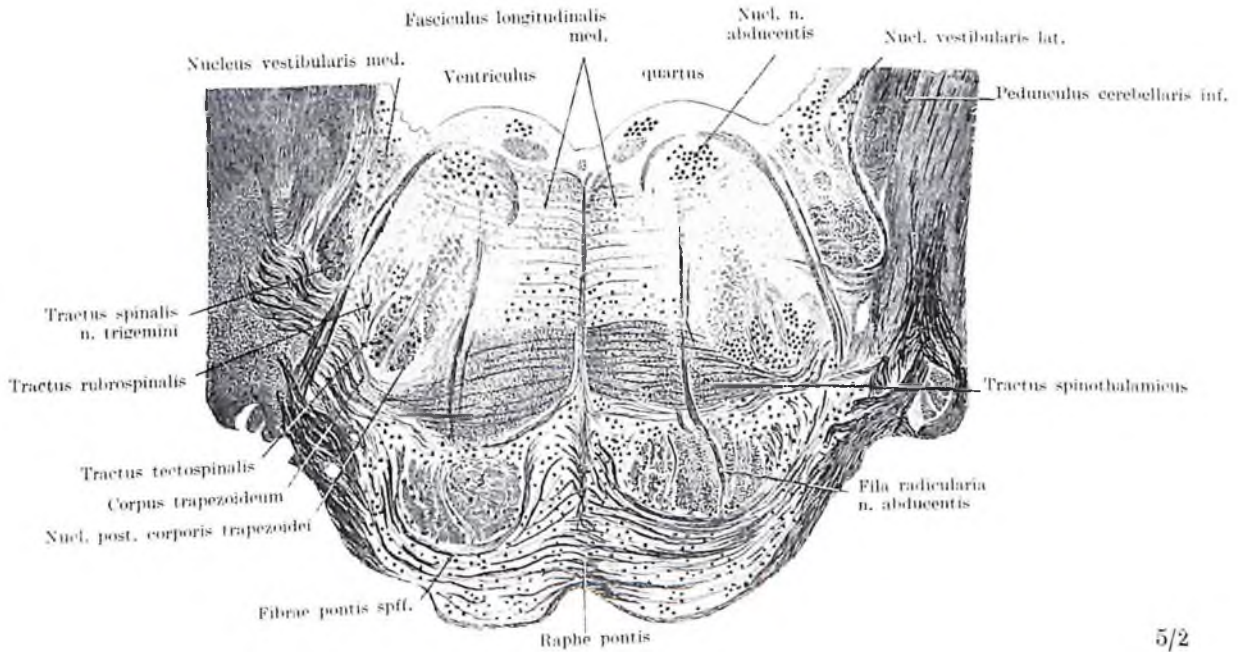
3/1

Fig. 50. SECTIO TRANSVERSA ISTHMI RHOMBENCEPHALI
(myeloarchitectura)



5/2

Fig. 51. SECTIO TRANSVERSA PONTIS I.
(pars superior, myeloarchitectura)



5/2

Fig. 52. SECTIO TRANSVERSA PONTIS II
(pars inferior, myeloarchitectura)

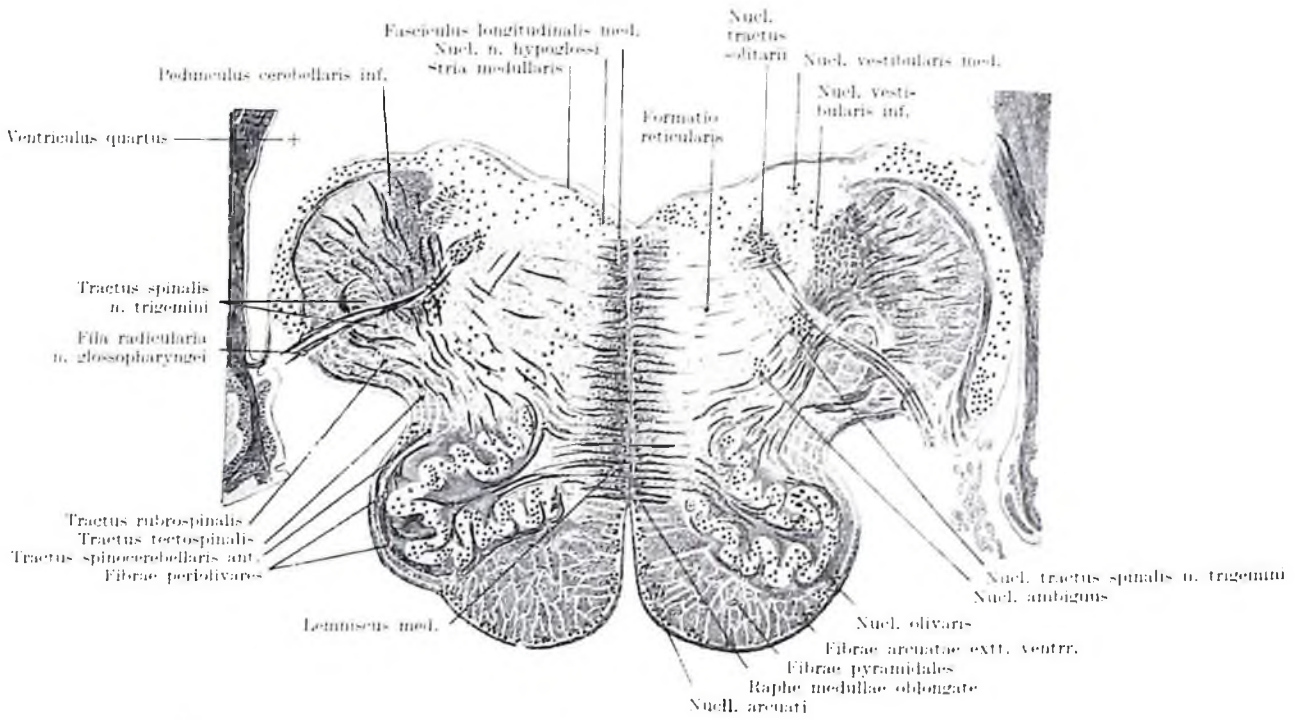


Fig. 53. SECTIO TRANSVERSA MEDULLÆ OBLONGATÆ I.
(pars superior, myeloarchitectura)

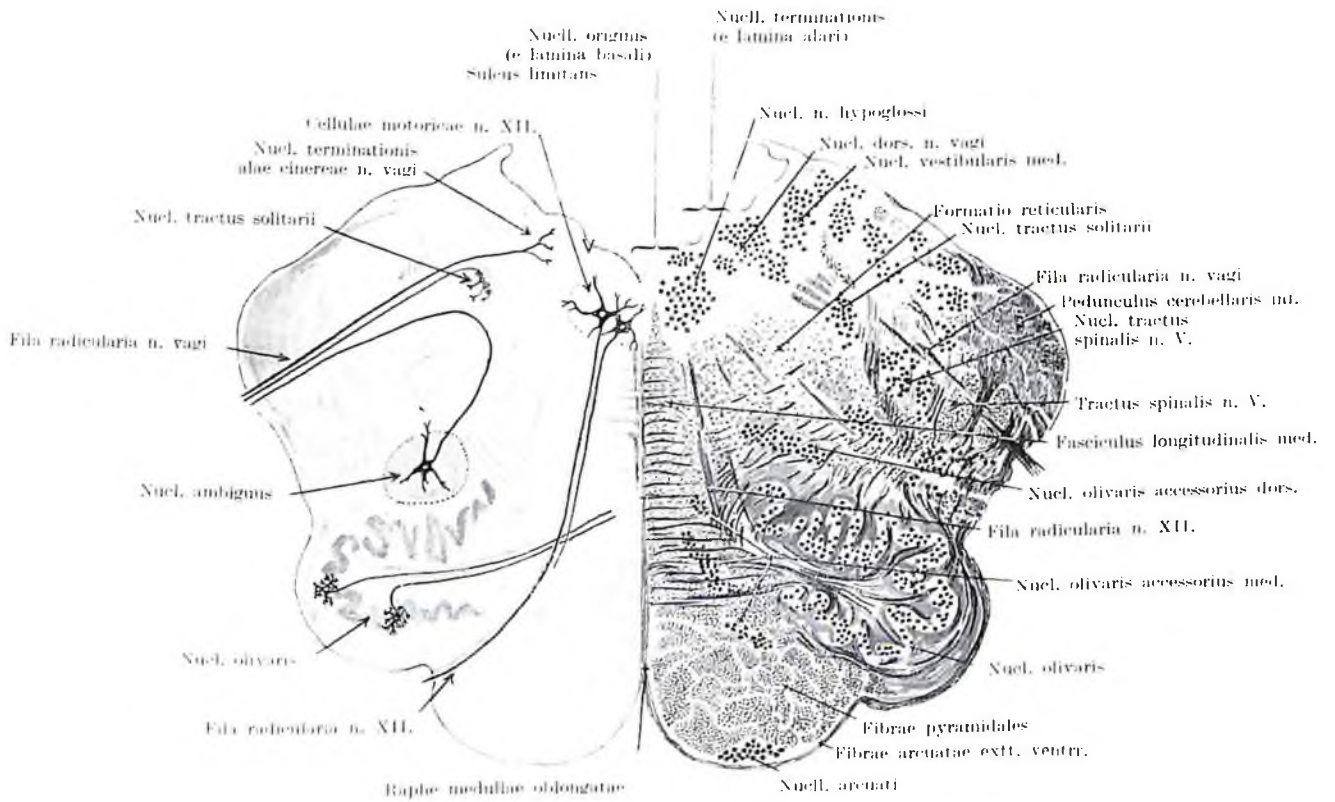


Fig. 54. SECTIO TRANSVERSA MEDULLÆ OBLONGATÆ II.
(pars media, cyto- et myeloarchitectura)

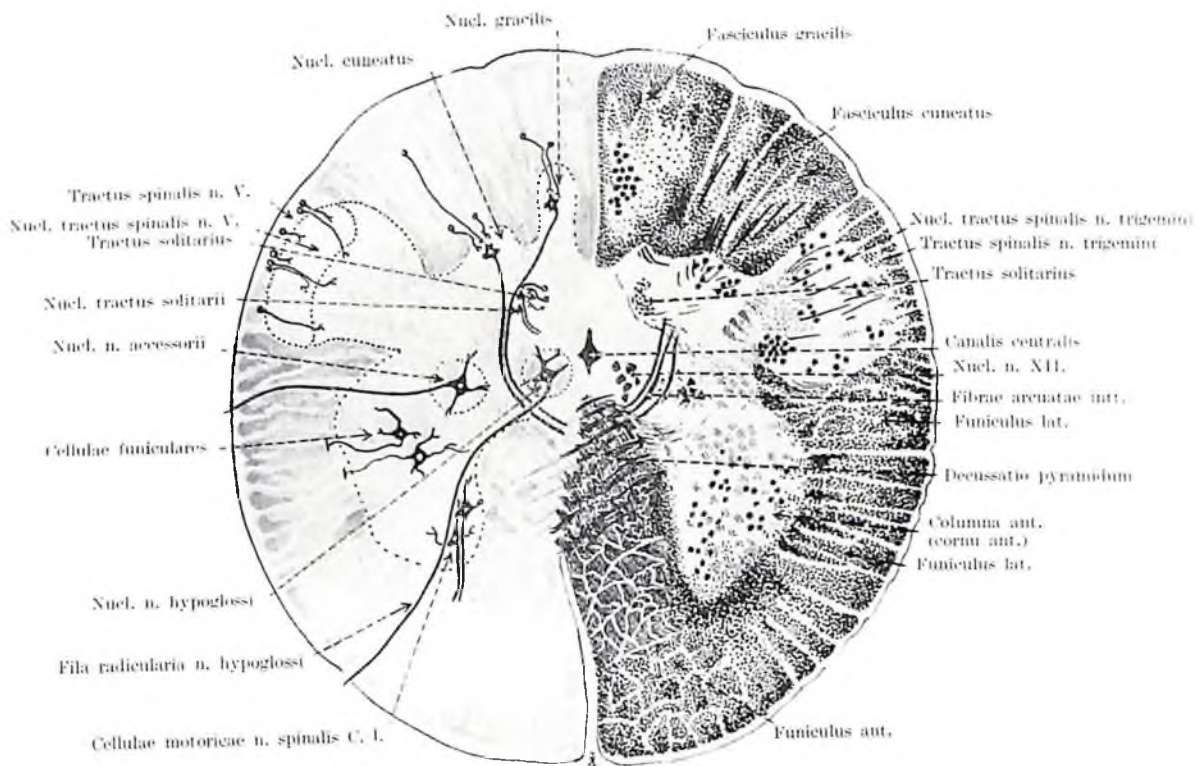


Fig. 55. SECTIO TRANSVERSA MEDULLAE OBLONGATAE III.
(pars intima, cyto- et myeloarchitecturae)

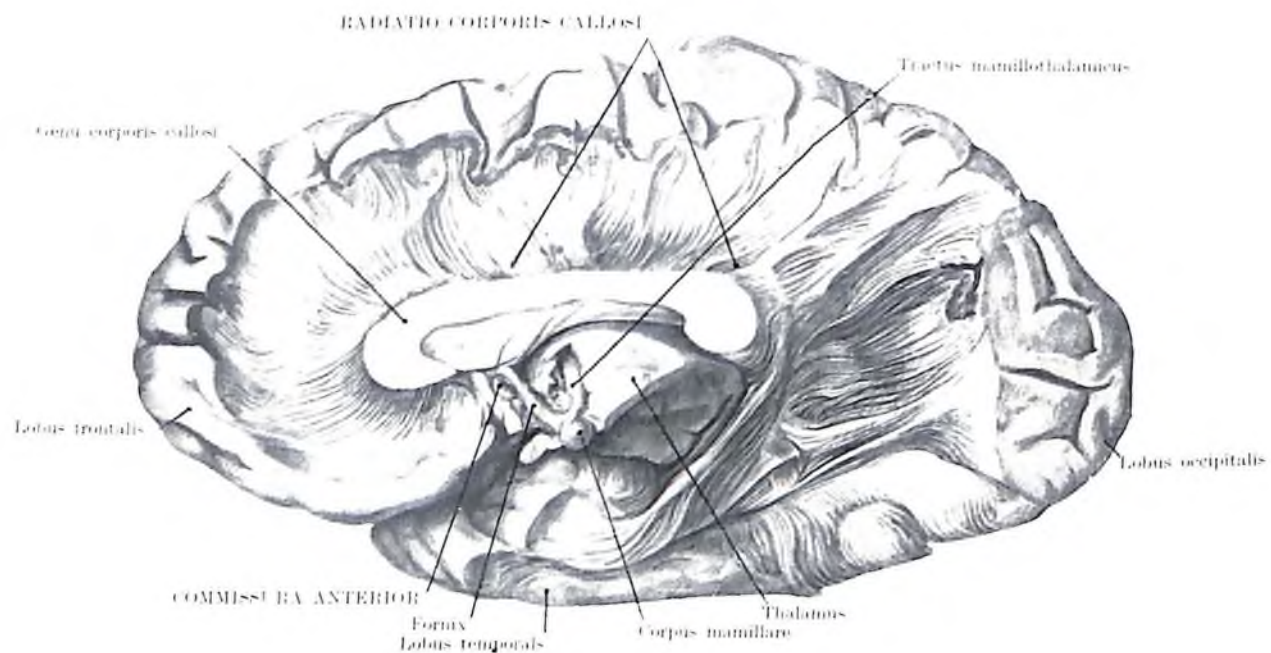


Fig. 56. TRACTUS ENCEPHALI I.
(tractus nervosi commissurales, corpus callosum, preparatum fecit: S. B. Dzugaeva)

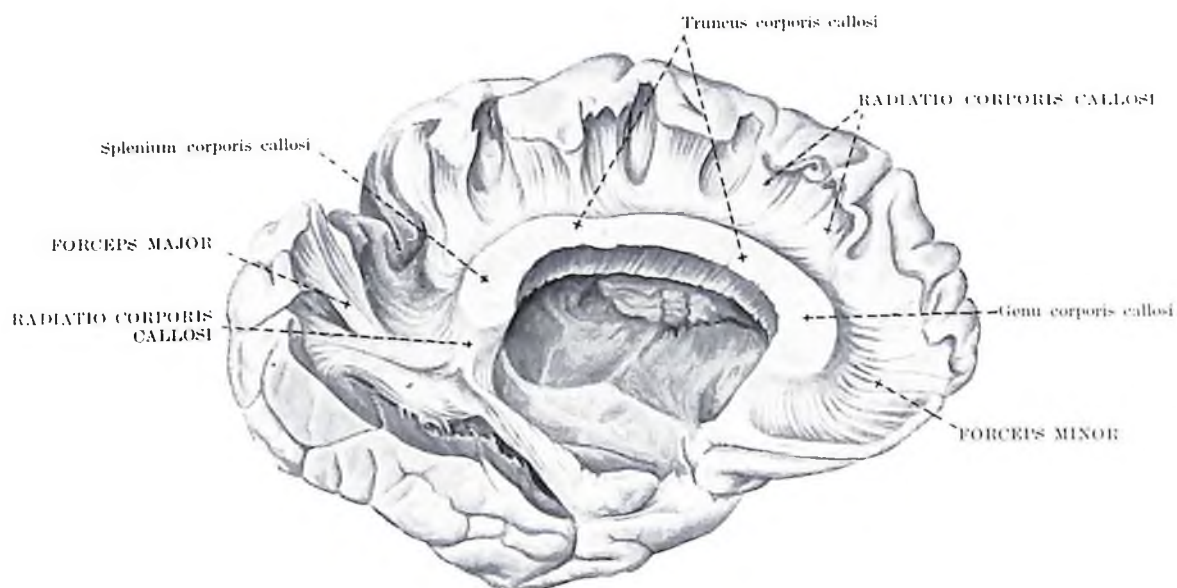


Fig. 57. TRACTUS ENCEPHALI II.
(corpus callosum, hemispherium sin.)

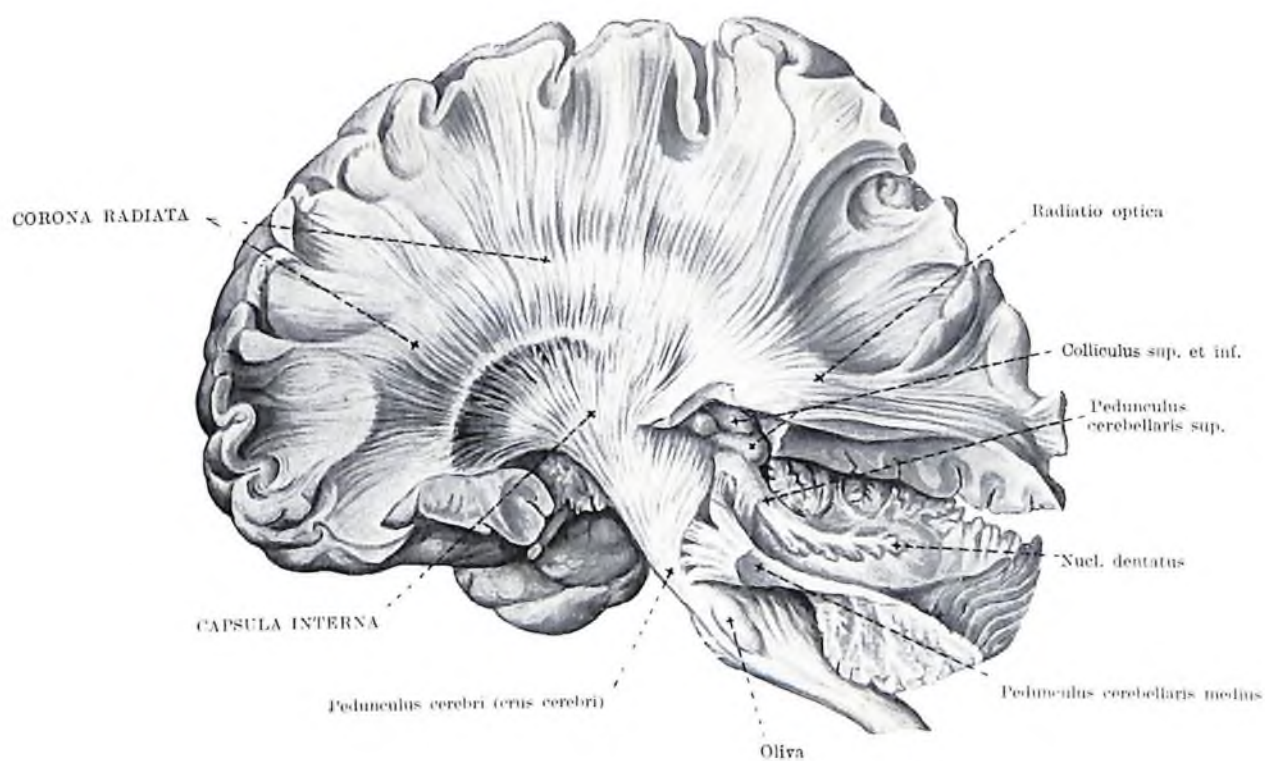


Fig. 58. TRACTUS ENCEPHALI III.
(corona radiata et capsula interna)

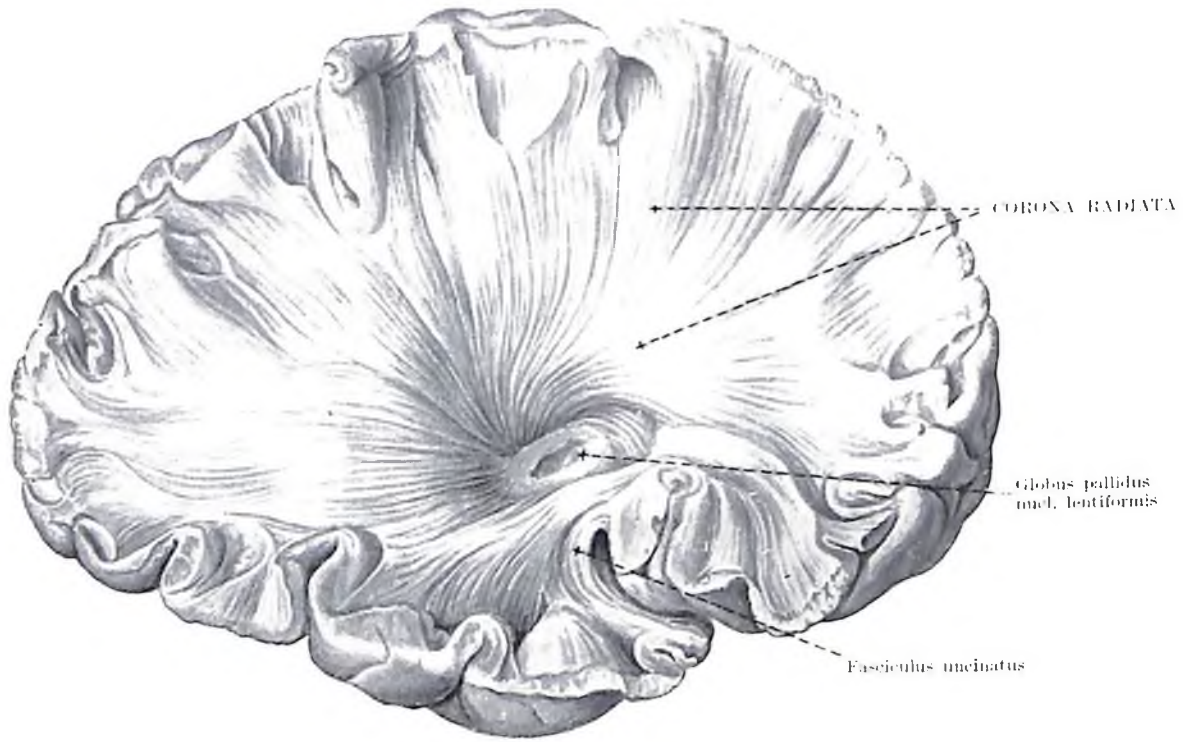


Fig. 59. TRACTUS ENCEPHALI IV.
(corona radiata, l. dext.)

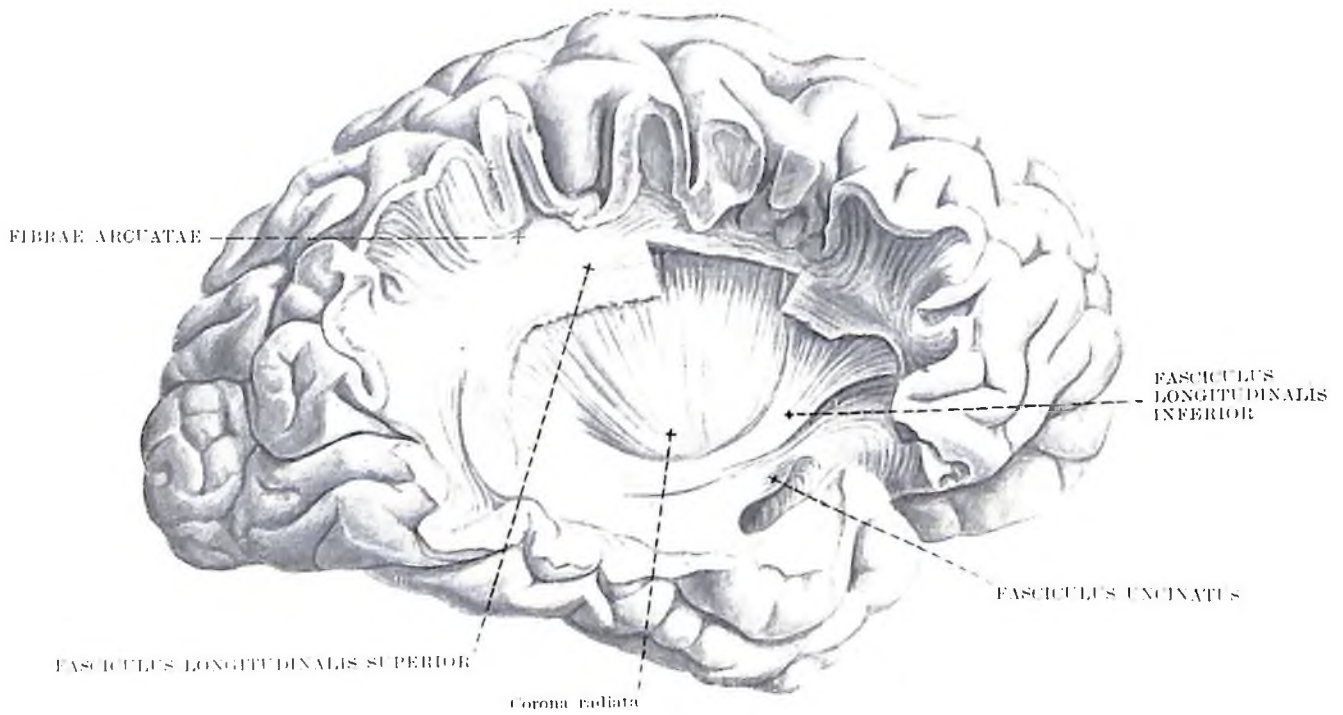


Fig. 60. TRACTUS ENCEPHALI V.
(tractus nervosi associationis)

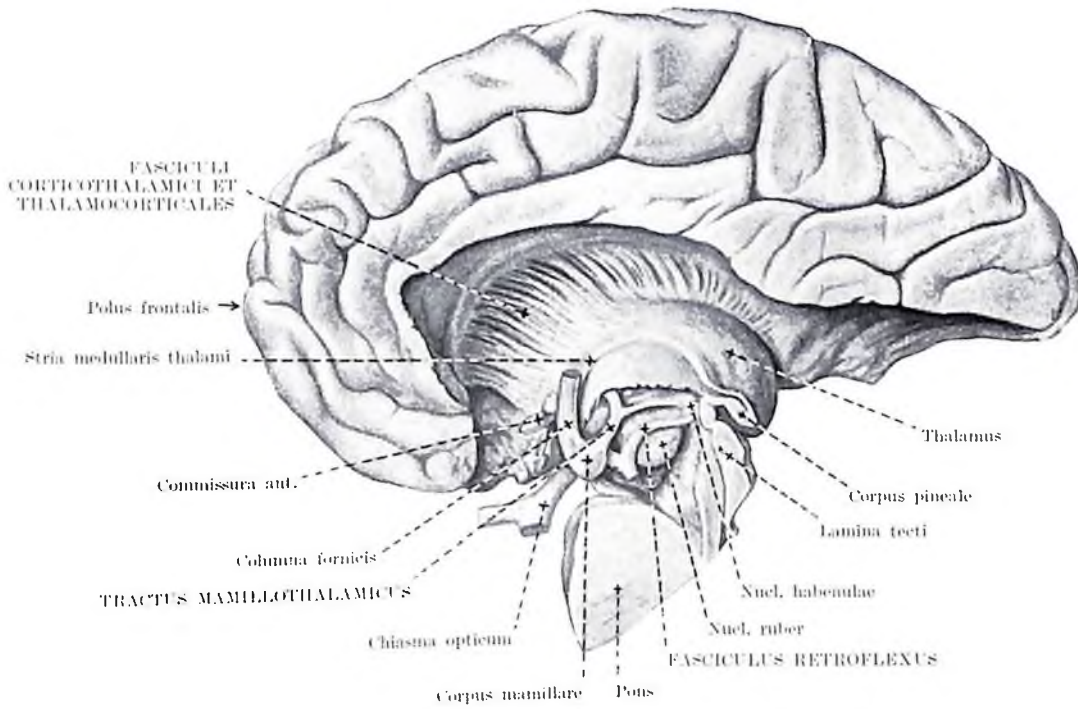


Fig. 61. TRACTUS ENCEPHALI VI.
(radiatio thalami, tractus mamillothalamicus et fasciculus retroflexus, l. dext.)

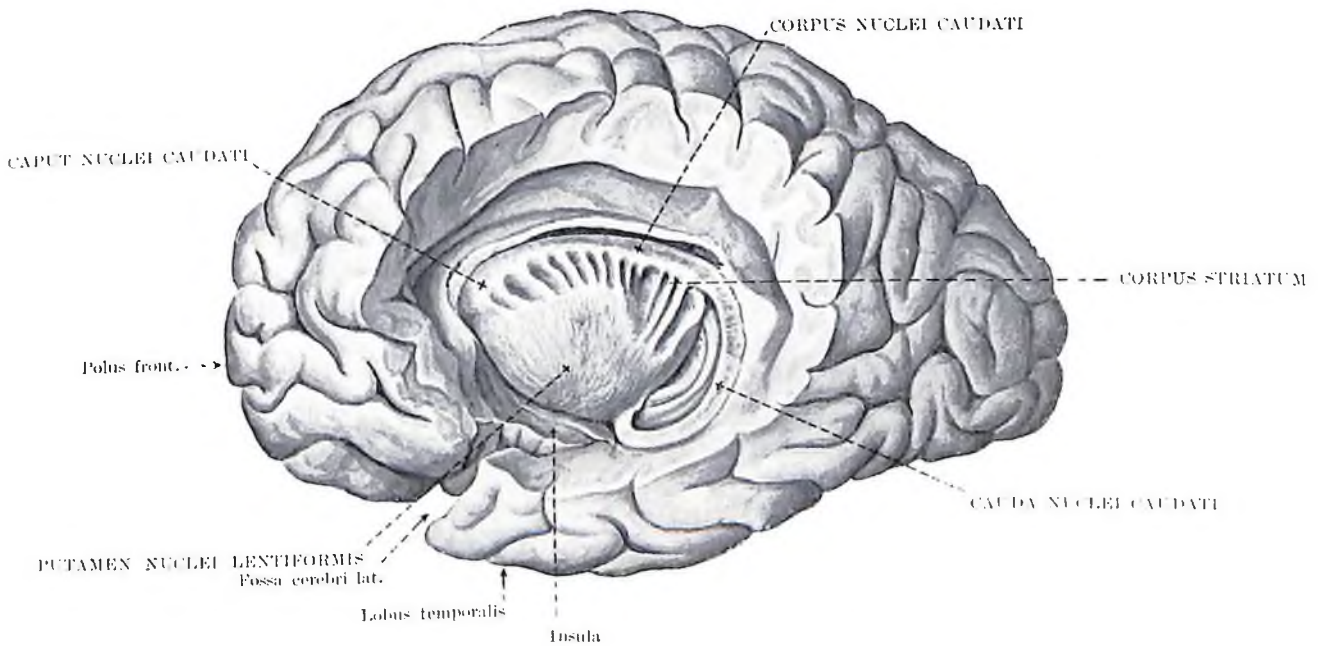


Fig. 62. TRACTUS ET NUCLEI ENCEPHALI I.
(nucleus caudatus et nucleus lentiformis, aspectus lateralis, l. sin.)

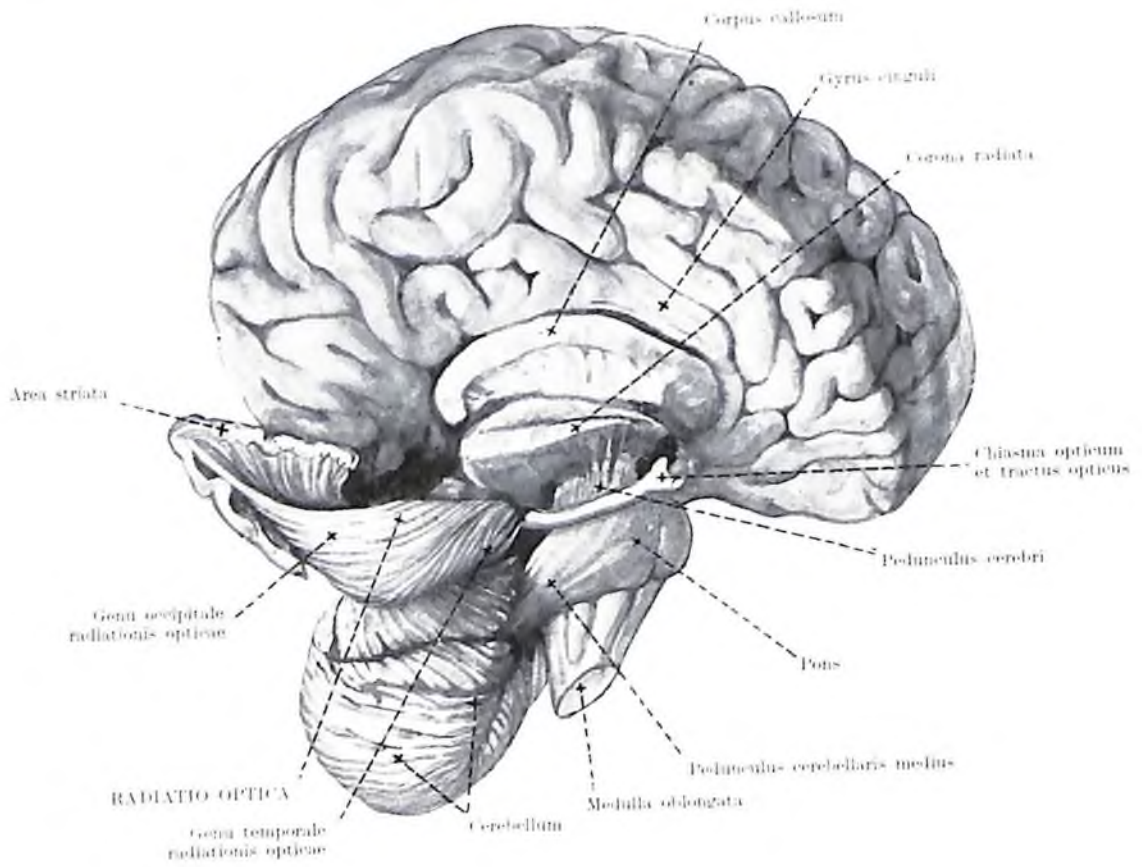


Fig. 63. TRACTUS ENCEPHALI VII.
(radiatio optica)

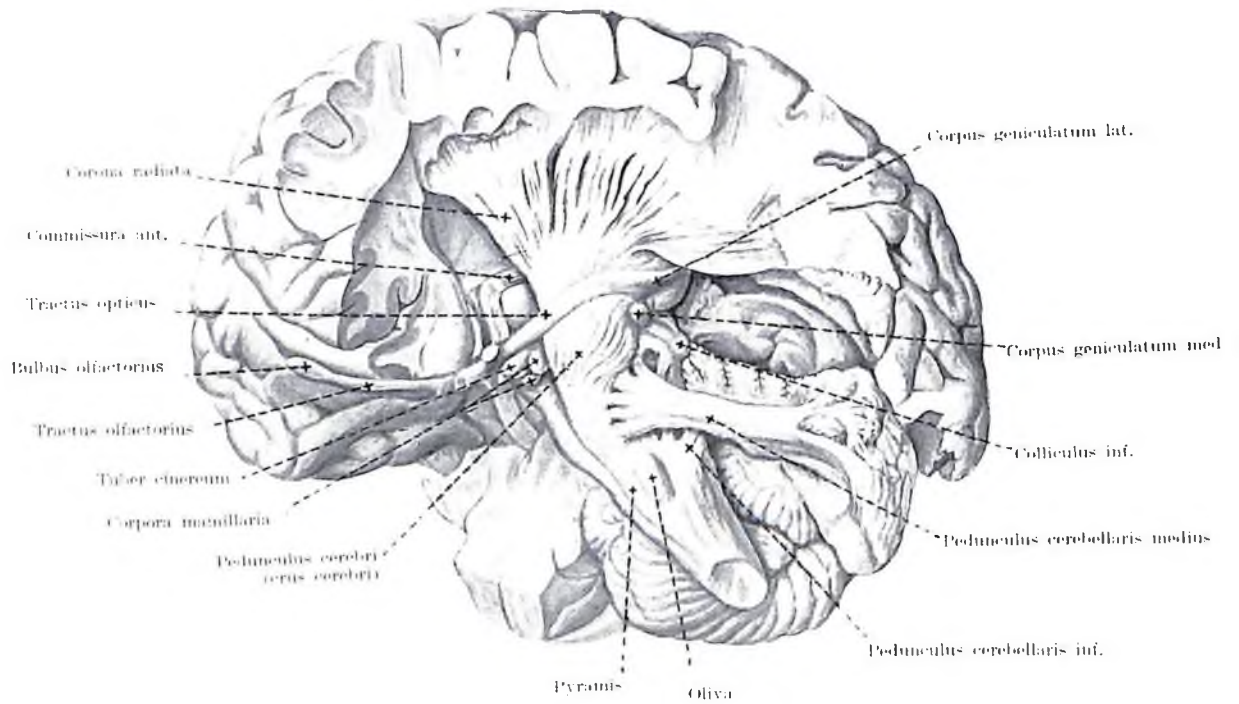


Fig. 64. TRACTUS ET NUCLEI ENCEPHALI II.
(aspectus infero-lateralis, l. sin.)

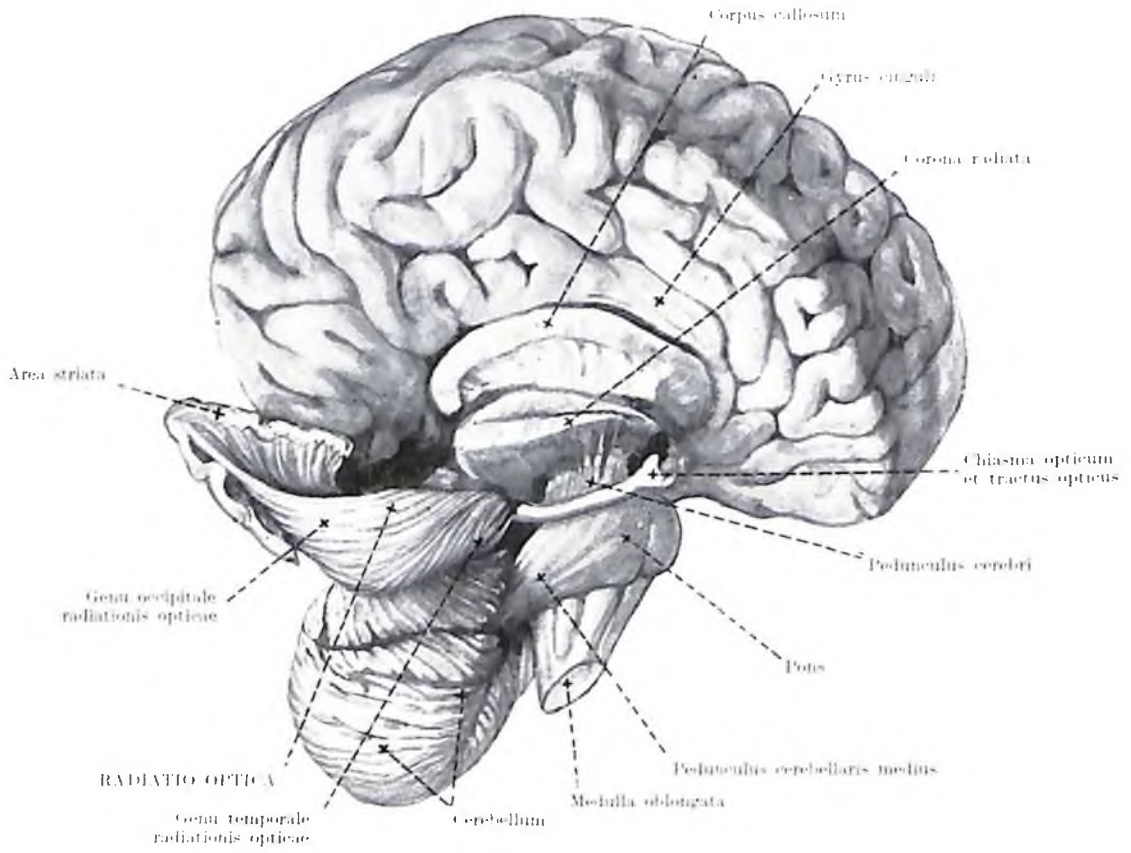


Fig. 63. TRACTUS ENCEPHALI VII.
(radiatio optica)

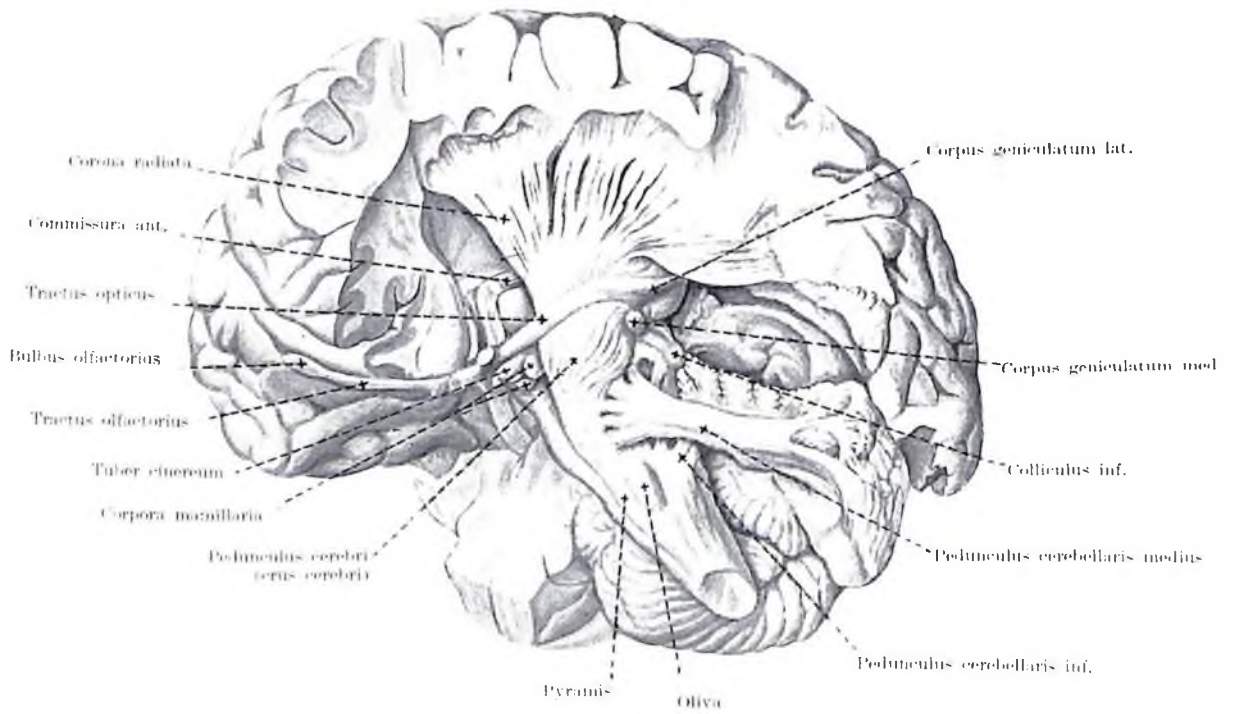


Fig. 64. TRACTUS ET NUCLEI ENCEPHALI II.
(aspectus infero-lateralis, l. sin.)

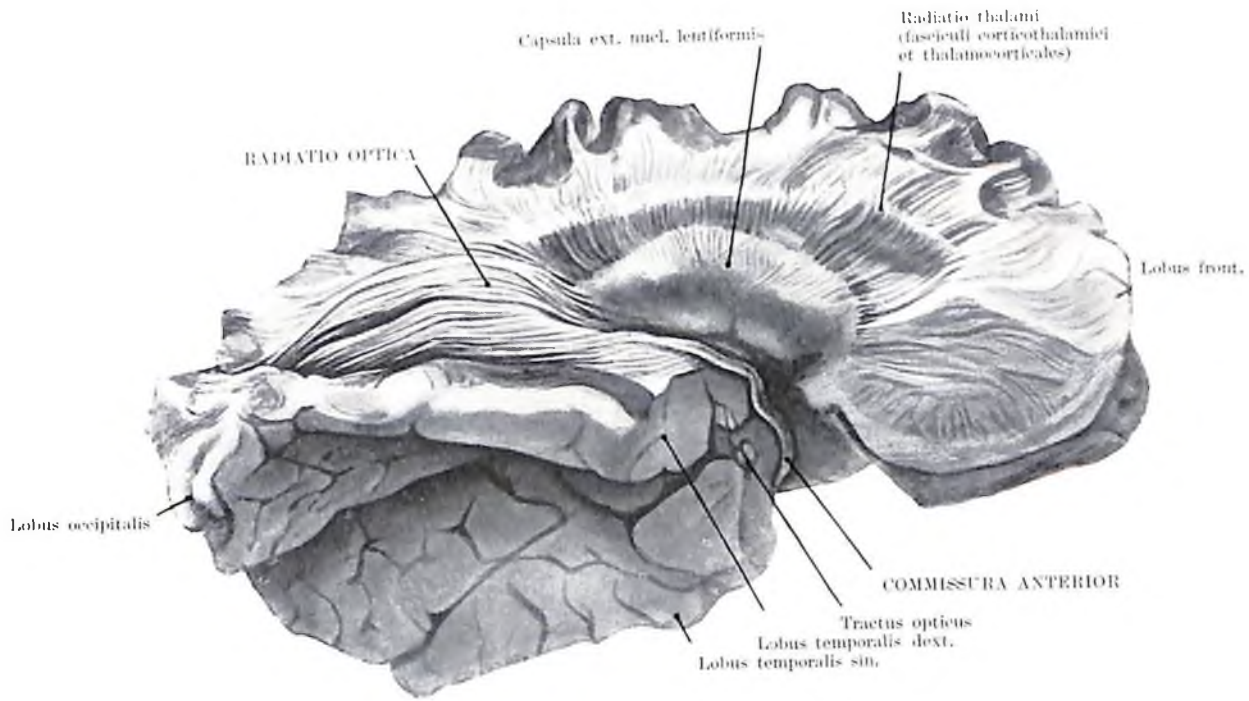


Fig. 65. TRACTUS ENCEPHALI VIII.
(radiatio optica et commissura anterior, aspectus infero-lateralis dexter)

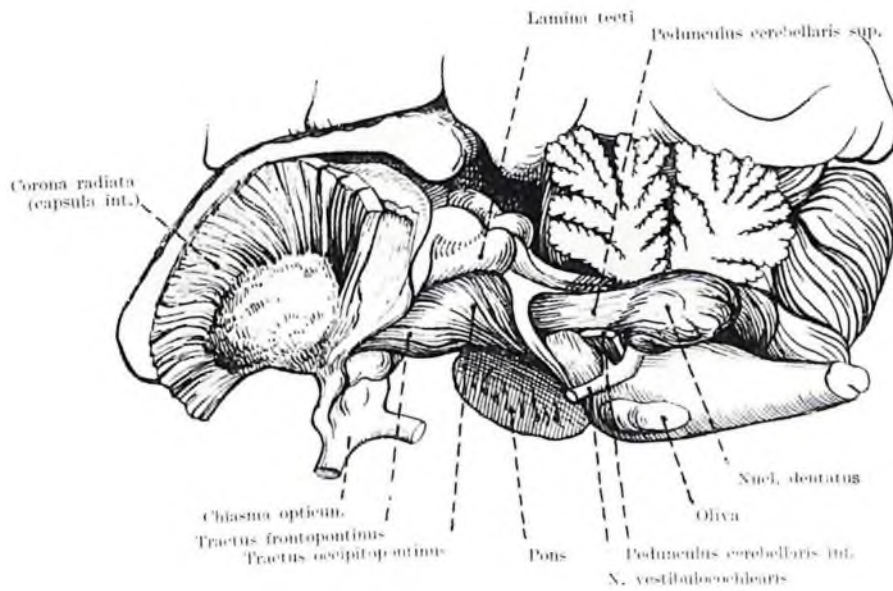
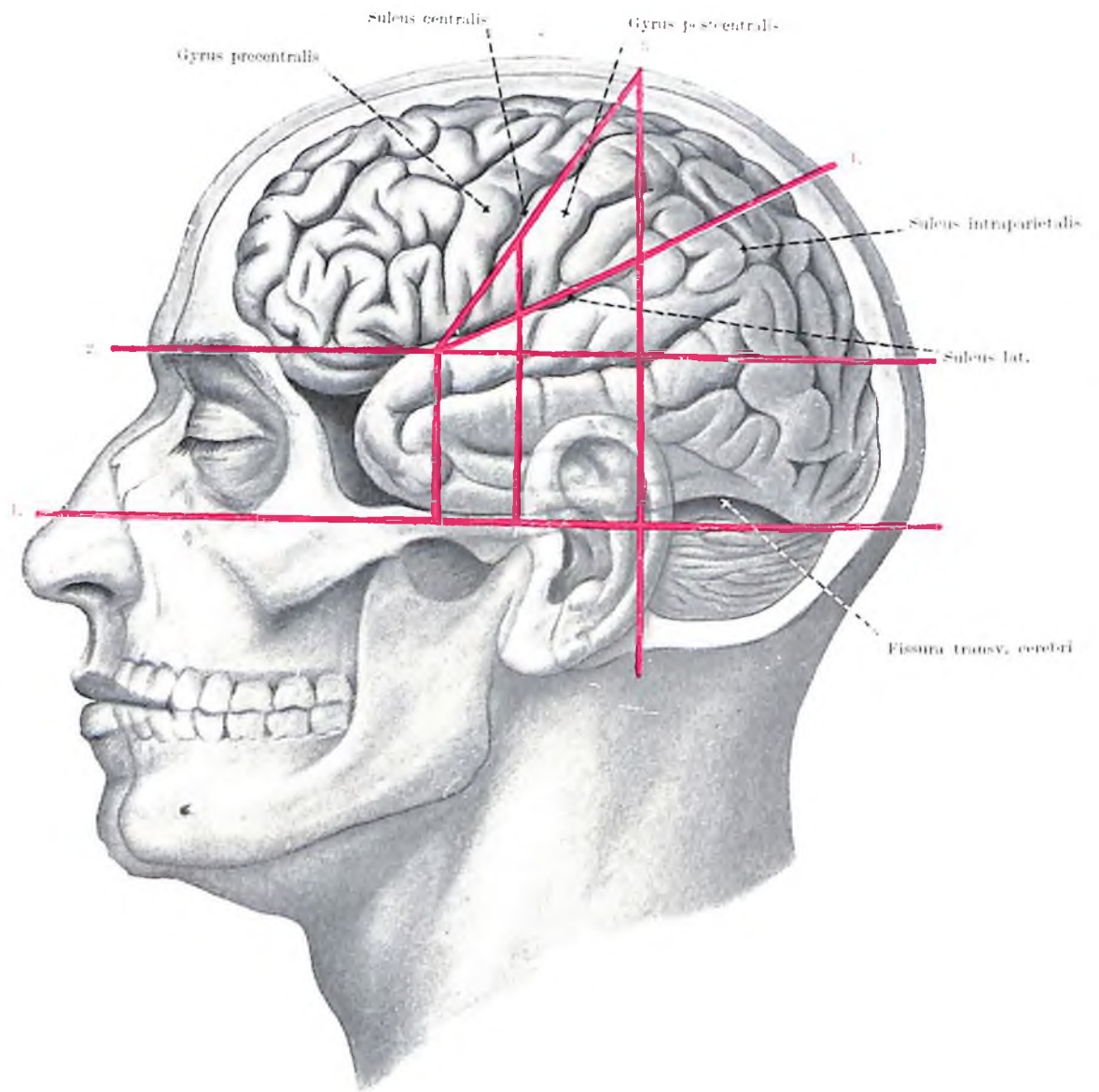


Fig. 66. TRACTUS ET NUCLEI ENCEPHALI III.
(aspectus supero-lateralis, l. sin.)



1. Linea horizontalis infraorbitalis (Frankfurt)
2. Linea horizontalis supraorbitalis
3. Linea Rolandica
4. Linea Sylvii

Fig. 67. TOPOGRAPHIA CRANIOCEREBRALIS I.
(secundum Krönlein)

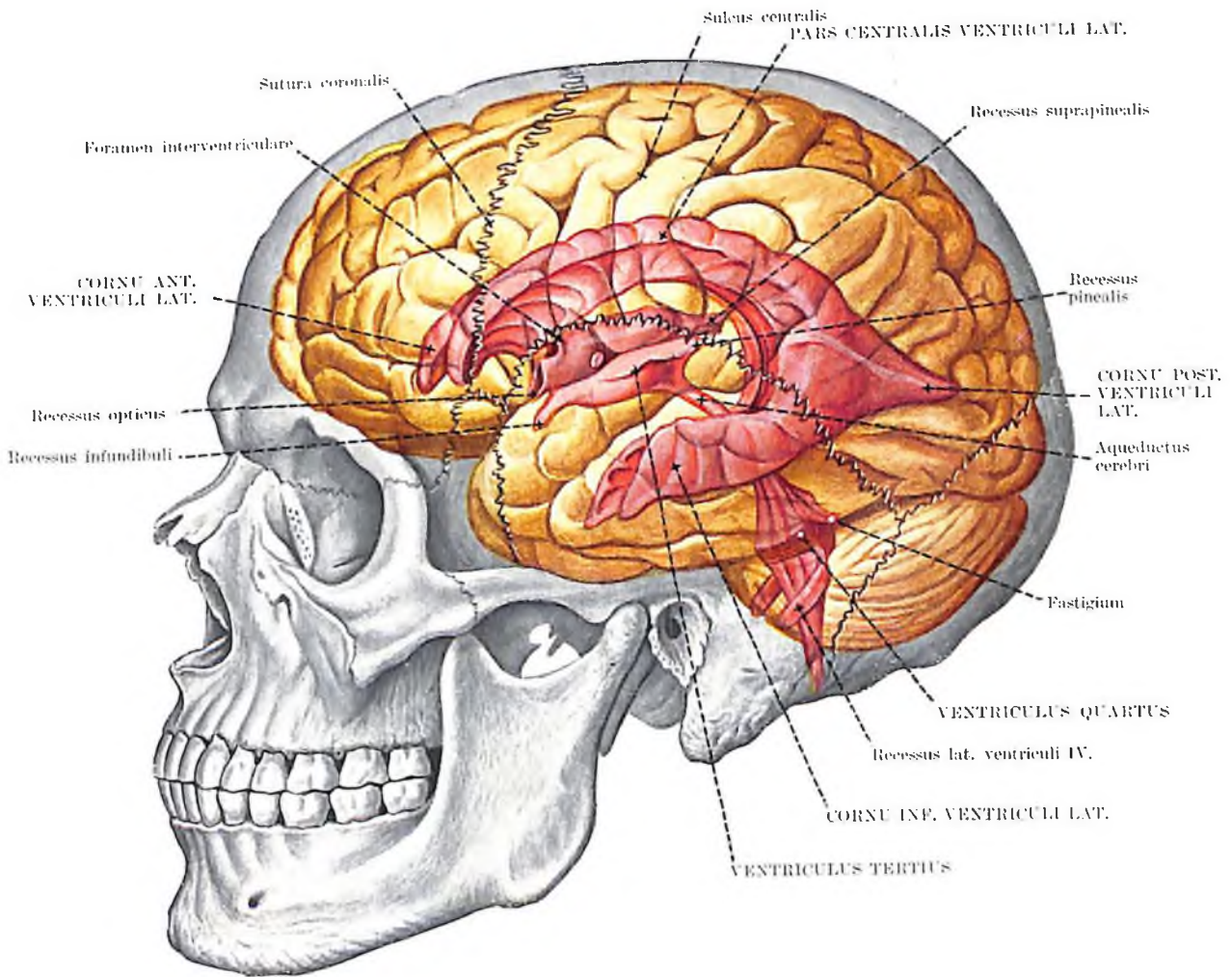


Fig. 68. TOPOGRAPHIA CRANIOCEREBRALIS II.
(ventriculi cerebri, aspectus lateralis)

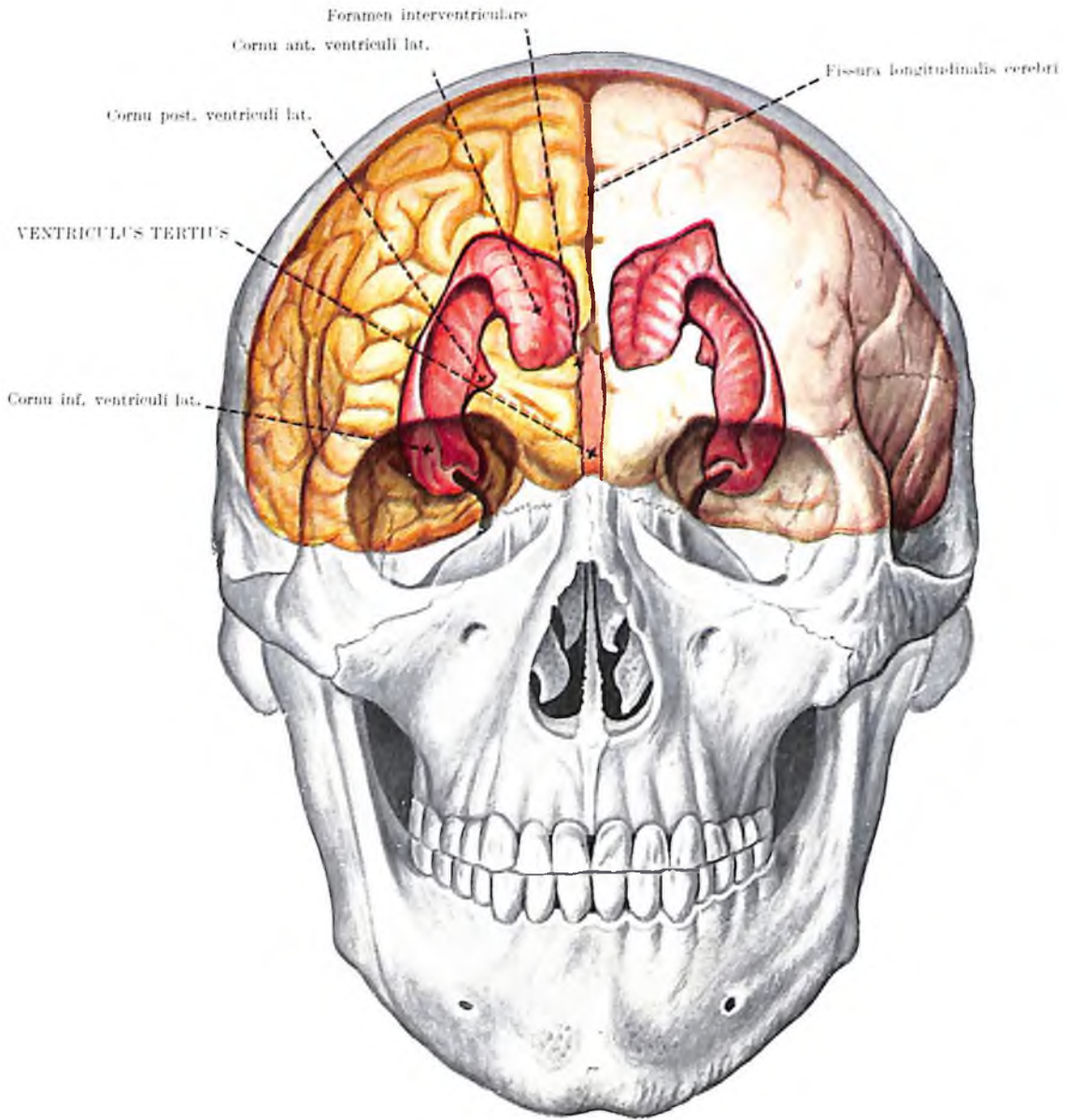


Fig. 69. TOPOGRAPHIA CRANIOCEREBRALIS III.
(ventriculi cerebri, aspectus antero-posterior)

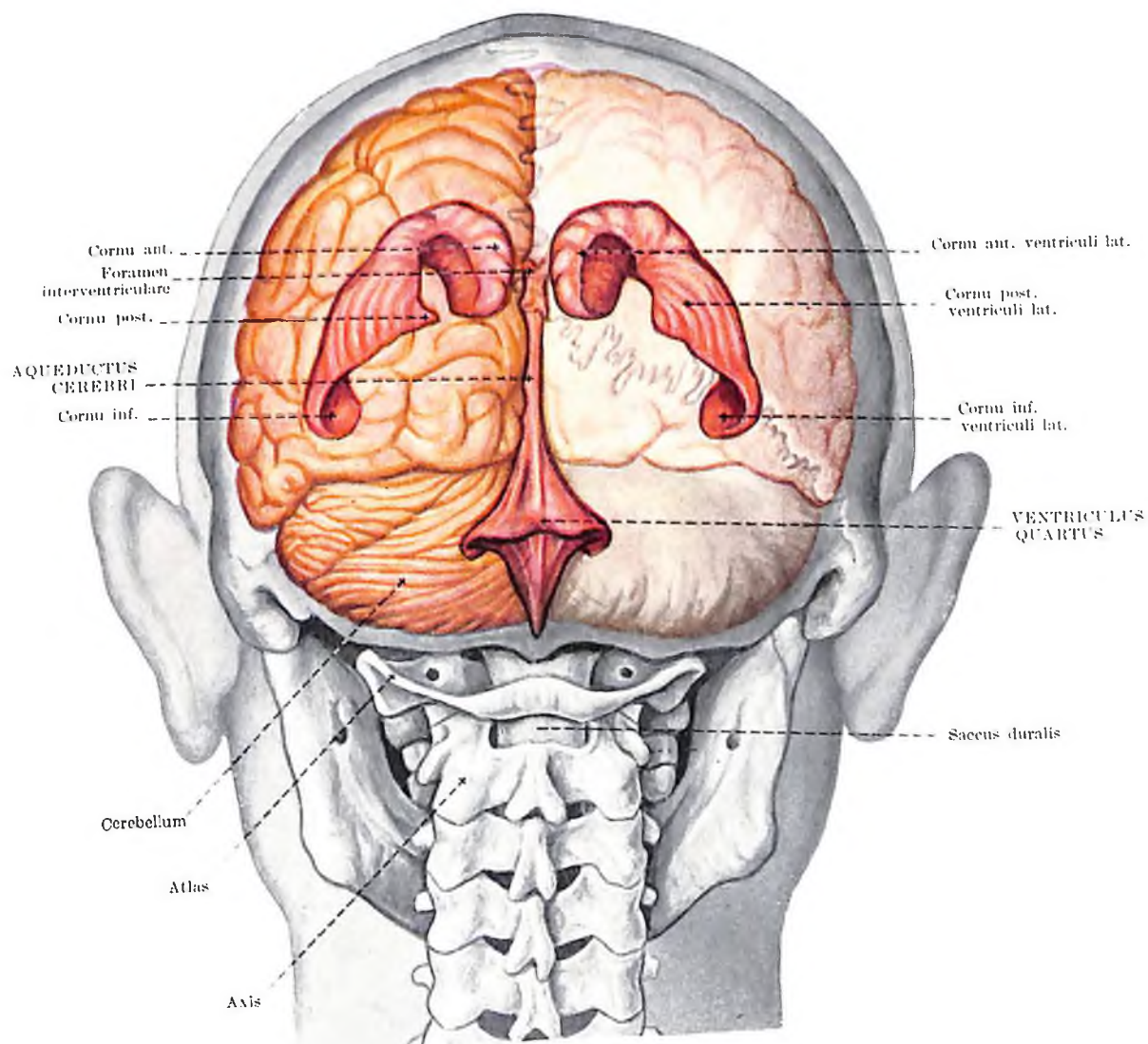


Fig. 70. TOPOGRAPHIA CRANIOCEREBRALIS IV.
(ventriculi cerebri, aspectus postero-anterior)

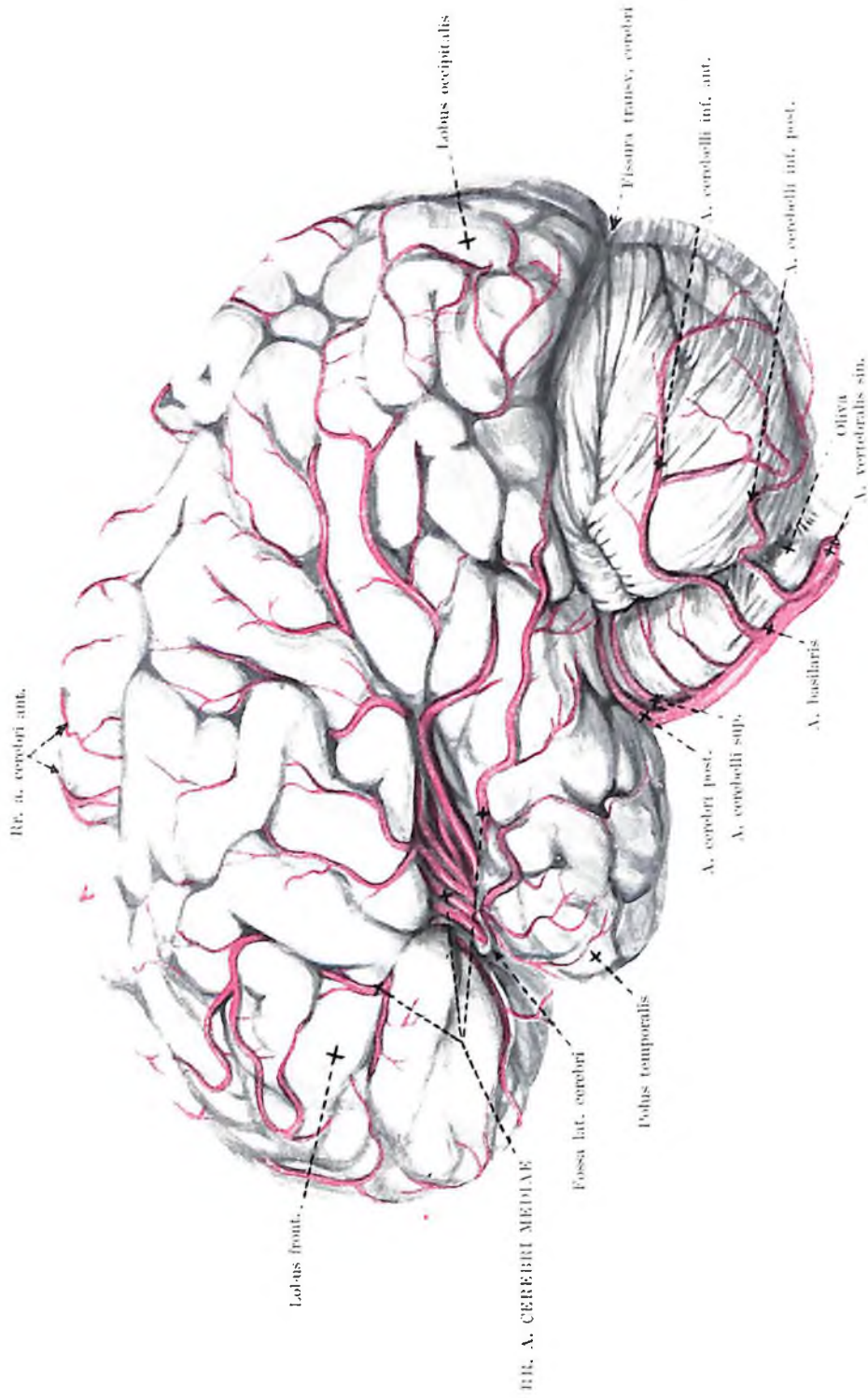


Fig. 71. ARTERIAE ENCEPHALI I.
(arteriae laterales cerebri)

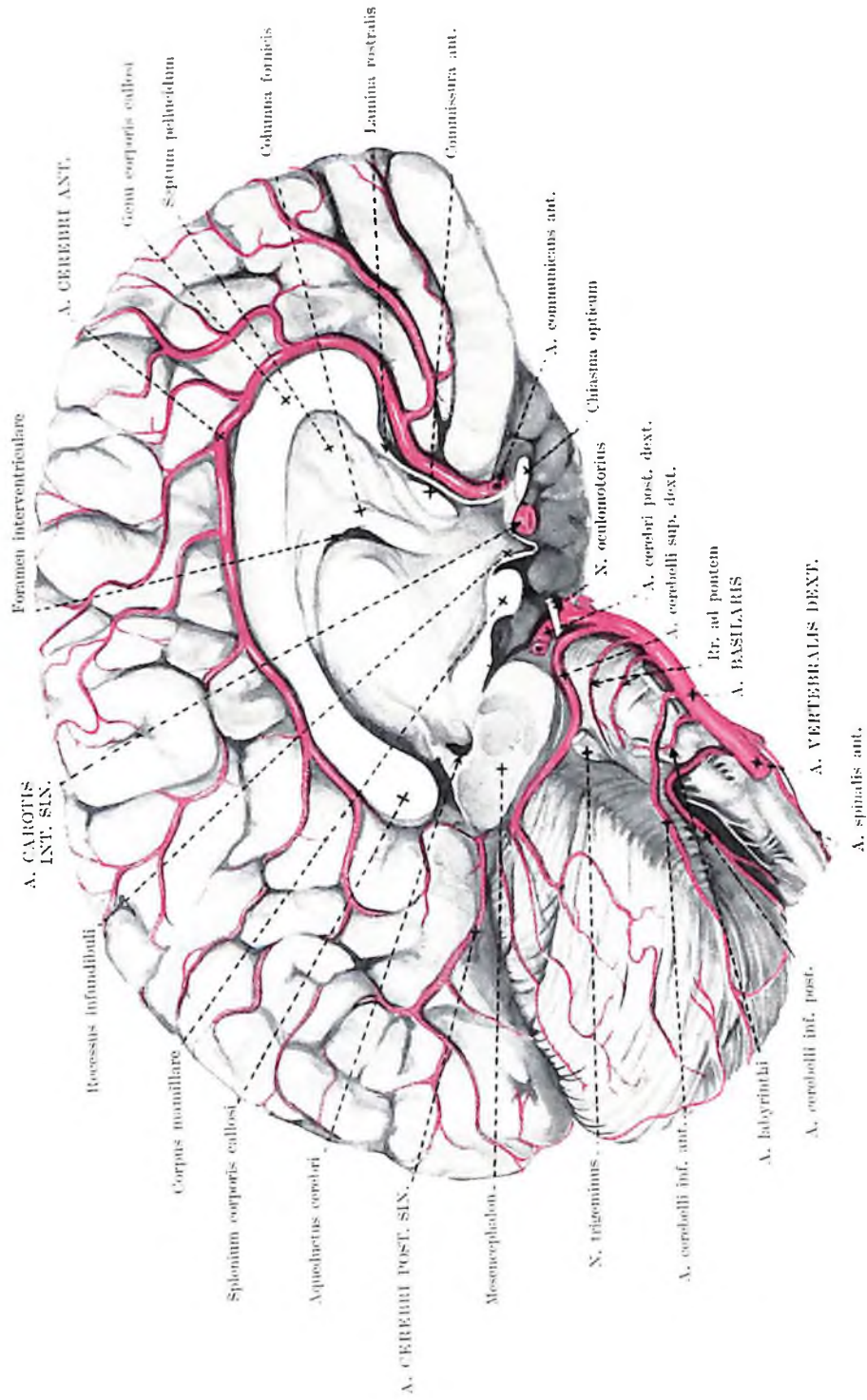


Fig. 72. ARTERIAE ENCEPHALI II.
(arteriae mediales cerebri)

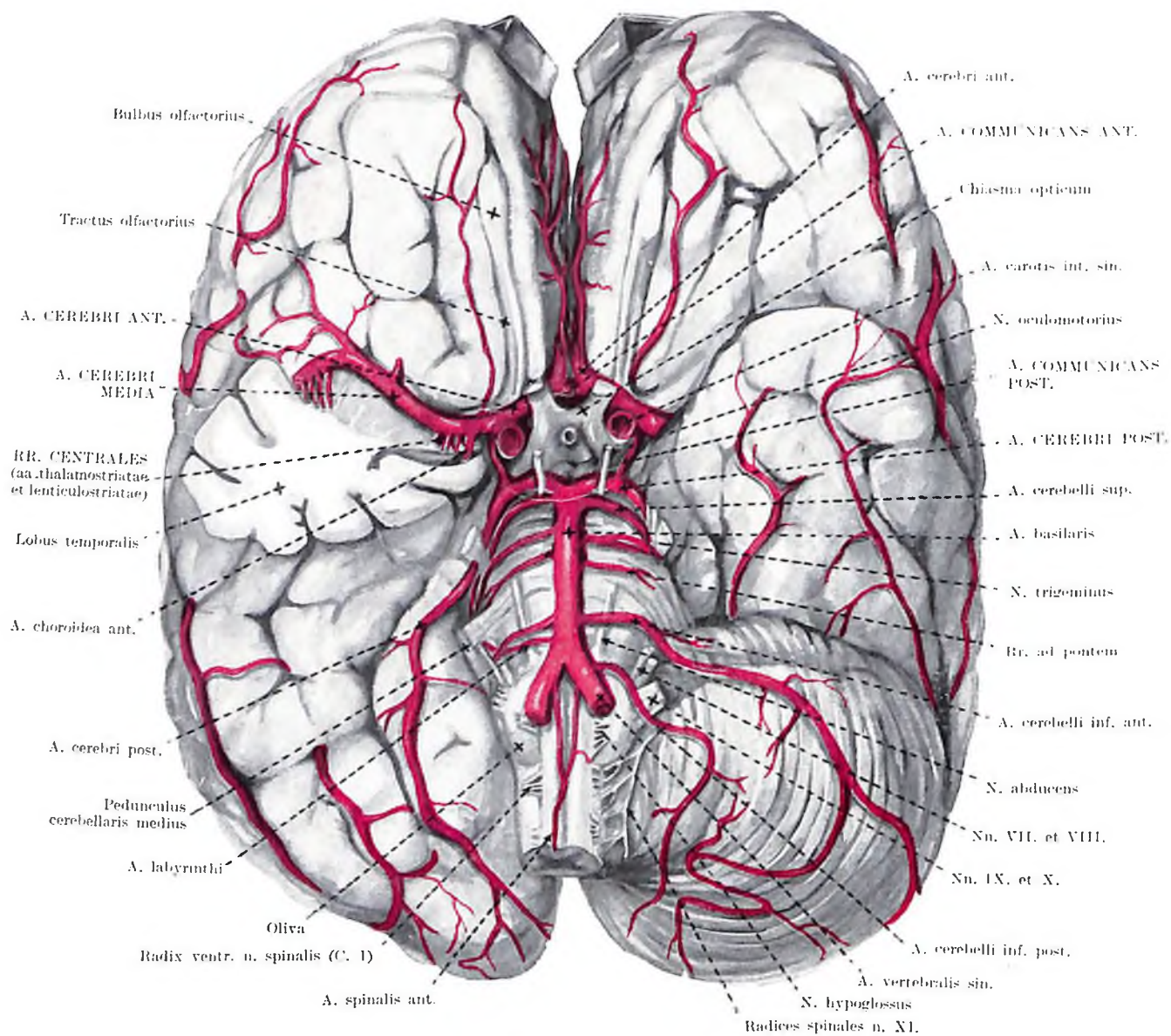


Fig. 73. ARTERIAE ENCEPHALI III.
(arteriae basales cerebri, circulus arteriosus)

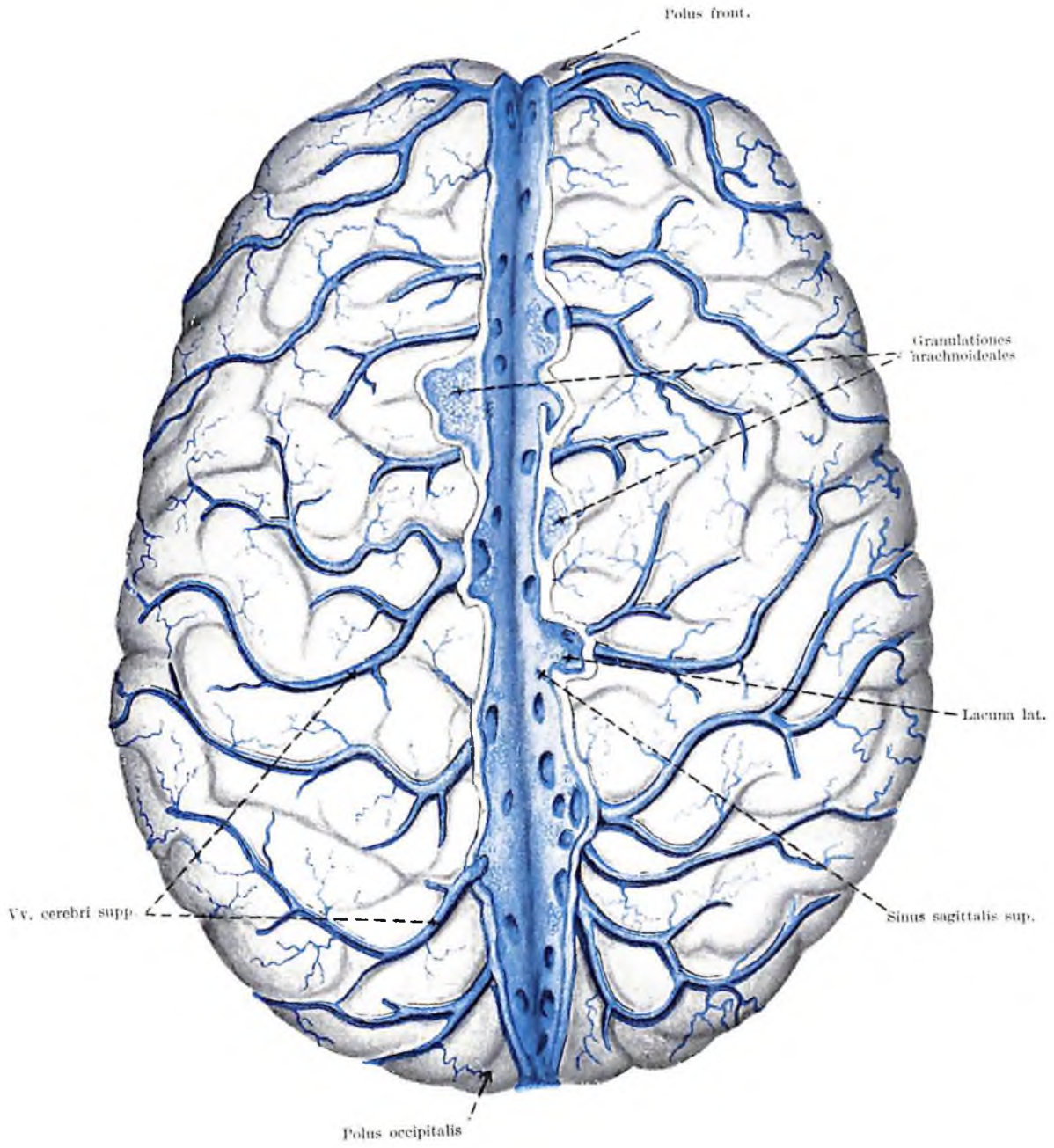


Fig. 74. SINUS DURAE MATRIS ET VENAE CEREBRI I.
(aspectus superior)

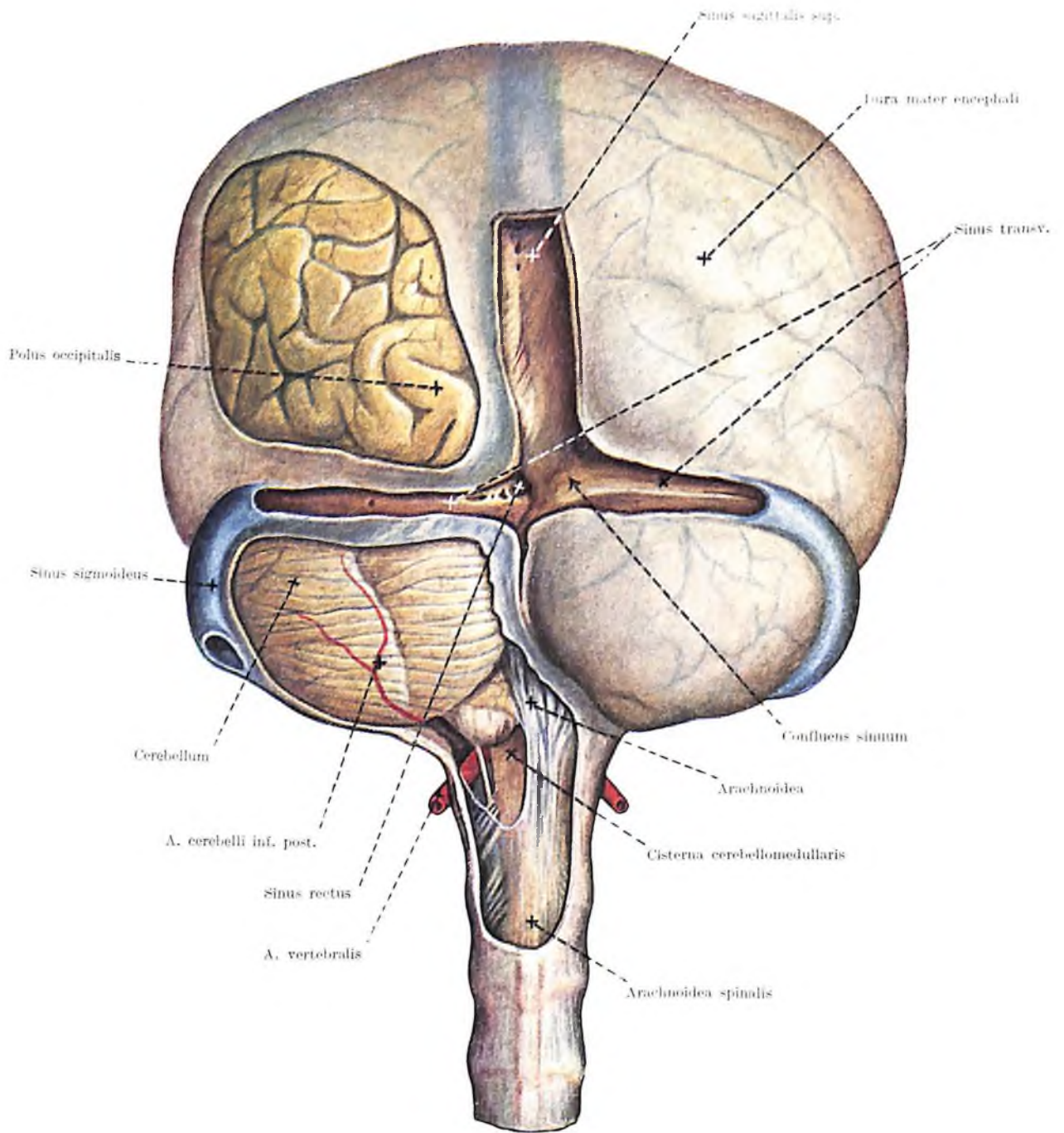


Fig. 75. DURA MATER ENCEPHALI ET SINUS DURAE MATRIS
(aspectus posterior)

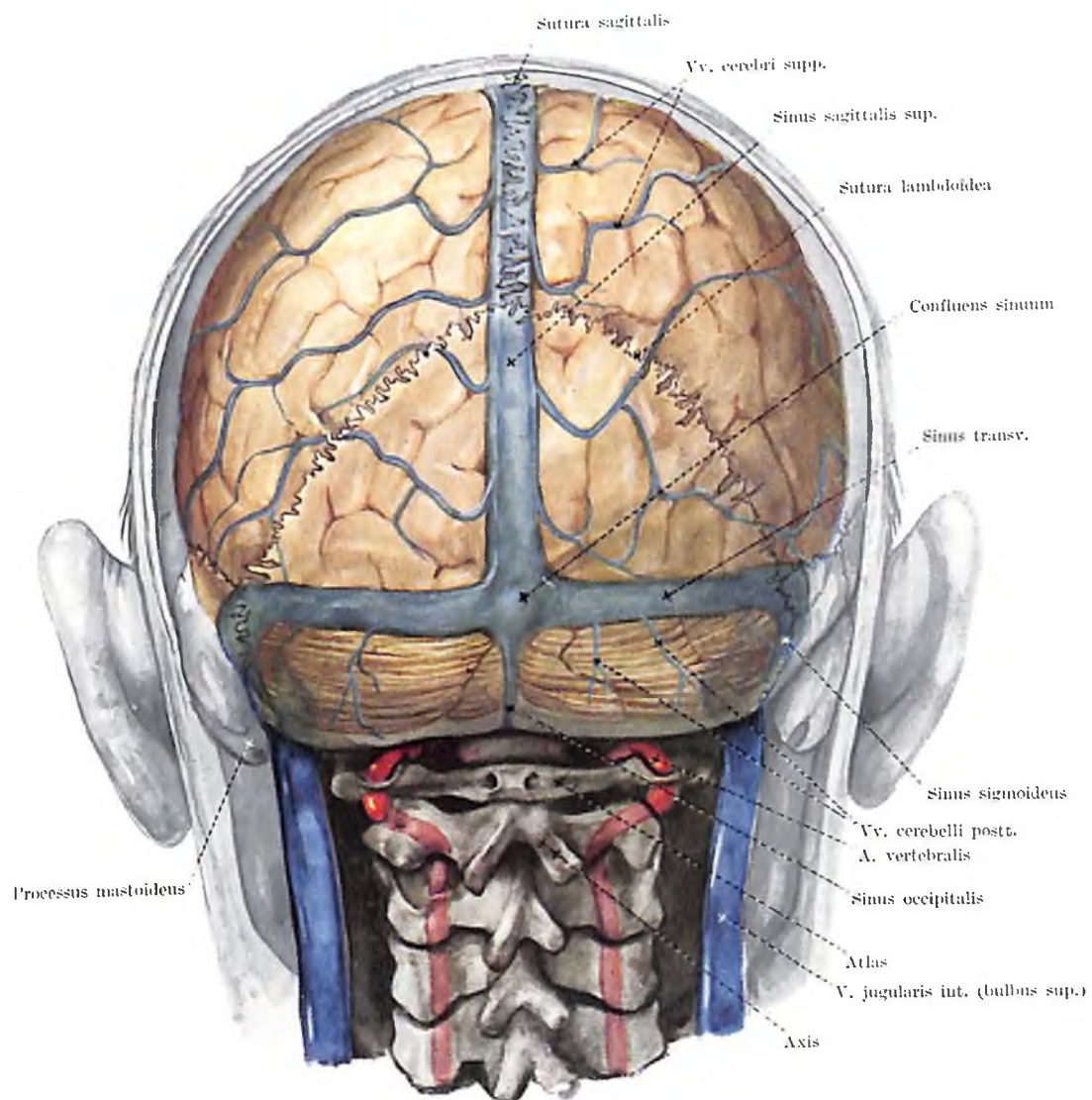


Fig. 76. SINUS DURAE MATRIS ET VENAE CEREBRI II.
(aspectus posterior)

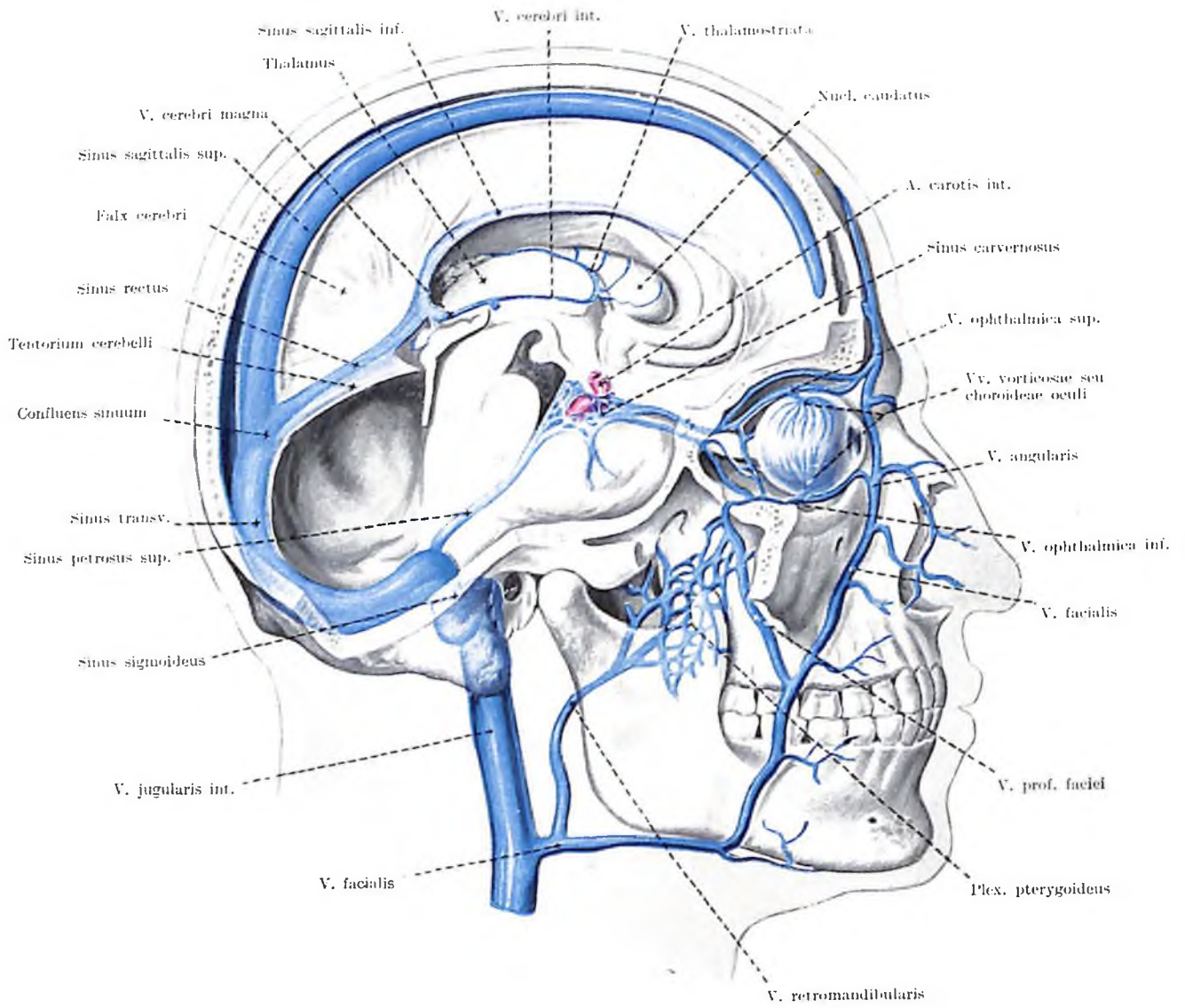


Fig. 77. SINUS DURAE MATRIS ET VENAE CAPITIS

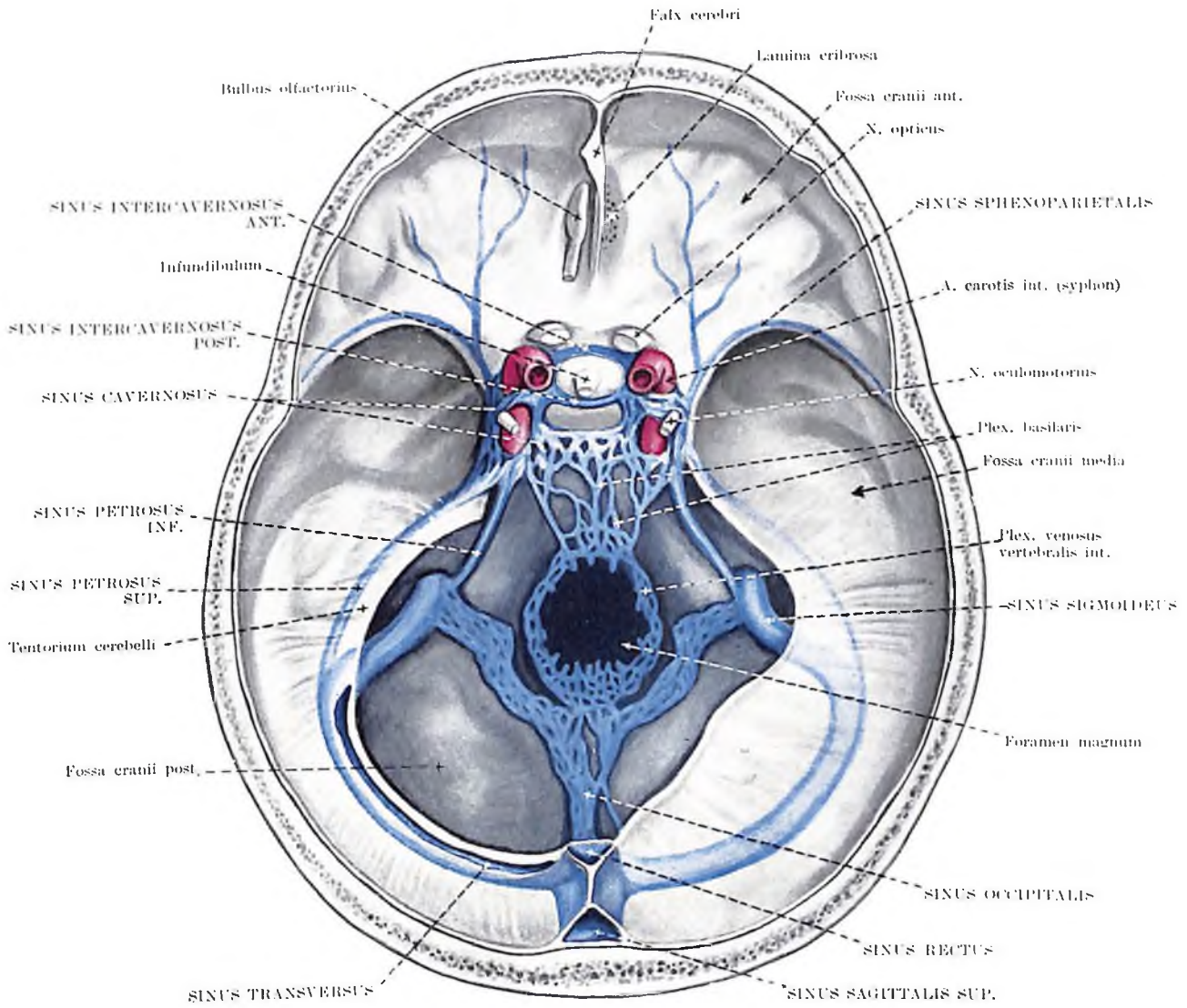


Fig. 78. SINUS VENOSI DURAE MATRIS BASEOS CRANII

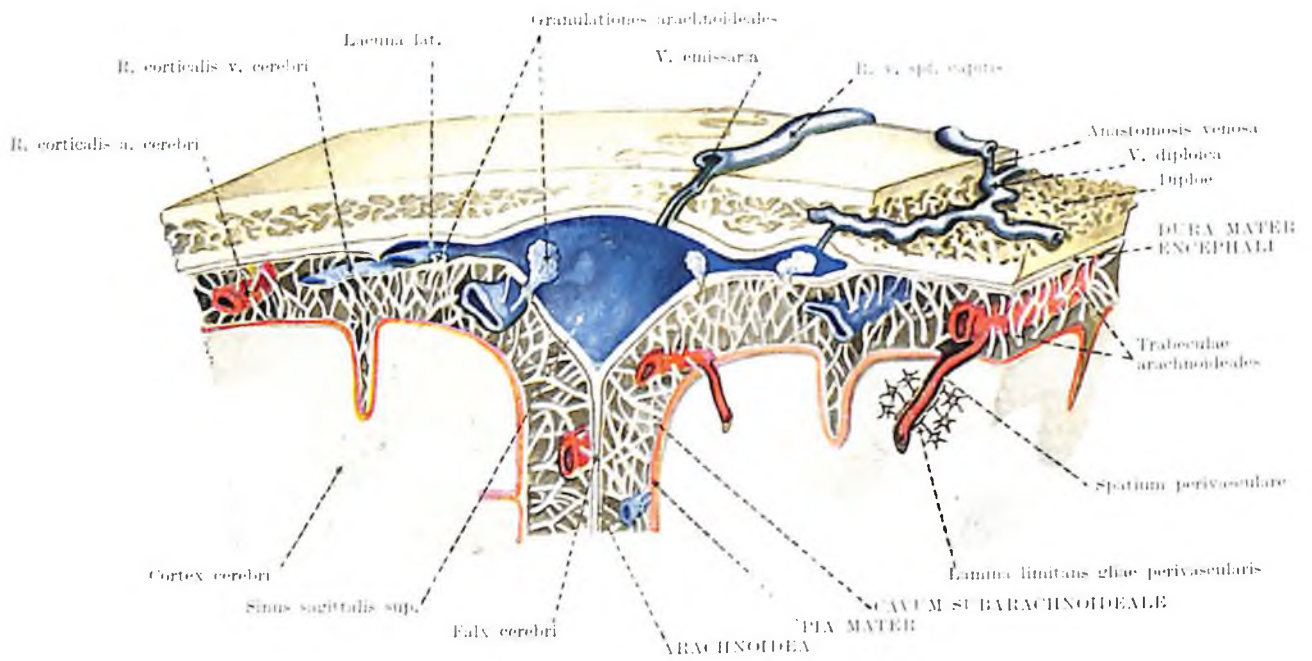


Fig. 79. SINUS VENOSI DURAE MATRIS, MENINGES, ARTERIAE ET VENAE CORTICALES ENCEPHALI (sinus sagittalis superior, sectio transversalis)

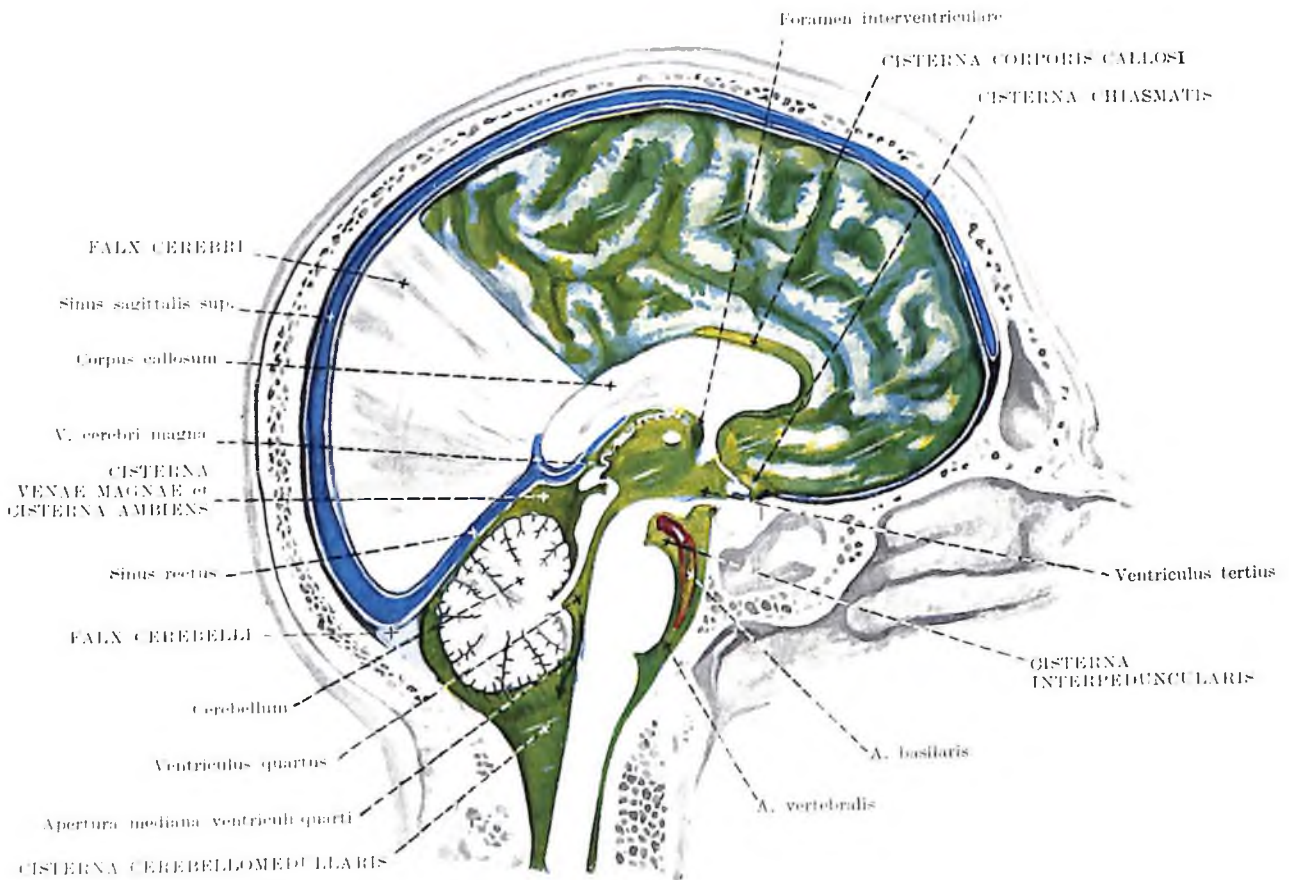


Fig. 80. MENINGES ENCEPHALI ET CISTERNAE SUBARACHNOIDEALES (sectio sagittalis paramediana)

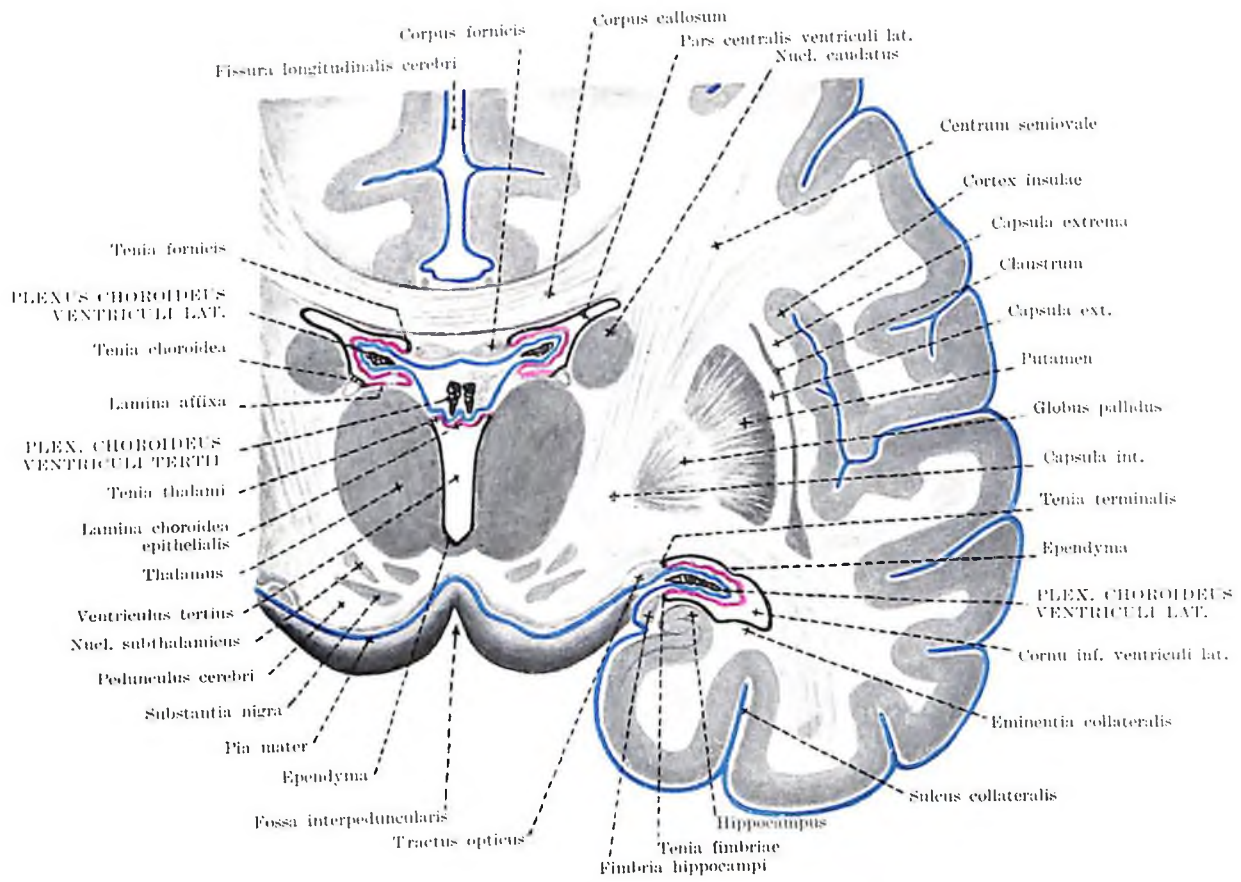


Fig. 51. PLEXUS CHOROIDEI
(tela choroidea, lamina epithelialis et teniae, sectio frontalis cerebri)

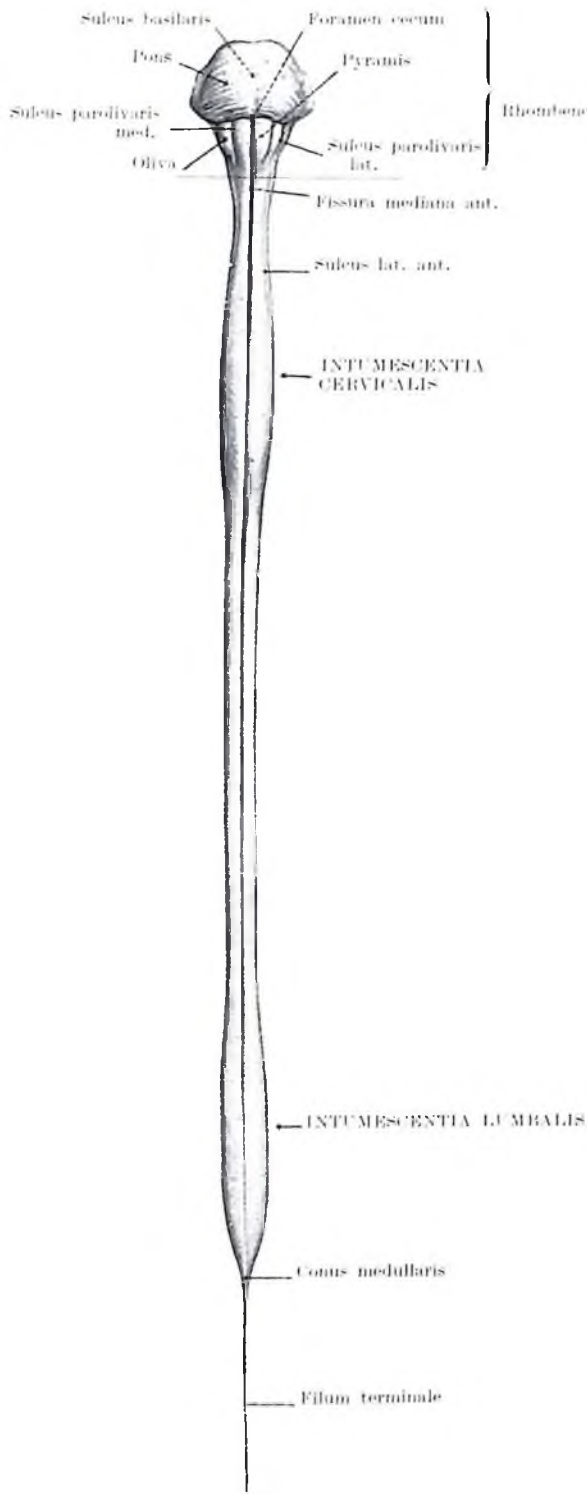


Fig. 82. MEDULLA SPINALIS
(aspectus anterior)

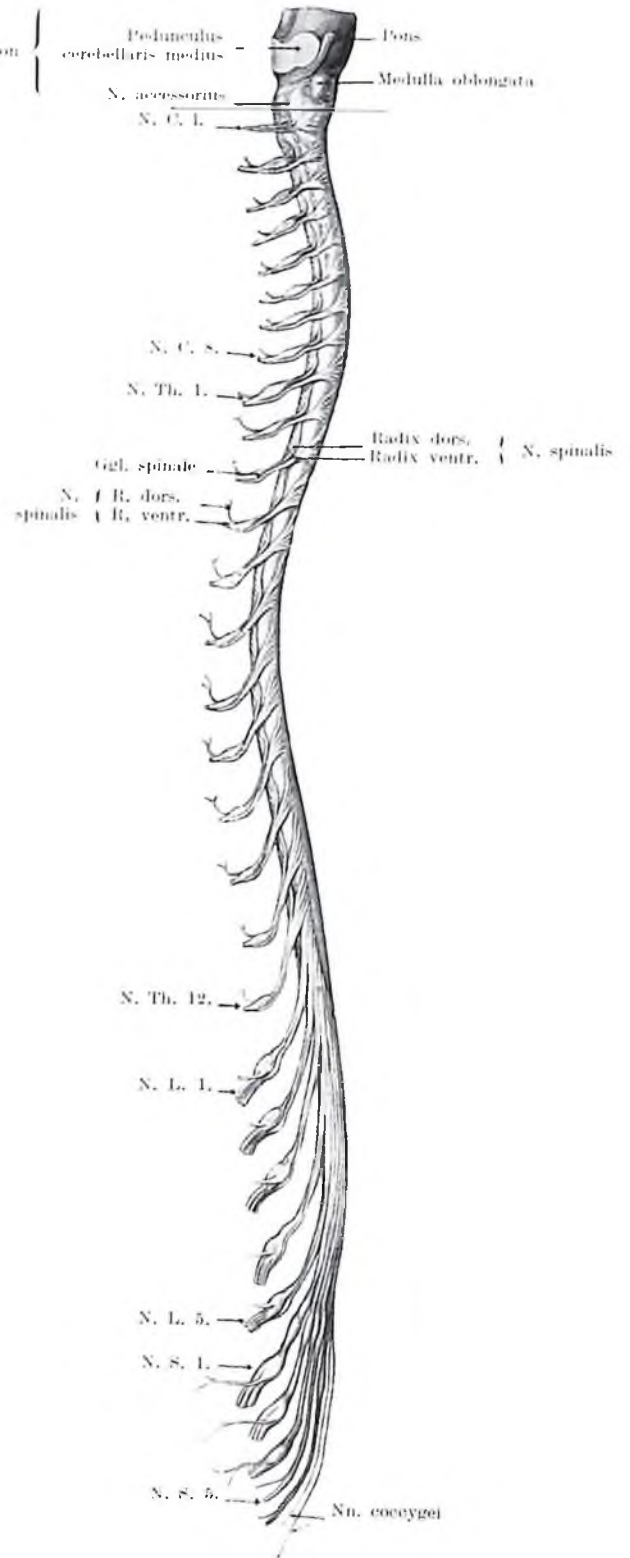


Fig. 83. MEDULLA SPINALIS ET NERV
SPINALES
(aspectus dexter)

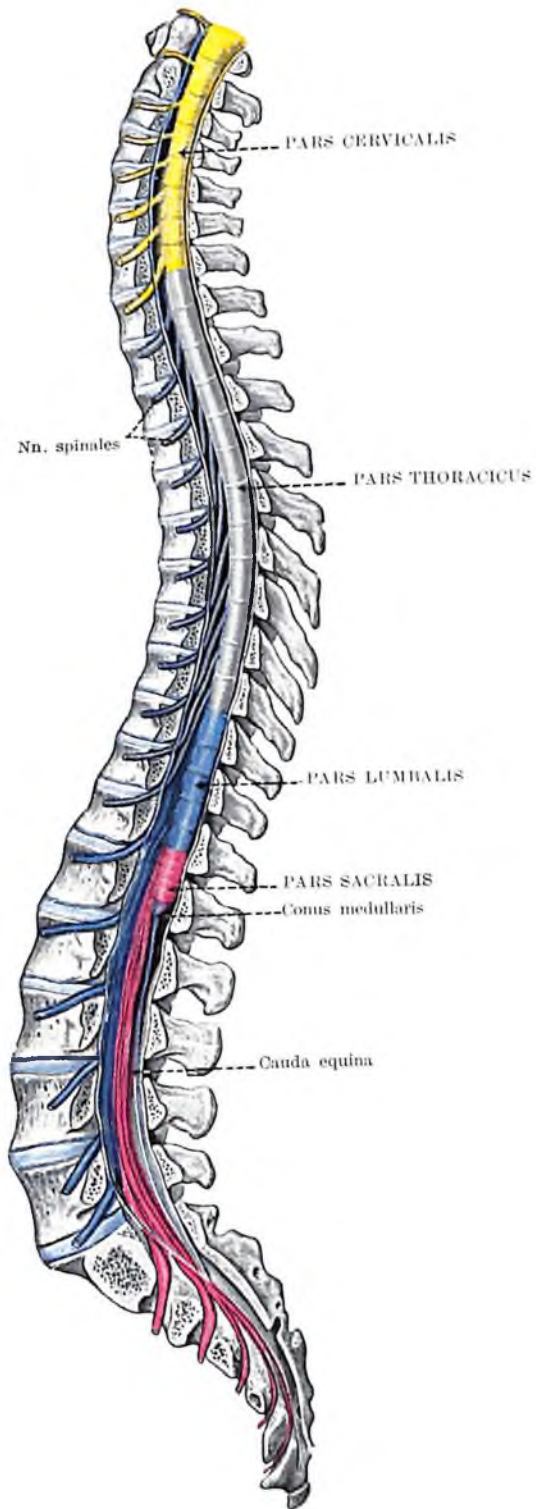


Fig. 84. MEDULLA SPINALIS IN SITU
(aspectus sinister)

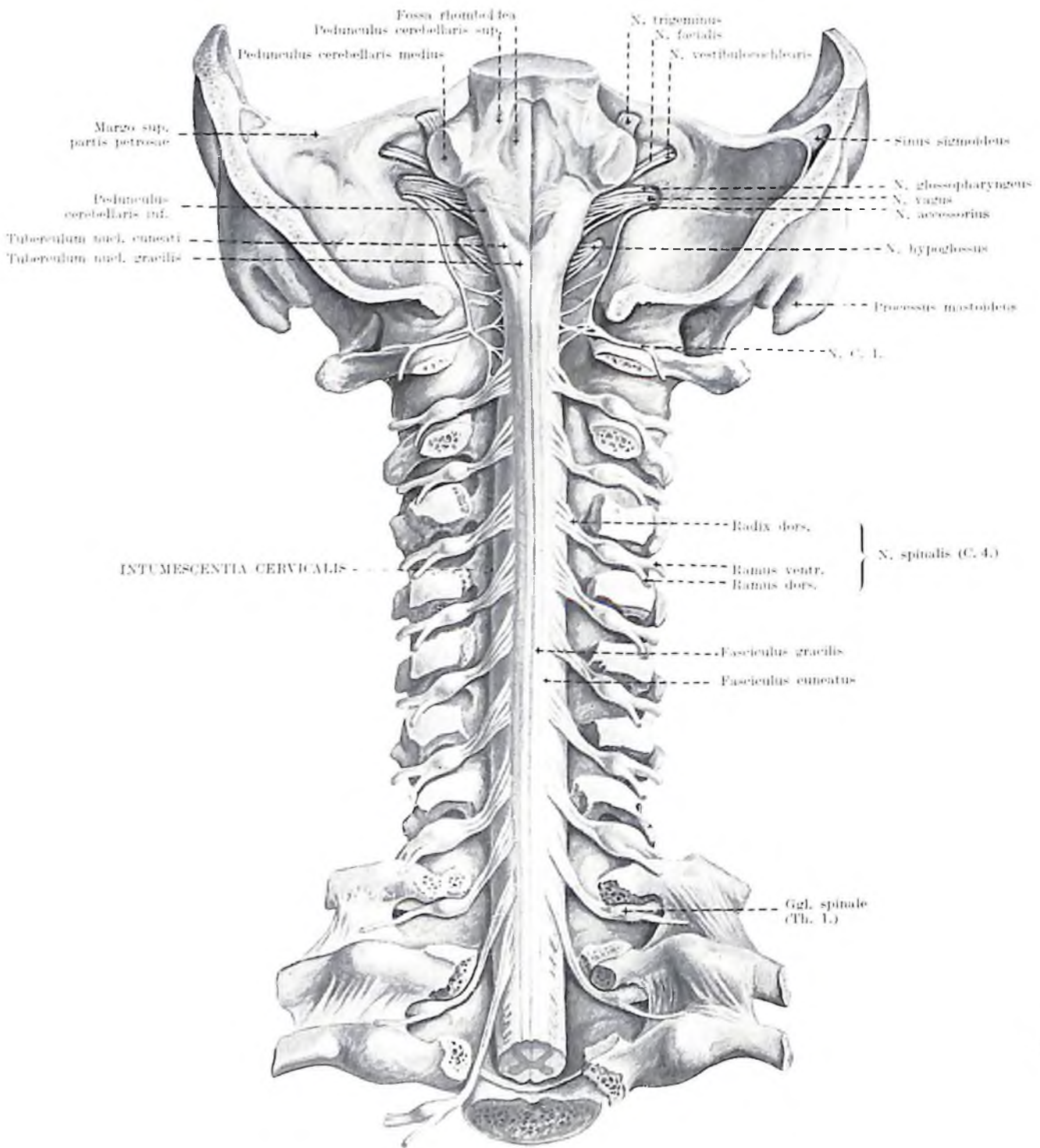


Fig. 85. PARS CERVICALIS MEDULLAE SPINALIS
(canalis vertebralis et dura mater spinalis apertae, aspectus posterior)

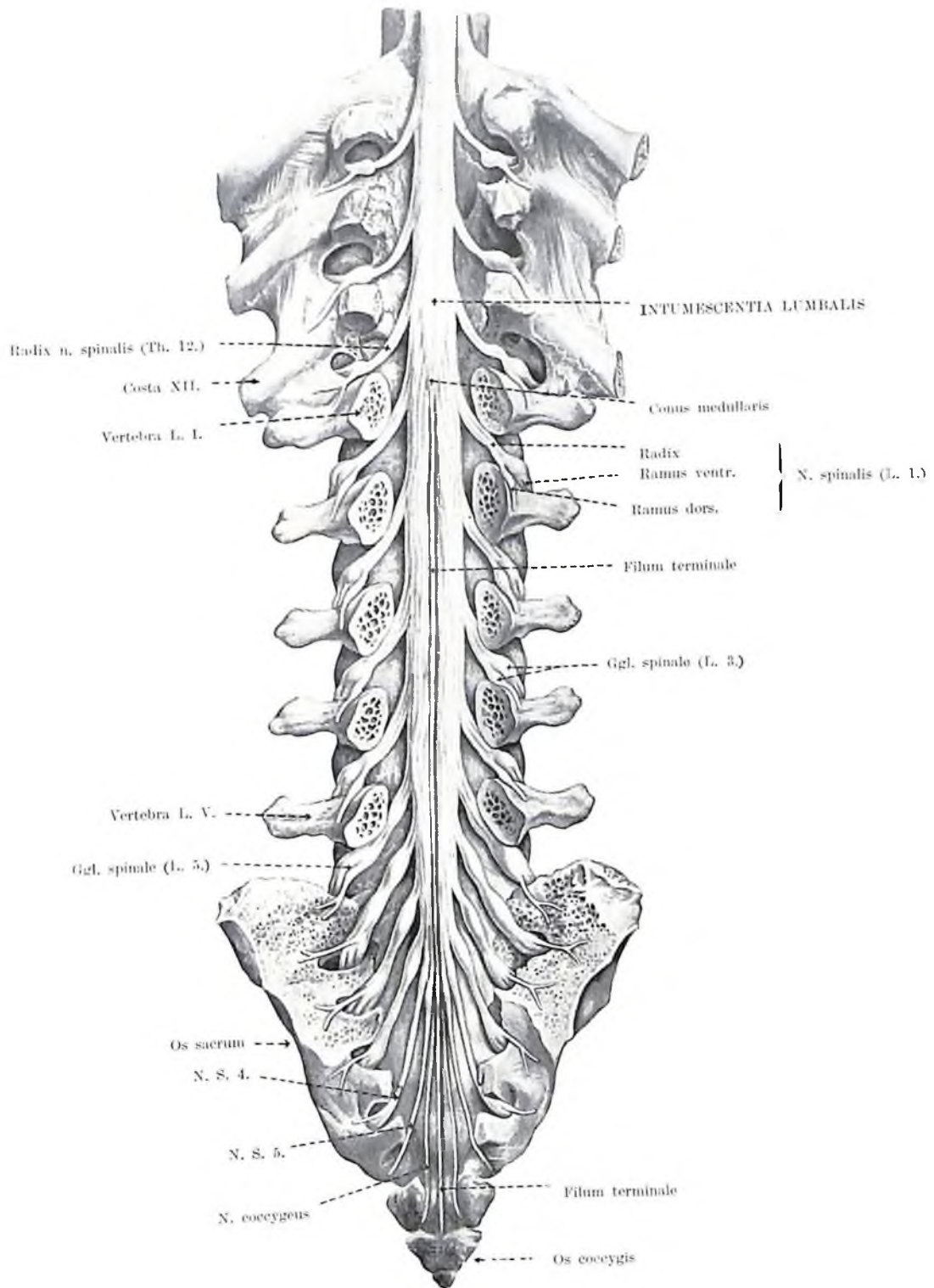


Fig. 86. PARS LUMBALIS MEDULLAE SPINALIS ET CAUDA EQUINA
 (canalis vertebralis et dura mater spinalis apertae, aspectus posterior)

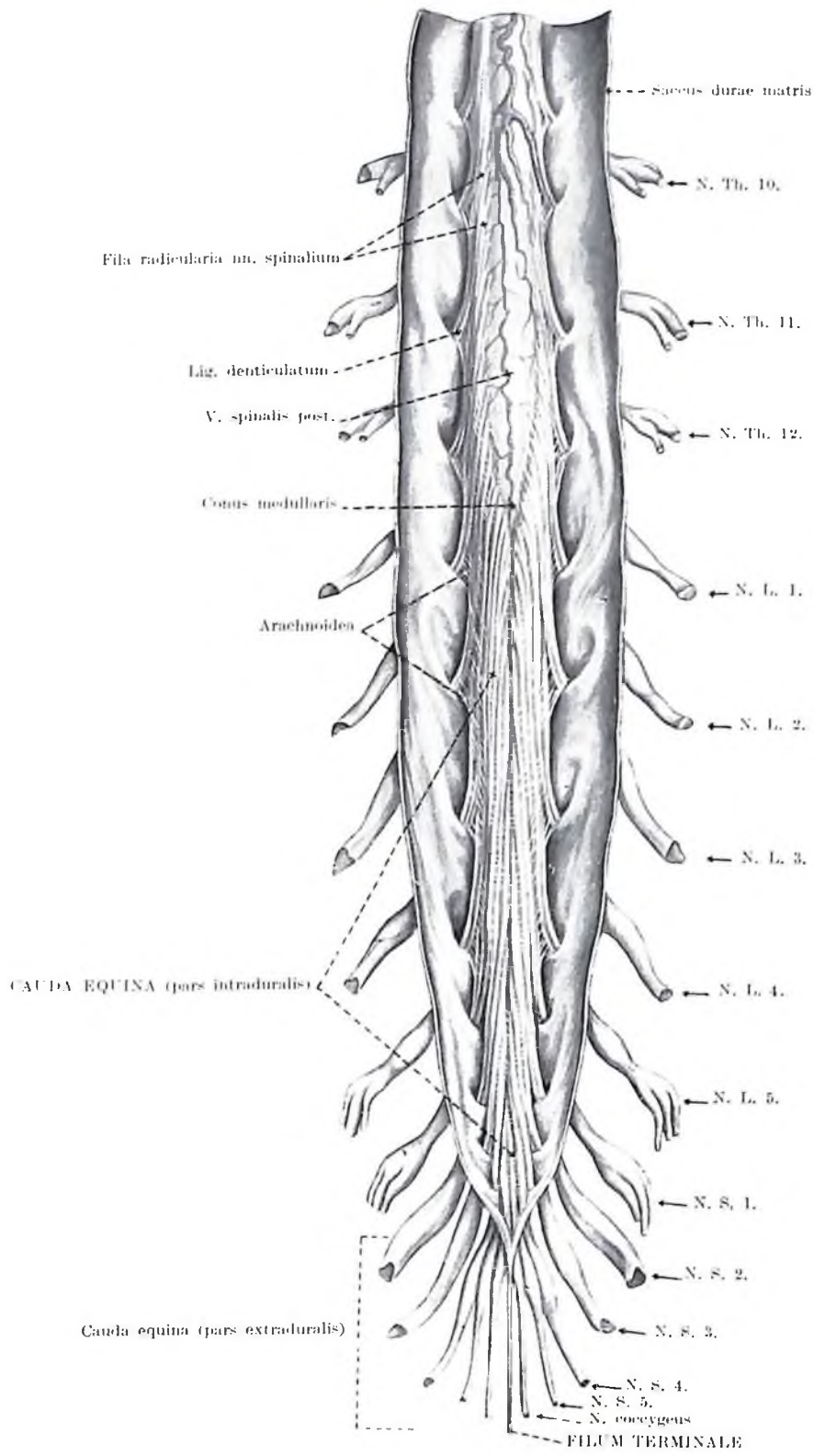


Fig. 87. CAUDA EQUINA ET SACCUS DURAE MATRIS
(dura mater spinalis aperta, aspectus posterior)

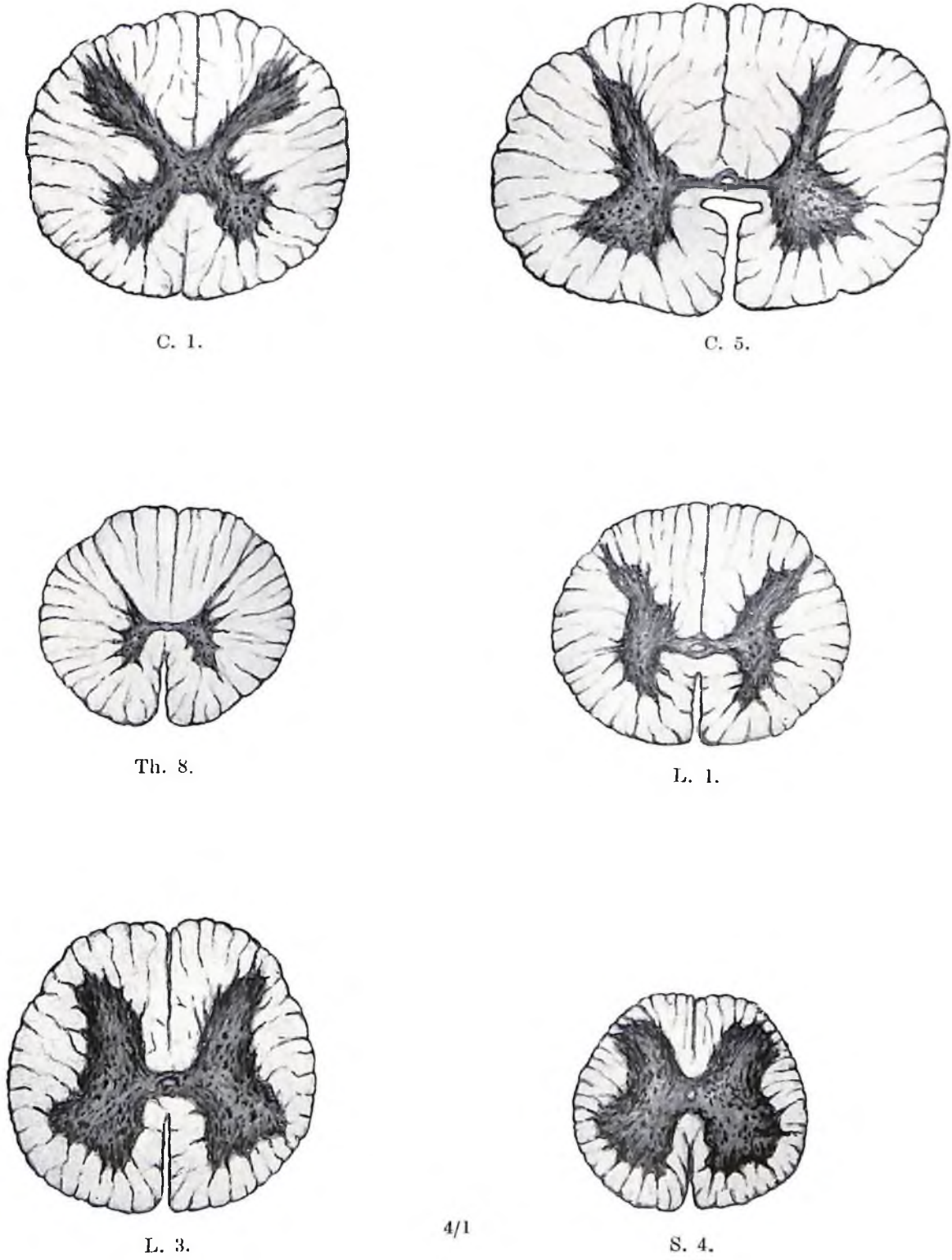


Fig. 88. SECTIONES TRANSVERSAE MEDULLAE SPINALIS
(segmenta medullae spinalis)

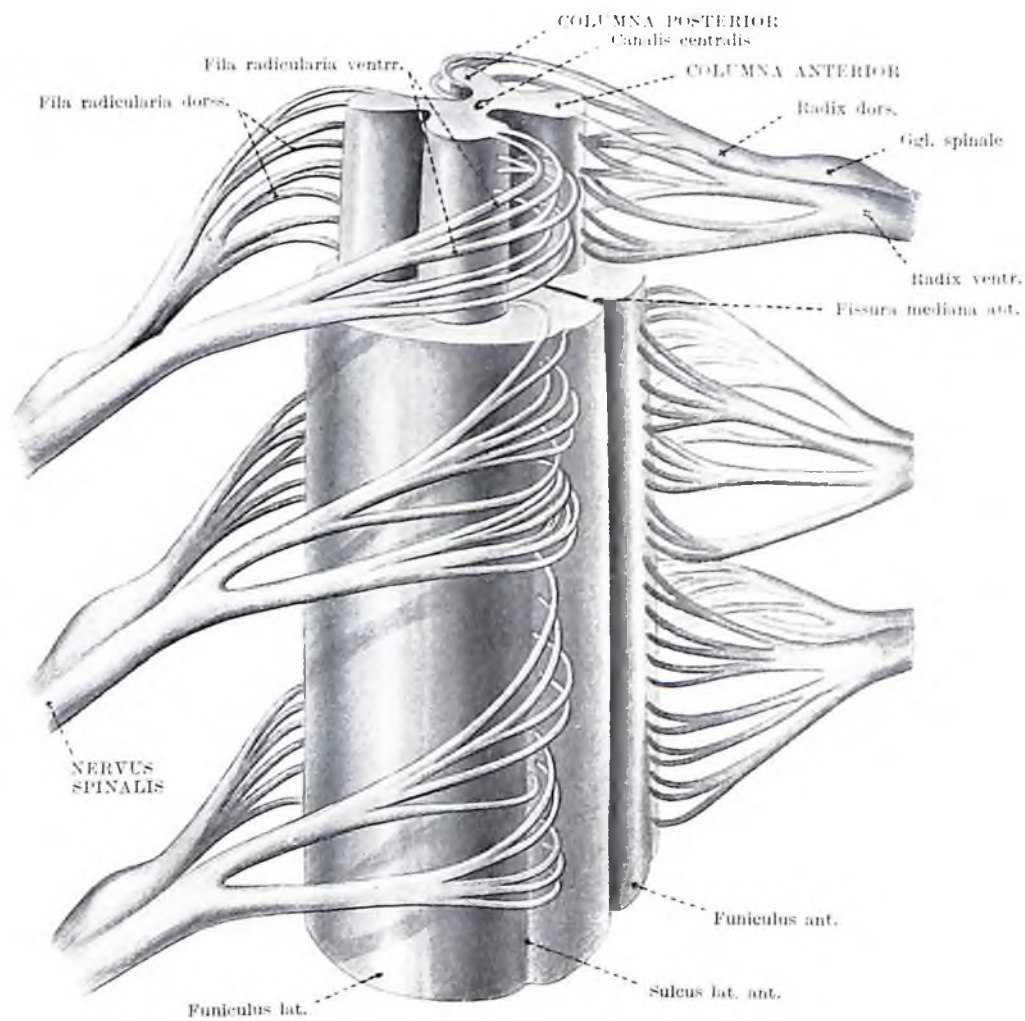


Fig. 89. STRUCTURA MEDULLAE SPINALIS ET NERVI SPINALIS

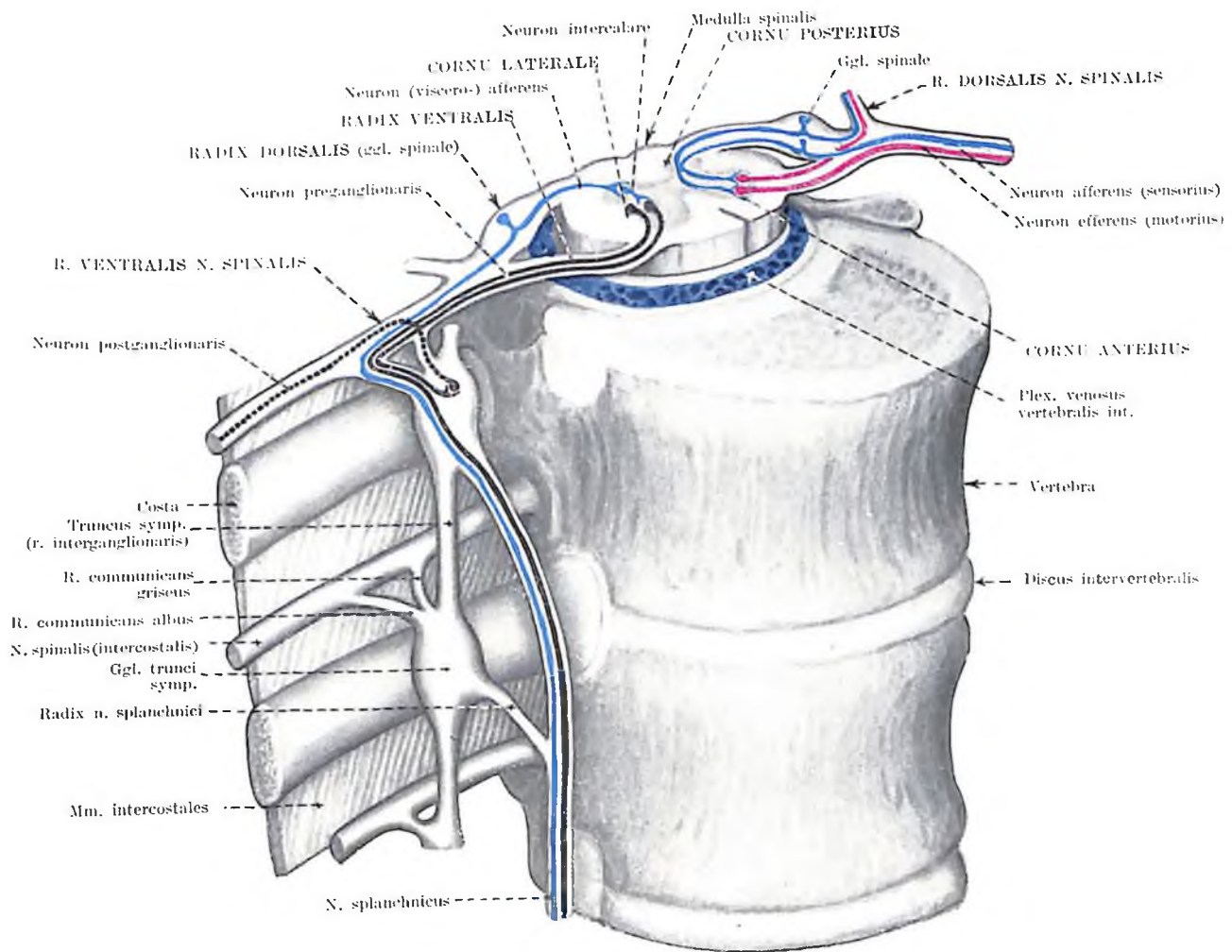


Fig. 90. STRUCTURA MEDULLAE SPINALIS ET NERVORUM PERIPHERIALIUM

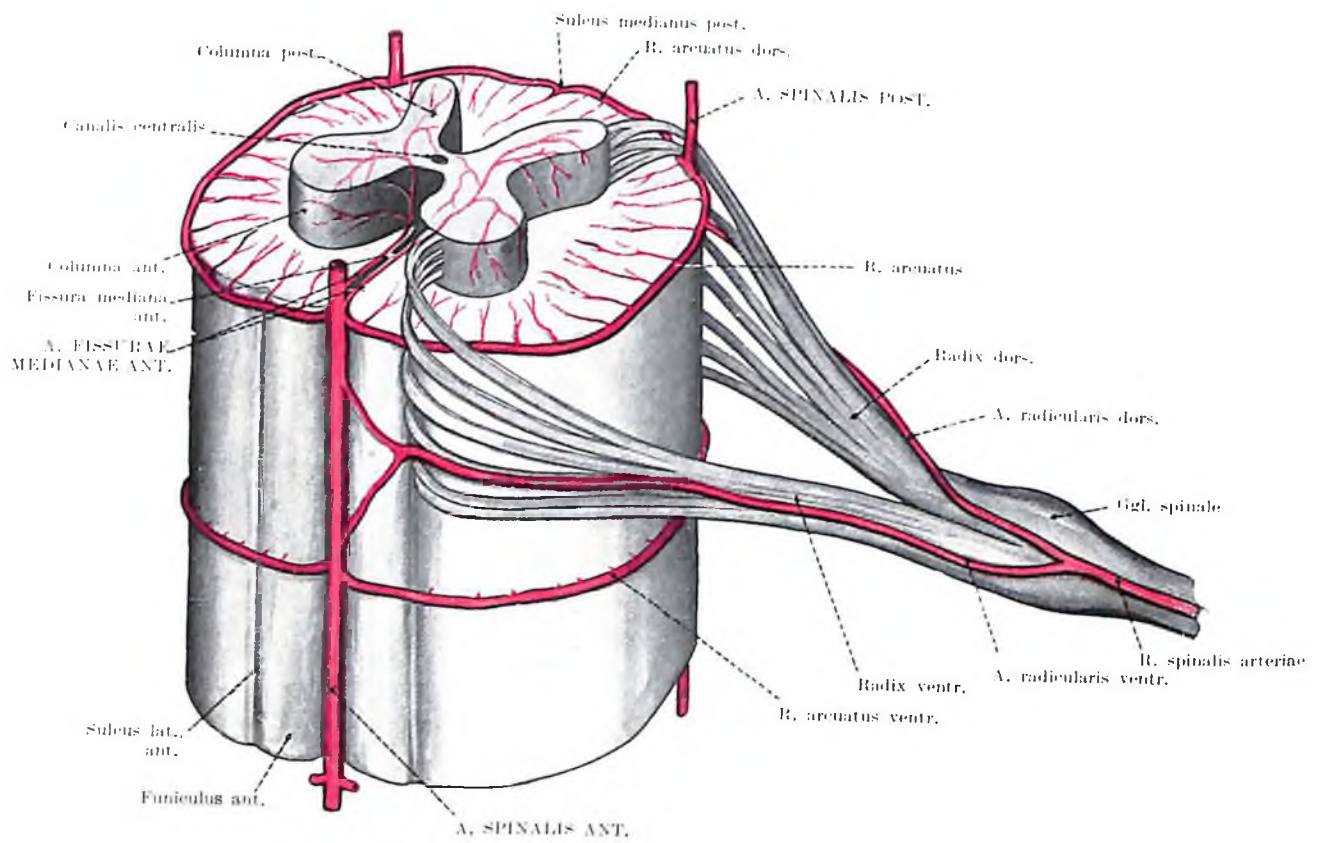


Fig. 91. ARTERIAE MEDULLAE SPINALIS

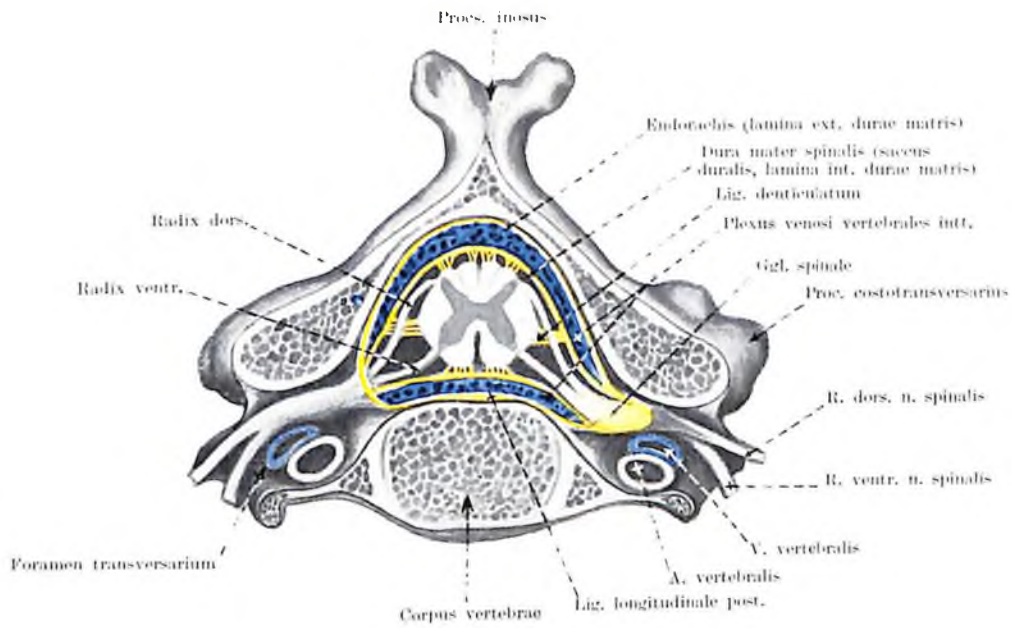


Fig. 92. PLEXUS VENOSI VERTEBRALES I.
(sectio transversa partis cervicalis columnae vertebralis)

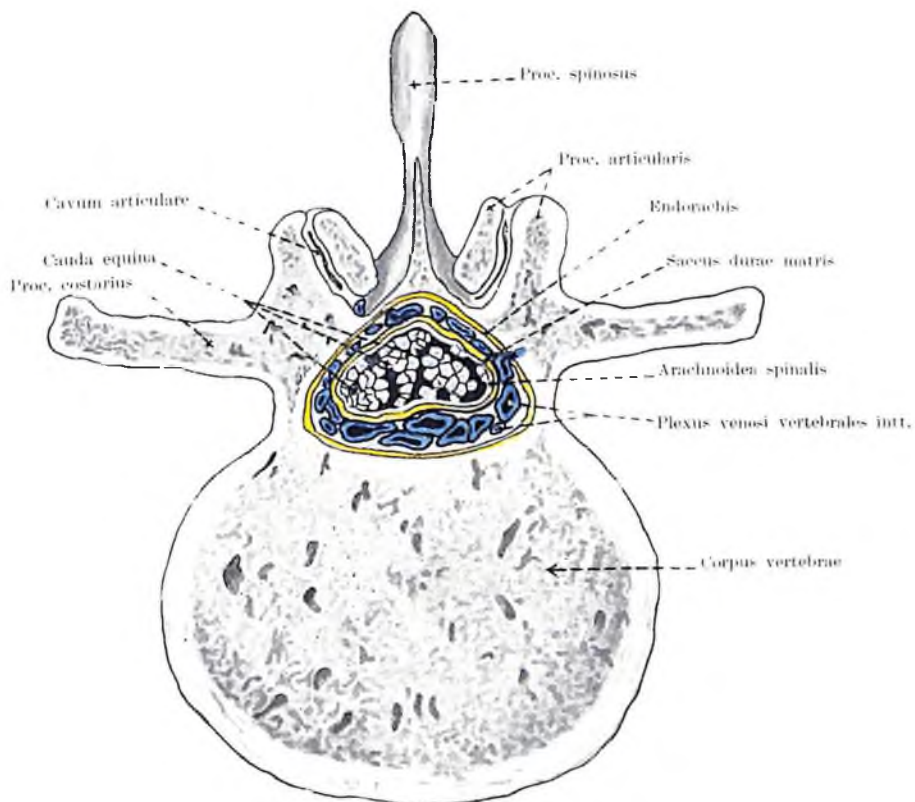


Fig. 93. PLEXUS VENOSI VERTEBRALES II.
(sectio transversa partis lumbalis columnae vertebralis)

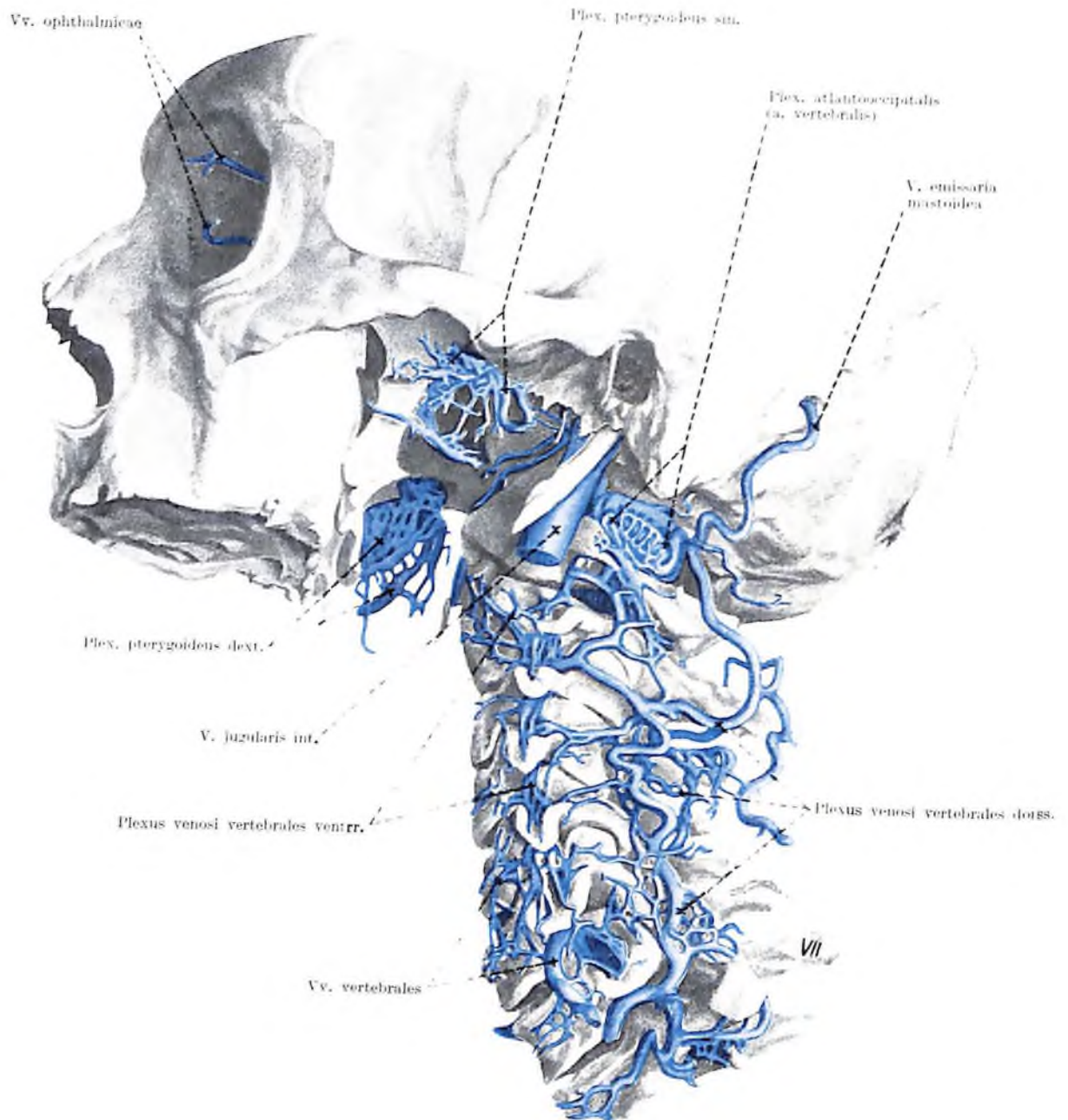


Fig. 94. PLEXUS VENOSI VERTEBRALES ET CAPITIS
(preparatum corrosum fecerunt G. Szikla et B. Zolnai)

SYSTEMA NERVOSUM PERIPHERICUM
ANGIOLOGIA

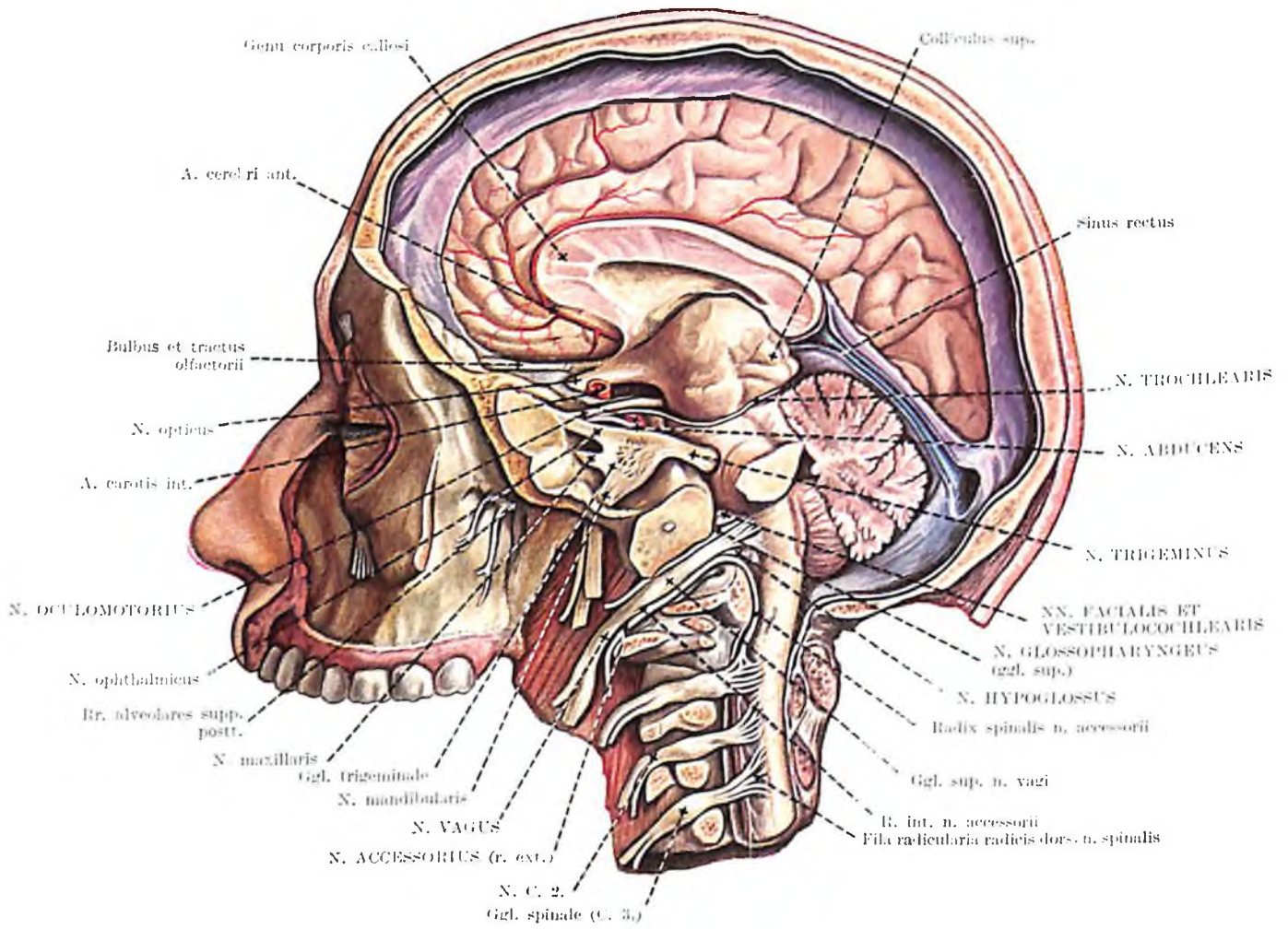
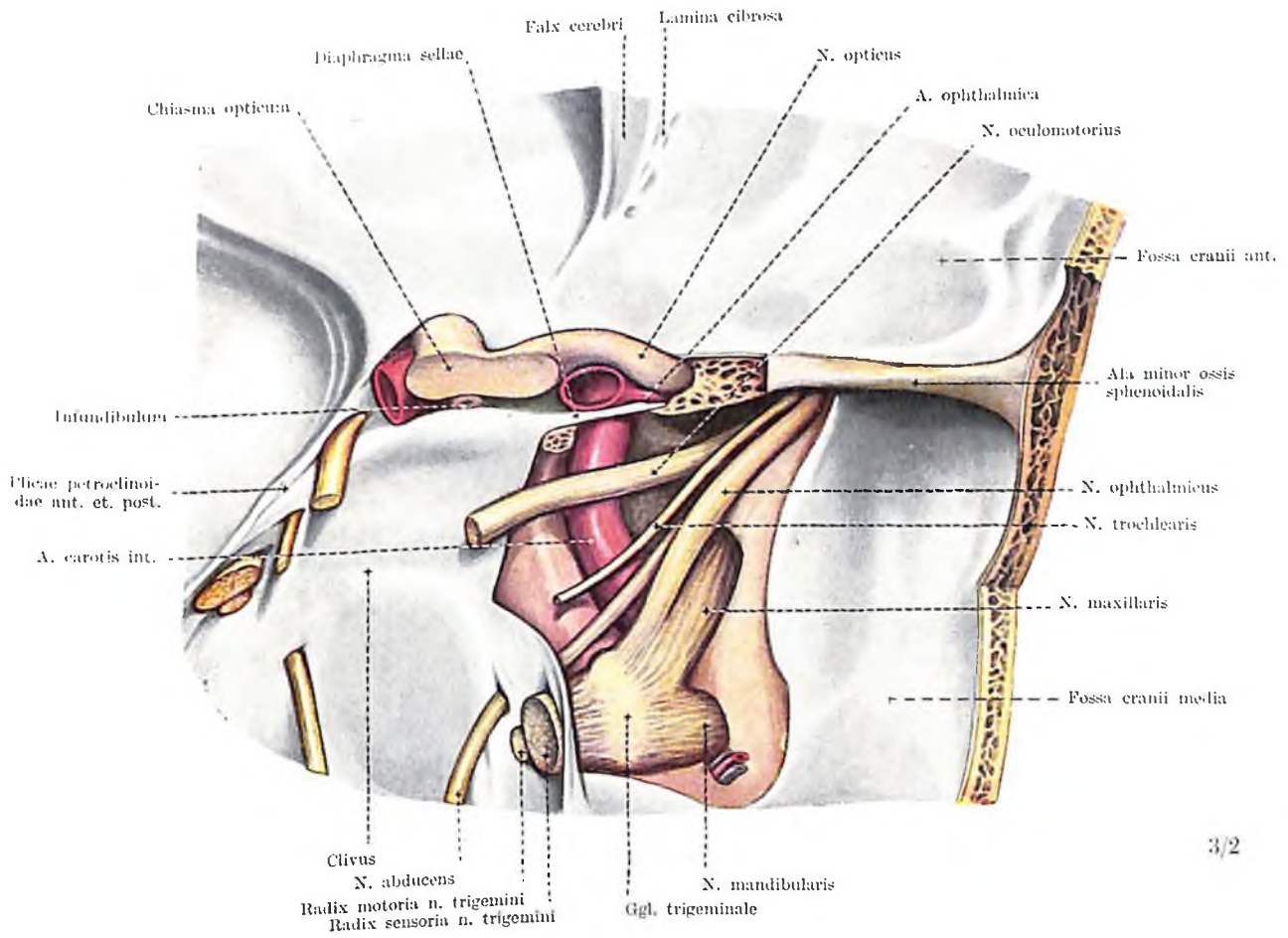
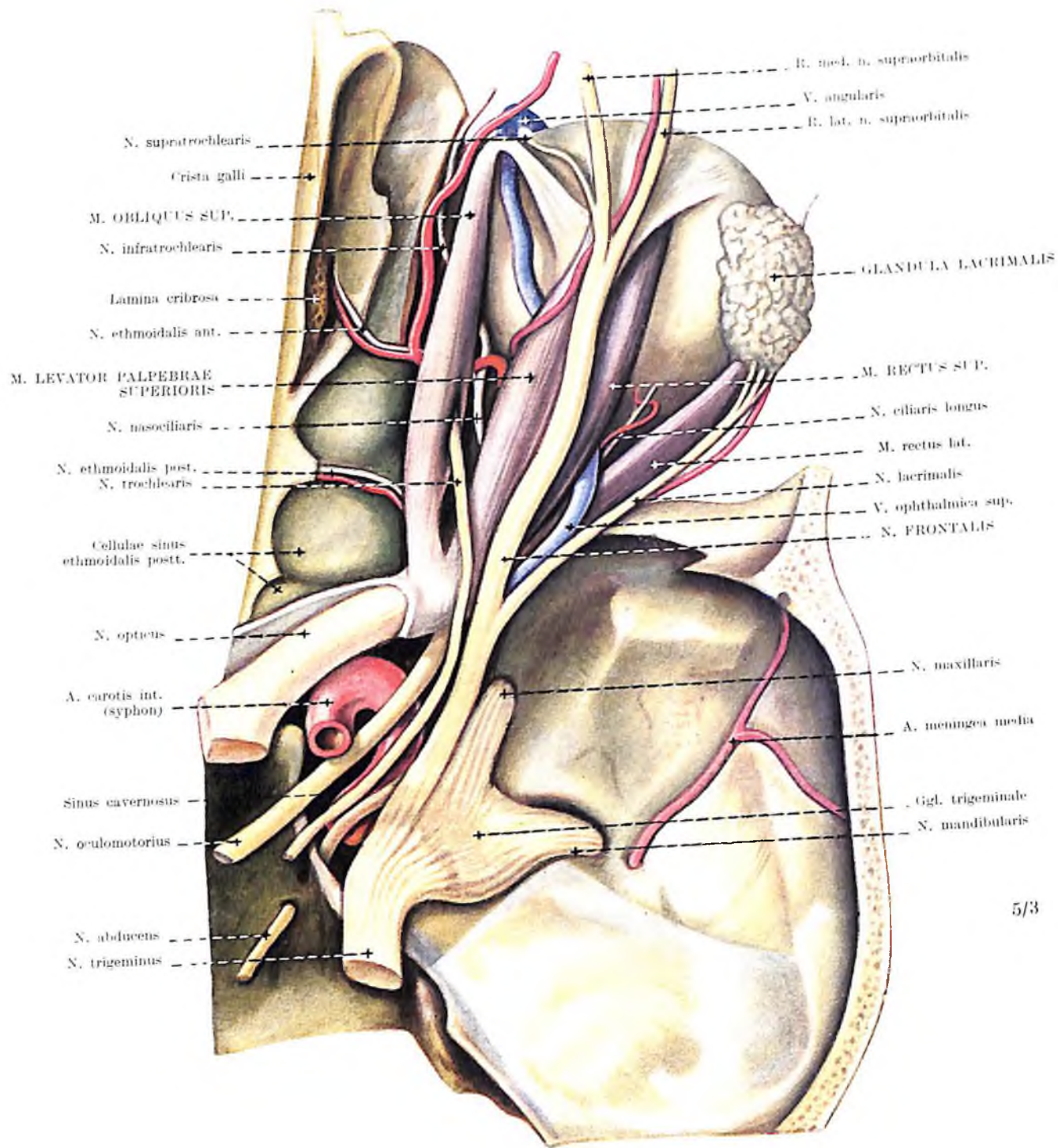


Fig. 96. NERVI CRANIALES
(situs intracranialis)



3/2

Fig. 97. NERVI CRANIALES ET DURA MATER
 (aspectus postero-supero-lateralis, sinus cavernosus dexter apertus)



5/3

Fig. 98. ORBITA I.
(stratum superficiale, aspectus superior)

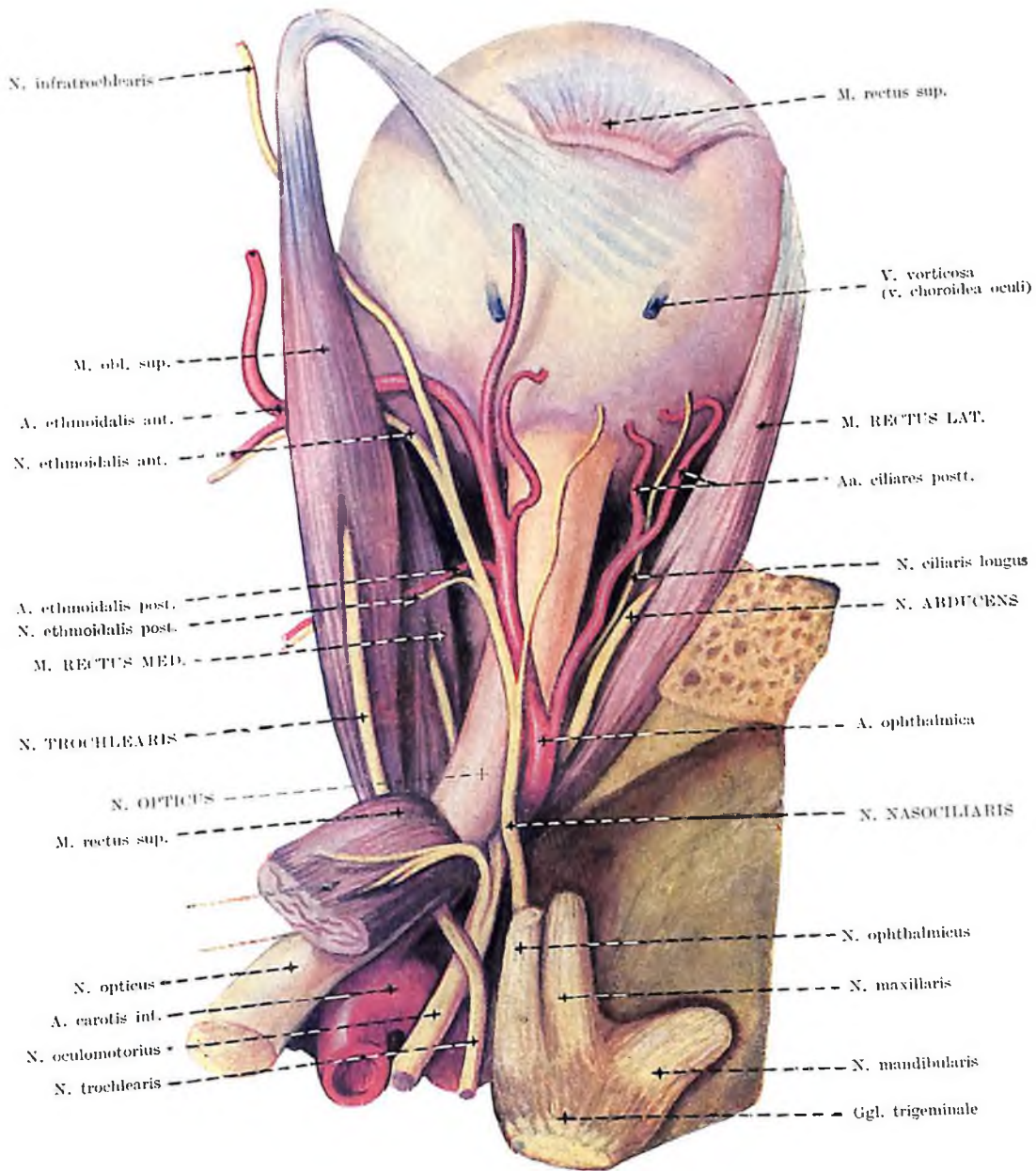


Fig. 99. ORBITA II.
(stratum medium, aspectus superior)

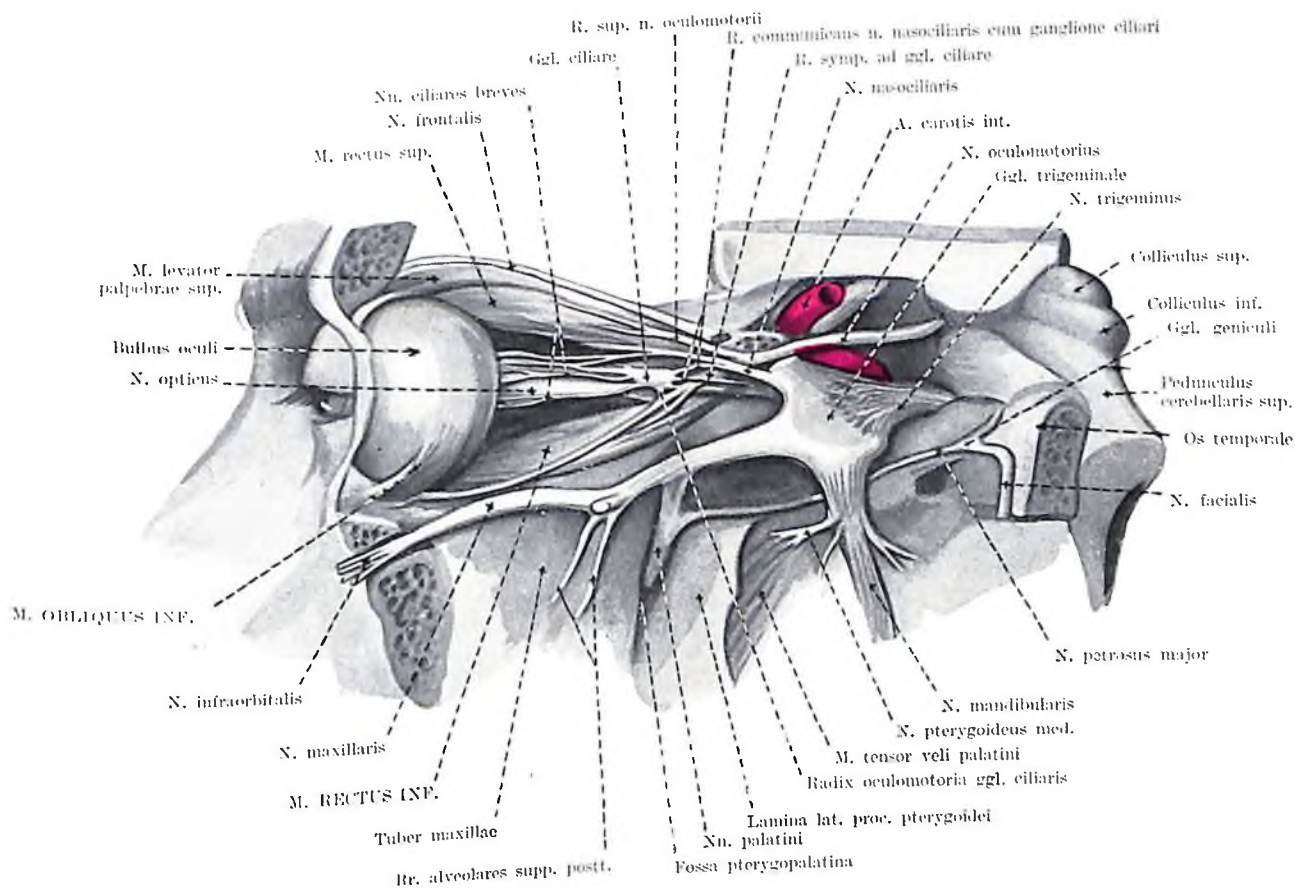


Fig. 101. ORBITA IV.
(aspectus lateralis)

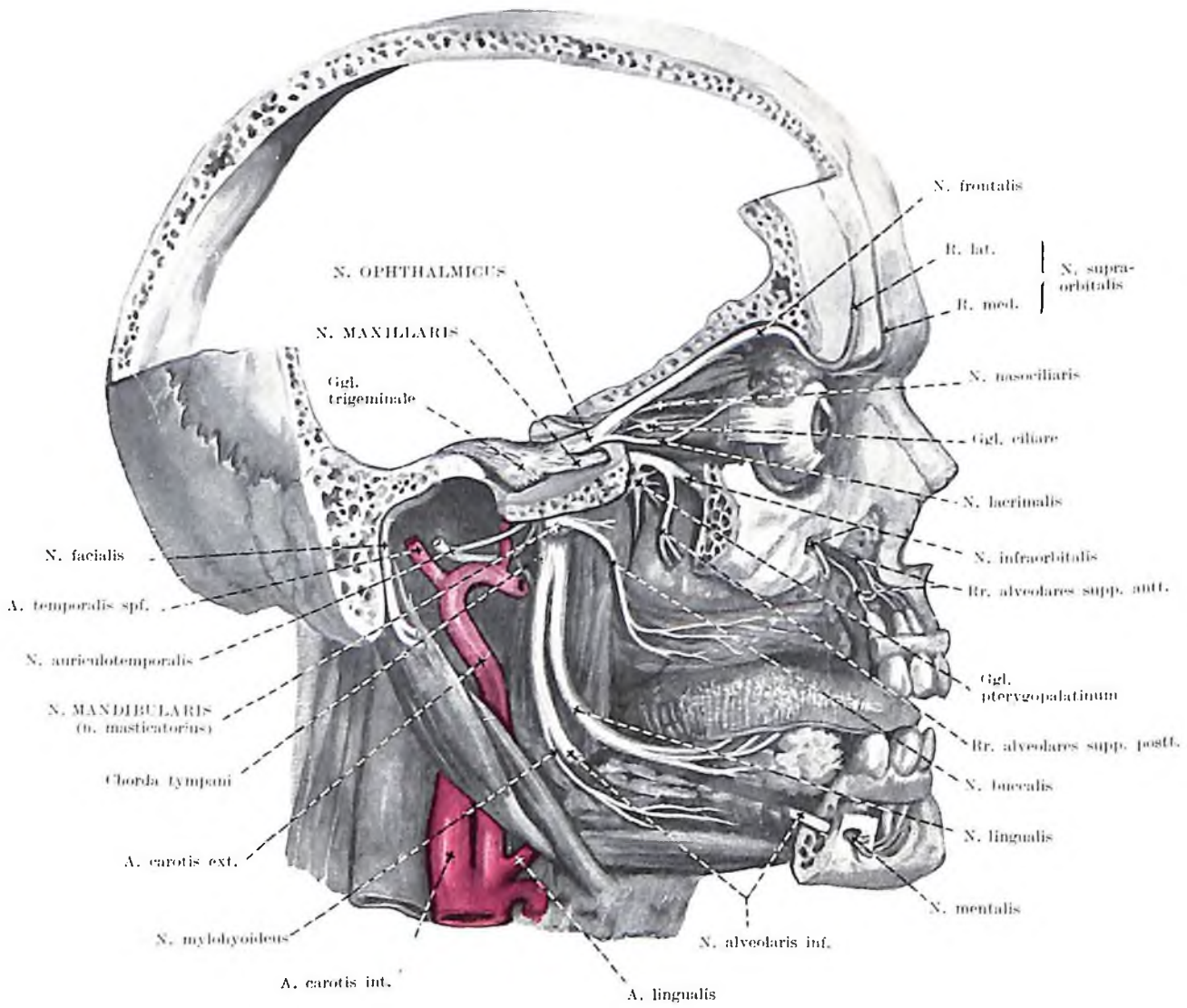


Fig. 102. NERVUS TRIGEMINUS I.
(ramificatio profunda)

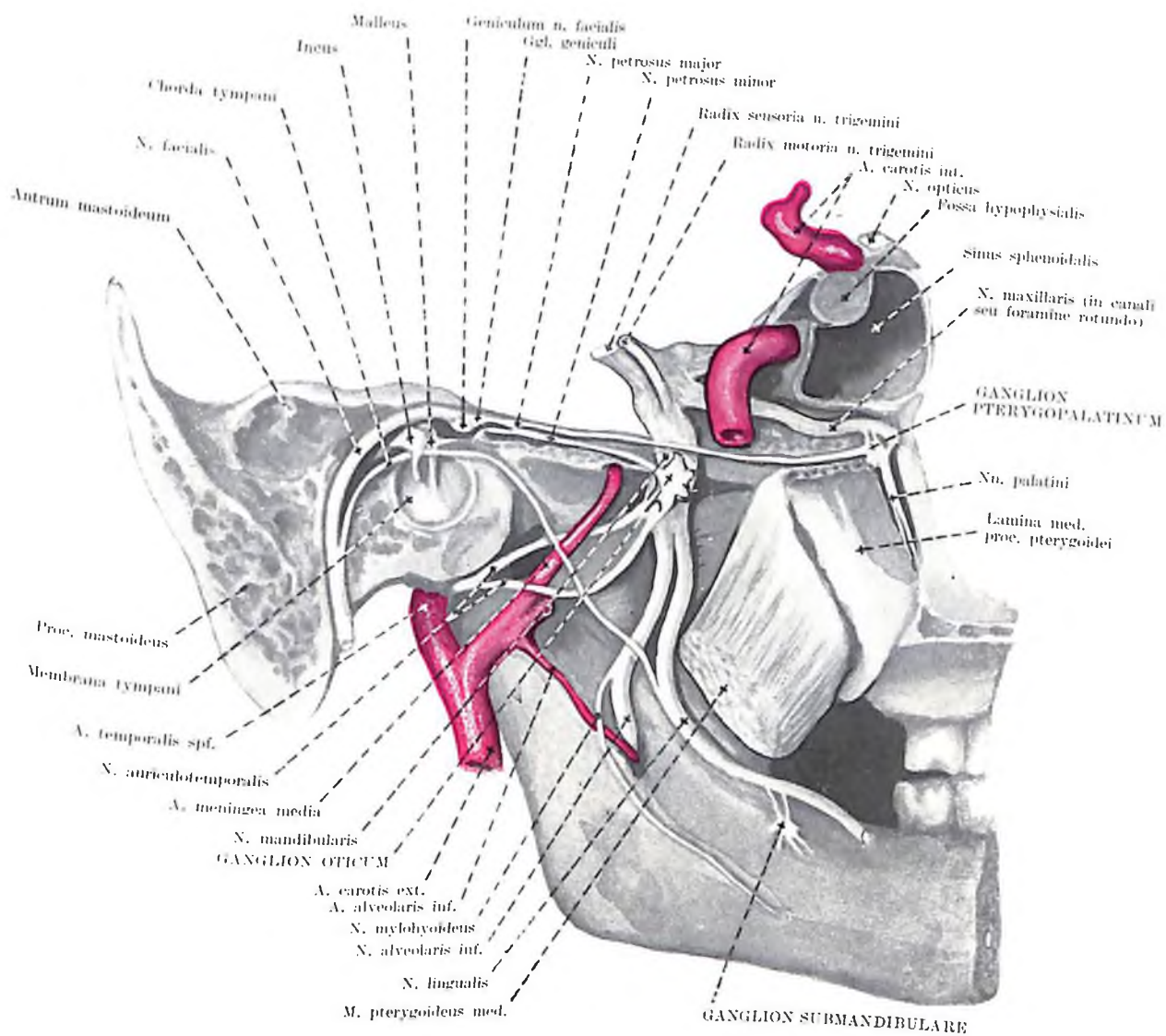


Fig. 103. NERVUS TRIGEMINUS II. ET NERVUS FACIALIS I.
(ganglia autonómica capitis, aspectus medialis, l. sin.)

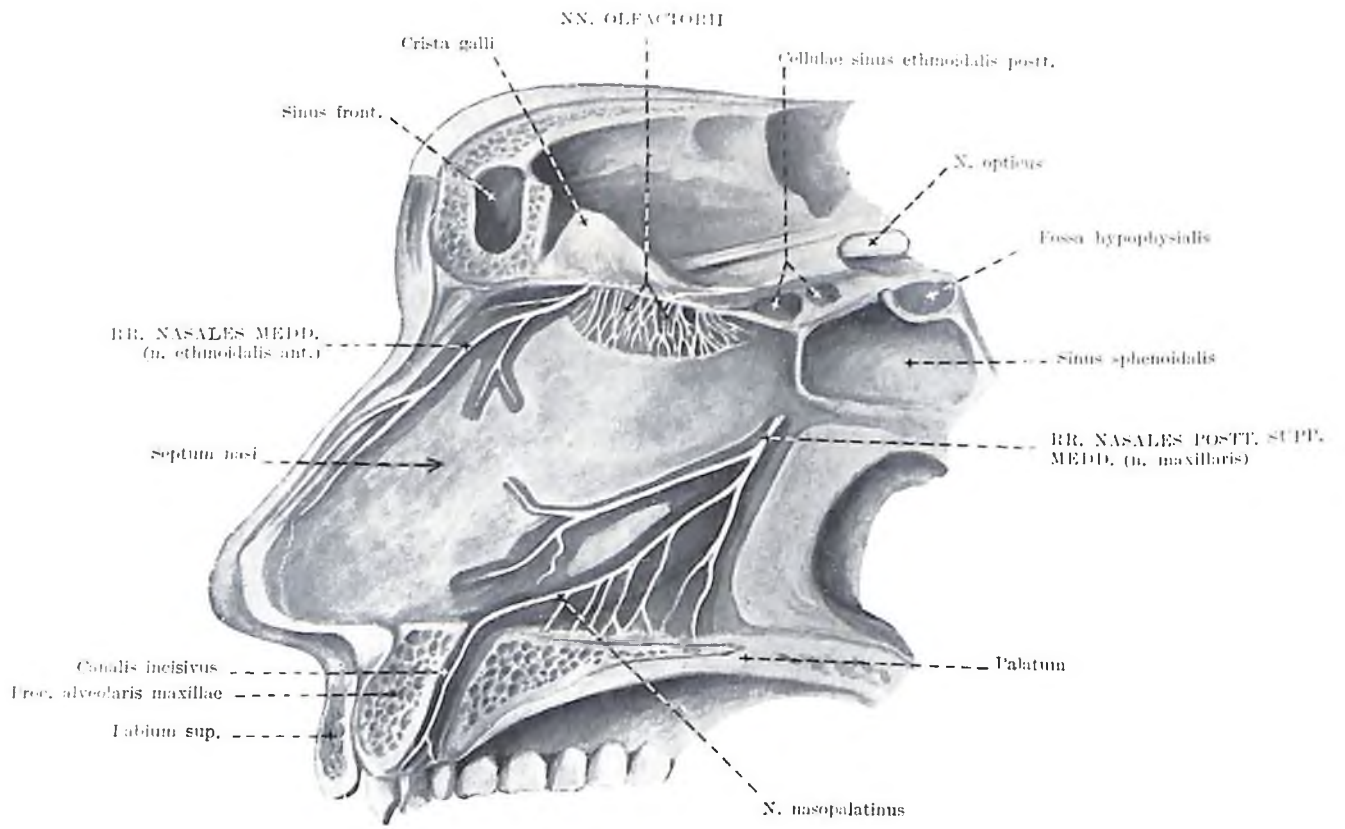


Fig. 104. NERVUS TRIGEMINUS III.
(nervi septi nasi, aspectus sinister)

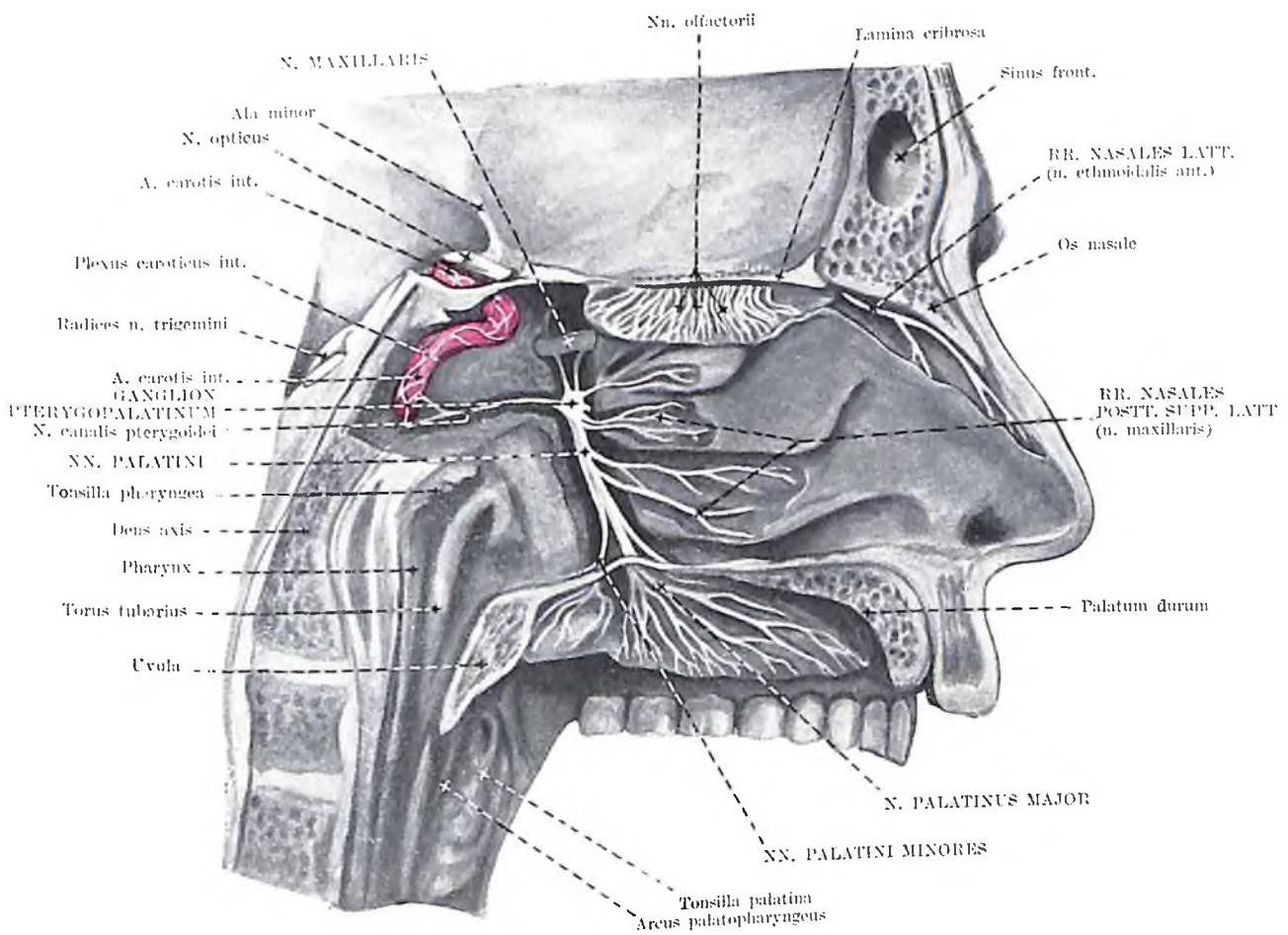


Fig. 105. NERVUS TRIGEMINUS IV.
 (nervus maxillaris, ganglion pterygopalatinum, nervi parietis lateralis cavi nasi et nervi palatini, aspectus medialis, l. sin.)

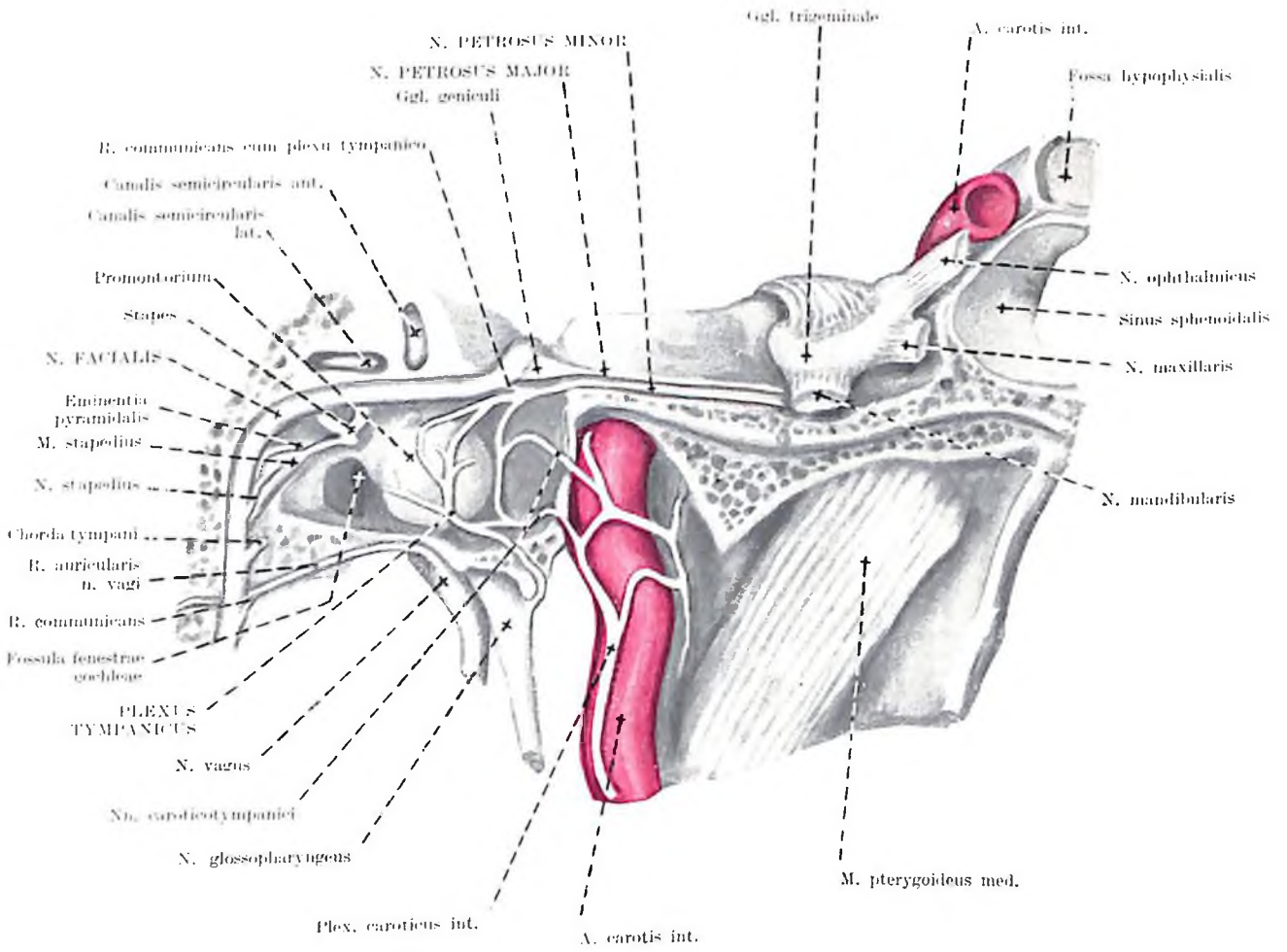


Fig. 106. NERVUS FACIALIS II.
 (plexus tympanicus et nervi petrosi, aspectus lateralis, I. dext.)

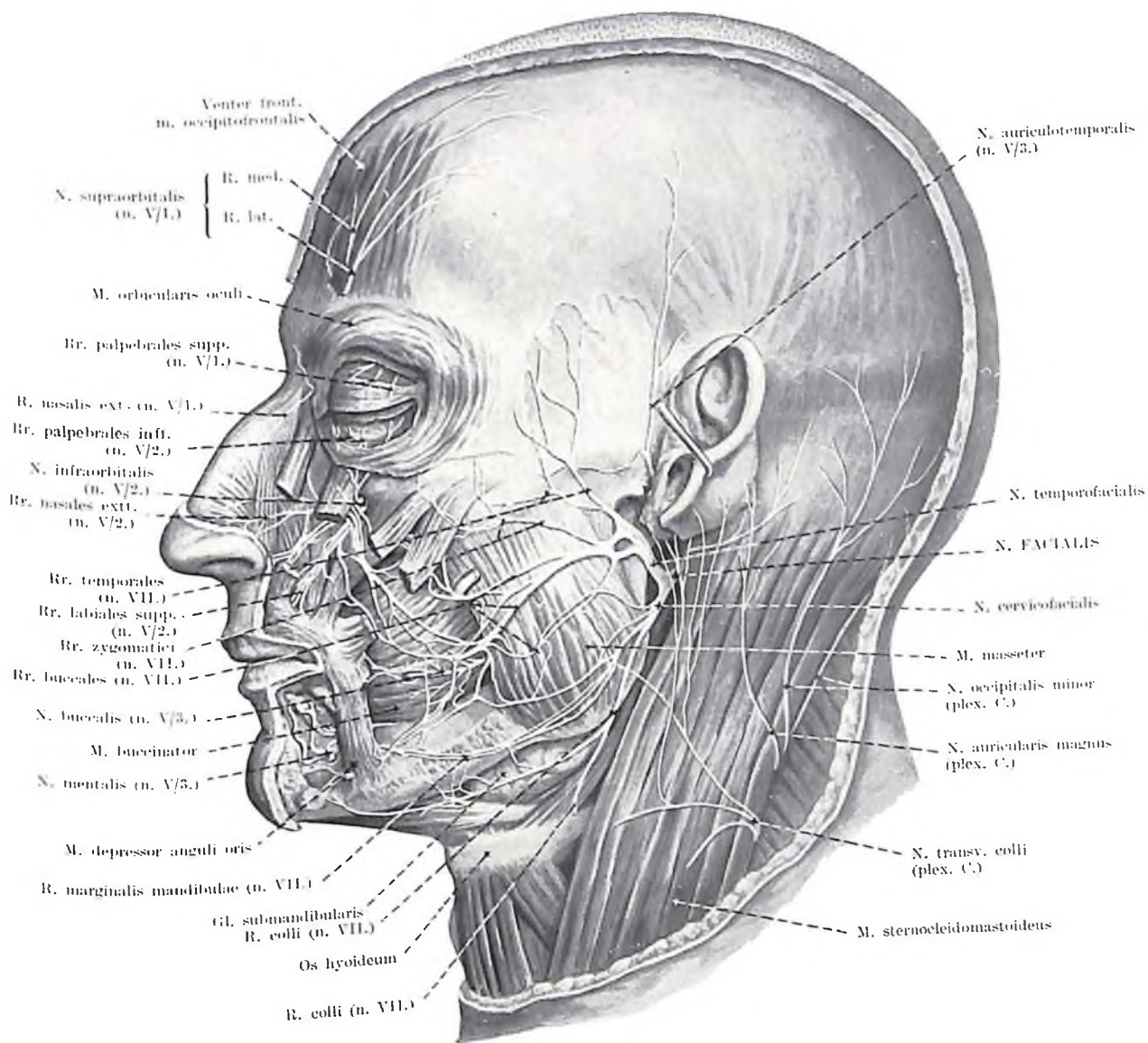


Fig. 107. NERVUS FACIALIS III.
(nervi superficiales faciei)

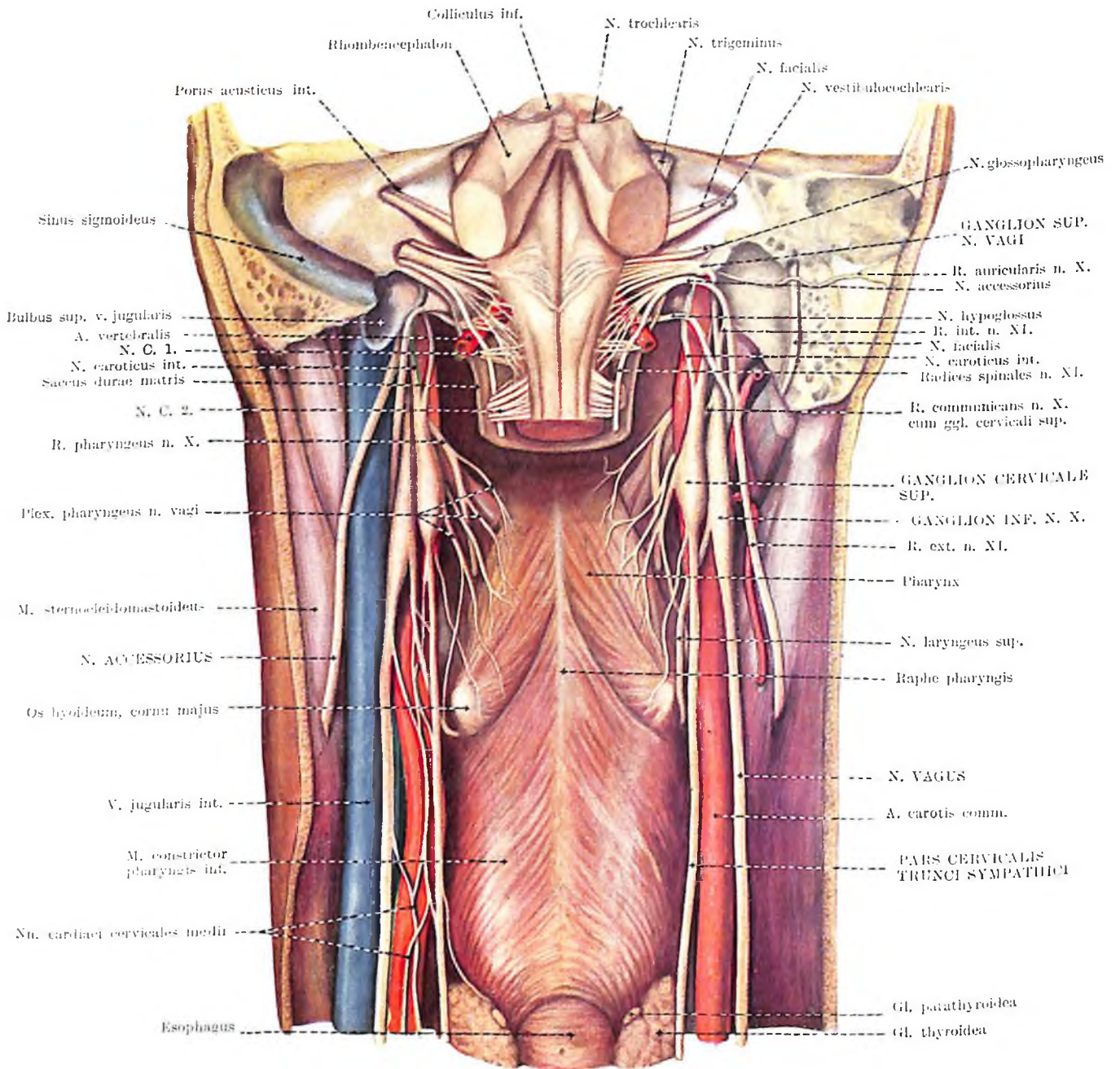


Fig. 108. NERVUS VAGUS, NERVUS ACCESSORIUS
 ET PARS CERVICALIS TRUNCUS SYMPHATICI I.
 (aspectus posterior)

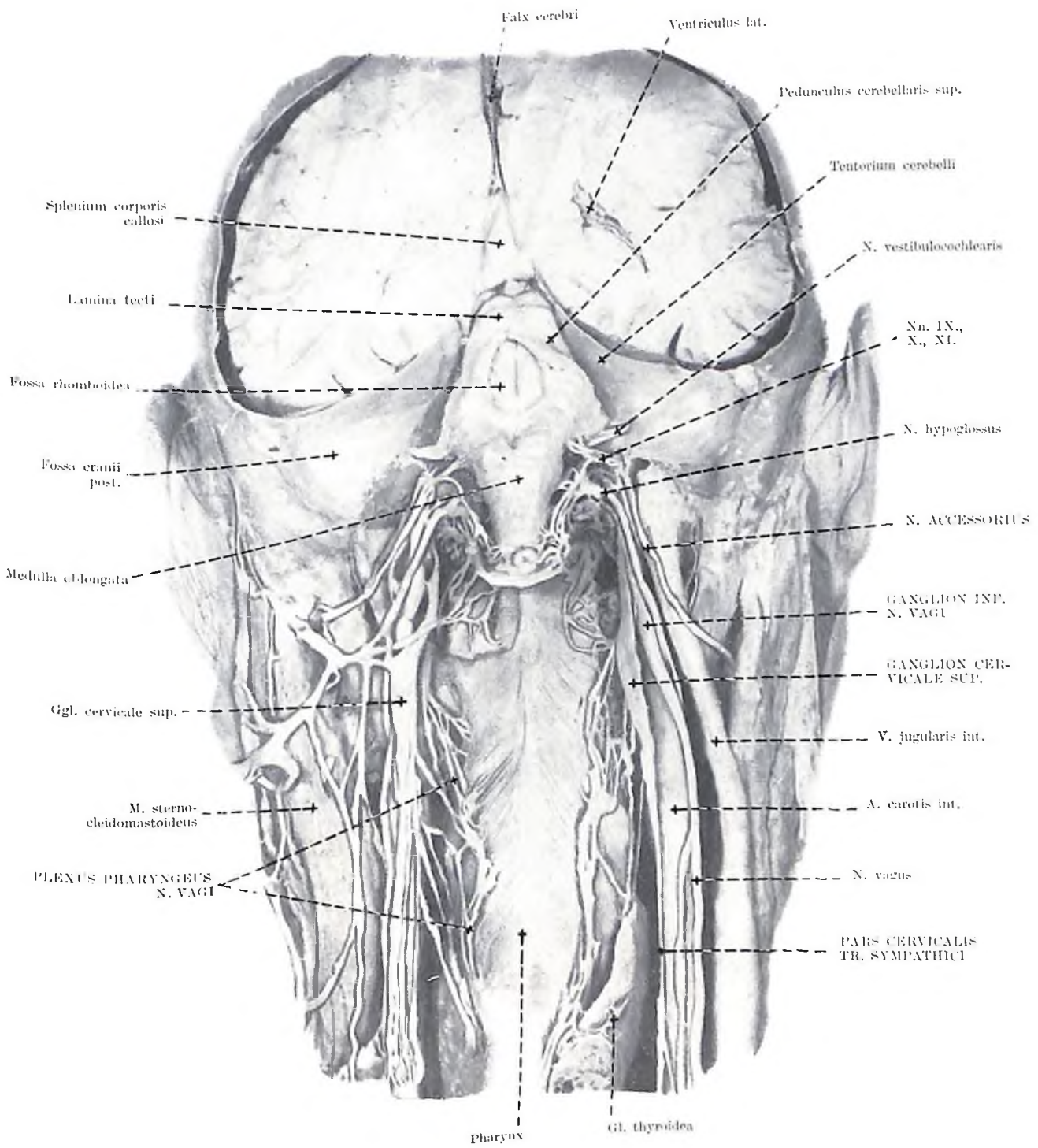


Fig. 109. NERVUS VAGUS, NERVUS ACCESSORIUS ET PARS CERVICALIS TRUNCI SYMPATHICI II. (sectio frontalis capitis et cervicis)

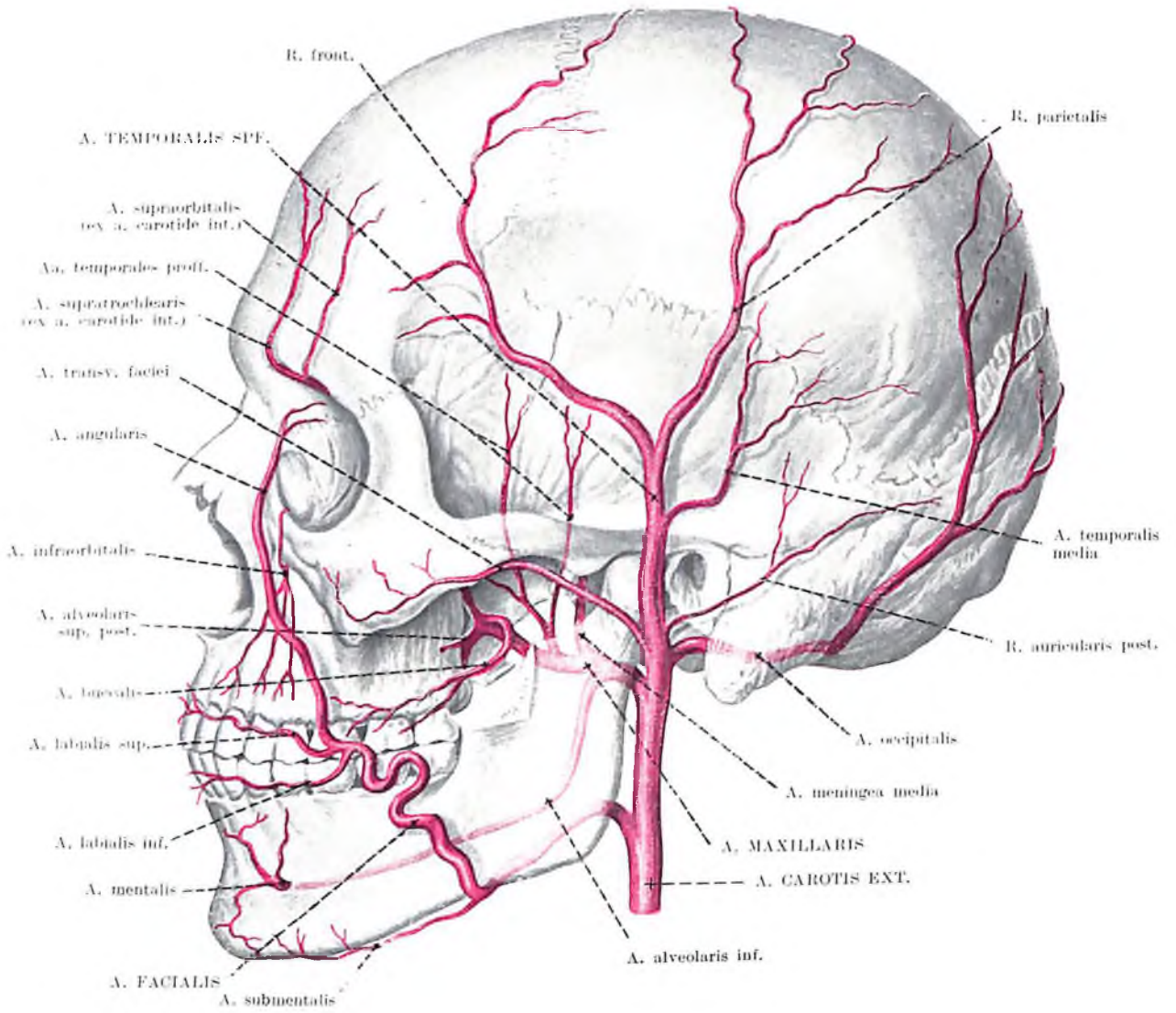


Fig. 110. ARTERIAE SUPERFICIALES CAPITIS

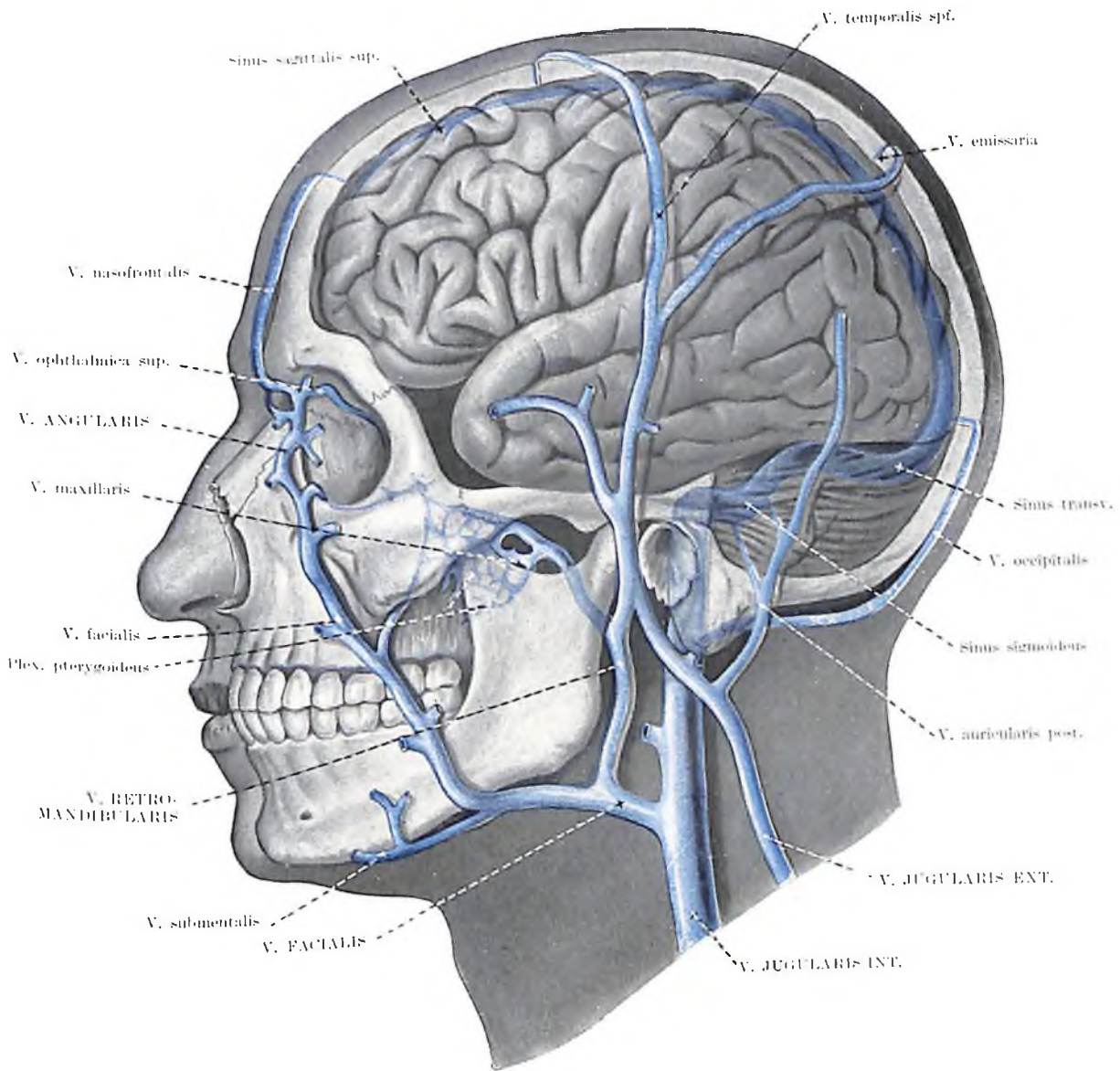


Fig. 111. VENAE SUPERFICIALES CAPITIS

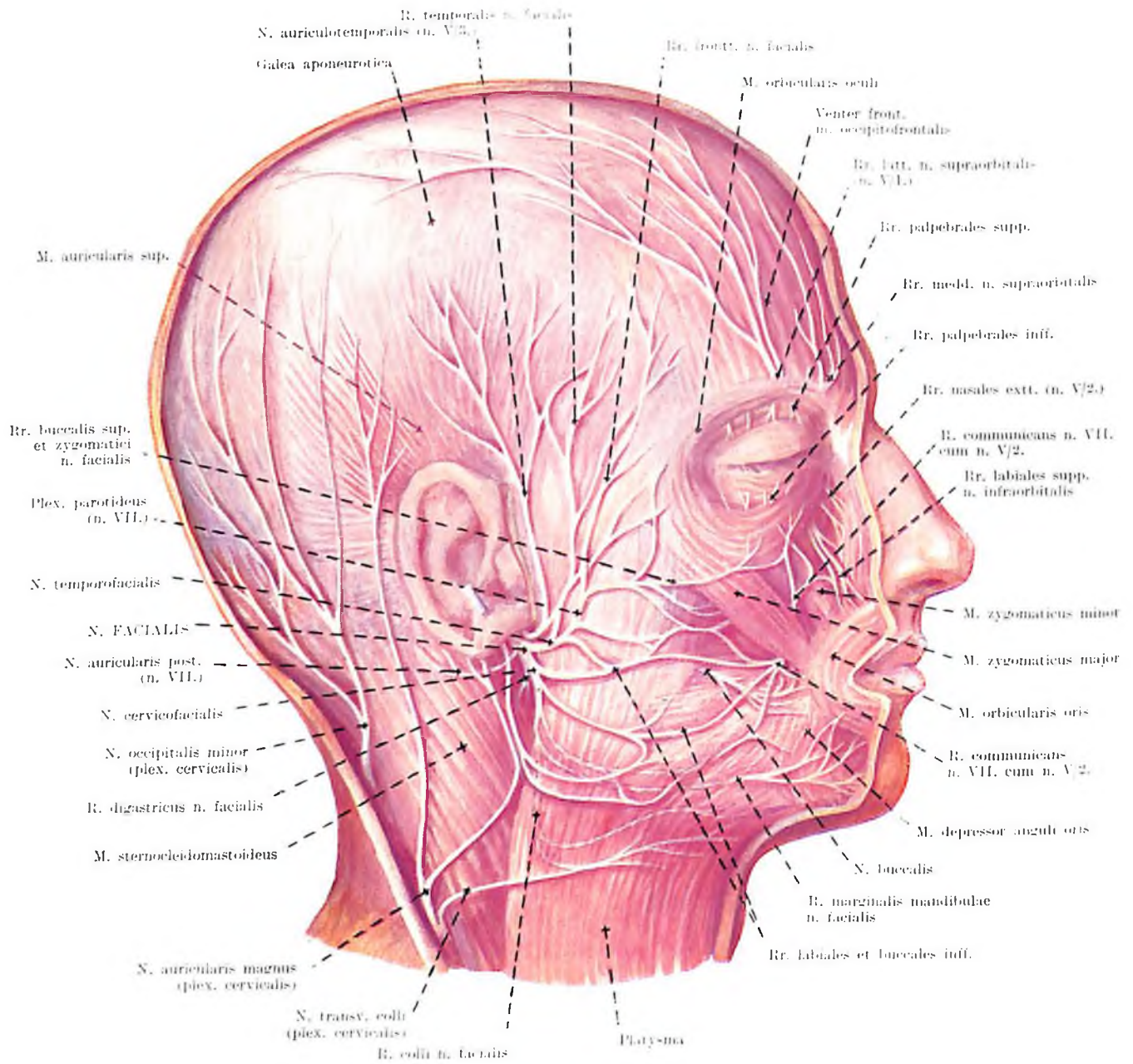


Fig. 112. NERVI SUPERFICIALES FACIEI
 (rami communicantes inter nervos facialem, trigeminum et cervicales)

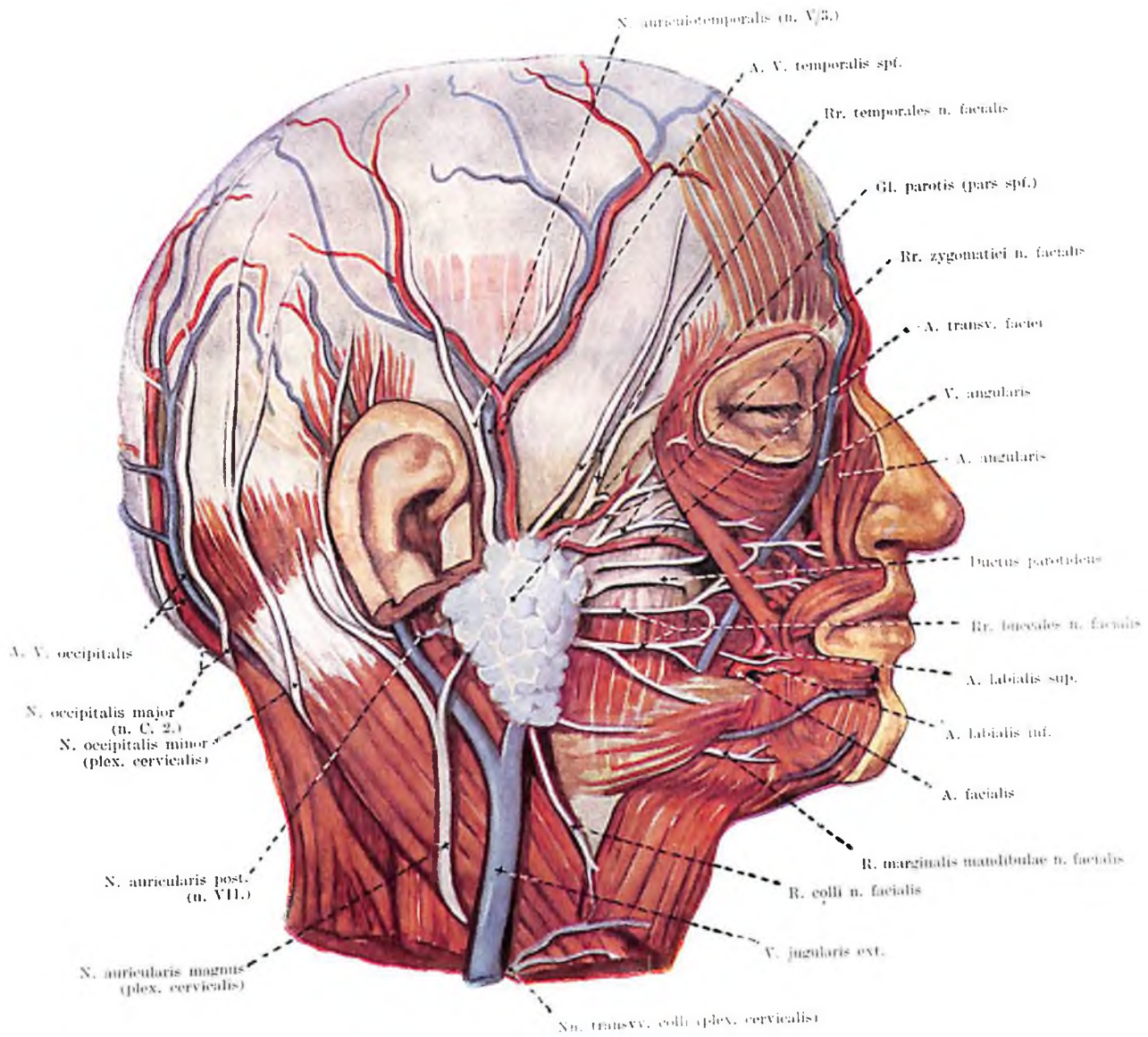


Fig. 113. ARTERIAE, VENAE ET NERVI FACIEI I.
(stratum superficiale)

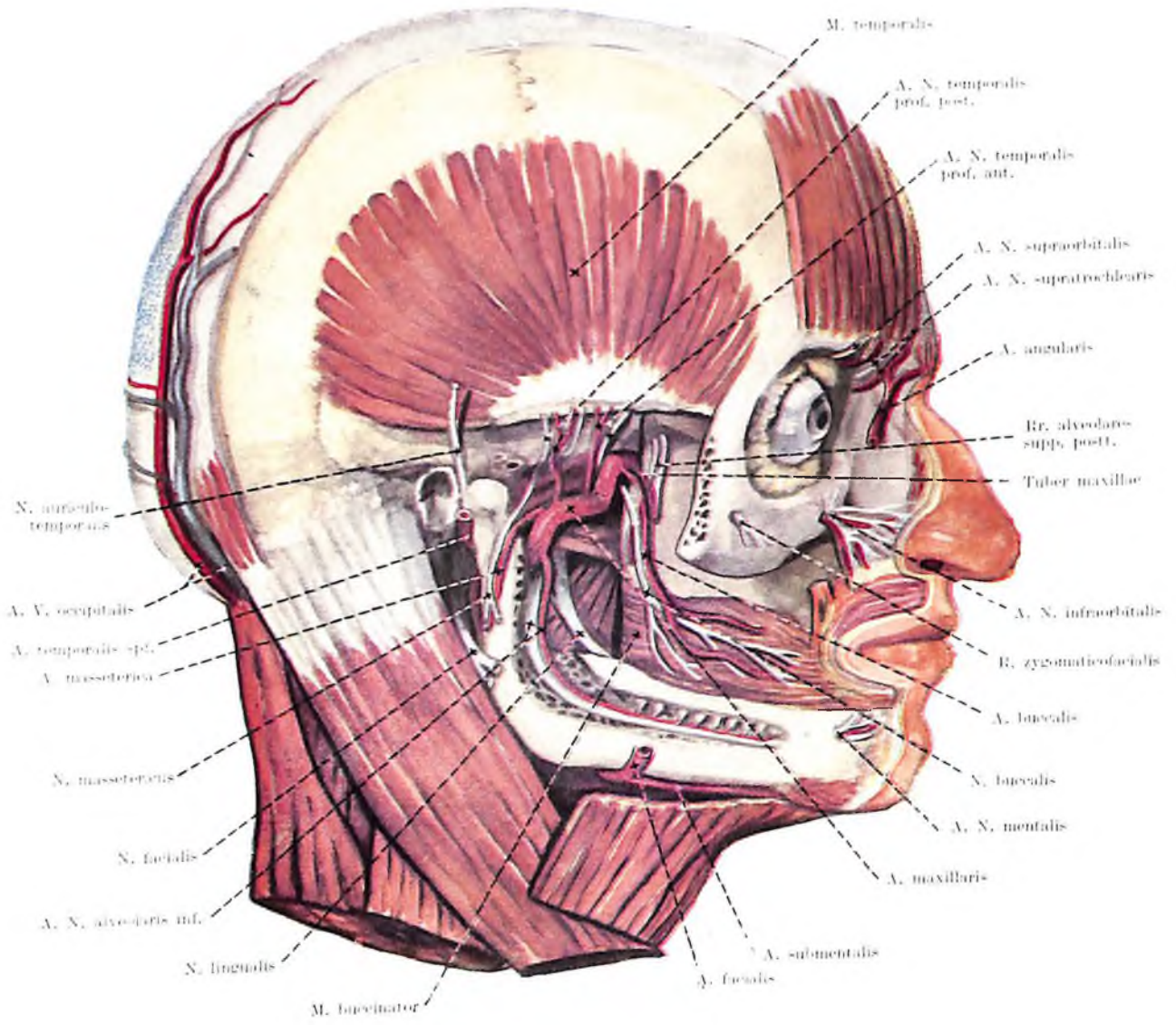


Fig. 114. ARTERIAE, VENAE ET NERVI FACIEI II.
(stratum medium)

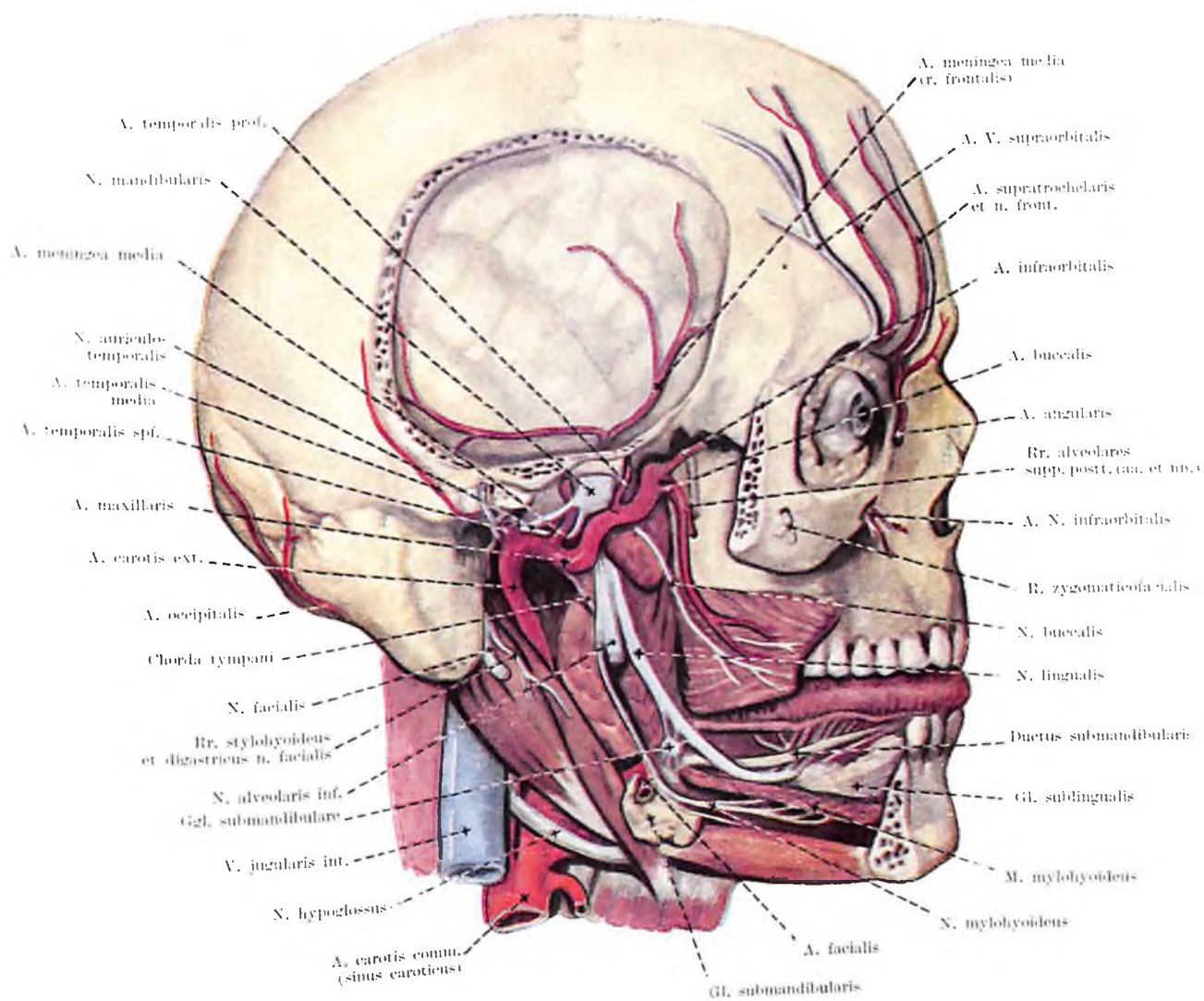


Fig. 115. ARTERIAE, VENAE ET NERVI FACIEI III.
(stratum profundum)

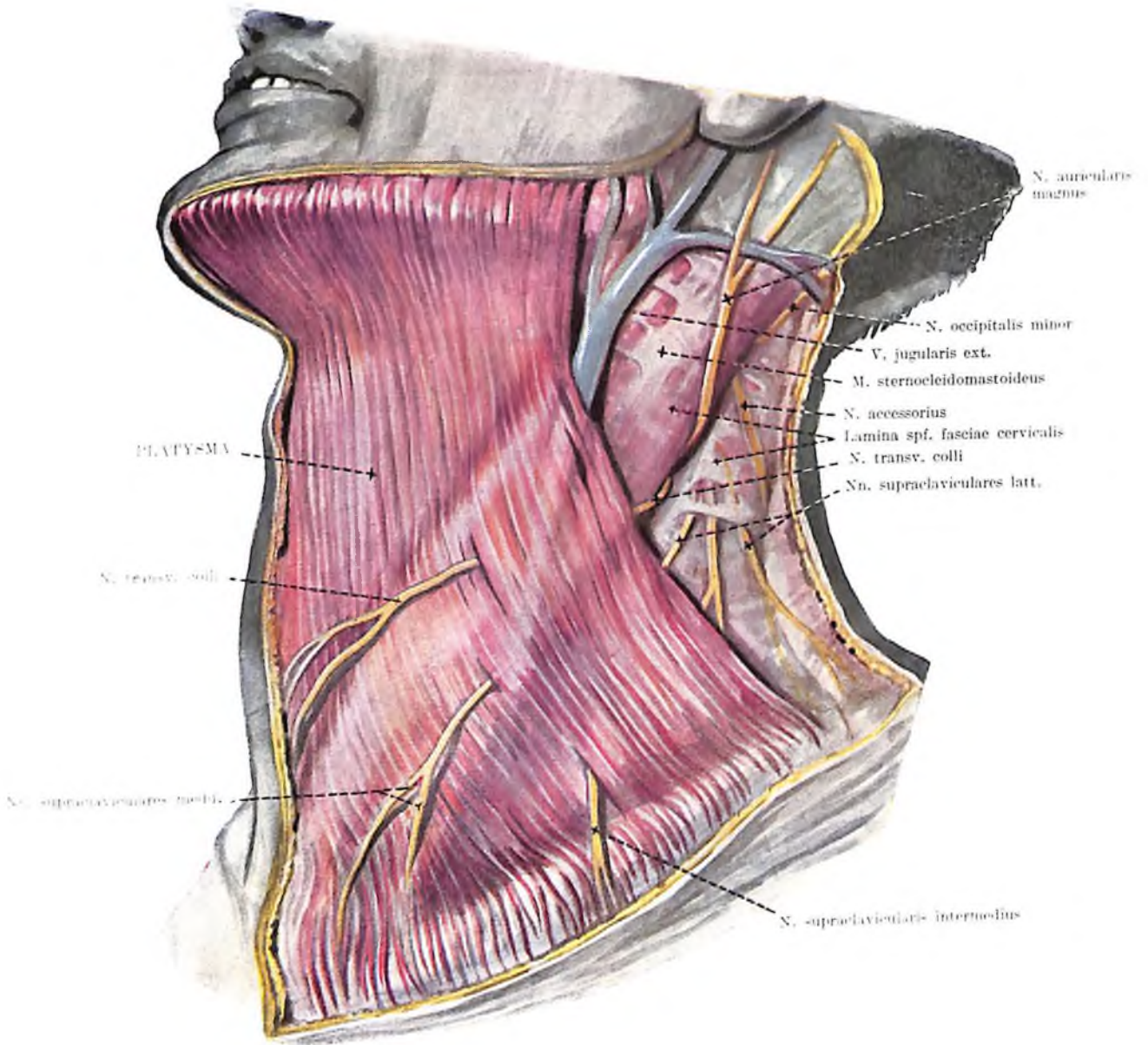


Fig. 116. ARTERIAE. VENAE ET NERVI COLLI I.
(stratum superficiale, platysma)

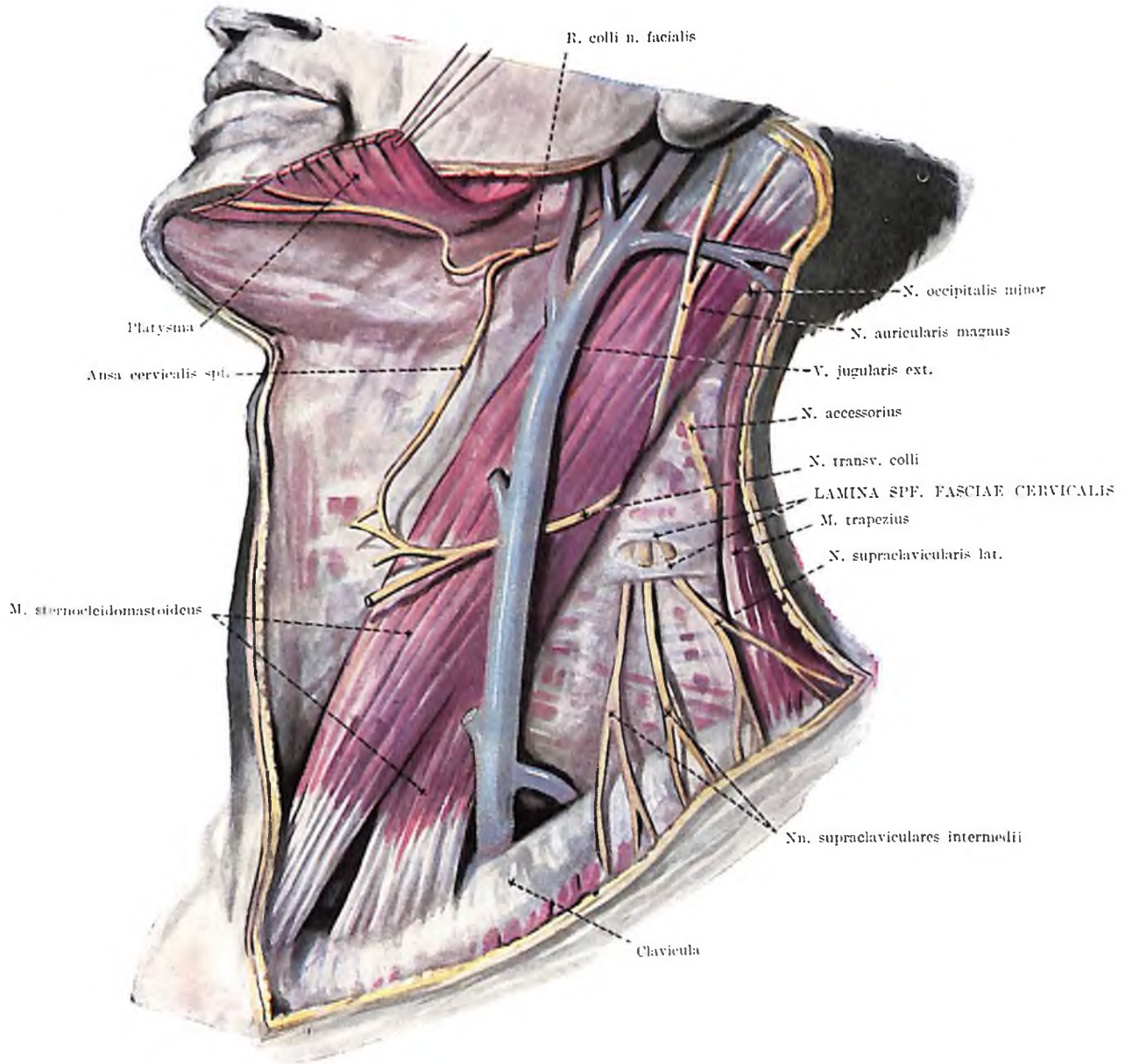


Fig. 117. ARTERIAE. VENAE ET NERVI COLLI II.
 (stratum superficiale, lamina superficialis fasciae cervicalis)

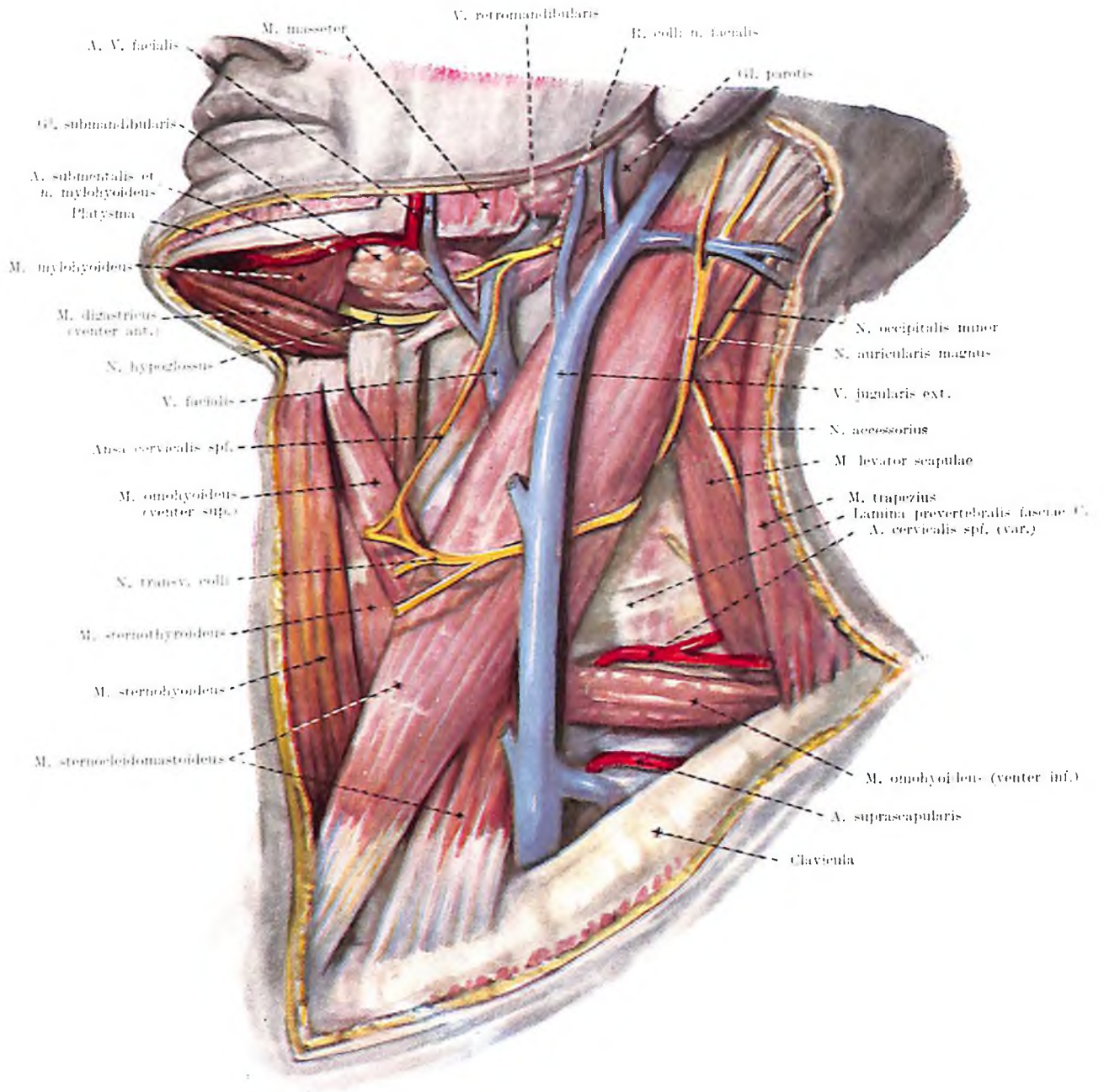


Fig. 118. ARTERIAE, VENAE ET NERVI COLLI III.
(stratum medium, musculi superficiales)

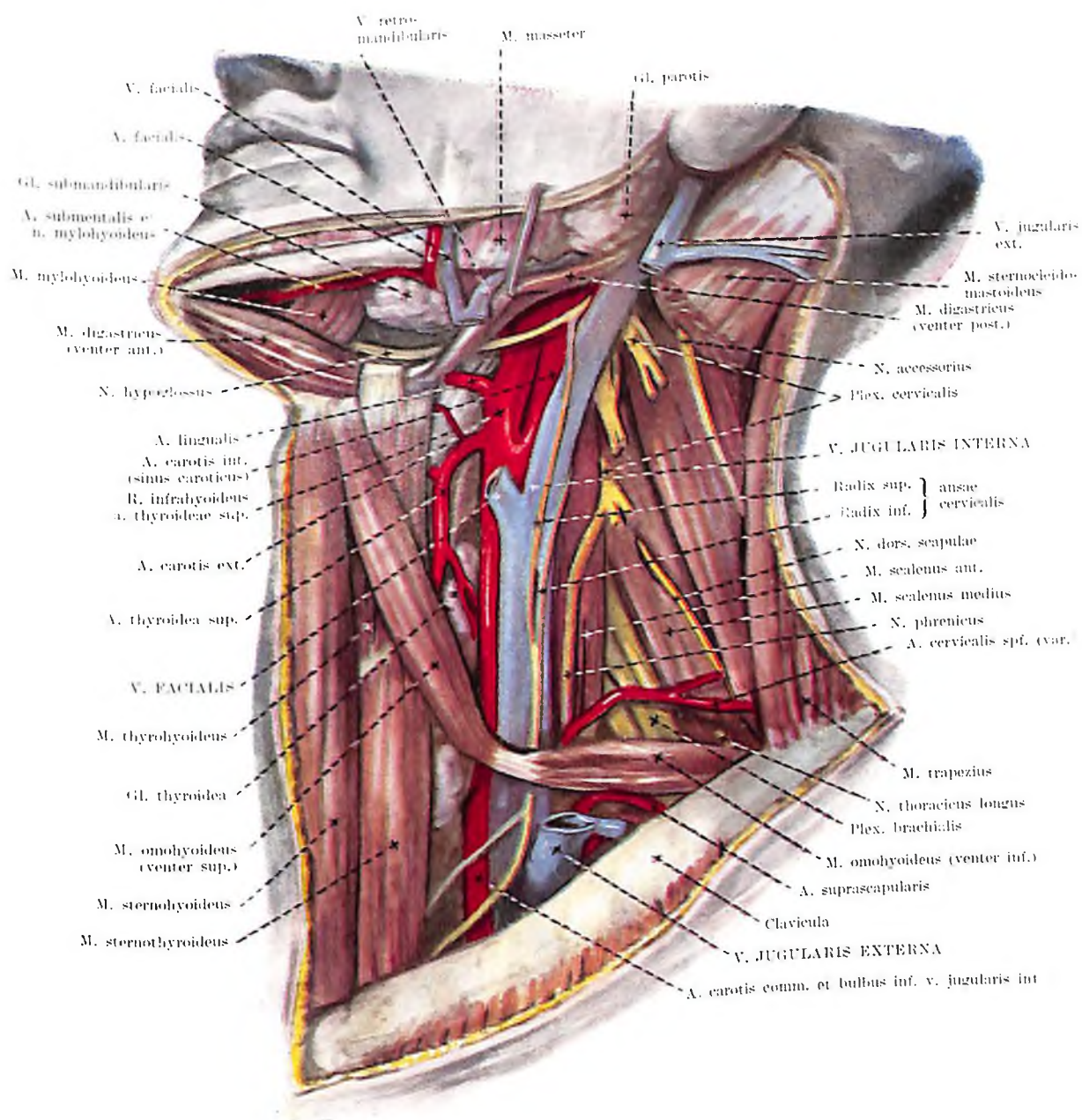


Fig. 119. ARTERIAE, VENAE ET NERVI COLLI IV.
(stratum medium, vena jugularis interna)

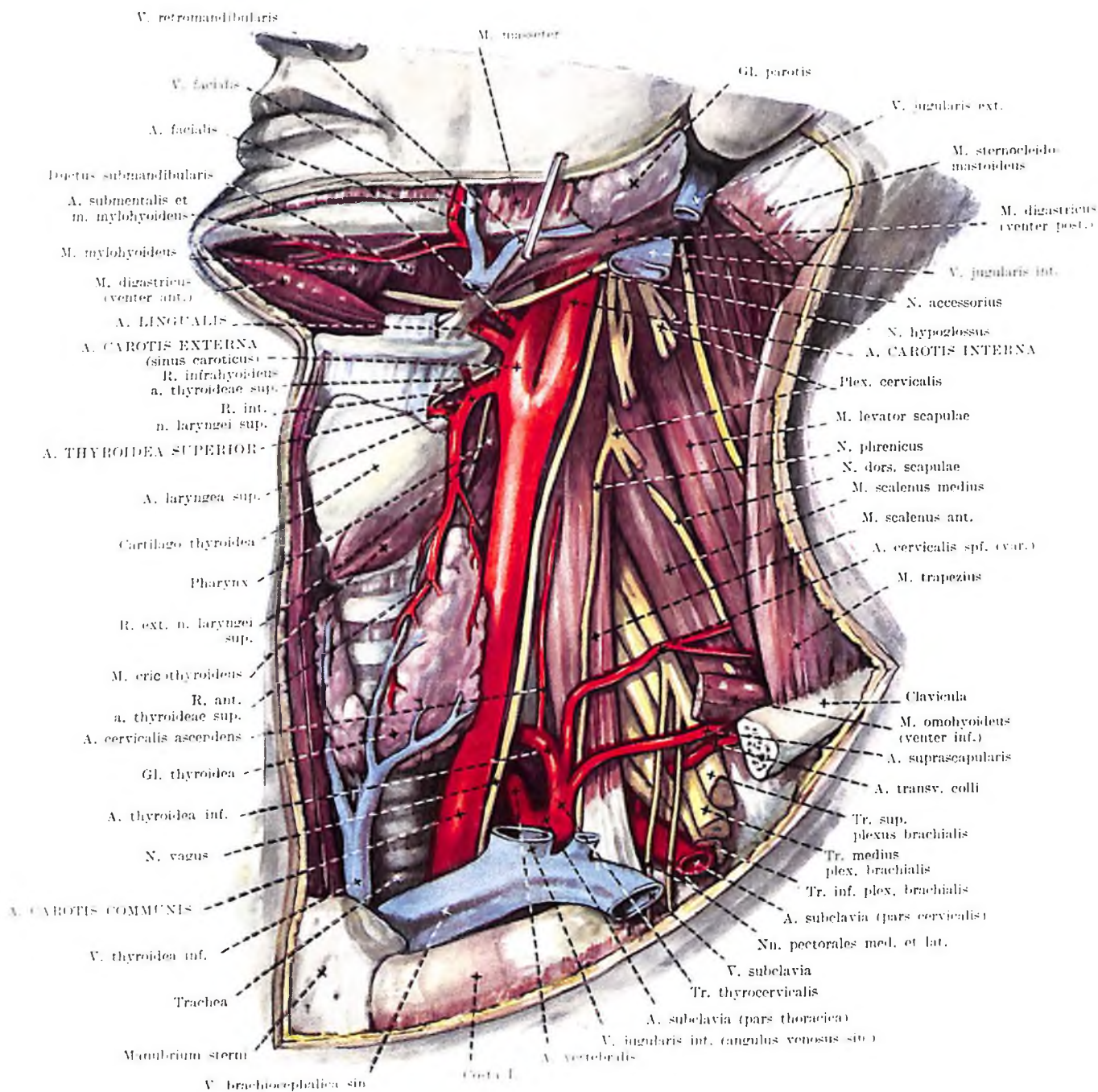


Fig. 120. ARTERIAE, VENAE ET NERVI COLLI V.
 (stratum profundum, arteriae carotides)

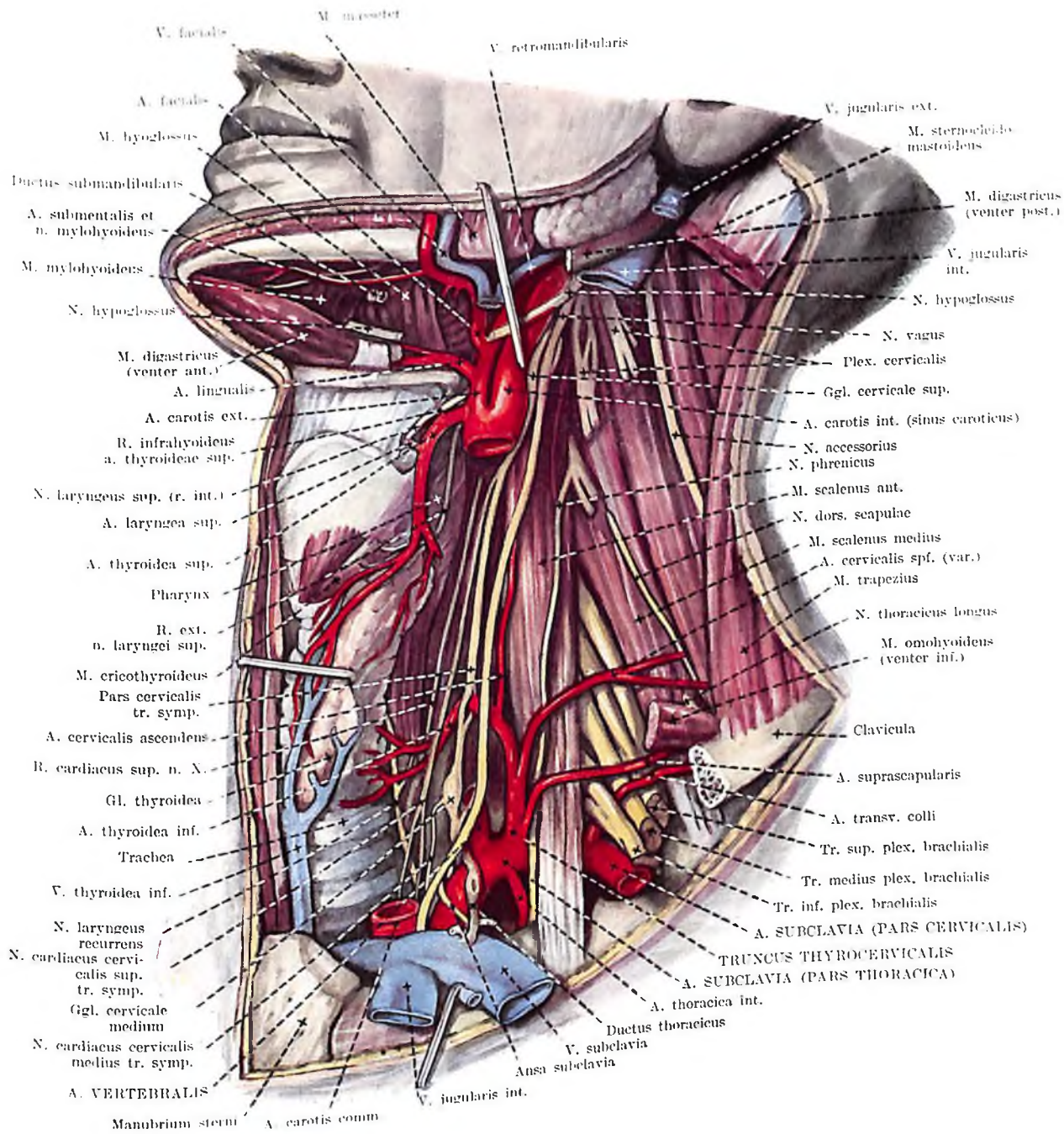


Fig. 121. ARTERIAE, VENAE ET NERVI COLLI VI.
(stratum profundum, arteria subclavia)

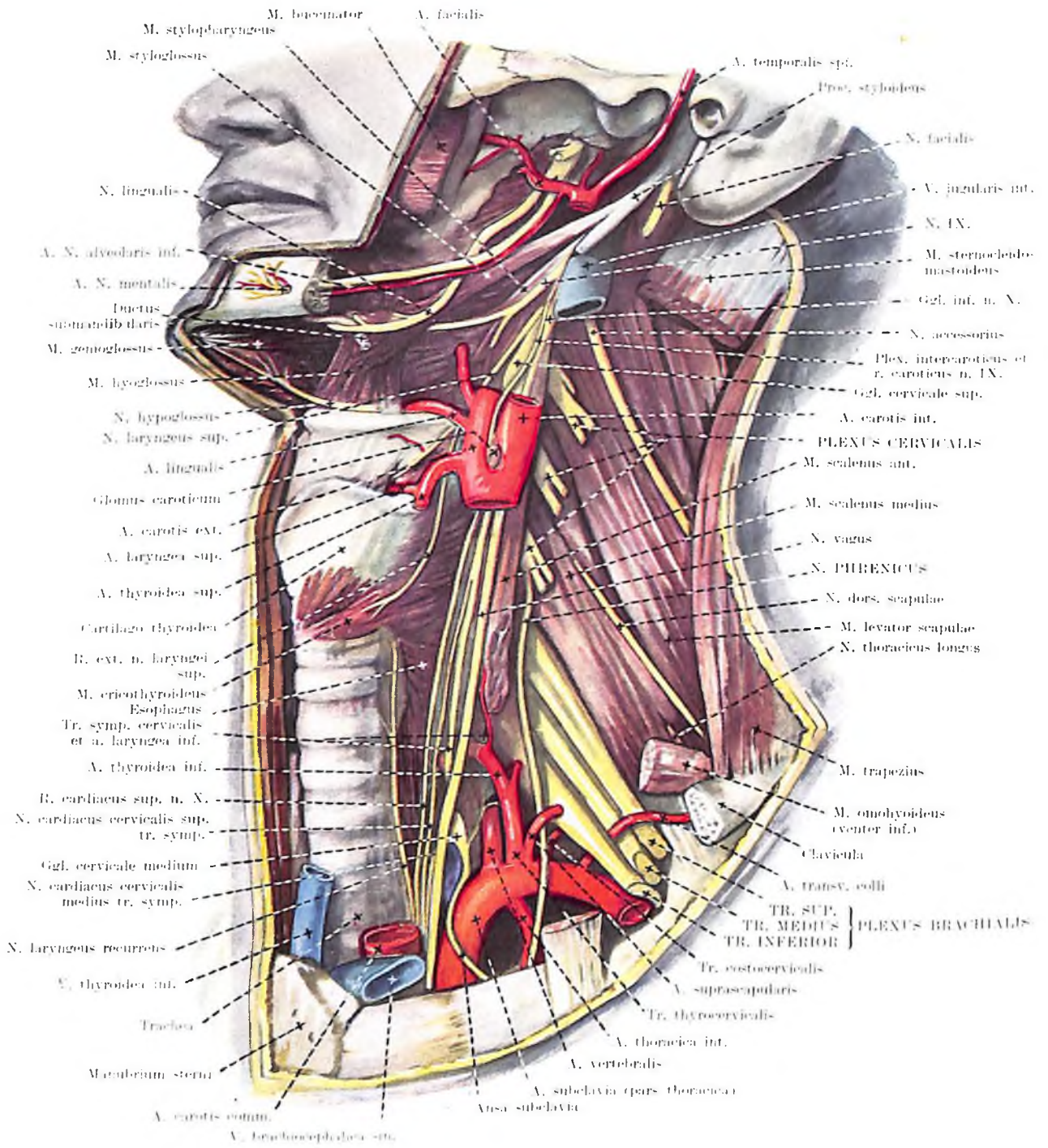


Fig. 122. ARTERIAE, VENAE ET NERVI COLLI VII.
(stratum profundum, plexus cervicade et brachialis)

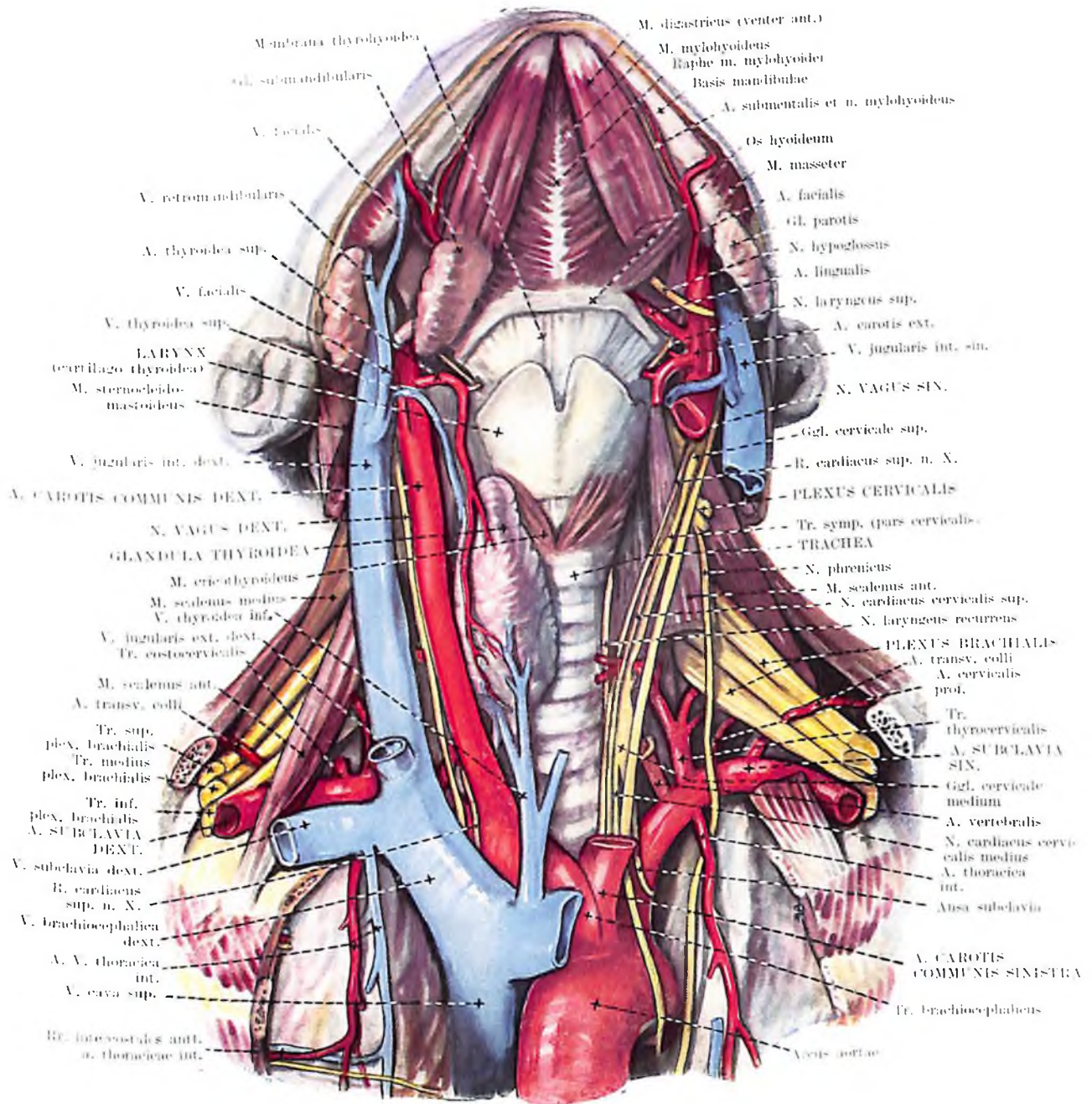
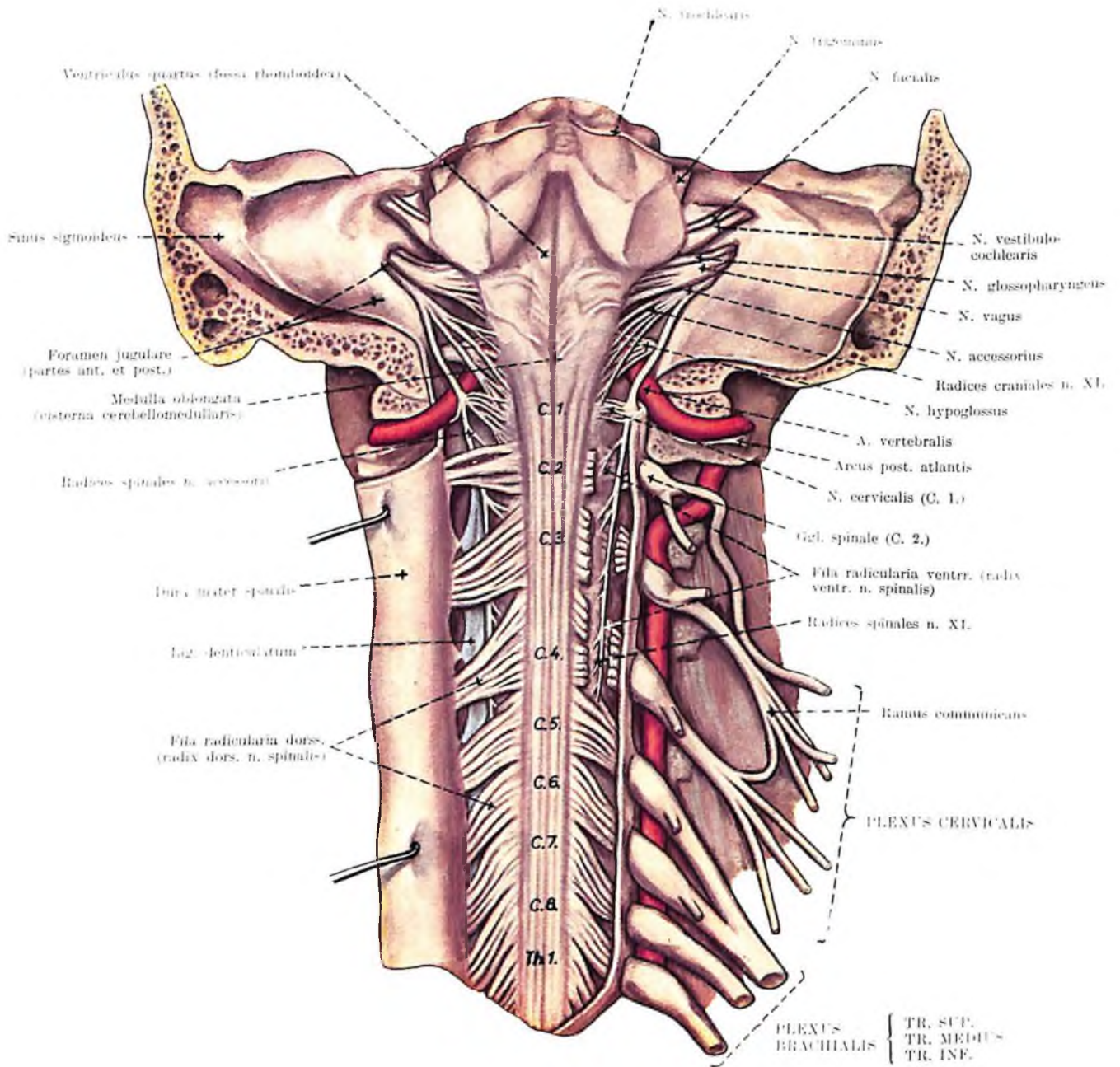


Fig. 123. ARTERIAE, VENAE ET NERVI COLLI VIII.
 (stratum profundum, aspectus anterior)



* 4. 11. 1 — segmenta medullae spinalis

Fig. 124. PLEXUS CERVICALIS ET BRACHIALIS
(partes cervicales canalis vertebralis et medullae spinalis, aspectus posterior)

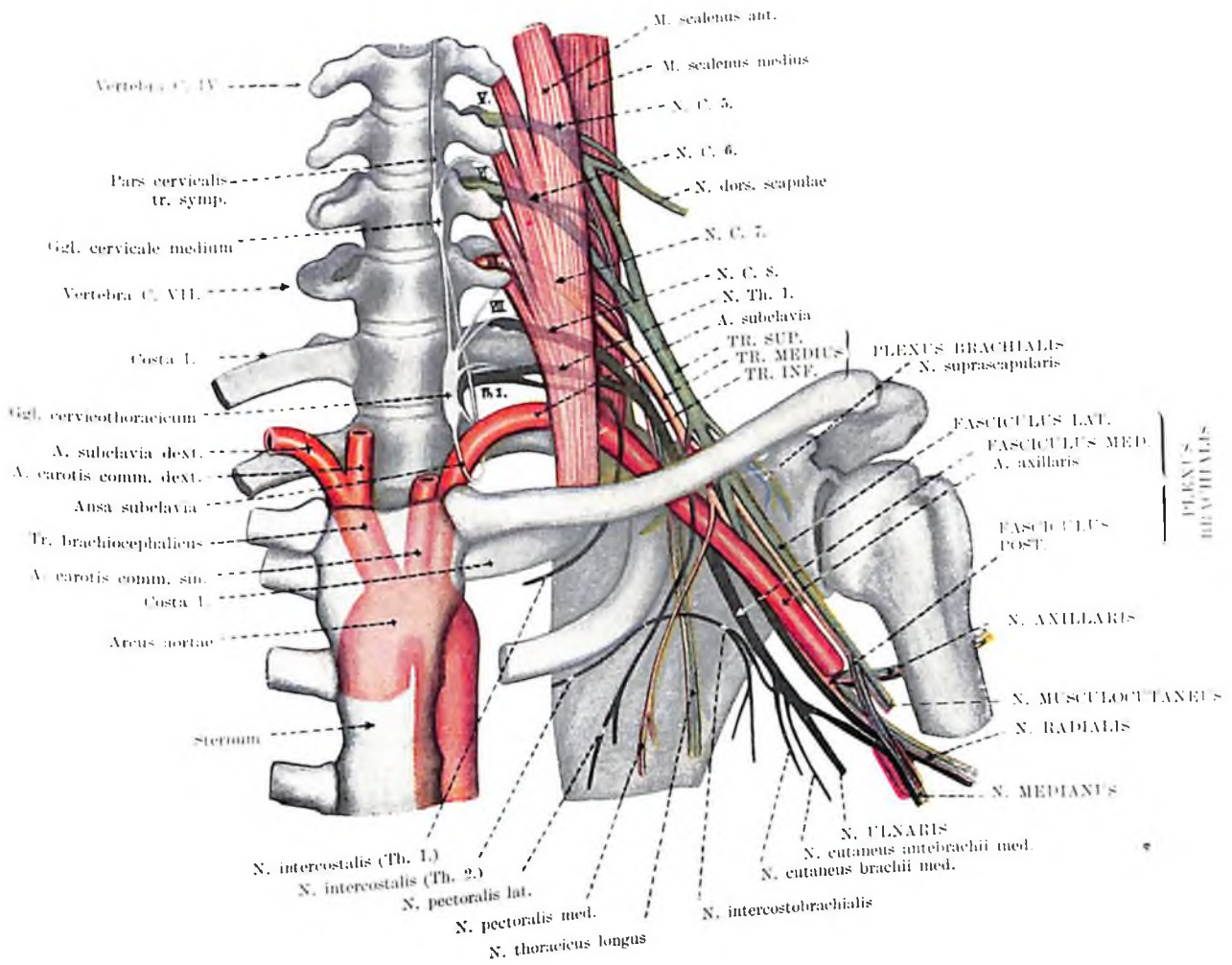


Fig. 125. PLEXUS BRACHIALIS I.
(structura plexus)

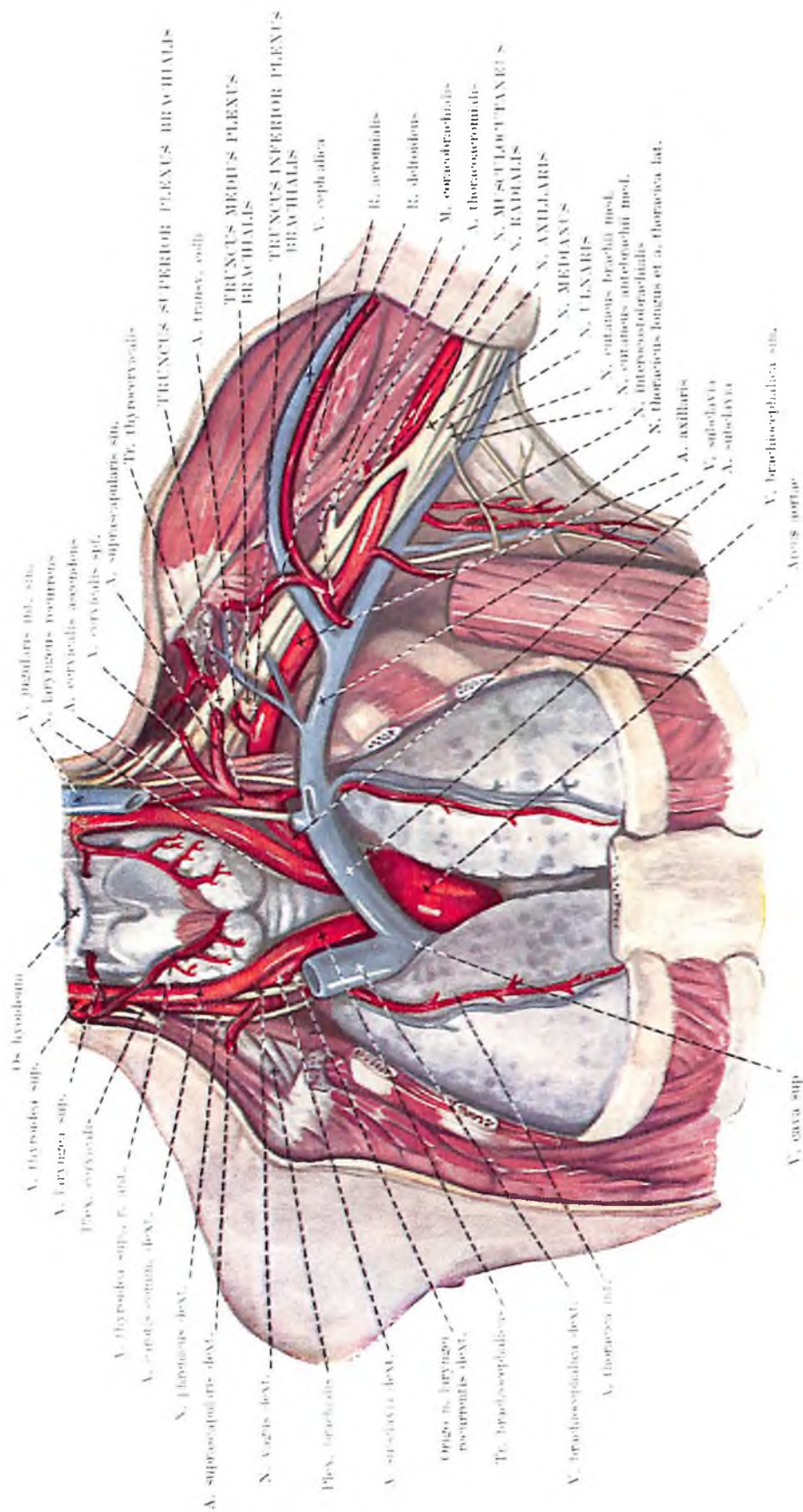


Fig. 126. PLEXUS BRACHIALIS II.
(topographia plexus, regiones colli lateralis et axillaris)

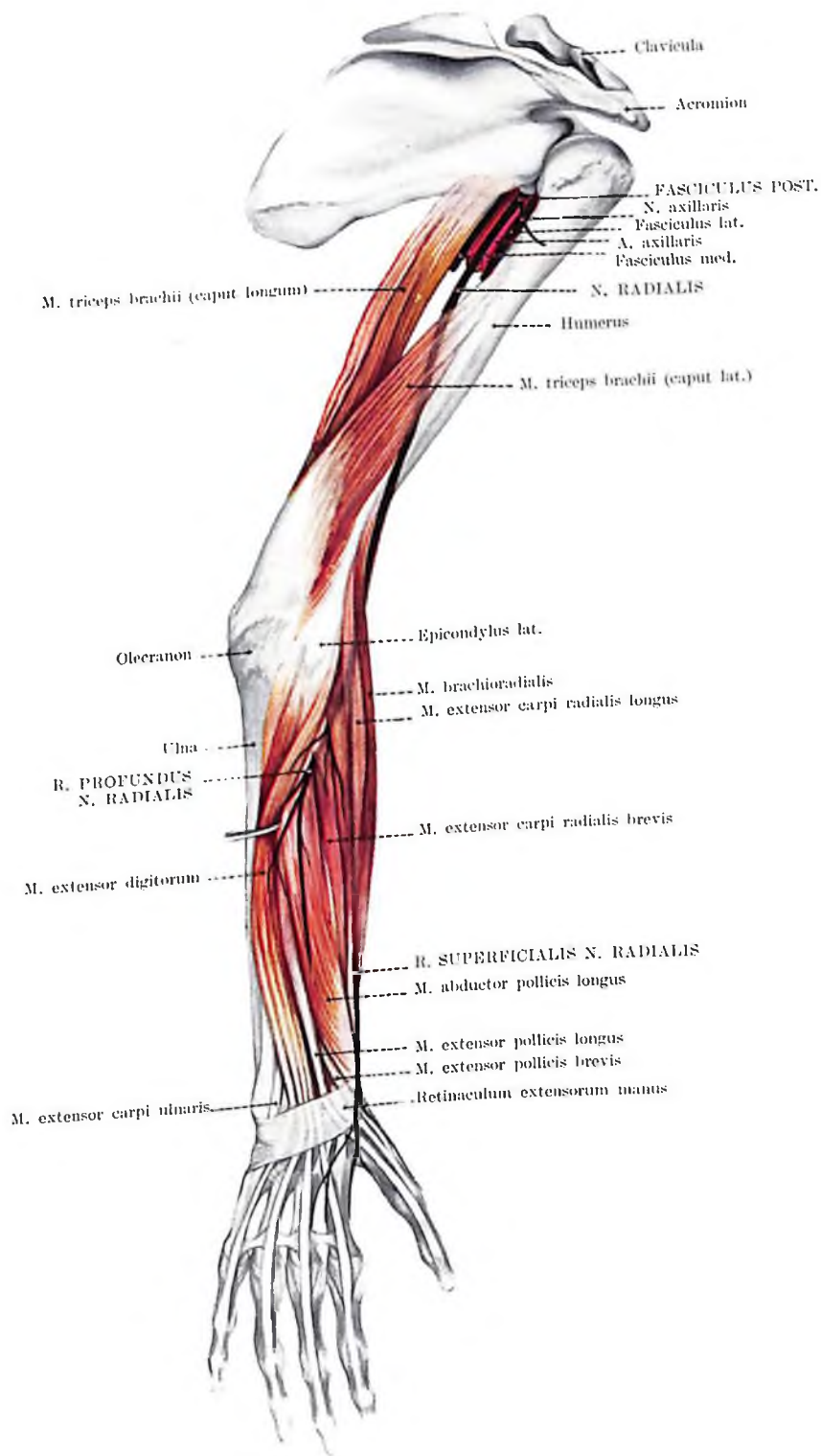


Fig. 127. NERVUS RADIALIS
(musculi extensores brachii et antebrachii)

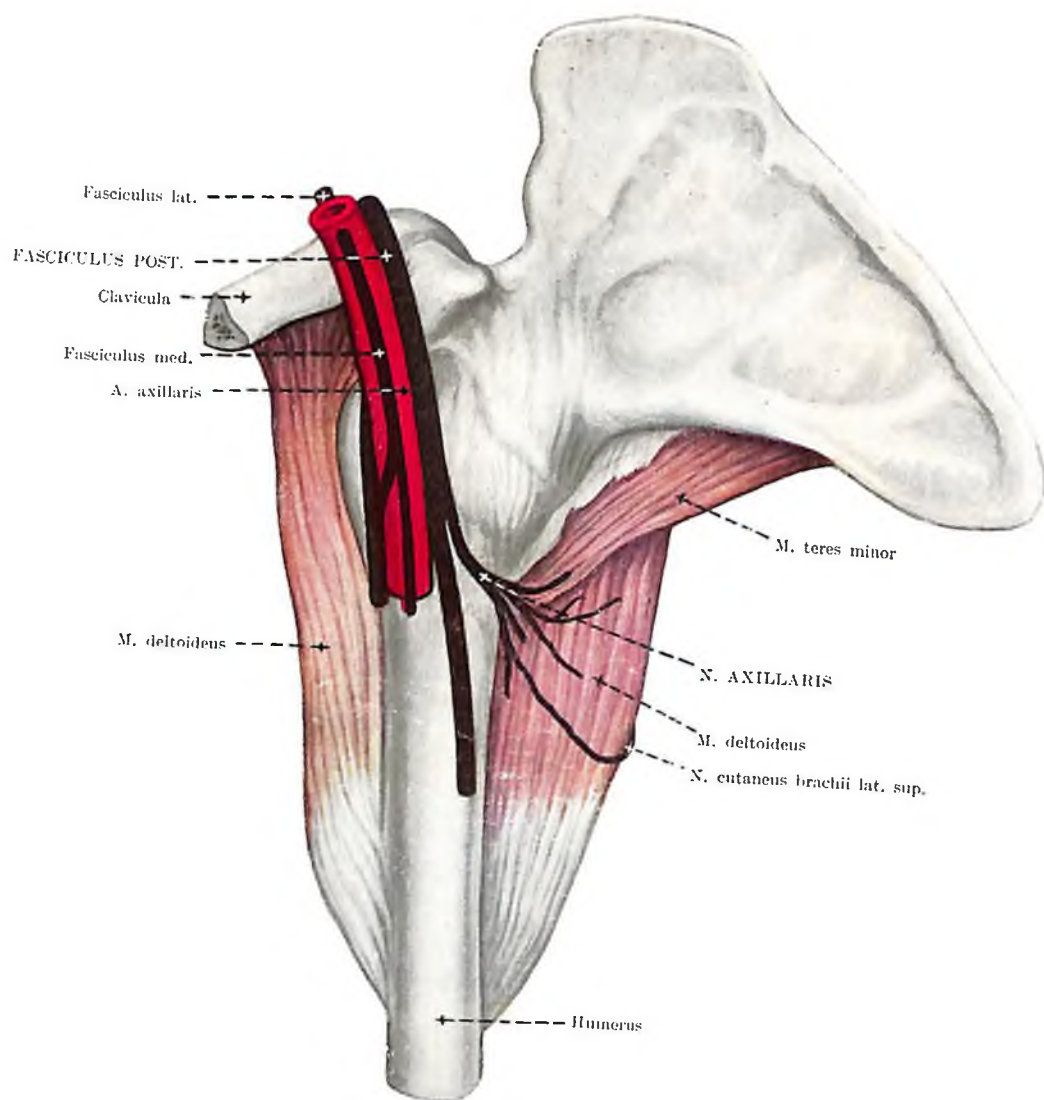


Fig. 128. NERVUS AXILLARIS
(musculus deltoideus)

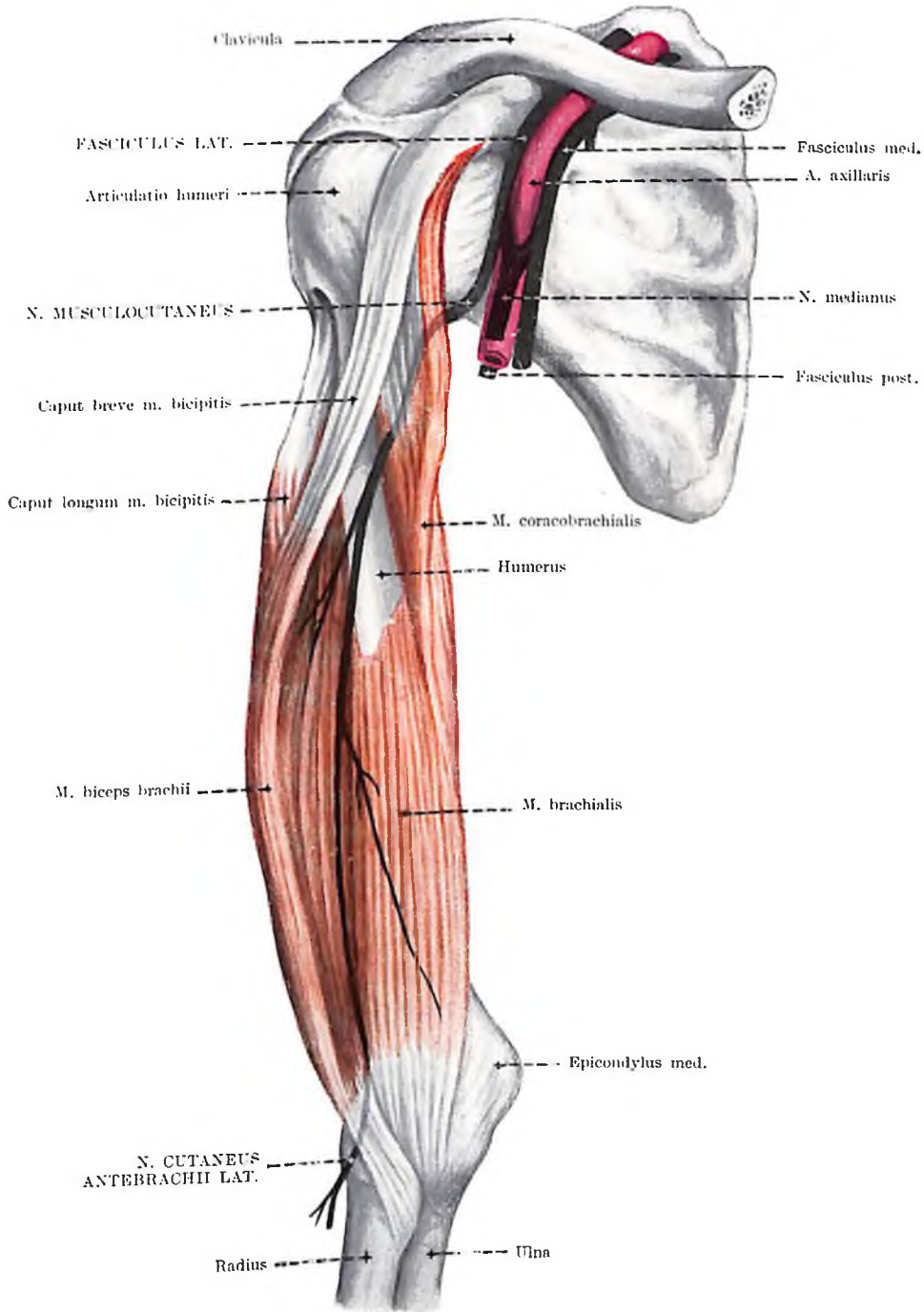


Fig. 129. NERVUS MUSCULOCUTANEUS
(museuli flexores brachii)

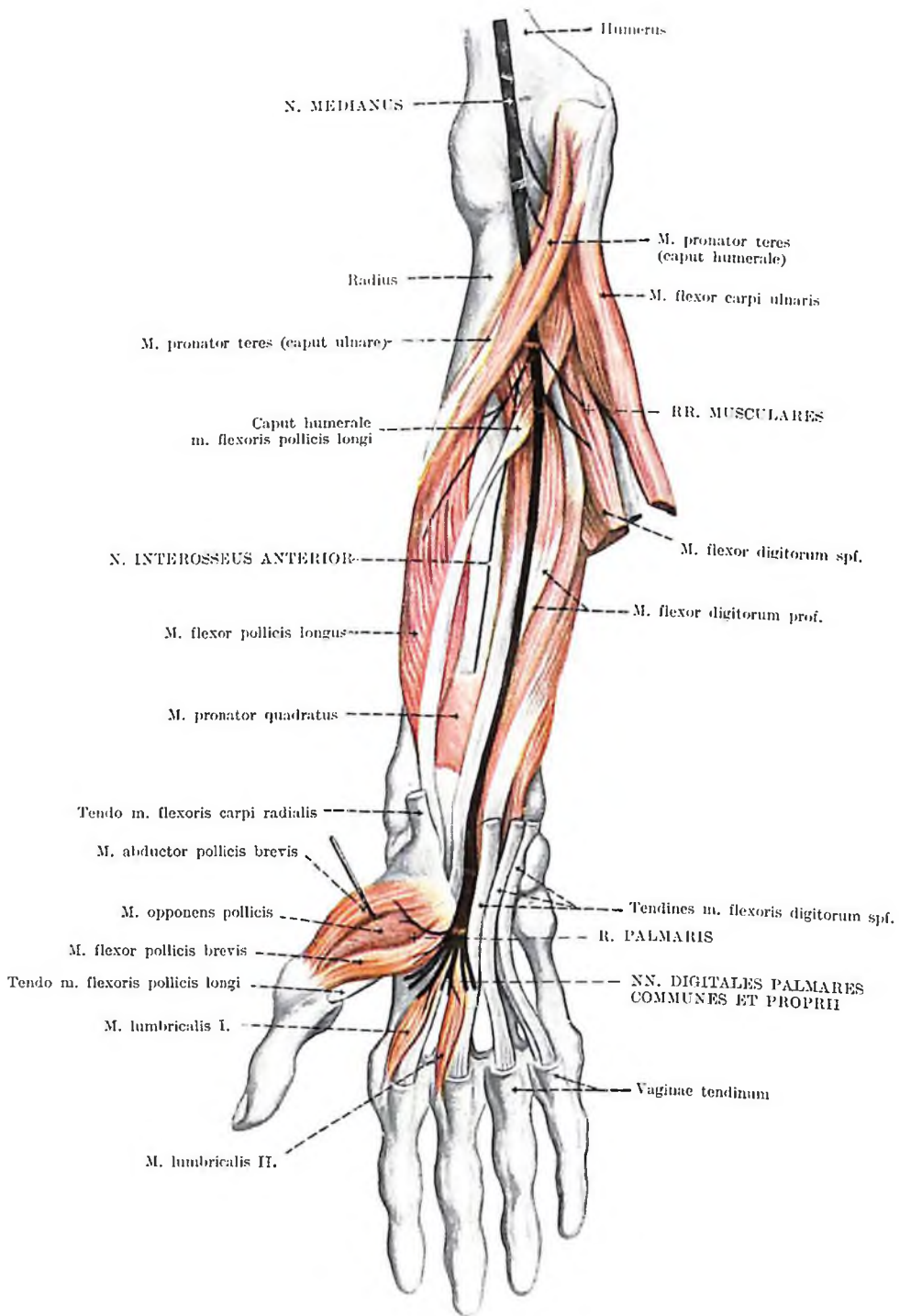


Fig. 130. NERVUS MEDIANUS
(musculi flexores antebrachii et palmares)

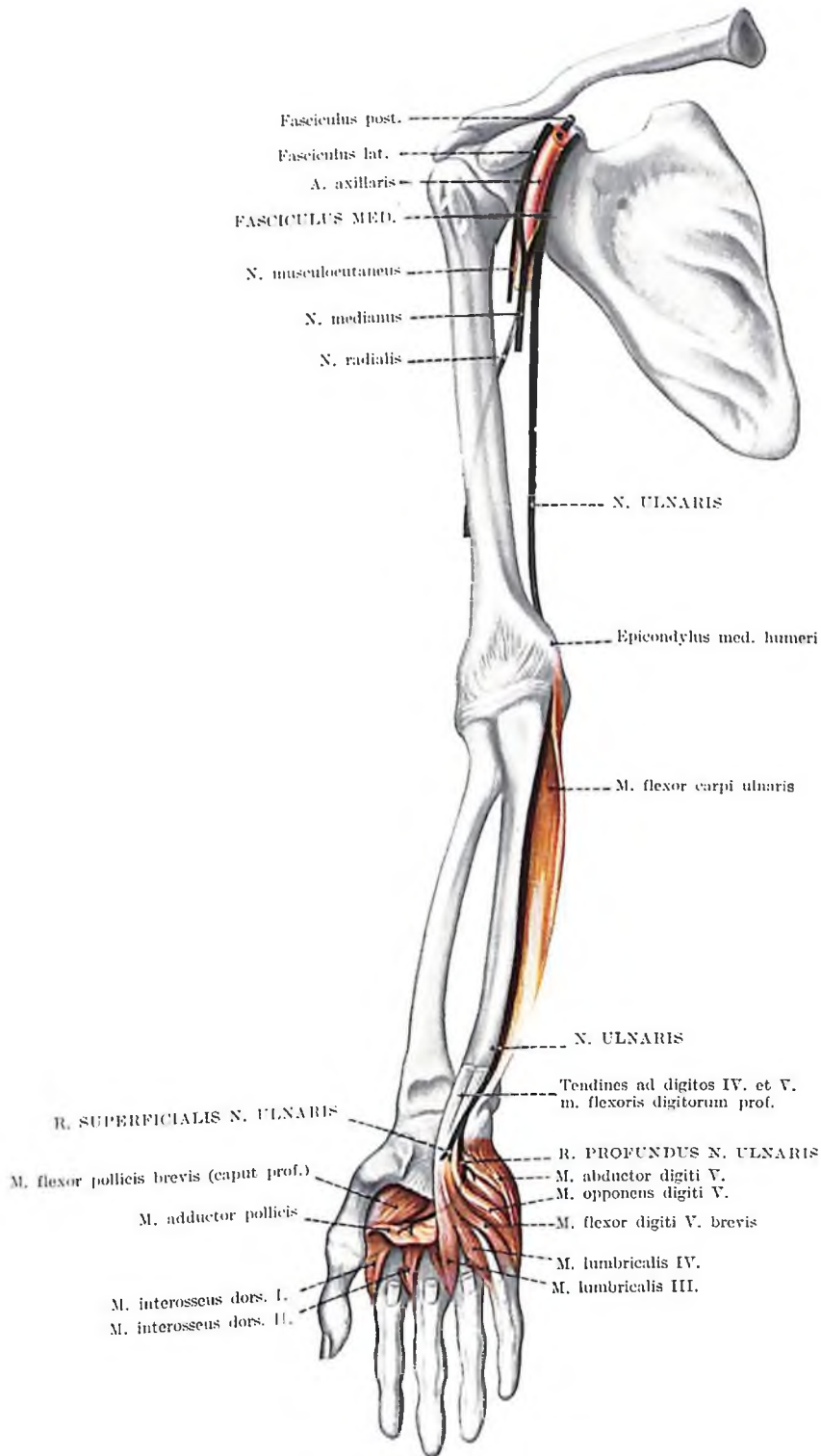


Fig. 131. NERVUS ULNARIS
(musculi flexores antebrachii et palmares)

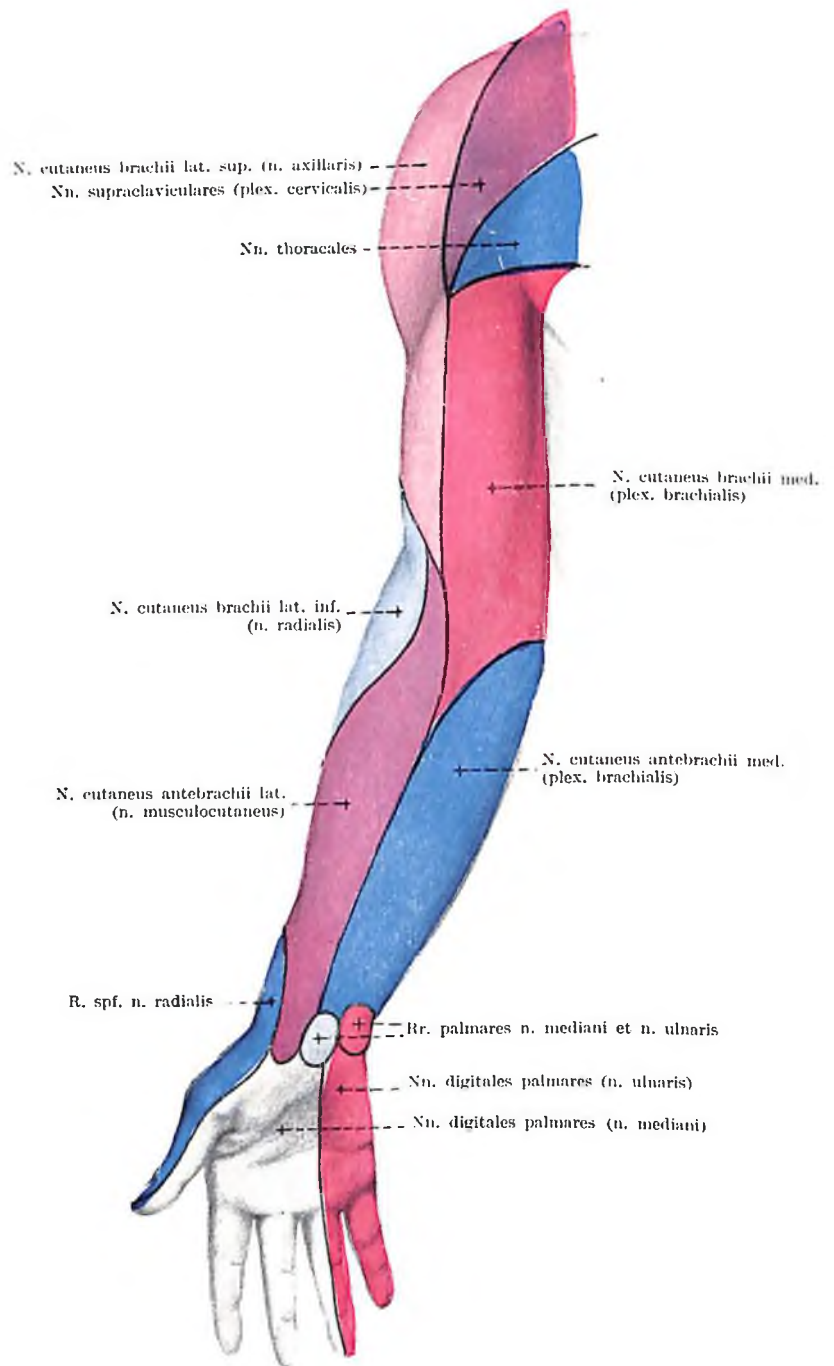


Fig. 132. NERVI CUTANEI MEMBRI SUPERIORIS I.
 (innervatio peripherica, aspectus anterior)

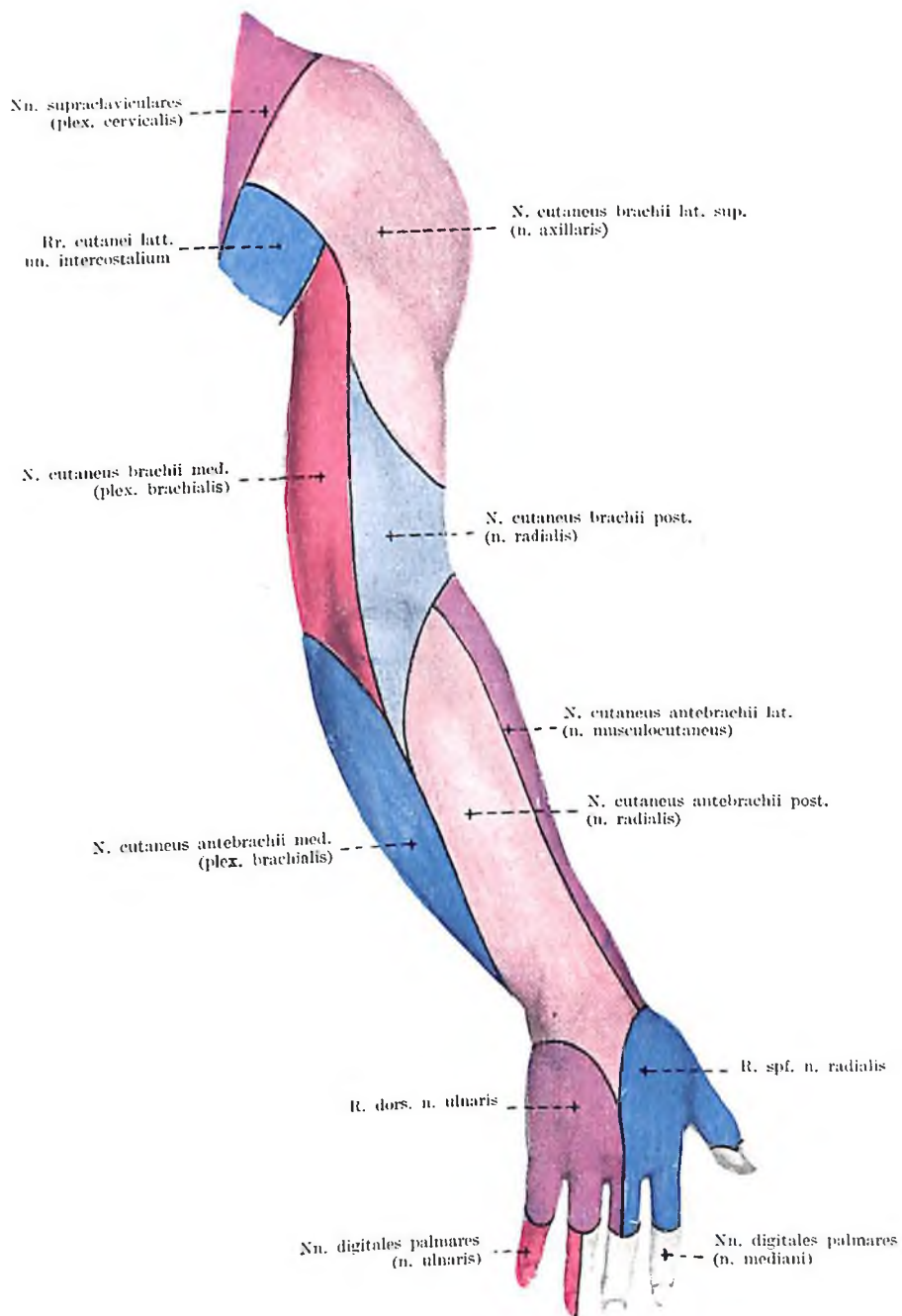


Fig. 133. NERVI CUTANEI MEMBRI SUPERIORIS II.
 (innervatio peripherica, aspectus posterior)

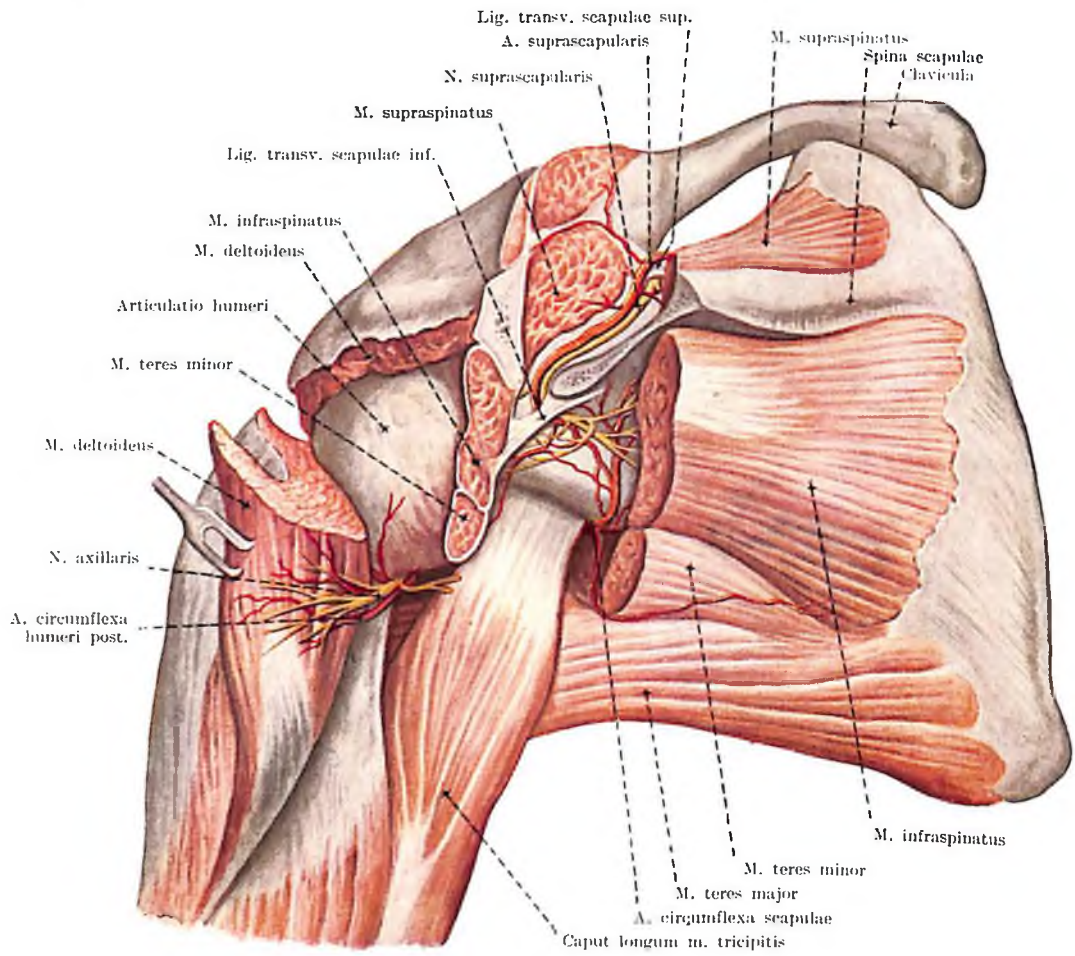


Fig. 134. ARTERIAE ET NERVI POSTERIORES MEMBRI SUPERIORIS I.
(regiones deltoidea et scapularis, 1. sin.)

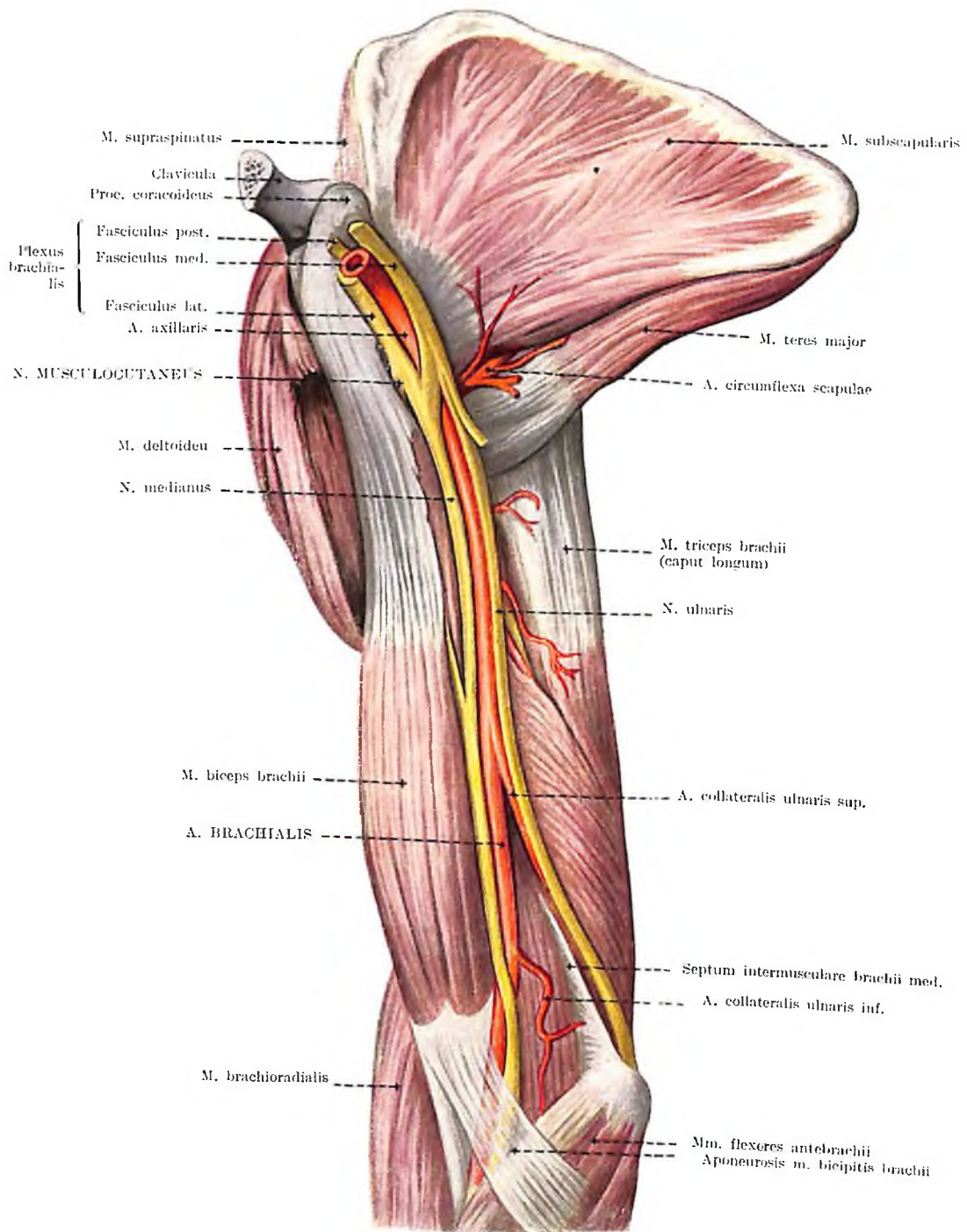


Fig. 136. ARTERIAE ET NERVI ANTERIORES BRACHII I.
(regio brachii anterior, stratum superficiale)

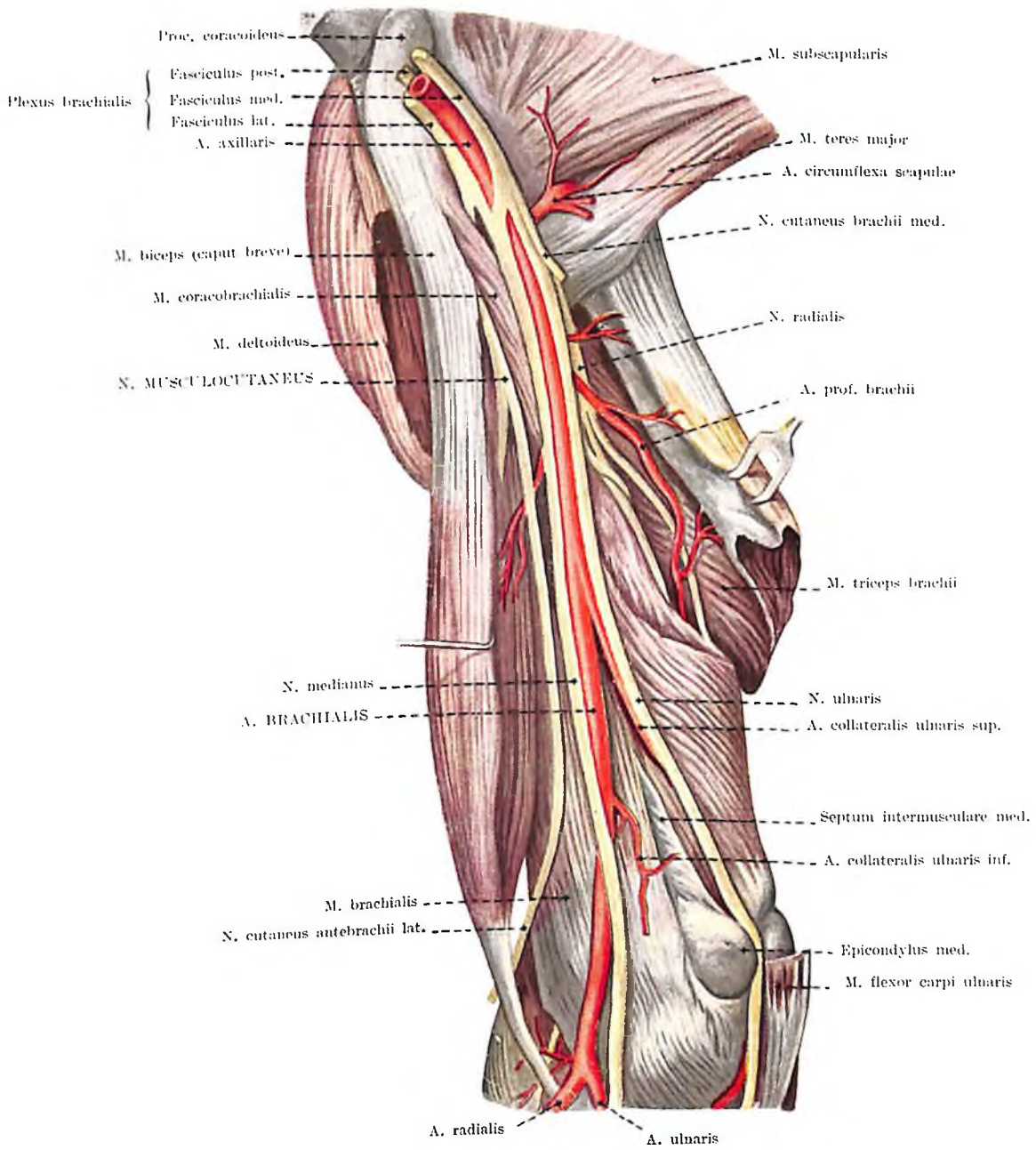


Fig. 137. ARTERIAE ET NERVI ANTERIORES BRACHII II.
(regio brachii anterior, stratum profundum)

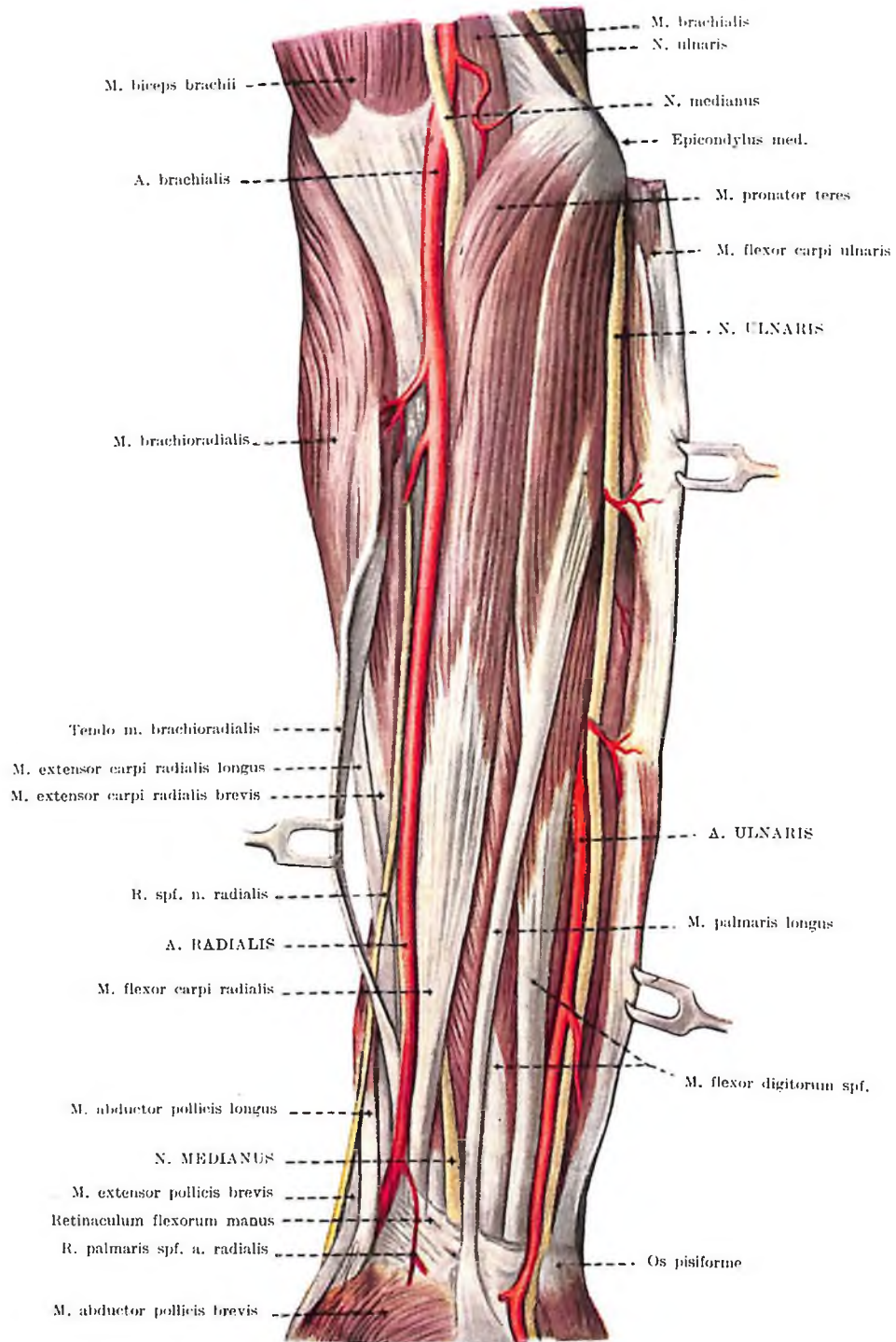


Fig. 138. ARTERIAE ET NERVI ANTERIORES ANTEBRACHII I.
 (fossa cubitalis et regio antebrachii anterior, stratum superficiale)

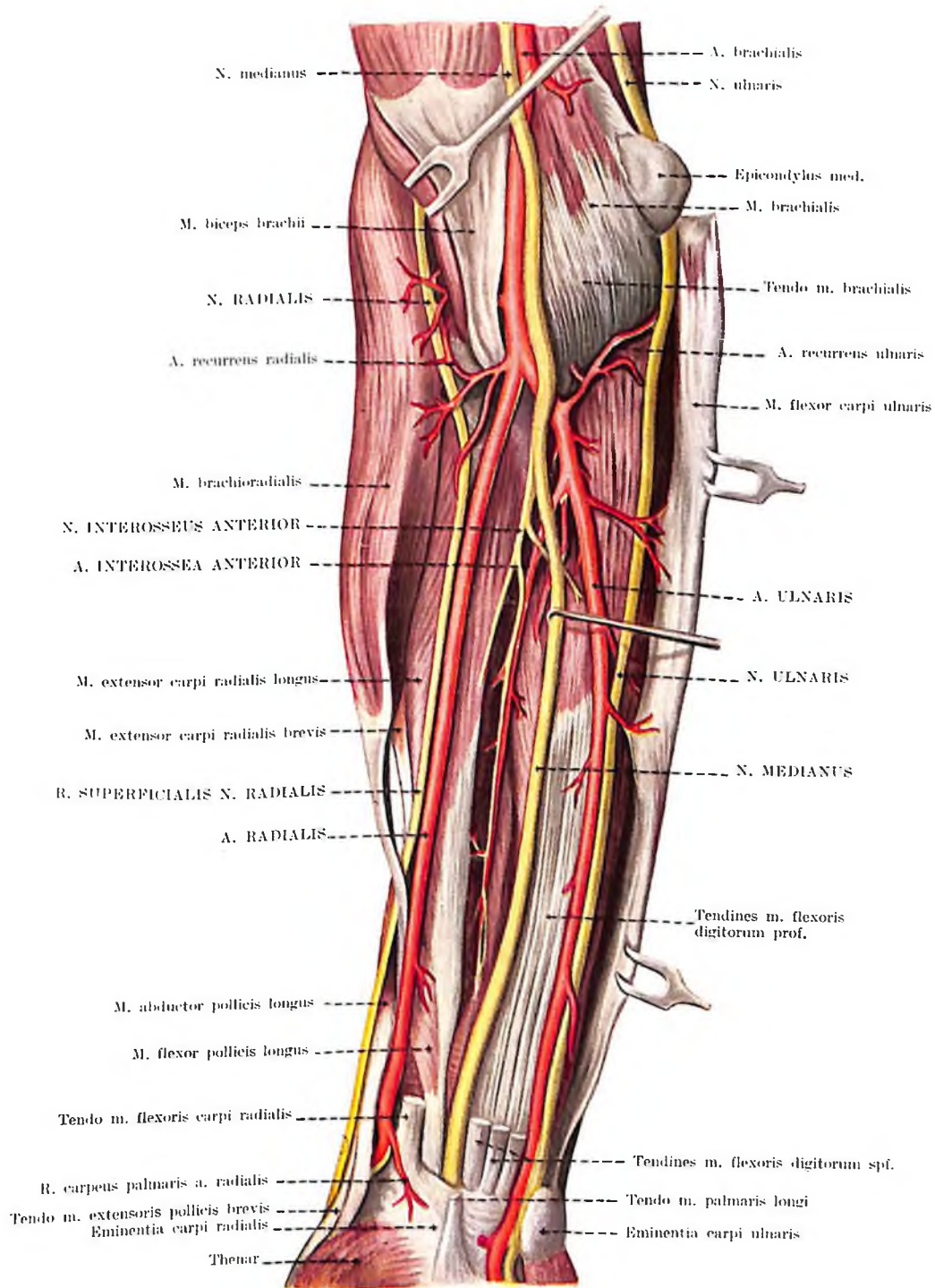


Fig. 139. ARTERIA ET NERVI ANTERIORES ANTEBRACHII II.
 (regiones cubiti et antebrachii anteriores, stratum profundum)

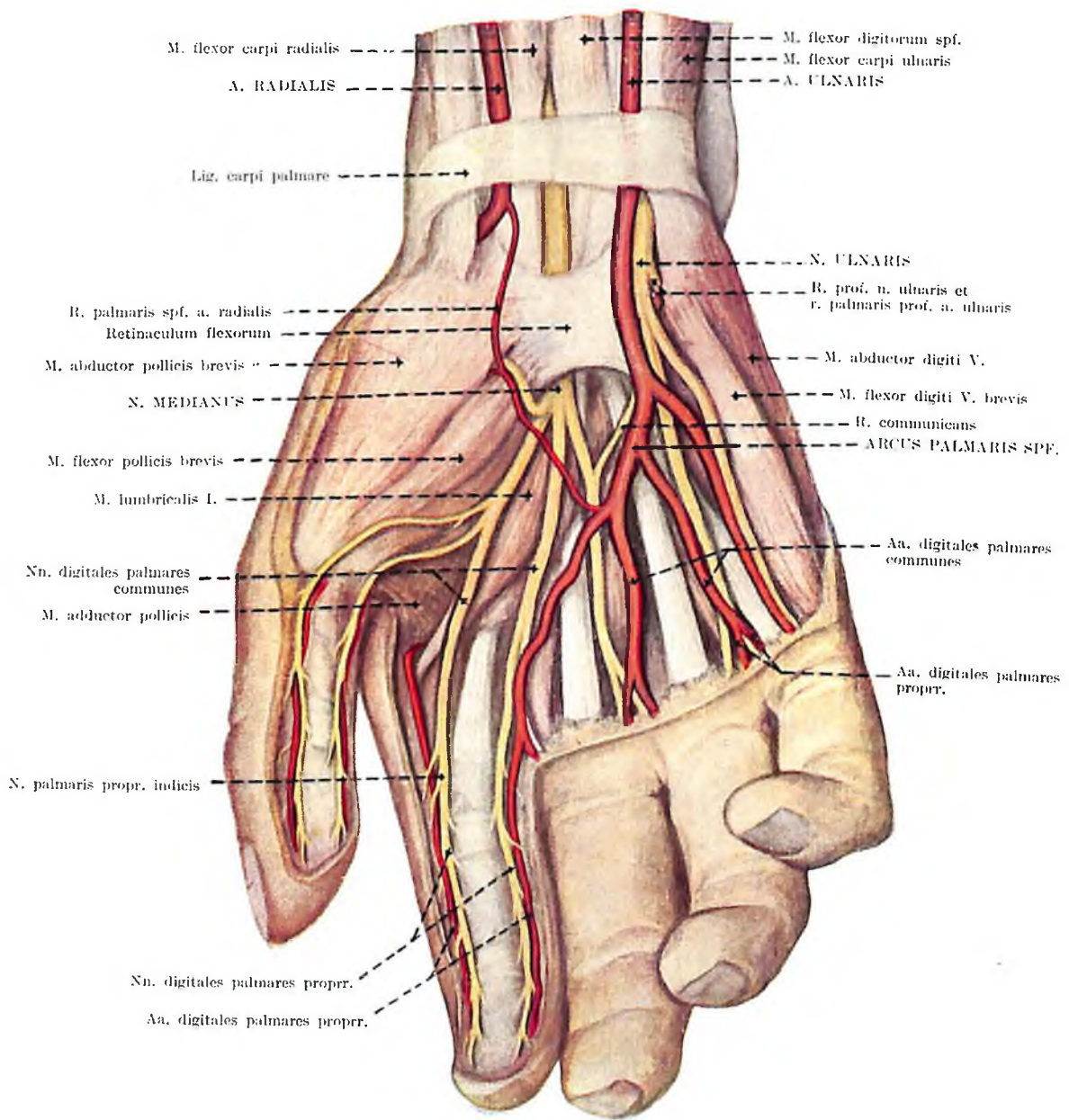


Fig. 140. ARTERIAE ET NERVI PALMAE MANUS I.
(stratum superficiale)

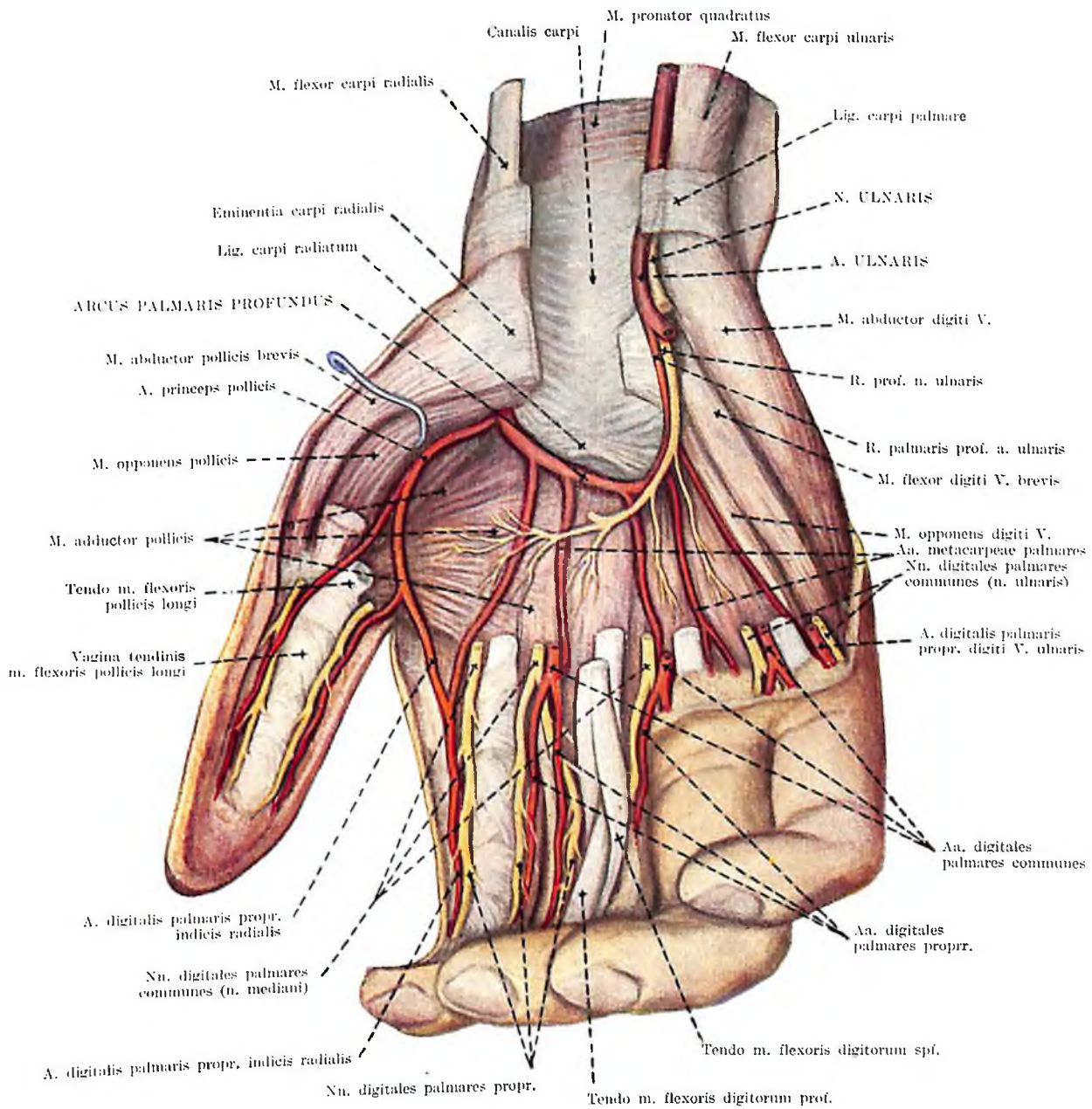


Fig. 141. ARTERIAE ET NERVI PALMAE MANUS II.
(stratum profundum)

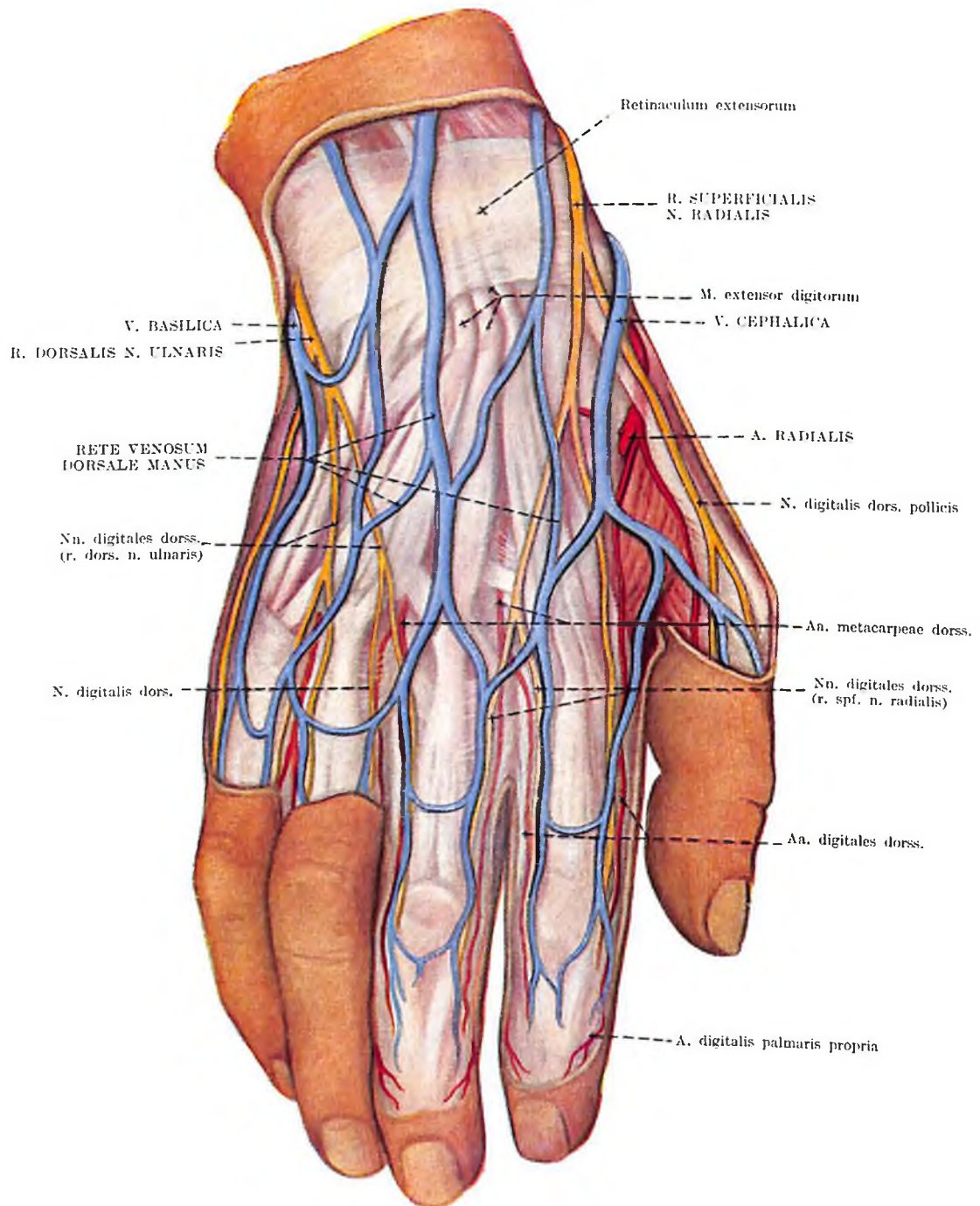


Fig. 142. ARTERIAE, VENAE ET NERVI DORSI MANUS I.
(aspectus dorsalis)

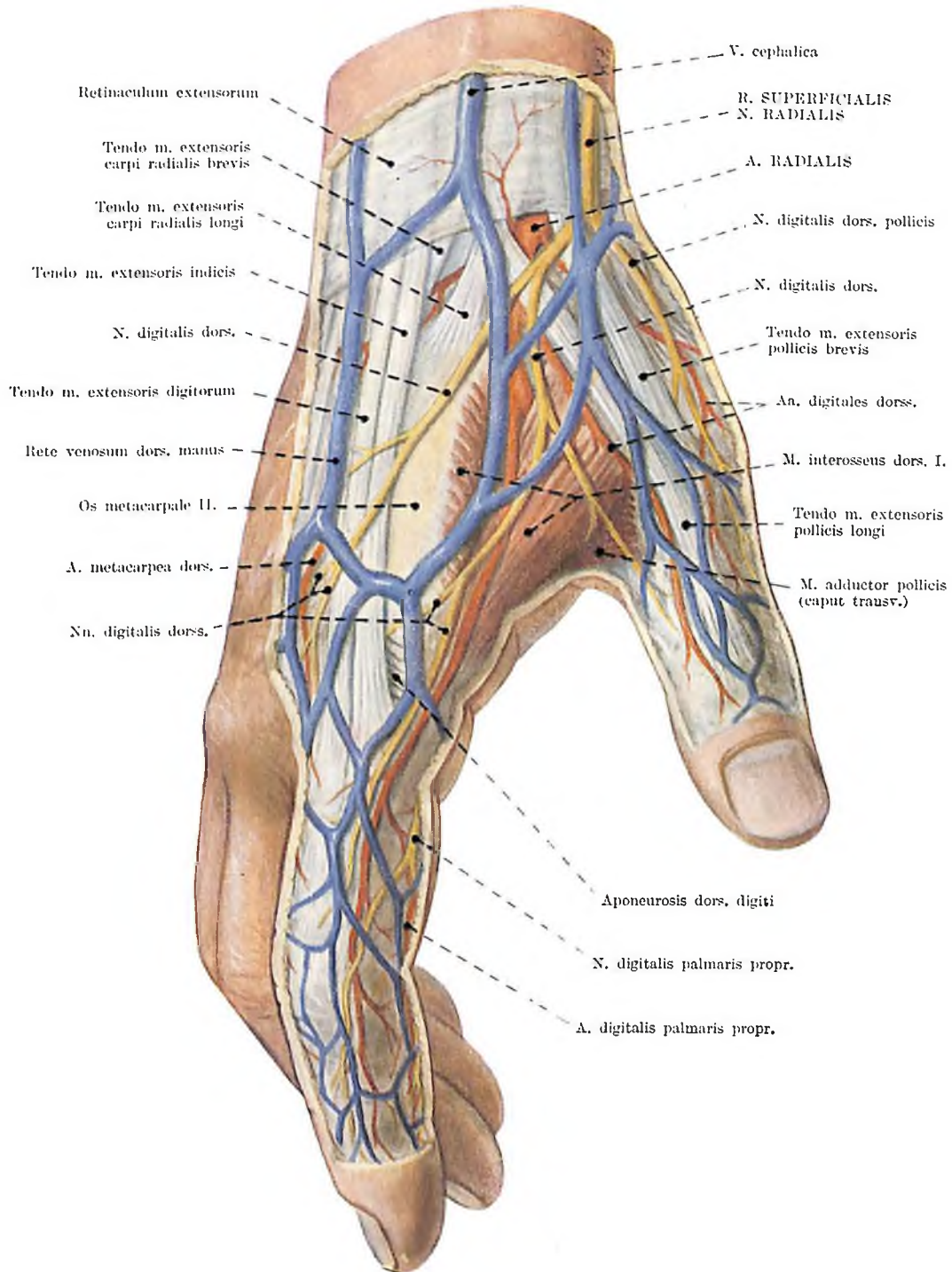


Fig. 143. ARTERIAE, VENAE ET NERVI DORSI MANUS II.
(aspectus radialis)

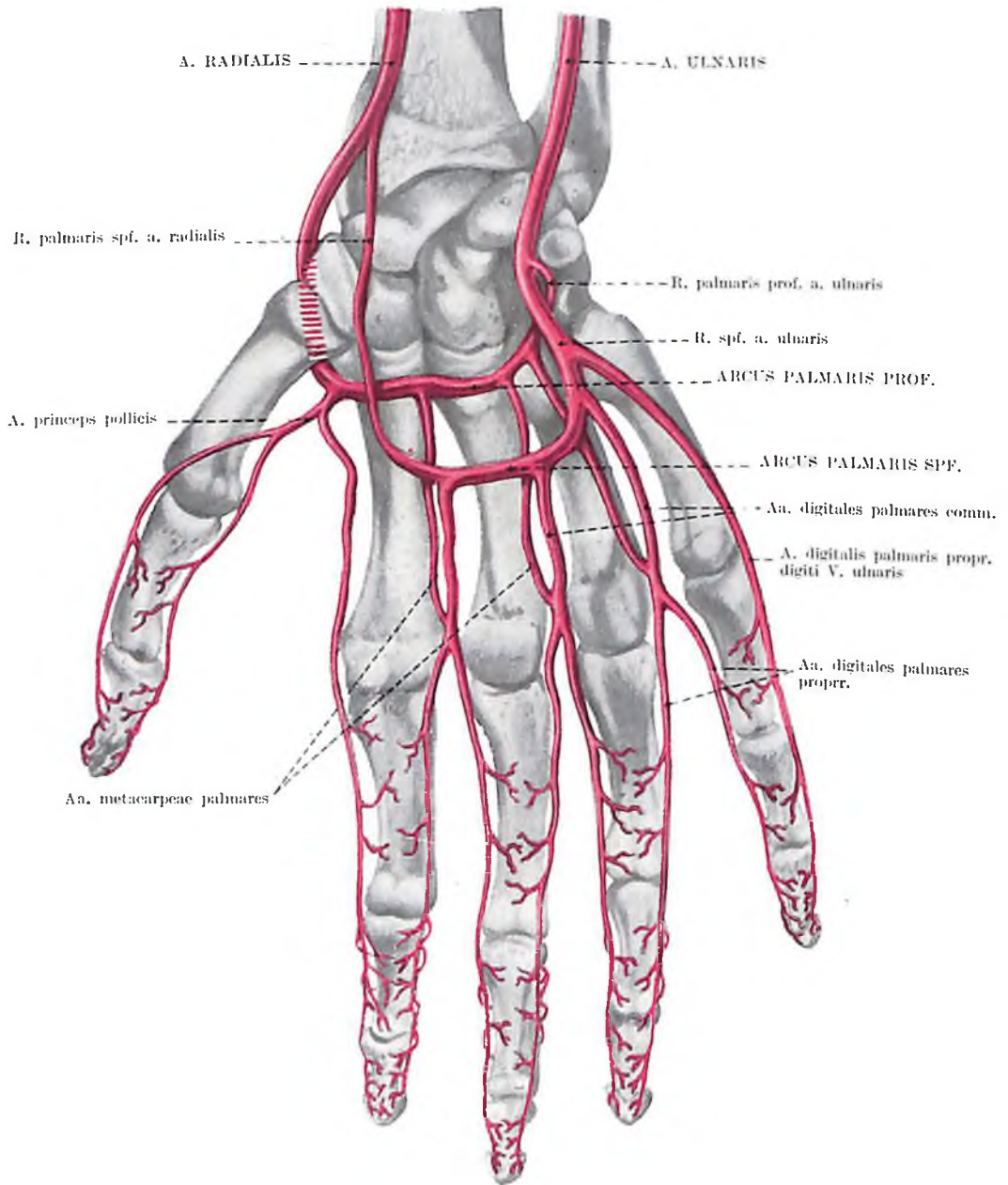


Fig. 144. ARTERIAE MANUS
(arcus palmares)

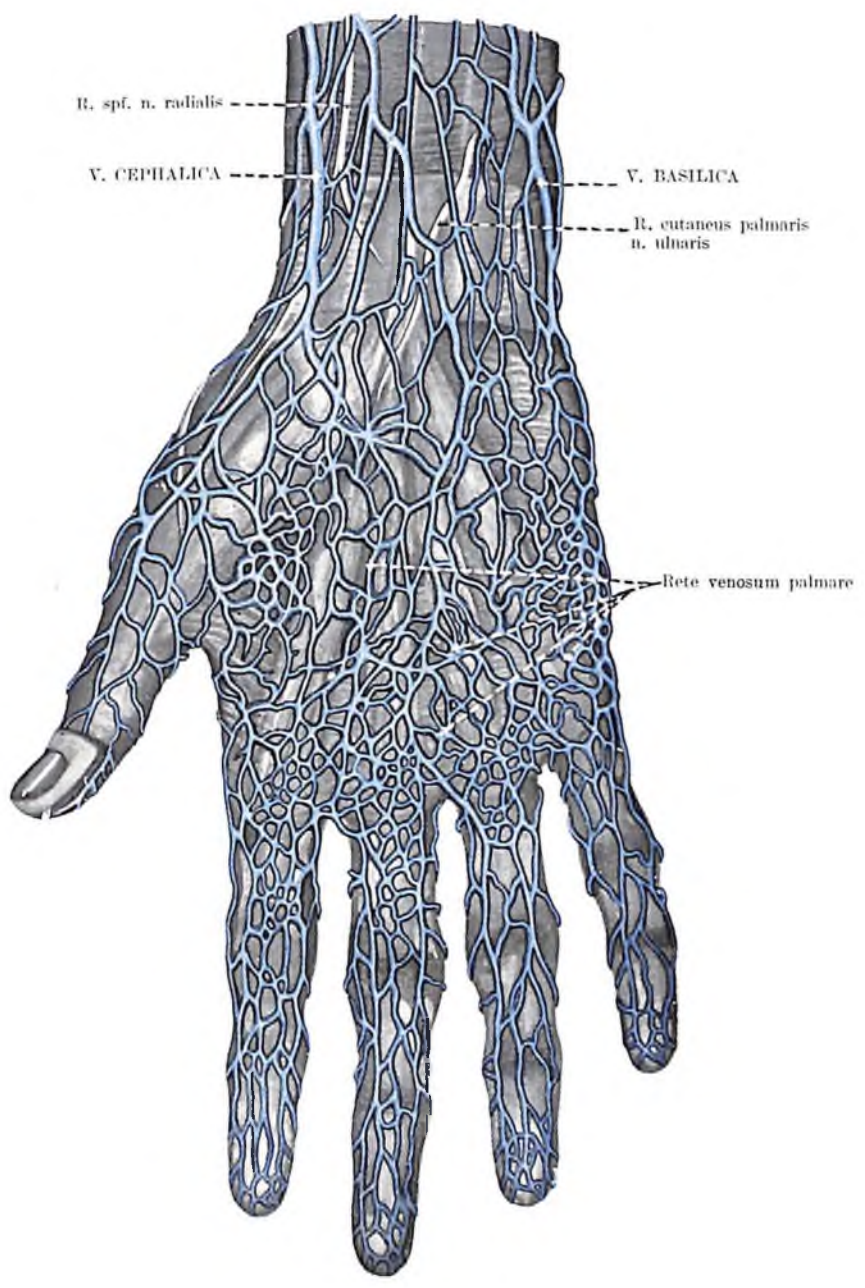


Fig. 145. VENAE MANUS
(rete venosum palmare)

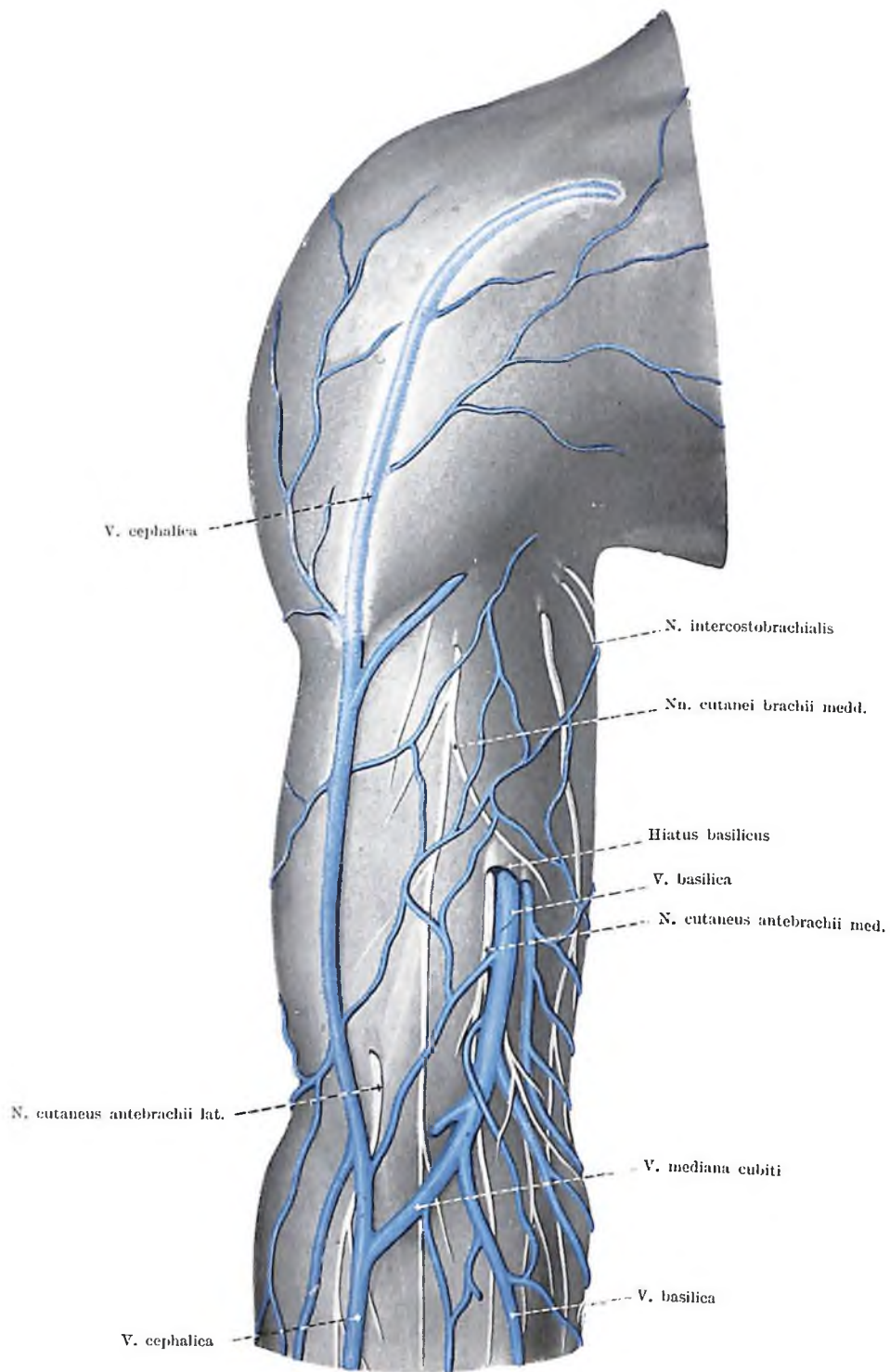


Fig. 146. VENAE SUPERFICIALES ET NERVI CUTANEI BRACHII

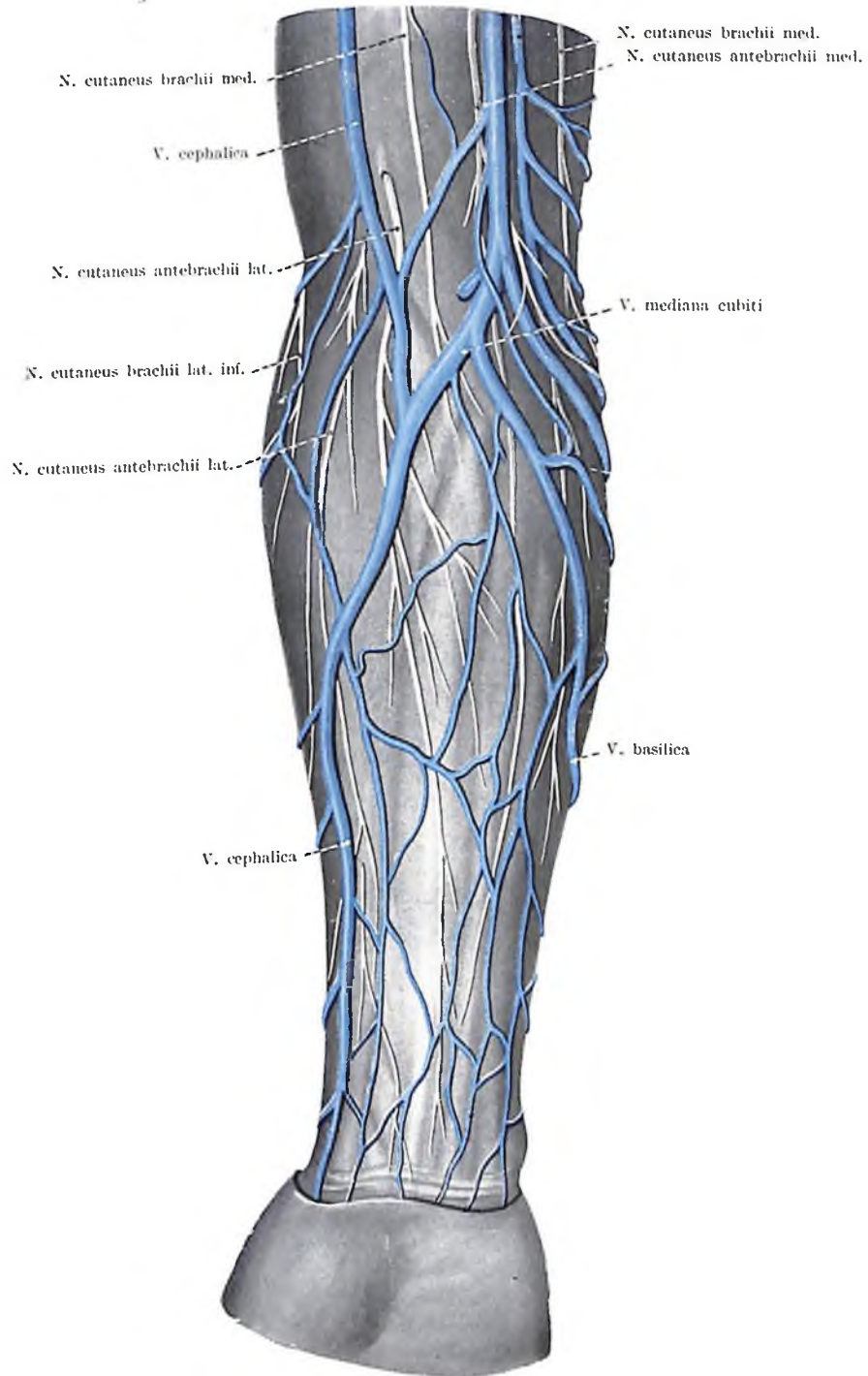


Fig. 147. VENAE SUPERFICIALES ET NERVI CUTANEI ANTEBRACHII

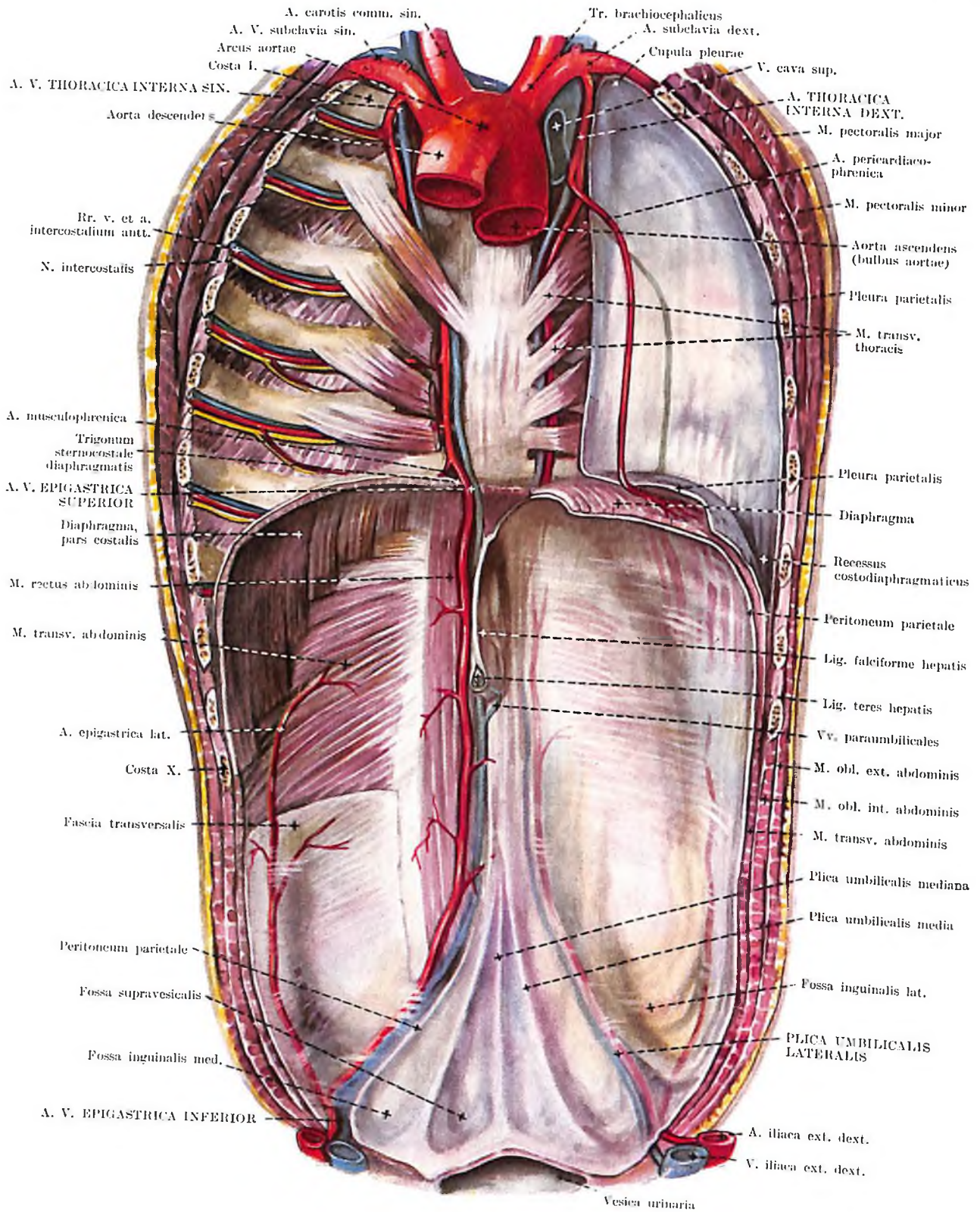


Fig. 148. ARTERIAE ET NERVI PARIETIS ANTERIORIS TRUNCI
 (arteriae thoracica interna et epigastricae, aspectus posterior)

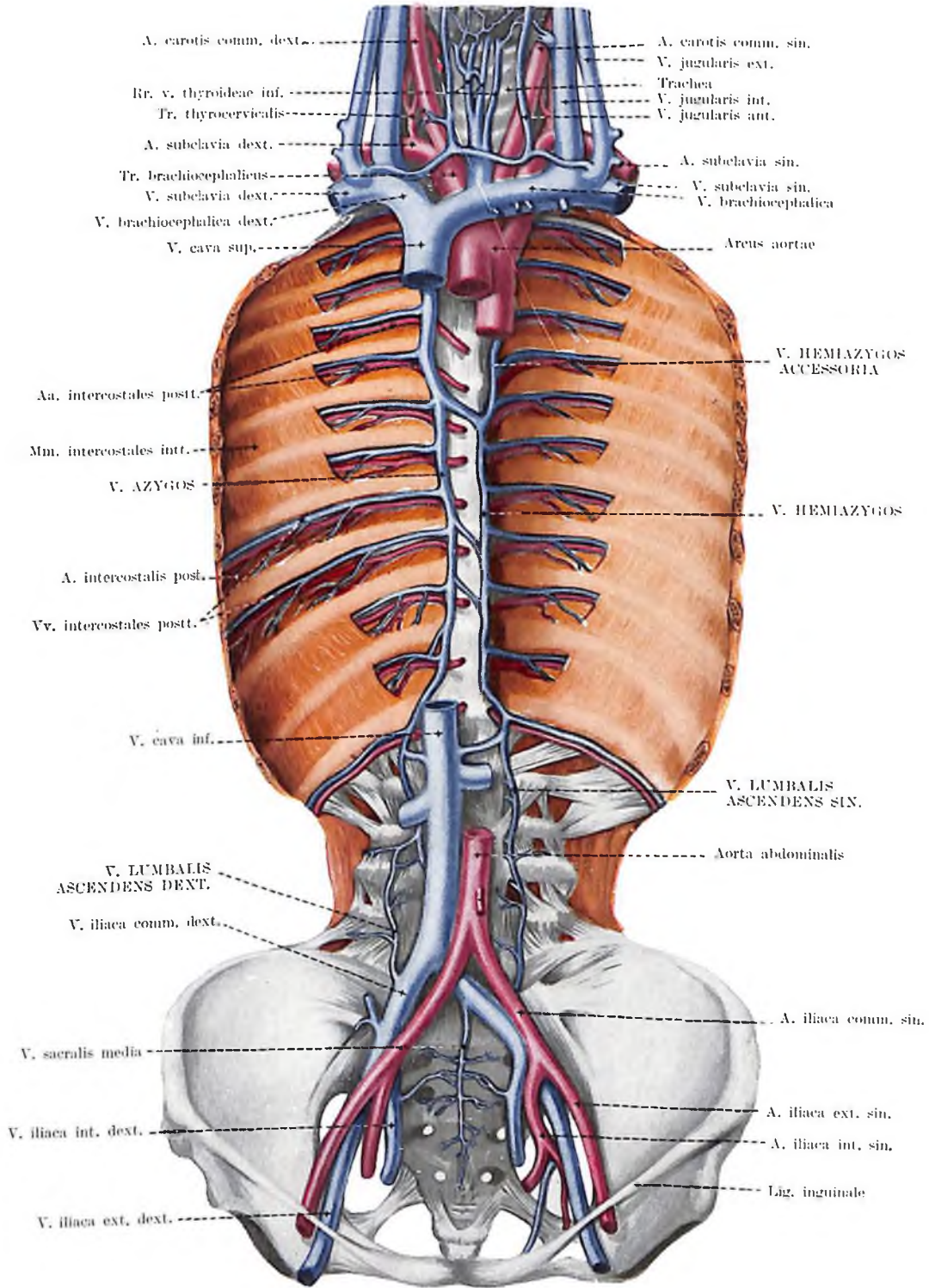


Fig. 149. VENAE PARIETIS POSTERIORIS TRUNCI
(vena azygos)

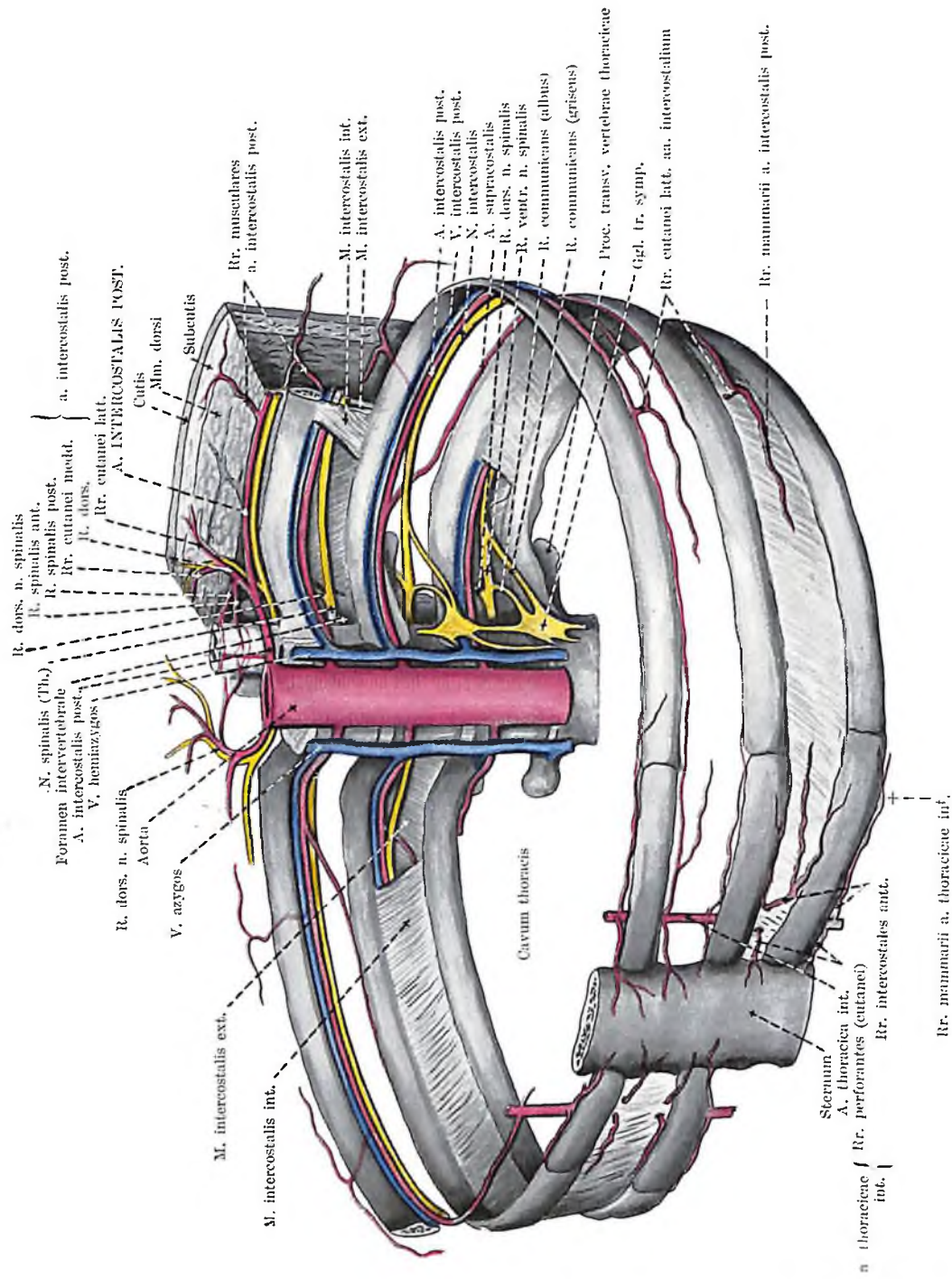


Fig. 150. ARTERIAE, VENAE ET NERVI INTERCOSTALES
(structura parietis thoracis)

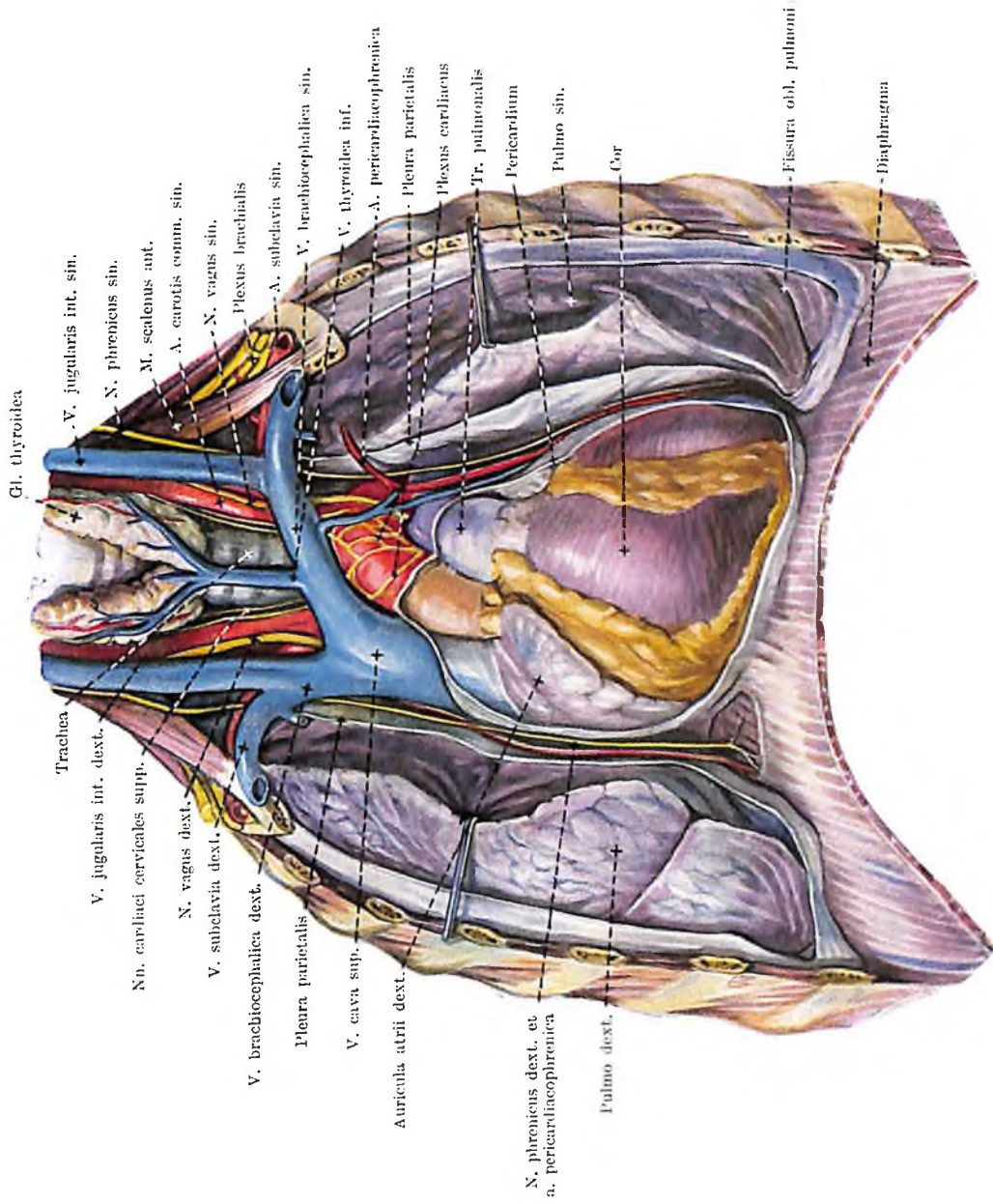


Fig. 151. ARTERIAE, VENAE ET NERVI THORACIS I.
(mediastinum anterior)

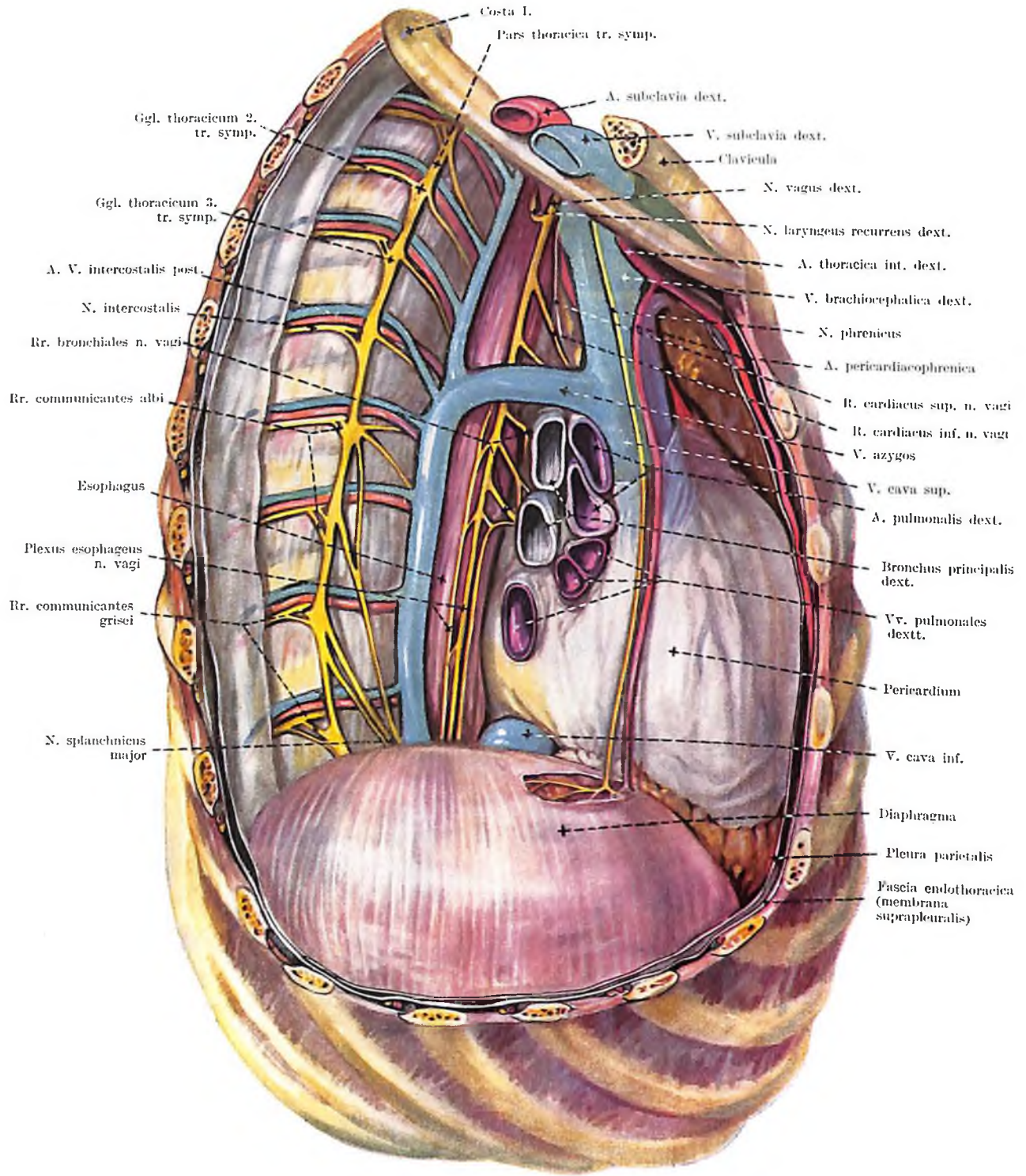


Fig. 152. ARTERIAE, VENAE ET NERVI THORACIS II.
(cavum pleurae dextrum et mediastinum)

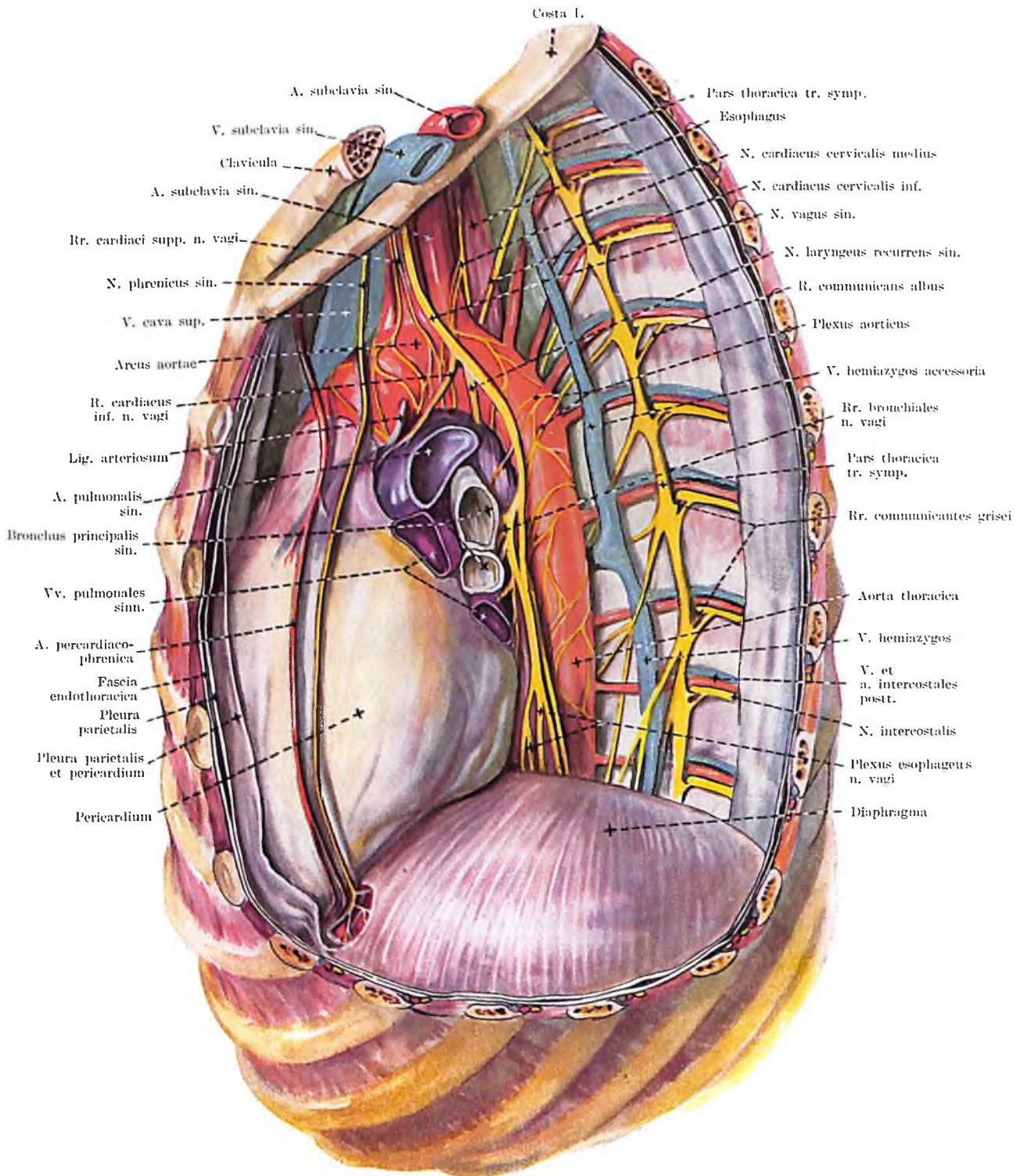


Fig. 153. ARTERIAE, VENAE ET NERVI THORACIS III.
(cavum pleurae sinistrum et mediastinum)

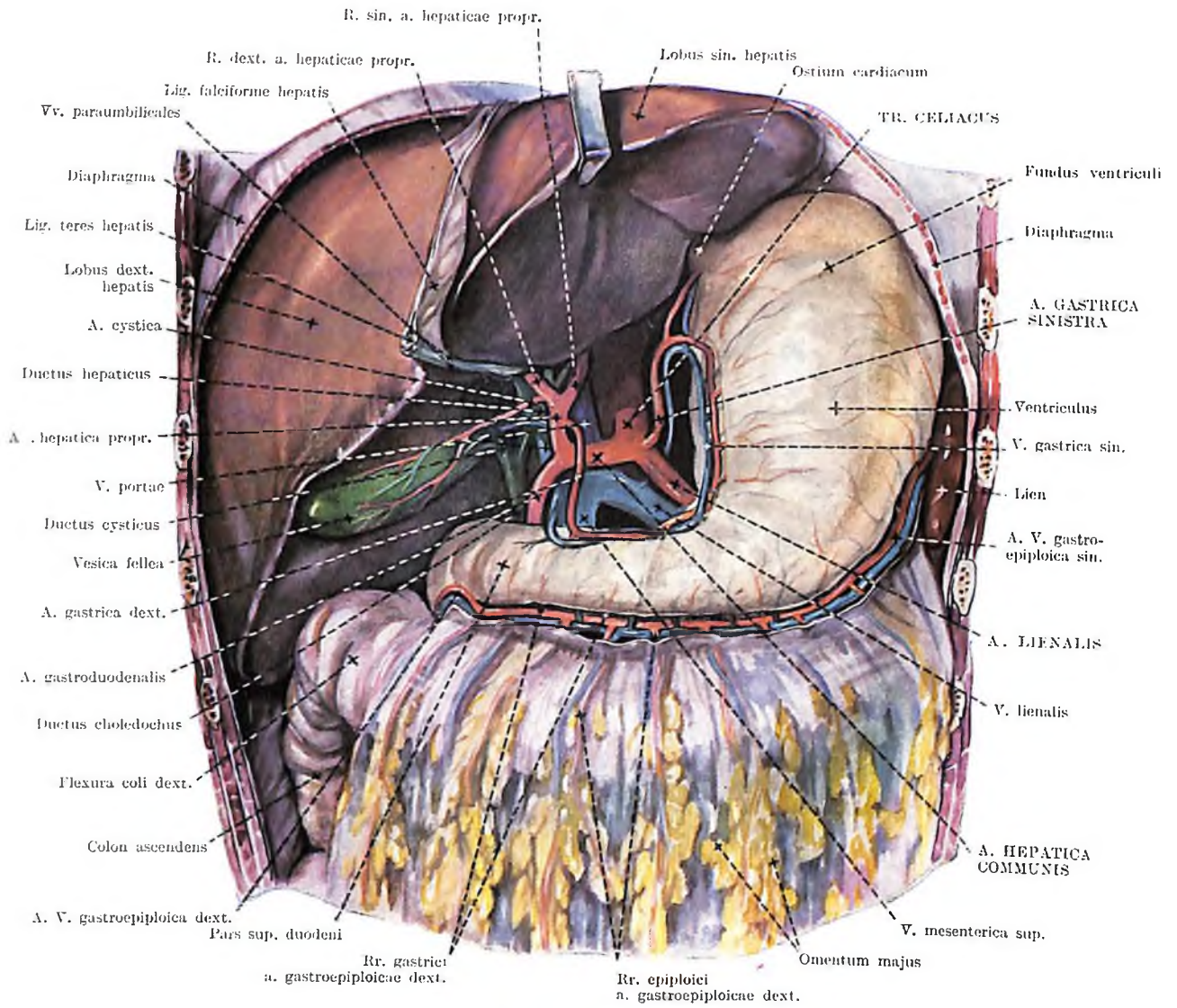


Fig. 154. ARTERIAE ET VENAE VISCERALES ABDOMINIS I,
(truncus celiacus)

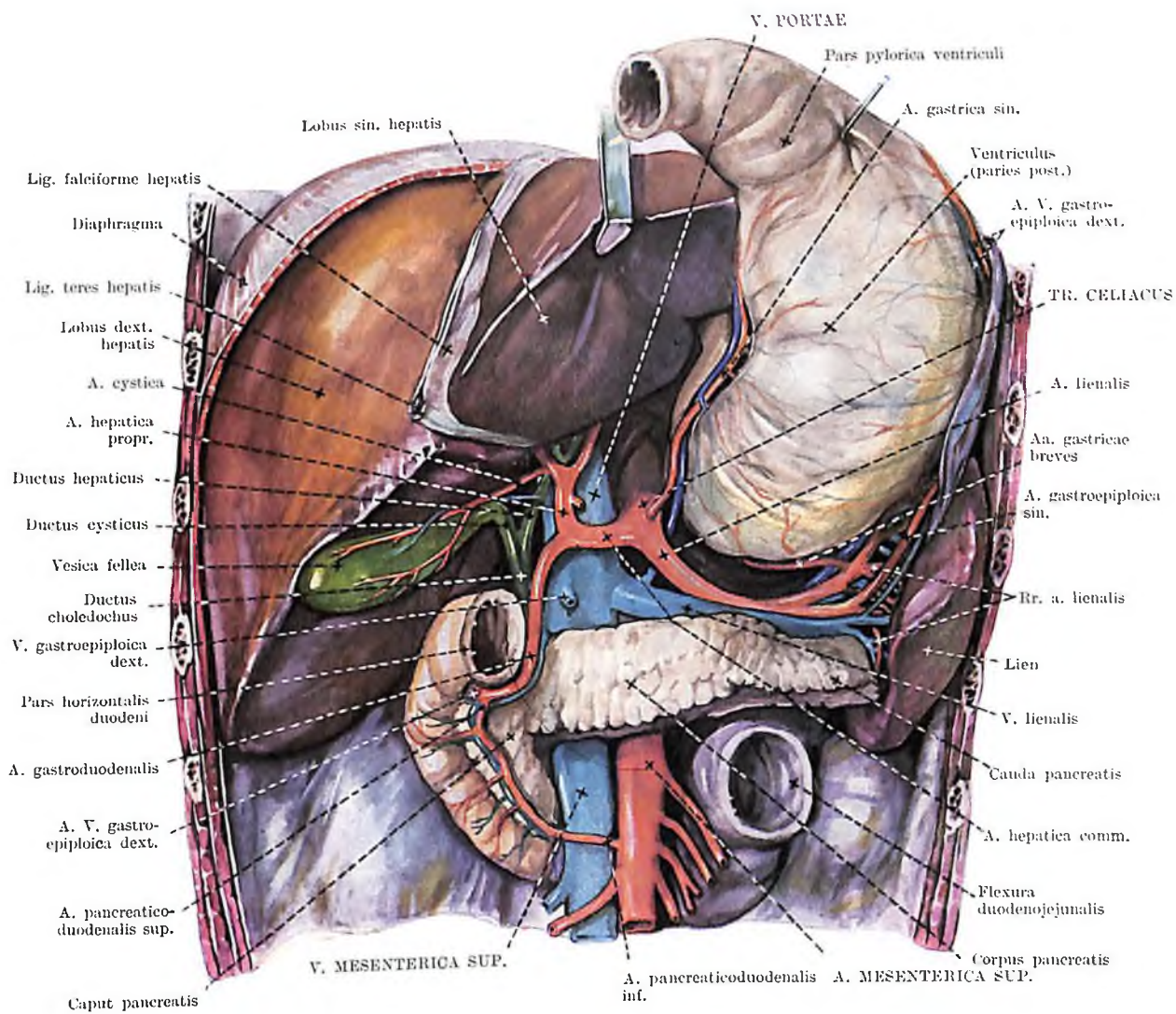


Fig. 155. ARTERIAE ET VENAE VISCERALES ABDOMINIS II.
 (truncus celiacus, arteria mesenterica superior, venae portae et mesenterica superior)

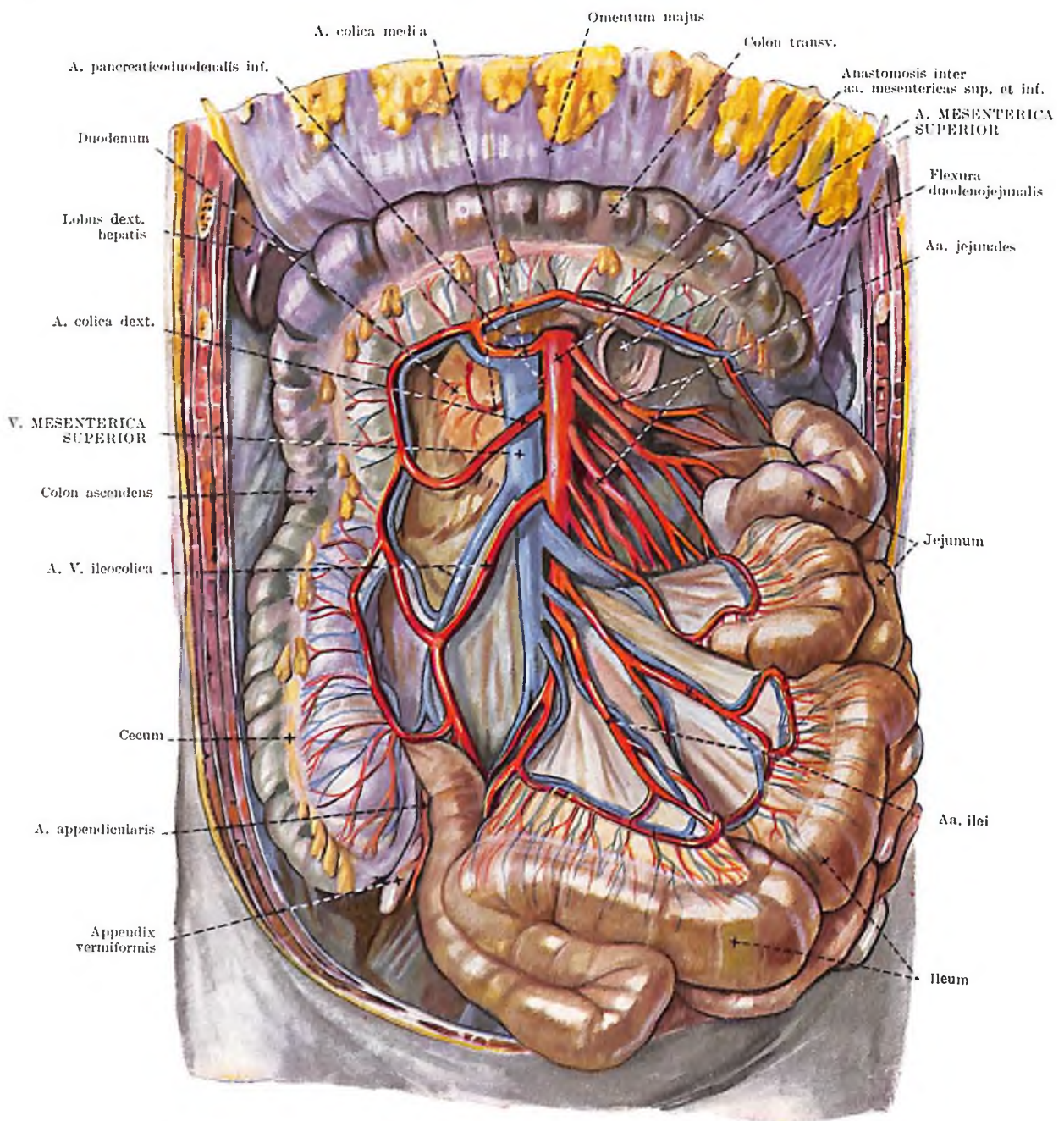


Fig. 156. ARTERIAE ET VENAE VISCERALES ABDOMINIS III.
 (arteria et vena mesentericae superiores)

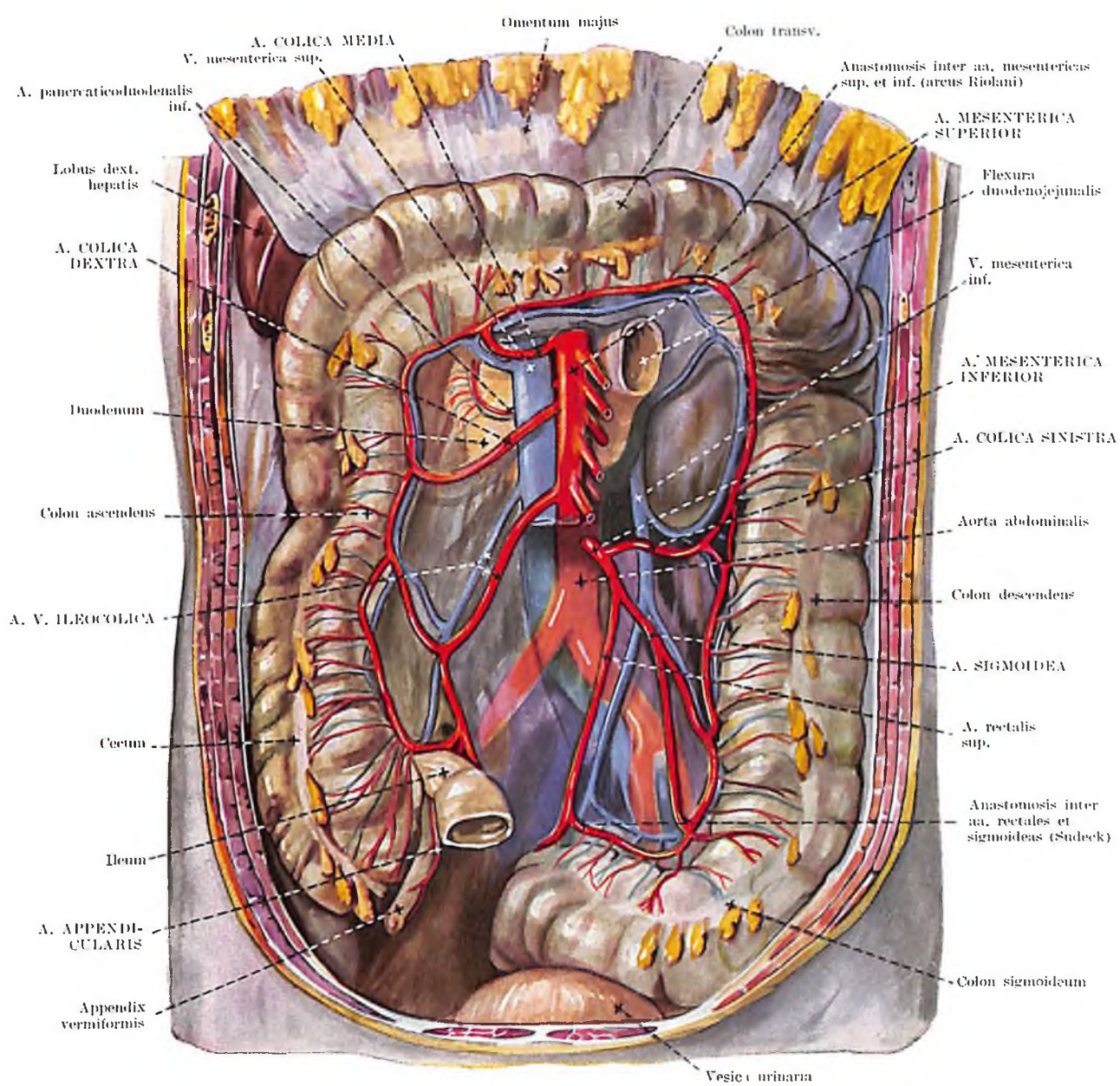


Fig. 157. ARTERIAE ET VENAE VISCERALES ABDOMINIS IV.
(vasa intestini crassi)

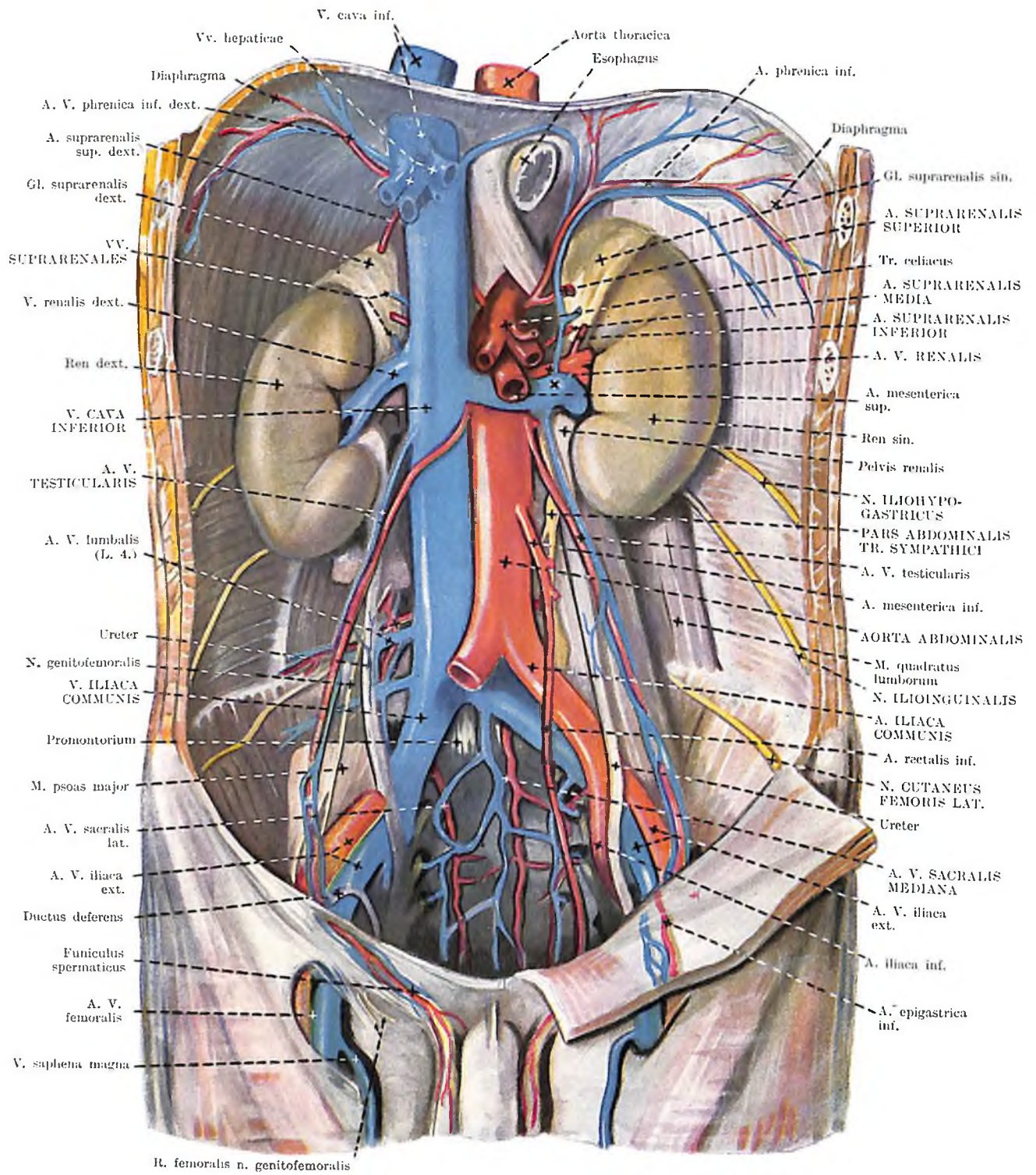


Fig. 158. ARTERIAE, VENAE ET NERVI RETROPERITONEALES
(spatium retroperitoneale, nervi lumbales)

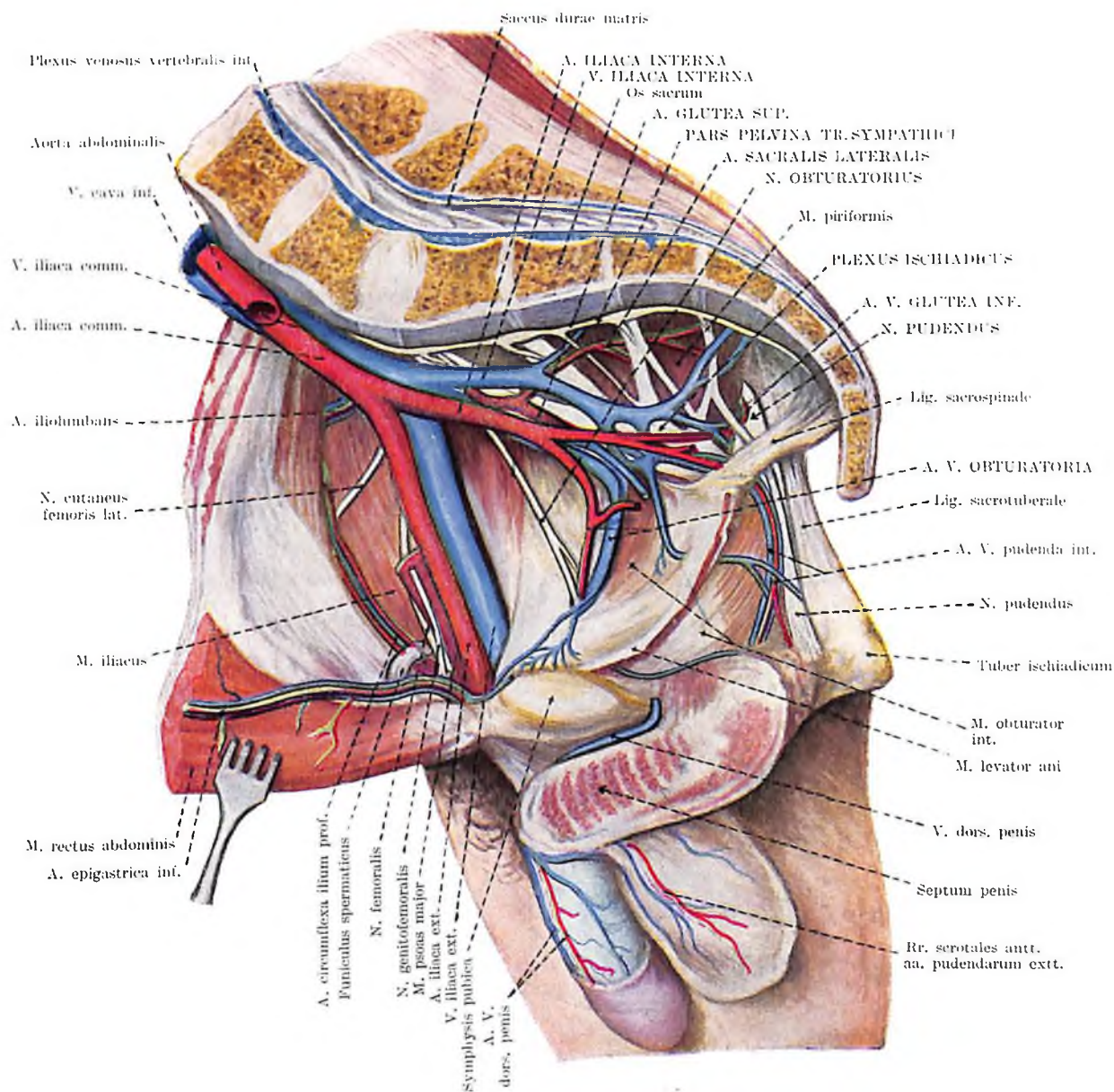


Fig. 159. ARTERIAE, VENAE ET NERVI PARIETALES PELVIS
(sectio sagittalis mediana)

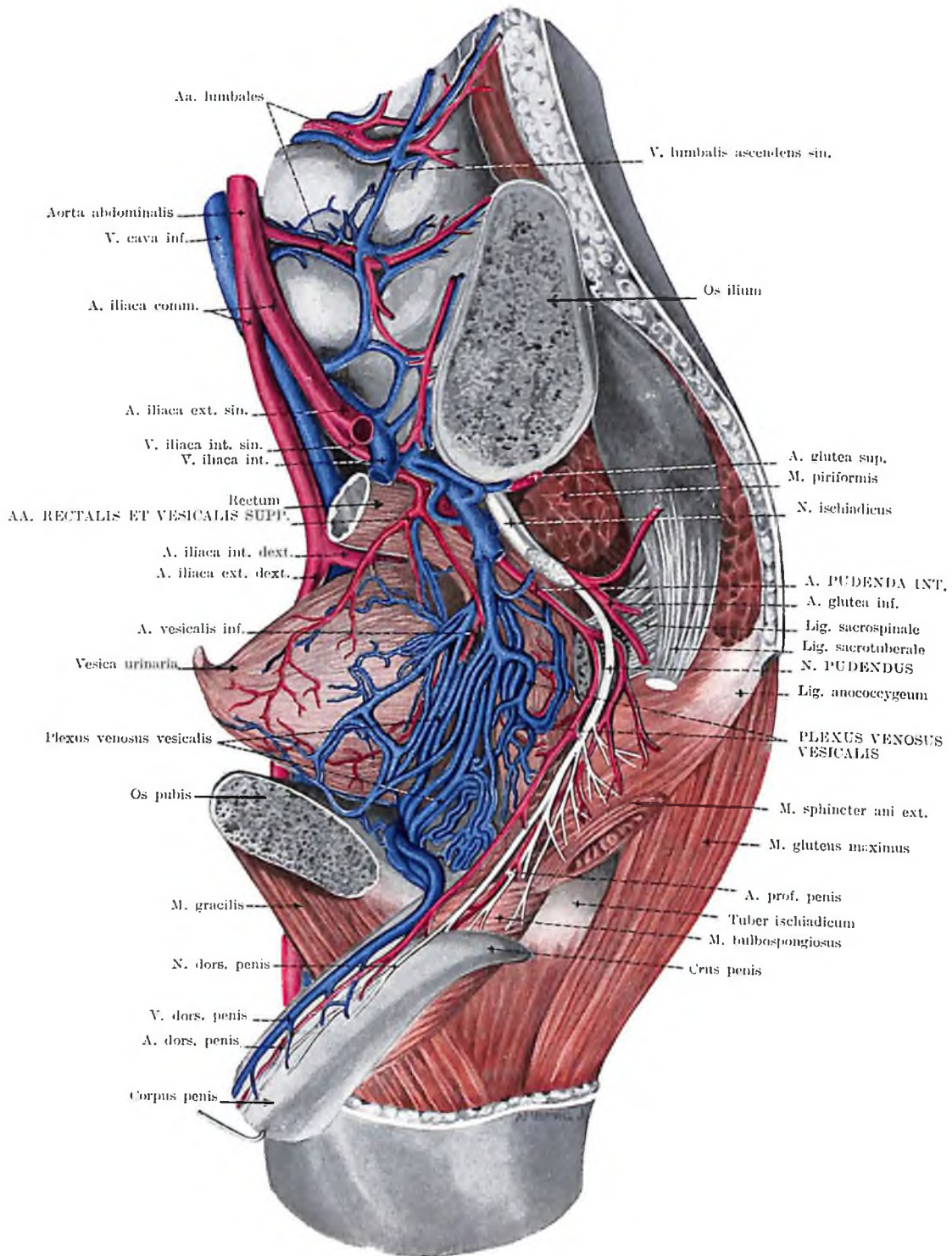


Fig. 160. ARTERIAE, VENAE ET NERVI VISCERALES PELVIS MASCULINAE
 (sectio sagittalis paramediana sin.)

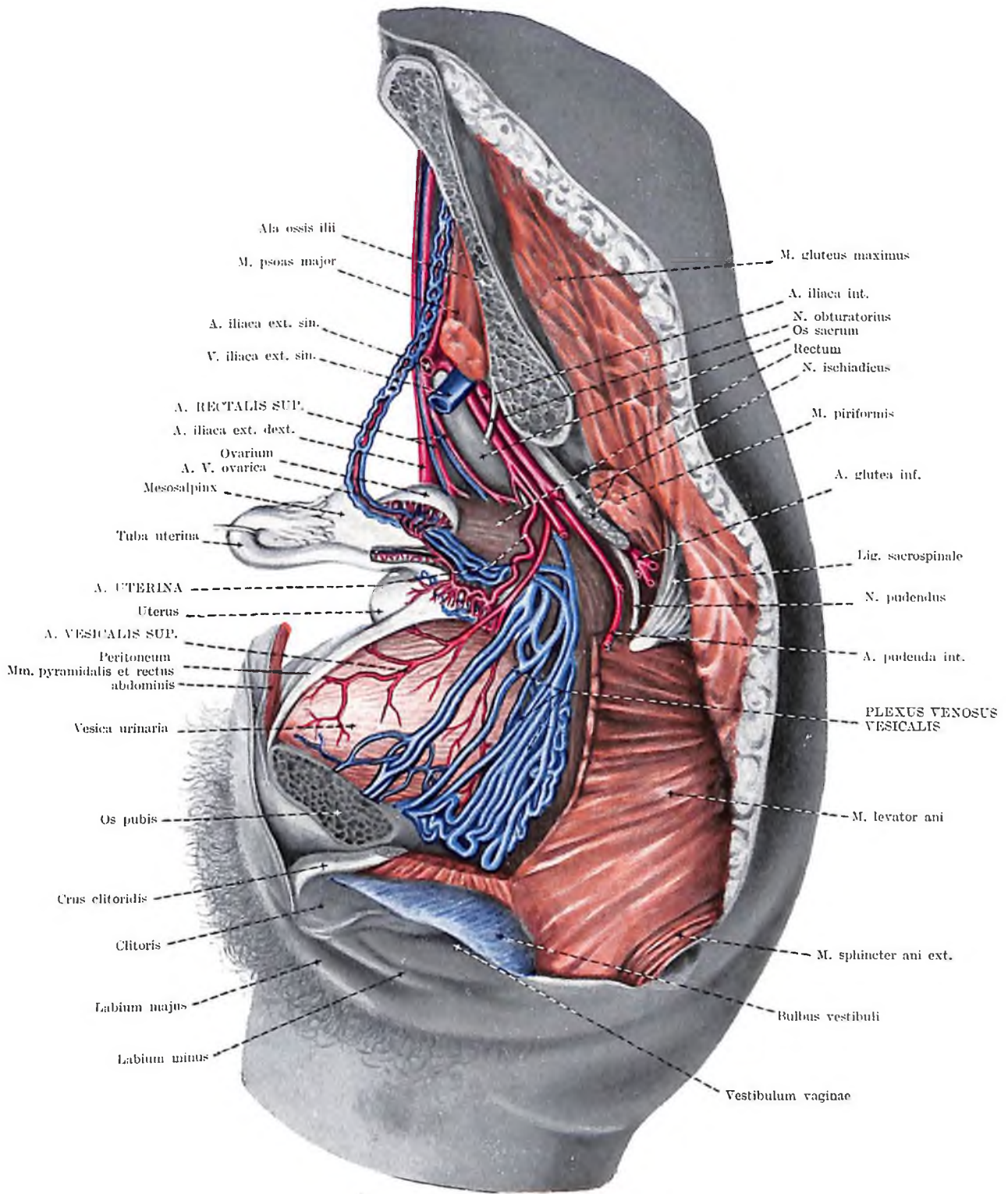


Fig. 161. ARTERIAE, VENAE ET NERVI VISCERALES PELVIS FEMININAE
(sectio sagittalis paramediana sin.)

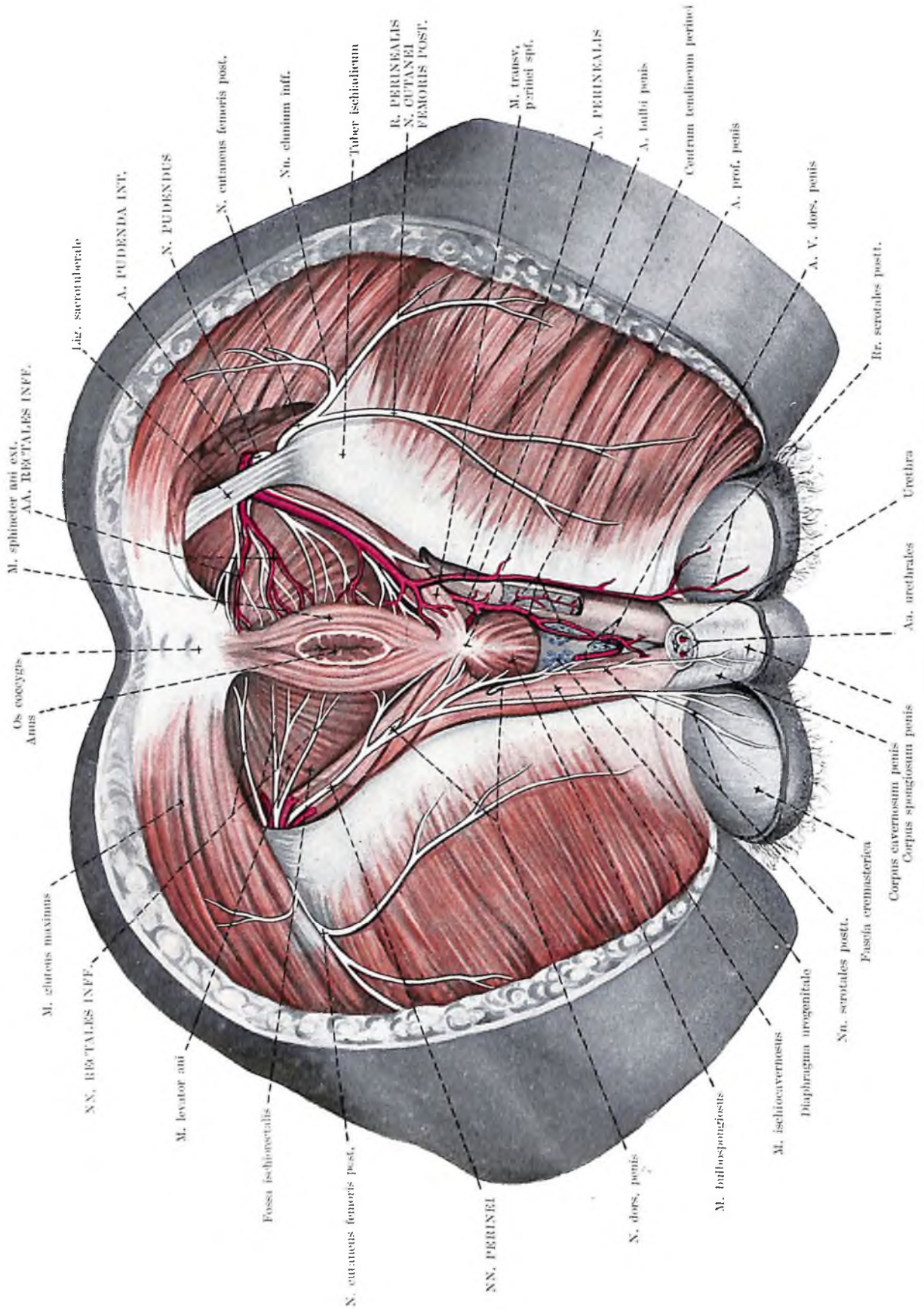


Fig. 162. ARTERIAE ET NERVI REGIONIS PERINEALIS
(regio perinealis masculina)

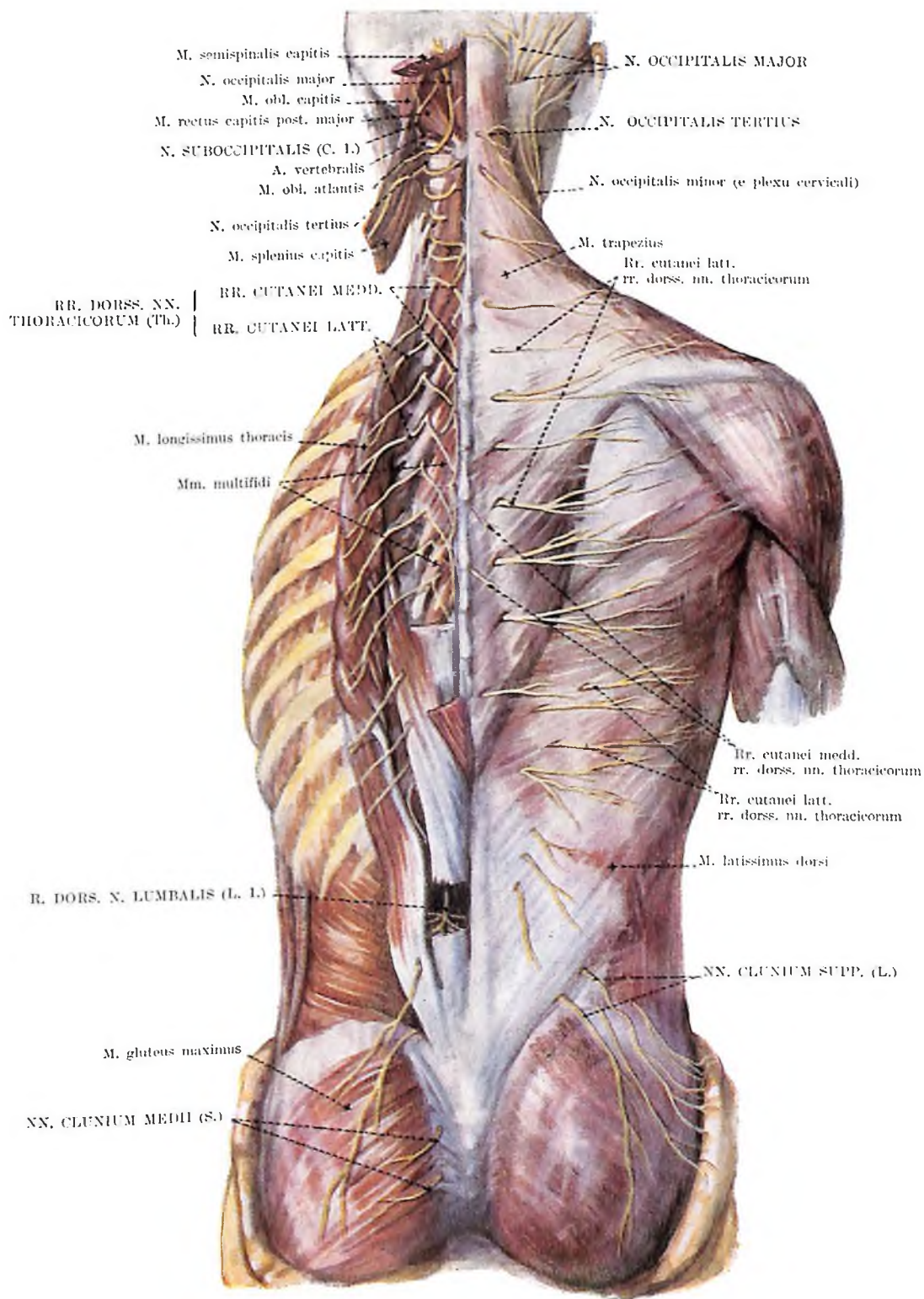


Fig. 163. RAMI DORSALES NERVORUM SPINALIUM

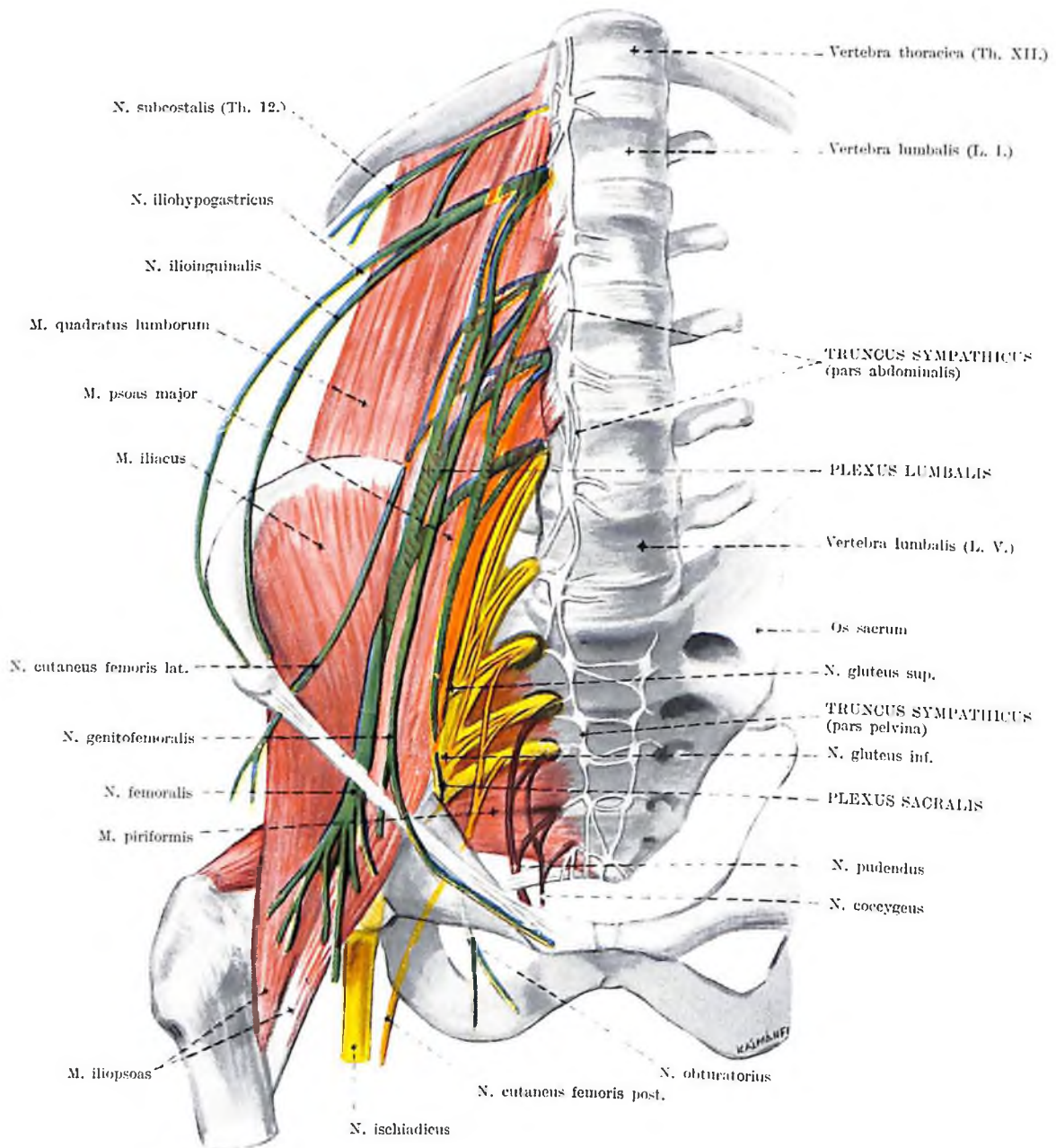


Fig. 164. PLEXUS LUMBOSACRALIS
(structura plexus, cum partibus abdominali et pelvina systematis autonomici)

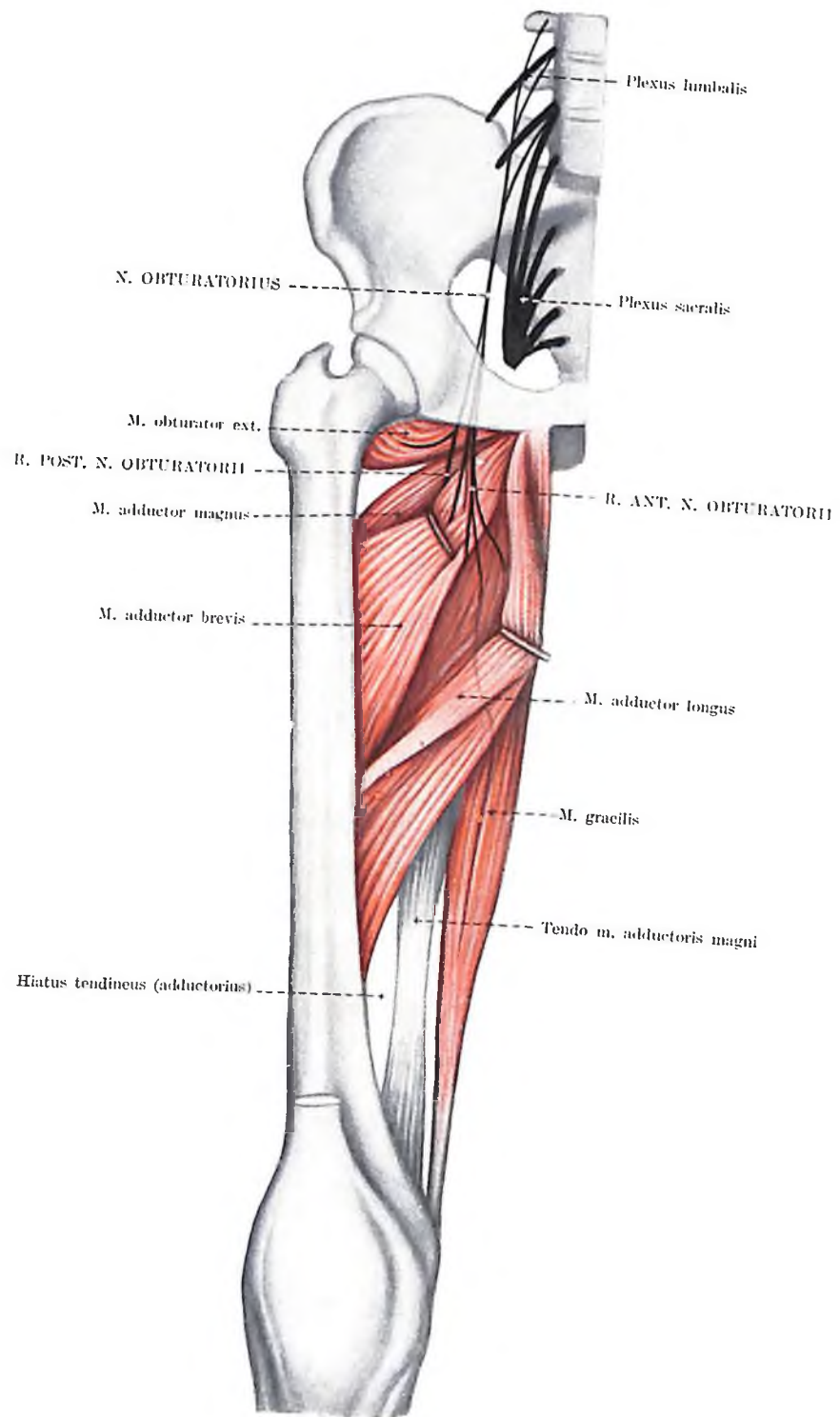


Fig. 165. NERVUS OBTURATORIUS
 (musculi adductores femoris)

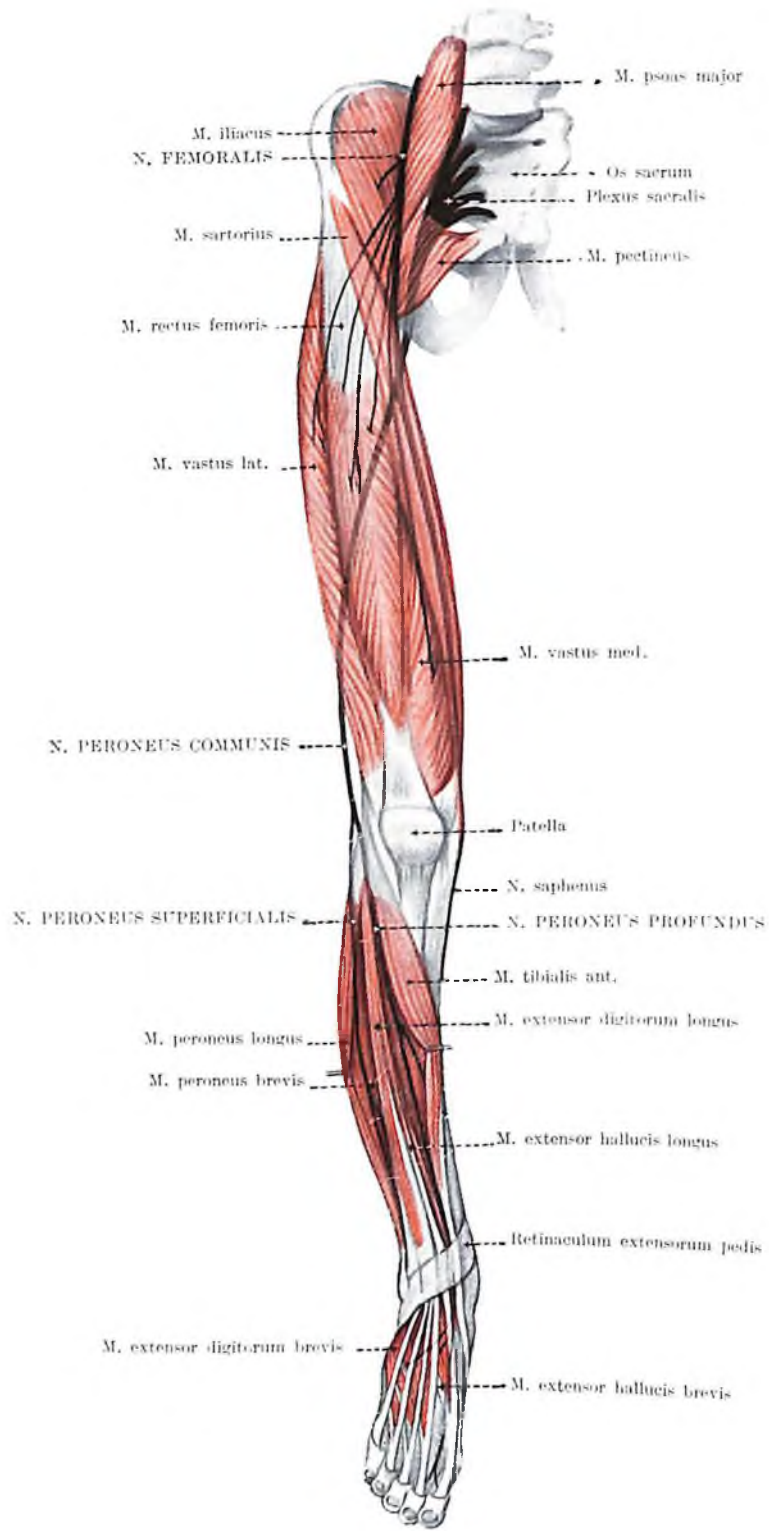


Fig. 166. NERVUS FEMORALIS ET NERVI PERONEI
(musculi extensores femoris et cruris)

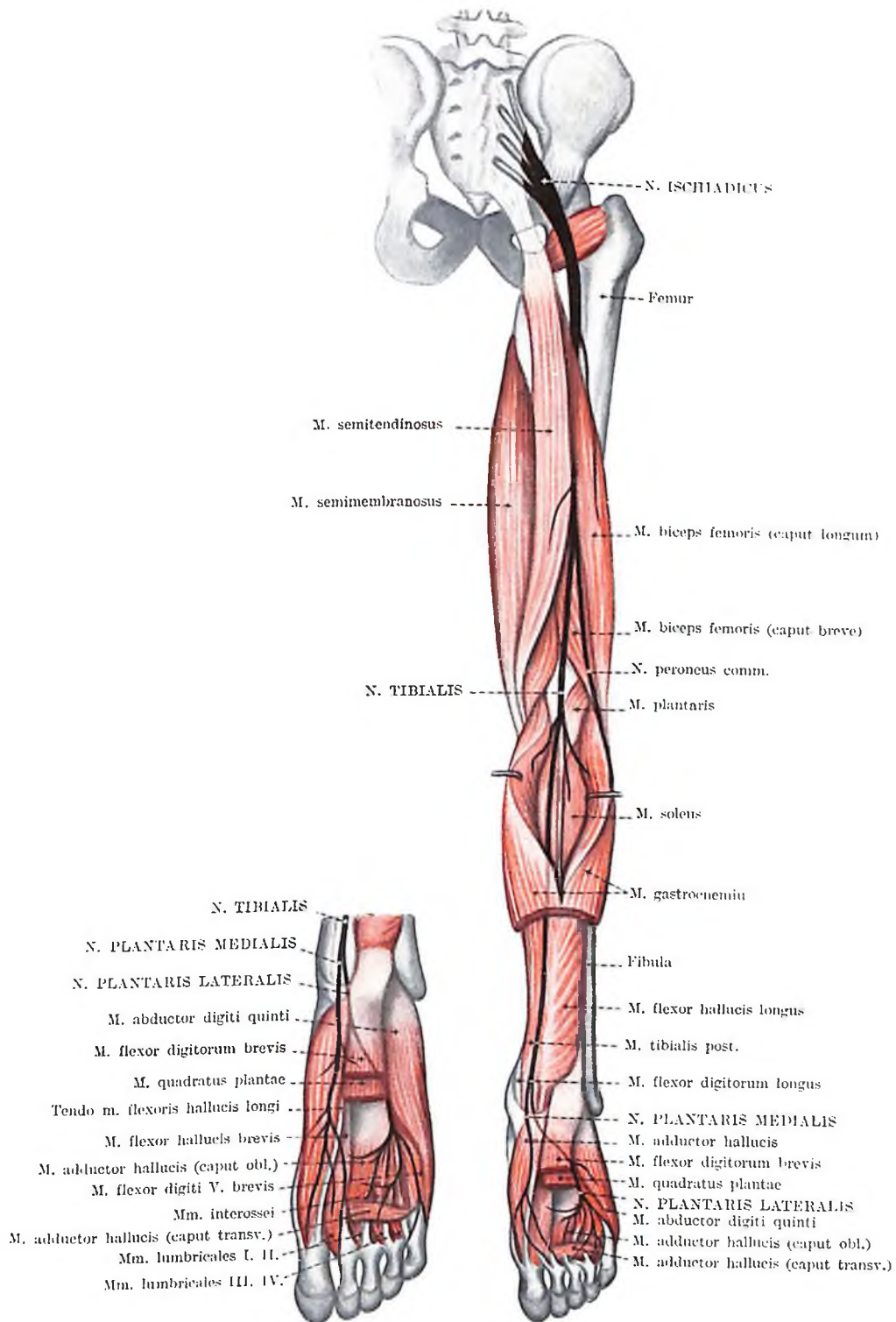


Fig. 167. NERVUS ISCHIADICUS ET NERVUS TIBIALIS
(musculi flexores femoris et cruris, musculi plantares)

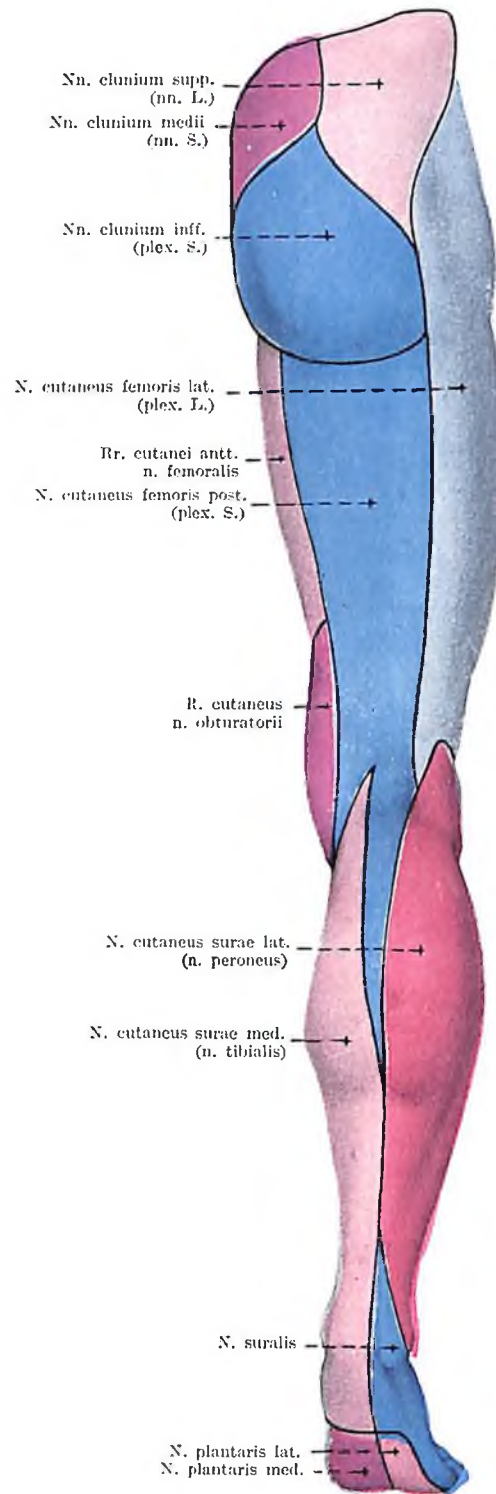


Fig. 168. NERVI CUTANEI MEMBRI INFERIORIS I.
 (innervatio peripherica, aspectus posterior)

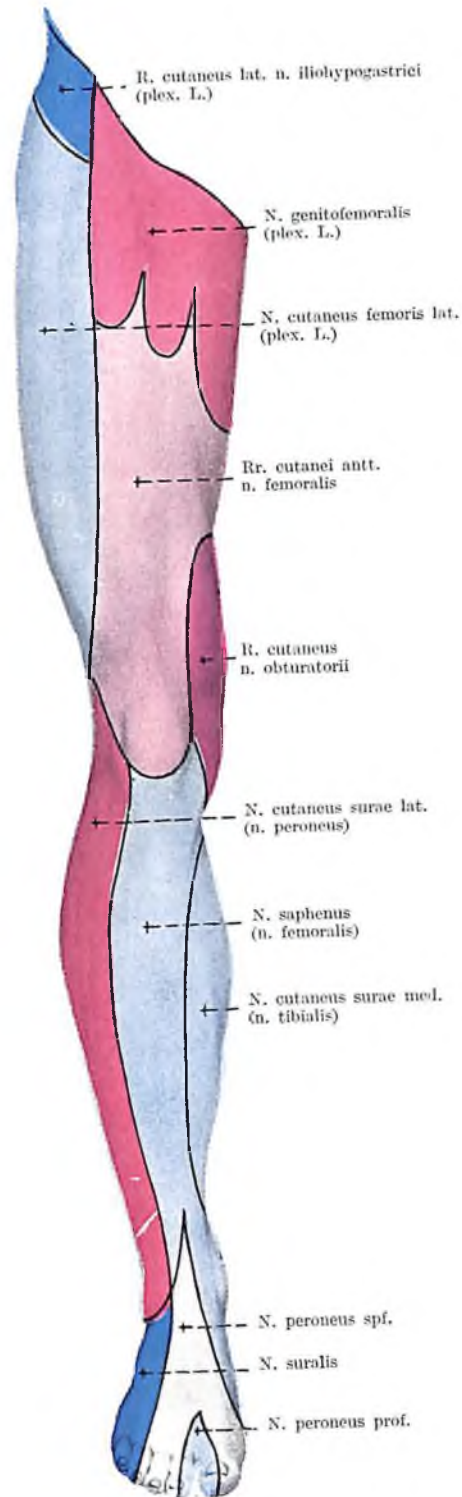


Fig. 169. NERVI CUTANEI MEMBRI INFERIORIS II.
 (innervatio peripherica, aspectus anterior)

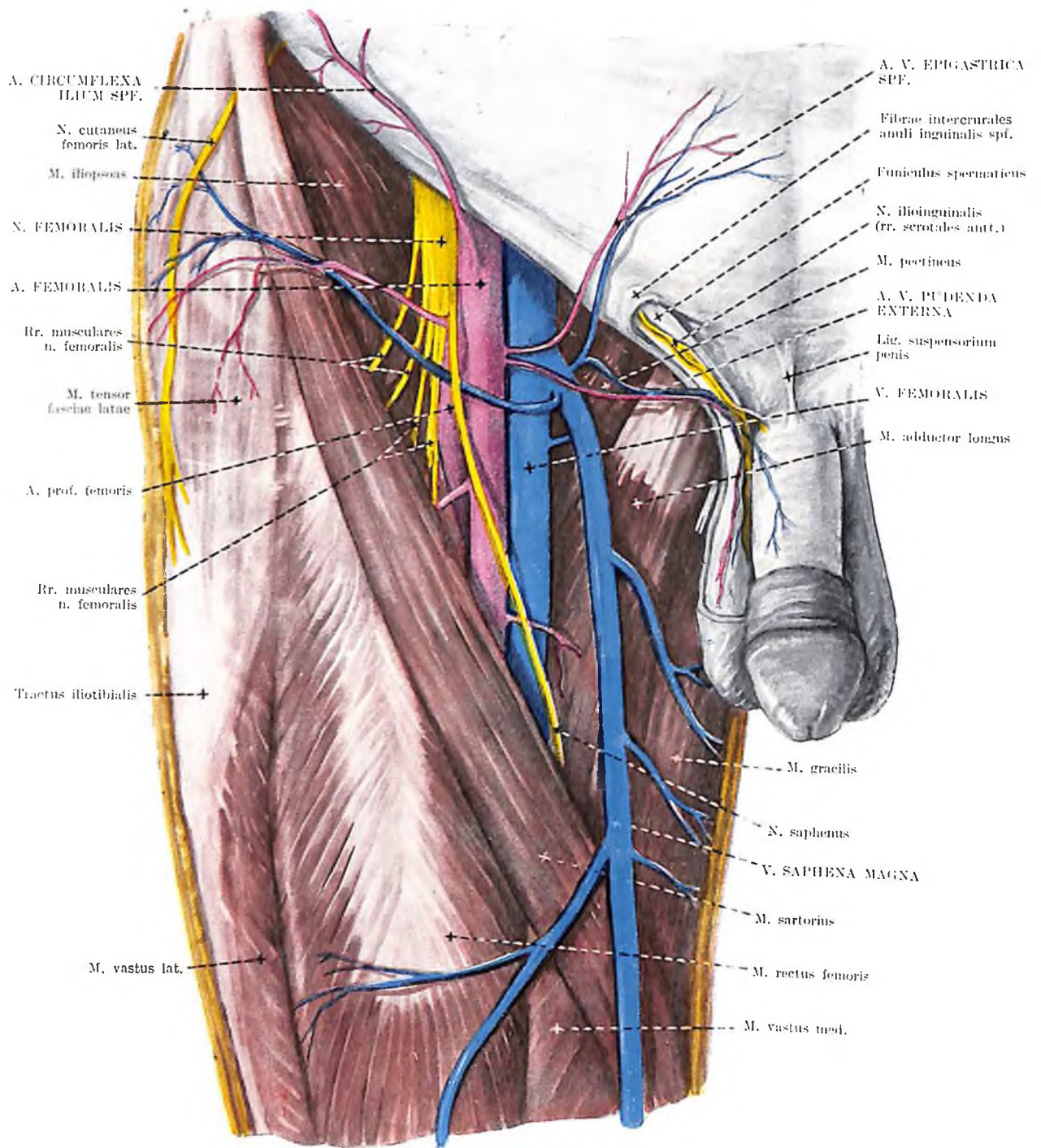


Fig. 170. ARTERIAE, VENAE ET NERVI SUBINGUINALES ET FEMORIS ANTERIORES I. (trigonum femorale, regiones subinguinalis et femoris anterior, stratum superficiale)

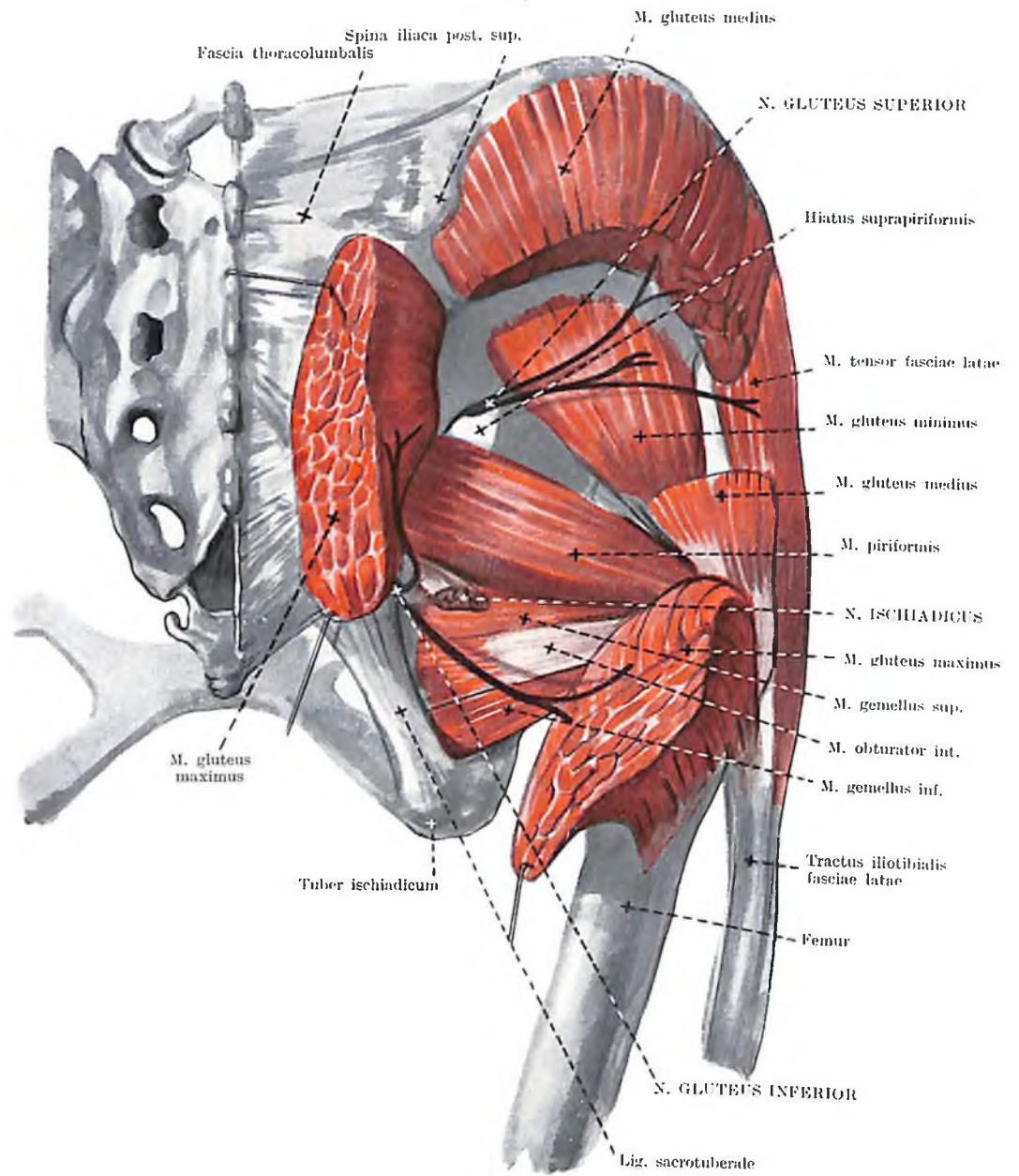


Fig. 172. NERVI REGIONIS GLUTEAE
(musculi glutei)

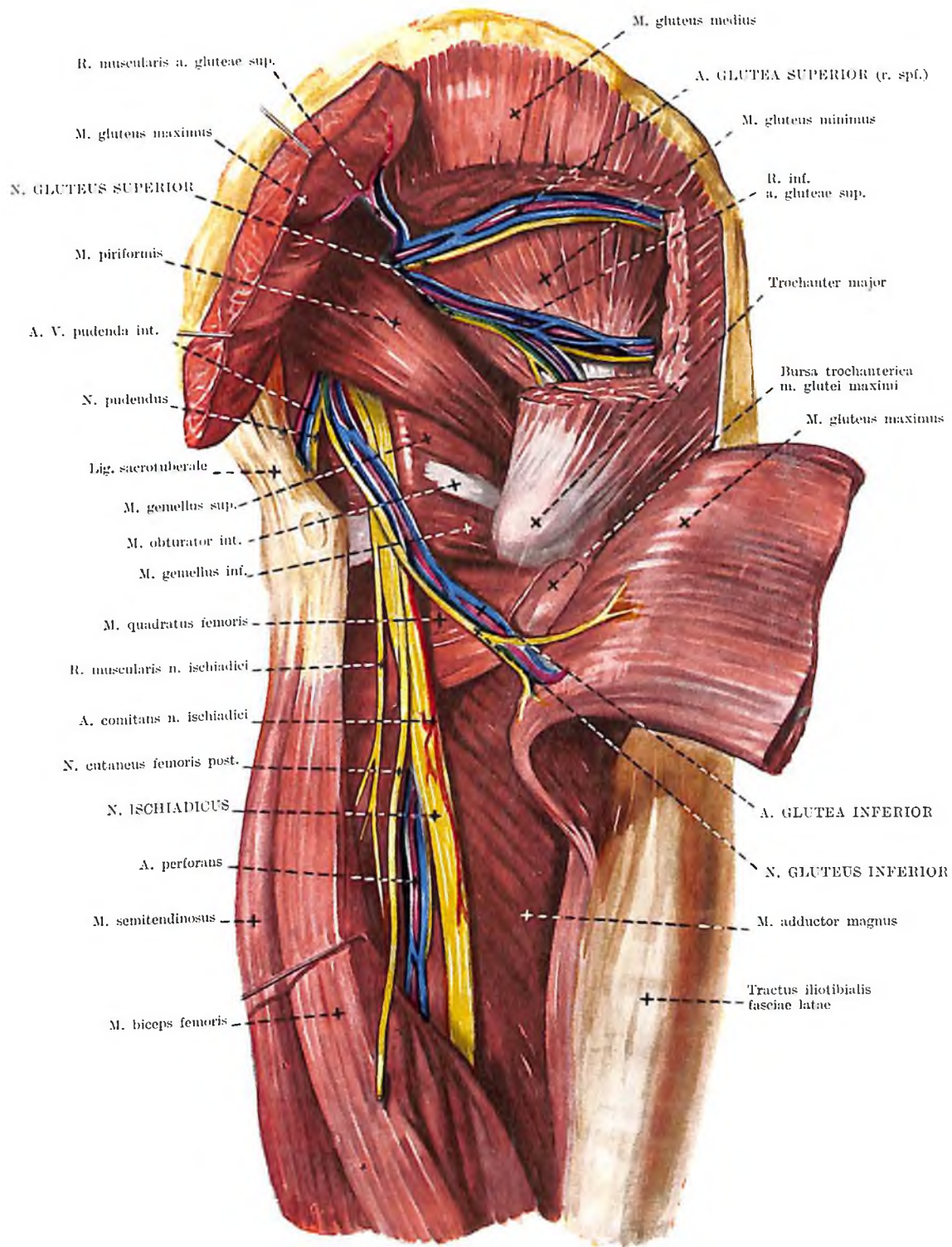


Fig. 173. ARTERIAE, VENAE ET NERVI FEMORIS POSTERIORES I.
(regiones glutea et femoris posterior)

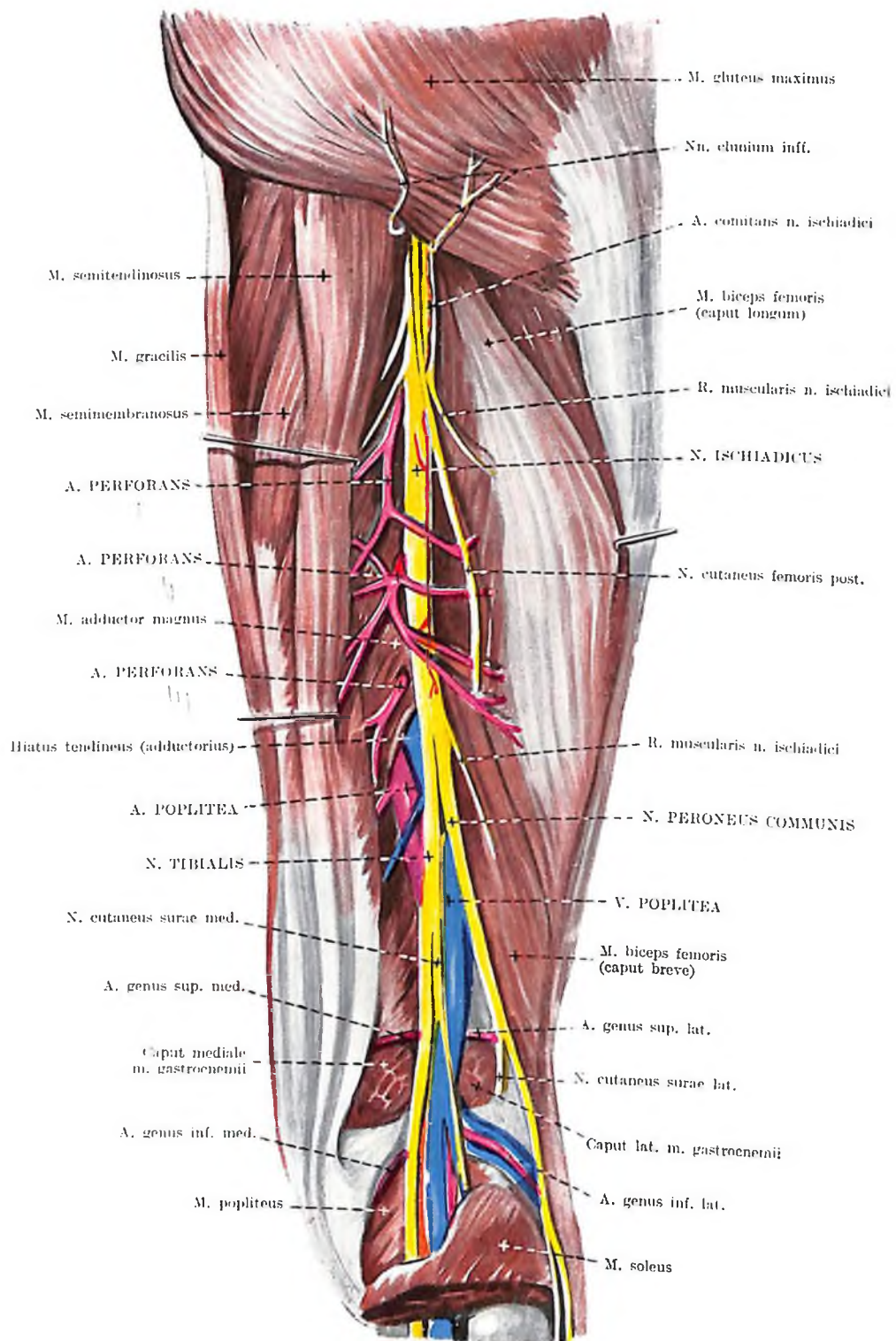


Fig. 174. ARTERIAE, VENAE ET NERVI FEMORIS POSTERIORES II.
(regiones femoris et genus posteriores et fossa poplitea)

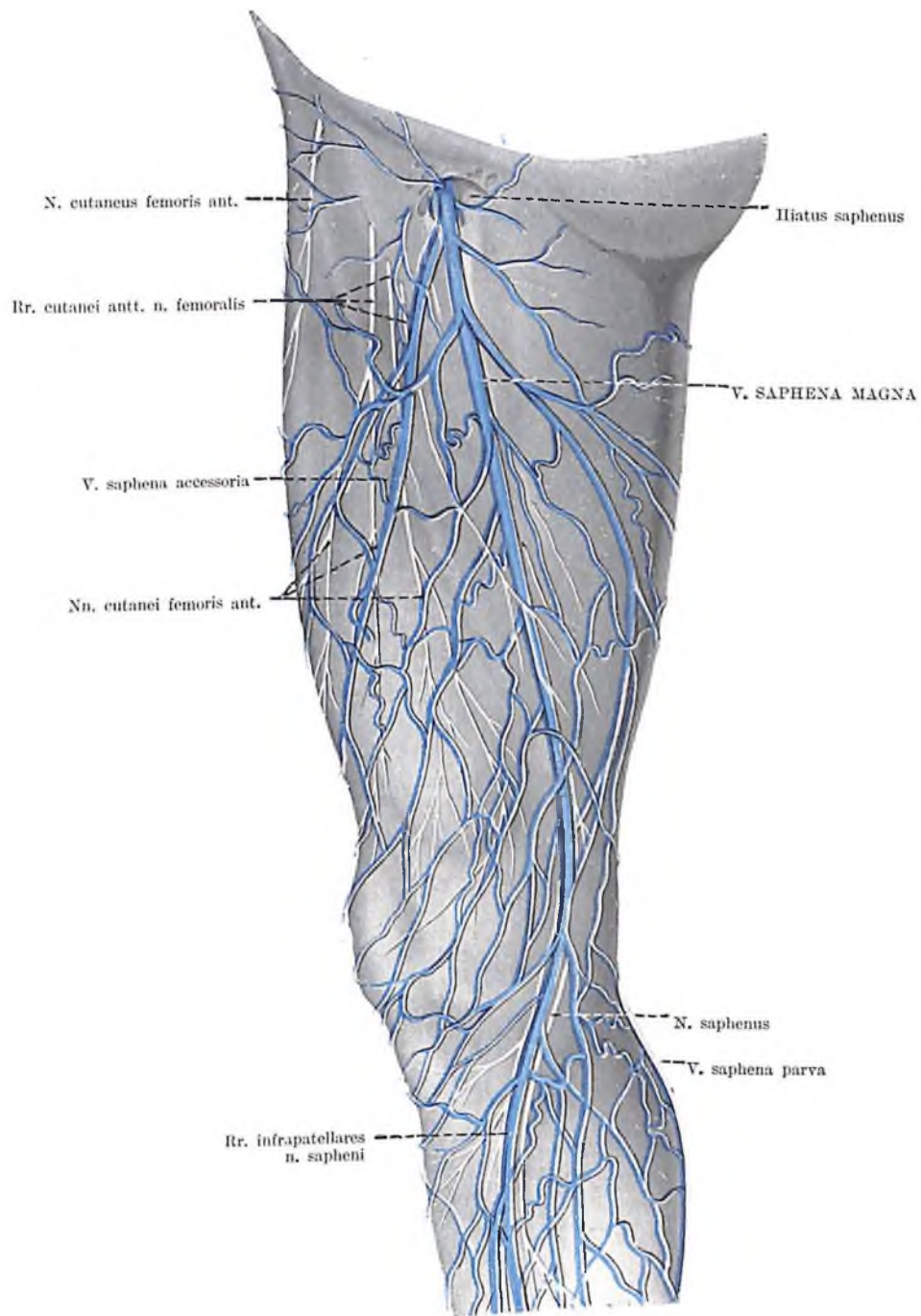


Fig. 175. VENAE SUPERFICIALES ET NERVI CUTANEI FEMORIS

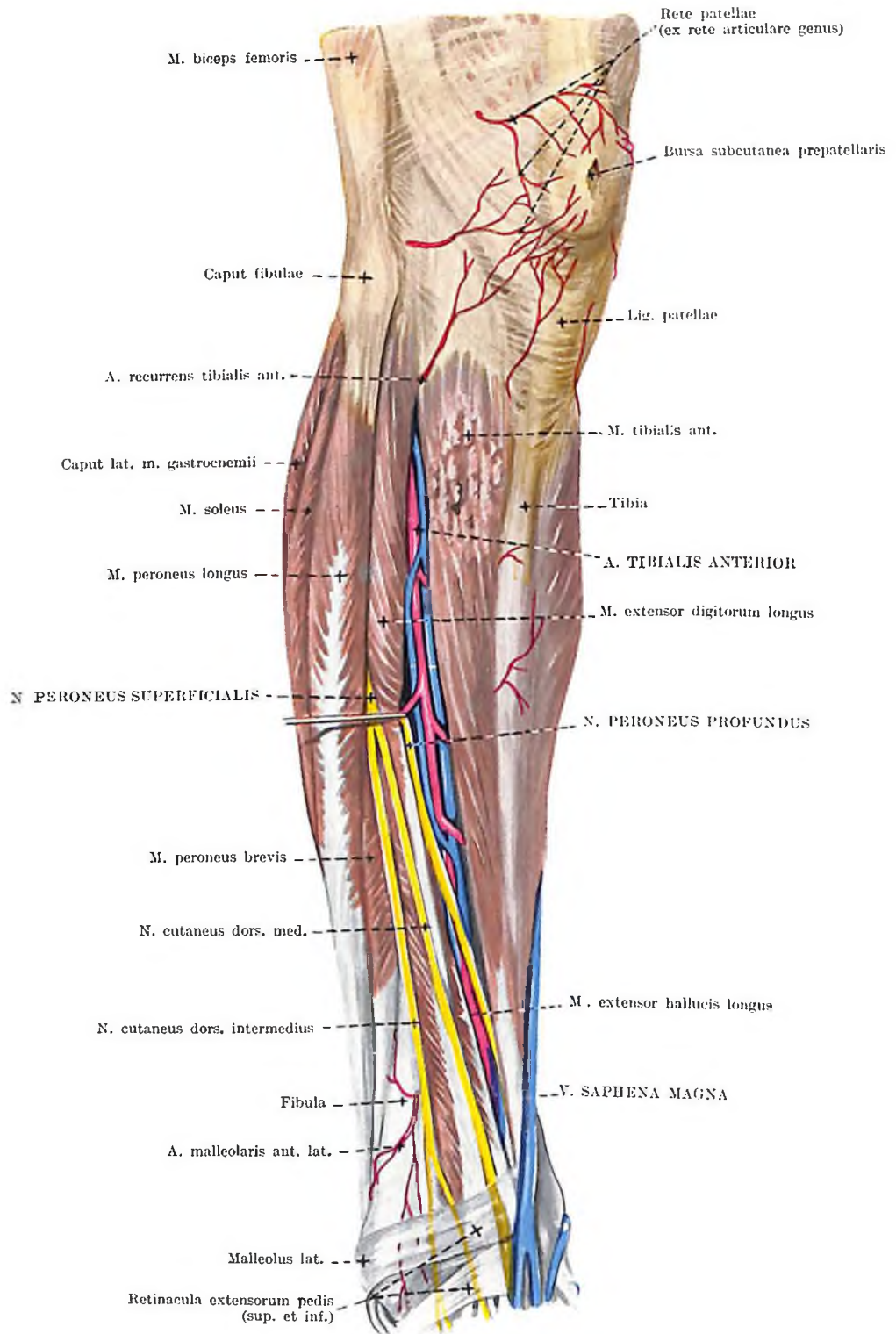


Fig. 176. ARTERIAE, VENAE ET NERVI CRURIS ANTERIORES
(regiones genus et cruris anteriores)

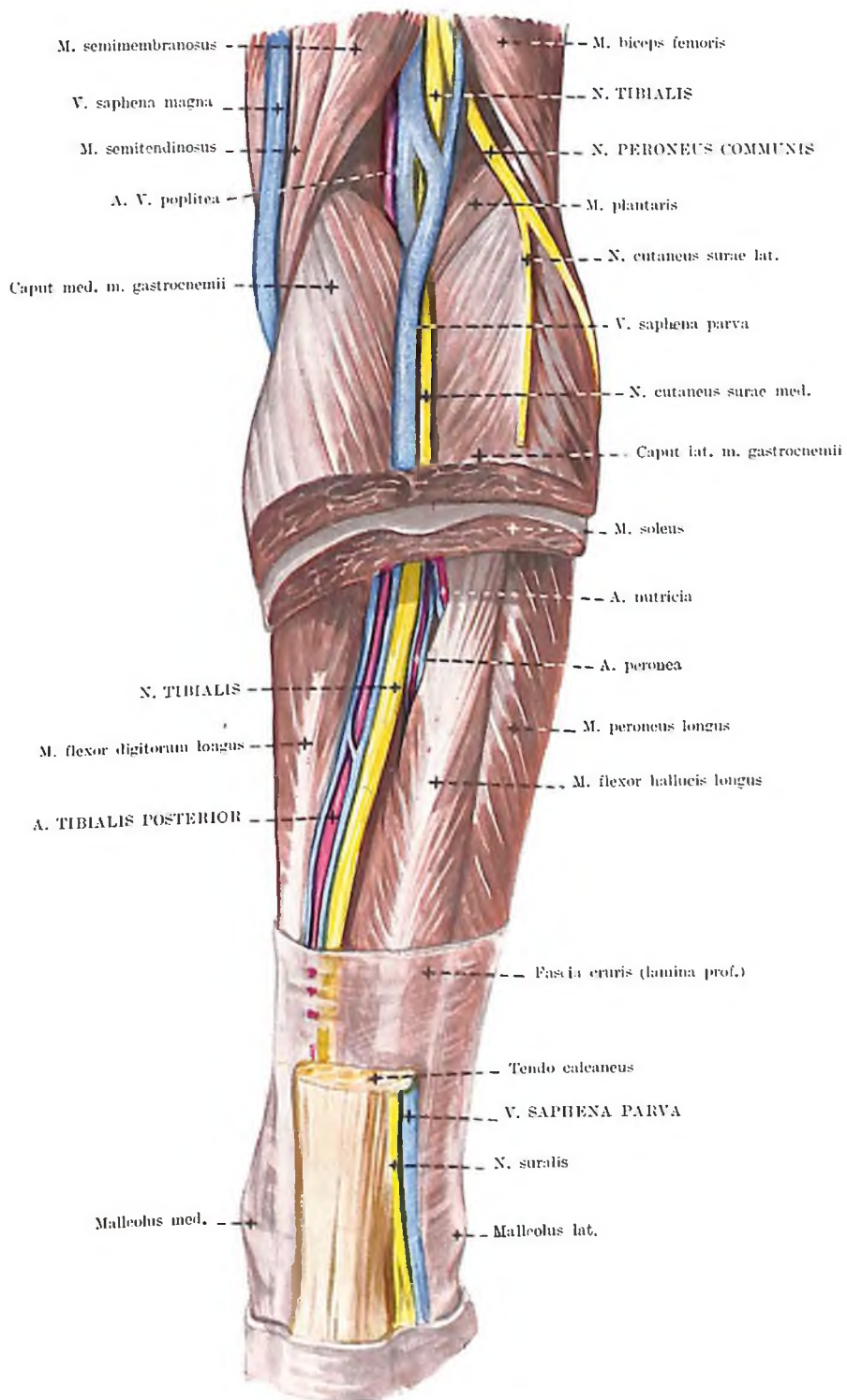


Fig. 177. ARTERIAE, VENAE ET NERVI CRURIS POSTERIORES
(fossa poplitea et regiones genua et cruris posteriores)

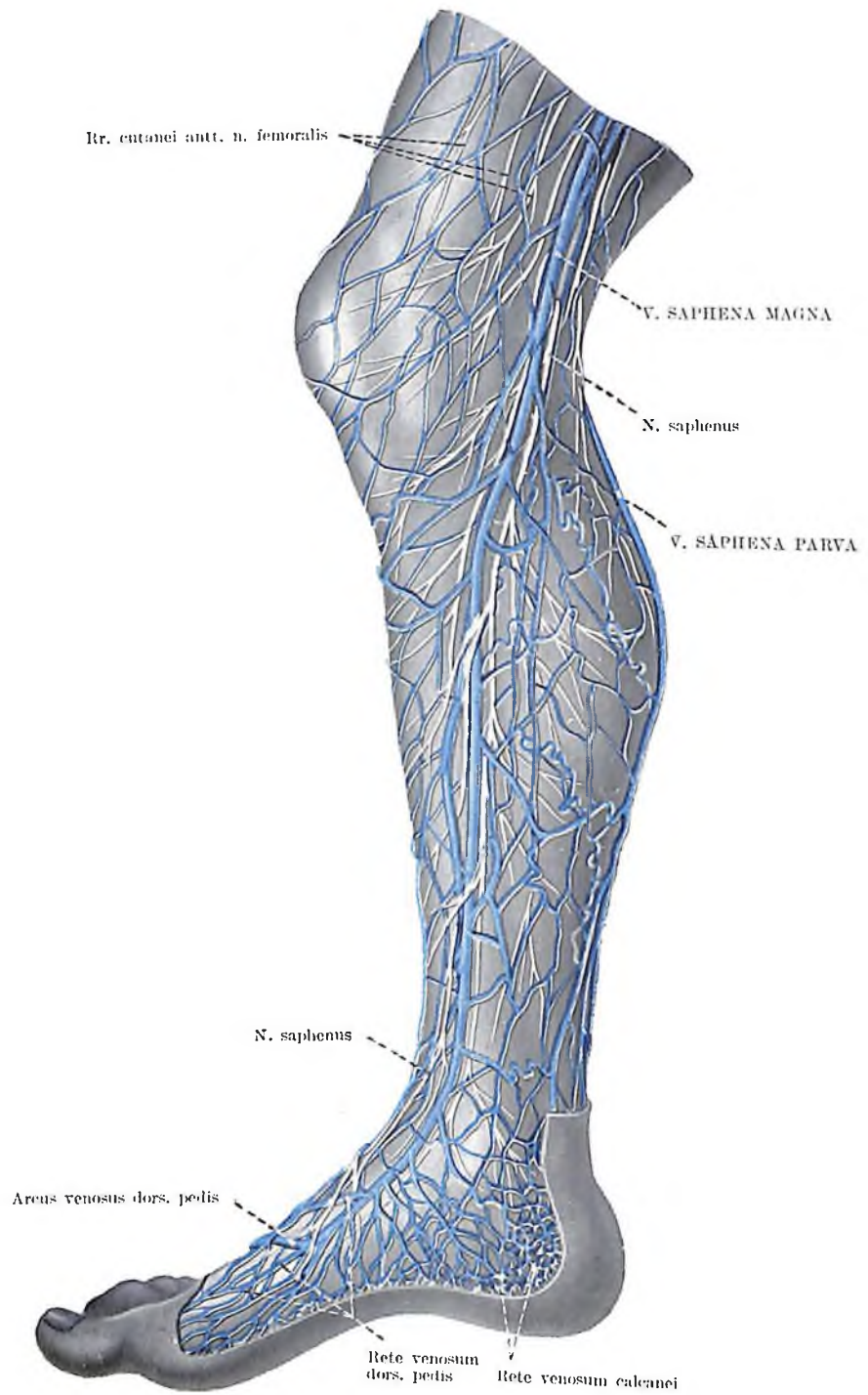


Fig. 178. VENAE SUPERFICIALES ET NERVI CUTANEI CRURIS ET PEDIS I.

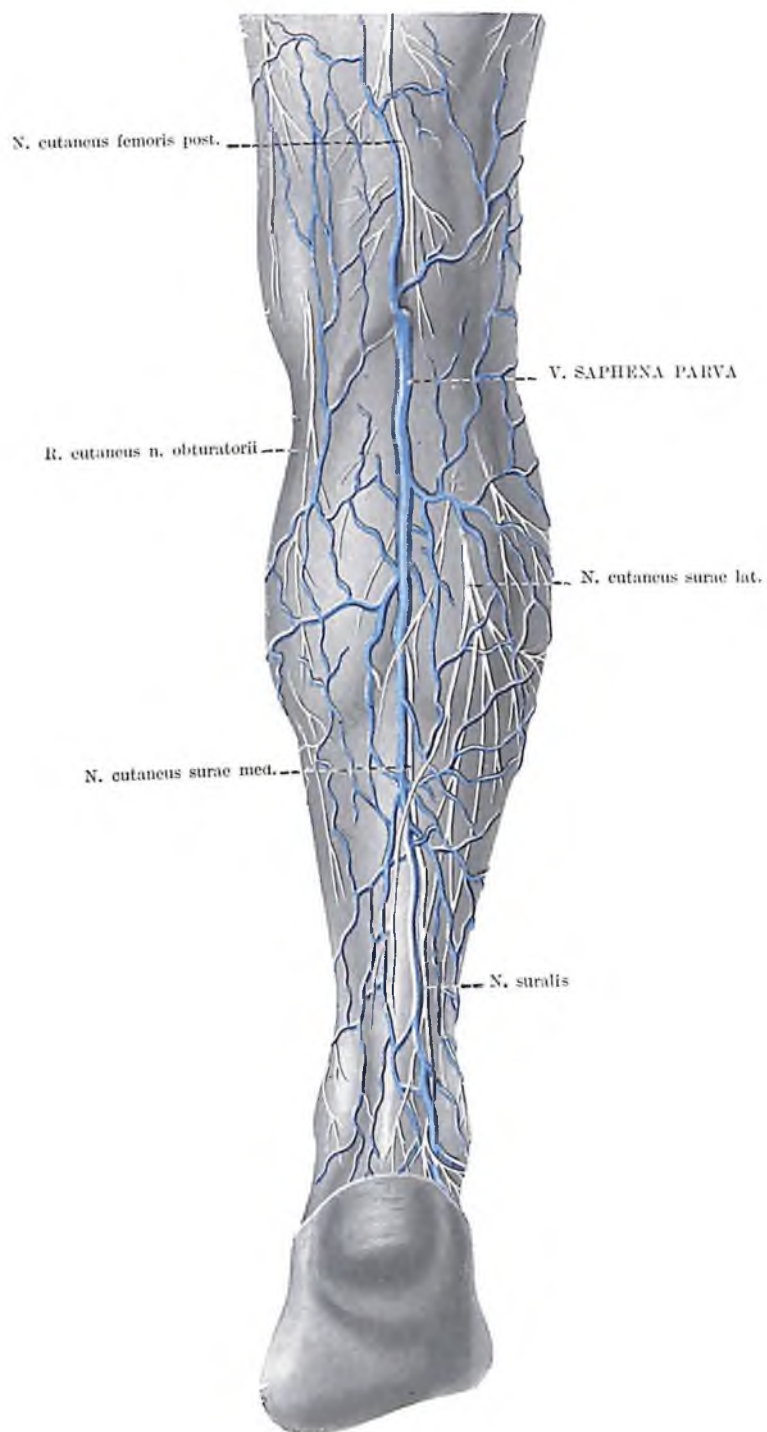


Fig. 179. VENAE SUPERFICIALES ET NERVI CUTANEI CRURIS II.

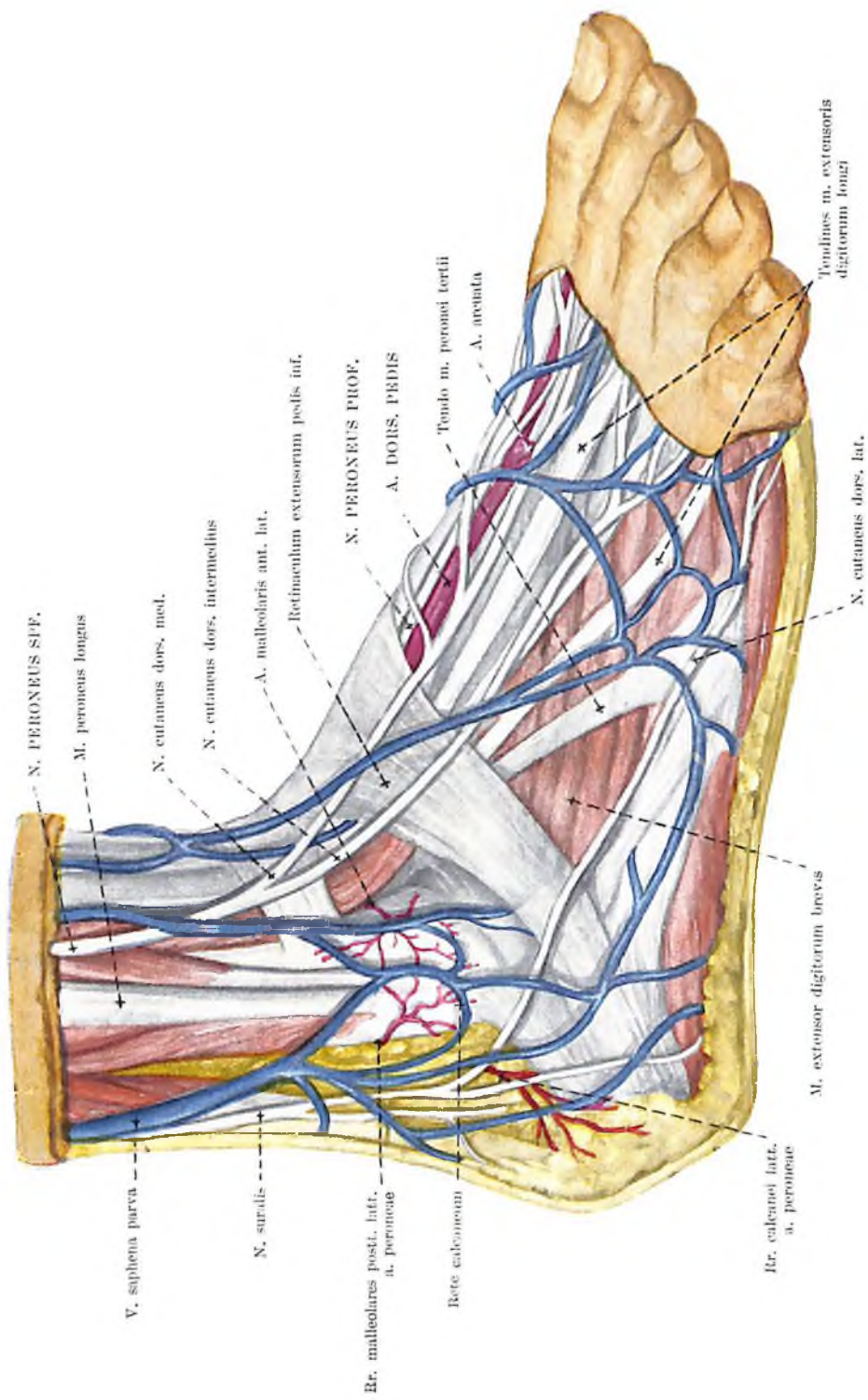


Fig. 180. ARTERIAE, VENAE ET NERVI DORSI PEDIS

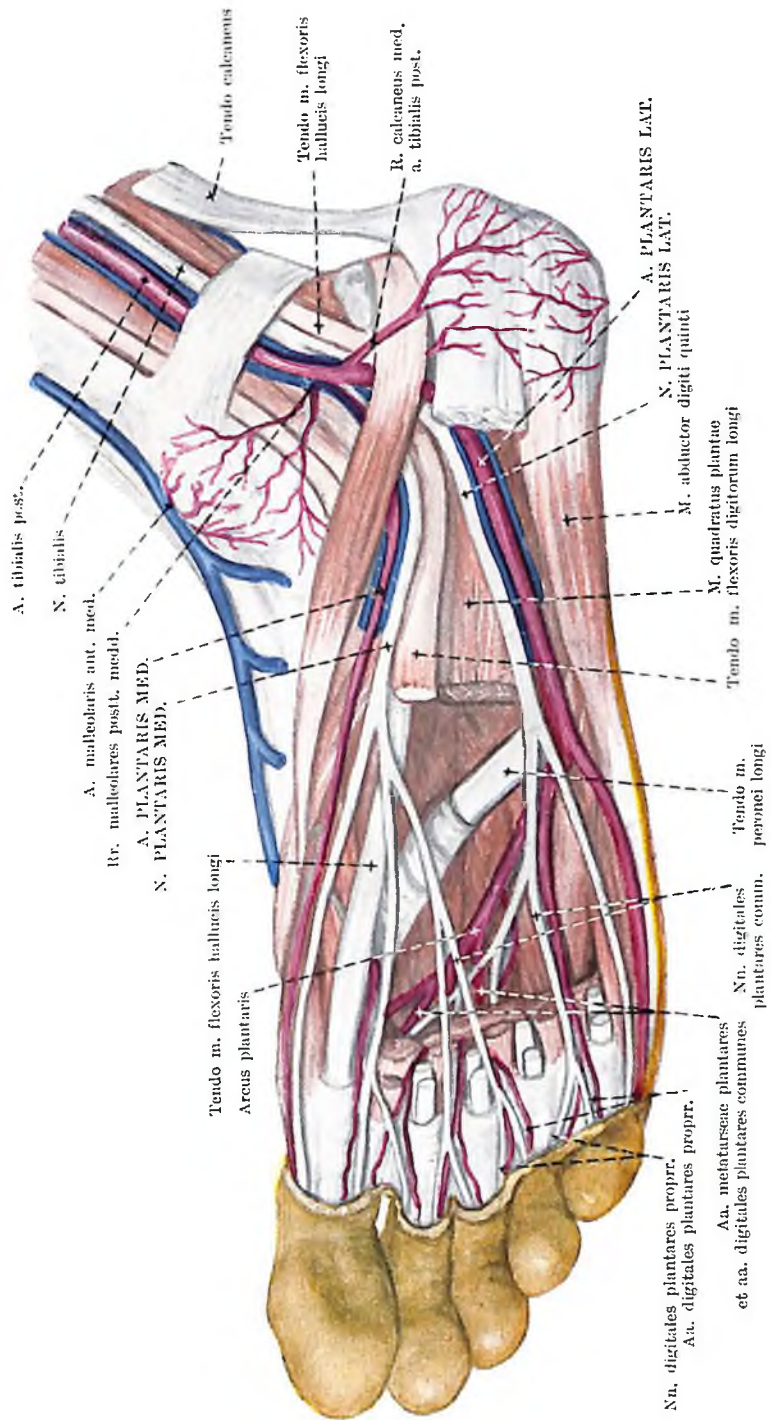


Fig. 181. ARTERIAE, VENAE ET NERVI PLANTAE PEDIS

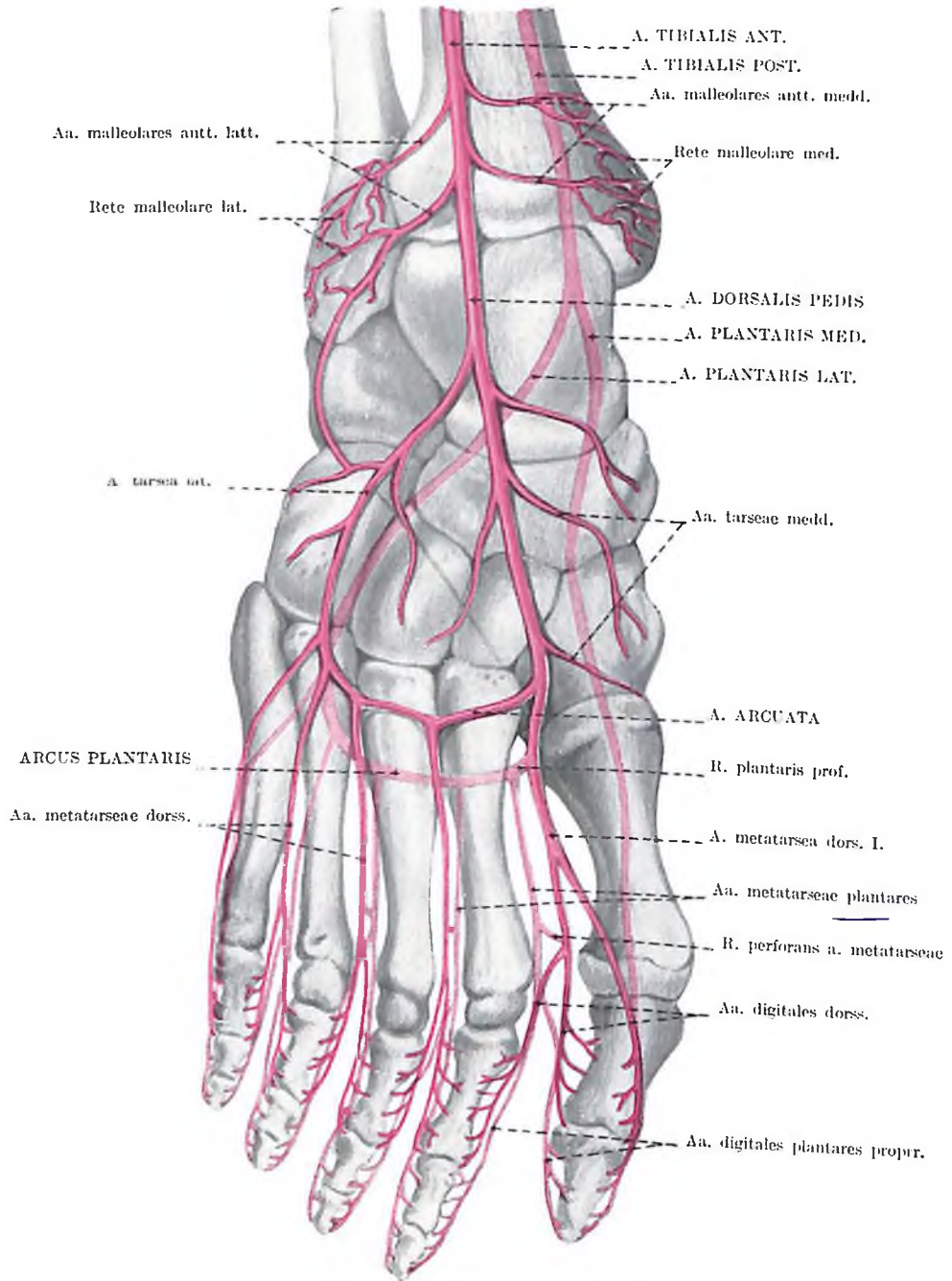


Fig. 182. ARTERIAE PEDIS
(aspectus dorsalis)

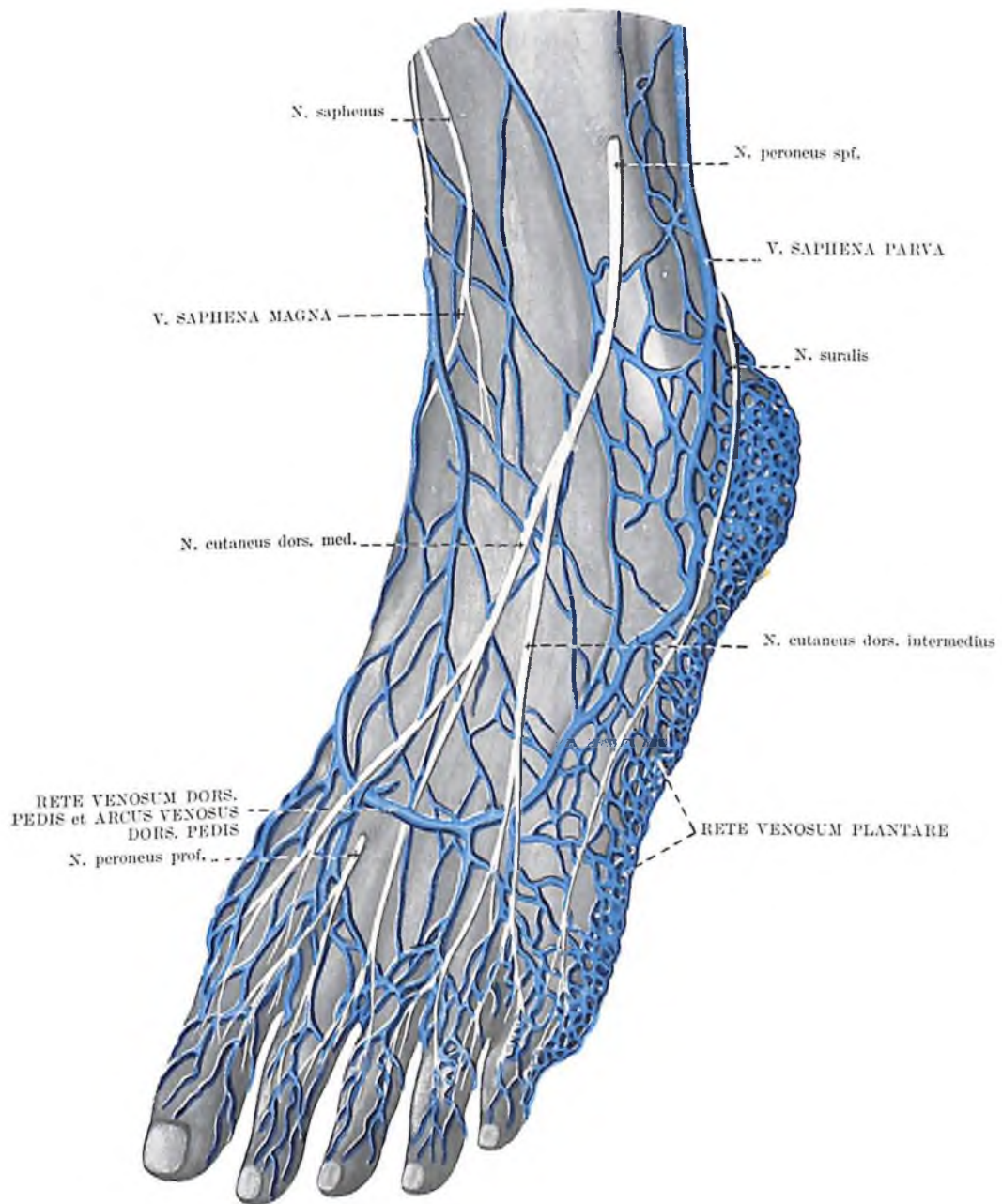


Fig. 183. VENAE SUPERFICIALES ET NERVI CUTANEI PEDIS II.

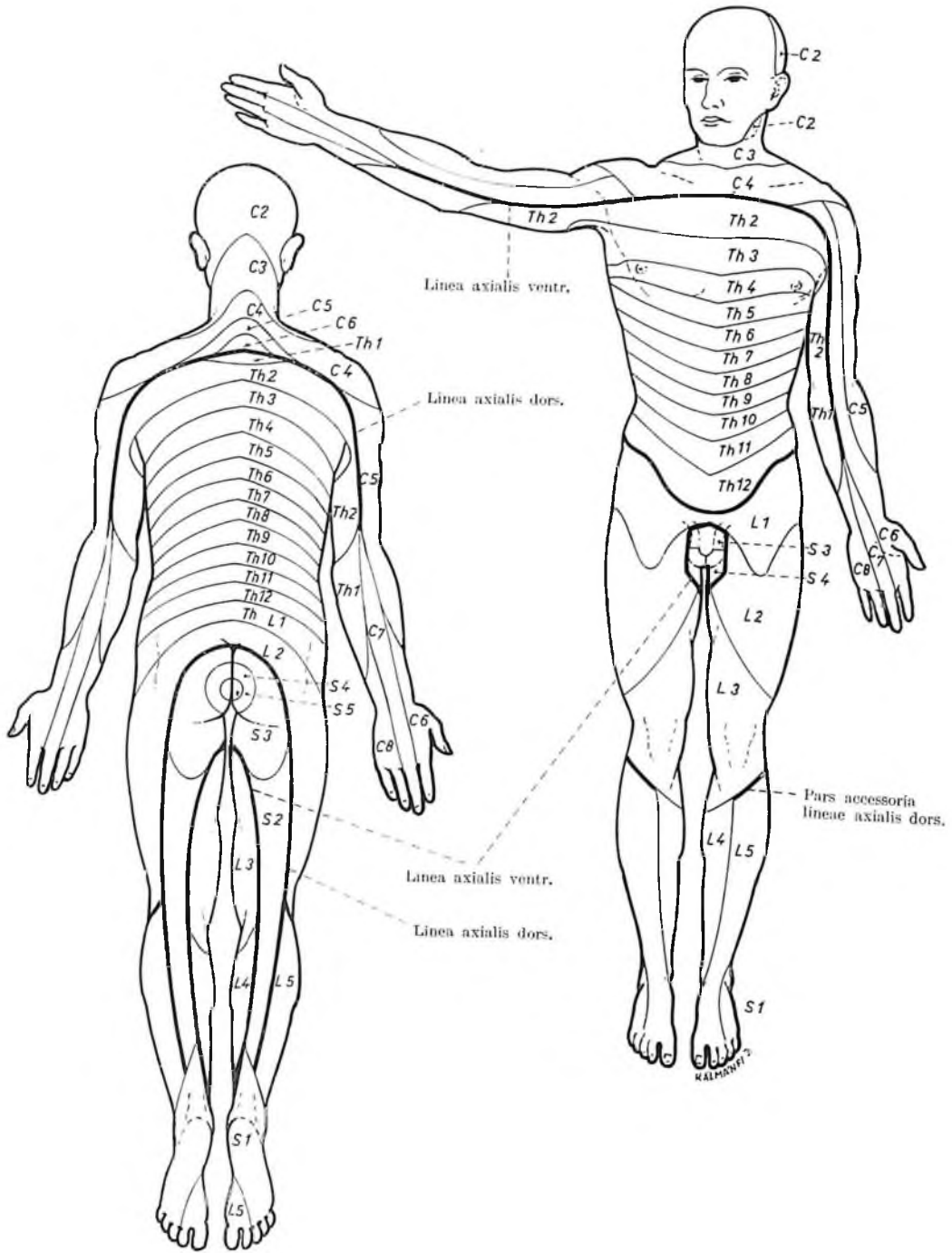
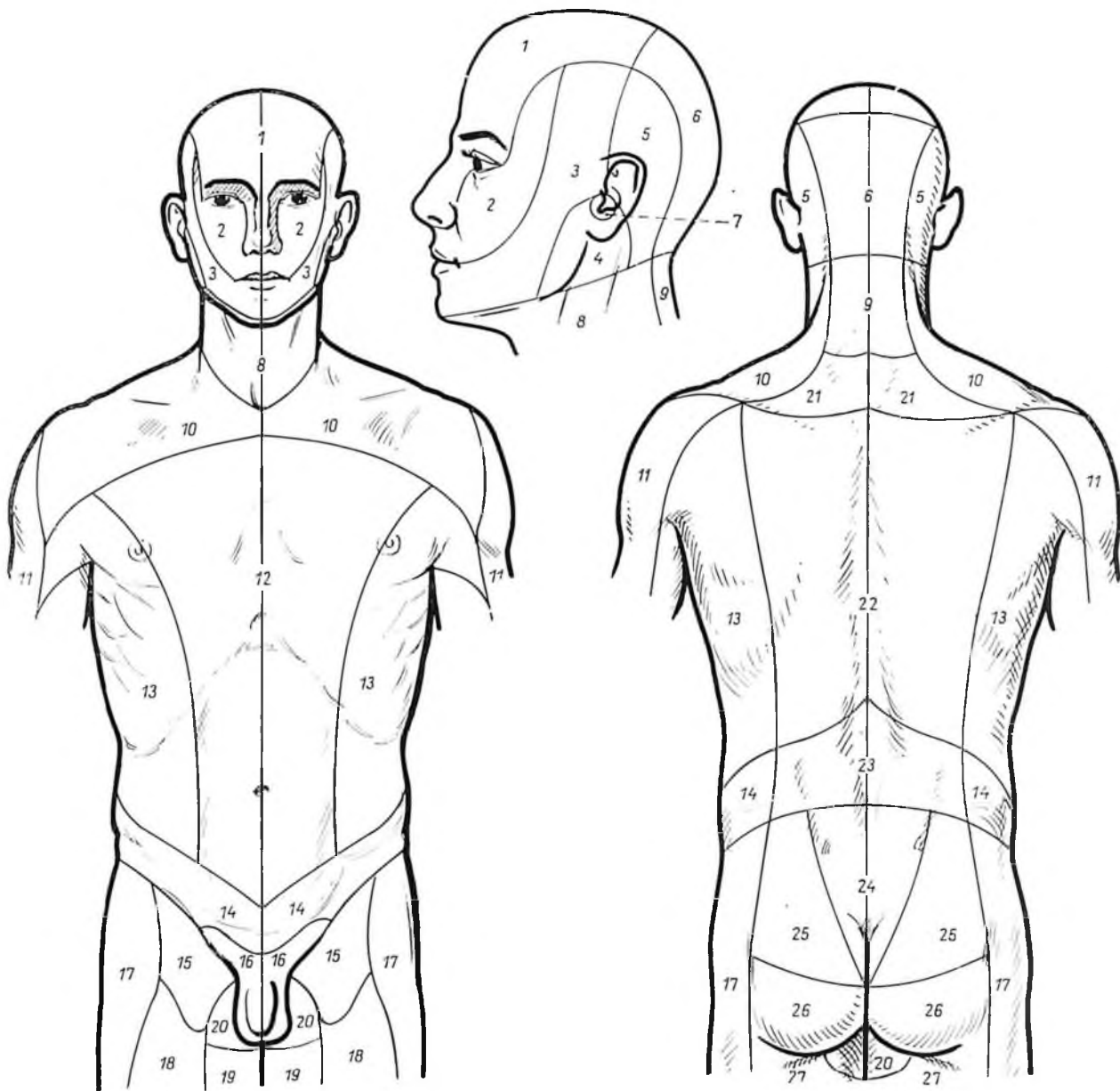


Fig. 184. INNERVATIO SEGMENTALIS CUTIS



1. N. ophthalmicus (V/1.)
2. N. maxillaris (V/2.)
3. N. mandibularis (V/3.)
4. N. auricularis magnus (plex. C.)
5. N. occipitalis minor (plex. C.)
6. N. occipitalis major (C. 2.)
7. R. auricularis n. vagi
8. Nn. transv. colli (plex. C.)
9. N. occipitalis tertius (C. 3.)
10. Nn. supraclaviculares medd., intermedii et lat. (plex. C.)
11. N. axillaris (plex. brachialis)
12. Nn. intercostales (rr. cutanei ant.) (Th.)
13. Nn. intercostales (rr. cutanei lat.) (Th.)

14. N. iliohypogastricus (plex. L.)
15. R. femoralis } n. genitofoemoralis (plex. L.)
16. R. genitales }
17. N. cutaneus femoris lat. (plex. L.)
18. Rr. cutanei ant. (n. femoralis)
19. R. cutaneus n. obturatorii
20. Rr. perineales n. cutanei femoris post.
21. Rr. dors. nn. cervicalium (rr. cutanei medd. et lat.)
22. Rr. dors. nn. thoracicorum (rr. cutanei medd. et lat.)
23. Rr. dors. nn. lumbalium (rr. cutanei medd. et lat.)
24. Rr. dors. nn. sacralium (nn. clunium medii)
25. Nn. clunium sup. (nn. L.)
26. Nn. clunium inf. (n. cutaneus femoris post.)
27. N. cutaneus femoris post.

Fig. 185. INNERVATIO PERIPHERICA CUTIS
(arcae nervorum cutaneorum capitis, colli et trunci)

SYSTEMA NERVOSUM AUTONOMICUM

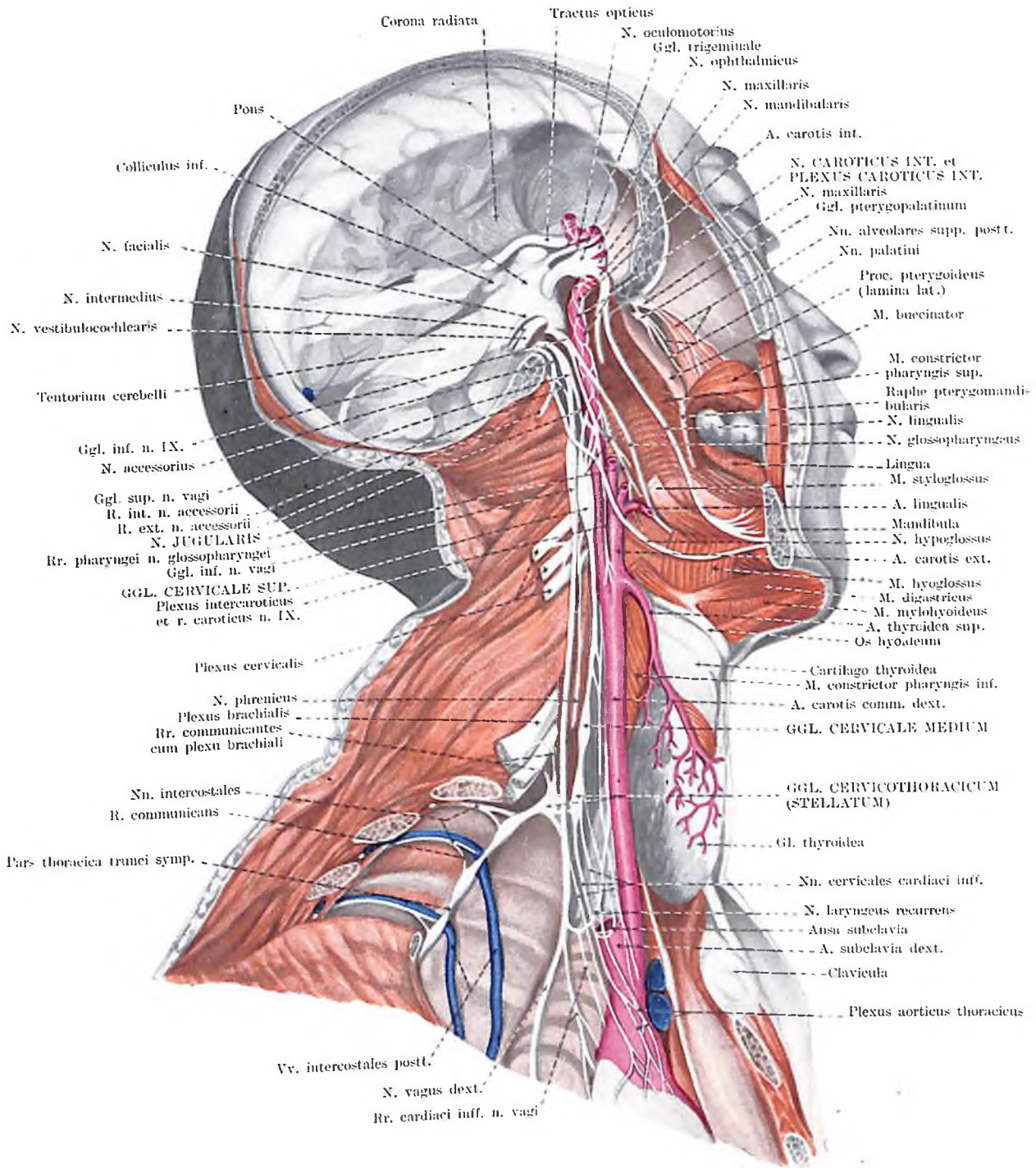


Fig. 186. PARS CEPHALICA ET PARS CERVICALIS SYSTEMATIS NERVOSI AUTONOMICI

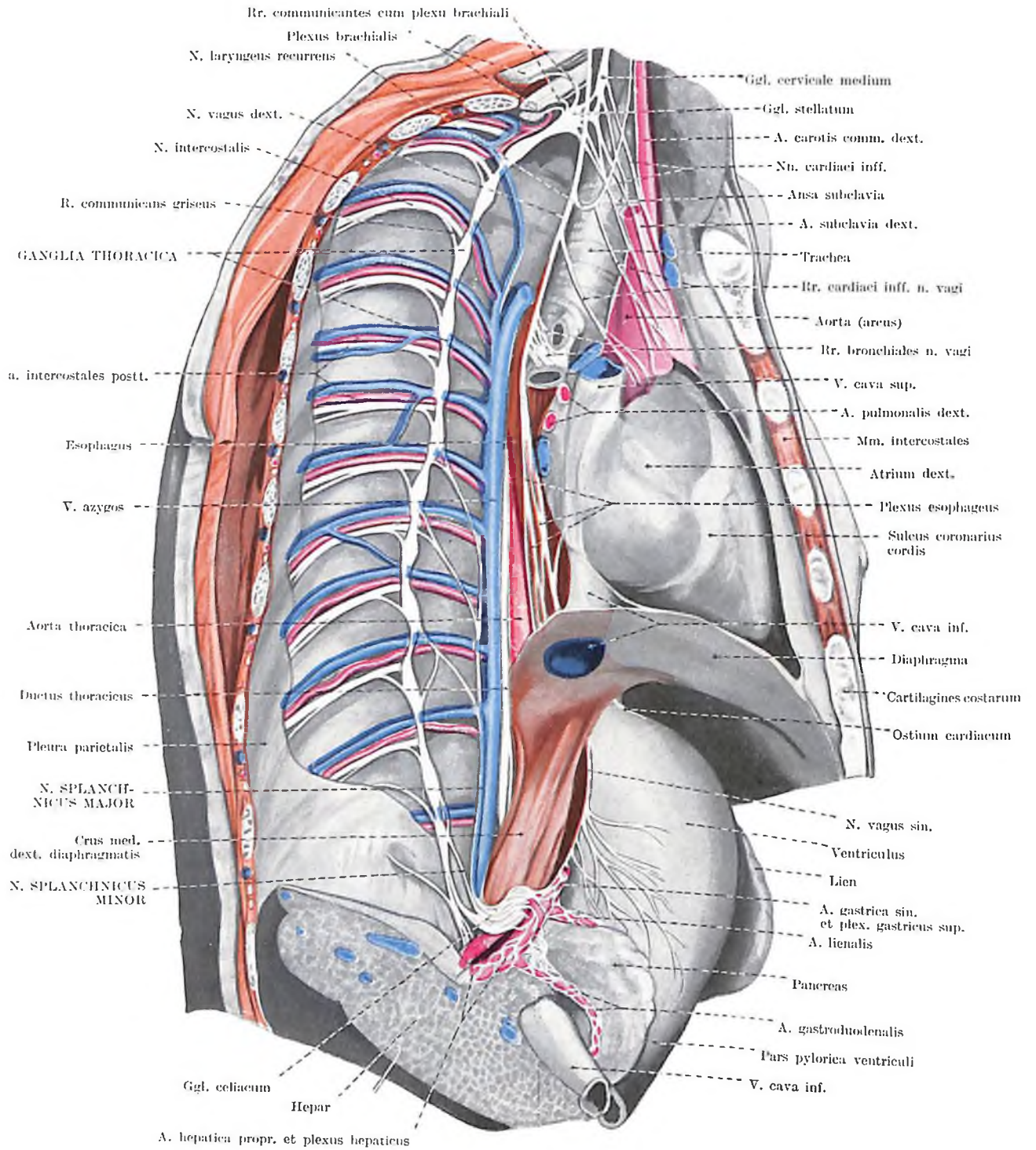


Fig. 187. PARS THORACICA SYSTEMATIS NERVOSI AUTONOMICI
(aspectus lateralis dexter)

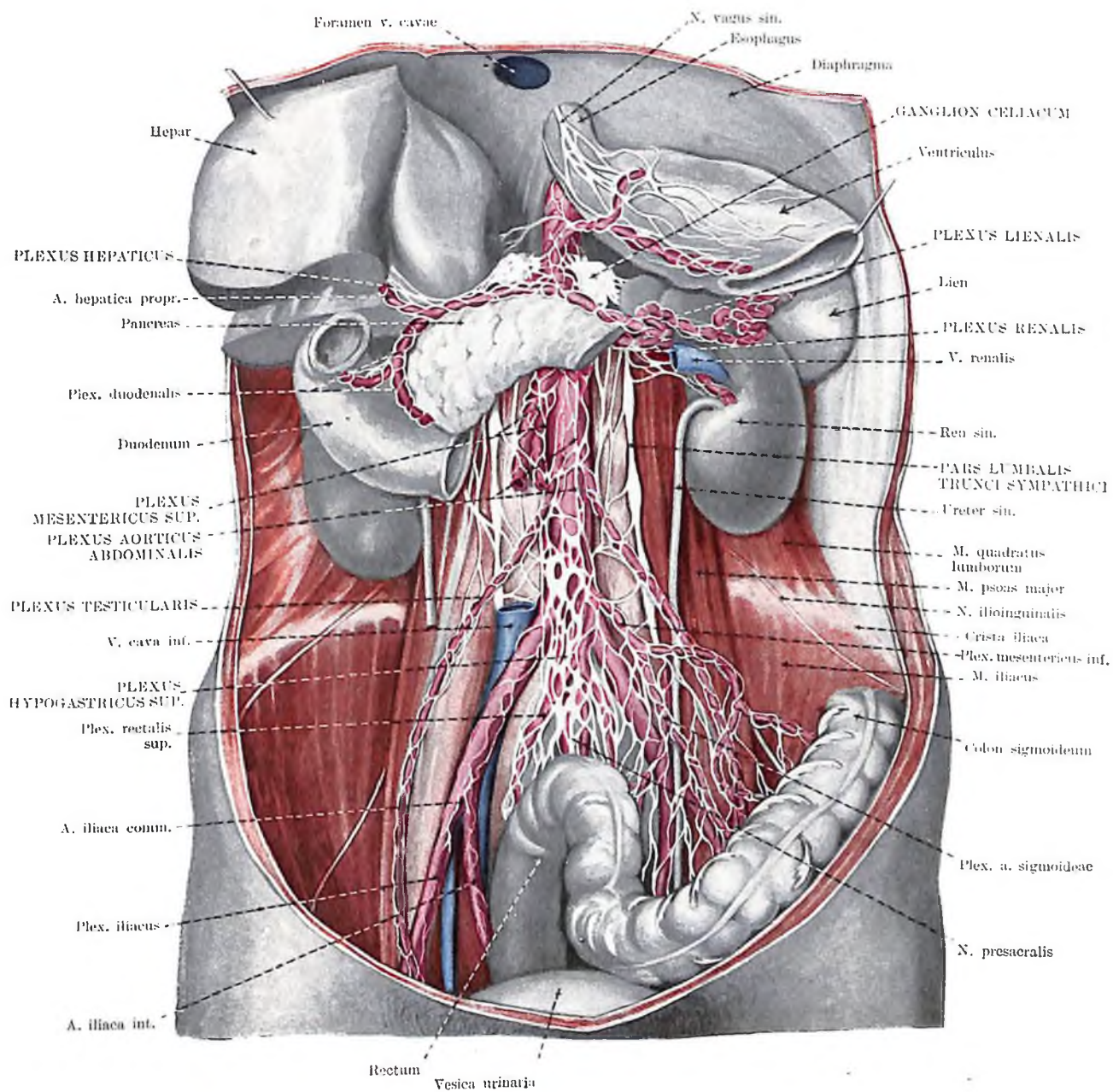


Fig. 188. PARS ABDOMINALIS SYSTEMATIS NERVOSI AUTONOMICI

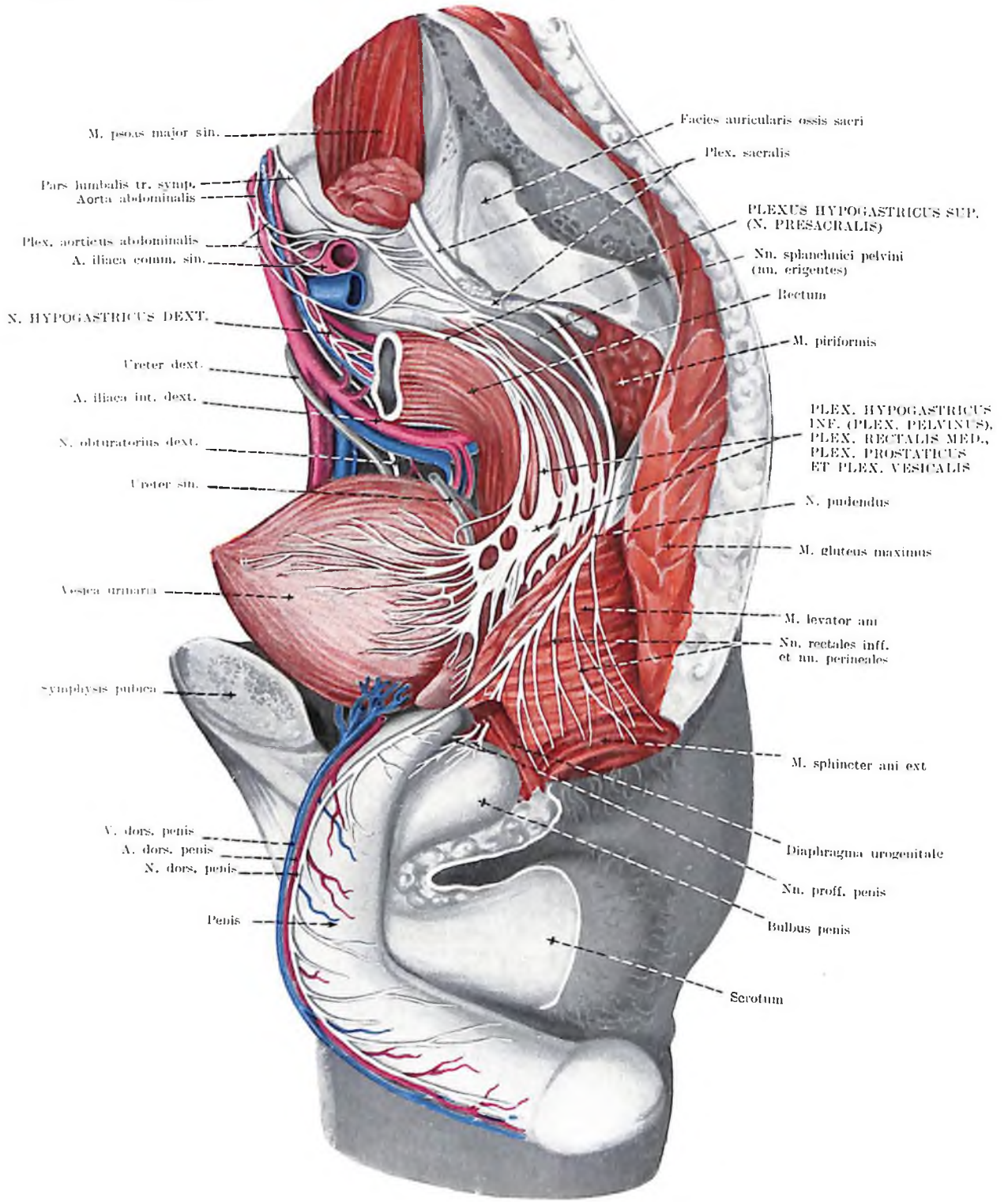


Fig. 189. PARS PELVINA SYSTEMATIS NERVOSI AUTONOMICI I.
(plexus hypogastricus inferior seu pelvinus, sectio sagittalis paramediana pelvis masculinae)

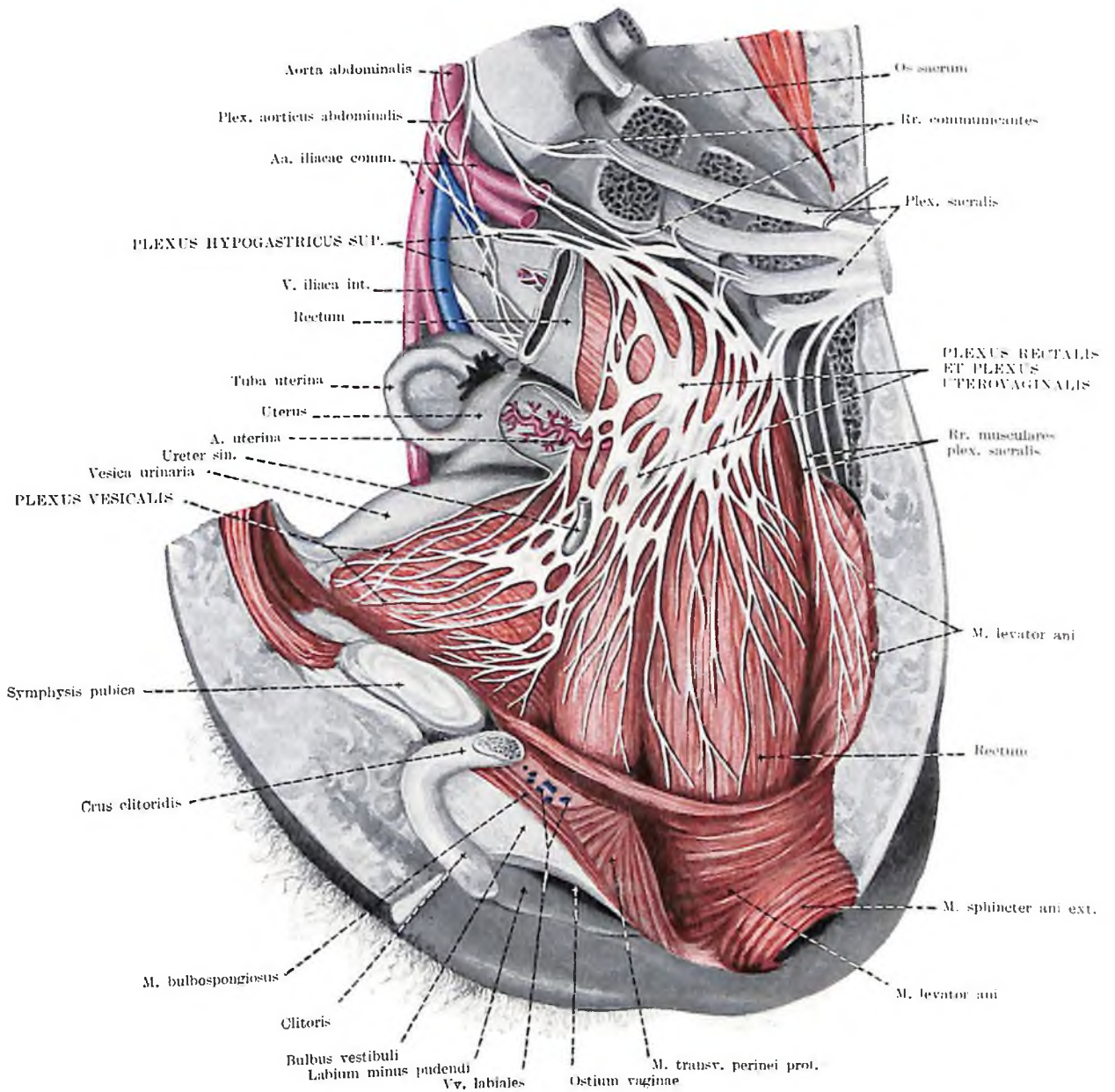


Fig. 190. PARS PELVINA SYSTEMATIS NERVOSI AUTONOMICI II.
(sectio sagittalis paramediana pelvis femininae)

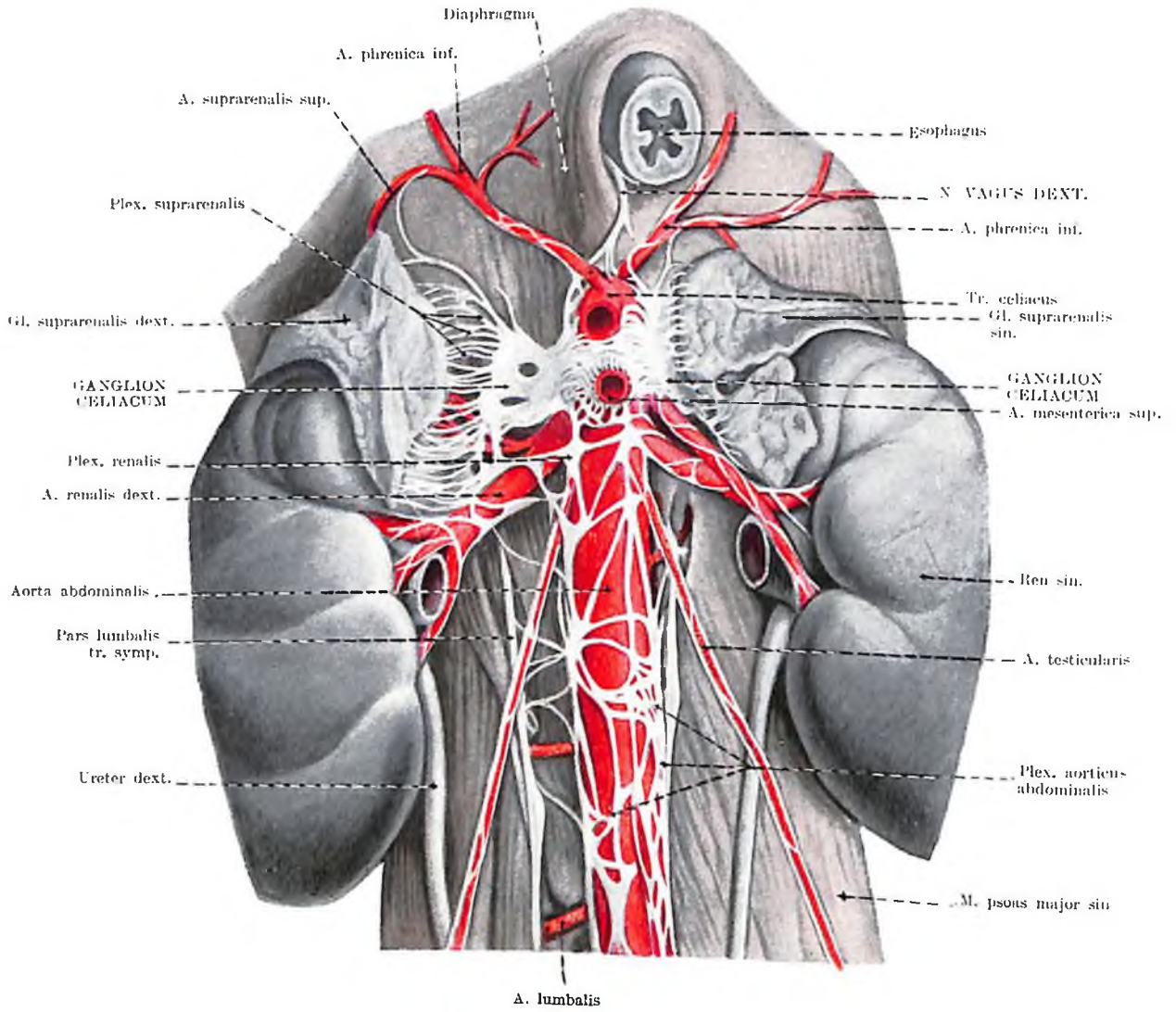


Fig. 191. GANGLIA CELJACA I.
 (plexus celiacus, aorticus abdominalis, renalis et suprarenalis)

SYSTEMA LYMPHATICUM

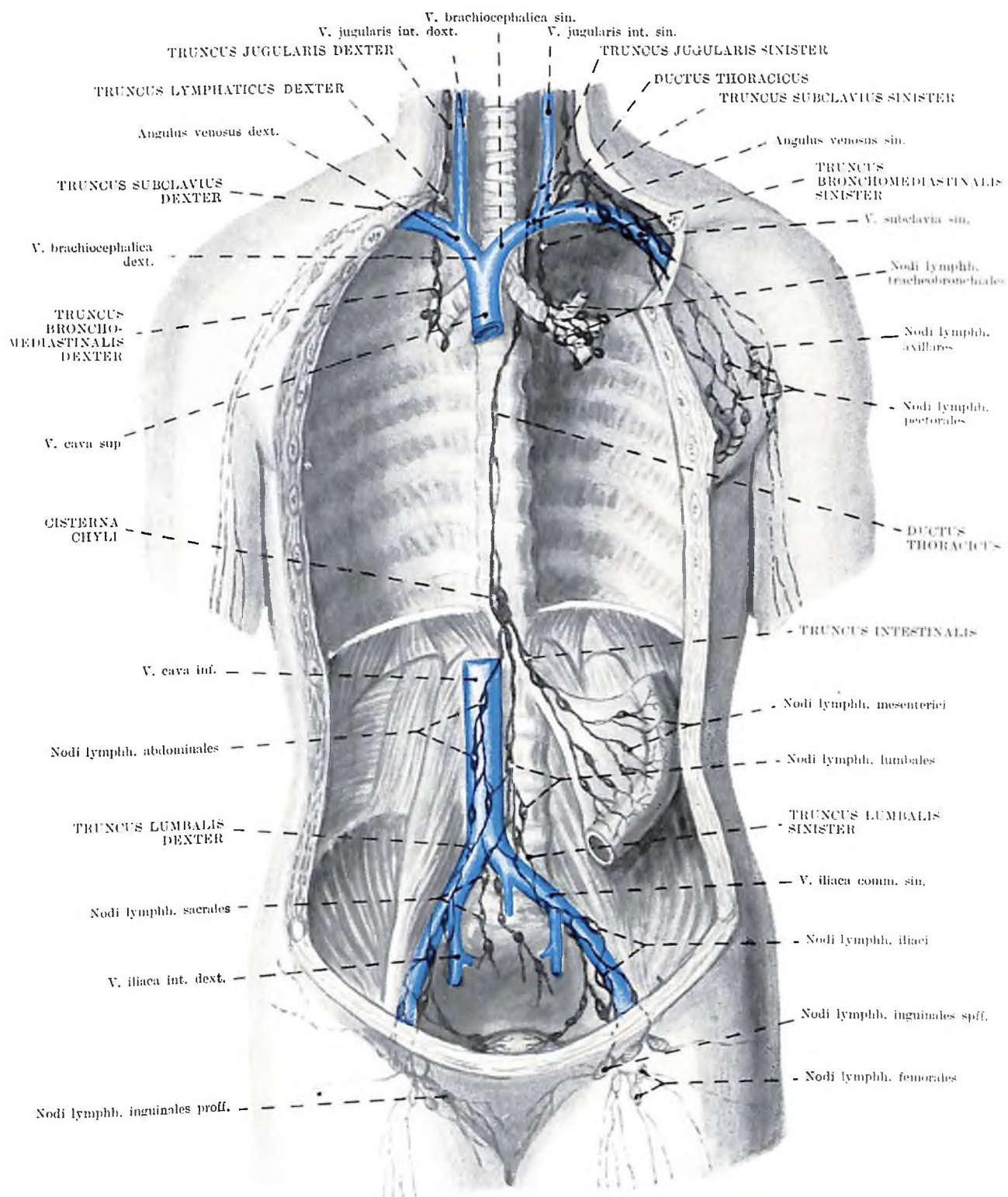
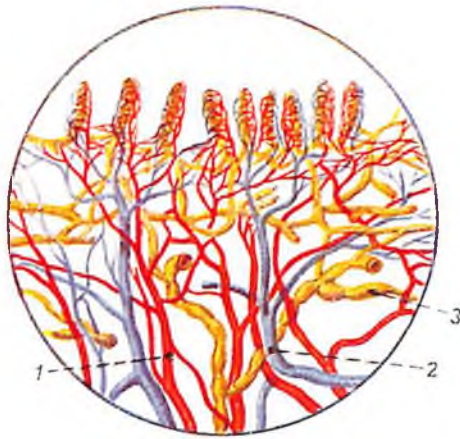
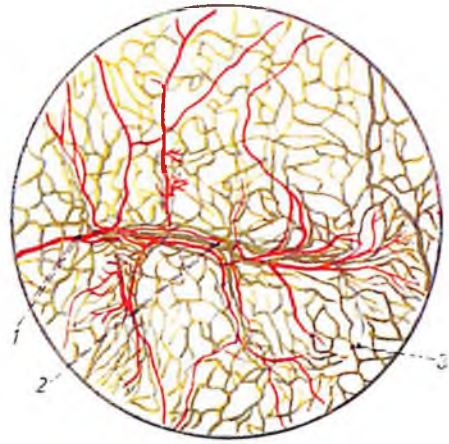


Fig. 192. SYSTEMA LYMPHATICUM
(trunci lymphatici)



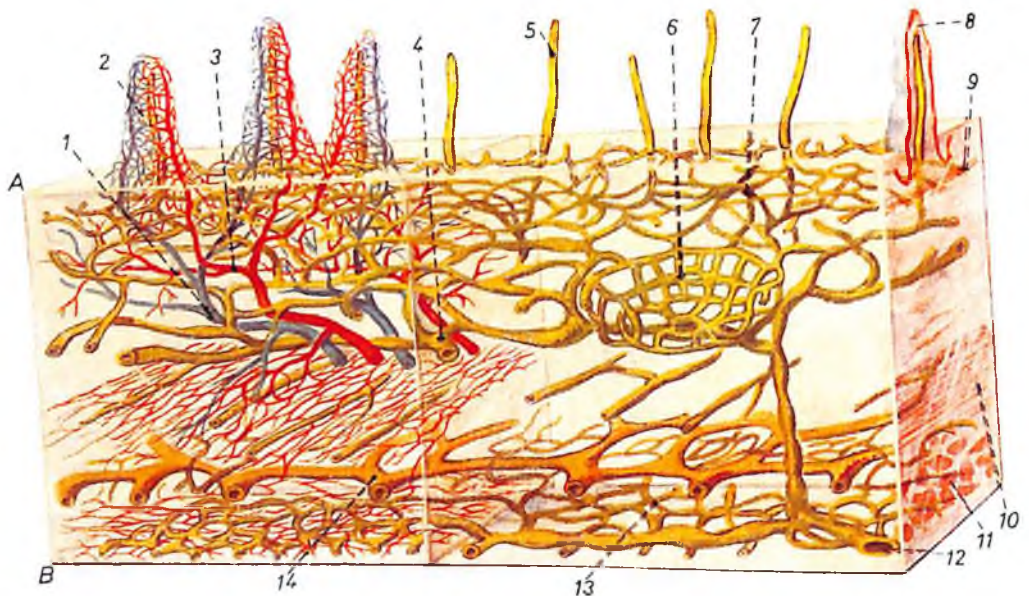
1. Arteria
2. Vena
3. Vas lymphaticum

Fig. 193. STRUCTURA SYSTEMATIS LYMPHATICI I.
(intestinum tenue, preparatum injectum, sectio transversa, fecit A. V. Borisov)



1. Arteria
2. Vas lymphaticum profundum
3. Vasa lymphatica superficialia

Fig. 194. STRUCTURA SYSTEMATIS LYMPHATICI II.
(hepar, preparatum injectum, aspectus e superficie, fecit M. A. Dolgova)



A. Tunica mucosa
B. Tunica serosa
1. Vena
2. Vasa villi intestinalis
3. Arteria
4. Vas lymphaticum efferens telae submucosae
5. Vas lymphaticum centrale villi intestinalis
6. Vasa lymphatica perivillularia
7. Vasa lymphatica telae submucosae
8. Villus intestinalis
9. Lamina muscularis mucosae
10. Tunica muscularis, stratum circulare
11. Tunica muscularis, stratum longitudinale
12. Vas lymphaticum efferens telae subserosae
13. Vasa lymphatica telae subserosae
14. Spatium perineurale

Fig. 195. STRUCTURA SYSTEMATIS LYMPHATICI III.
(intestinum tenue, angioarchitectum, sectio longitudinalis, secundum A. V. Borisov)

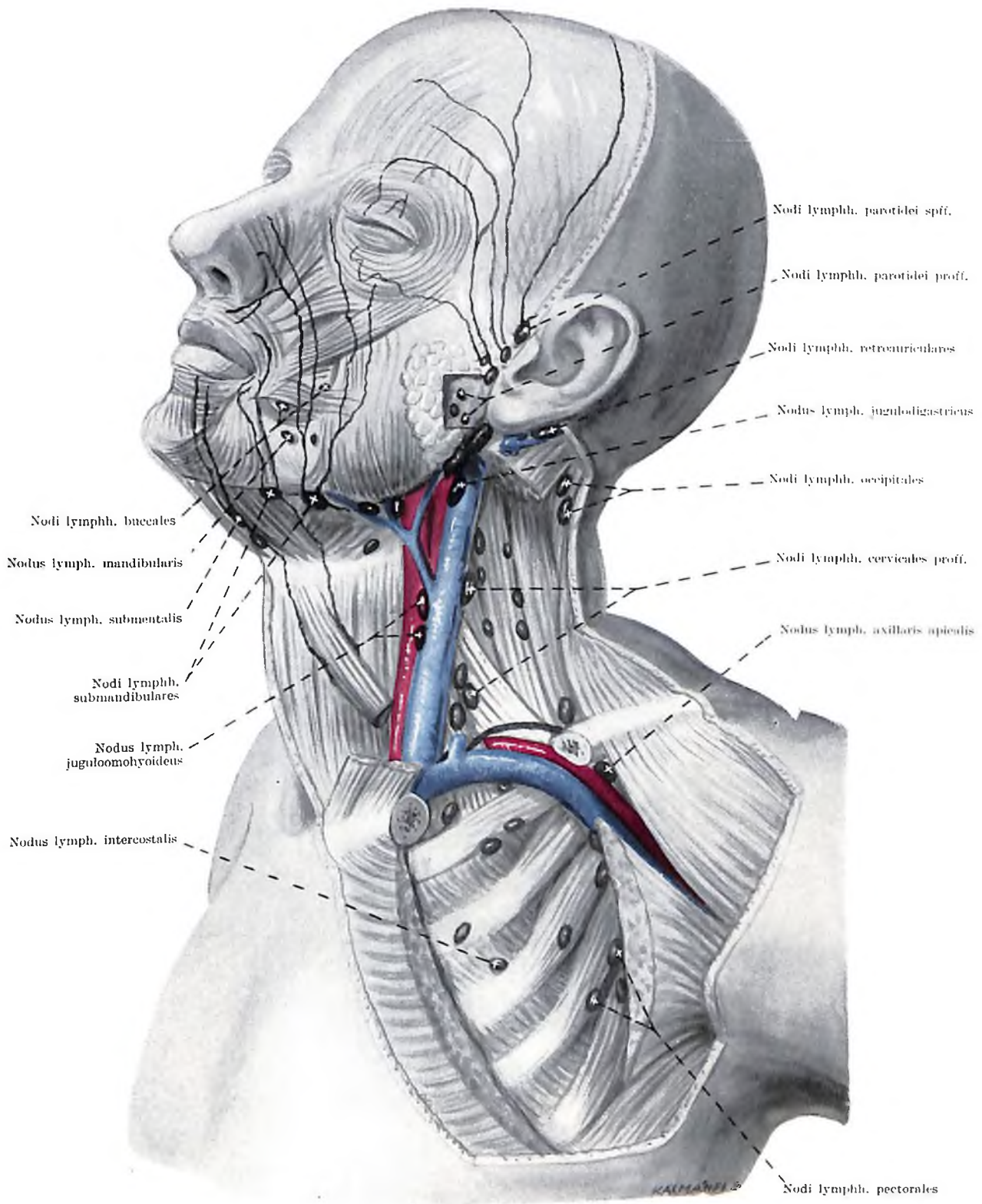


Fig. 196. VASA LYMPHATICA ET NODI LYMPHATICI CAPITIS, CERVICIS ET THORACIS SUPERFICIALES

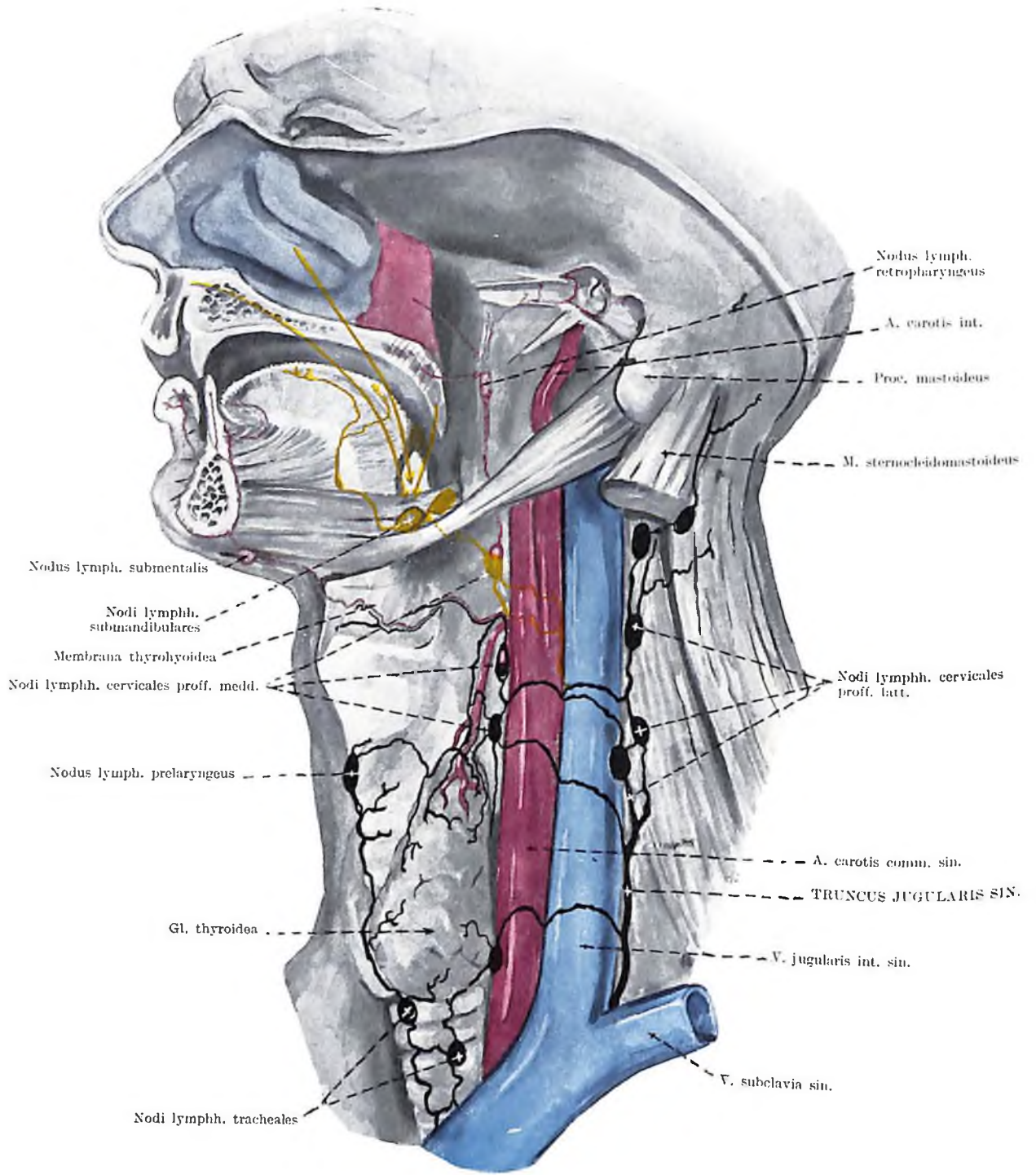


Fig. 197. VASA LYMPHATICA ET NODI LYMPHATICI CERVICIS

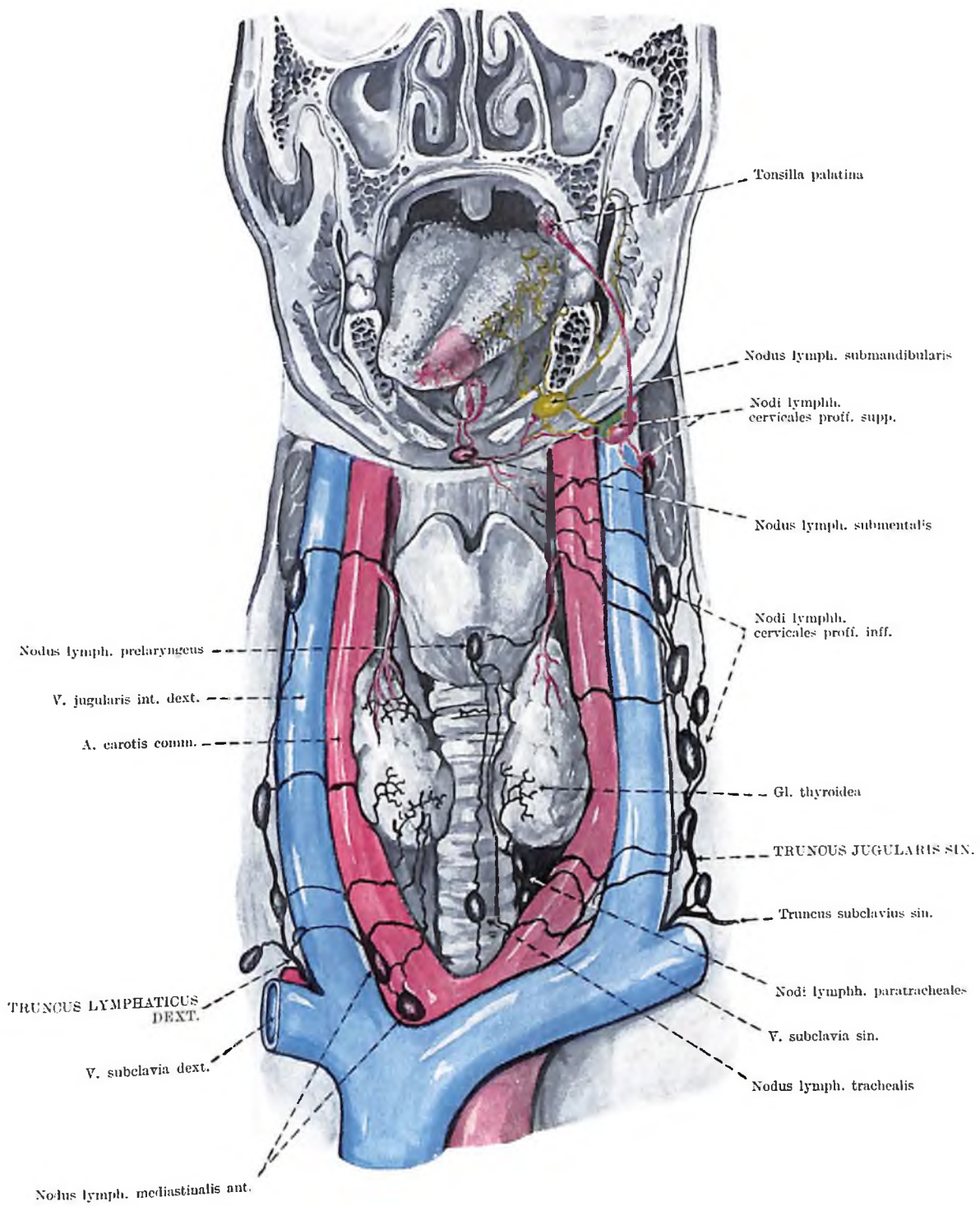


Fig. 198. VASA LYMPHATICA ET NODI LYMPHATICI FACIEI ET CERVICALES PROFUNDI

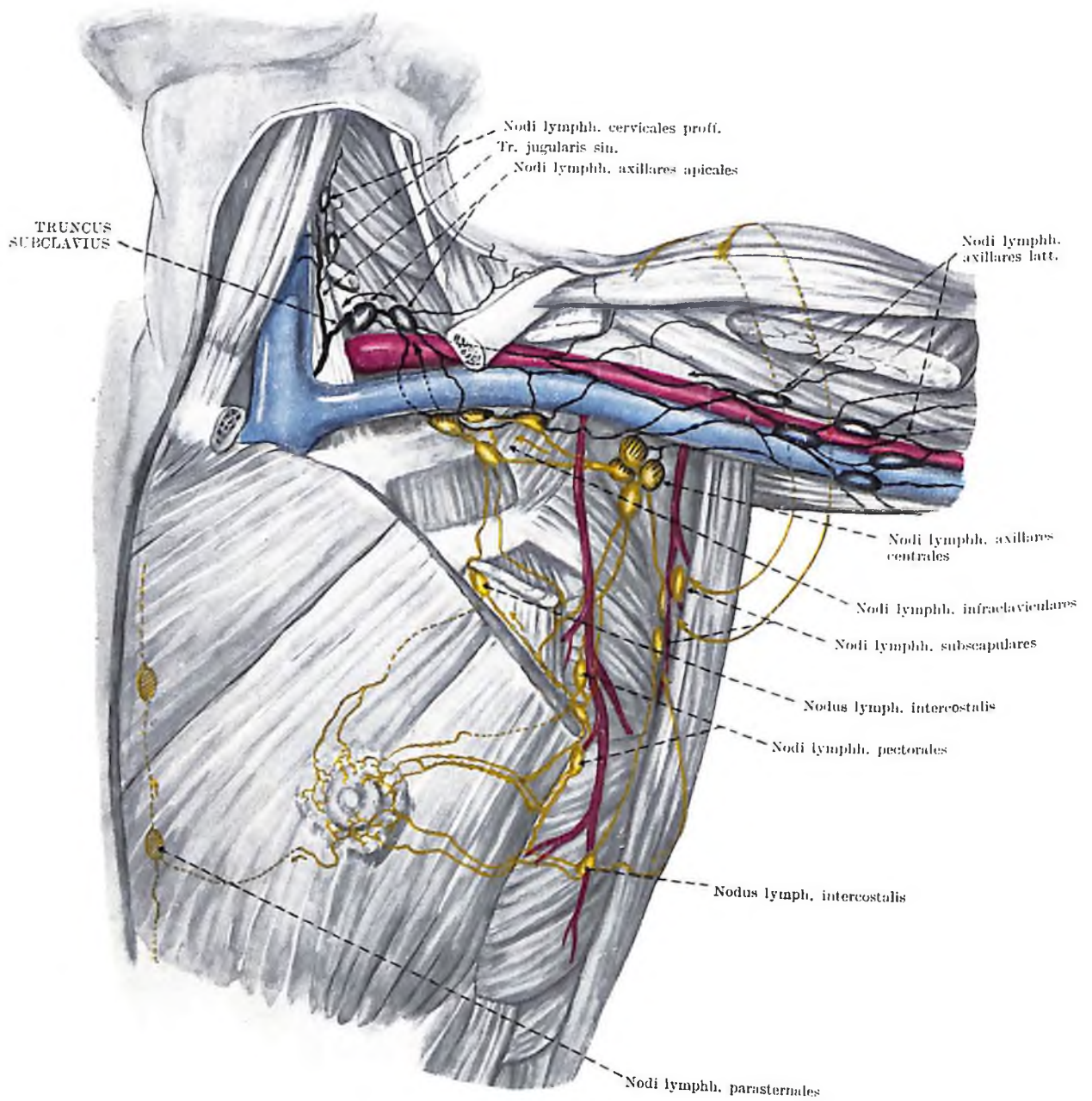


Fig. 199. VASA LYMPHATICA ET NODI LYMPHATICI REGIONUM MAMMALIS, AXILLARIS, INFRACLAVICULARIS ET COLLI LATERALIS

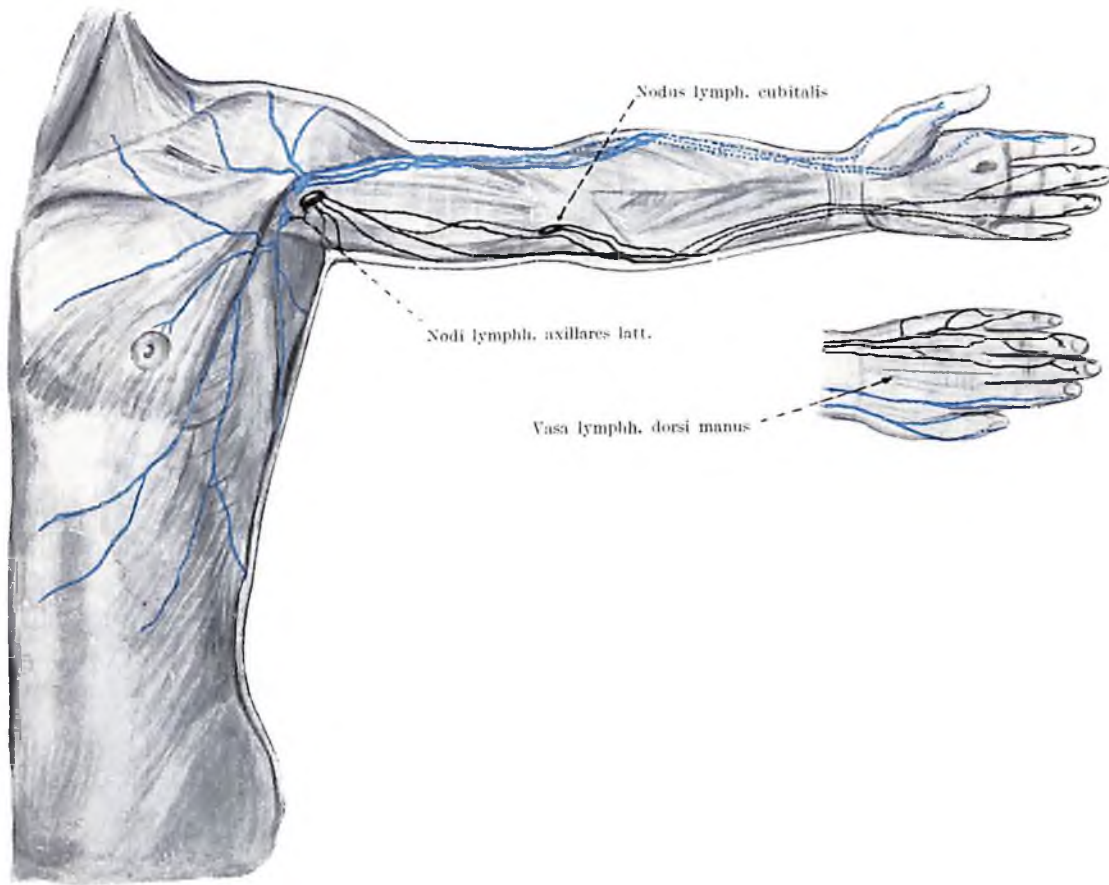


Fig. 200. VASA LYMPHATICA ET NODI LYMPHATICI MEMBRI SUPERIORIS

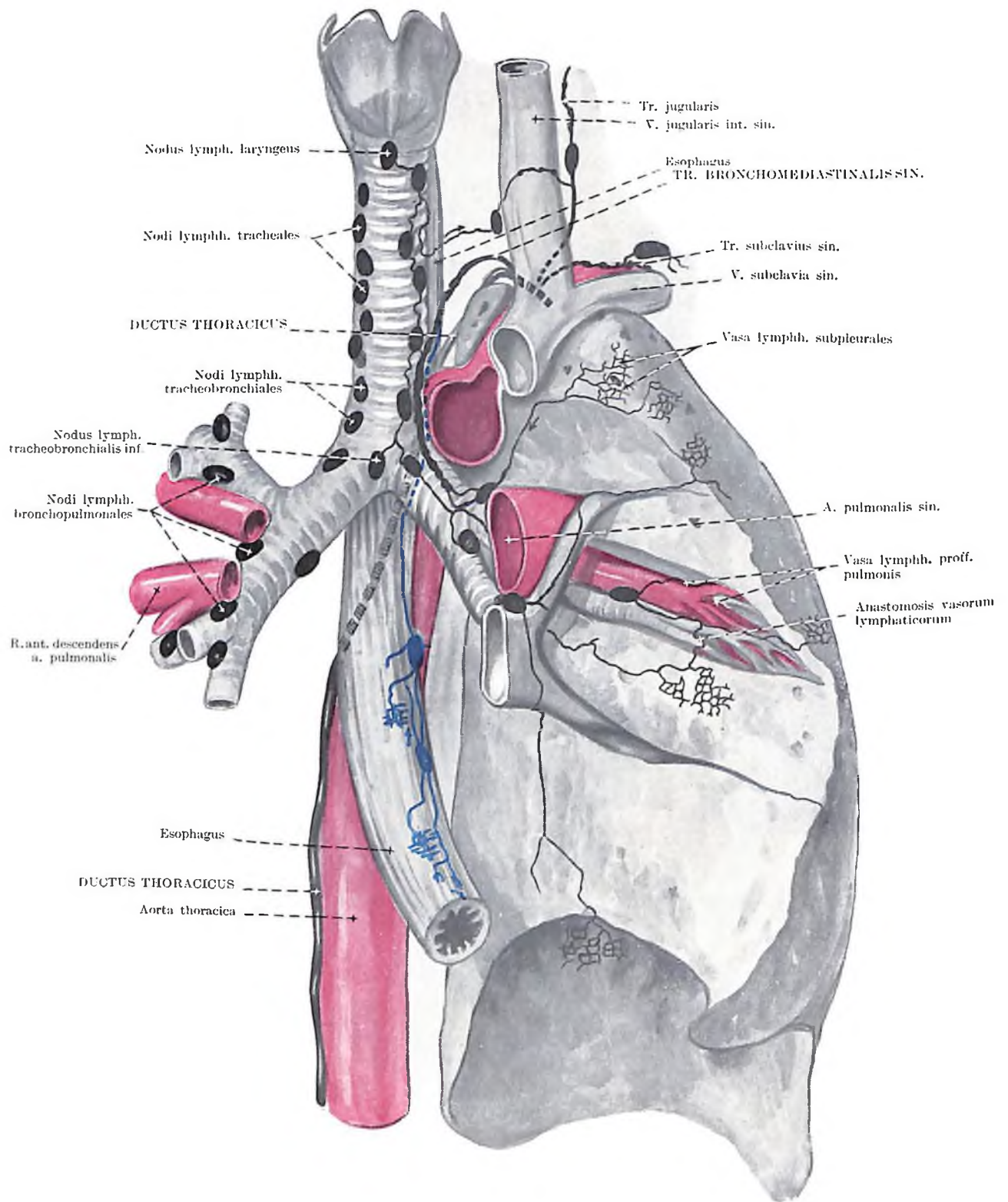


Fig. 201. VASA LYMPHATICA ET NODI LYMPHATICI MEDIASTINALES I.

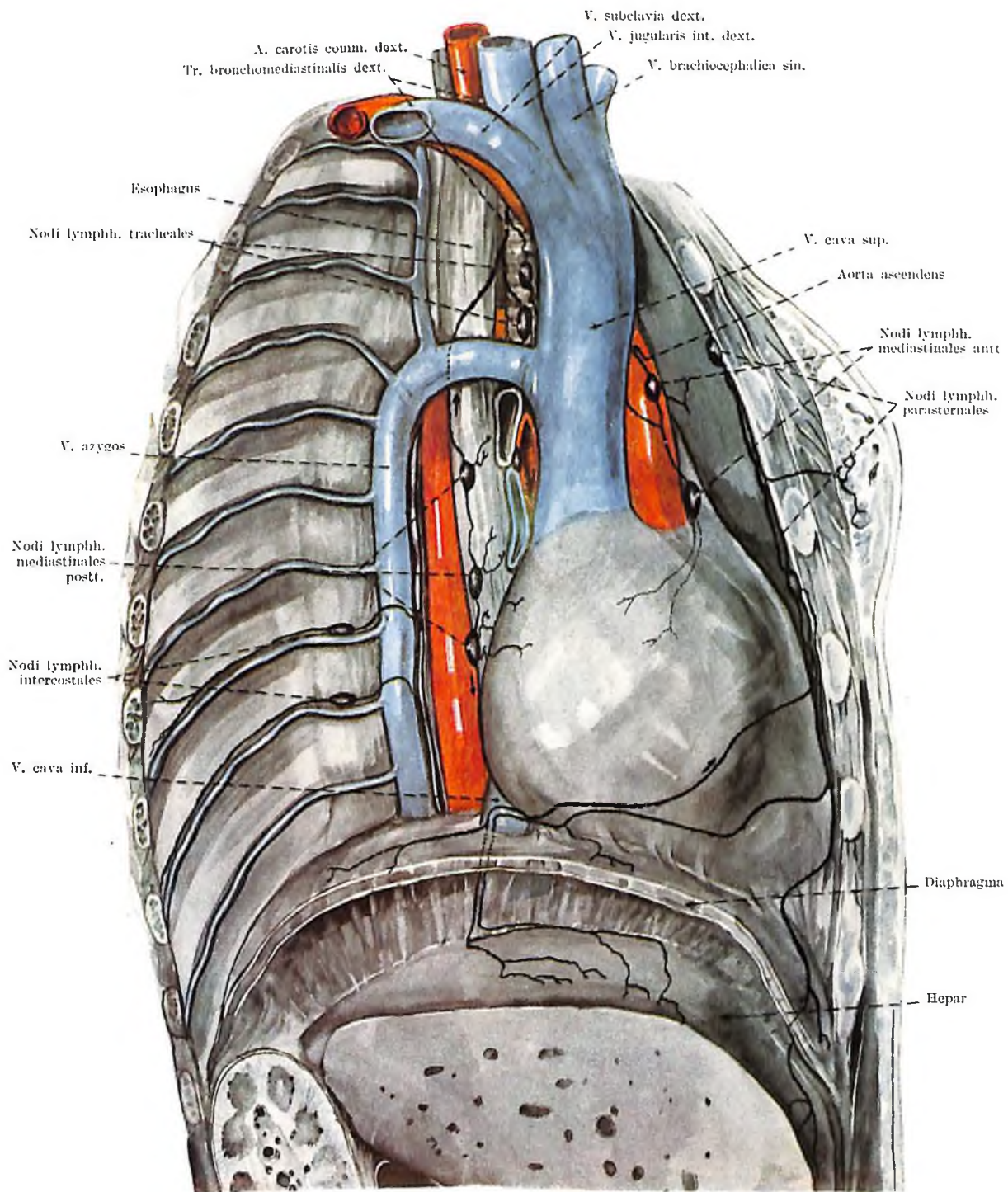


Fig. 202. VASA LYMPHATICA ET NODI LYMPHATICI MEDIASTINALES II.

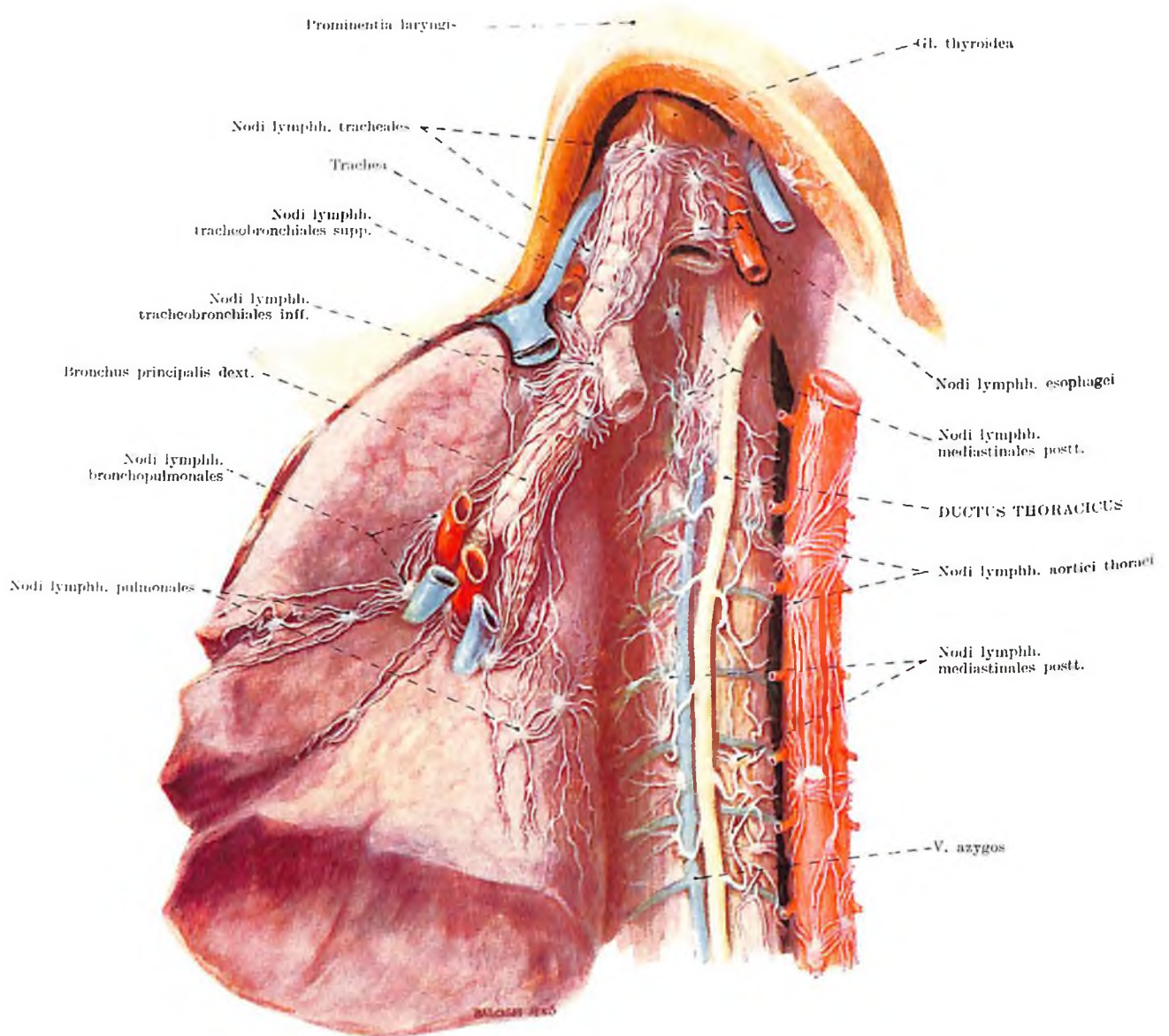


Fig. 203. VASA LYMPHATICA ET NODI LYMPHATICI MEDIASTINALES III.
(fecerunt Mascagni et Fontana, anno 1788.)

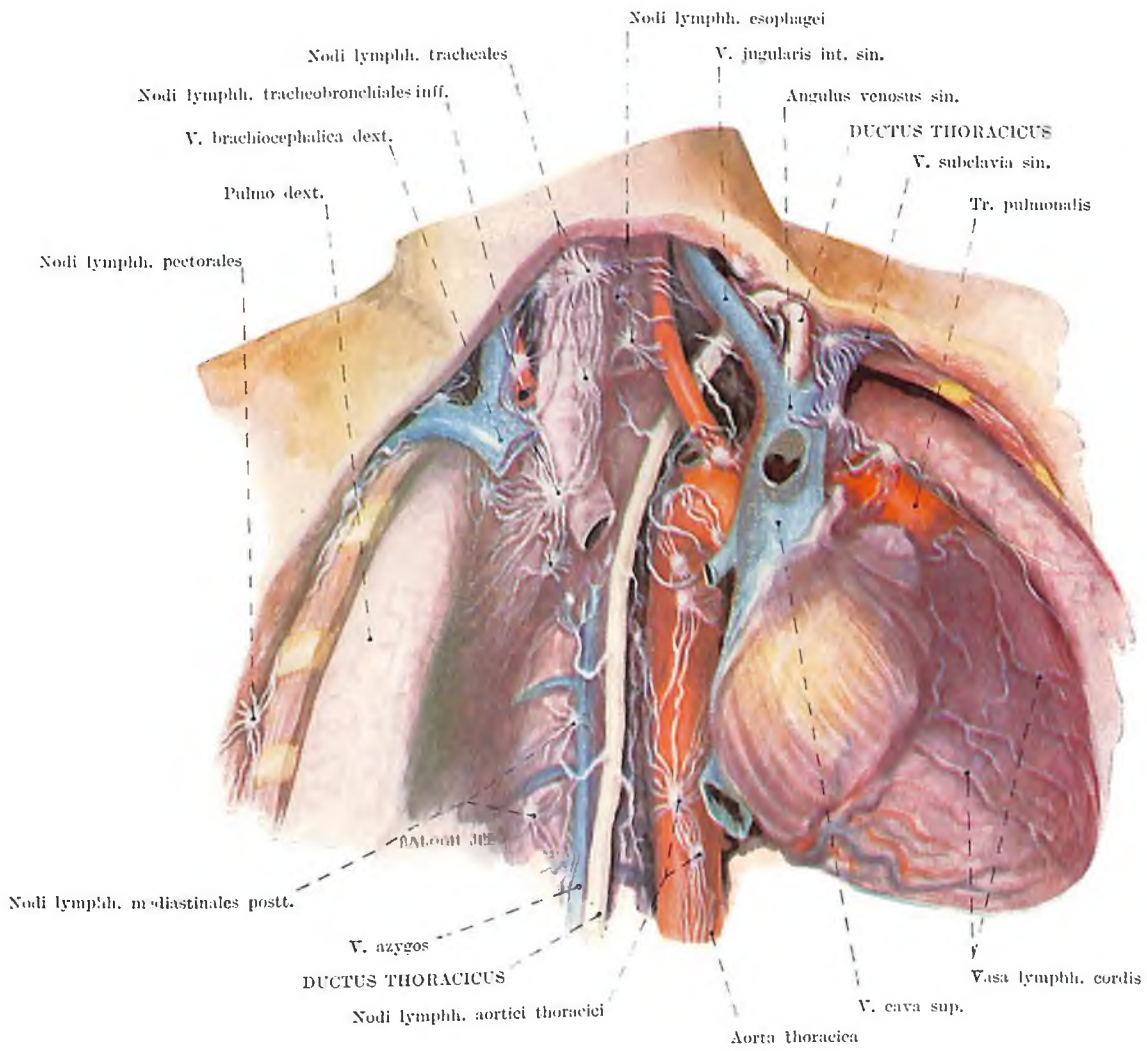


Fig. 204. VASA LYMPHATICA ET NODI LYMPHATICI MEDIASTINALES IV.
 (fecerunt Mascagni et Fontana, anno 1788.)

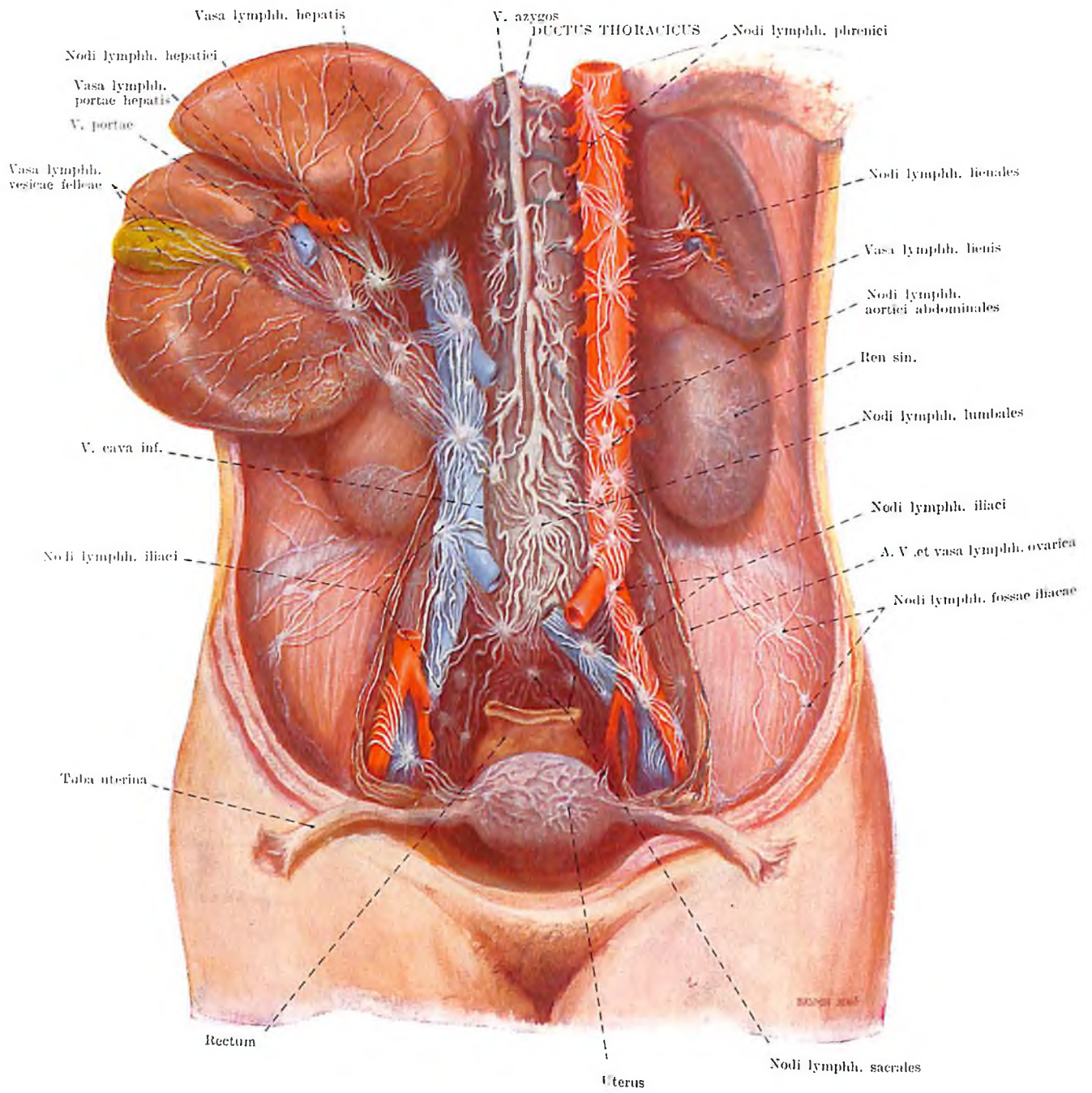


Fig. 205. VASA LYMPHATICA ET NODI LYMPHATICI RETROPERITONEALES I.
(fecerunt Mascagni et Fontana, anno 1788.)

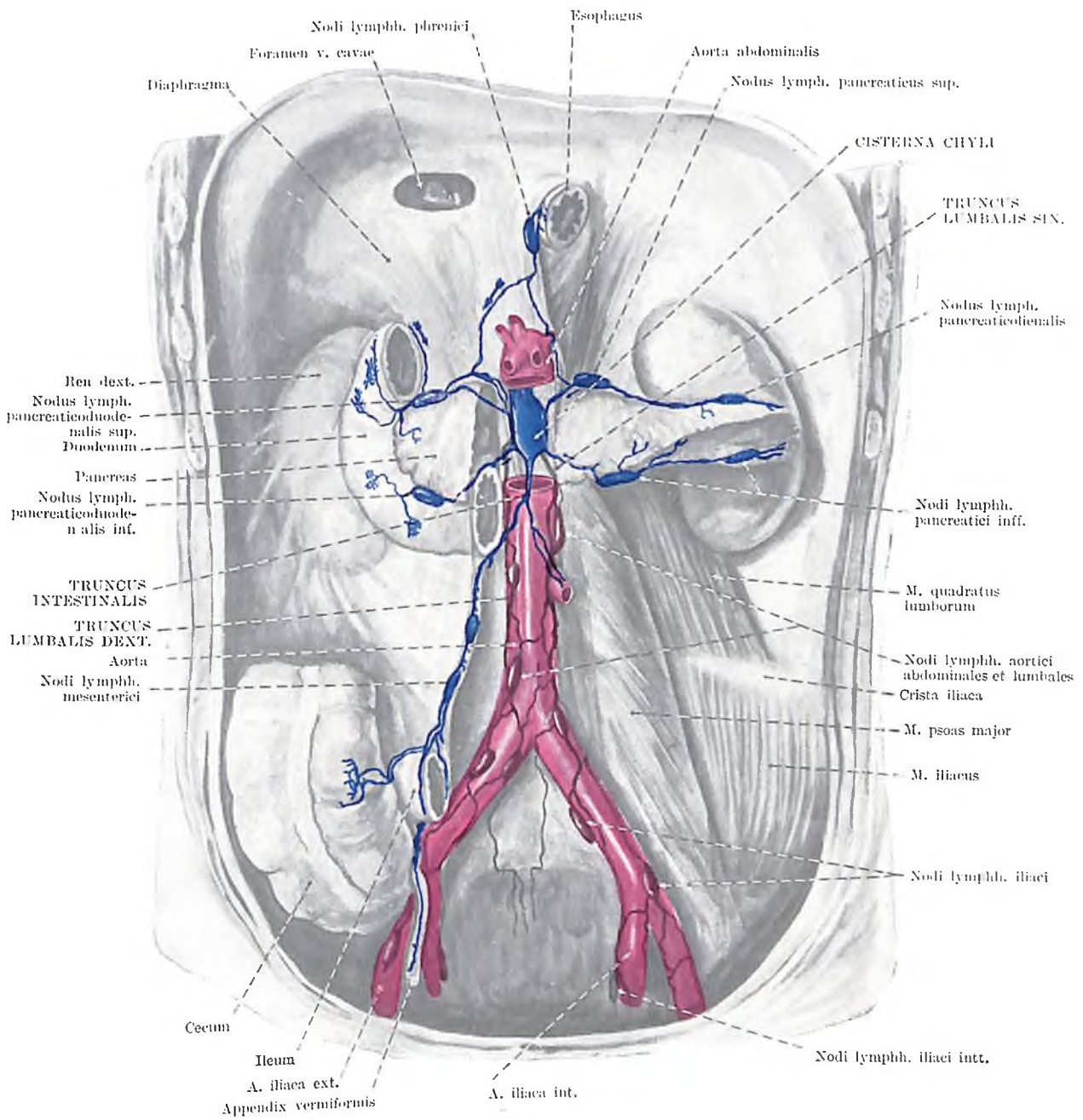


Fig. 206. VASA LYMPHATICA ET NODI LYMPHATICI RETROPERITONEALES II.

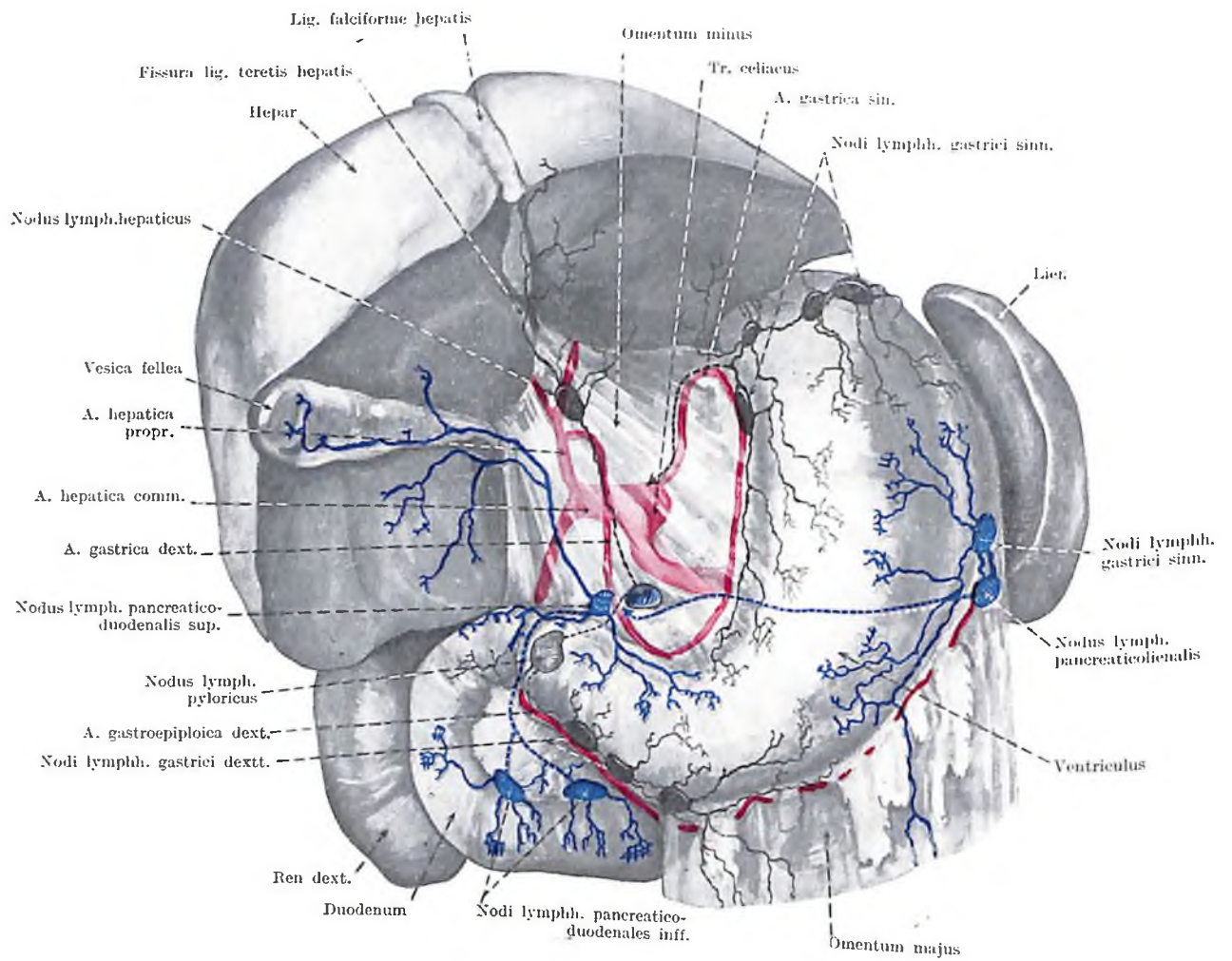


Fig. 207. VASA LYMPHATICA ET NODI LYMPHATICI VENTRICULI, HEPATIS ET DUODENI

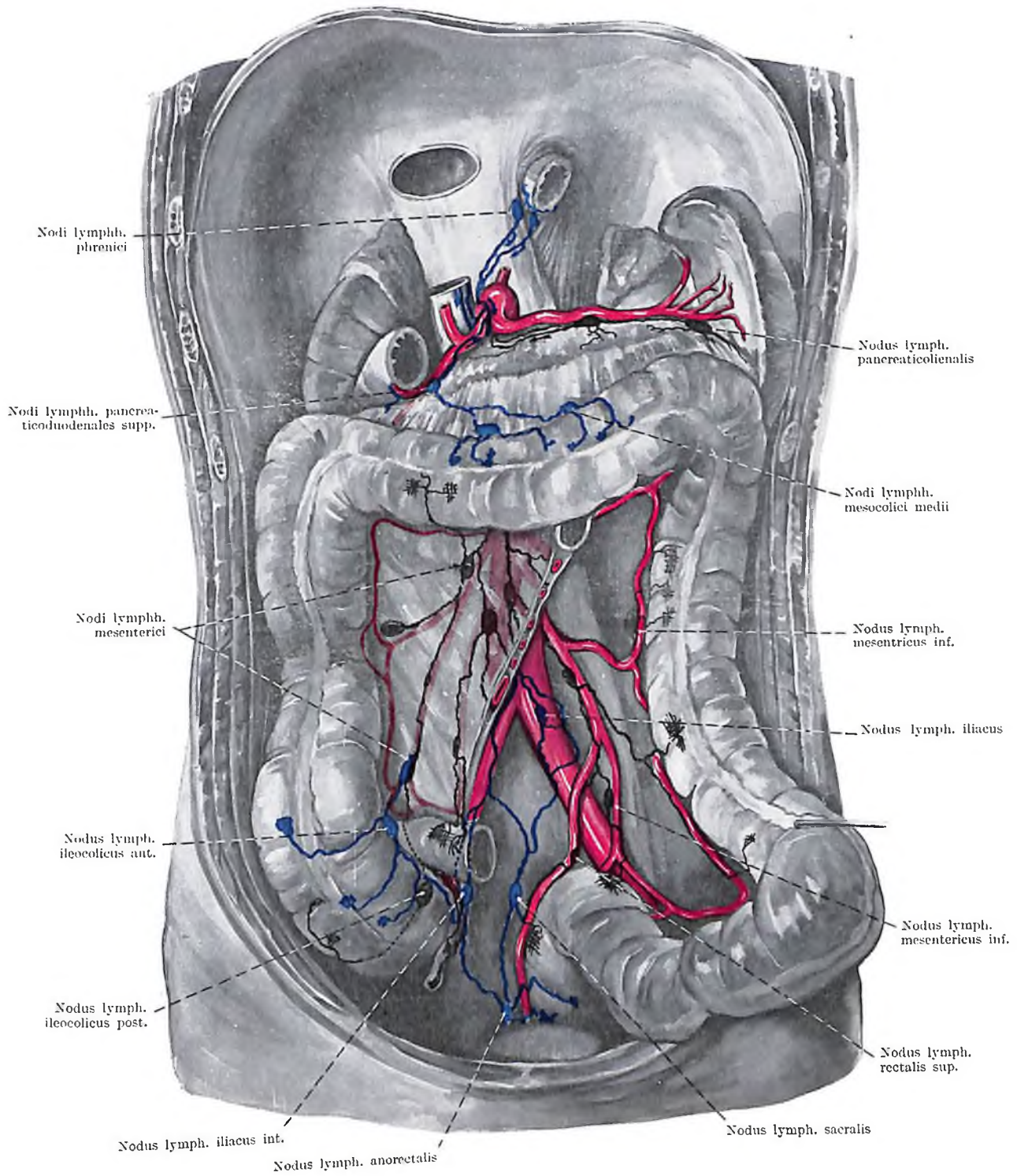


Fig. 208. VASA LYMPHATICA ET NODI LYMPHATICI MESENTERICI

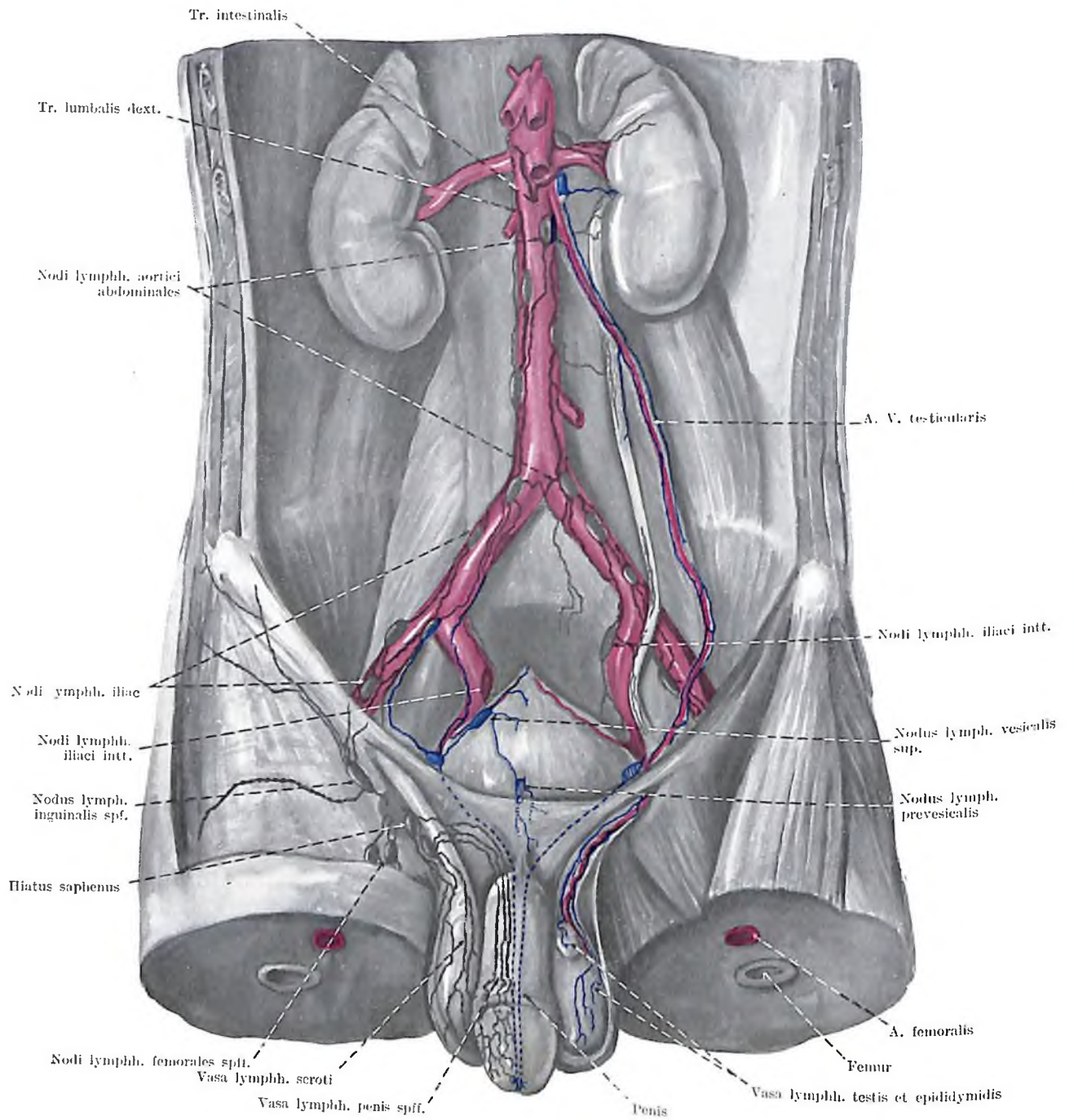


Fig. 209. VASA LYMPHATICA ET NODI LYMPHATICI ORGANORUM
GENITALIUM MASCULINORUM

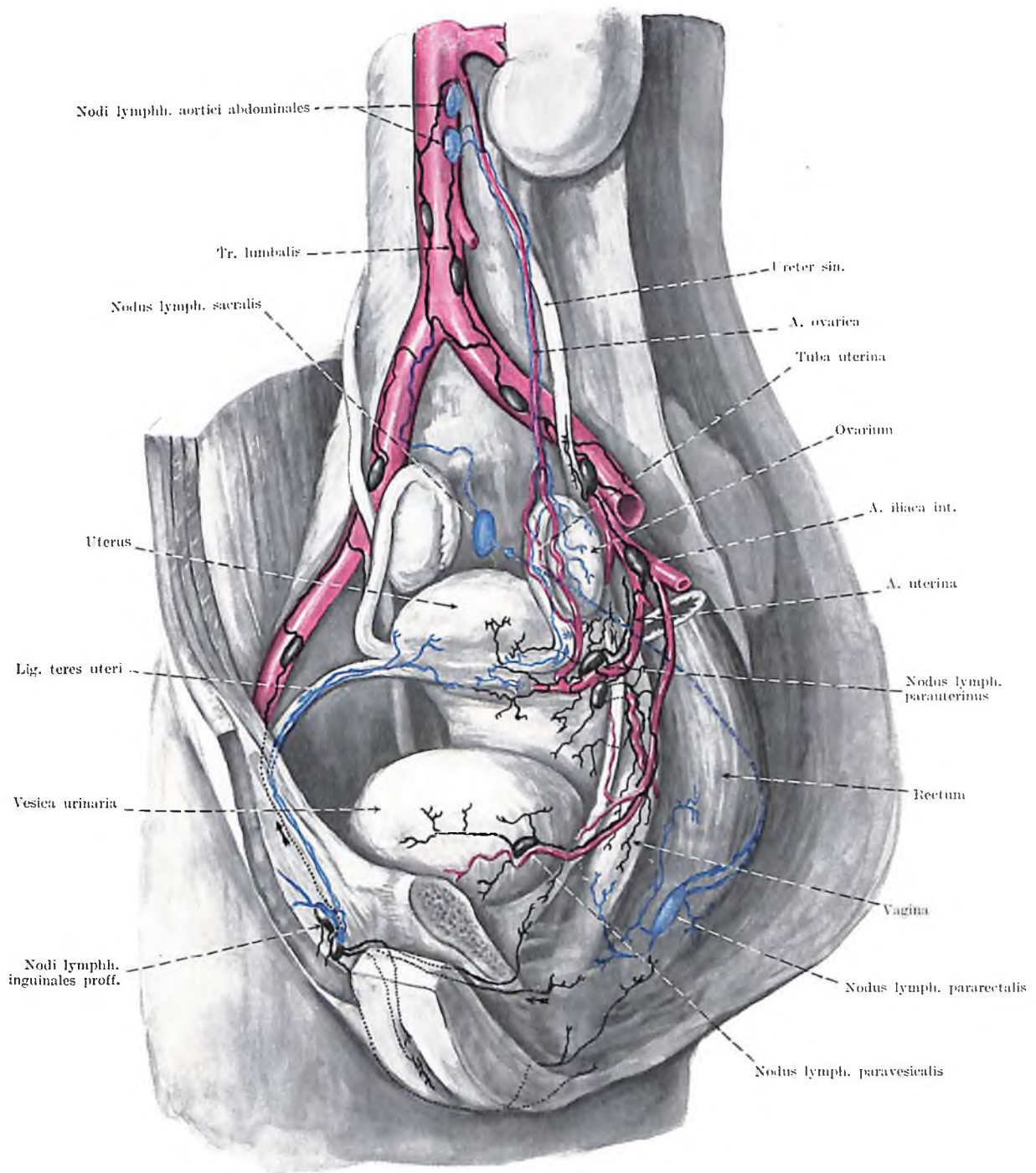


Fig. 210. VASA LYMPHATICA ET NODI LYMPHATICI ORGANORUM
GENITALIUM FEMININORUM

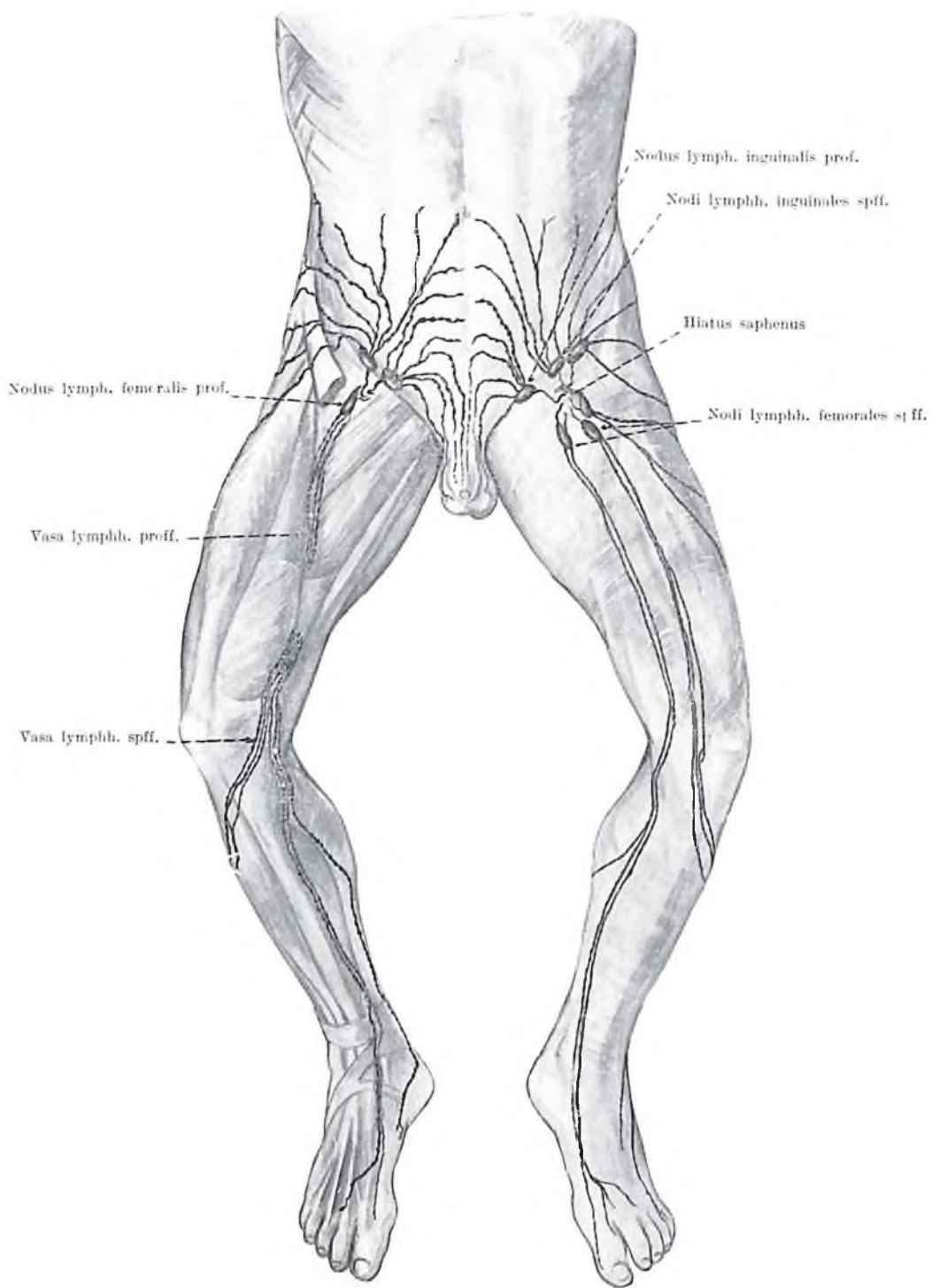


Fig. 211. VASA LYMPHATICA ET NODI LYMPHATICI MEMBRI INFERIORIS I.
(aspectus anterior)

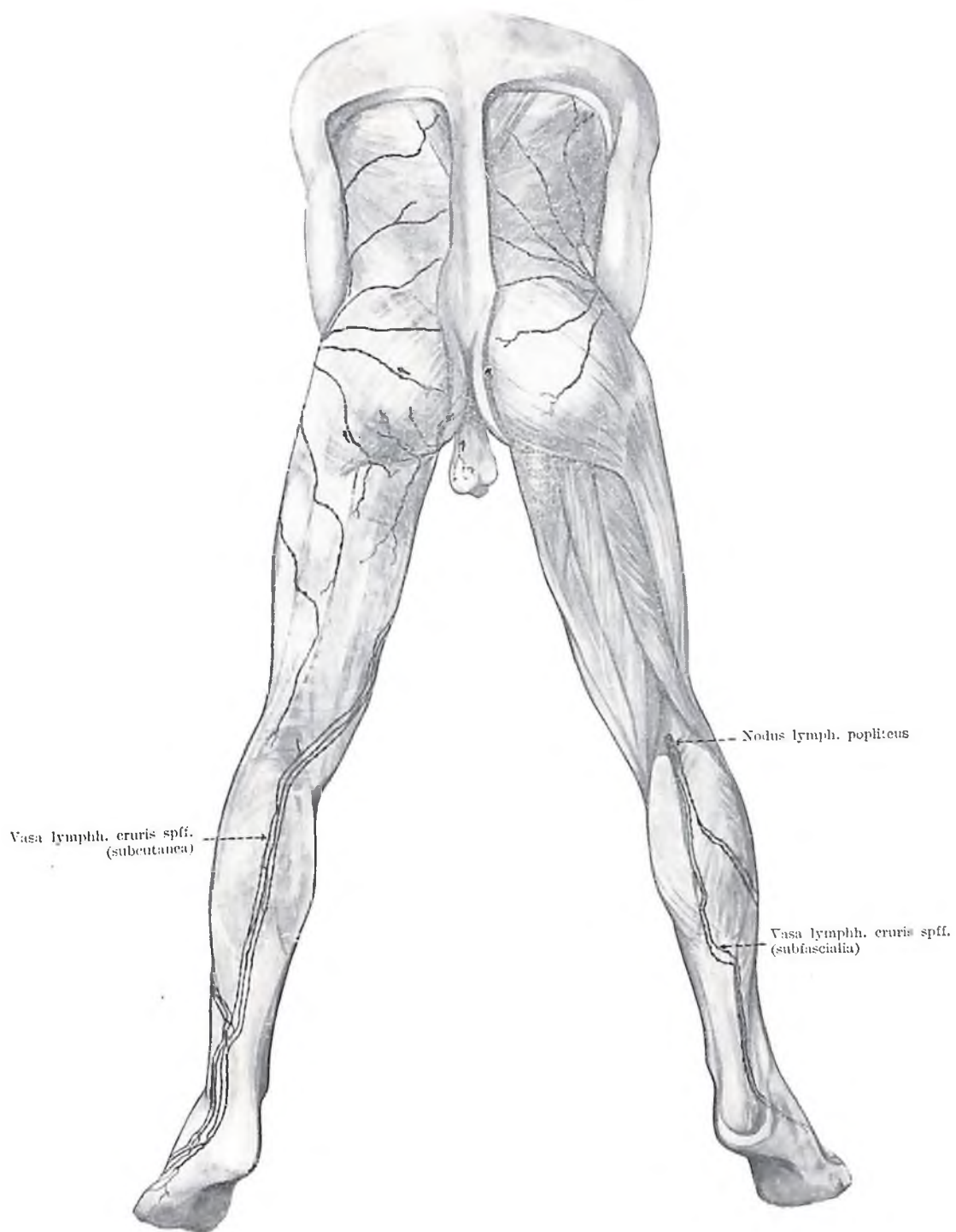


Fig. 212. VASA LYMPHATICA ET NODI LYMPHATICI MEMBRI INFERIORIS II.
(aspectus posterior)

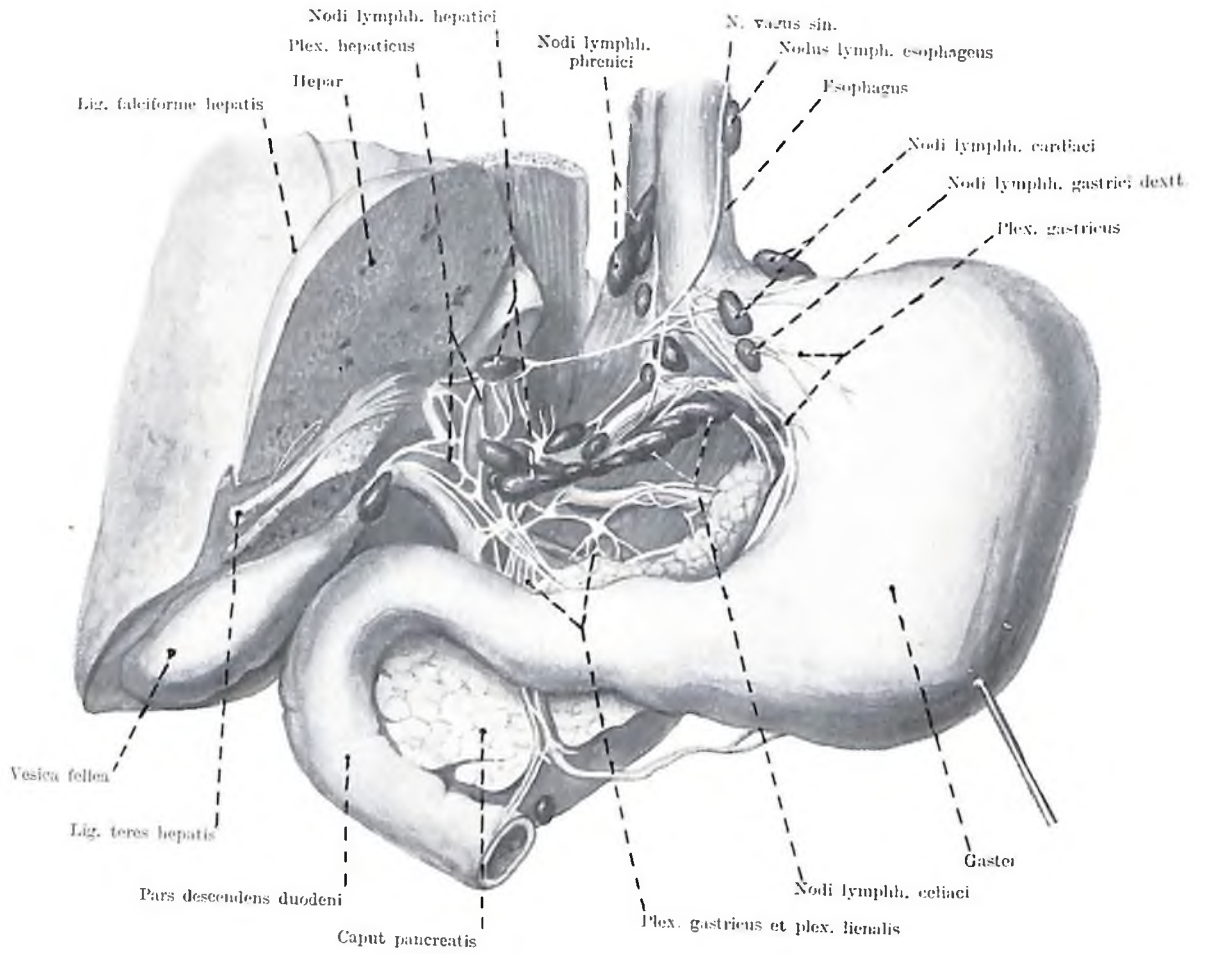


Fig. 213. NODI LYMPHATICI ET PLEXUS AUTONOMICUS CELIACI

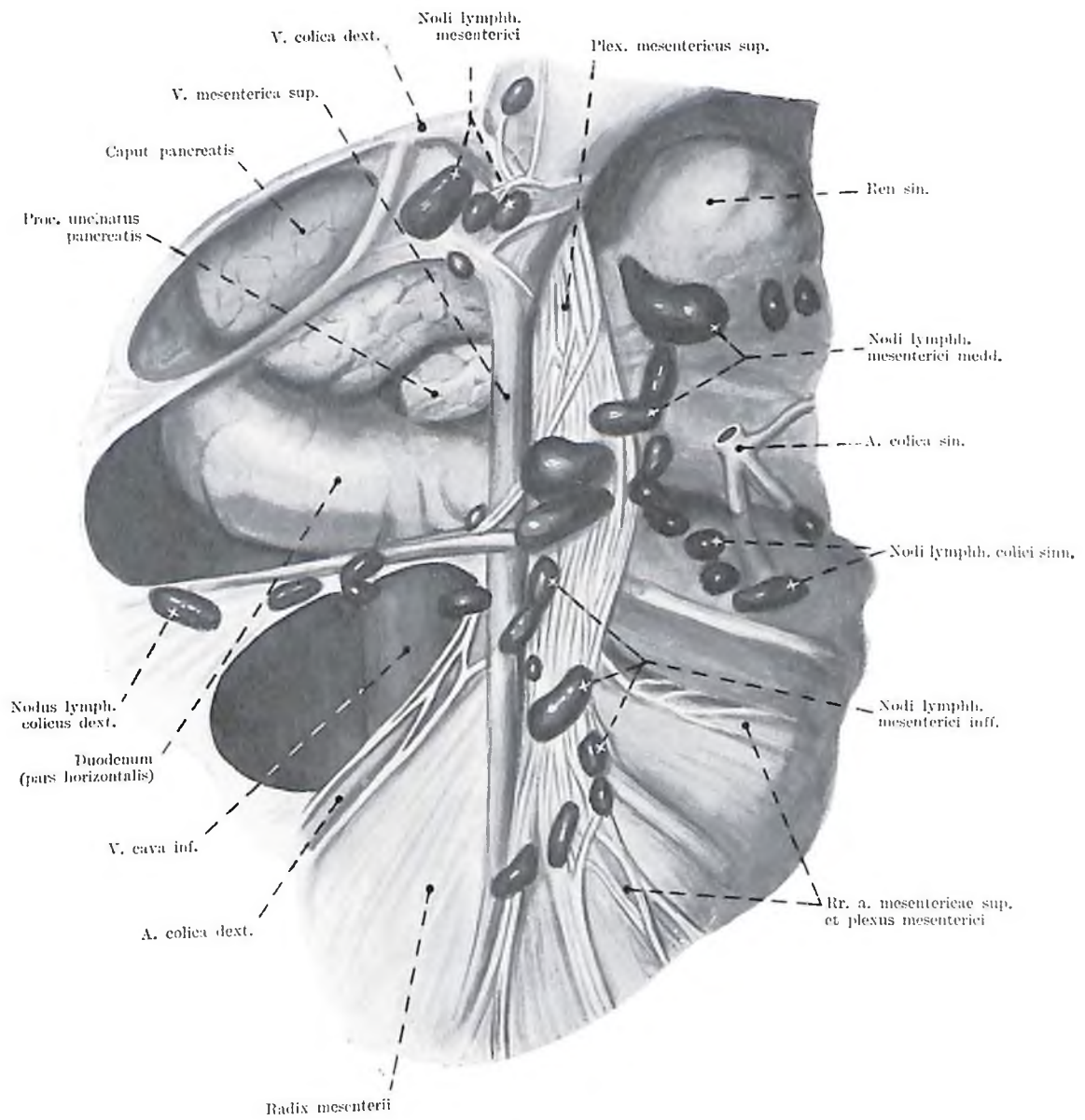


Fig. 214. NODI LYMPHATICI ET PLEXUS AUTONOMICI MESENTERICI

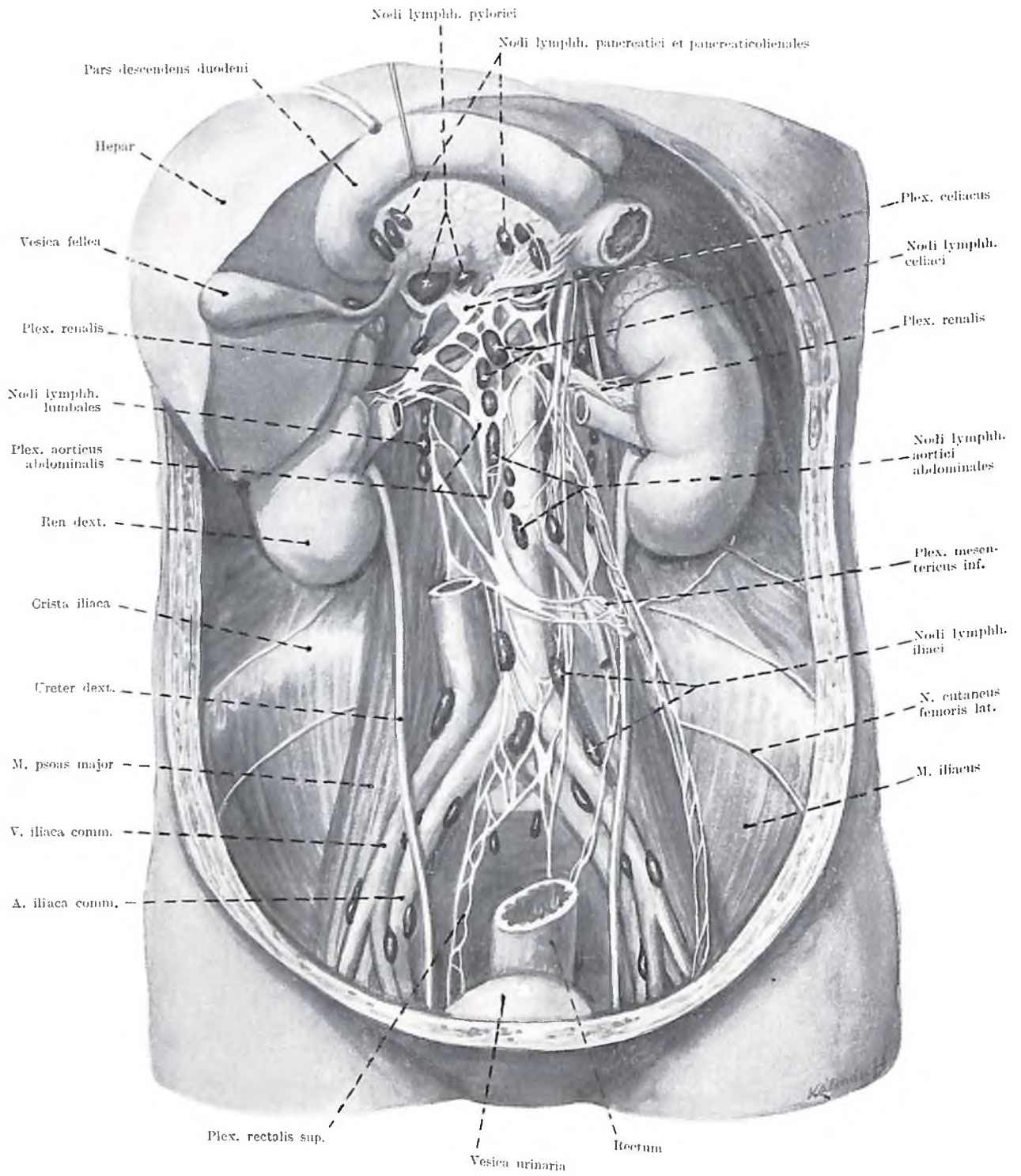


Fig. 215. NODI LYMPHATICI ET PLEXUS AUTONOMICI RETROPERITONEALES

ORGANA SENSUUM

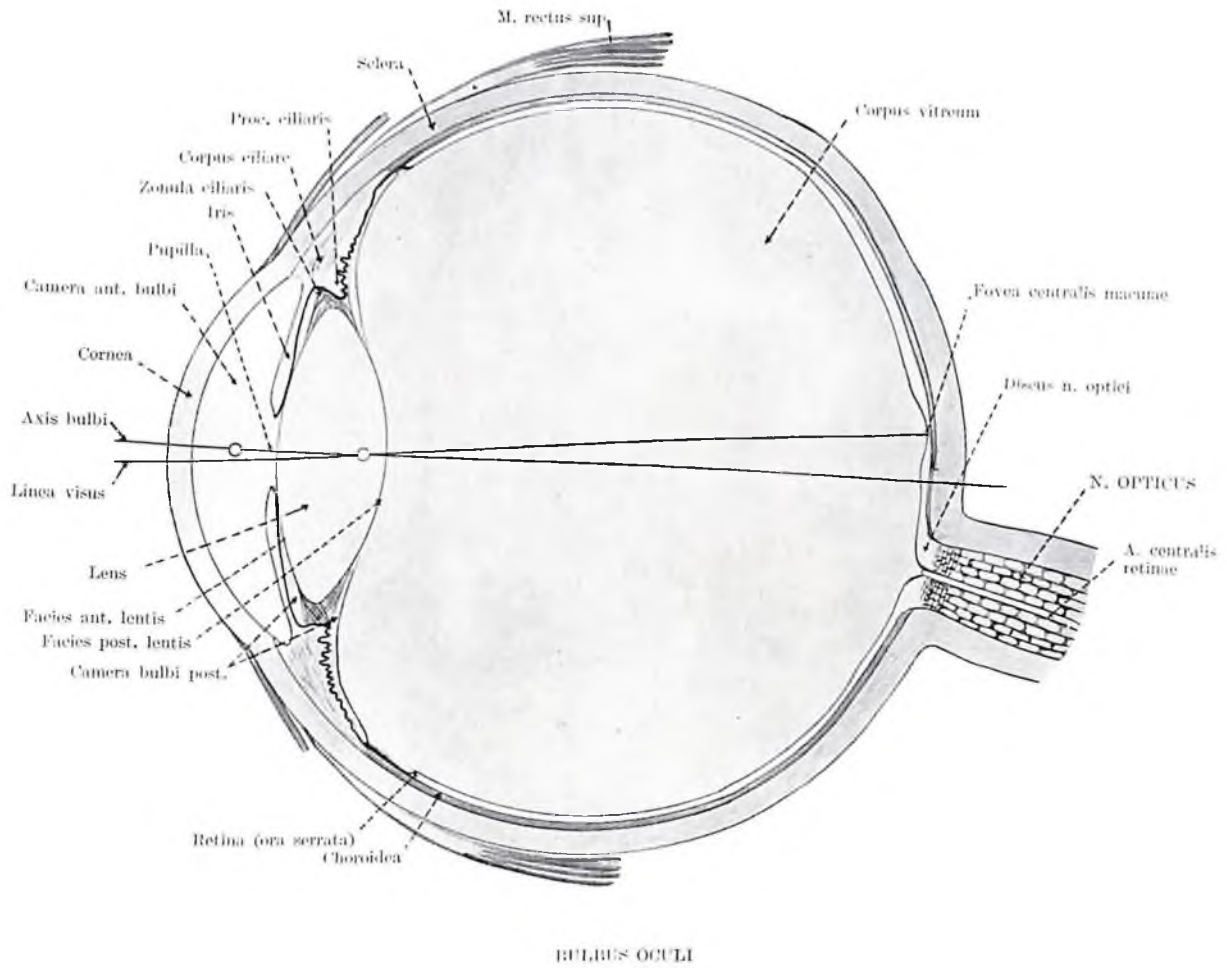


Fig. 216. ORGANUM VISUS, OCULUS
(sectio horizontalis bulbi oculi)

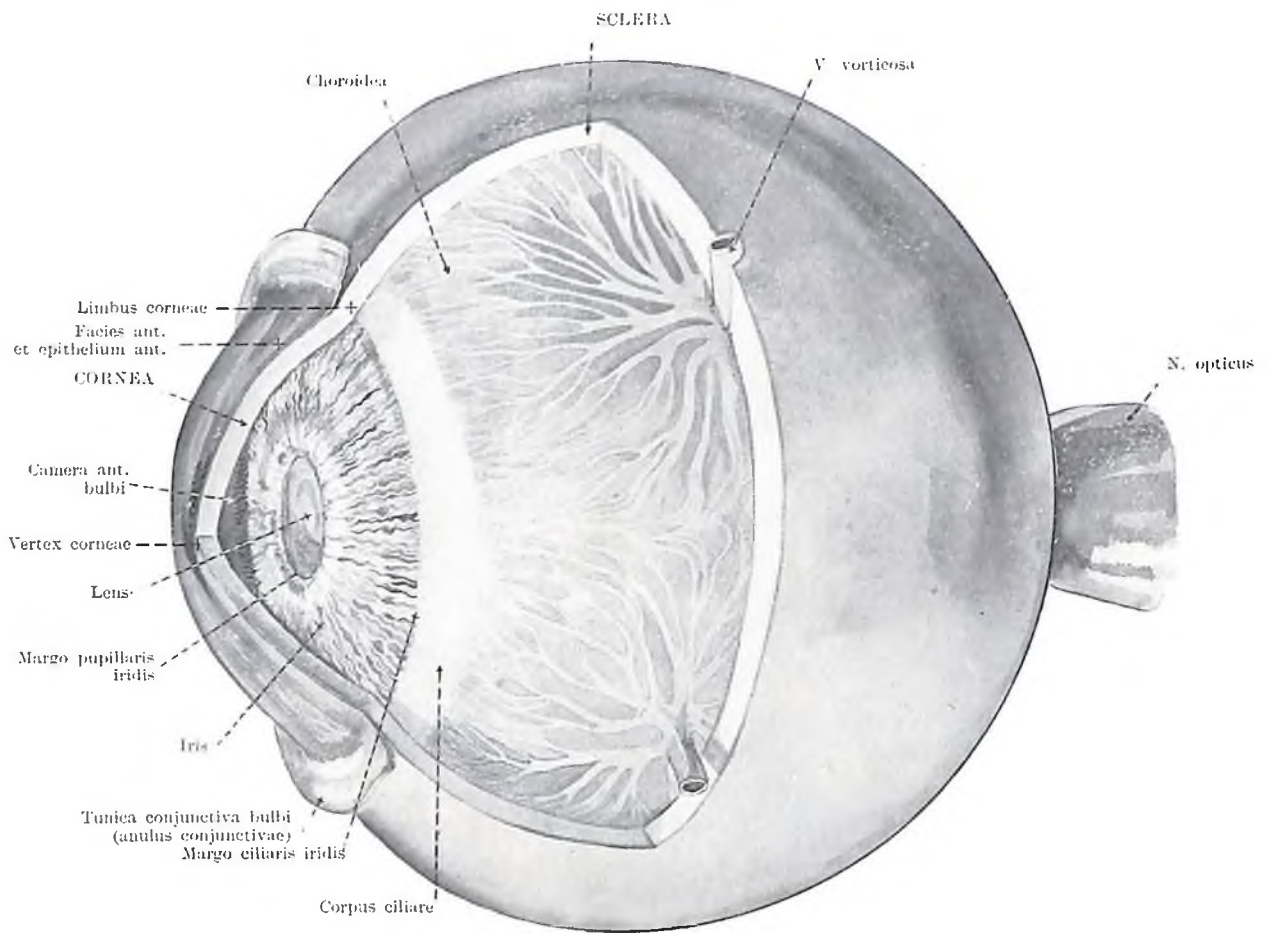


Fig. 217. BULBUS OCULI I.
(tunica fibrosa bulbi)

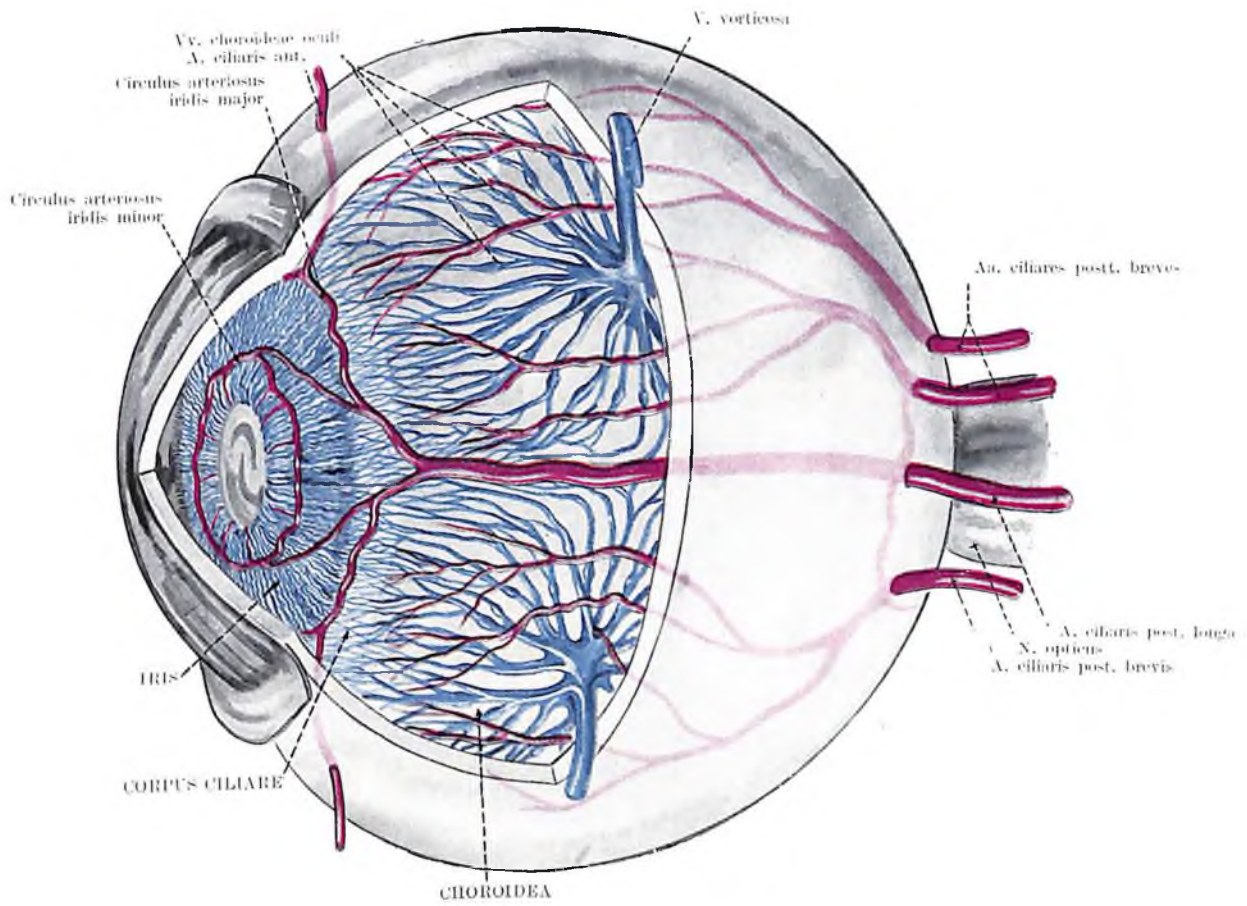


Fig. 218. BULBUS OCULI II.
(tunica vasculosa bulbi)

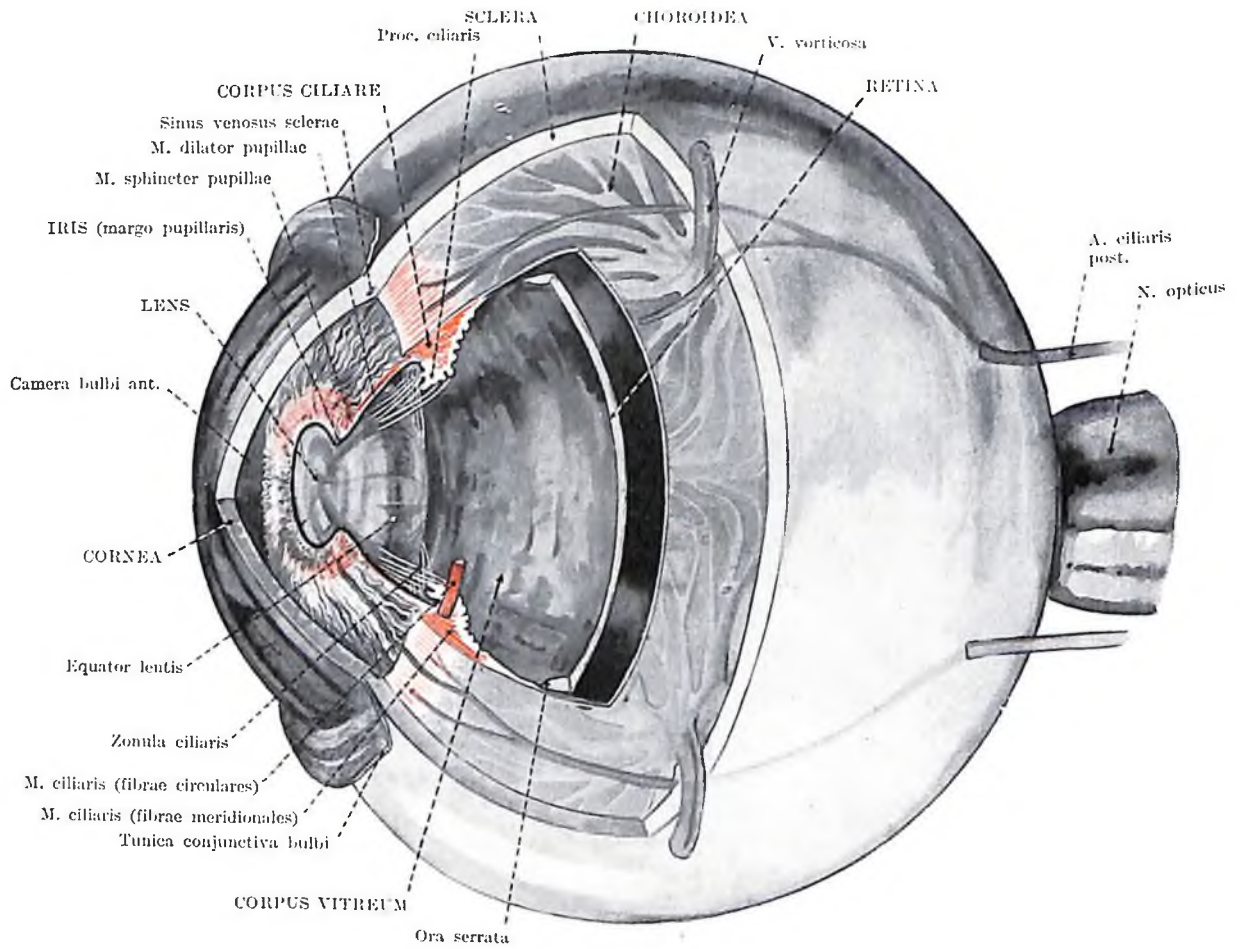


Fig. 219. BULBUS OCULI III.
(structura bulbi)

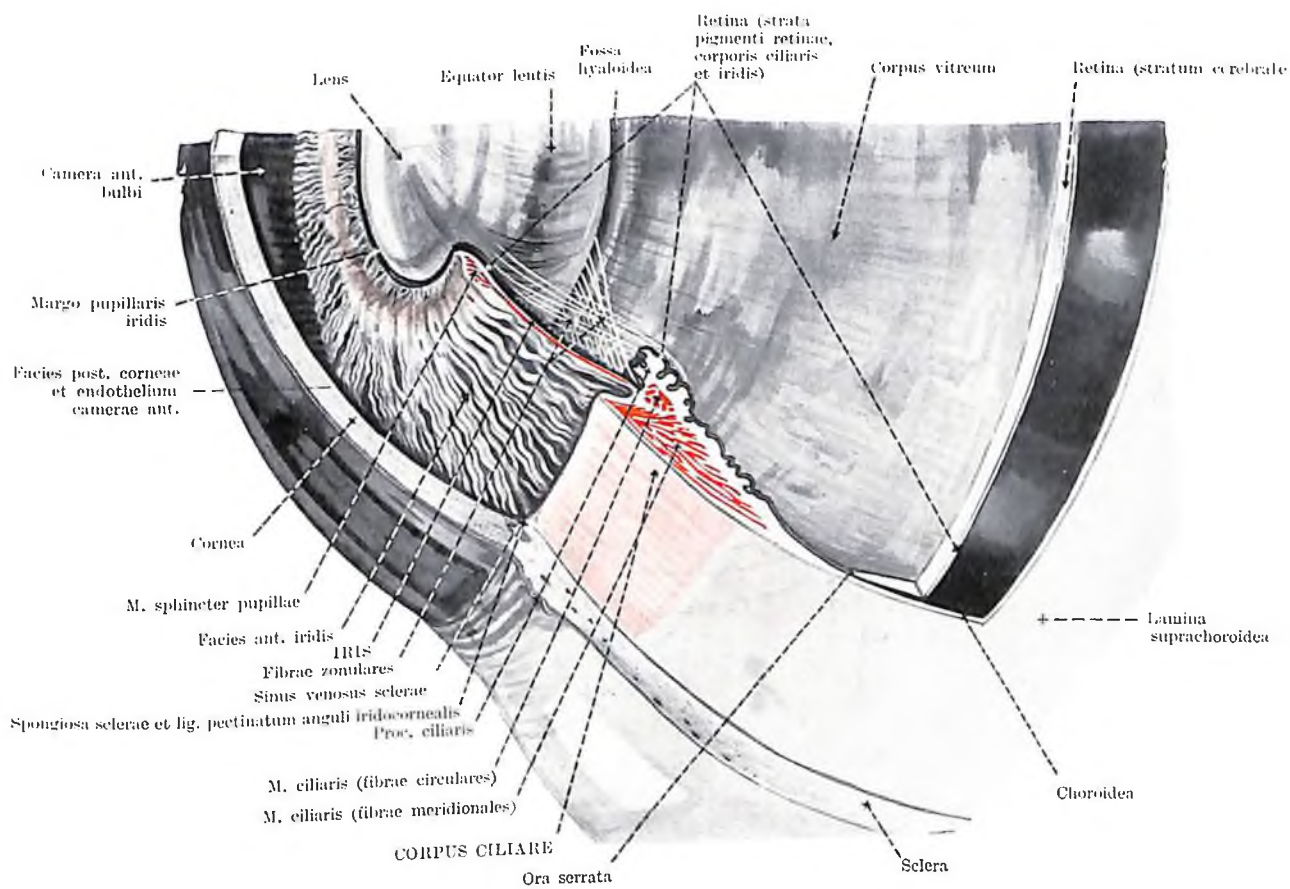


Fig. 220. CORPUS CILIARE ET IRIS
(structura partis anterioris bulbi)

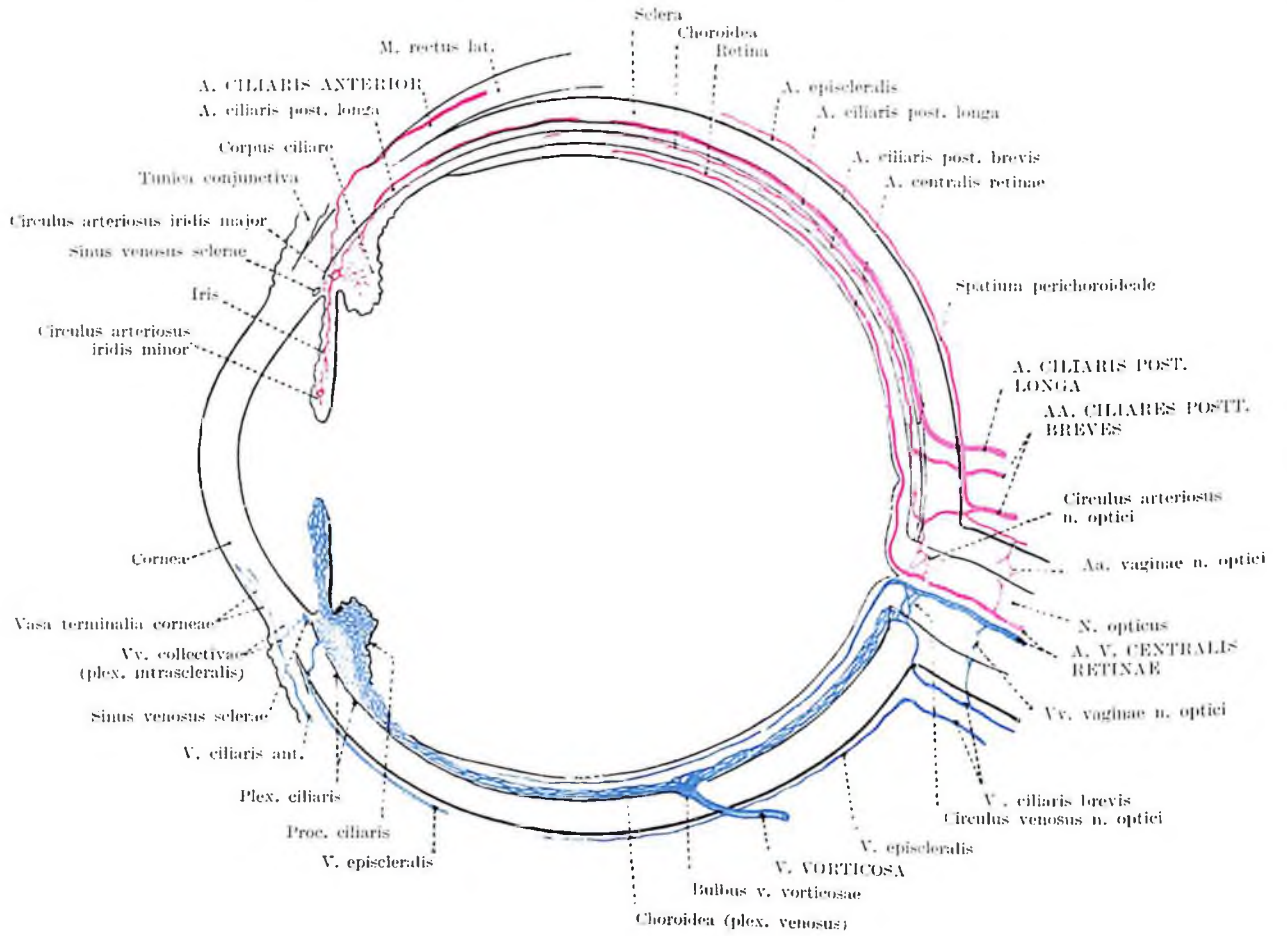


Fig. 221. ARTERIAE ET VENAE BULBI OCULI
(secundum F. Kiss et T. Orbán, sectio horizontalis)

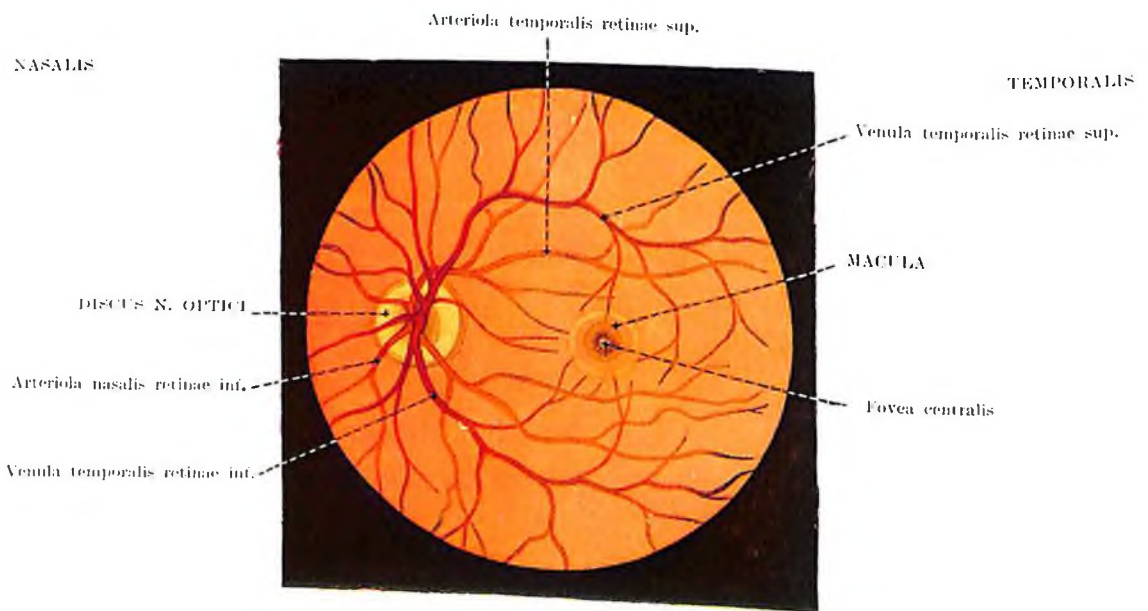
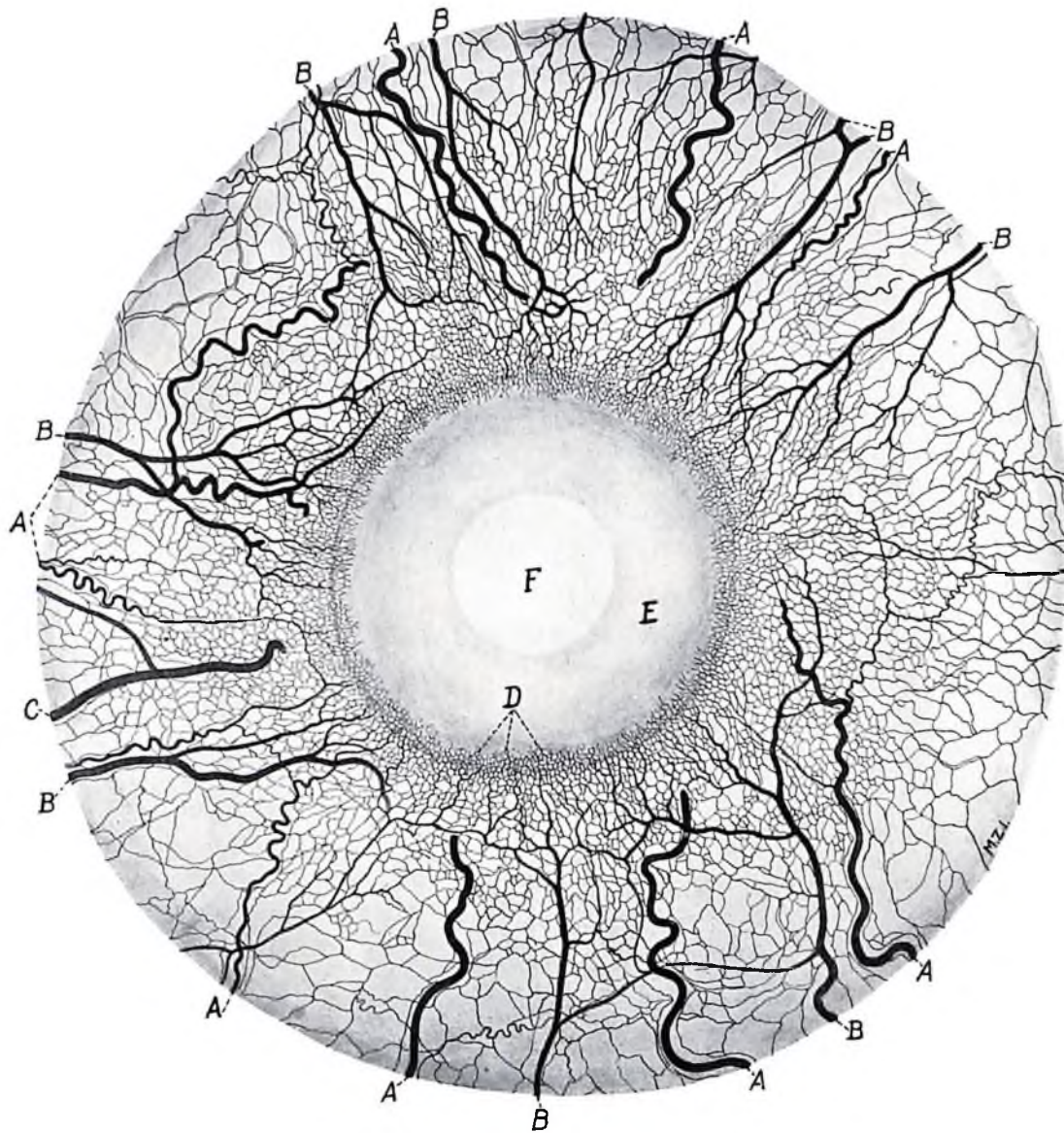


Fig. 222. ARTERIAE ET VENAE RETINAE
(fundus oculi, discus nervi optici et macula)



- A = aa. ciliares antt.
- B = vv. ciliares antt.
- C = v. emissaria bulbi
- D = vasa terminalia
- E = cornea
- F = pupilla

Fig. 223. PLEXUS VASCULOSUS EPISCLERALIS
(aspectus anterior partis anterioris bulbi)

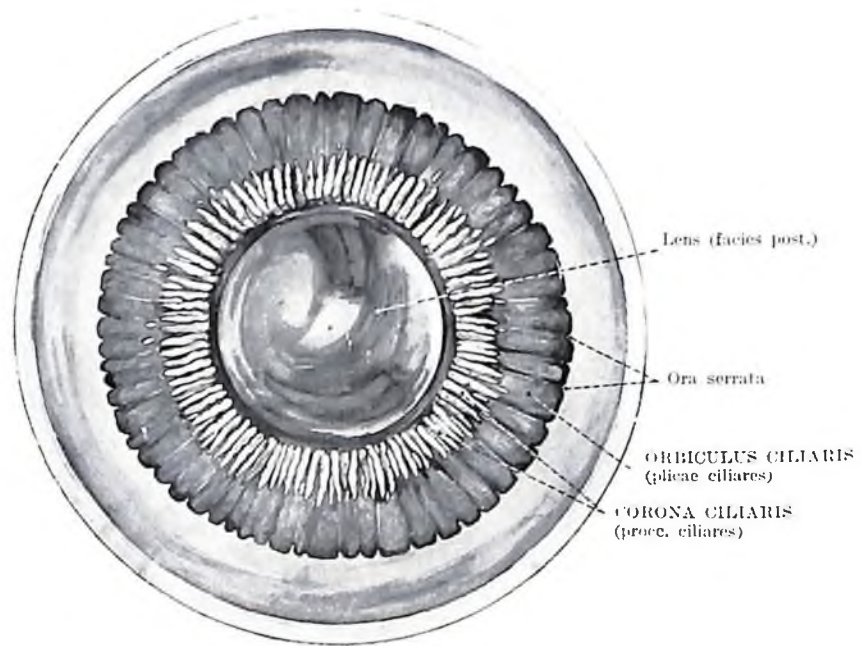


Fig. 224. CORPUS CILIARE
(aspectus posterior partis anterioris bulbi)

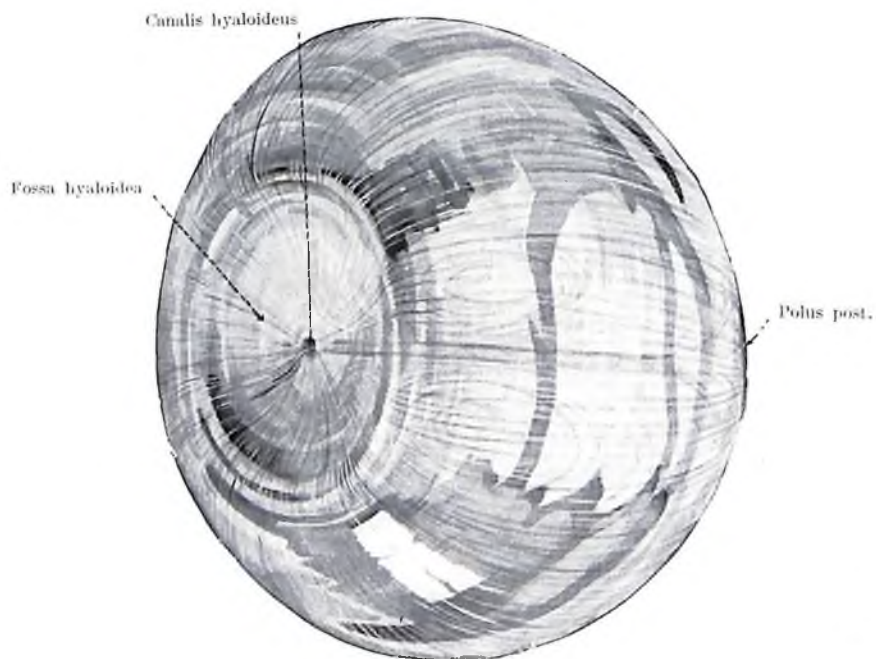
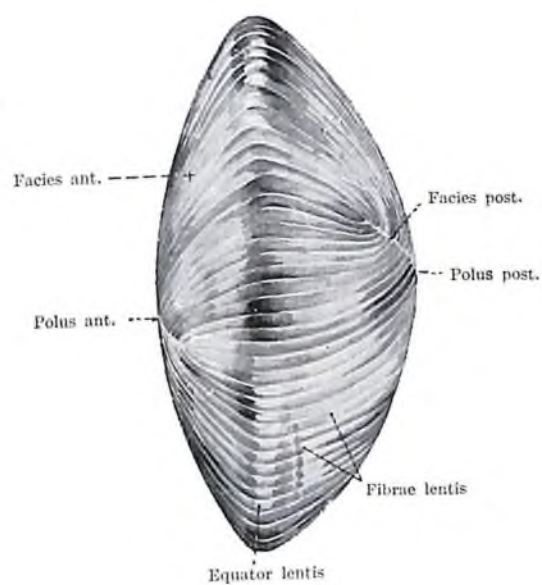


Fig. 225. CORPUS VITREUM



5/1

Fig. 226. LENS I.
(aspectus lateralis)

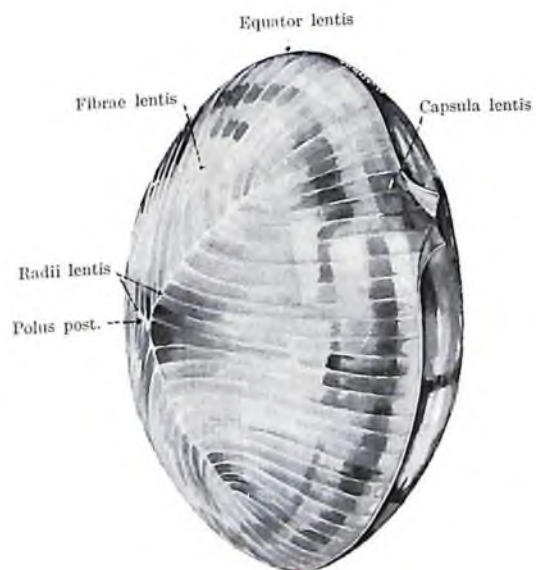
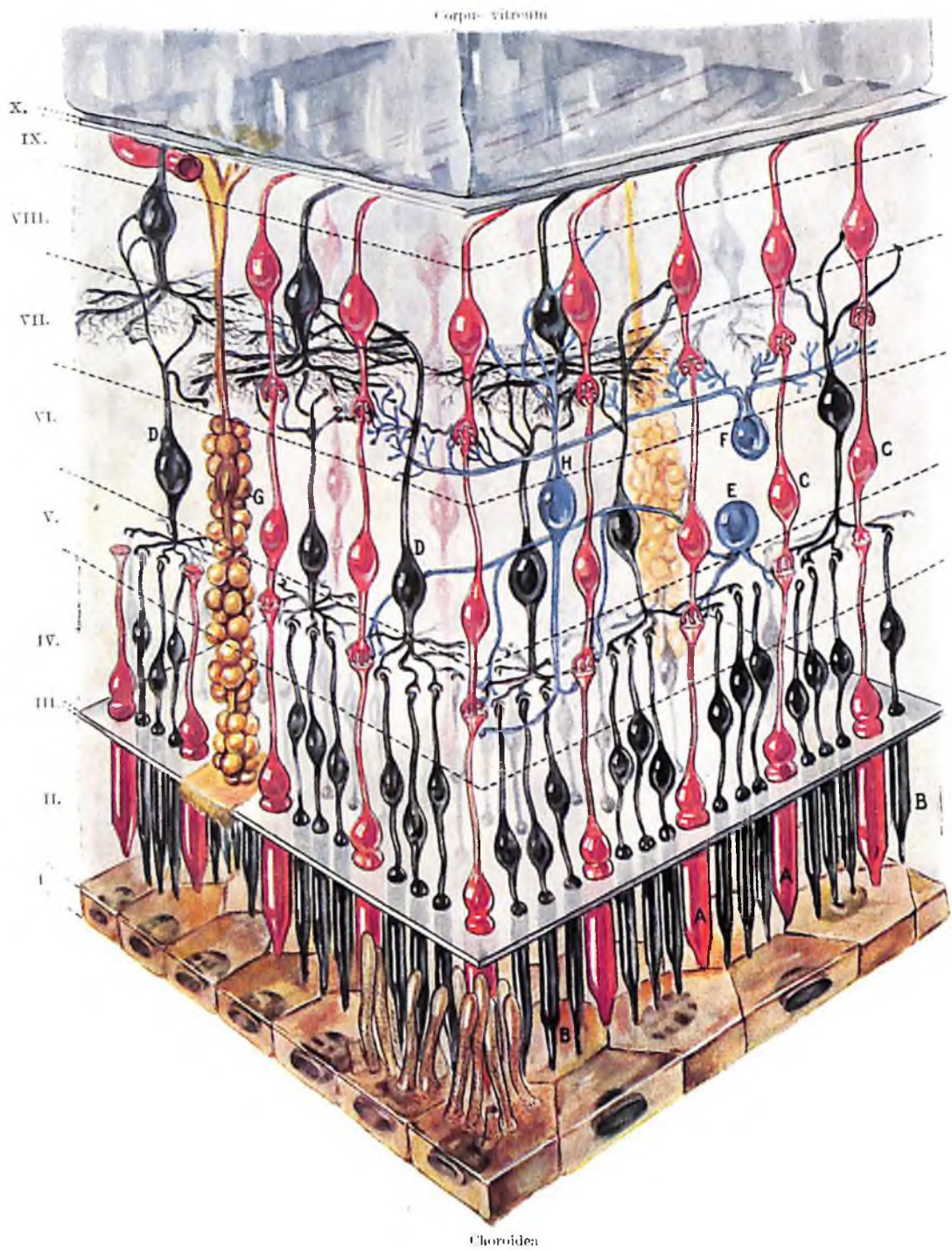


Fig. 227. LENS II.
(aspectus postero-lateralis)



- I. stratum pigmenti retinae
 II. coni et bacilli
 III. membrana limitans externa
 IV. stratum granulosum externum (stratum neuroepitheliale)
 V. stratum plexiforme externum
 VI. stratum granulosum internum (stratum ganglionare retinae)
 VII. stratum plexiforme internum
 VIII. stratum ganglionare (stratum ganglionare nervi optici)
 IX. stratum fibrarum nervearum
 X. membrana limitans interna

- A. coni
 B. bacilli
 C. neuron intercalare pro conibus
 D. neuron intercalare pro bacillis
 E. neuron associationis
 F. cellula unipolaris
 G. cellula Mulleri
 H. cellula associationis

Fig. 228. RETINA
 (structura partis opticae retinae)

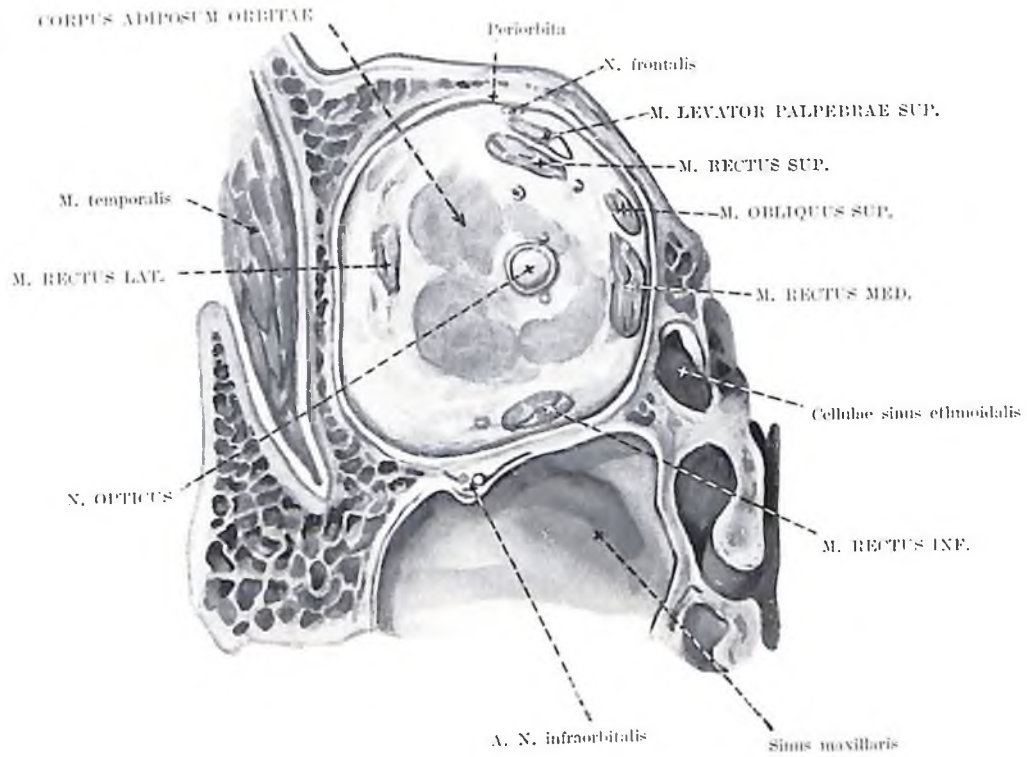


Fig. 229. ORGANA OCULI ACCESSORIA
(sectio frontalis retrobulbaris orbitae)

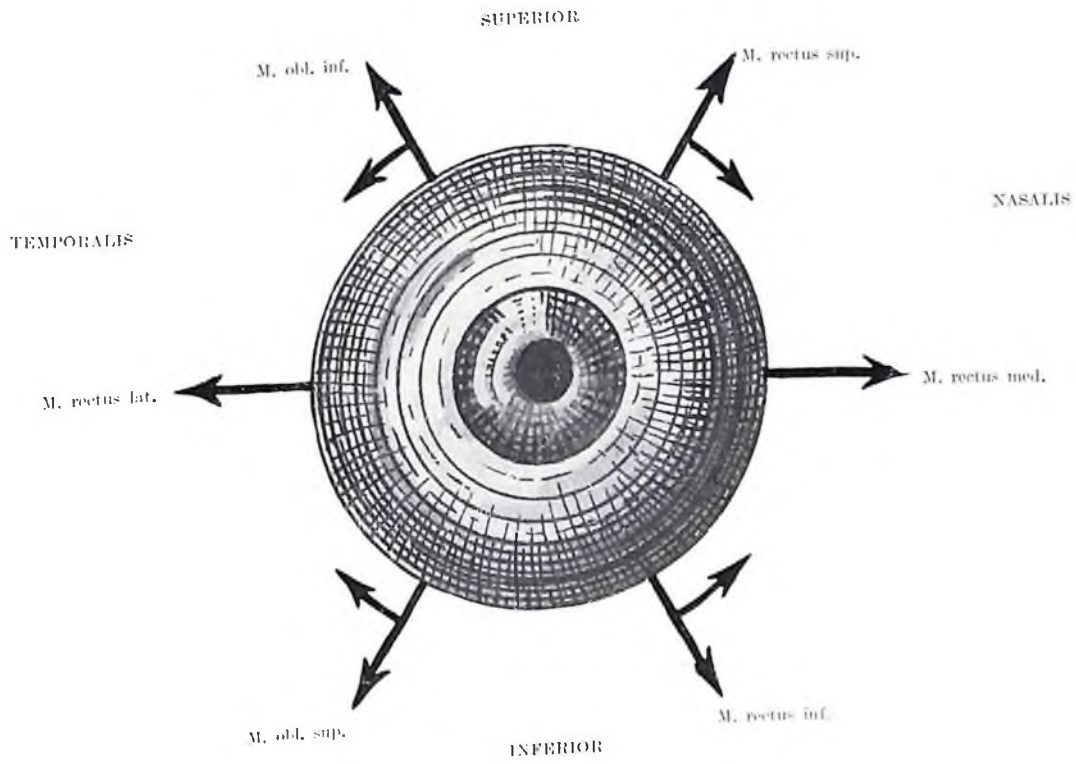


Fig. 230. ACTIO MUSCULORUM BULBI
(bulbus dexter, aspectus anterior)

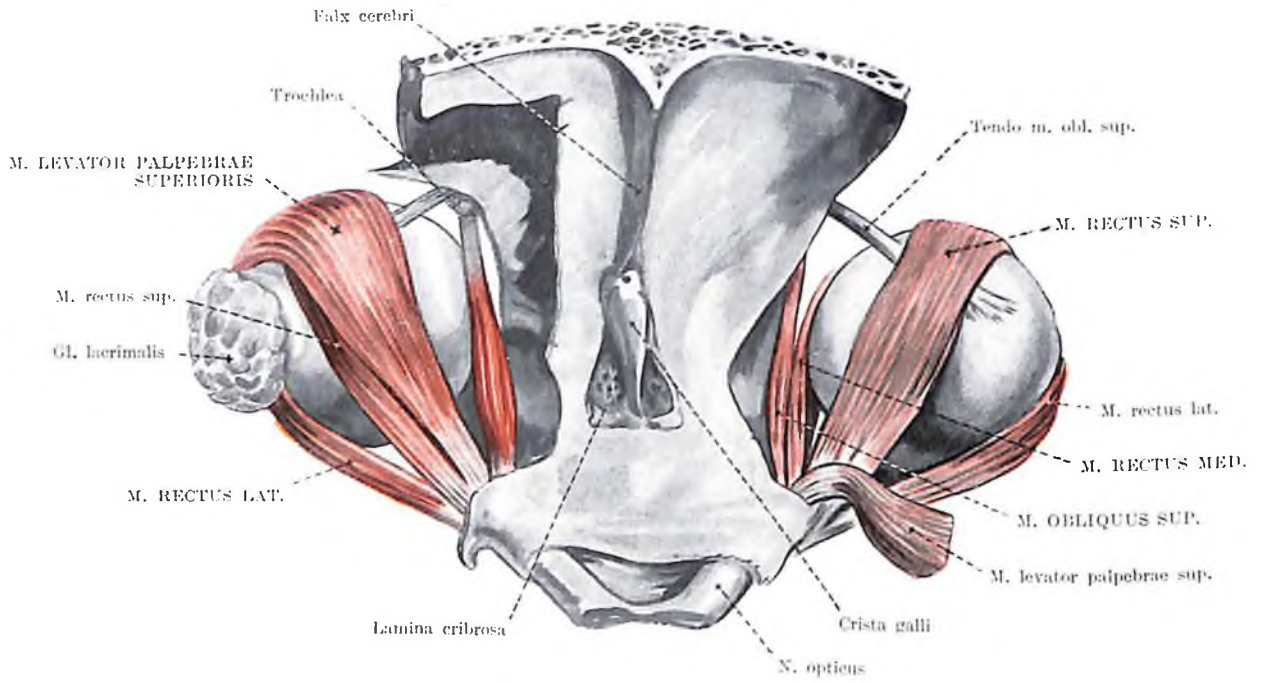


Fig. 231. MUSCULI BULBI I.
(aspectus superior)

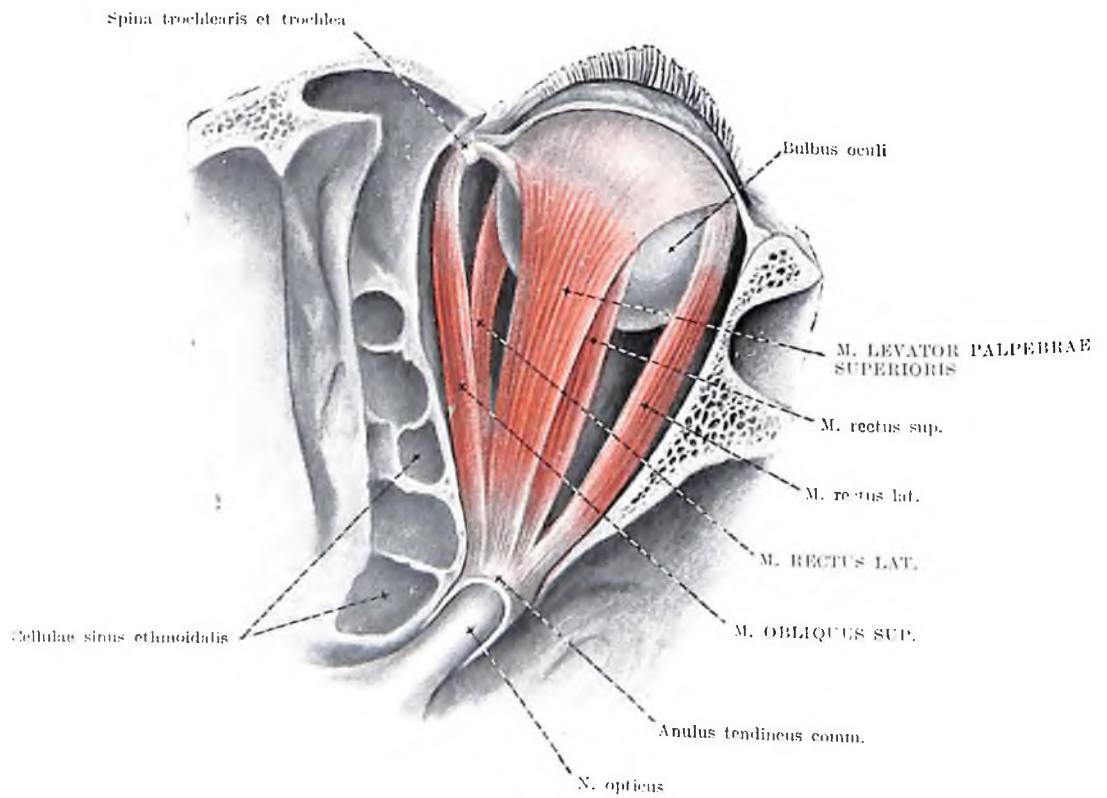


Fig. 232. MUSCULI BULBI II.
(aspectus superior, l. dext.)

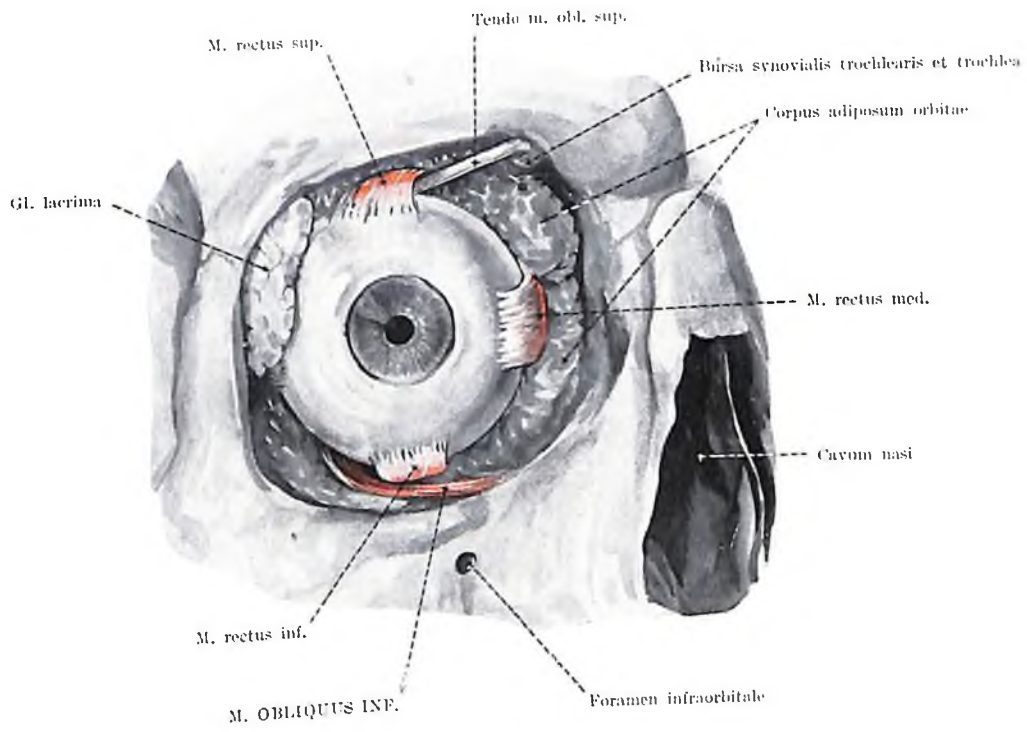


Fig. 233. MUSCULI BULBI III.
(aspectus anterior, 1. dext.)

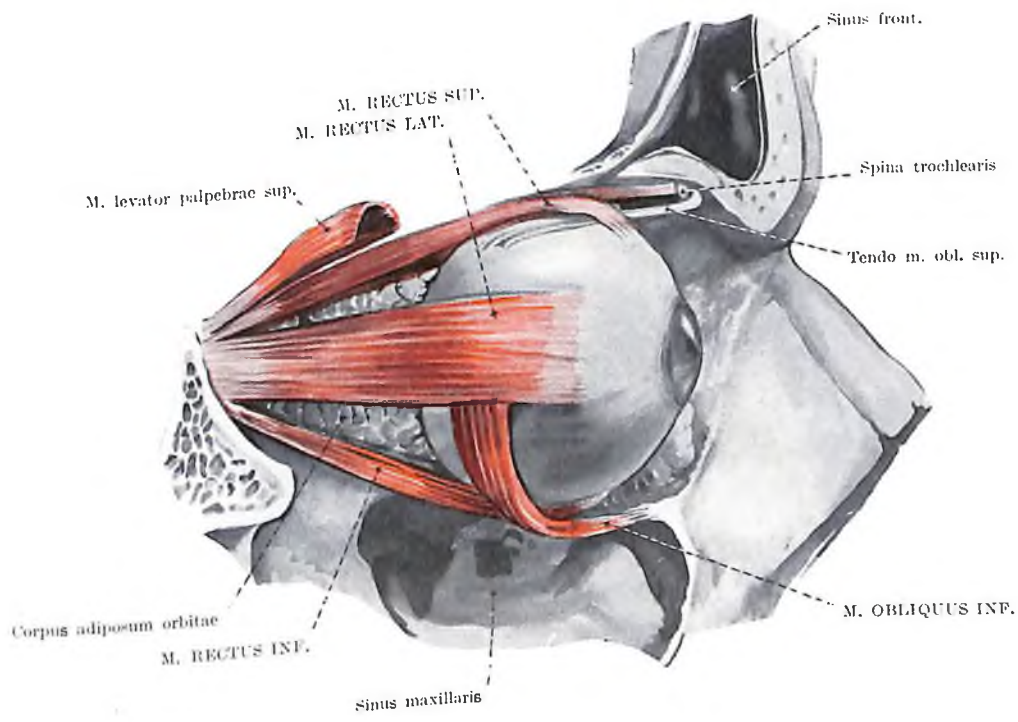


Fig. 234. MUSCULI BULBI IV.
(aspectus lateralis, 1. dext.)

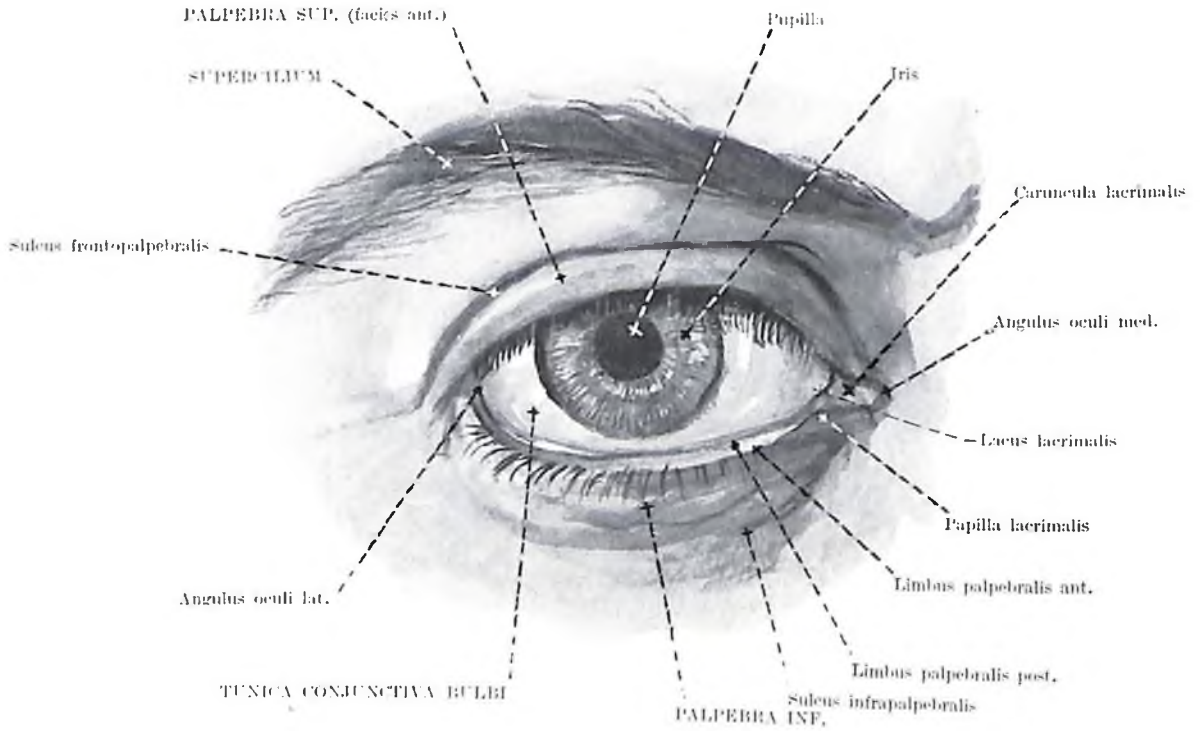


Fig. 235. PALPEBRAE I.
(palpebrae et supercilium, I. dext.)

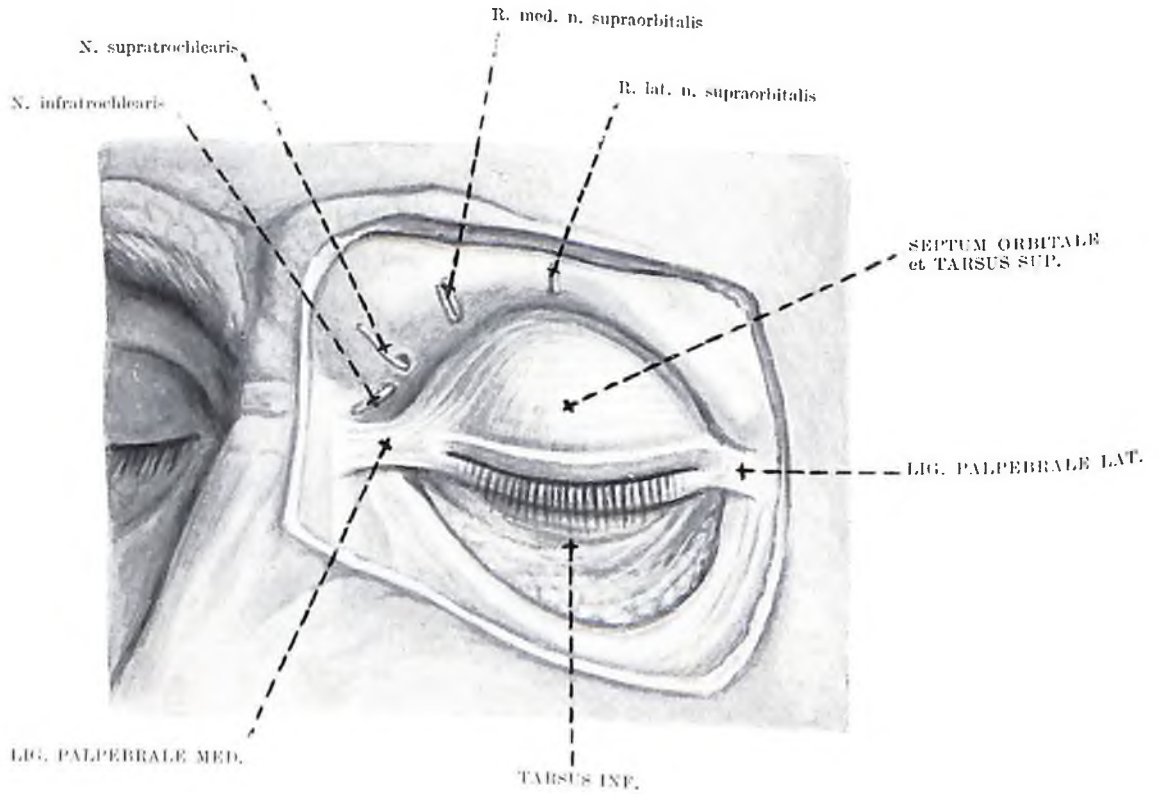


Fig. 236. PALPEBRAE II.
(structura palpebrarum, I. sin.)

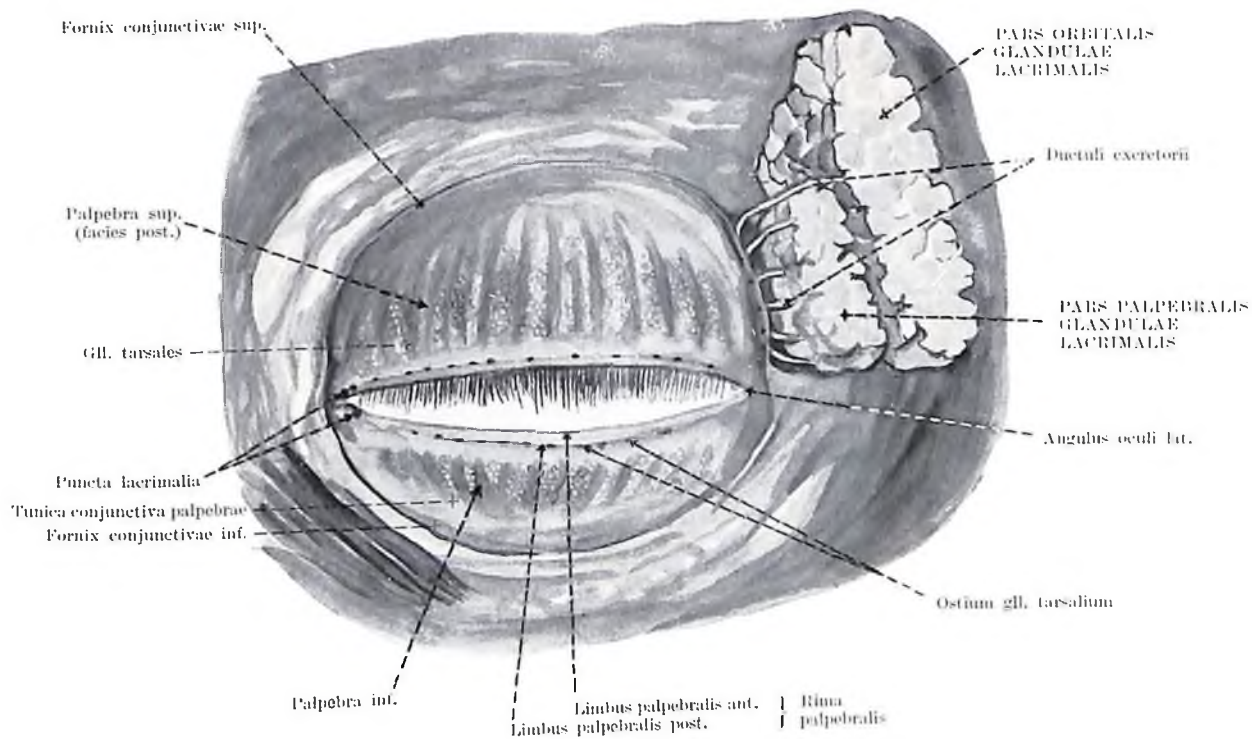


Fig. 237. APPARATUS LACRIMALIS I.
(facies posterior palpebrarum et glandula lacrimalis, l. dext.)

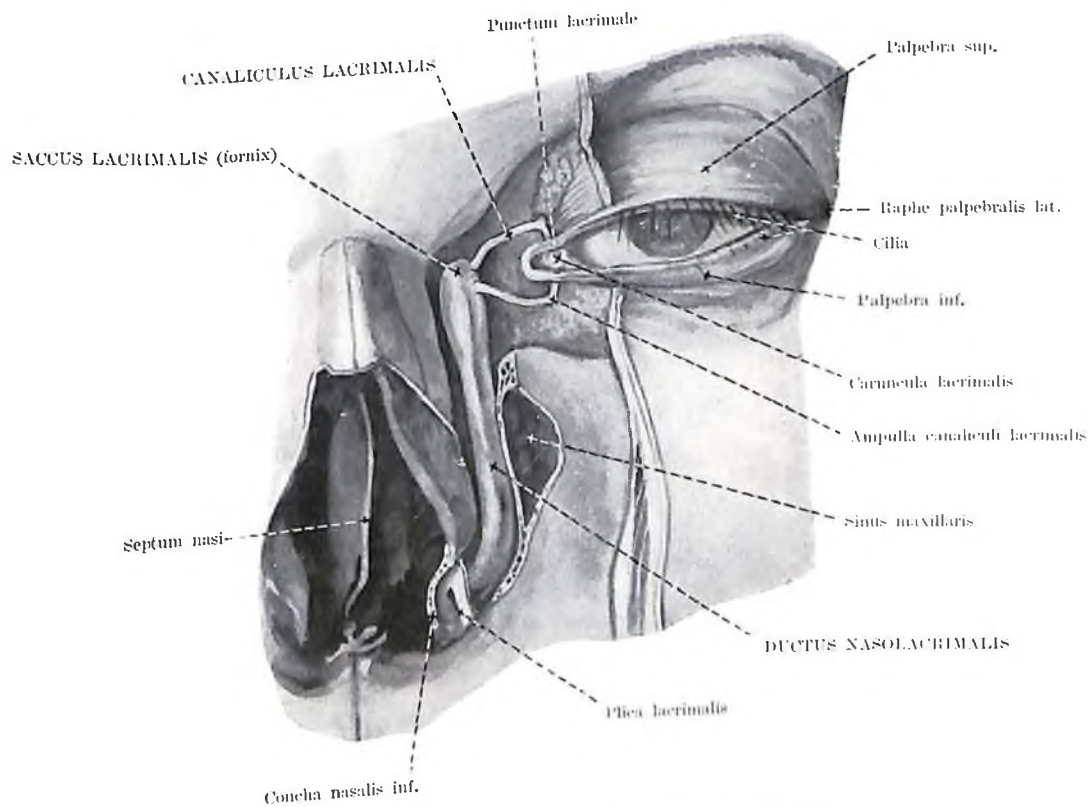


Fig. 238. APPARATUS LACRIMALIS II.
(saccus lacrimalis, l. sin.)

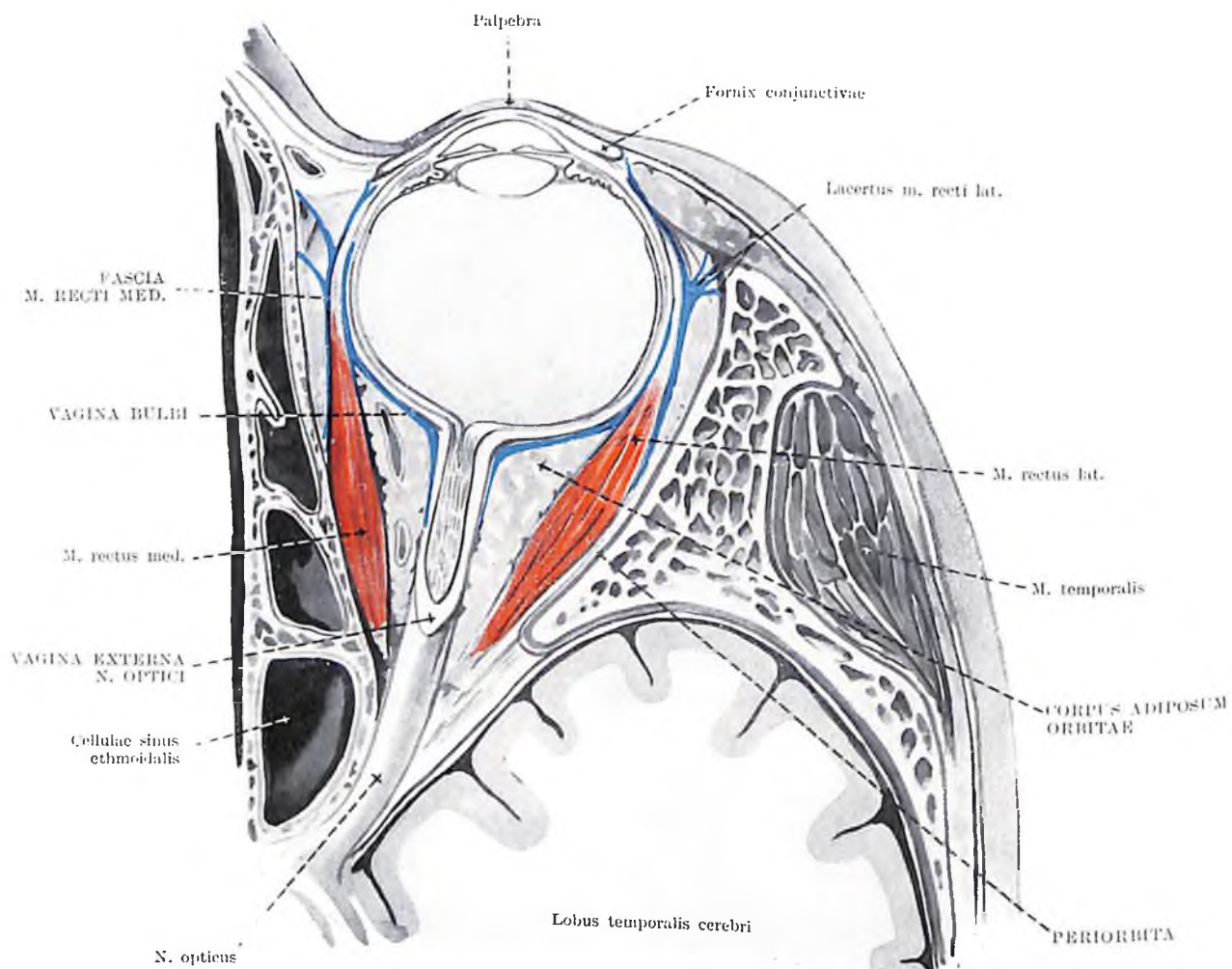


Fig. 239. TOPOGRAPHIA ORBITAE
(vaginae bulbi, sectio horizontalis)

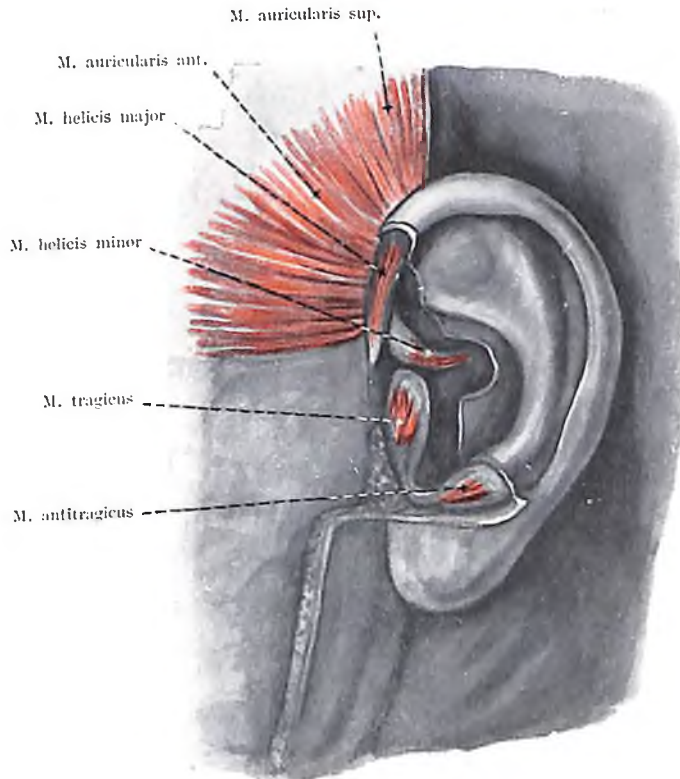


Fig. 240. AURICULA I.
(musculi auriculæ, aspectus lateralis)

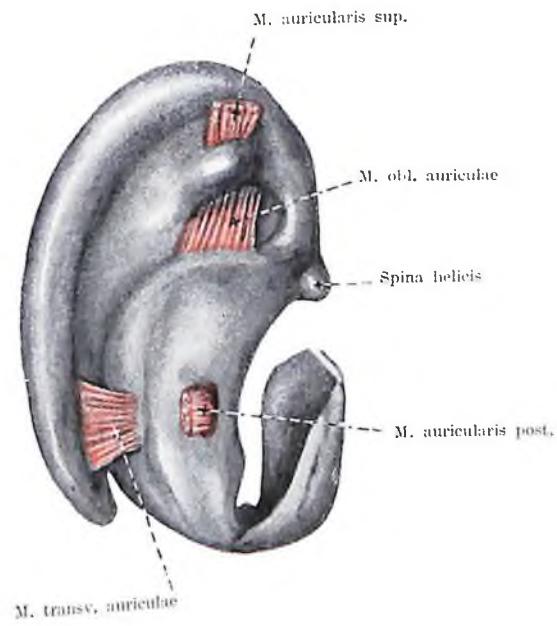


Fig. 241. AURICULA II.
(musculi auriculæ, aspectus medialis)

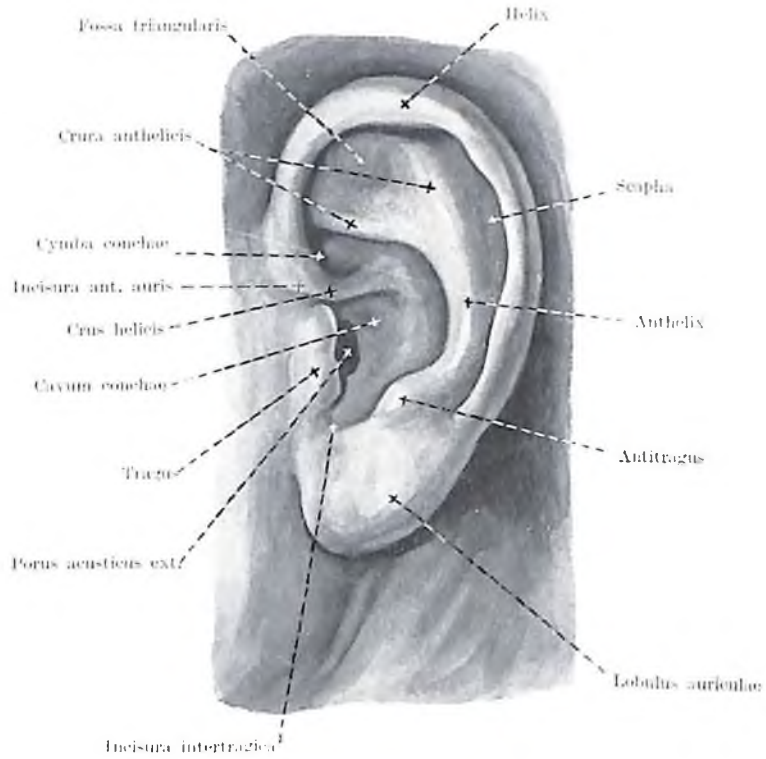


Fig. 242. AURICULA III.
(aspectus lateralis)

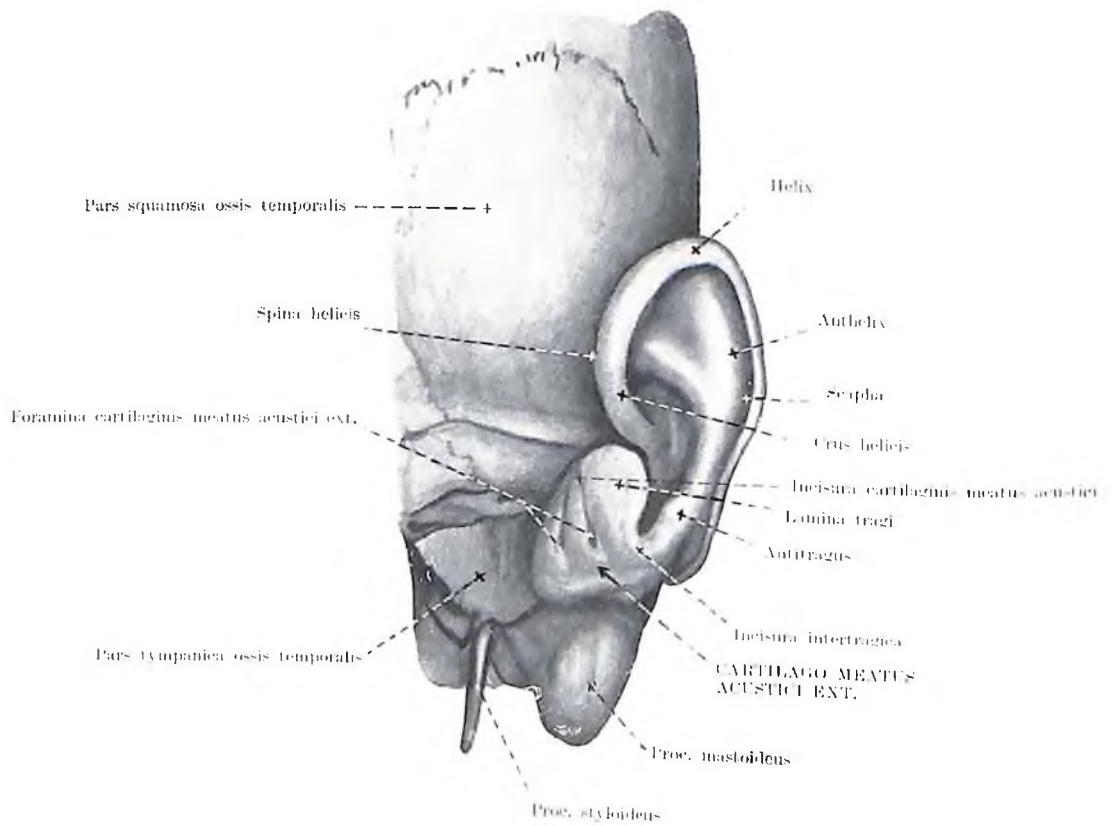


Fig. 243. AURICULA IV.
(cartilago auriculæ et meatus acustici externi, aspectus anterior, l. sin.)

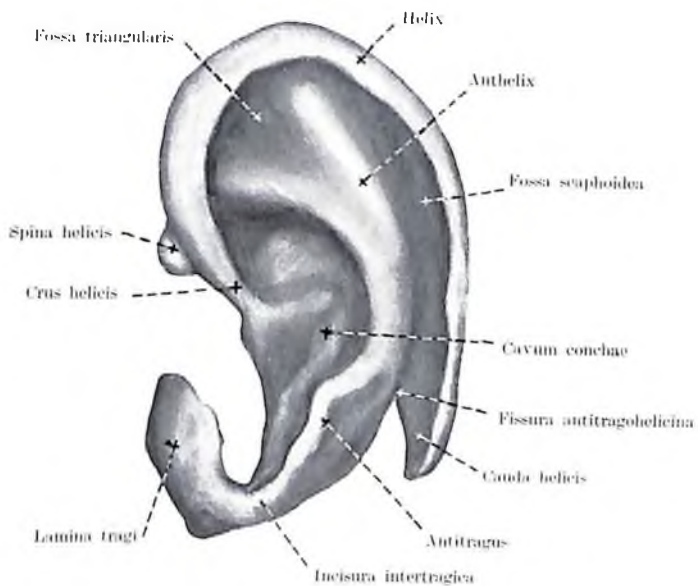


Fig. 244. AURICULA V.
(cartilago auriculæ, aspectus lateralis, l. sin.)

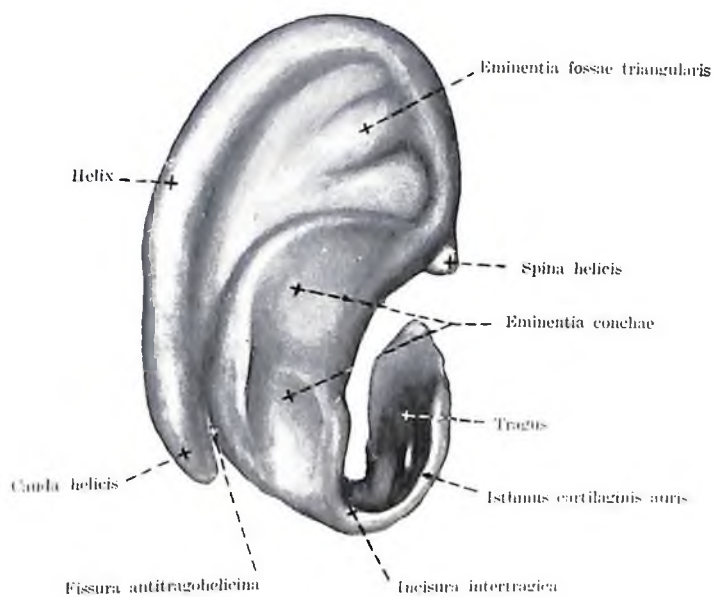


Fig. 245. AURICULA VI.
(cartilago auriculæ, aspectus medialis, l. sin.)

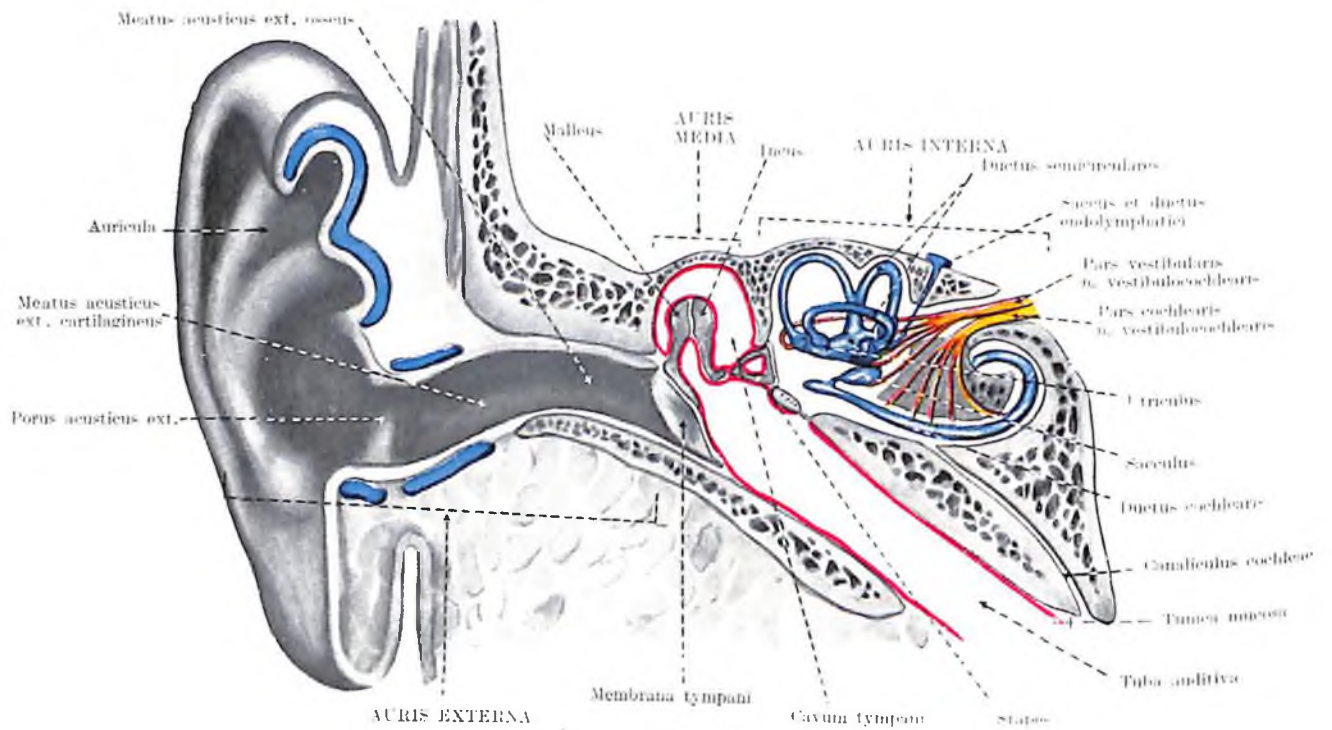


Fig. 246. ORGANUM VESTIBULOCOCHLEARE I.
(sectio frontalis, I. dext.)

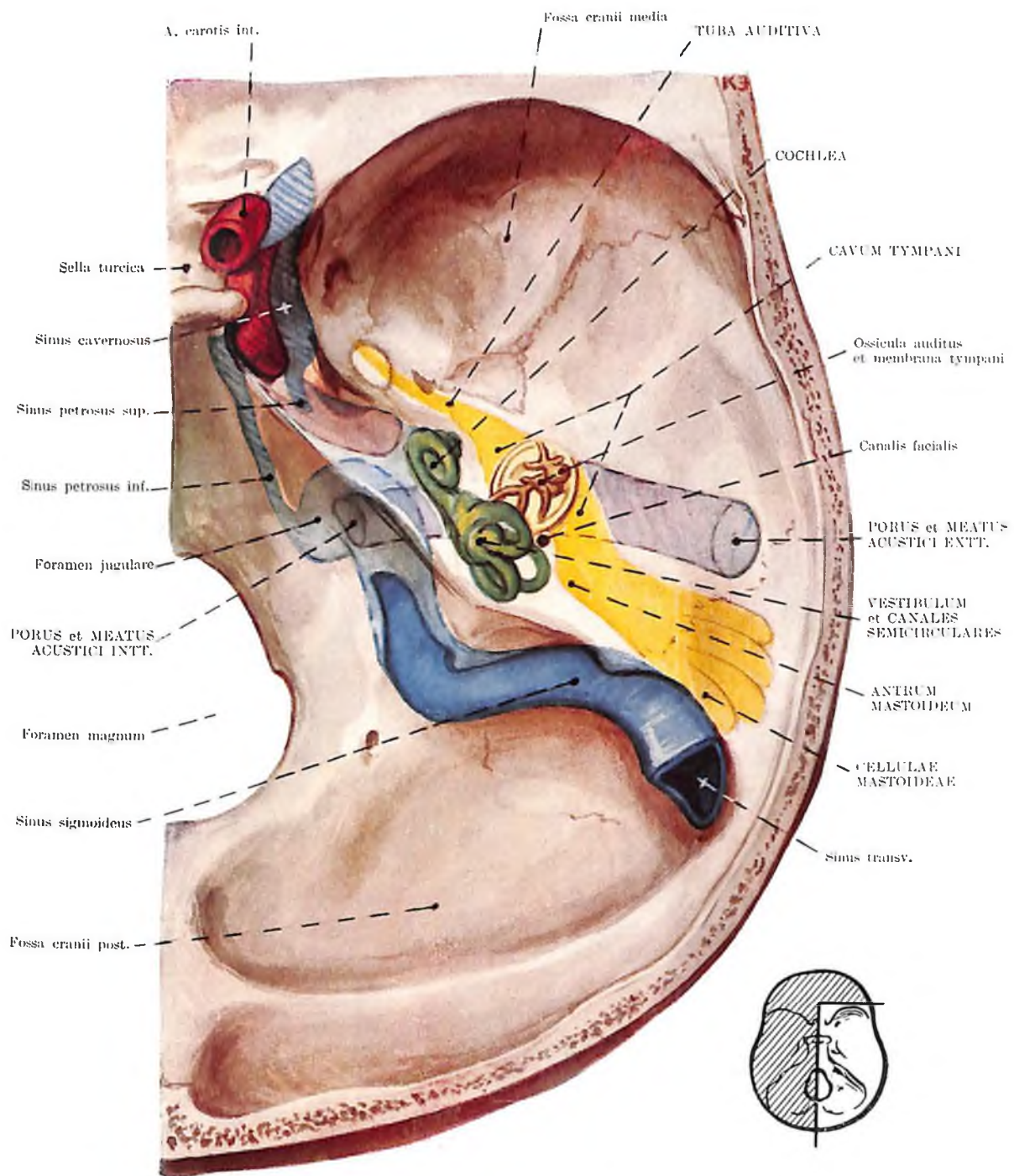


Fig. 247. ORGANUM VESTIBULOCOCHLEARE II.
(situs partium organi projectus, aspectus superior)

Stria membranae tympani post.

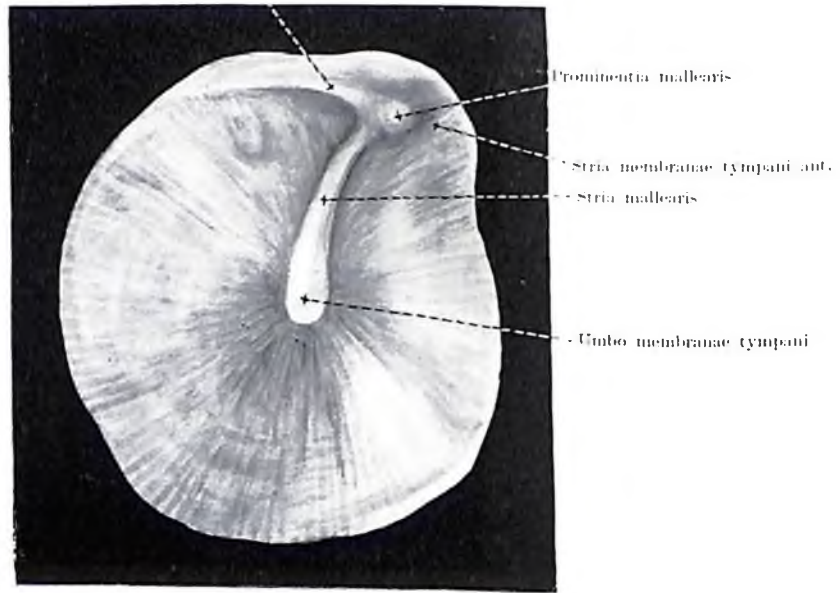


Fig. 248. MEMBRANA TYMPANI I.
(aspectus lateralis, 1. dext.)

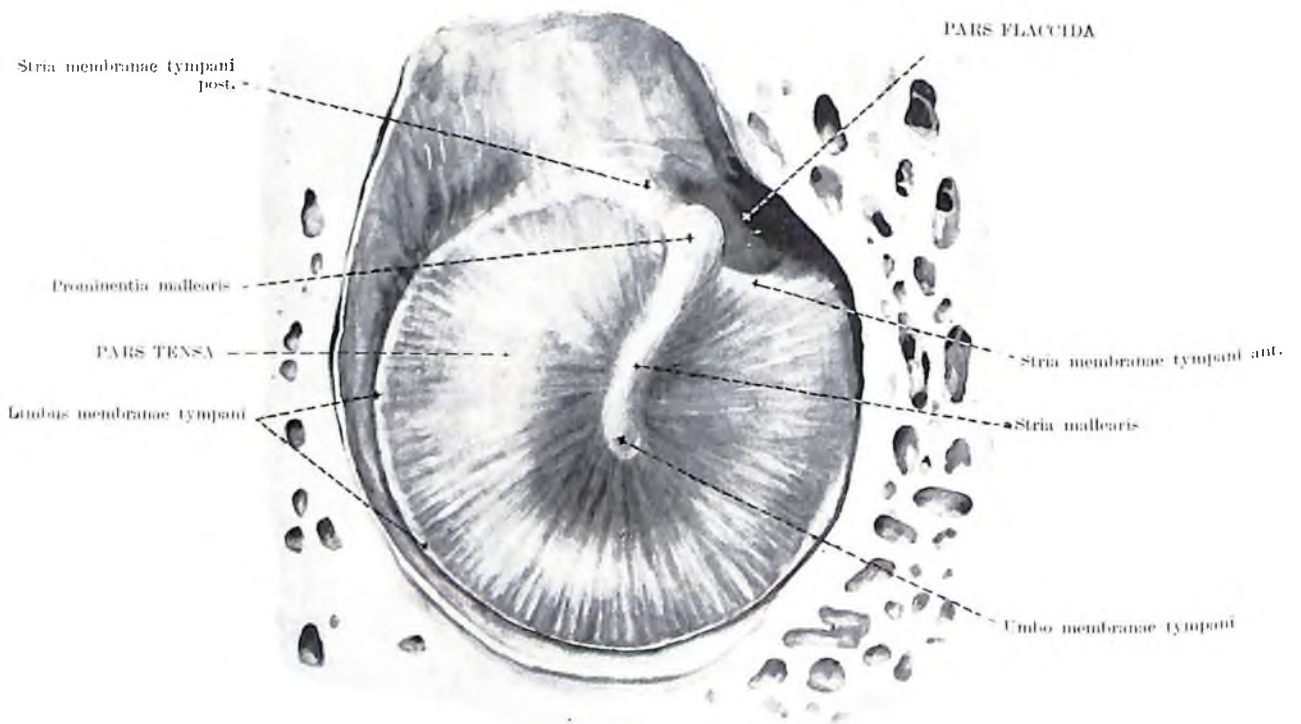
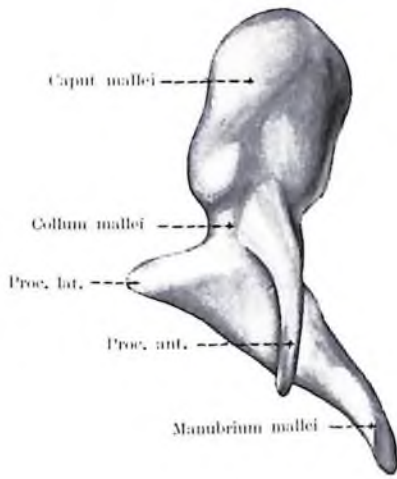
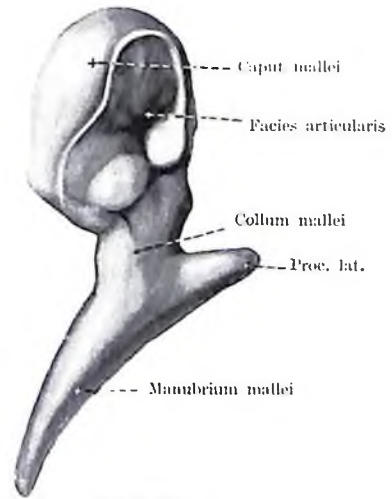


Fig. 249. MEMBRANA TYMPANI II.
(aspectus lateralis, in situ)

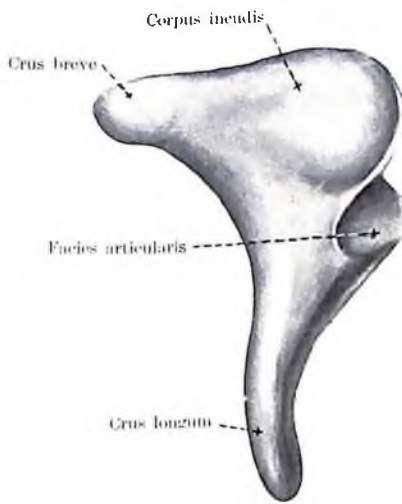


MALLEUS
(aspectus anterior)

7/1

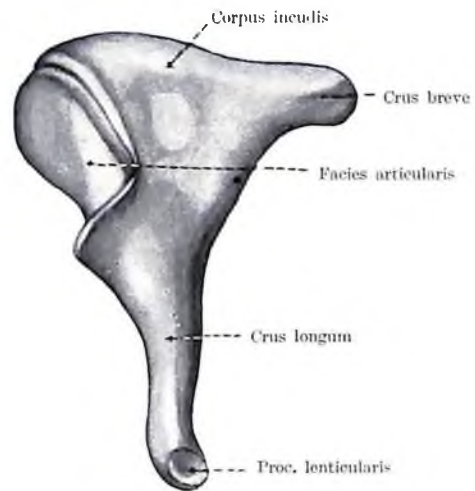


MALLEUS
(aspectus posterior)

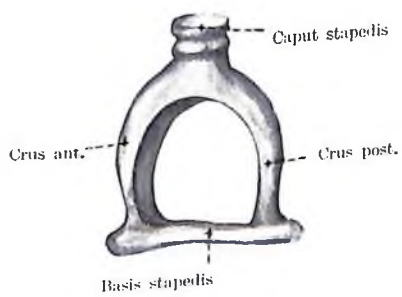


INCUS
(aspectus inferior)

8/1

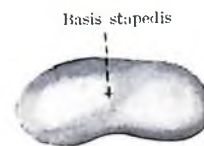


INCUS
(aspectus superior)



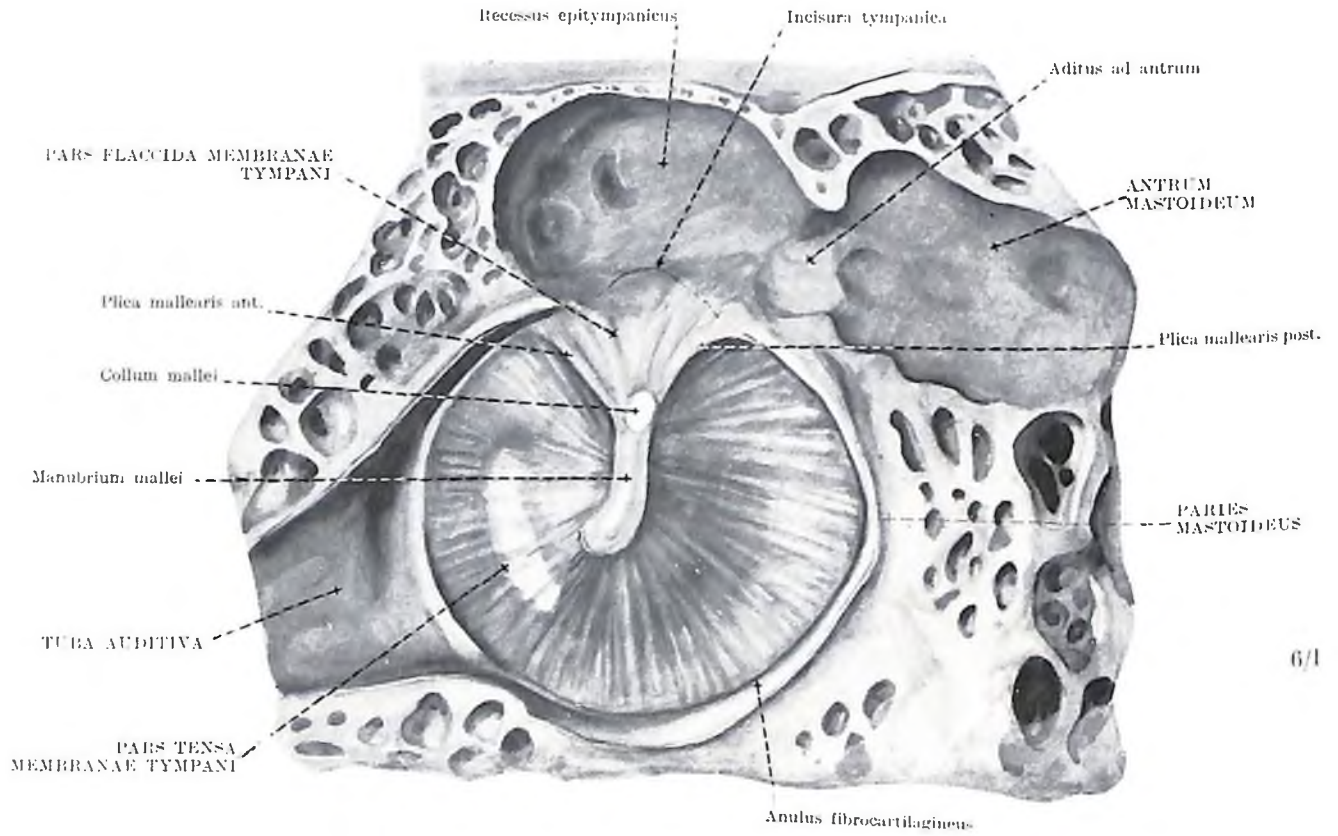
STAPES
(aspectus superior)

9/1



STAPES
(aspectus labyrinthicus)

Fig. 250. OSSICULA AUDITUS
(auris mediae dextrae)



6/1

Fig. 251. CAVUM TYMPANI I.
(paries membranaceus, I. dext.)

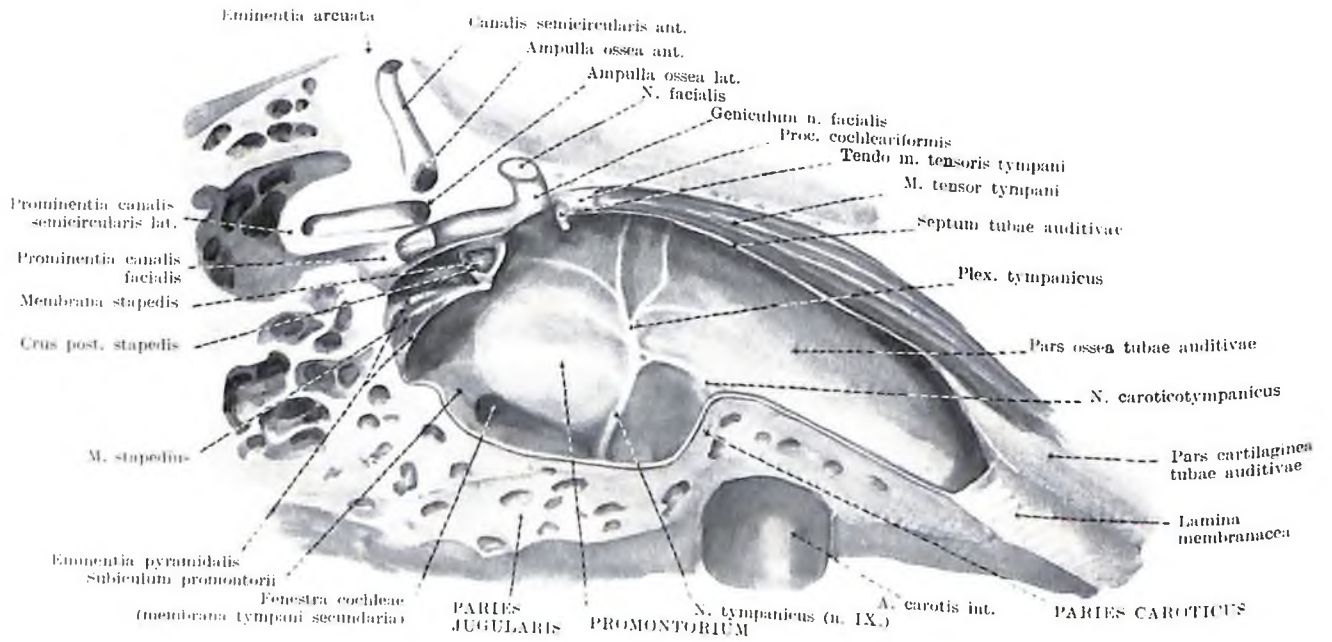


Fig. 252. CAVUM TYMPANI II.
(paries labyrinthicus, I. dext.)

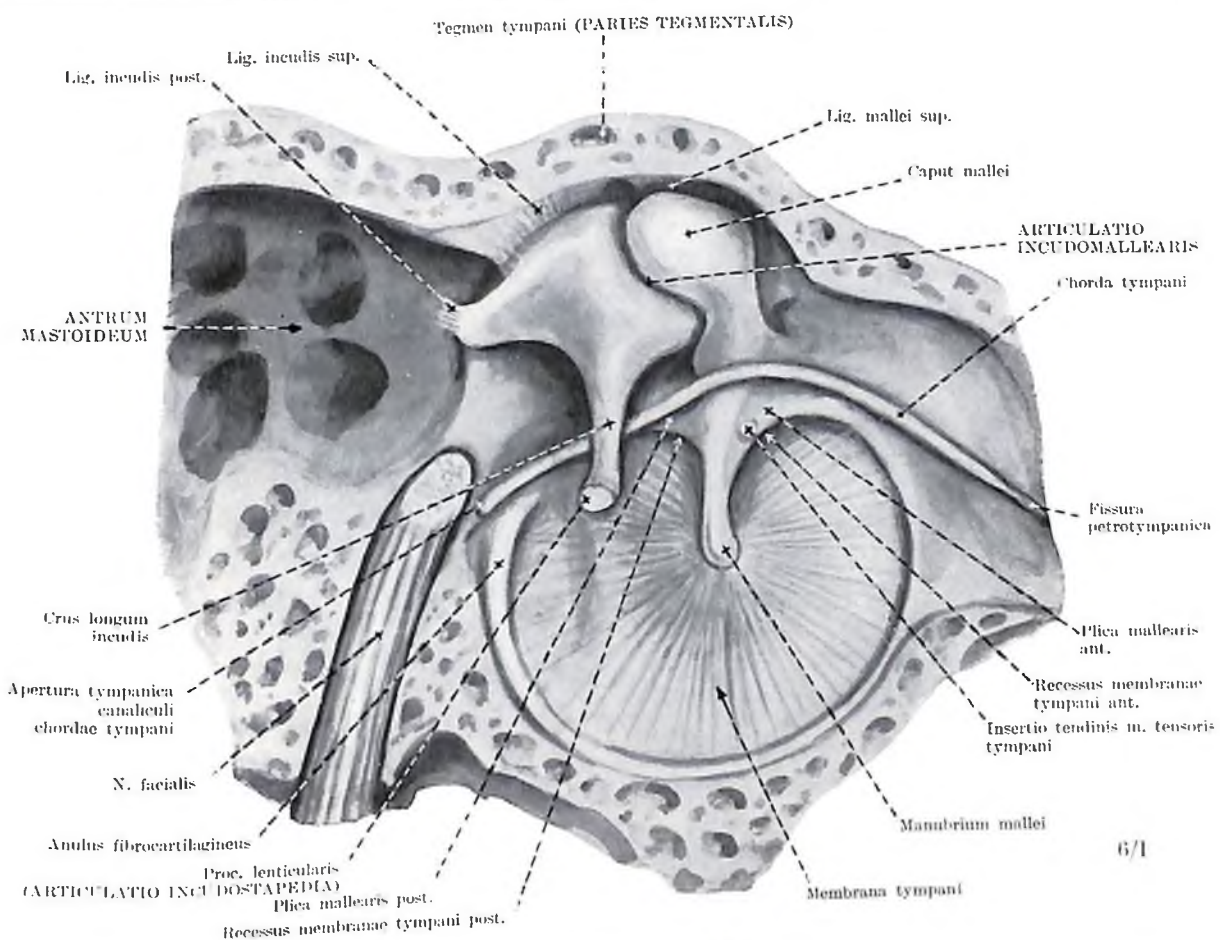


Fig. 253. CAVUM TYMPANI III.

(ossicula auditus in situ, articulationes et ligamenta ossiculorum, aspectus medialis, l. sin.)

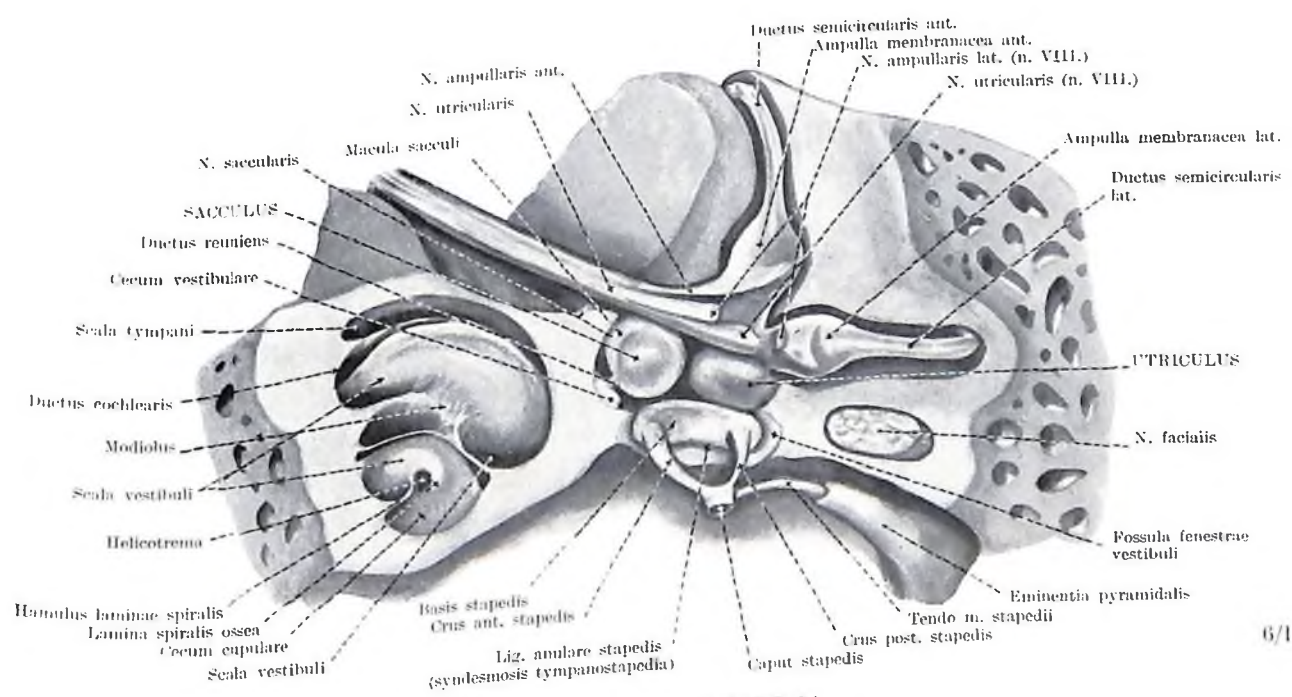
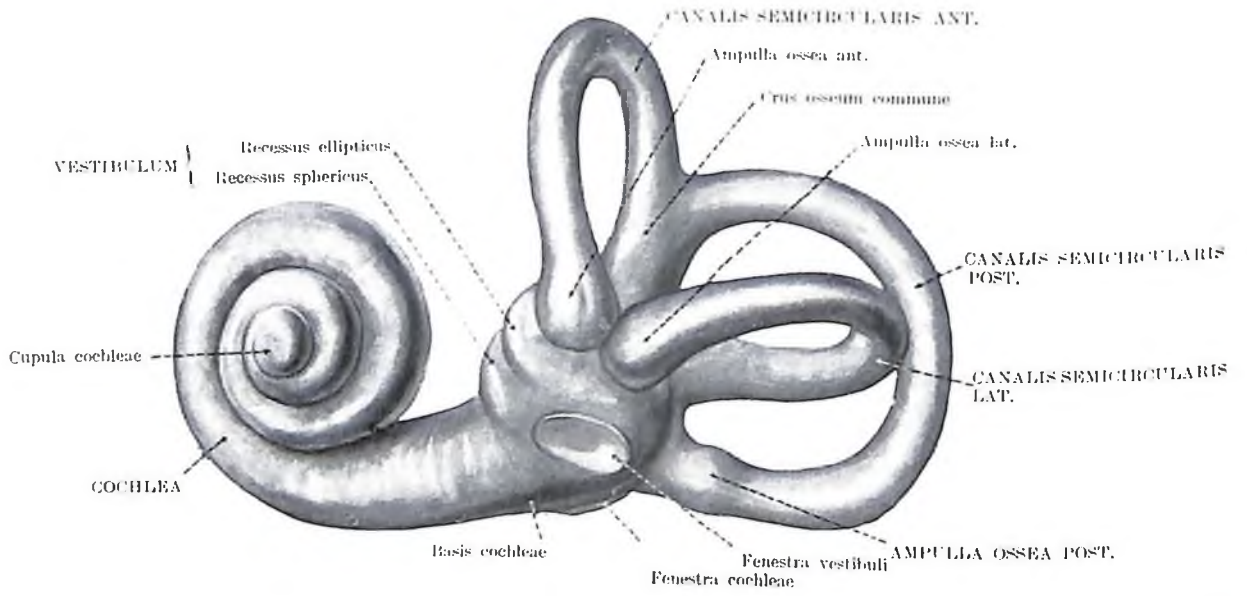


Fig. 254. AURIS INTERNA

(sectio obliqua, aspectus supero-lateralis, l. sin.)



6/1

Fig. 255. LABYRINTHUS OSSEUS I.
(preparatum corrosum, aspectus lateralis, l. sin.)

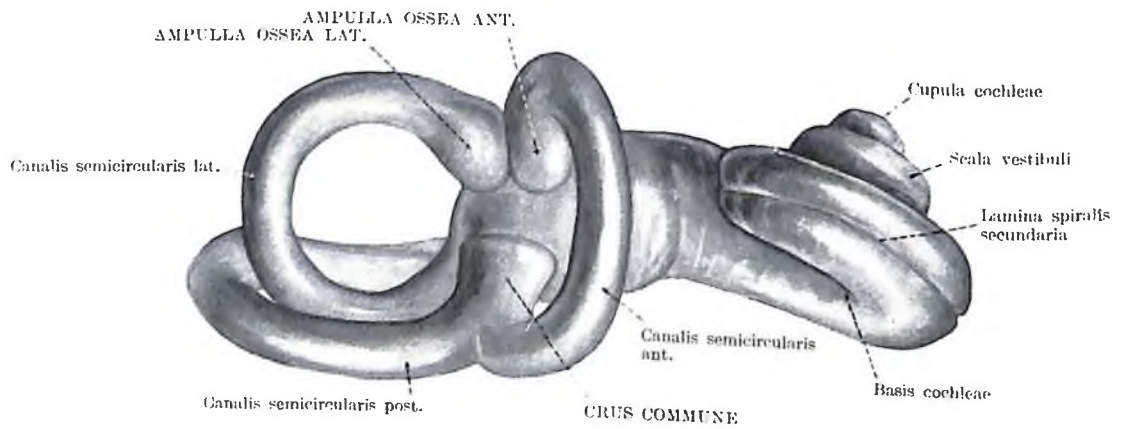


Fig. 256. LABYRINTHUS OSSEUS II.
(preparatum corrosum, aspectus superior, l. sin.)

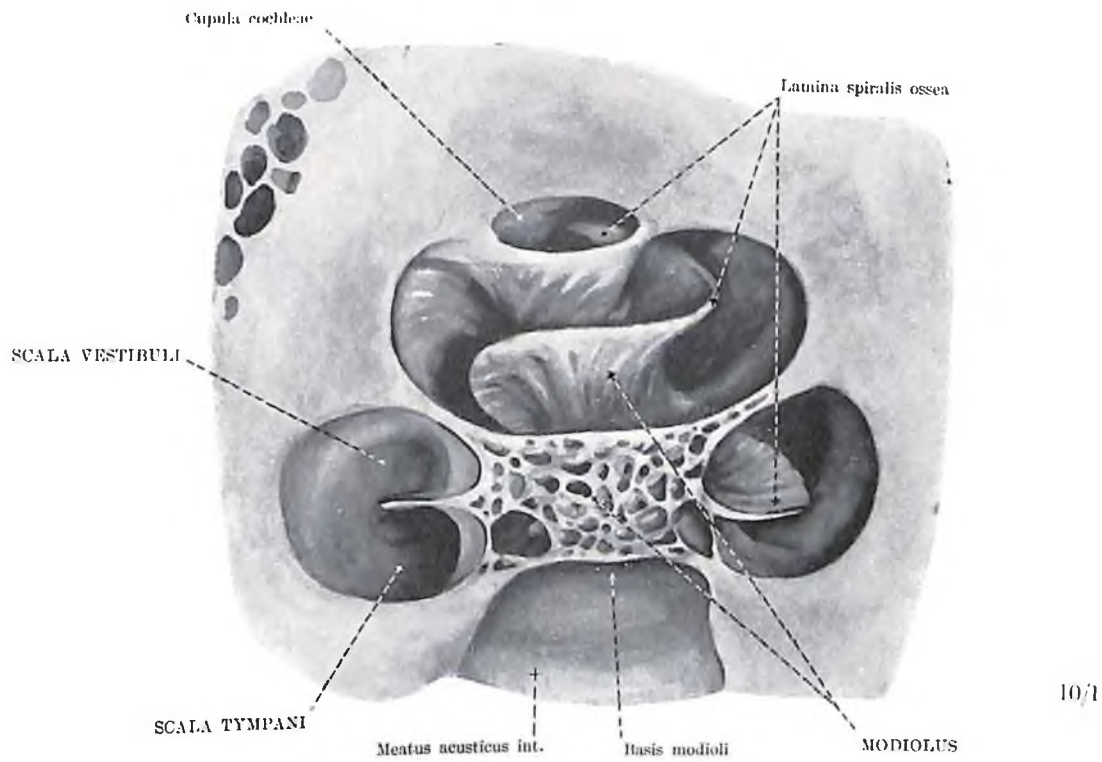


Fig. 257. COCHLEA
(sectio longitudinalis)

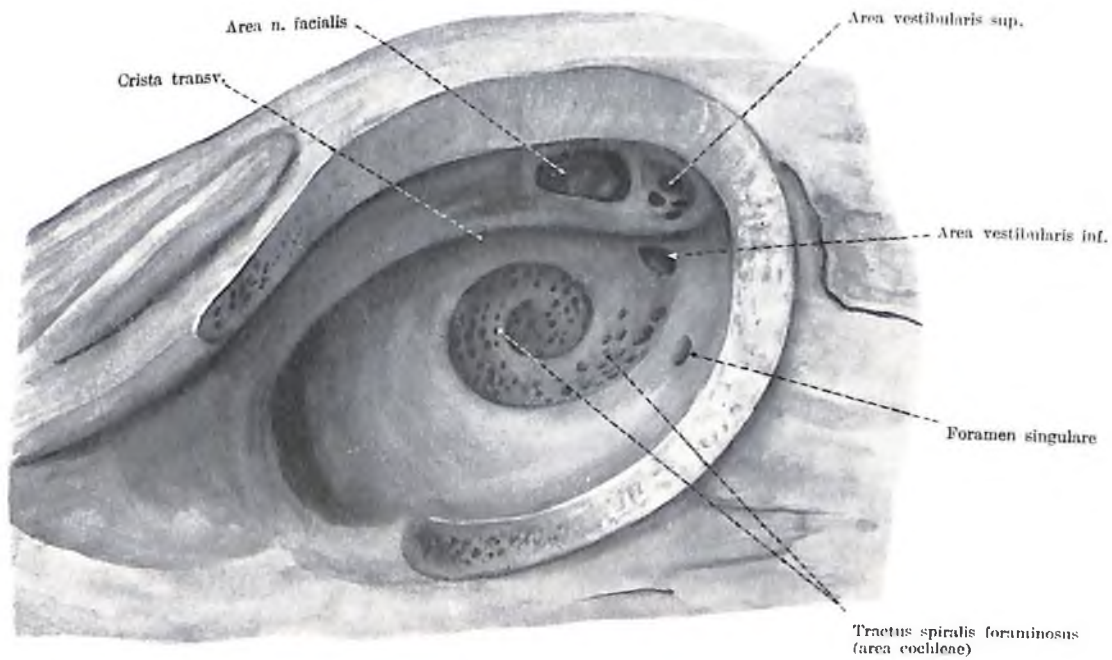


Fig. 258. FUNDUS MEATUS ACUSTICI INTERNI
(aspectus medialis, l. dext.)

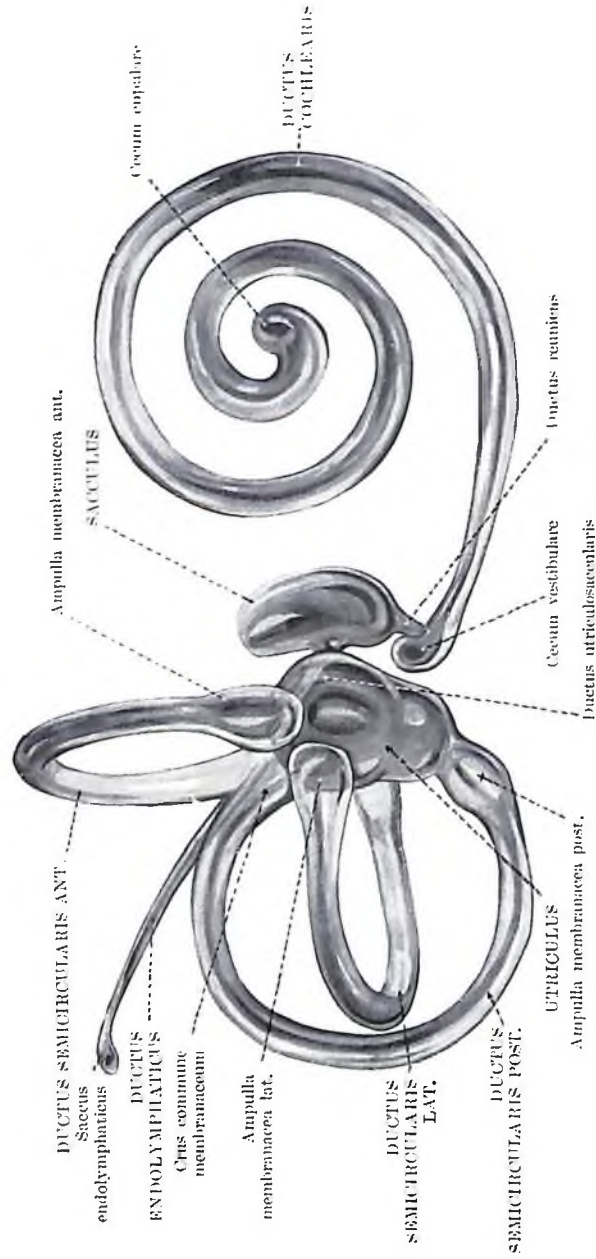


Fig. 259. LABYRINTHUS MEMBRANACEUS I.
 aspectus lateralis, 1. (dext.)

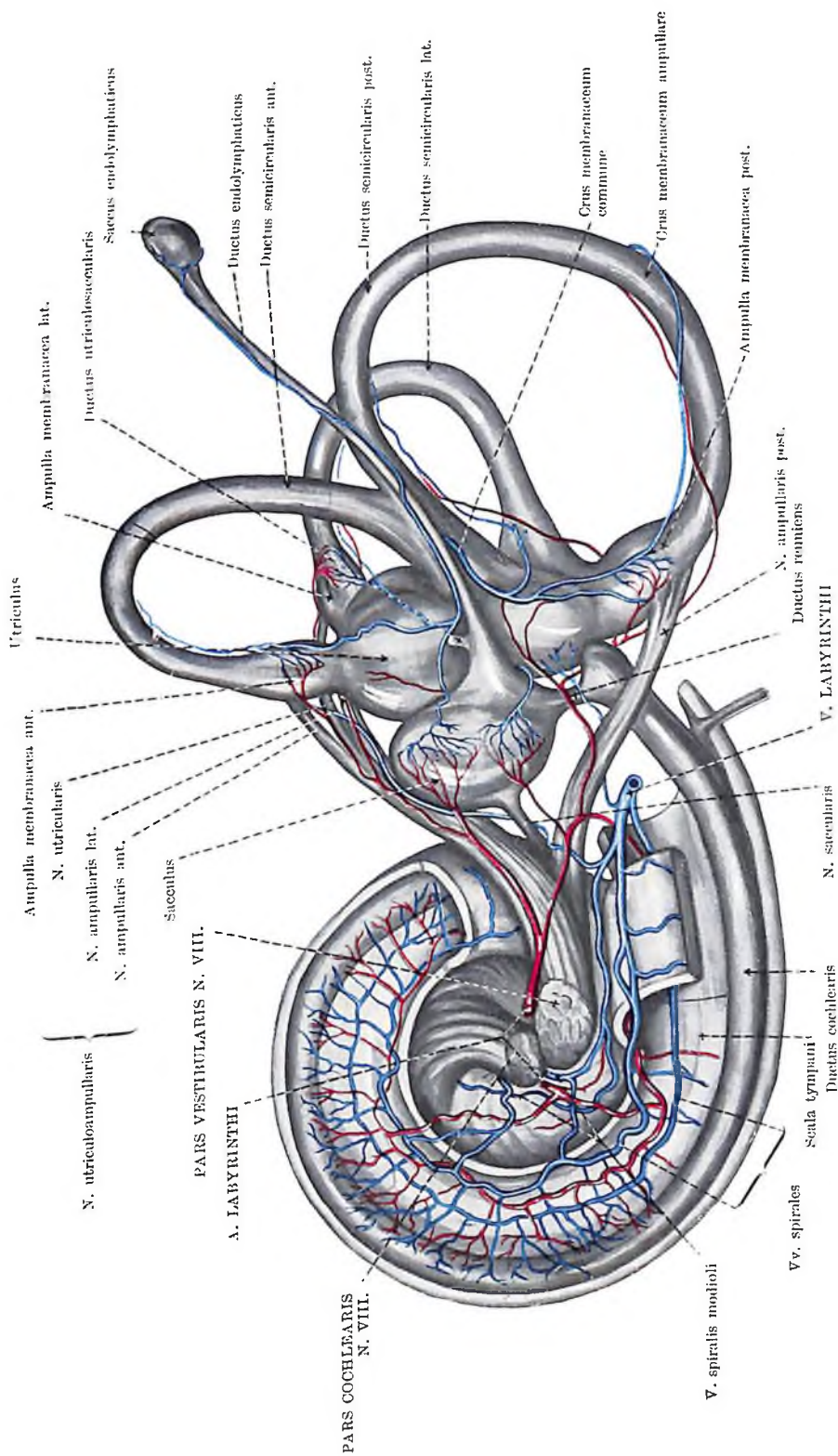


Fig. 260. LABYRINTHUS MEMBRANACEUS II.
(arteriæ, venæ et nervi auris internæ, aspectus medialis, l. dext.)

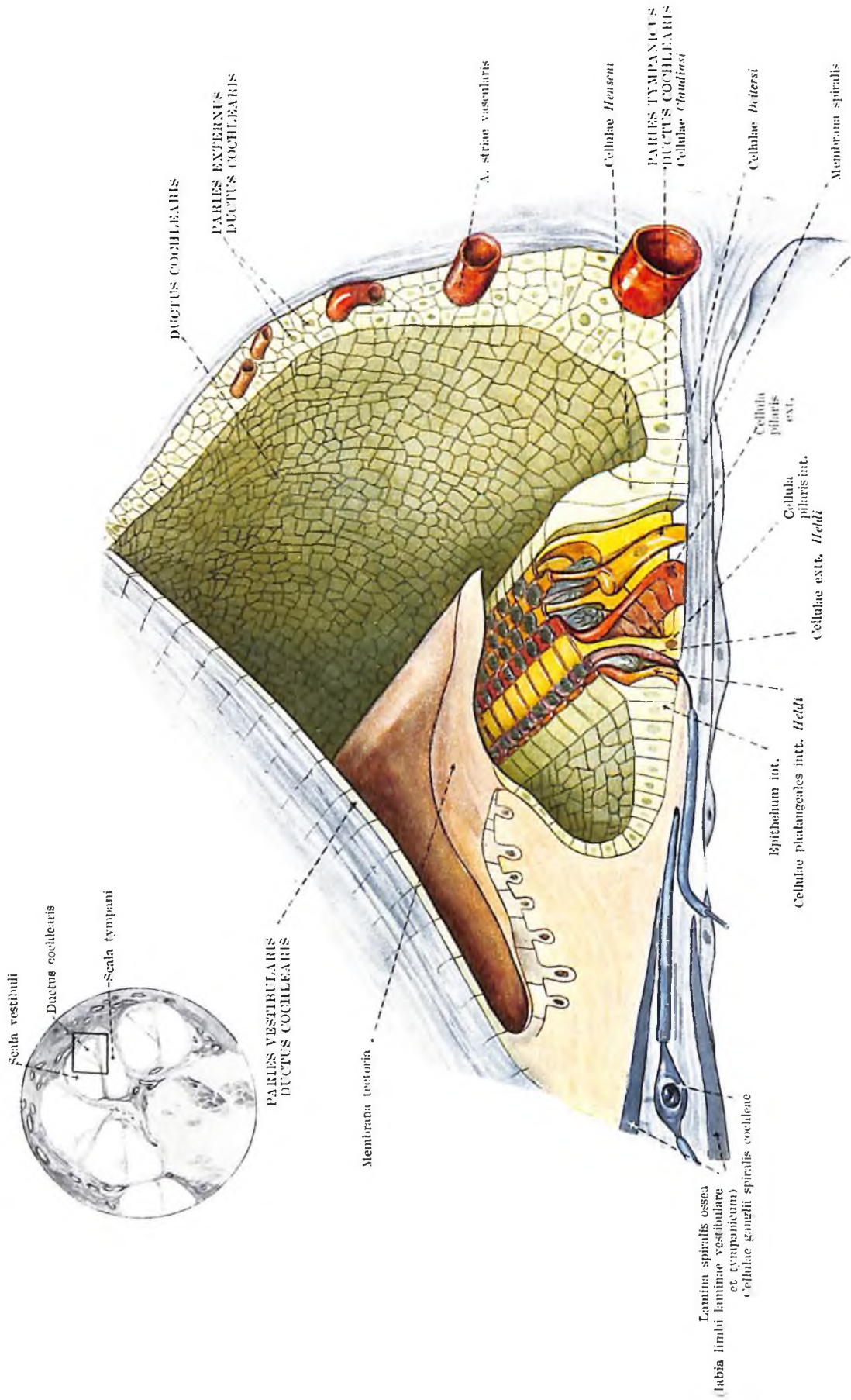


Fig. 261. DUCTU COCHLEARIS (organum spirale Corti, structura organi, sectio transversa)

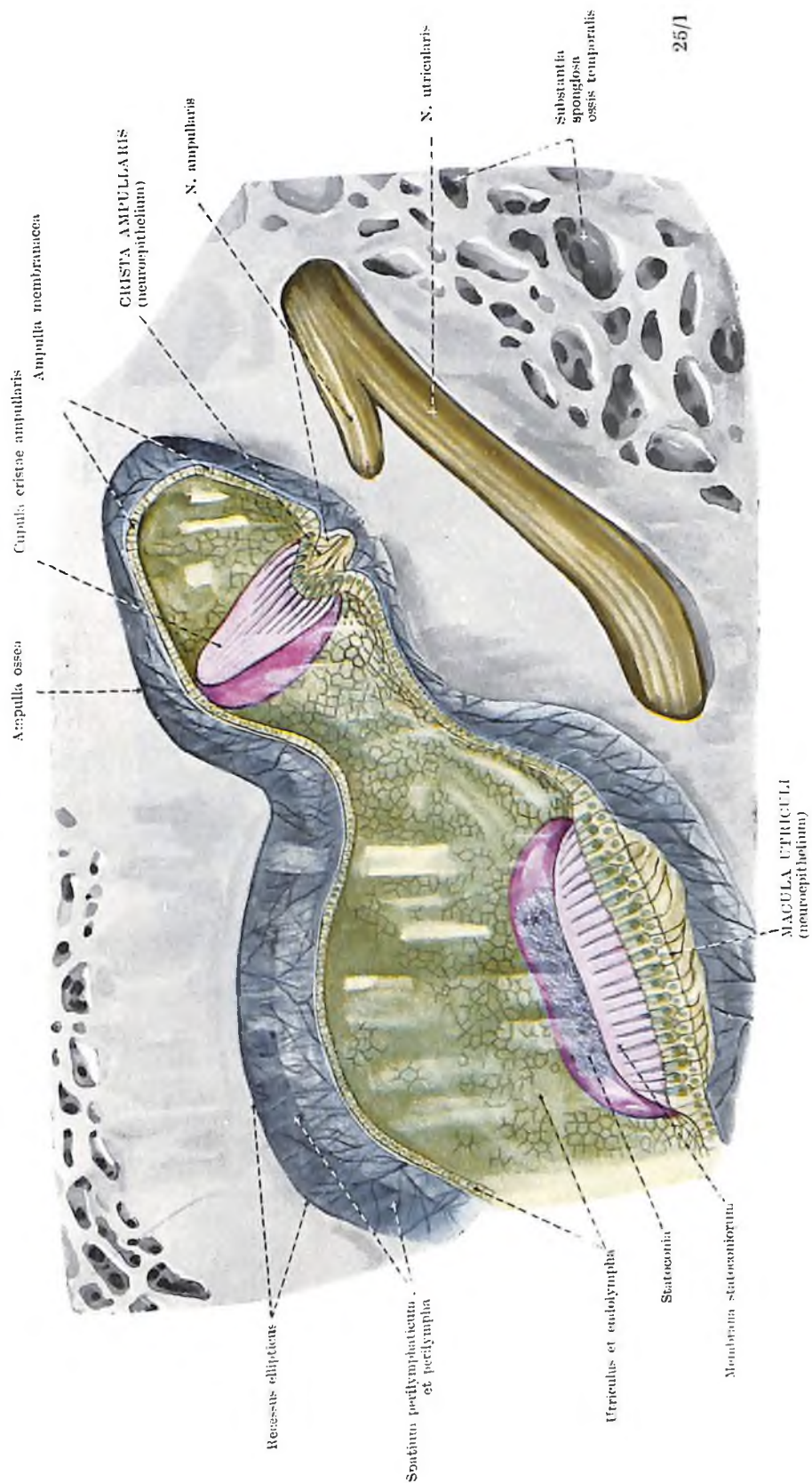


Fig. 262. CRISTA AMPULLARIS ET MACULA UTRICULI
 (structura labyrinthi membranacei)

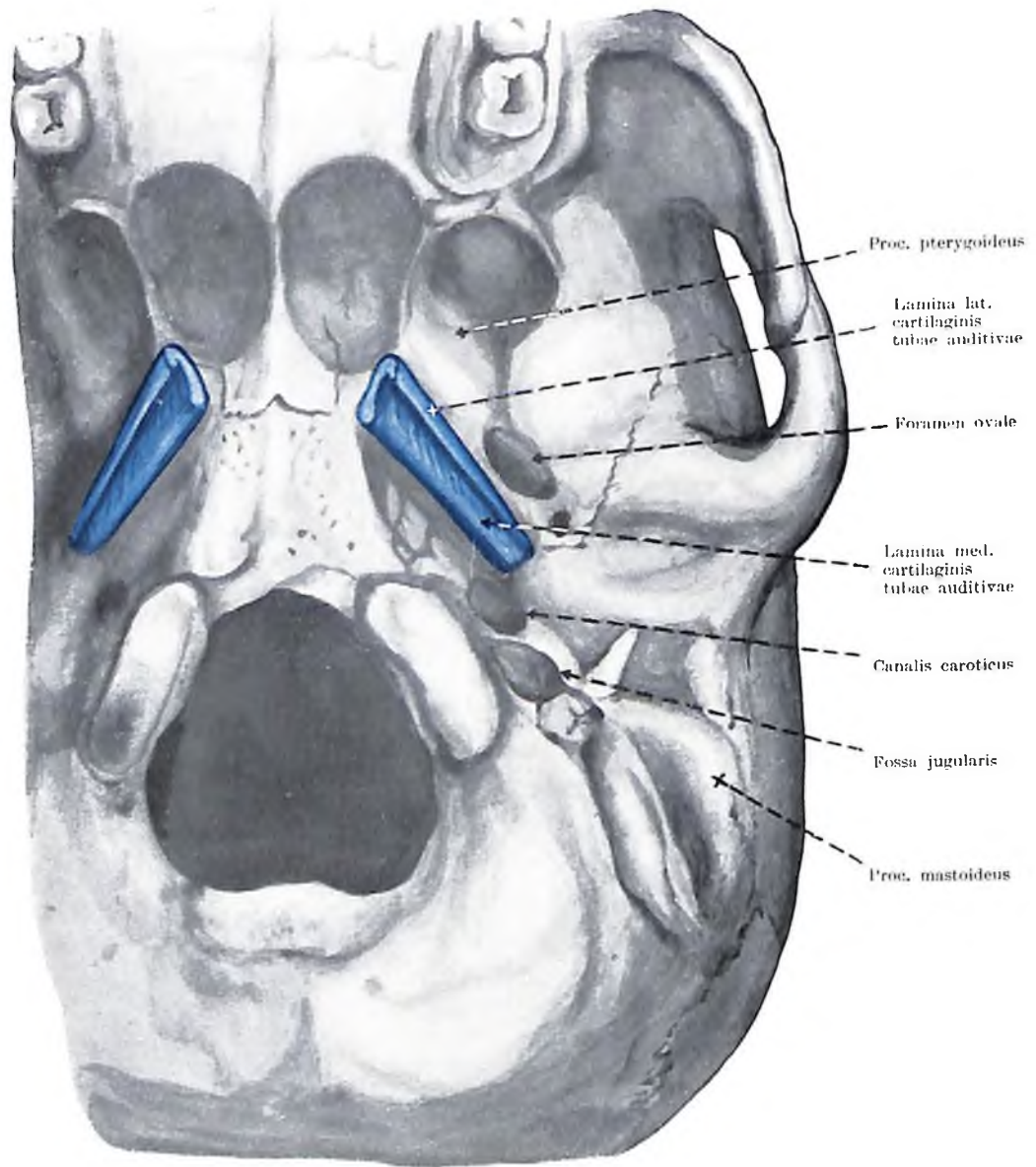


Fig. 263. TUBA AUDITIVA
(cartilago tubae auditivae)

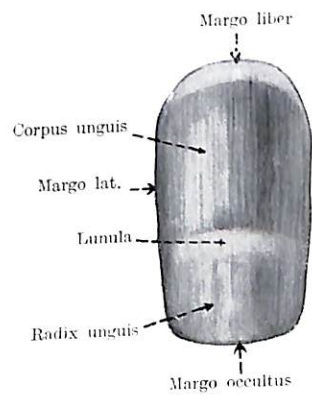
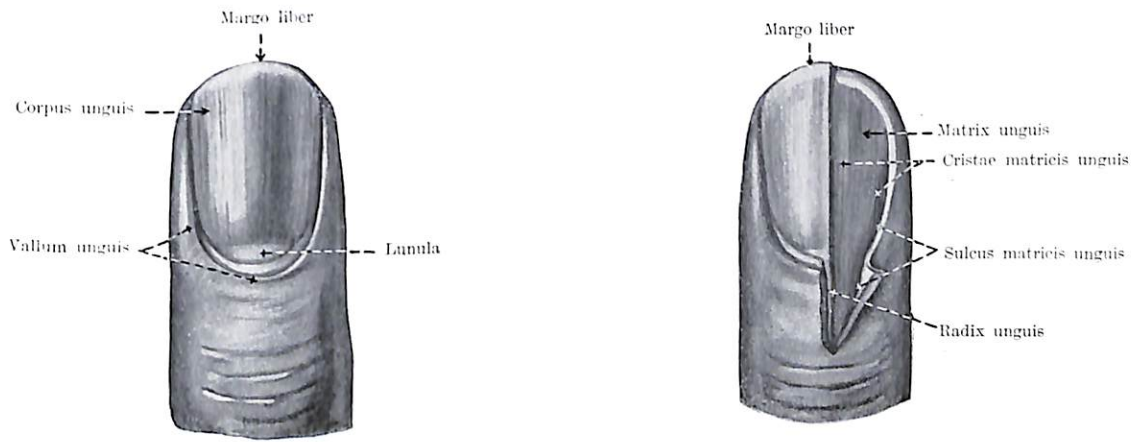


Fig. 264. UNGUIS

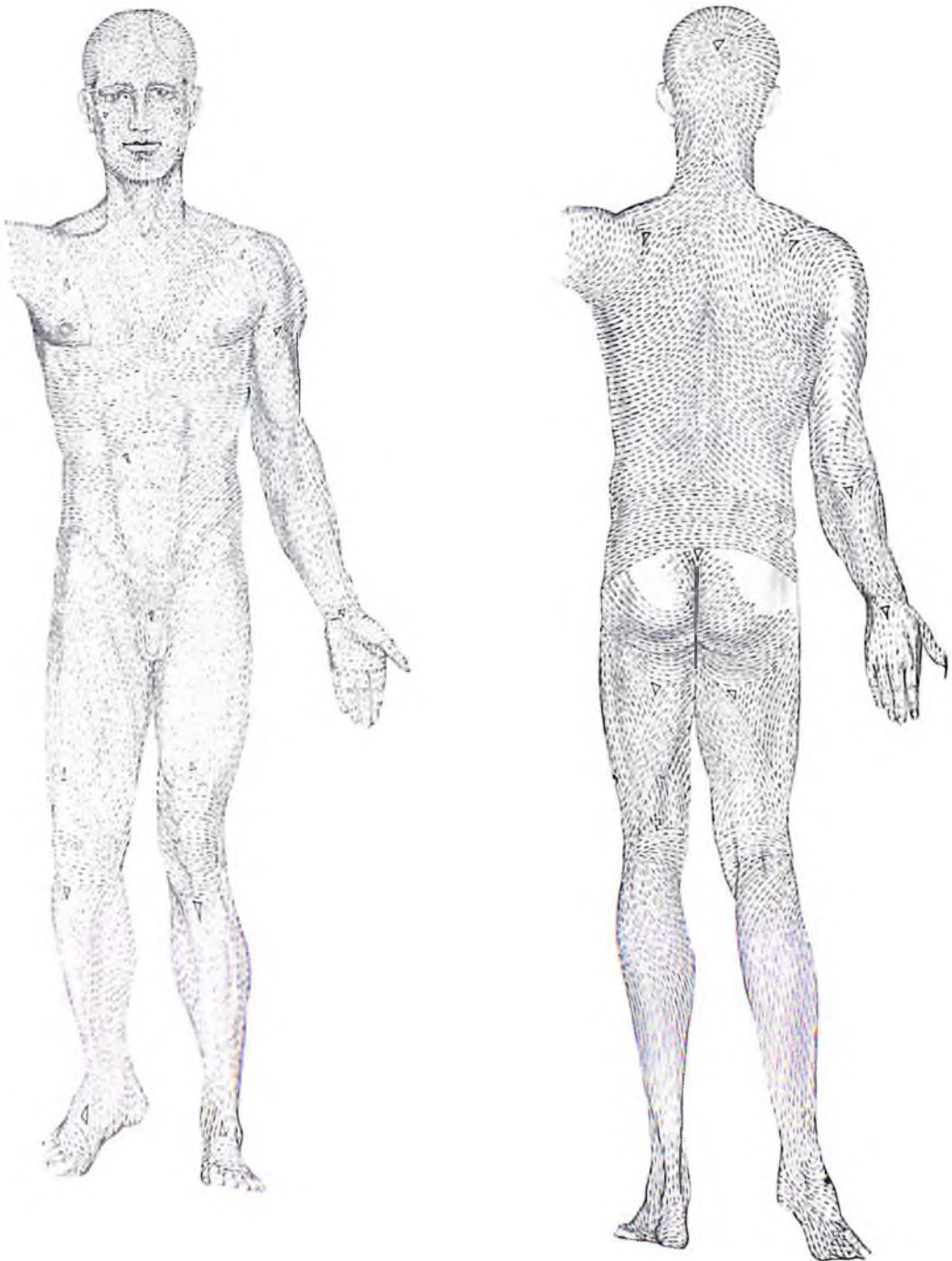


Fig. 265. SULCI CUTIS

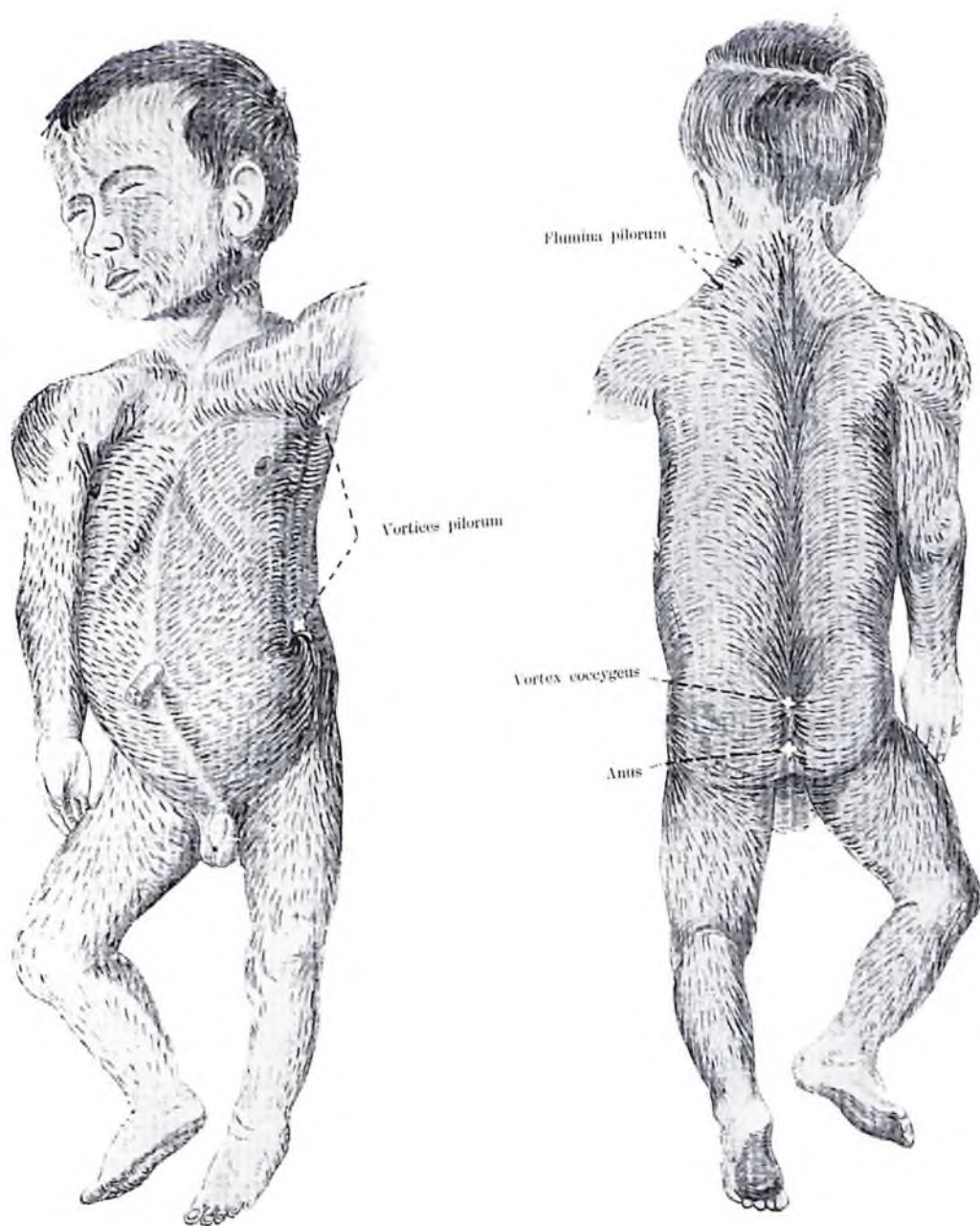


Fig. 266. FLUMINA PILORUM

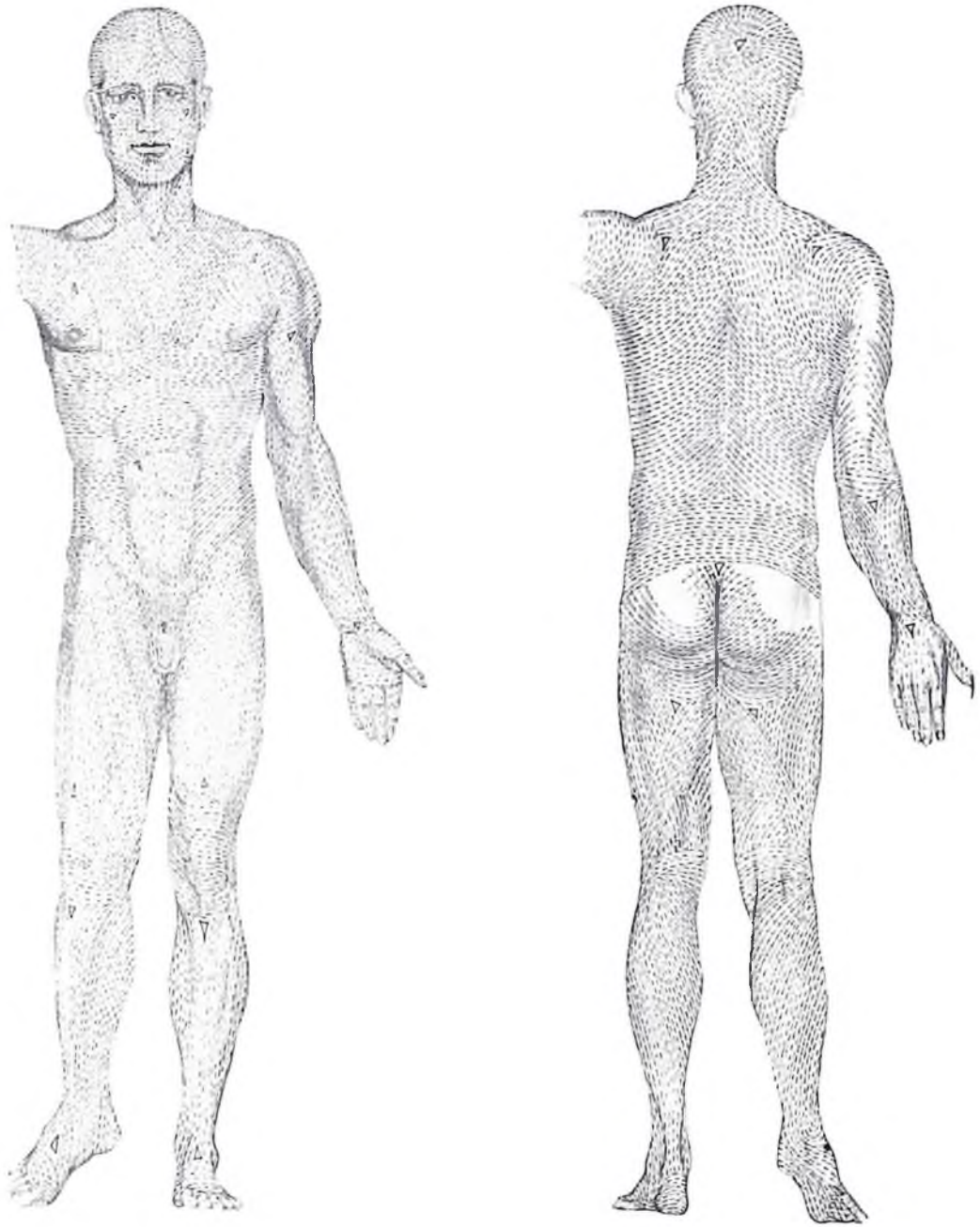


Fig. 265. SULCI CUTIS

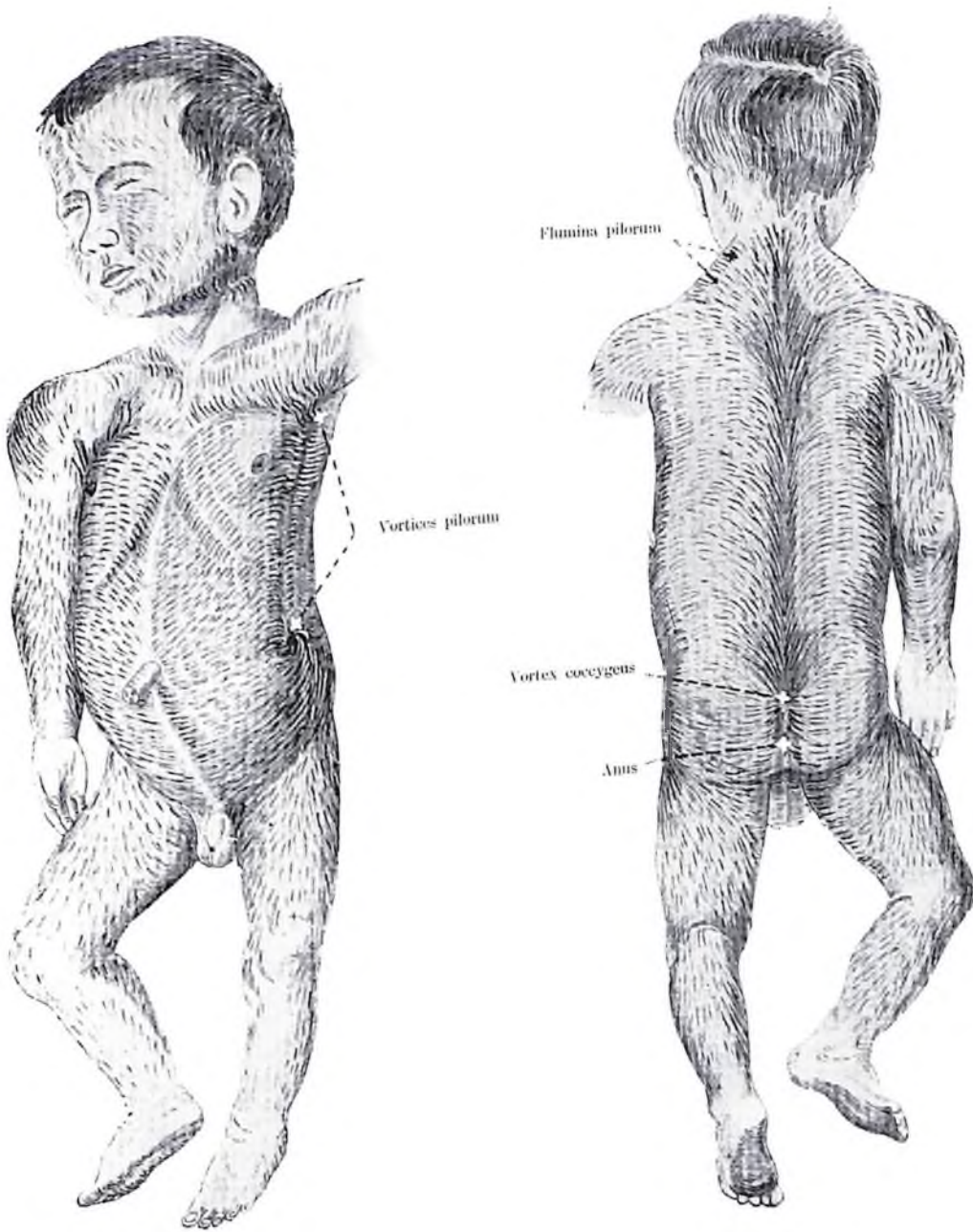


Fig. 266. FLUMINA PILORUM

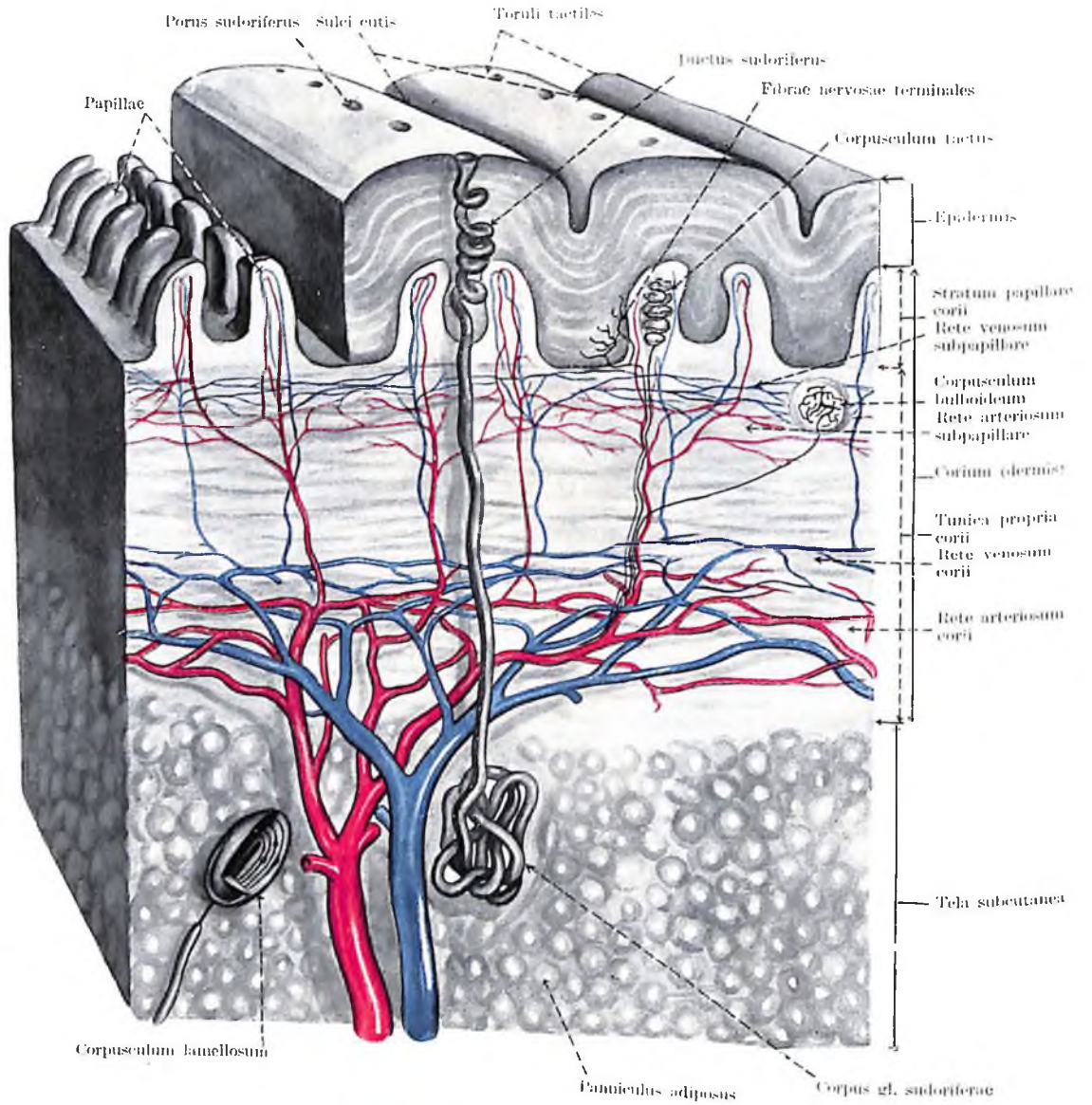


Fig. 267. CUTIS
(structura cutis)

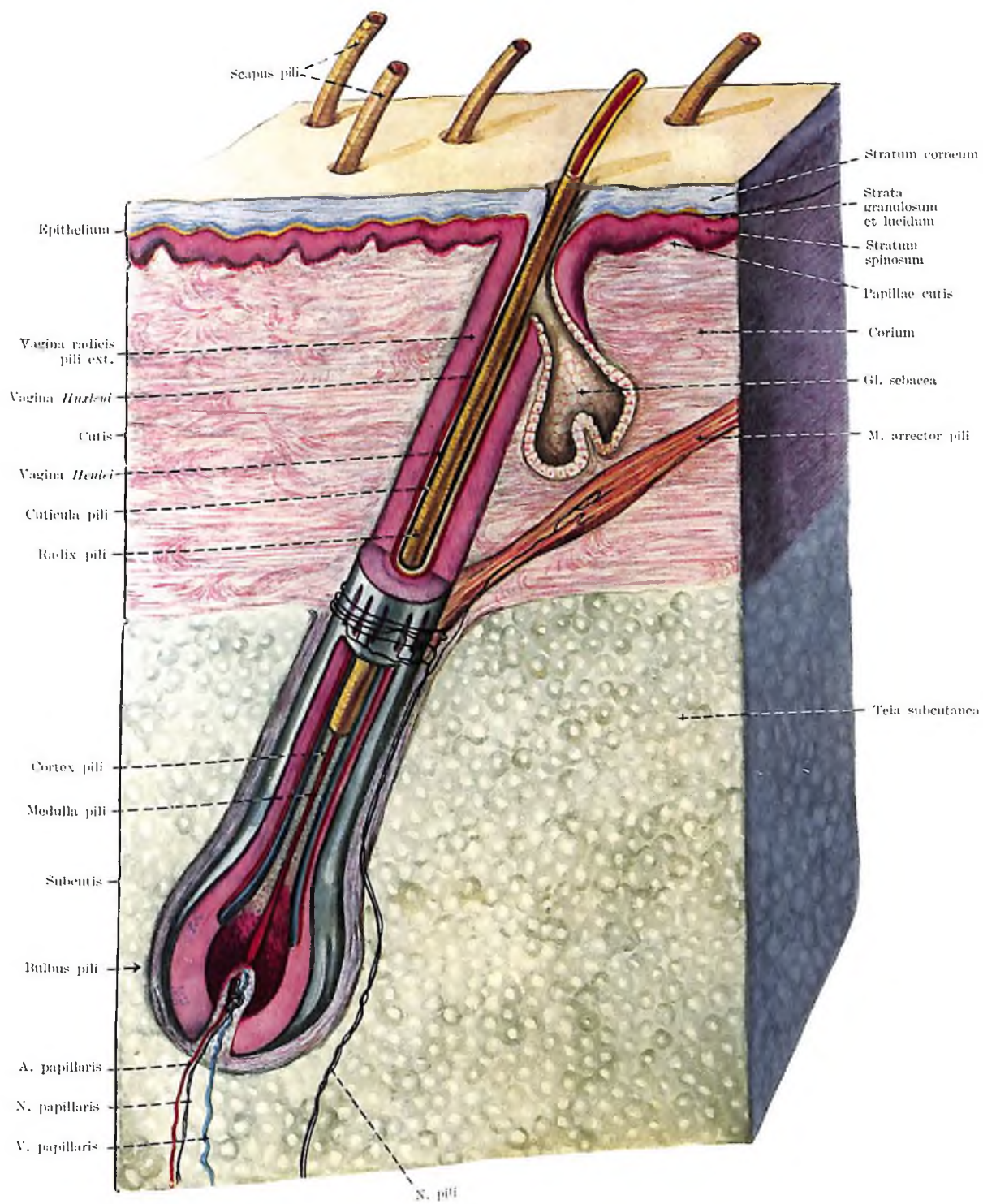


Fig. 268. PILUM
(structura radiceis pili)

INDEX

- angulus iridocornealis, *angulus iridis III.* 220
 — lateralis scapulae *I.* 175
 — mandibulae *I.* 47, *II.* 6, 32
 — mastoideus ossis parietalis *I.* 28, 29
 — *medialis scapulae*, vide: angulus superior
 — occipitalis ossis parietalis *I.* 28, 29
 — oculi lateralis *III.* 235, 237
 — — *medialis III.* 235
 — oris *II.* 2
 — *pubis*, vide: angulus subpubicus
 — sphenoidalis ossis parietalis *I.* 28, 29
 — sterni, *angulus sterni (Ludovici) I.* 96, 170
 — subpubicus, *angulus pubis I.* 121
 — superior pyramidis, vide: margo superior partis petrosae ossis temporalis
 — — scapulae, *angulus med. scapulae I.* 103, 104
 * — venosus dexter *III.* 192
 * — sinister *III.* 192, 204
 * angustia aortica esophagi *II.* 39
 * — cricoidea esophagi *II.* 39
 * — diaphragmatica esophagi *II.* 39
 annulus, vide: anulus
 — *haemorrhoidalis*, vide: zona hemorrhoidalis
 — *inguinalis abdominalis*, vide: anulus inguinalis profundus
 — — *subcutaneus*, vide: anulus inguinalis superficialis
 ansa cervicalis, *ansa n. hypoglossi III.* 119
 — — superficialis, *ansa cervicalis spl. (Langeri) III.* 117, 118
 * — hypoglossi, vide: ansa cervicalis
 — lenticularis, *ansa lentiformis III.* 45, 46
 — *nervi hypoglossi*, vide: ansa cervicalis
 — subclavia, *ansa subclavia (Vieussensii) III.* 121, 122, 123, 125, 186, 187
 * — vasculosae spirales hypophyseos *II.* 183
 antebrachium, *antibrachium*, vide: musculi, regiones antebrachii
 anthelix *III.* 242, 243, 244
antibrachium, vide: antebrachium
 antitragus *III.* 242, 243, 244
 antrum mastoideum, *antrum tympanicum I.* 19, 20, *III.* 103, 251, 253
 — *tympanicum*, vide: antrum mastoideum
 anulus (-i)
 — conjunctivae *III.* 217
 — femoralis *I.* 245
 — fibrocartilagineae membranae tympani *III.* 251, 253
 — fibrosus (cordis) *II.* 193, 199, 204
 — — dexter *II.* 193, 199, 204
 — — disci intervertebralis *I.* 165, 166
 — — sinister *II.* 199
 — *inguinalis profundus*, *annulus inguinalis abdominalis I.* 242, 244
 — — superficialis, *annulus inguinalis subcutaneus I.* 235, 240, 241, 243, 245, *II.* 149, *III.* 171
 — tendineus communis *III.* 232
 — tympanicus *I.* 21, 71, 73
 anus *II.* 80, 154, 171, 172, 173, *III.* 162, 166
 aorta, vide etiam: arcus, bulbus aortae *II.* 37, 38, 134, 189, 193, 194, 198, 200, 201, 202, 208, 210, 217, *III.* 123, 150, 187, 206
 — abdominalis *II.* 52, 74, 78, 79, 81, 117, 134, *III.* 149, 157, 158, 159, 160, 171, 189, 190, 191, 206
 — ascendens *II.* 117, 192, 215, 216, *III.* 148, 202
 — descendens, vide etiam: aorta abdominalis, thoracica *II.* 117, 211, *III.* 148, 158
 — thoracica, *aorta thoracalis I.* 249, 250, *II.* 110, 120, *III.* 153, 158, 187, 201
 apertura (-ae)
 * — cellularum posteriorum sinus ethmoidalis *I.* 63, *II.* 86
 * — ductus nasolacrimalis *I.* 63
 — — externa aqueductus vestibuli *I.* 17
 — — canaliculi cochleae *I.* 18
 * — apertura inferior canaliculi tympanici *I.* 18
 — — *medialis ventriculi quarti*, vide: apertura mediana ventriculi quarti
 — — mediana ventriculi quarti, *apertura medialis ventriculi quarti (foramen Magendii) III.* 80
 — — pelvis (minoris) inferior, *exitus pelvis I.* 125, 126
 — — — superior, *aditus pelvis I.* 123, 124, 125, 126
 — sinus frontalis *I.* 26
 — — sphenoidalis *I.* 23, 61, 64, *II.* 86
 — thoracis inferior *I.* 97
 — — superior *I.* 97
 — tympanica canaliculi chordae tympani *III.* 253
 — — — *tympanici I.* 19
 apex capitis fibulae, *apex capituli fibulae I.* 133, 134
 — cartilaginis arytenoideae *II.* 31, 94, 99
 — cordis *II.* 117, 190, 191, 192, 194, 195, 196, 198, 200, 210
 — dentis axis *I.* 78, 79
 — linguae *II.* 21, 22, 26, 88
 — nasi *II.* 2
 — ossis sacri *I.* 88, 89, 90
 — partis petrosae ossis temporalis, *apex pyramidis I.* 17, 18, 20, 60
 — patellae *I.* 131, 132
 — prostatae *II.* 136, 137, 151
 — pulmonis, *II.* 82, 109, 110, 111, 112, 117, 118
 — — dextri *II.* 118
 — — sinistri *II.* 118, 119
 — pyramidis, vide: apex partis petrosae
 — radices dentis *II.* 10
 — vesicae urinariae, *vertex vesicae urinariae II.* 136, 137, 138, 139, 140, 141, 143
 * aponeurosis dorsalis digitorum manus *I.* 283, 284
 * — — pedis *I.* 310, 311
 — musculi bicipitis brachii, *lacertus fibrosus I.* 261, 263, 270, *III.* 136
 — — obliqui externi abdominis *I.* 235, 236, 238, 240, 241, 242, 243, 245, *II.* 148
 — — — interni abdominis *I.* 236, 238, 241, 242
 — — transversi abdominis *I.* 238
 — palmaris *I.* 261, 270, 271, 273, 278
 — —, fasciuli longitudinales, *aponeurosis palmaris, fibrae longitudinales I.* 278
 — — — transversi, *aponeurosis palmaris, fibrae transversae I.* 278
 — plantaris *I.* 312, 313
 apophysis *I.* 2
 apparatus digestorius seu systema digestorium *II.* 1—67
 — lacrimalis *III.* 237, 238
 — respiratorius seu systema respiratorium *II.* 82—118
 — urogenitalis seu systema urogenitale *II.* 122—180
 appendix (-ices)
 — epididymidis *II.* 145, 146, 148
 — epiploicae *II.* 48, 49, 50, 74, 75, 78
 — fibrosa hepatis *II.* 63, 64, 65, 73, 76
 — testis *II.* 141, 143, 144, 149
 — *ventriculi laryngis*, vide: sacculus laryngis
 — vermiformis, *processus vermiformis II.* 1, 48, 49, 50, 57, 58, 74, 75, 78, *III.* 156, 157, 206
 — vesiculosa, *appendix vesiculosa (Morgagnii) II.* 168
 aqueductus cerebri, *aqueductus cerebri (Sylvii), aqueductus mesencephali III.* 4, 8, 10, 20, 21, 32, 36, 43, 49, 68, 70, 72
 arachnoidea *III.* 75, 79, 87
 — spinalis *III.* 75, 87, 93
 arbor vitae *III.* 32
 arcus (-us)
 — alveolaris mandibulae, *limbus alveolaris, margo alveolaris I.* 47, *II.* 15
 — — maxillae, *limbus alveolaris, margo alveolaris I.* 34, *II.* 13

- arcus anterior atlantis *I.* 75, 76, *II.* 26, 86, 88
 — aortae *II.* 37, 38, 109, 117, 120, 190, 191, 206, 208, 211, 214, 215, 216, *III.* 123, 125, 126, 148, 149, 153, 187
 — cartilaginis cricoideae *II.* 26, 88, 91, 99, 100, 104, 106
 — costalis, *arcus costarum I.* 97
 — dentales *II.* 7
 — — inferior *II.* 6, 7, 14, 17, 36
 — — superior *II.* 5, 7, 12, 16
 — glossopalatinus, vide: arcus palatoglossus
 — iliopectineus *I.* 296, 297
 — lumbocostalis medialis, vide: ligamentum arcuum mediale
 — palatoglossus, *arcus glossopalatinus II.* 21, 29, 30
 — palatopharyngeus, *arcus pharyngopalatinus II.* 29, 30, 34, 96, *III.* 105
 * — palmares *III.* 144
 — — profundus, *arcus rotaris prof. III.* 111, 111
 — — superficialis, *arcus rotaris spf. III.* 140, 144
 — pedis longitudinalis *I.* 214
 — — transversalis *I.* 146
 — pharyngopalatinus, vide: arcus palatopharyngeus
 — plantaris *III.* 181, 182
 — posterior atlantis *I.* 75, 76, 157, *II.* 36, *III.* 124
 — pubis *I.* 122
 — superciliaris *I.* 27
 — tendineus fasciae pelvis *II.* 138
 — — musculi levatoris ani *I.* 246, 247, *II.* 135, 138, 151, 175, 176
 — venosus dorsalis pedis *III.* 178, 183
 — vertebrae *I.* 80, 163
 — volaris, vide: arcus palmaris
 — zygomaticus *I.* 73, 150, 151, 152, *II.* 23, 24, 27, 31, 32, 33, 35, 87
 area (-ae)
 — acustica, vide: area vestibularis
 — cochleae *III.* 258
 — corticis cerebri *III.* 12, 13
 — cribrosa papillae renalis *II.* 128
 * — cytoarchitectonicae *III.* 12, 13
 — intercondylaris anterior, *fossa intercondyloidea ant. I.* 135
 — — posterior, *fossa intercondyloidea post. I.* 135
 — nervi facialis *III.* 258
 — nuda hepatis, *pars affixa hepatis II.* 64
 — parolfactoria, vide: area subcallosa
 * — postrema fossae rhomboideae *III.* 37
 * — striata *III.* 63
 — subcallosa, *area parolfactoria (Broca) III.* 4, 5, 10, 20, 21
 — vestibularis fossae rhomboideae, *area acustica III.* 37
 — — inferior *III.* 258
 — — superior *III.* 258
 areola mammae *II.* 178, 179
 arteria (-ae)
 — alveolaris inferior *II.* 27, 36, *III.* 103, 110, 114, 122
 — — superiores posteriores *III.* 110, 115
 — angularis *III.* 110, 113, 114, 115
 — anonyma, vide: truncus brachiocephalicus
 * — anteriores antibrachii *III.* 138, 139
 * — — brachii *III.* 136, 137
 — appendicularis *III.* 156, 157
 — arcuata *II.* 129, 130, *III.* 180, 182
 — auditiva interna, vide: arteria labyrinthi
 * — auris internae *III.* 260
 — axillaris *III.* 125, 126, 127, 128, 129, 131, 136, 137
 * — baseos cerebri *III.* 1, 73, 95
 — basilaris *III.* 1, 71, 72, 73, 80, 95
 — brachialis *III.* 136, 137, 139
 — bronchiales, vide: rami bronchiales
 — bronchialis *II.* 121
 — buccalis, *a. buccinatoria III.* 110, 114, 115
 — buccinatoria, vide: arteria buccalis
 * — arteriae bulbi oculi *III.* 221
 — — penis, *a. bulbi urethrae II.* 135, 159, *III.* 162
 — — urethrae, vide: arteria bulbi penis
 — carotis *II.* 189
 — — communis *I.* 228, *III.* 121, 122, 123, 198
 — — — dextra *I.* 225, *II.* 37, 38, 109, 110, 117, 214, 215, 217, *III.* 123, 125, 126, 149, 186, 187, 202
 — — — sinistra *II.* 37, 38, 106, 110, 117, 185, 190, 191, 206, 211, 213, 214, 215, 216, 217, *III.* 123, 125, 148, 149, 151, 197
 — — externa *II.* 23, 27, 36, 38, *III.* 102, 103, 110, 115, 119, 120, 121, 122, 123
 — — interna *II.* 23, 25, 36, 38, 181, *III.* 1, 77, 78, 95, 96, 97, 98, 99, 100, 101, 102, 103, 105, 106, 109, 119, 120, 121, 122, 186, 197, 247, 252
 — — —, *syphon *II.* 181, *III.* 78, 98
 — centralis retinae *III.* 216, 221
 — cerebelli inferior anterior *III.* 1, 71, 72, 73, 95
 — — — posterior *III.* 1, 71, 72, 73, 75, 95
 — — superior *III.* 1, 71, 73, 95
 — — — dextra *III.* 72
 * — cerebri *III.* 79
 — — anterior *II.* 181, *III.* 1, 42, 72, 73, 95, 96
 — — media *III.* 48, 73
 — — posterior *III.* 1, 71, 73, 95
 — — — dextra *III.* 72
 — — — sinistra *III.* 72
 — cervicalis ascendens *II.* 38, *III.* 120, 121, 126
 — — profunda *III.* 123
 — — superficialis (var.), vide etiam: ramus superficialis arteriae transversae colli *II.* 38, *III.* 118, 119, 120, 121, 126
 — choroidea anterior, *a. chorioidea ant. III.* 73
 — ciliares anteriores *III.* 218, 221, 223
 — — posteriores *III.* 99, 219
 — — — breves *III.* 218, 221
 — — — longa *III.* 218, 221
 — circumflexa femoris lateralis *III.* 171
 — — — medialis *III.* 171
 — — humeri posterior *III.* 134
 — — ilium profunda *III.* 159, 171
 — — — superficialis *III.* 170
 — — scapulae *III.* 134, 136, 137
 — coeliaca, vide: truncus celiacus
 — colica dextra *II.* 49, *III.* 156, 157, 214
 — — media *II.* 49, *III.* 156, 157
 — — sinistra *III.* 157, 214
 — collateralis ulnaris inferior *III.* 136, 137
 — — — superior *III.* 136, 137
 * — colli *III.* 116—123
 — comitans nervi ischiadici *III.* 173, 174
 — communicans anterior *III.* 1, 72, 73, 95
 — — posterior *III.* 1, 73, 95
 — coronaria dextra *II.* 193, 199, 206, 208, 209
 — — sinistra *II.* 196, 199, 205, 206, 207, 209
 * — corticales *III.* 79
 * — cruris anteriores *III.* 176
 * — — posteriores *III.* 177
 — cystica *II.* 52, 53, *III.* 154, 155
 — digitales dorsales manus *III.* 142, 143
 — — palmares communes, *aa. digitales volares communes III.* 140, 141, 144
 — — — propria, *a. digitalis volaris propria III.* 140, 141, 142, 143, 144
 — — — digiti quinti ulnaris, *a. volaris propria digiti V. ulnaris III.* 141, 144
 — — — indicis radialis, *a. volaris propria indicisradialis III.* 141
 — — plantares communes *III.* 181
 — — — propriae *III.* 181, 182
 — dorsalis pedis *III.* 180, 182
 — — penis *II.* 158, 159, 160, 162, 163, *III.* 159, 160, 162
 — — — dextra *II.* 150, 158
 — — — sinistra *II.* 150

- *arteriae dorsi manus III. 142, 143
 * — — pedis III. 180, 182
 — ductus deferentis, *a. deferentialis* II. 146
 * — encephali III. 71, 72, 73
 * — epigastricae III. 148
 — — inferior I. 242, 243, 244, II. 135, III. 148, 158, 159, 171
 * — — lateralis III. 148
 — — superficialis III. 170
 — — superior III. 148
 — episcleralis III. 221
 — ethmoidalis anterior III. 99, 100
 — — posterior III. 99, 100
 — facialis, *a. maxillaris ext.* II. 27, III. 110, 113, 114, 115, 118, 119, 120, 121, 122, 123
 * — faciei III. 113, 114, 115
 — femoralis I. 235, 243, 245, 297, II. 135, III. 158, 170, 171, 209
 * — femoris anteriores III. 170, 171
 * — — posteriores III. 173, 174
 * — fissurae medianae anterioris III. 91
 — frontalis, *vide: arteria supratrochlearis*
 — gastricae breves III. 155
 — — dextra III. 154, 207
 — — sinistra II. 51, 52, 53, 134, III. 154, 155, 187, 207
 — gastroduodenalis II. 51, 52, 53, 81, III. 154, 155, 187
 — gastroepiploica dextra III. 154, 155, 207
 — — sinistra III. 154, 155
 — genus descendens, *a. genus suprema* III. 171
 — — inferior lateralis III. 174
 — — — medialis III. 174
 — — superior lateralis III. 174
 — — — medialis III. 174
 — glutea inferior III. 159, 160, 161, 172
 — — superior III. 159, 160, 173
 — haemorrhoidalis, *vide: arteria rectalis*
 — helicina II. 159, 163
 — hepatica communis II. 53, 134, 189, III. 154, 155, 207
 — — propria II. 51, 52, 53, 65, 81, III. 154, 155, 187, 188, 207
 * — hepatis III. 194
 — hypogastrica, *vide: arteria iliaca interna*
 * — hypophysialis inferior II. 183
 * — — superiores II. 183
 * — ilei, *aa. ileae* III. 156
 — ileocolica III. 156, 157
 — iliaca communis II. 51, 52, 122, 134, 176, 189, 211, III. 158, 159, 160, 188, 190, 215
 — — — sinistra II. 211, III. 149, 171, 189
 * — — externa I. 243, 244, 246, 247, II. 122, 189, 211, III. 158, 159, 171, 206
 — — — dextra II. 211, III. 148, 160, 161
 — — — sinistra III. 149, 160, 161
 — — interna, *a. hypogastrica* II. 122, 189, III. 158, 159, 161, 188, 206, 210
 — — — dextra III. 160, 189
 — — — sinistra III. 149, 160
 — iliolumbalis III. 159
 — infraorbitalis III. 110, 114, 115, 229
 — intercostalis, *vide: arteria intercostalis posterior*, *ramus intercostalis anterior*
 — — posterior, *a. intercostalis* II. 38, 110, 180, III. 149, 150, 153, 187
 * — interlobaris renis II. 128, 129, 130
 * — interlobularis hepatis II. 69
 * — — renis II. 128, 130, 132
 * — interossea antibrachii anterior, *a. interossea volaris* III. 139
 — — — posterior, *a. interossea dors.* III. 135
 * — intestini crassi III. 157
 * — — tenuis III. 193, 195
 * — jejunales III. 156
 — labialis inferior III. 110, 113
 arteria labialis superior III. 110, 113
 — labyrinthi, *a. auditiva int.* III. 72, 73, 260
 — laryngea inferior III. 122
 — — superior III. 120, 121, 122, 126
 * — laterales cerebri III. 71
 * — lenticulostrata III. 73
 — lienalis II. 51, 52, 53, 71, 72, 79, 80, 134, III. 154, 155, 187
 — lingualis III. 102, 119, 120, 121, 122, 123, 186
 — lumbalis III. 160, 191
 — — (L. 4.) III. 158
 — malleolaris anterior lateralis III. 176, 180, 182
 — — — medialis III. 181, 182
 — *mammaria interna*, *vide: arteria thoracica interna*
 * — manus III. 141
 — masseterica III. 114
 — maxillaris, *a. maxillaris int.* II. 27, 31, III. 110, 114, 115, 186
 — — *externa*, *vide: arteria facialis*
 — — *interna*, *vide: arteria maxillaris*
 * — mediales cerebri III. 72
 * — medullae spinalis III. 91
 — meningeae media II. 27, III. 1, 95, 98, 103, 110, 115
 — mentalis III. 110, 114, 122
 — mesenterica II. 181
 — — inferior II. 51, 52, 122, 134, 211, III. 157, 158
 — — superior II. 49, 51, 52, 53, 122, 134, 211, III. 155, 156, 157, 158, 191
 — metacarpeae dorsales III. 142, 143
 — — palmares, *aa. metacarpeae volares* III. 141, 144
 — metatarsae dorsalis III. 182
 — — plantares III. 181, 182
 — musculophrenica III. 148
 — obturatoria III. 159
 — occipitalis III. 110, 113, 114, 115
 — ophthalmica II. 25, II. 1, 95, 97, 99, 100
 — ovarica II. 167, III. 161, 205, 210
 * — palmae manus III. 140, 141
 — pancreaticoduodenalis inferior III. 155, 156, 157
 — — superior III. 155
 * — papillaris cutis III. 268
 * — parietales pelvis III. 59
 * — parietis anterioris trunci III. 148
 * — pedis III. 182
 — perforans, *a. perforans I., II., III.* III. 173, 174
 — pericardiacophrenica II. 213, 214, 215, 216, 217, III. 148, 151, 152, 153
 — — dextra II. 213
 — — sinistra II. 213
 — perinealis, *a. perinei* III. 162
 — peronea I. 303, III. 177
 — phrenica inferior II. 51, 52, 53, 122 III. 158, 191
 — — dextra III. 158
 * — plantae pedis III. 181, 182
 — plantaris lateralis III. 181, 182
 — — medialis III. 181, 182
 * — polaris inferior renis II. 129
 * — — superior renis II. 129
 * — poplitea I. 229, III. 174, 177
 — posteriores membri superioris III. 131, 135
 — princeps pollicis III. 141, 144
 — profunda brachii III. 135, 137
 — — femoris III. 170, 171
 — — linguae II. 25
 — — penis II. 155, 158, 159, 160, 162, 163, III. 160, 162
 — pudendae externae, *aa. pudendales ext.* III. 159, 170, 171
 — — interna, *a. pudendalis int.* II. 135, 159, III. 159, 160, 161, 162, 173
 — pulmonalis, *vide: truncus pulmonalis*
 — pulmonalis, *r. a. pulmonalis* II. 121, 189
 — — dextra, *r. dext. a. pulmonalis* II. 112, III. 152, 187

- arteria pulmonalis sinistra, *v. sin. a. pulmonalis* II. 111, 120, 190, 191, 208, 211, III. 153, 201
 — radialis III. 135, 137, 138, 139, 140, 142, 143
 — radicularis dorsalis, *a. radicularis post.* III. 91
 — — ventralis, *a. radicularis ant.* III. 91
 — rectalis inferior, *a. haemorrhoidalis inf.* III. 158, 162
 — superior, *a. haemorrhoidalis sup.* II. 51, 52, III. 157, 160, 161
 — recurrens radialis III. 139
 — — tibialis anterior III. 176
 — — ulnaris III. 139
 * regionis perinealis III. 162
 — renalis II. 53, 122, 123, 124, 125, 129, 134, 188, 211, III. 158
 — — dextra II. 122, III. 191
 — — sinistra II. 122
 * renis II. 130, 132, 133
 * retinae III. 222
 * retroperitoneales III. 158
 — sacralis lateralis III. 158, 159
 — — mediana II. 134, III. 158
 — sigmoidea III. 157
 — spermatica interna, *vide: arteria testicularis*
 — spinalis anterior III. 1, 72, 73, 91, 95
 — — posterior III. 91
 * striae vascularis III. 261
 — subclavia I. 225, II. 134, 189, III. 120, 121, 122, 123, 125, 126
 — — dextra II. 37, 38, 109, 110, 117, III. 123, 125, 126, 148, 149, 151, 152, 186, 187
 — — sinistra II. 37, 38, 109, 110, 117, 120, 190, 191, 206, 211, 214, 215, 216, 217, III. 123, 124, 148, 149, 151, 153
 * subinguinales III. 170, 171
 — submentalialis III. 110, 114, 118, 119, 120, 121, 123
 * superficiales capitis III. 110
 * supracostalis III. 150
 — supraorbitalis III. 110, 114, 115
 — suprarenalis II. 188
 — — inferior II. 122, 188, III. 158
 — — media II. 122, III. 158
 — — superior III. 158, 191
 — — dextra III. 158
 — suprascapularis, *a. transversa scapulae* II. 38, III. 118, 119, 120, 121, 122, 126, 134
 — supratrochlearis, *a. frontalis* III. 110, 114, 115
 — tarsea lateralis III. 182
 — — medialis III. 182
 — temporalis media III. 110, 115
 — profundae III. 110, 114, 115
 — — anterior III. 114
 — — posterior III. 114
 — — superficialis II. 27, 35, III. 102, 103, 110, 113, 114, 115, 122
 — testicularis, *a. spermatica int.* I. 244, II. 51, 52, 134, 135, 146, 148, III. 158, 171, 191, 209
 — — dextra II. 122
 — — sinistra II. 122
 * thalamostriata III. 73
 — thoracica interna, *a. mammaria int.* II. 37, 38, 213, 214, 215, 216, 217, III. 121, 122, 123, 126, 148, 150, 152
 — — — dextra II. 217, III. 118, 152
 — — — sinistra III. 118
 — — lateralis, *a. thoracalis lat.* III. 126
 * thoracis III. 151, 152, 153
 * thoracoacromialis III. 126
 * thymica II. 213
 — thyroidea inferior II. 38, III. 120, 121, 122
 — — superior II. 23, 27, III. 119, 120, 121, 122, 123, 126, 186
 — tibialis anterior I. 304, 305, III. 176, 182
 — — posterior I. 303, III. 177, 180, 181, 182
 * trabecularis II. 72, 183
 *arteria trabecularis hypophyseos II. 183
 * — — lienalis II. 72
 — — transversa colli II. 37, 38, III. 120, 121, 122, 123, 126
 — — — faciei III. 110, 113
 — — — scapulae, *vide: arteria suprascapularis*
 — — ulnaris III. 137, 138, 139, 140, 141, 144
 — — umbilicalis II. 211
 — — urethralis II. 158, 160, 162, 163, III. 162
 — — uterina II. 167, 168, 170, III. 161, 190, 210
 * vaginae nervi optici III. 221
 — vertebralis I. 229, II. 36, 37, 38, 117, III. 1, 71, 72, 73, 75, 76, 80, 92, 95, 108, 120, 121, 122, 123, 124, 163
 — — — dextra III. 72
 — — — sinistra III. 71, 73
 — vesicalis inferior III. 160
 — — — superior III. 160, 161
 * viscerales abdominis III. 154, 155, 156, 157
 * — — pelvis feminae III. 161
 * — — masculinae III. 160
 — — volaris indicis radialis, *vide: arteria radialis*
 arteriola nasalis retinae inferior III. 222
 * — recta spuria II. 133
 — — temporalis retinae superior III. 222
 *arthrologia I. 150—211
 articulatio (-nes)
 — acromioclavicularis I. 173
 — atlantoaxialis, *articulatio atlantocipitrophica* I. 154, 155, 156, 157
 — — — mediana I. 157
 — atlantooccipitalis I. 154, 155, 156, 157
 — capitis costae, *articulatio capituli costae* I. 160
 — carpometacarpea I. 190
 — — I. (pollicis) I. 185, 187, 188
 — — IV. I. 188
 — costovertebrales I. 160, 161, 162, 163
 — coxae I. 195, 196, 197, 198, 199
 — cricoarytenoidea II. 98
 — cricothyroidea II. 97, 98
 — cubiti I. 176—183
 — digitorum manus I. 189, 190
 — genus I. 200—208
 — humeri I. 172, 173, 174, 175, III. 129, 134
 — incudomallearis III. 253
 — incudostapedialis III. 253
 — intercarpea, *vide: articulatio mediocarpea*
 — interchondrales I. 170
 — intermetacarpeae I. 188
 — interphalangea manus I. 190
 — — pedis I. 214
 — intertarsae I. 212
 * laryngis II. 97, 98, 99
 — mandibularis, *vide: articulatio temporomandibularis*
 — manus I. 185, 186, 187, 188
 — mediocarpea, *articulatio intercarpea* I. 188
 — membri (*extremitatis*) inferioris I. 192—211
 — — — superioris I. 172—191
 — metacarpophalangea I. 187, 190
 — metatarsophalangea I. 214
 — ossiculorum auditus III. 253
 — pedis I. 213, 214
 — radiocarpea I. 188
 — radioulnaris distalis I. 184, 186, 187, 188
 — — proximalis, *vide etiam: articulatio cubiti* I. 132, 176, 181, 184
 — sacroiliaca I. 192, II. 175
 — sternoclavicularis I. 170, 171
 — sternocostales, *junctionae sternocostales* I. 170, 171
 — — I. I. 171
 — subtalaris, *articulatio talocalcanea* I. 212, 214
 — talocalcanea, *vide: articulatio subtalaris*
 — talocalcaneonavicularis I. 212, 214
 — talocruralis I. 209, 214

- articulatio tarsi transversa, *articulatio tarsi transversa (Choparti) I. 213*
 — tarsometatarsæ, *articulatio tarsometatarsæ (Lisfranci) I. 116, 213*
 — temporomandibularis, *articulatio mandibularis I. 150, 151, 152*
 atlas, vide etiam: arcus anterior, posterior atlantis *I. 75, 76, 158, II. 36, III. 70, 76, 124*
 atrium dextrum *II. 189, 191, 192, 193, III. 187*
 — sinistrum *II. 189, 191, 195, 200, 205*
 auricula *III. 240—246*
 — atrii dextri, *auricula dextra II. 190, 192, 193, 200, 210, III. 151*
 — sinistri, *auricula sinistra II. 190, 195, 197, 200, 201, 205, 206, 216*
 — cordis, vide: auricula atrii
 auris externa *III. 244—246*
 — interna *III. 246, 247, 254—257, 259—262*
 — media *III. 246, 247, 250—253*
 axilla, vide: fossa, regio axillaris
 axis, *epistropheus I. 77, 78, 79, 155, 156, 158, II. 26, 36, 86, 88, 117 III. 76*
 — bulbi, *axis oculi III. 216*
- B**
- *bacilli retinae *III. 228*
 basis cartilaginis arytеноideae *II. 93, 94*
 — cerebri, *facies basialis cerebri*, vide etiam: facies inferior cerebri *III. 1, 95*
 — cochleae *III. 255, 256*
 — cranii externa, *basis cranii, facies ext. I. 59, 60*
 — interna, *basis cranii, facies int. I. 58*
 glandulae suprarenalis, vide: facies renalis mandibulae *II. 32, III. 123*
 — modioli *III. 257*
 — nasi *II. 2*
 — ossis metacarpalis V. *I. 114, 115, 116*
 — — pollicis *I. 114, 115*
 — sacri *I. 88, 90, 92, 120, II. 175*
 patellae *I. 131, 132*
 — pedunculi cerebri, vide: crus cerebri
 phalangis *I. 117, 190*
 *pontis *III. 42*
 — prostatae *II. 136, 137*
 — pulmonis *II. 109, 118*
 — pyramidis renalis *II. 126*
 — stapedis *III. 250, 254*
 bifurcatio tracheae *II. 82, 106, 107, 113*
 brachium, vide: musculi, regiones brachii
 — colliculi inferioris, *brachium quadrigeminum inf. II. 184, III. 37*
 — superioris, *brachium quadrigeminum sup. II. 184, III. 37*
 — conjunctivum, vide: pedunculus cerebellaris superior
 — pontis, vide: pedunculus cerebellaris medius
 — quadrigeminum, vide: brachium colliculi
 bronchiolus *II. 121*
 — respiratorius *II. 121*
 bronchus (-i)
 — dexter, vide: bronchus principalis dexter
 — lingularis inferior *II. 113*
 — superior *II. 113*
 — lobaris, *r. bronchialis lobi II. 82, 106, 113*
 — inferior pulmonis dextri *II. 82, 113*
 — — sinistri *II. 82, 106, 113*
 — medius *II. 82, 113, 116*
 — superior pulmonis dextri *II. 82, 113*
 — — sinistri *II. 82, 105, 113*
 — principalis *II. 113*
 — dexter, *bronchus dext. II. 37, 38, 82, 106, 107, 112, 113, 115, 116, III. 152, 203*
 — sinister, *bronchus sin. II., 38, 82, 106, 107, 111, 113, 120, III. 153*
 bronchi segmentales, *rr. bronchiales bronchorum II. 38, 106, 113, 115, 116*
 — anterior pulmonis dextri *II. 113, 115*
 — — sinistri *II. 113*
 — apicalis lobi superioris pulmonis dextri *II. 113*
 — — superioris pulmonis sinistri *II. 113*
 — (superior) lobi inferioris pulmonis dextri *II. 113, 115*
 — — lobi inferioris pulmonis sinistri *II. 113*
 — apicoposterior *II. 113*
 — basalis anterior pulmonis dextri *II. 113*
 — — pulmonis sinistri *II. 113*
 — lateralis pulmonis dextri *II. 113*
 — — pulmonis sinistri *II. 113*
 — medialis (cardiacus) *II. 113, 116*
 — posterior pulmonis dextri *II. 113*
 — — pulmonis sinistri *II. 113*
 — lateralis *II. 113*
 — medialis *II. 113, 116*
 — posterior pulmonis dextri *II. 113*
 — — sinistri *II. 113*
 — sinister, vide: bronchus principalis sinister
 bucca seu mala *II. 2*
 bulbus aortae *II. 37*
 — inferior venae jugularis interna *III. 119*
 — oculi *III. 1, 95, 98, 99, 100, 101, 216—269, 232*
 — olfactorius *III. 1, 8, 9, 10, 20, 26, 64, 73, 78, 95, 96*
 — penis, *bulbus urethrae I. 246, II. 135, 140, 141, 142, 143, 155, 156, 159, III. 189*
 — pili *III. 268*
 — superior venae jugularis interna *III. 76, 108*
 — urethrae, vide: bulbus penis
 *venae vorticosae *III. 221*
 — vestibuli *II. 169, III. 161, 190*
 bulla ethmoidalis *I. 30, 32, 33, 63, 64, II. 86*
 bursa infrapatellaris profunda *I. 206, 207*
 — ischiadica musculi glutei maximi *I. 289, 290*
 *musculi bicipitis subtendinea, *bursa bicipitoradialis I. 265*
 — — poplitei, vide: recessus subpopliteus
 — omentalis, vide etiam: *cavum proprium, recessus inferior, lienalis, superior, vestibulum bursae omentalis *II. 77, 78, 80, 81*
 — subcutanea infrapatellaris *I. 306*
 — — prepatellaris *I. 295, 306*
 — subfascialis prepatellaris *I. 296, 297, 298, 300, 307*
 — subtendinea musculi gastrocnemii lateralis *I. 304, 305*
 — — — medialis *I. 207, 303, 304, 305*
 — — — poplitei *I. 305*
 — suprapatellaris *I. 203, 206, 207, 299, 300*
 — synovialis trochlearis, *vagina synovialis trochlearum III. 233*
 — tendinis calcanei *I. 214, 303, 304, 305*
 — trochanterica musculi glutei maximi *I. 289, 290, 293, 294, III. 173*
- C**
- caecum, vide: cecum
 calcaneus *I. 5, 12, 136, 137, 138, III, 142, 143, 209, 213, 214*
 calcar avis *III. 16, 17, 18, 44*
 calvaria *I. 54, 55*
 calx *I. 312*
 calyx (-ces)
 — renalis *II. 122, 129, 141*
 — — majores *II. 126, 128, 141*
 — — minores *II. 128, 141*
 camera anterior bulbi, *camera oculi ant. III. 216, 217, 219, 220*
 — oculi, vide: camera anterior, posterior bulbi
 — posterior bulbi, *camera oculi post. III. 216*

canaliculus (-i)

- caroticotympanici, *foramina caroticotympanica I. 18
- chordae tympani III. 253
- cochleae III. 246
- lacrimalis, ductus lacrimalis III. 238
- mastoideus I. 18

canalis (-es)

- analis II. 61
 - caroticus I. 16, 18, 59, 60, II. 31, III. 263
 - carpi I. 185, 191, III. 141
 - centralis medullae oblongatae III. 55
 - - spinalis III. 89, 91
 - cervicis uteri II. 168, 169
 - condyloideus I. 13
 - diploici I. 69, 70
 - facialis, canalis facialis (Falloppii), canalis n. facialis I. 19, 20
 - femoralis I. 243
 - hyaloideus III. 225
 - hypoglossi, canalis n. hypoglossi I. 13, 14
 - incisivus I. 35, 61, 62, 63, II. 23, 86, III. 104
 - infraorbitalis I. 68
 - inguinalis I. 235, 240-242, II. 166
 - mandibulae II. 6, 28, 31, 33
 - musculotubarius I. 16
 - nervi facialis, vide: canalis facialis
 - - hypoglossi, vide: canalis hypoglossi
 - obturatorius I. 246, 247, II. 150
 - opticus, foramen opticum I. 22, 23, 58, 64, 65, 66, 68
 - palatinus major, canalis pterygopalatinus I. 67, II. 23
 - pterygoideus, canalis pterygoideus (Vidii) I. 23, 24
 - pterygopalatinus, vide: canalis palatinus major
 - pudendalis, *canalis pudendalis (Alcocki) I. 247, II. 135, 159
 - radialis dentis II. 11
 - rotundus, vide: foramen rotundum
 - sacralis I. 91, 92, 192, II. 175, 176
 - semicirculares III. 247
 - - anterior, canalis semicircularis sup. III. 106, 252, 255, 256
 - - lateralis III. 106, 255, 256
 - - posterior III. 255, 256
 - - superior, vide: canalis semicircularis anterior
 - * supinatorius I. 276
 - * tendinis musculi flexoris carpi radialis I. 191
 - vertebralis I. 159, 163, 165
- capitulum costae, fibulae, mallei, mandibulae, ossis metacarpalis, radii, stapedis, vide: caput
- fibulae, vide: caput fibulae
 - humeri I. 108, 109, 180
 - mallei, vide: caput mallei
 - mandibulae, vide: caput mandibulae
 - ossis metacarpalis, vide: caput ossis metacarpalis
 - radii, vide: caput radii
 - stapedis, vide: caput stapedis
 - ulnae, vide: caput ulnae
- capsula adiposa renis II. 52, 53, 81, 122, 134
- articularis I. 150, 151, 152, 155, 156, 164, 172, 173, 174, 175, 176, 177, 178, 179, 183, 190, 191, 198, 199, 203, 206, 207
 - - cricoarytenoidea II. 98
 - - cricothyroidea II. 98
 - externa nuclei lentiformis III. 15, 40, 41, 42, 47, 48, 65, 81
 - * extrema nuclei lentiformis III. 15, 40, 41, 42, 47, 48, 81
 - fibrosa renis, tunica fibrosa II. 125, 126, 134
 - interna nuclei lentiformis III. 15, 17, 25, 40, 41, 42, 45, 46, 47, 48, 58, 66, 81
 - * lentis III. 227
 - * nuclei lentiformis, vide: capsula externa, extrema, interna

capsula prostatae II. 138

- renis II. 134

caput, vide etiam: ossa, juncturae ossium, musculi capitis I. 1, III. 109, 110, 111

- angulare musculi quadrati labii superioris, vide: musculus levator labii superioris aequae nasi
 - breve musculi bicipitis brachii I. 231, 263, 264, 268, III. 129, 137
 - - - femoris I. 294, III. 167, 174
 - costae, capitulum costae I. 99, 100
 - epididymidis II. 141, 144, 145, 146, 147, 148, 149
 - femoris I. 2, 127, 128, 129, 198, 199
 - fibulae, capitulum fibulae I. 133, 134, 200, 201, 203, 205, 209, 305, 307, 308, 309, III. 176
 - humerale musculi flexoris carpi ulnaris I. 272
 - - - pollicis longi I. 272, III. 130
 - - - pronatoris teretis I. 272, III. 130
 - humeri I. 106, 107, 108, 175
 - infraorbitale musculi quadrati labii superioris, vide: musculus levator labii superioris
 - * laterale musculi flexoris hallucis brevis I. 315
 - - - gastrocnemii I. 201, 202, 292, 293, 294, 301, 302, 303, 304, 305, 307, 308, 309, III. 174, 176, 177
 - - - tricipitis brachii I. 267, 268, 269, III. 127
 - longum musculi bicipitis brachii I. 173, 174, 231, 263, 264, III. 129
 - - - femoris I. 293, 294, III. 167, 174
 - - - tricipitis brachii I. 266, 267, 268, 269, III. 127, 134, 136
 - mallei, capitulum mallei III. 250, 253
 - mandibulae, capitulum mandibulae I. 47, 48, 49, 152, 218, II. 14, 15
 - * mediale musculi flexoris hallucis brevis I. 315
 - - - gastrocnemii I. 202, 292, 293, 294, 301, 302, 303, 304, 305, III. 174, 177
 - - - tricipitis brachii I. 263, 264, 265, 266, 267, 269
 - nuclei caudati III. 16, 23, 40, 41, 47, 48, 62
 - obliquum musculi adductoris hallucis I. 315, III. 167
 - - - pollicis I. 281
 - ossis metacarpalis, capitulum ossis metacarpalis I. 190
 - pancreatis II. 45, 51, 52, 79
 - phalangis, trochlea phalangis I. 117, 190
 - profundum musculi flexoris pollicis brevis III. 131
 - radii, capitulum radii I. 181
 - stapedis, capitulum stapedis III. 250, 254
 - tali I. 138, 140, 143, 209
 - transversum musculi adductoris hallucis I. 315, III. 167
 - - - pollicis I. 281, III. 143
 - ulnae, capitulum ulnae I. 111, 184
 - ulnare musculi flexoris carpi ulnaris I. 272
 - - - pronatoris teretis I. 272, III. 130
 - zygomaticum musculi quadrati labii superioris, vide: musculus zygomaticus minor
- cardia, vide: ostium cardiacum
- *carina epiglottidis II. 95, 98, 105
- carpus, vide: articulationes, ossa manus, vaginae tendinum
- cartilago (-ines)
- alaris major II. 83, 84, 85, 86
 - - minor II. 84, 85
 - articularis I. 175, 212
 - arytenoidea II. 26, 88, 93, 94, 98, 99, 101
 - auriculae III. 243, 244, 245
 - corniculata, cartilago corniculata (Santorini) II. 26, 88, 93, 94, 98, 99, 103
 - costales I. 97, 170, III. 187
 - cricoidea I. 224, II. 33, 82, 91, 92, 97, 98, 99, 100, 101, 102, 103, 105, 106
 - cuneiformis II. 99
 - epiglottica II. 95, 98

- cartilago meatus acustici externi *III.* 213
 — nasalis accessoria, *cartilago sesamoidea nasi II.* 85
 — nasi *II.* 81, 85
 — — lateralis *II.* 84, 85, 86
 — septi nasi *II.* 83, 84
 — thyroidea *I.* 224, 225, 229, *II.* 28, 82, 89, 90, 97, 98, 99, 100, 101, 102, 103, 104, 105, 185, 186, *III.* 120, 122, 123, 186
 — tracheales *II.* 97, 98, 100, 101, 102, 103, 104, 105, 106, 107, 108
 — — *I.* *II.* 97
 — triticea *II.* 98, 99, 100, 101, 103
 — tubae auditivae *II.* 25, *III.* 263
 caruncula (-ae)
 — hymenales *II.* 171
 — lacrimalis *III.* 235, 238
 — sublingualis *II.* 22
 * — urethrales *II.* 139
 cauda epididymidis *II.* 146, 147, 148
 — equina *III.* 84, 86, 87, 93
 — helices *III.* 244, 245
 — nuclei caudati *III.* 43, 45, 46, 47, 48
 — pancreatis *II.* 1, 45, 46, 51, *III.* 155
 cavernae corporis cavernosi penis *II.* 161, 162
 cavitas glenoidalis *I.* 103, 105, 174
 cavum abdominis *II.* 80, 81
 — articulare *I.* 175, 183, 190, 199, 206
 — — articulationis intervertebralis *III.* 93
 — conchae *III.* 242, 244
 * — esophagi *II.* 26
 — infraglotticum *II.* 101, 105
 — laryngis *II.* 88, 101, 105
 — medullare *I.* 3, 6
 — nasi *I.* 64, *II.* 82, 86–88
 — —, paries lateralis *I.* 62, 63, *III.* 105, 233
 — oris *II.* 26, 29, 87, 88
 — — proprium *II.* 26, 86, 87, 88
 — pelvis *II.* 164
 — peritonei *II.* 73, 74, 75, 76, 77, 78, 79, 80
 — pharyngis *II.* 26, 34, 88
 — pleurae *II.* 120
 — — dextrum *III.* 152
 — — sinistrum *III.* 152
 * — proprium bursae omentalis *II.* 75, 77, 81
 — septi pellucidi *III.* 23
 — subarachnoideale *III.* 79
 — thoracis *III.* 150, 152, 153
 — tracheae *II.* 88, 105
 — tympani *I.* 19, 20, *III.* 246, 247, 251, 252, 253
 — uteri *II.* 168, 169
 caecum, *intestinum caecum II.* 1, 48, 49, 50, 57, 58, 74, 75, 78, *III.* 156, 157, 206
 — cupulare, *caecum cupulare III.* 254, 259
 — vestibulare, *caecum vestibulare III.* 254, 259
 cellula (-ae)
 — anteriores sinus ethmoidalis *I.* 31, 60, 69
 * — associationis retinae *III.* 228
 * — Claudiusi *III.* 261
 * — Deitersi *III.* 261
 — ethmoidales, vide: cellulae sinus ethmoidalis
 * — externae Heldi *III.* 261
 * — ganglii spiralis cochleae *III.* 261
 * — Henseni *III.* 261
 — mastoideae *I.* 19, 20, 70, *III.* 247
 * — motoricae nervi hypoglossi *III.* 54
 * — — spinalis *III.* 55
 * — Mülleri *III.* 228
 * — phalangeales internae Heldi *III.* 261
 * — pilaris externa *III.* 261
 * — — interna *III.* 261
 — (sinus) ethmoidalis, *cellulae ethmoidales II.* 86, 87, *III.* 229, 232, 239
 — — anteriores *I.* 31, 60, 69
 — — mediae *I.* 60, 64
 — — posteriores *I.* 33, 63, 69, 151, *III.* 98, 104
 * — unipolaris retinae *III.* 228
 cementum, *substantia ossca dentis II.* 11
 centrum semiorale *III.* 14, 16, 81
 — — tendineum diaphragmatis *I.* 248, 249, 250
 — — — perinei *II.* 172, 173, 175, *III.* 162
 cerebellum *II.* 181, *III.* 1, 2, 4, 27–31, 63, 70, 75, 80
 cerebrum *III.* 1–70
 cervix, vide: collum
 — uteri, vide etiam: portio supravaginalis, vaginalis cervicis uteri *II.* 164, 168
 chiasma opticum *II.* 181, 183, *III.* 8, 10, 21, 22, 26, 35, 41, 61, 63, 66, 72, 73, 97
 choana *I.* 64, *II.* 31, 82
 *cholecysta (gr.), vide: vesica fellea
 chorda (-ae)
 — obliqua *I.* 176, 178, 184
 — tendineae *II.* 193, 194, 196, 198, 203
 — tympani *III.* 102, 103, 106, 115, 253
 choroidea, *chorioidea III.* 216, 217, 218, 219, 220, 221, 228
 cilia *III.* 238
 circulus arteriosus cerebri, *circulus arteriosus (Willisi) III.* 73
 — — iridis major *III.* 218, 221
 — — — minor *III.* 218, 221
 * — — nervi optici *III.* 221
 — — vasculosus nervi optici *III.* 221
 * — venosus nervi optici *III.* 221
 circumferentia articularis *I.* 110, 112, 113
cisterna ambiens III. 89
 — cerebellomedullaris *III.* 75, 80, 124
 — chiasmatis *II.* 182, *III.* 80
 — chyli *III.* 192, 206
 — corporis callosi *III.* 80
 — interpeduncularis, *cisterna intercruialis III.* 80
 — subarachnoidealis *III.* 80
 — venae magnae *III.* 80
 claustrum *III.* 15, 40, 41, 42, 45, 46, 47, 48, 81
 clava, vide: tuberculum nuclei gracilis
 clavicula *I.* 101, 102, 171, 173, 174, 175, 222, 223, 224, 229, 230, 231, 232, 259, 260, 263, 264, *II.* 117, 185, 213, 217, *III.* 117, 118, 119, 120, 121, 122, 127, 128, 129, 134, 136, 152, 153, 186
 *cleidos (gr.), vide: clavicula
 clitoris *II.* 161, 172, 177, *III.* 161, 190
 clivus *I.* 13, 58, 61, 62, 156, *II.* 26, 31, 32, 88, *III.* 97
 cochlea *III.* 247, 255, 257
 colliculus (-i)
 — cartilaginis arytenoideae *II.* 93, 94
 — facialis *III.* 37
 — inferior *II.* 181, 184, *III.* 4, 21, 23, 25, 33, 37, 47, 58, 64, 101, 108, 186
 — — dexter *III.* 26
 — seminalis *II.* 140
 — superior *II.* 181, 184, *III.* 4, 16, 21, 23, 25, 26, 33, 37, 47, 49, 58, 96, 101
 collum (-i)
 — seu cervix, vide etiam: musculi, regiones colli *I.* 1, *III.* 109
 — anatomicum humeri *I.* 106, 107, 108
 — chirurgicum humeri *I.* 106, 108, 266, 268, 269
 — costae *I.* 100, 160
 — dentis *II.* 10
 — femoris *I.* 127, 128
 * — glandis clitoridis *II.* 177
 — — penis *II.* 141, 150, 157
 — mallei *III.* 251, 252
 — mandibulae *I.* 47, *II.* 14, 15
 — radii *I.* 112, 113, 181
 — scapulae *I.* 103, 104, 175
 — tali *I.* 139, 140
 — vesicae felleae *II.* 53, 65, 81
 colon ascendens *II.* 1, 48, 49, 50, 57, 58, 78
 — descendens *II.* 1, 48, 49, 50, 74, 75, 78
 — sigmoideum *II.* 1, 50, 74, 75, 78, 142, *III.* 157, 188

- colon transversum *II.* 1, 48, 49, 50, 74, 80, *III.* 156, 157
- *colpos (gr.), vide: vagina
- columna (-ae)
- anales, *columnae rectales (Morgagnii) II.* 62, 143
 - anterior medullae spinalis, vide etiam: cornu anterius *III.* 55, 89, 91
 - fornicis *III.* 10, 21, 23, 24, 41, 42, 45, 47, 48, 61, 72
 - posterior medullae spinalis, vide etiam: cornu posterius *III.* 89, 91
 - *rectales*, vide: columnae anales
 - renales, *columnae renales (Bertini) II.* 126
 - rugarum *II.* 172
 - vertebralis *I.* 74, 153
- commissura anterior *III.* 4, 10, 20, 21, 42, 45, 48, 56, 61, 64, 65, 72
- — telencephali *II.* 181
 - fornicis, *commissura hippocampi III.* 16
 - habenularum *III.* 21, 23, 37, 43, 47
 - *hippocampi*, vide: commissura fornicis
 - labiorum oris *II.* 2
 - — pudendi anterior *II.* 171
 - — — posterior *II.* 171
 - posterior *III.* 21, 36, 43, 47
 - — telencephali *II.* 184
- * — valvae ileocecalis, *commissura valvulae coli seu ileocaecalis II.* 58
- concha nasalis inferior *I.* 45, 46, 62, 64, 65, *II.* 26, 82, 86, 87, 88, *III.* 238
- — media *I.* 30, 31, 32, 33, 62, 64, *II.* 26, 82, 86, 87, 88
 - — superior *I.* 62, *II.* 26, 86, 87, 88
- condylus humeri *I.* 109
- lateralis femoris *I.* 127, 129, 130, 135, 203, 205, 209
 - — tibiae *I.* 133, 134, 135, 209
 - medialis femoris *I.* 127, 128, 130, 203, 204, 205, 207
 - — tibiae *I.* 133, 134, 135, 209
 - occipitalis *I.* 14, 59, 60
- confluens sinuum *III.* 75, 76, 77
- *coni retinae *III.* 228
- *conjugata anatomica *I.* 125
- * — diagonalis *I.* 126
 - * — vera (diametrum mediana) *I.* 125, 126
- conjunctiva, vide: tunica conjunctiva
- connexus intertendineus, *junctionum I.* 283
- conus arteriosus seu infundibulum *II.* 190, 194, 216
- elasticus *II.* 99, 102, 103, 105
 - medullaris *III.* 82, 84, 86
- cor *II.* 189—217
- corium *III.* 267, 268
- cornea *III.* 216, 217, 219, 220, 221, 223
- cornu anterius medullae spinalis, vide etiam: columna anterior *III.* 55, 90
- — ventriculi lateralis *III.* 15, 16, 17, 23, 24, 40, 45, 47, 48, 68, 69, 70, 81
 - coccygeum *I.* 93, 94
 - inferius cartilaginis thyroideae *II.* 89, 90, 97, 98, 100, 101
 - — hiatus sapheni, *cornu inf. fossae oralis I.* 240, 243, 295
 - — ventriculi lateralis *III.* 15, 16—19, 24, 43, 44, 45, 46, 47, 48, 68, 69, 70, 81
 - laterale medullae spinalis *III.* 90
 - majus ossis hyoidei *I.* 51, 229, *II.* 23, 28, 31, 32, 38, 97, 98, 99, 100, 101, 102, 103, 186, 187, *III.* 108
 - minus ossis hyoidei *I.* 51, 225, *II.* 97, 98, 99, 100, 101, 102, 103, 186
 - posterius medullae spinalis, vide etiam: columna posterior *III.* 90
 - — ventriculi lateralis *III.* 15, 16, 17, 68, 69, 70
 - sacrale *I.* 89, 90, 91
 - superius cartilaginis thyroideae *II.* 31, 89, 90, 97, 98, 99, 100, 101, 102, 103
 - — hiatus sapheni, *cornu sup. fossae oralis I.* 240, 243, 295
- corona ciliaris *III.* 221
- — dentis *II.* 7, 10
- * — glandis clitoridis *II.* 177
- — penis *II.* 150, 155, 157, 158
 - radiata *III.* 58, 59, 60, 63, 64, 66, 186
- corpus adiposum buccae, *corpus adiposum buccae (Bichat) II.* 36, 87
- * — — fossae ischio-rectalis *II.* 172
 - — — *genus*, vide: corpus adiposum infrapatellare
 - — infrapatellare, *corpus adiposum genus I.* 207
 - * — — laryngis *II.* 103, 104
 - * — — mammae *II.* 180
 - * — — mediastini superioris *II.* 212
 - * — — orbitae *II.* 87, *III.* 229, 233, 234, 239
 - * — — subcutaneum *II.* 169
- amygdaloideum, *nucleus amygdalae III.* 18, 42
- calcanei *I.* 141
 - callosum, vide etiam: genu, rostrum, splenium, truncus corporis callosi *II.* 181, *III.* 5, 14, 15, 16, 20, 40, 41, 42, 43, 46, 56, 57, 63, 80, 81, 109
 - cavernosum penis *II.* 140, *II.* 113, 150, 154, 155, 159, 160, 161, 162, 163, *III.* 162
 - — *urethrae*, vide: corpus spongiosum penis
 - ciliare *III.* 216, 217, 218, 219, 220, 221, 223, 224
 - * — claviculae *I.* 101
 - clitoridis *II.* 177
 - costae *I.* 100
 - epididymidis *II.* 145, 146, 148
 - femoris *I.* 127
 - fornicis *III.* 10, 21, 42, 43, 46, 81
 - geniculatum laterale *II.* 184, *III.* 10, 25, 26, 37, 43, 47, 64
 - — mediale *II.* 184, *III.* 10, 25, 26, 37, 43, 49, 64
 - * — glandulae sudoriferae *III.* 269
 - — incudis *III.* 250
 - linguae *II.* 21
 - luteum *II.* 168
 - mamillare *III.* 1, 4, 8, 10, 20, 21, 22, 35, 45, 56, 61, 64, 72, 95
 - mammae *II.* 179
 - mandibulae *I.* 47, *II.* 6
 - nuclei caudati *III.* 16, 42, 43, 62
 - ossis hyoidei *I.* 51, *II.* 186
 - — illi, *corpus ossis ilium I.* 118
 - — ischii, *corpus et r. sup. ossis ischii I.* 118, 119, 120
 - — metacarpalis *I.* 190
 - — phalangis *I.* 117
 - — — proximalis *I.* 190
 - — pubis *I.* 118
 - — sphenoidalis *I.* 65, 73, *II.* 23
 - pancreatis *II.* 45, 46, 51, 52, 77, 79, *III.* 155
 - penis *II.* 140, 150, 154, 157, *III.* 160
 - phalangis proximalis manus *I.* 190
 - pineale *II.* 181, 184, *III.* 4, 10, 21, 23, 36, 37, 47, 61
 - *restiforme*, vide: pedunculus cerebellaris inferior
 - spongiosum penis, *corpus cavernosum urethrae II.* 141, 113, 150, 154, 155, 156, 158, 160, 162, *III.* 162
 - sterni *I.* 95, 96, 97, 171
 - striatum *III.* 40, 62
 - trapezoideum *III.* 52
 - unguis *III.* 264
 - ventriculi *II.* 40, 41, 42, 43, *II.*
 - vertebrae *I.* 80, 83, 85, 159, 160, 163, 164, 165, *III.* 92, 93
 - vesicae felleae *II.* 51, 53, 65
 - — urinariae *II.* 128, 130, 136, 138, 151
 - vitreum *III.* 216, 219, 220, 225, 228
- corpuseculum bulboideum, *corpuseculum bulboideum (Krausei) III.* 267
- lamellosum, *corpuseculum lamellosum (Vateri—Pacini) III.* 267
- * — lienale *II.* 74

- corpusculum renis, *corpusculum renis (Malpighii)*,
 vide: glomerulus
 — tactus, *corpusculum tactus (Meissneri) III*. 267
 cortex cerebelli *III*. 33
 — cerebri *III*. 11, 12, 79
 * — corticis renis (Hyll) *II*. 126
 — glandulae suprarenalis, *substantia corticalis II*. 188
 — hemispherii cerebelli *III*. 33
 * — insulae *III*. 81
 * — pili *III*. 268
 — renis, *substantia corticalis II*. 126
 — vermis cerebelli *III*. 33
 costa (-ae) *I*. 163
 — I. *I*. 97, 99, 171, 224, 225, 226, 257, 258, *II*. 117,
 118, 119, *III*. 120, 125, 148, 152, 153
 — II. *I*. 97, 99, 171, 226, *II*. 117, 118, 119, 120
 — III. *II*. 117, 118, 119, 120, 180
 — IV. *II*. 119, 120, 180
 — V. *I*. 100, *II*. 119, 120, 180
 — VI. *II*. 119, 120, 180
 — VII. *II*. 119, 120, 180
 — VIII. *II*. 119, 120
 — IX. *I*. 252, *II*. 119, 120
 — X. *II*. 117, 118, 119, 120, 134, *III*. 148
 — XI. *I*. 97, 98, 236, *II*. 117, 118, 119, 120, 134
 — XII. *I*. 12, 97, 98, 234, *II*. 118, 119, 120, 134,
III. 86
 cranium, vide etiam: basis, juncturae ossium, ossa,
 suturae cranii *I*. 1, 52–73
 — cerebrale, *neurocranium I*. 54, 55, 58
 — neonati *I*. 71, 72, 73
 — viscerale, *splanchnocranium I*. 61–65, 68
 crista (-ae)
 — ampullaris *III*. 262
 — anterior fibulae, tibiae, vide: margo anterior
 fibulae, tibiae
 — arcuata cartilaginis arytenoideae *II*. 94
 — capitis costae, *crista capiti costae I*. 100
 — conchalis *I*. 35, 42, 43, 63
 — ethmoidalis *I*. 35, 42, 63
 — frontalis *I*. 25
 — galli *I*. 30, 31, 32, 58, 61, 62, 63, 64, *II*. 26, 83,
 88, *III*. 98, 104, 231
 — iliaca *I*. 118, 119, 120, 194, 232, 251, 252, 287,
 288, 289, 290, *II*. 40, 73, 134, 135, 142, *III*. 188,
 206, 215
 — infratemporalis *I*. 23, 57
 — infrazygomata *I*. 34
 — interossea fibulae, radii, tibiae, ulnae, vide:
 margo interosseus
 — intertrochanterica *I*. 128
 — lacrimalis anterior *I*. 34, 65
 — — posterior *I*. 36, 65, 66
 — lateralis fibulae, vide: margo posterior
 — matricis unguis *III*. 264
 — medialis fibulae *I*. 134
 — musculi supinatoris, *crista supinatoria I*. 111
 — nasalis *I*. 42, 43, 64, *II*. 82
 — occipitalis externa *I*. 14
 — — interna *I*. 13
 — palatina *II*. 12, 13, 16
 * — pro concha nasali medio *I*. 63
 * — — superiori *I*. 63
 — sacralis articularis, vide: crista sacralis intermedia
 — — intermedia, *crista sacralis articularis I*. 89
 — — lateralis *I*. 89, 90
 — — mediana, *crista sacralis media I*. 89, 90, 92,
II. 176
 — sphenoidalis *I*. 23
 — supinatoria, vide: crista musculi supinatoris
 — supraventricularis *II*. 194, 204
 — tegmentalis *I*. 15, 18
 — terminalis *II*. 192, 193
 — transversa meatus acusticus interni *III*. 258
 — tuberculi majoris *I*. 108
 — — minoris *I*. 108
 crista tympanica *II*. 23
 — urethralis *II*. 140
 crus (-ra)
 —, vide: musculi, regiones cruris
 — anterior capsulae internae *III*. 47
 — — stapedis *III*. 254
 — anthelicis *III*. 242
 — breve incedis *III*. 250
 — cerebri, *pedunculus cerebri II*. 181, 184, *III*. 10,
 43, 46, 48, 49, 58, 64
 — clitoridis *II*. 169, 177, *III*. 161, 190
 — dextrum fasciculi atrioventricularis *II*. 201
 — — partis lumbalis diaphragmatis, *pars lumbalis*
diaphragmatis I. 248, *II*. 82, 117, *III*. 187
 — fornicis *III*. 17, 25, 47
 — helicis *III*. 242, 243, 244
 — intermedium diaphragmatis *I*. 248
 — laterale anuli inguinalis superficialis, *crus infe-*
rius anuli inguinalis subcutanei I. 235, 240, 243,
II. 149
 — — cartilaginis alaris majoris *II*. 84, 85
 * — — musculi cremasteris *I*. 241
 — longum incedis *III*. 250, 253
 — mediale anuli inguinalis superficialis, *crus supe-*
rius anuli inguinalis subcutanei I. 235, 240, 243,
II. 149
 — — cartilaginis alaris minoris *II*. 84, 85
 * — — musculi cremasteris *I*. 241
 — membranaceum ampullare *III*. 260
 — commune *III*. 259, 260
 — osseum commune *III*. 255, 256
 — penis *II*. 135, 140, 141, 155, 156, 159, *III*. 160
 — posterius capsulae internae *III*. 47
 — — stapedis *III*. 250, 252, 254
 — sinistrum fasciculi atrioventricularis *II*. 205
 — — partis lumbalis diaphragmatis, *pars lumbalis*
diaphragmatis I. 248, 250, *II*. 134
 cubitus, vide: fossa cubitalis, regio cubiti
 culmen *III*. 27, 28, 29, 30, 32
 cuneus *III*. 4, 5, 8, 9, 10
 cupula cochleae *III*. 255, 256, 257
 — cristae ampullaris *III*. 262
 — pleurae *II*. 117, 119, 120, 213, *III*. 148
 curvatura ventriculi major *II*. 40, 41, 42, 43, 44, 47,
 73, 76, 77, 78, 80
 — — minor *II*. 40, 41, 42, 43, 44, 80
 cuspidis anterior valvae atrioventricularis dextrae seu
 valvae tricuspidalis, *cuspidis ant. valvulae tricusp-*
idalis II. 192, 193, 194, 199
 — — — sinistræ seu valvae mitralis, *cuspidis*
ant. valvulae bicuspidalis seu mitralis II. 195,
 196, 197, 198, 199, 203
 — — — mitralis, vide: cuspidis anterior valvae atrio-
 ventricularis sinistræ
 — — — tricuspidalis, vide: cuspidis anterior valvae
 atrioventricularis dextrae
 — — — medialis valvulae tricuspidalis, vide: cuspidis sep-
 talis
 — — — posterior valvae atrioventricularis dextrae seu
 valvae tricuspidalis, *cuspidis post. valvulae tri-*
cuspidalis II. 192, 193, 199
 — — — sinistræ seu valvae mitralis, *cuspidis*
post. valvulae bicuspidalis II. 196, 197, 198, 199,
 203
 — — — mitralis, vide: cuspidis posterior valvae
 atrioventricularis sinistræ
 — — — tricuspidalis, vide: cuspidis posterior valvae
 atrioventricularis dextrae
 — — — septalis valvae atrioventricularis dextrae seu
 valvae tricuspidalis, *cuspidis med. valvulae tricusp-*
idalis II. 192, 193, 199
 — — — tricuspidalis, vide: cuspidis septalis valvae
 atrioventricularis dextrae
 * cuticula pili *III*. 268
 cutis *III*. 267, 268
 — mammae *II*. 180

cutis penis *II.* 150, 156, 162
 — scroti *II.* 118, 149
 cymba conchae *III.* 242
 *cysta (gr.), vide: vesica
 cytoarchitectura *III.* 49, 51, 55

D

declive *III.* 27, 28, 32
 decussatio nervorum trochlearium *III.* 38, 50
 — pedunculorum cerebellarium superiorum, *decussatio brachiorum conjunctivorum III.* 48
 — pyramidum *III.* 31, 35, 45, 46, 55
 dens (-tes) *II.* 8, 9
 — axis, *dens epistrophei I.* 77, 78, 79, 157, *II.* 36, *III.* 105
 — caninus *I.* 69, *II.* 5, 6, 7, 8, 9, 12, 14, 18, 30
 — — (deciduus) *II.* 16, 17, 18
 — decidui *II.* 16, 17, 18, 19
 — *epistrophei*, vide: dens axis
 — incisivi *I.* 69, *II.* 8, 9, 30
 — — *I.* *II.* 5, 6, 7, 12, 14, 18
 — — *II.* *II.* 5, 6, 7, 12, 14, 18, 23, 24
 — — (decidui) *I.* 73
 — — — lateralis *II.* *II.* 16, 17, 18
 — — — medialis *I.* *II.* 16, 17
 — molares *I.* 69, *II.* 8, 9, 30
 — — *I.* *II.* 5, 6, 12, 14, 18
 — — *II.* *II.* 5, 6, 12, 14, 18
 — — *III.*, dens serotinus seu *dens sapientiae *II.* 5, 6, 12, 14
 — — deciduus *I.* *II.* 16, 17, 18
 — — — *II.* *II.* 16, 17, 18
 — — permanentes *II.* 18, 20
 — — — *I.* *II.* 16, 17, 18
 — premolares *I.* 69, *II.* 8, 9, 30
 — — *I.* *II.* 5, 6, 7, 12, 14, 18, 23
 — — *II.* *II.* 5, 6, 7, 12, 14, 18
 * — sapientiae, vide: dens molaris *III.*
 — serotinus, vide: dens molaris *III.*
 dentinum, *substantia eburnea II.* 11
 dermis *III.* 267
 *diameter mediana aperturæ pelvis minoris inferioris *I.* 125, 126
 * — — — minoris superioris *I.* 125, 126
 — obliqua *I.* (dextra) *I.* 125
 — — *II.* (sinistra) *I.* 125
 — transversa *I.* 125
 diaphragma, vide etiam: crus dextrum, sinistrum, pars costalis, lumbalis, sternalis diaphragmatis *I.* 248, 249, 250, 321, *II.* 38, 50, 51, 52, 53, 73, 76, 81, 82, 109, 118, 119, 120, 122, 134, 185, 212, 213, 214, 216, *III.* 148, 151, 152, 153, 154, 155, 158, 187, 188, 191, 202, 206
 * — oris, vide etiam: musculus mylohyoideus *II.* 1
 — pelvis *II.* 154, 169, 173, 174
 — sellae *II.* 25, 182, 183
 — urogenitale *II.* 135, 151, 151, 155, 156, 169, 173, *III.* 162, 189
 diaphysis *I.* 2, 9
 diencephalon *III.* 21, 22
 digitationes hippocampi, vide: pes hippocampi
 digitus (-i)
 — annularis seu digitus manus *IV.* *I.* 278
 — manus seu pedis, vide etiam: articulationes, ossa, tendines manus seu pedis
 — medius seu digitus manus *III.* *I.* 278
 — minimus manus seu digitus manus *V.* *I.* 278
 — — pedis seu digitus pedis *V.* *I.* 312
 *dimensiones pelvis femininæ *I.* 125, 126
 diploe *III.* 79
 discus articularis articulationis radioulnaris distalis *I.* 188
 — — sternoclavicularis *I.* 171
 — — temporomandibularis *I.* 152

discus interpubicus, *lamina fibrocartilaginea interpubica I.* 192
 — intervertebralis, *fibrocartilago intervertebralis I.* 153, 159, 161, 161, 166, 193, 234, *III.* 90
 — nervi optici, *papilla n. optici III.* 216, 222
 *distantia cristarum *I.* 125
 * — spinarum *I.* 125
 dorsum, vide: musculi, regiones dorsi
 — linguae *II.* 21, 26, 28, 88
 — manus *I.* 283
 — nasi *II.* 2
 — pedis *III.* 180
 — sellae *I.* 22, 24, 61, 62, 63, 151, 154, 155, *II.* 26, 32, 86, 88, 182
 ductuli biliferi interlobulares, *ductus biliferi II.* 69
 — efferentes testis *II.* 147
 — epoophori transversi *II.* 168
 — excretorii glandulae lacrimalis *III.* 237
 — prostatici, *ductus prostatici II.* 140
 ductus (-us)
 — alveolaris *II.* 121
 — arteriosus, *ductus arteriosus (Botalli) II.* 211
 — choledochus *II.* 1, 46, 52, 53, 79, 81, *III.* 154, 155
 — cochlearis *III.* 246, 254, 259, 260, 261
 — cysticus *II.* 52, 53, 65, *III.* 154, 155
 — deferens *I.* 244, *II.* 75, 135, 136, 137, 138, *III.* 112, 146, 147, 148, 151, 152, 153, *III.* 158
 — —, pars pelvina *I.* 244
 — ejaculatorius *II.* 137, 141, 143, 152, 153
 — endolymphaticus, *ductus endolymphaticus III.* 246, 259, 260
 — epididymidis *II.* 147
 — epoophori longitudinalis *II.* 168
 — excretorius glandulae bulbourethralis *II.* 141, 142
 — — vesiculae seminalis *II.* 152, 153
 — hepaticus *II.* 51, 52, 53, 65, 81, *III.* 154, 155
 — lactiferi *II.* 180
 — nasolacrimalis *II.* 86, *III.* 238
 — pancreaticus, *ductus pancreaticus (Wirsungii), ductus pancreaticus major II.* 1, 46, 52, 53
 — — accessorius, *ductus pancreaticus accessorius (Santorini) II.* 46, 52, 53
 — parotideus *II.* 35, 87, *III.* 113
 — reuniens, *ductus reuniens (Henseni) III.* 254, 259, 260
 — semicirculares *III.* 246
 — — anterior, *ductus semicircularis sup. III.* 254, 259, 260
 — — lateralis *III.* 157, 259, 260
 — — posterior *III.* 259, 260
 — — superior, vide: ductus semicircularis anterior
 — sublingualis *II.* 27
 — — major *II.* 22
 — — minor *II.* 22, 27
 — submandibularis, *ductus submaxillaris (Whartoni) II.* 22, 23, 27, 28, *III.* 115, 120, 121, 122
 — *submaxillaris*, vide: ductus submandibularis
 * — sudoriferi *III.* 267
 — thoracicus *II.* 117, *III.* 121, 187, 192, 201, 203, 201, 205
 — utriculosaccularis *III.* 259, 260
 — venosus, *ductus venosus (Arantii) II.* 211
 duodenum, vide etiam: pars ascendens, descendens, horizontalis, superior duodeni *II.* *I.* 15, 16, 49, 50, 51, 52, 53, 80, 81, *III.* 154, 155, 156, 157, 188, 206, 207, 213, 214, 215
 dura mater *I.* 154, 155, *III.* 95, 97, 108, 124
 — — encephali *II.* 87, 181, 182, *III.* 1
 — — spinalis, vide etiam: *endorachis *II.* 36, 68, *III.* 1, 85, 86, 92, 124

E

eminentia arcuata partis petrosae ossis temporalis *I.* 16, 17, *III.* 252

- eminentia carpi radialis III.* 139, 141
 — — *ulnaris III.* 139
 — *collateralis III.* 19, 81
 — *conchae III.* 245
 — *fossae triangularis III.* 245
 — *iliopubica, eminentia iliopectinea I.* 119, 120
 — *intercondylaris, eminentia intercondyloidea I.* 133, 134, 135
 — *medialis fossae rhomboideae III.* 37
 — *pyramidalis III.* 106, 252, 254
emissarium, vide: vena emissaria
enamelum, substantia adamantina dentis II. 11
encephalon III. 2, 4, 6
endolympha III. 262
endometrium, vide: tunica mucosa uteri
**endorachis III.* 92, 93
endothelium camerae anterioris bulbi III. 220
ependyma III. 81
epicardium, vide: lamina visceralis pericardii serosi
epicondylus lateralis femoris I. 127, 128, 130, 200, 205, 206
 — — *humeri I.* 106, 108, 109, 177, 179, 180, 269, 270, 274, 275, III. 127
 — — *medialis femoris I.* 127, 128, 129, 130
 — — *humeri I.* 106, 108, 109, 176, 178, 179, 180, 261, 263, 265, 266, 267, 269, 270, 271, 272, 273, III. 129, 131, 137, 138, 139
epidermis III. 267
epididymis, vide etiam: caput, cauda, corpus epididymidis *I.* 246, *II.* III, III, III, III, III, III, III
epiglottis, vide etiam: cartilago epiglottica *II.* 21, 26, 31, 34, 38, 39, 88, 95, 96, 97, 99, 100, 101, 102, 103, 104, 105
epiorchium, vide: lamina visceralis tunicae vaginalis testis
epipyphsis I. 9
 — *distalis femoris I.* 3
 — *proximalis femoris I.* 2, 4
epistropheus, vide: axis
epithalamus III. 23
epithelium III. 268
 — *anterior corneae III.* 217
 * — *internum ductus cochlearis III.* 261
equator lentis, aequator lentis III. 219, 220, 226, 227
esophagus, oesophagus I. 248, 249, 250, *II.* I, 26, 28, 32, 33, 34, 37, 38, 39, 41, 42, 43, 44, 51, 52, 53, 73, 79, 96, 104, 109, 110, 117, 122, 187, III. 108, 122, 152, 153, 158, 187, 188, 191, 201, 202, 206, 213
excavatio rectouterina, excavatio rectouterina (cavum Douglasi) II. 80, 164, 165, 167
 — *rectovesicalis II.* 142, 143
 — *vesicouterina II.* 80, 164, 165
extremitas acromialis claviculae I. 101, 102
 — *anterior lienis, extremitas inf. II.* 70, 71
 — (*corporis*), vide: membrum
 — *inferior lienis*, vide: extremitas anterior
 * — — *radii I.* 113
 — — *renis II.* 123, 124, 125, 126
 — — *testis II.* 144
 — *posterior lienis, extremitas sup. II.* 70, 71
 — *sternalis claviculae I.* 101, 102
 — *superior lienis*, vide: extremitas posterior
 — — *renis II.* 123, 124, 125
 — — *testis II.* 144, 145
 — *tubaria ovarii II.* 165
 — *uterina ovarii II.* 165

F

facies (-es)
 —, vide: regiones faciei
 — *anterior corneae III.* 217
 — — *glandulae suprarenalis II.* 188
 — — *iridis III.* 220
 — — *lateralis humeri I.* 108
 — — *facies anterior lentis III.* 216, 226
 — — *maxillae I.* 34
 — — *medialis humeri I.* 108
 — — *ossis sacri*, vide: facies pelvina
 — — *pulpebrae superioris III.* 235
 — — *partis petrosae ossis temporalis, facies cereb-
 ralis I.* 16
 — — *patellae I.* 131
 — — *prostatae II.* 136
 — — *radii, facies volaris I.* 112
 — — *renis II.* 123, 124
 — — *ulnae, facies volaris I.* 110
 — *articularis acromialis claviculae I.* 102
 — — *acromii I.* 104
 — — *anterior dentis axis I.* 78
 — — *arytenoidea cartilaginis cricoideae II.* 9, 92, 102
 — — *calcanea anterior tali I.* 140, 143
 — — — *media tali I.* 140
 — — — *posterior tali I.* 140
 — — *capitis costae, facies articularis capituli cost-
 ae I.* 100
 — — — *fibulae, facies articularis capituli fibulae I.* 133
 — — *carpea radii I.* 112
 — — *cricoidea cartilaginis arytenoideae II.* 89, 90, 93
 — — — *thyroideae II.* 89, 90
 — — *cuboidea calcanei I.* 142, 143, 209
 — — *cuneiformis intermedius I.* 145
 — — — *lateralis I.* 145
 — — — *medialis I.* 145
 — — *distalis femoris I.* 203
 — — — *ossis cuboidei I.* 147
 — — *fibularis tibiae I.* 134
 * — — *incudis III.* 250
 — — *inferior atlantis I.* 76
 — — — *vertebrae I.* 86
 * — — *mallearis incudis III.* 250
 * — — *mallei III.* 250
 — — *malleoli fibulae I.* 134
 — — *medialis ossis cuneiformis II. I.* 147
 — — *navicularis tali I.* 140
 — — *patellae I.* 132
 — — *posterior dentis axis I.* 77, 78, 79, 156
 — — *proximalis (calcanea) ossis cuboidei I.* 144, 147, 148, 149
 — — — (*talaris*) *ossis navicularis I.* 144, 212
 — — *sternalis claviculae I.* 102
 — — *superior axis, facies articularis sup. epis-
 trophei I.* 77, 78, 79, 156
 — — — *ossis coccygis I.* 93
 — — — *tibiae I.* 134, 135, 208
 — — — *vertebrae I.* 80, 82, 83, 87
 — — *talaris anterior calcanei, facies articularis
 ant. I.* 141, 212
 — — — *media calcanei, facies articularis media
 I.* 141, 212
 — — — *ossis navicularis I.* 144, 212
 — — — *posterior calcanei, facies articularis post-
 I.* 141, 143, 212
 — — *thyroidea cartilaginis cricoideae II.* 91, 92, 102, 106
 — — *tuberculi costae I.* 100
 — *auricularis ossis coxae I.* 119, 120
 — — *sacri I.* 90, III. 189
 — *buccales dentium II.* 14
 — *cerebralis alae majoris ossis sphenoidalis I.* 24
 — — *partis squamosae ossis temporalis I.* 16, 17
 — *colica lienis II.* 71
 — *contactus dentium II.* 10, 12
 — *convexa cerebri*, vide: facies superolateralis
 — *costalis pulmonis II.* 109, 110, 115
 — — — *dextri II.* 115
 — — *scapulae I.* 104, 173
 — *diaphragmatica cordis II.* 191

- facies diaphragmatica hepatis, facies superior hepatis*,
 vide etiam: partes anterior, dextra, posterior, si-
 nistra faciei diaphragmaticae hepatis *II.* 63,
 64, 73
 — — lienis *II.* 70
 — — pulmonis *II.* 111, 112
 — dorsalis ossis sacri, *facies post.* *I.* 89
 — — radii, vide: facies posterior radii
 — — scapulae *I.* 103, 105, 172
 — — ulnae, vide: facies posterior
 — gastrica lienis *II.* 71
 — glutea ossis ilii *I.* 118
 — inferior cerebri *III.* 8, 9, 13
 — — hemispherii cerebelli *III.* 29, 31
 — — — cerebri *III.* 10
 — — hepatis, vide: facies visceralis
 * — lobi frontalis *III.* 10
 — — partis petrosae *I.* 18
 — infratemporalis alae majoris *I.* 34, 73
 — — maxillae *I.* 34
 * — lateralis cavi nasi *I.* 61, 62, 63
 — — femoris *I.* 128
 — — fibulae *I.* 133
 — — ossis zygomatici, *facies malaris I.* 39
 — — testis *II.* 145, 148
 — — lingualis dentium *II.* 14
 — lunata *I.* 118, 198, 245
 — malaris ossis zygomatici, vide: facies lateralis
 — malleolaris lateralis tali *I.* 139, 143
 — — medialis tali *I.* 139
 — masticatoria dentium *II.* 12
 — maxillaris, *facies sphenomaxillaris I.* 23
 — medialis cartilaginis arytenoideae *II.* 93
 — — femoris *I.* 128, 129
 * — — hemispherii cerebri *III.* 5, 10, 13
 — — lobi frontalis *III.* 21
 — — pulmonis dextri, *facies mediastinalis pulmonis*
dext. *II.* 112, 116
 — — — sinistri, *facies mediastinalis pulmonis sin.*
II. 111
 * — thalami *III.* 10
 — — tibiae *I.* 133
 — mediastinalis pulmonis, vide: facies medialis
 — nasalis maxillae *I.* 35
 — orbitalis alae majoris *I.* 23, 66
 — — maxillae *I.* 34, *II.* 5
 — — ossis frontalis *I.* 60
 — — — zygomatici *I.* 40
 — patellaris femoris *I.* 127, 130, 203
 — pelvina ossis sacri, *facies anterior I.* 88
 — poplitea femoris, *planum popliteum I.* 128, 202,
 294, 303, 304, 305
 — posterior cartilaginis arytenoideae *II.* 93
 — — corneae *III.* 220
 — — glandulae suprarenalis *II.* 188
 — — humeri *I.* 106
 — — lentis *III.* 216, 223, 226
 — — ossis sacri, vide: facies dorsalis
 — palpebrarum *III.* 237
 — — superioris *III.* 237
 — — partis petrosae *I.* 17
 — — prostatae *II.* 137
 — — radii, *facies dorsalis I.* 113
 — — renis *II.* 125
 — — tibiae *I.* 134
 — — ulnae, *facies dorsalis I.* 111
 — pulmonalis cordis, *margo obtusus cordis *II.*
 190, 191
 — renalis glandulae suprarenalis, *basis gl. supra-*
renalis II. 188
 — — lienis *II.* 71
 — sacropelvina ossis ilii *I.* 119
 — sphenomaxillaris ossis sphenoidalis, vide: facies
 maxillaris
 — sternocostalis cordis *II.* 190
 — superior hemispherii cerebelli *III.* 27, 29, 31
facies superior hepatis, vide: facies diaphragmatica,
 partes anterior, dextra, posterior, sinistra
 — — trochleae tali *I.* 139
 — superolateralis cerebri, *facies convexa cerebri*
III. 3, 7, 12
 — symphysialis, *facies symphysos I.* 119, 120, 299, 300
 — temporalis ossis sphenoidalis *I.* 23
 — — — zygomatici *I.* 40
 — visceralis hepatis, *facies inf.* *II.* 63, 73, 76, 78
 — — lienis *II.* 71
 falx cerebelli *III.* 80
 — cerebri *II.* 181, *III.* 77, 78, 79, 80, 97, 231
 — septi, vide: valvula foraminis ovalis
 fascia (-ae)
 — antebrachii, *fascia antibrachii I.* 261, 262
 — axillaris *I.* 259, 260
 — brachii *I.* 261, 262
 — cervicalis, *fascia colli*, vide etiam: lamina pre-
 trachealis, prevertebralis, superficialis fasciae
 cervicalis *I.* 227, 228, 229, *III.* 117, 118
 — —, lamina pretrachealis, vide: lamina pretra-
 chealis
 — —, — prevertebralis, vide: lamina prevertebralis
 — —, — superficialis, vide: lamina superficialis
 — clavipectoralis, *fascia pectoralis prof., *fascia*
coracoclavipectoralis I. 260, *II.* 180
 — colli, vide: fasciae cervicalis
 — — media, vide: lamina pretrachealis fasciae
 cervicalis
 — — profunda, vide: lamina prevertebralis fasciae
 cervicalis
 — — superficialis, vide: lamina superficialis fasciae
 cervicalis
 — coracoclavipectoralis, vide: fasciae clavipectoralis
 — cremasterica *II.* 148, 149, 150
 — cribrosa, *lamina cribrosa I.* 240, 295
 — cruris *I.* 301, 302, 303, 306, 310, *III.* 177
 — —, lamina profunda *I.* 303, *III.* 177
 — —, — superficialis *I.* 301, 302, 306
 — diaphragmatis pelvis inferior *II.* 169, 176
 — — — superior *II.* 135, 169, 176
 — — urogenitalis inferior *II.* 135, 154, 169, 172,
 173, 176
 — — — superior *II.* 135, 151, 169, 176
 — dorsalis pedis *I.* 306
 — endothoracica *III.* 152, 153
 — iliaca *I.* 245, 296, 297, *II.* 169
 — infraspinata *I.* 251, 252, 262
 — lata, vide etiam: tractus iliotalibialis *I.* 243, 245,
 287, 288, 289, 290, 295, 296, 297, *III.* 172, 173
 — lumbodorsalis, vide: fasciae thoracolumbalis
 — masseterica, *fascia parotideomasseterica I.* 216,
II. 87
 — musculi deltoidei *I.* 259, 260, 261, 262
 * — — pectoralis majoris profunda *I.* 259
 — — poplitei *I.* 303
 — — quadrati lumborum *II.* 134
 — — temporalis *II.* 87
 * — nucae profunda *II.* 36
 — obturatoria *I.* 246, 247, *II.* 161, 167, 169, 175
 — parotidea, *fascia parotideomasseterica I.* 216
 — parotideomasseterica, vide: fasciae masseterica,
 parotidea
 — pectinea *I.* 254, 296, 297
 — pectoralis, vide etiam: *fascia pectoralis super-*
ficialis I. 259
 * — — profunda, vide: fasciae clavipectoralis
 — — superficialis *I.* 260, 261, *II.* 180
 — pelvis *II.* 151
 — — parietalis *II.* 138, 151, 175, 176
 — — visceralis *II.* 151
 — penis profunda *II.* 154, 162
 — — superficialis *II.* 149, 150, 154, 156, 162
 — perinei superficialis *II.* 169
 — pharyngobasilaris *II.* 24, 32, 33
 * — prerenalis *II.* 131

- fascia prostatica II. 138, 151
 * — renalis II. 81, 131
 * — retroduodenalis II. 134
 * — retrorenalis II. 134
 — spermatica interna, *tunica vaginalis communis testis et funiculi spermatici* II. 144, 145, 146, 118, 119
 * — superficialis abdominis II. 148
 * — — membri superioris I. 260, 261
 — temporalis I. 216, 217, II. 35
 — —, lamina profunda I. 217
 — —, — superficialis I. 216, II. 35
 — thoracolumbalis, *fascia lumbodorsalis* I. 239, 252, 253, 254, III. 172
 — transversalis I. 237, 238, 241, 242, 243, 244, II. 81, 148, III. 148
- fasciculus (-i)
 — atrioventricularis, *fasciculus atrioventricularis (His)* II. 201, 205
 — corticothalamici, *radiatio thalami III. 61, 65
 — cuneatus, *fasciculus cuneatus (Burdachi)* III. 55, 85
 — gracilis, *fasciculus gracilis (Golli)* III. 55, 85
 — lateralis plexus brachialis III. 125, 127, 128, 129, 131, 136, 137
 * — longitudinales aponeurosis plantaris, *fibrae longitudinales* I. 312
 — — inferior III. 60
 — — medialis III. 48, 49, 50, 52, 53, 54
 — — superior III. 60
 — medialis plexus brachialis III. 125, 127, 128, 129, 131, 136, 137
 — posterior plexus brachialis III. 125, 127, 128, 129, 131, 136, 137
 — retroflexus, *fasciculus retroflexus (Mequert)* III. 43, 61
 — thalamocorticales, *radiatio thalami III. 61, 65
 — thalamomamillaris, vide: tractus mamillothalamicus
 * — transversa aponeurosis plantaris, *fibrae transversae* I. 312
 — uncinatus III. 59, 60
- fastigium III. 4, 68
- femur, vide: etiam caput, condyli, corpus, musculi femoris I. 127, 128, 129, 130, 199, 200, 201, 202, 205, 206, 207, 291, 299, 300, III. 167, 172, 209
- fenestra cochleae I. 20, III. 252, 255
 — vestibuli I. 20, III. 255
- fibra (-ae)
 — aponeurosis, vide: *fasciuli longitudinales, transversa aponeurosis
 — arcuatae cerebri III. 60
 — — externae ventrales III. 53, 54
 — — internae III. 55
 — circulares musculi ciliaris III. 219, 220
 * — decussatae musculi levatoris ani II. 174
 — intercurales anuli inguinalis superficialis I. 235, 240, 243, II. 149, III. 170
 — lentis III. 226, 227
 — meridionales musculi ciliaris III. 219, 220
 * — nervi trigemini III. 51
 * — nervosae terminales III. 267
 — obliquae tunicae muscularis ventriculi II. 43
 * — periolivares III. 53
 * — pontis longitudinales III. 43, 46, 51
 — — superficiales III. 52
 — — transversae III. 43, 45, 46
 * — pyramidales III. 53, 54
 — zonulares III. 220
- fibrocartilagineae intervertebrales, vide: disci intervertebrales
- fibula I. 133, 134, 200, 201, 202, 203, 204, 206, 209, 211, III. 167, 176
- filum (-a)
 — radicularia dorsalia nervi spinalis, *fila radicularia post.* III. 89
 — nervi abducentis III. 52
- fila radicularia nervi glossopharyngei III. 53
 * — — hypoglossi III. 54, 55
 — — oculomotorii III. 49
 — — spinalium, vide etiam: fila radicularia dorsalia, ventralia III. 87
 * — — trigemini III. 51
 * — — vagi III. 54
 — — ventralia nervi spinalis, *fila radicularia ant.* III. 89, 124
 — terminale III. 82, 86, 87
- fimbria hippocampi III. 15, 18, 19, 43, 45, 81
 — ovarica II. 167, 168
 — tubae uterinae II. 165, 167, 169
- fissura (-ae)
 — accessoria pulmonis, vide: fissura horizontalis
 — antitragohelicina III. 244, 245
 — cerebri lateralis, vide: sulcus lateralis
 — horizontalis cerebelli III. 28, 32
 — — pulmonis dextri, *fissura accessoria* II. 109, 112, 115, 117, 212
 — ligamenti torctis hepatis, *fossa sagittalis sin., fossa v. umbilicalis* II. 65, III. 207
 — longitudinalis cerebri, *fissura interhemisphaerica* III. 6, 7, 9, 14, 22, 40, 41, 42, 43, 44, 45, 46, 47, 48, 69, 81
 — mediana anterior medullae oblongatae III. 34, 82
 — — — spinalis III. 82, 89, 91
 — — posterior medullae oblongatae, vide: sulcus medianus posterior
 — obliqua pulmonis, *incisura interlobaris, fissura interlobaris* II. 109, 110, 111, 112, 115, 117, 118, 119, 212, III. 151
 — — — dextri, *incisura interlobaris dext.* II. 212
 — — — sinistri, *incisura interlobaris sin.* II. 212
 — orbitalis inferior I. 59, 64, 66, 67, 73, II. 87
 — superior I. 22, 23, 24, 60, 64, 66
 — parietooccipitalis, vide: sulcus parietooccipitalis
 — petrooccipitalis I. 59
 — petrosquamosa I. 15, 16, 20
 — petrotympanica, *fissura petrotympanica (Glaser)* I. 15, 20, III. 253
 — posterolateralis cerebelli III. 30, 32
 — prima cerebelli III. 28, 32
 — pterygoidea I. 24
 — pterygomaxillaris, *fissura pterygopalatina* I. 67
 — pterygopalatina, vide: fissura pterygomaxillaris
 — sphenopetrosa I. 59
 — transversa cerebri, *fissura telodiencephalica* III. 2, 67, 71
 — tympanomastoidea I. 15, II. 24
- flexura coli dextra II. 1, 48, 49, 50, 76, 77, 78, III. 154
 — sinistra II. 1, 48, 49, 50, 73, 74, 77, 78
 — duodeni inferior II. 45
 — superior II. 41, 42, 45
 — duodenojejunalis II. 1, 45, 49, 50, 52, 53, 74, 77, 78, 79, III. 155, 156, 157
 — perinealis recti II. 61
 * — rectoromana II. 61
 — sacralis recti II. 61
- flocculus cerebelli III. 2, 29, 30, 31, 35, 46
- flumina pilorum III. 266
- folia cerebelli, *gri cerebelli* III. 25
 — vermis cerebelli III. 27, 28, 32
- folliculus (-i)
 — linguales II. 21
 — lymphatici aggregati, *noduli lymphh. aggregati (Peger)* II. 56
 * — intestini II. 56
 — lienalis, *nodulus lymph. lienalis (Malpighii)* II. 72
 — solitarii, *noduli lymphh. solitarii* II. 54, 56
 — ovarici (oophori) vesiculosi, *folliculi vesiculosi (Graaf)* II. 168
- fonticulus anterior, *fonticulus frontalis (major)* I. 71, 72

- fonticulus anterolateralis*, vide: fonticulus sphenoidalis
 — *frontalis*, vide: fonticulus anterior
 — *major*, vide: fonticulus anterior
 — mastoideus, *fonticulus posterolateralis I.* 71, 73
 — *minor*, vide: fonticulus posterior
 — *occipitalis*, vide: fonticulus posterior
 — posterior, *fonticulus occipitalis (minor) I.* 72
 — *posterolateralis*, vide: fonticulus mastoideus
 — sphenoidalis, *fonticulus anterolateralis I.* 71
- foramen (-ina)
 — alveolaria *I.* 34
 — — posteriora *I.* 67, 68
 — apicis dentis *II.* 11
 * arteriae laryngeae superioris *II.* 97, 98, 100, 101, 103
 * caroticotympanica, vide: canaliculi carotico-tympanici
 * cartilagineus meatus acustici externi *III.* 243
 — cecum linguae *II.* 21, 26, 28, 30, 34, 88, 96
 — — *medullae oblongatae III.* 34, 82
 — — ossis frontalis *I.* 25, 58
 — *costotransversarium*, vide: foramen transversarium
 — epiploicum, *foramen epiploicum (Winslowi) II.* 76, 81
 — ethmoidale anterius *I.* 26, 60, 65, 66, 68
 — — posterius *I.* 26, 65, 66
 — frontale, vide: incisura frontalis
 — incisivum *I.* 59, *II.* 12, 13, 16
 — infraorbitale *I.* 34, 65, 66, 67, 68, *II.* 5, *III.* 233
 — interventriculare, *foramen interentriculare (Monroi) II.* 181, *III.* 10, 20, 21, 24, 45, 47, 68, 69, 70, 72, 80
 — intervertebrale *I.* 163, 164, 165, *III.* 150
 — ischiadicum majus *I.* 193, 194, *II.* 174, 175
 — — minus *I.* 193, 194
 — jugulare *I.* 58, 154, 155, 156, *II.* 32, *III.* 124, 247
 — lacrum *I.* 60
 — magnum, *foramen occipitale magnum I.* 14, 59, *II.* 33, *III.* 78, 247
 — mandibulae, *foramen mandibulare I.* 47, 49, 151
 — mastoideum *I.* 15, 17, 18, 59, 60
 — mentale *I.* 47, 50, *II.* 6
 * nasale *I.* 37
 — nervi laryngei superioris *II.* 97, 98, 100, 101, 103
 — nutritium *I.* 102, 106, 108, 110, 112, 128, 134
 — obturatum *I.* 118, 119, 120, 195, *II.* 142, 154, 174
 — *occipitale magnum*, vide: foramen magnum
 — *opticum*, vide: canalis opticus
 — ovale alae majoris ossis sphenoidalis *I.* 22, 58, 59, 60, 67, *III.* 263
 — — (septi interatrialis cordis) *II.* 210, 211
 — pedatum majus *I.* 41, 59, *II.* 12, 13, 16, 23
 — — minus *I.* 59, *II.* 12, 13, 16
 — parietale *I.* 28, 29
 — rotundum, *canalis rotundus I.* 22, 23, 24, 58, 65, 68, *II.* 31, *III.* 103
 — sacrale dorsale, *foramen sacrale post. I.* 89, 91, 168, 169, 194
 — — pelvinum, *foramen sacrale ant. I.* 88, 91, 120, 167, 246, 247
 — singulare *III.* 258
 — sphenopalatinum *I.* 63, 65, 67, 68
 — spinosum *I.* 22, 58, 59
 — stylomastoideum *I.* 18, 19, 20, 59, 60, 73
 — supraorbitale *I.* 26, 27, 66
 — transversarium, *foramen costotransversarium I.* 75, 76, 77, 78, 79, 80, *III.* 92
 — — atlantis *I.* 77, 78, 79, 80, 157
 — venae caevae *I.* 248, 250, *III.* 188, 206
 — vertebrale *I.* 84
 — zygomaticofaciale *I.* 39, 66
 — zygomaticoorbitale *I.* 40, 66
 — zygomaticotemporale *I.* 40
- forceps major, *pars occipitalis et temporalis radiationis corporis callosi III.* 57
- forceps minor, *pars frontalis et parietalis radiationis corporis callosi III.* 57
- formatio reticularis *III.* 49, 50, 51, 53, 54
- fornix, vide etiam: columna, corpus, crus fornicis *II.* 181, *III.* 4, 5, 16, 20, 45, 56
 — conjunctivae *III.* 239
 — — inferior *III.* 237
 — — superior *III.* 237
 — sacci lacrimalis *III.* 238
 — vaginae *II.* 164
 * — — posterior *II.* 80
- fossa (-ae)
 — acetabuli *I.* 118, 199, 245
 — articularis (acetabuli) *I.* 199
 — axillaris *I.* 260, *III.* 125, 126, 127, 128, 136, 137
 — canina *I.* 34, *II.* 5
 * cerebellaris ossis occipitalis *I.* 13
 * cerebralis ossis occipitalis *I.* 13
 — *cerebri lateralis*, vide: fossa lateralis cerebri
 — condyloidea *I.* 14, 59
 — coronoidea *I.* 108, 180, 183
 — cranii anterior *I.* 58, *III.* 78, 97
 — — media *I.* 58, *III.* 78, 97, 247
 — — posterior *I.* 58, *III.* 78, 109, 247
 — cubitalis *III.* 138
 — digastrica *I.* 49
 — glandulae lacrimalis *I.* 26
 — hyaloidea *III.* 220, 225
 — hypophysialis, *fossa hypophysiosa I.* 22, 58, 62, 151, *II.* 26, 88, 182, *III.* 104, 106
 — iliaca *I.* 119
 — *iliopectinea*, vide: fossa incisiva
 — incisiva, *fossa iliopectinea I.* 298
 — infraspinata *I.* 103, 105
 — inguinalis lateralis, *fovea inguinalis lat. I.* 238, 244, 246, *II.* 135, *III.* 148
 — — medialis, *fovea inguinalis med. I.* 238, 244, 246, *II.* 135, *III.* 148
 — intercondylaris femoris, *fossa intercondyloidea I.* 128, 130
 — *intercondyloidea femoris*, vide: fossa intercondylaris
 — — *tibiae*, vide: area intercondylaris
 — interpeduncularis, *fossa interpeduncularis (Tarini) III.* 8, 21, 22, 35, 46, 80
 — ischiorectalis *II.* 135, 169, *III.* 162
 — jugularis *I.* 18, 59, *III.* 263
 — lateralis cerebri, *fossa cerebri lat. (Sylvii) III.* 2, 15, 16, 62, 71
 — mandibularis ossis temporalis *I.* 15, 18, 20, 59, *II.* 27, 33
 — naviculares urethrae, *fossa navicularis urethrae (Morgagnii) II.* 140, 143
 — — *vestibuli vaginae*, vide: fossa vestibuli vaginae
 — olecrani *I.* 106, 109, 183
 — ovalis *II.* 192, 193, 204
 — — *fasciae latae*, vide: hiatus saphenus
 — poplitea *I.* 292, 293, 301, 302
 — pterygoidea *I.* 24
 — pterygopalatina *I.* 65, 67, 68, *II.* 23, 33, *III.* 101
 — radialis humeri *I.* 108, 180
 — rhomboidea, vide etiam: eminentia medialis, fovea inferior et superior, sulcus medianus fossae rhomboideae *III.* 37, 109, 124
 — sacci lacrimalis *I.* 65, 66, 68
 — *sagittalis sinistra hepatis*, vide: fissura ligamenti teretis hepatis
 * scalenotrachealis *I.* 224
 — scaphoidea *I.* 24, 60, *III.* 244
 — subarcuata *I.* 17
 — supraclavicularis major, vide: trigonum omoclaviculare
 — — minor *III.* 116, 117, 118, 119, 120, 121, 122, 123

- fossa supraspinata *I.* 103, 105
 — supratonsillaris *II.* 29
 — supravescicalis, *fovea supravescicalis I.* 238, 244, *II.* 135, *III.* 148
 — temporalis *II.* 33
 — triangularis auriculæ *III.* 242, 244
 — trochanterica *I.* 128, 129
 — *venae umbilicalis*, vide: fissura ligamenti teretis
 — vesicae felleae *II.* 48, 51, 65, 68
 — vestibuli vaginae, *fossa navicularis vestibuli vaginae II.* 171
 fossula fenestreae cochleae *I.* 19, *III.* 10
 — — vestibuli *I.* 19, *III.* 254
 — petrosa *I.* 18
 fovea (-ae)
 — articularis superior atlantis *I.* 75, 157
 — capitis femoris *I.* 128, 129
 — *capituli radii I.* 112, 113, 181
 — centralis maculae retinae *III.* 216, 222
 — costales *I.* 158
 — — inferior *I.* 82.
 — — superior *I.* 82
 — — transversalis *I.* 82, 83, 158
 — dentis atlantis *I.* 75, 76
 — inferior fossae rhomboideae, *fovea caudalis III.* 37, 44
 — *inguinalis*, vide: fossa inguinalis
 — oblonga cartilaginis arytеноидеае *II.* 94
 — pterygoidea *I.* 47, 220
 — sublingualis *I.* 49
 — superior fossae rhomboideae, *locus coeruleus foveae caudalis III.* 37
 — *supravescicalis*, vide: fossa supravescicalis
 — triangularis cartilaginis arytеноидеае *II.* 94
 — trochlearis *I.* 26
 foveola (-ae)
 — *ethmoideae I.* 26
 — granulares, *foveolae granulares (Pacchioni) I.* 29, 55
 * — radialis *I.* 276, 277
 frenulum labii inferioris oris *II.* 29
 — — superioris oris *II.* 29
 — linguae *II.* 22
 — preputii *II.* 154, 157
 — veli medullaris anterioris *II.* 184
 frons *I.* 54
 fundus uteri *II.* 164, 166, 167, 170
 — ventriculi *II.* 1, 40, 41, 42, 43, 44, *III.* 154
 — vesicae felleae *II.* 47, 53, 65, 76
 — — urinariae *II.* 136, 137, 138, 139, 151
 funiculus anterior *III.* 34, 55, 89, 91
 — lateralis *III.* 34, 37, 55, 89
 — posterior, vide: fasciculus cuneatus et fasciculus gracilis
 * — separans *III.* 37
 — spermaticus *I.* 235, 237, 240, 241, 242, 243, 245, *II.* 144, 145, 149, 150, *III.* 158, 159, 170, 171

G

- galea aponeurotica *I.* 217
 ganglion (-ia)
 * — autonoma capitis *III.* 103
 — celiacum, *ggl. coeliacum dext. et sin. III.* 187, 188, 191
 — *cervicale inferius*, vide: ganglion cervicothoracicum
 — — medium *III.* 121, 122, 123, 125, 186, 187
 — — superior *II.* 36, *III.* 108, 109, 121, 122, 123, 186
 — cervicothoracicum seu ganglion stellatum, *ggl. cervicale inf. III.* 125, 186, 187
 — ciliare *III.* 100, 101, 102
 — *coeliacum*, vide: ganglion celiacum
 — *extracraniale nervi glossopharyngei*, vide: ganglion inferius
 — *extracraniale nervi glossopharyngei*, vide: ganglion inferius
 — inferius nervi glossopharyngei, *ggl. petrosum, ggl. extracraniale III.* 186
 — — vagi, *ggl. nodosum III.* 108, 109, 122, 186
 — *intracraniale nervi glossopharyngei*, vide: ganglion superius
 — *jugulare nervi vagi*, vide: ganglion superius
 — *nodosum nervi vagi*, vide: ganglion inferius
 — oticum *III.* 103
 — *petrosum nervi glossopharyngei*, vide: ganglion inferius
 — pterygopalatinum, *ggl. sphenopalatinum III.* 102, 103, 105, 186
 — *semilunare*, vide: ganglion trigeminale
 — *sphenopalatinum*, vide: ganglion pterygopalatinum
 — spinale *III.* 83, 89, 90, 91, 92, 96
 — — cervicale (C. 2.) *III.* 124
 — — lumbale (L. 3.) *III.* 86
 — — — (L. 5.) *III.* 86
 — — thoracicum (Th. 1.) *III.* 85
 — stellatum, vide: ganglion cervicothoracicum
 — submandibulare, *ggl. submandibulare III.* 103, 115
 — *submandibulare*, vide: ganglion submandibulare
 — superius nervi glossopharyngei, *ggl. intracraniale III.* 96
 — — — vagi, *ggl. jugulare III.* 96, 108, 186
 — thoracicum, vide: ganglion trunci sympathici
 — trigeminale, *ggl. semilunare (Gasserii) II.* 27, *III.* 95, 96, 97, 98, 99, 100, 101, 102, 106, 186
 — trunci sympathici *III.* 90, 150
 — — — thoracici, *ggl. trunci sympathici thoracales (Th.) III.* 150
 — — — — (Th. 2.) *III.* 152
 — — — — (Th. 3.) *III.* 152
 gaster, vide: ventriculus
 geniculum nervi facialis *III.* 103, 252
 genu, vide: articulatio, regiones genus
 — capsulae internae *III.* 47
 — corporis callosi *II.* 181, *III.* 4, 10, 11, 16, 20, 21, 25, 47, 48, 56, 57, 72, 96
 — internum nervi facialis *III.* 38
 * — occipitale radiationis opticae *III.* 63
 * — temporale radiationis opticae *III.* 63
 gingiva *II.* 11, 29
 glabella *I.* 27
 glandula (-ae)
 — arcularis, *gl. arcularis mammae (Montgomeryi) II.* 178, 179
 — buccales *II.* 4
 — bulbourethralis, *gl. bulbourethralis (Cowperi) II.* 140, *III.* 142, 143, 151, 154
 * — labiales inferiores *II.* 4
 * — — superiores *II.* 4
 — lacrimalis *III.* 98, 231, 233, 237
 — lingualis anterior, *gl. linguae II.* 22
 — mammaria *II.* 180
 — palatinae *II.* 30
 — parathyroidea *II.* 187, *III.* 108
 — — inferior *II.* 187
 — — superior *II.* 187
 — parotis *parotis *I.* 227, 228, *II.* 27, 35, 36, 87, *III.* 113, 118, 119, 120, 123
 — — accessoria *II.* 35
 — pituitaria, vide: hypophysis
 — sebacea *III.* 268
 — sine ductibus, *ggl. endocrinales II.* 181—188
 — sublingualis *II.* 22, 23, 27, 28
 * — —, pars major *II.* 22
 * — —, — minor *II.* 22
 — submandibularis, *gl. submandibularis I.* 227, 228, *II.* 23, 27, 28, 35, *III.* 107, 118, 119, 123
 — *submandibularis*, vide: glandula submandibularis
 — sudoriferae *III.* 267
 — suprarenalis *II.* 134, 188
 — — dextra *II.* 79, 122, 188, *III.* 158, 191

- glandula suprarenalis sinistra II. 52, 53, 81, 122, 188, III. 158, 191
 — tarsales, *gl. tarsales (Meibomi)* III. 267
 — thyroidea, *gl. thyroidea* I. 225, 229, II. 24, 26, 38, 88, 185, 186, 187, 213, 214, 215, 216, 217, III. 108, 109, 119, 120, 121, 123, 151, 186, 197, 198, 203
 — tracheales II. 98, 102, 107
 — vestibularis major, *gl. vestibularis major (Bartholini)* II. 172
 glans clitoridis II. 171, 177
 — penis II. 140, 141, II. 143, 150, 151, 155, 157, 158, 160
 globus pallidus, *pars pallida nuclei lentiformis* III. 42, 46, 48, 59, 81
 glomerulus renis II. 130, 132, 133
 — — corticalis II. 130, 133
 — — juxtamedullaris II. 130, 133
 glomus caroticum III. 122
 — choroideum, *glomus choroideum* III. 17
 *glossa (gr.), vide: lingua
 granulationes arachnoideales, *granulationes arachnoideales (Pavchioni)* III. 74, 79
 gubernaculum testis, *gubernaculum testis (Hunteri)* II. 145, 148
 gyrus (-i)
 — angularis III. 11
 — breves insulae III. 13
 — centralis anterior, vide: gyrus precentralis
 — — posterior, vide: gyrus postcentralis
 — cerebelli, vide: folia cerebelli
 — cerebri III. 3, 5, 7, 9
 — cinguli, *gyrus fornicatus* III. 4, 5, 10, 20, 63
 — dentatus, *fascia dentata* III. 18, 19, 43
 — frontalis inferior III. 2, 3, 6
 — — medius III. 2, 3, 6, 7, 11
 — — superior III. 2, 3, 4, 5, 6, 7, 11, 20
 — fusiformis, vide: gyrus occipitotemporalis lateralis
 — hippocampi, vide: gyrus parahippocampalis
 — lingualis III. 9
 * — longus insulae III. 11
 — occipitales, *gyri occipitales lat. et supp.* III. 3, 6, 7
 — occipitotemporalis lateralis, *gyrus fusiformis* III. 8, 9, 10
 * — — medialis, vide: gyrus parahippocampalis
 gyrus lingualis
 — orbitales III. 8, 9, 10, 20, 22
 — — medialis III. 8
 — parahippocampalis, *gyrus hippocampi* III. 8, 9, 10, 18, 19, 20, 43
 — paraterminalis, *gyrus subcallosus* III. 20, 21
 — postcentralis, *gyrus centralis post.* III. 2, 3, 6, 7, 11, 67
 — precentralis, *gyrus centralis ant.* III. 2, 3, 6, 7, 11, 67
 — rectus III. 5, 8, 9, 10, 20, 22
 — subcallosus, vide: gyrus paraterminalis
 — supramarginalis III. 3
 — temporalis inferior III. 2, 3, 9, 11
 — — medius III. 2, 3, 11
 — — superior III. 2, 3

H

- habenula corporis pinealis II. 184, III. 23, 37, 47
 hallux seu digitus pedis I. I. 312
 hamulus lacrimalis I. 36
 — laminae spiralis III. 254
 — ossis hamati I. 114, 117, 186
 — pterygoideus I. 23, 24, 67, 68, II. 31
 haustrea coli II. 57, 59
 helicotrema III. 254
 helix III. 242, 243, 244, 245

- hemisphaerium (*hemisphaerium*) cerebelli III. 27, 29, 44, 48
 — — — dextrum III. 27
 — — — sinistrum III. 27
 — — cerebri III. 1—21, 39—48
 — — — dextrum III. 12
 — — — sinistrum III. 12, 57
 hepar, vide etiam: facies, lobi hepatis I. 249, II. 1, 63, 64, 65, 66, 67, 73, 80, 81, 211, III. 154, 155, 187, 188, 194, 202, 207, 213, 215
 hiatus adductorius, vide: hiatus tendineus
 * — analis II. 174, 175
 — aorticus I. 248, 250
 * — axillaris lateralis I. 266, 268, 269
 * — — medialis I. 266, 268, 269
 * — basilius I. 261, III. 146
 — canalis nervi petrosi majoris, *hiatus canalis facialis* I. 16
 — — — minoris, *apertura sup. canaliculi tympanici* I. 16
 — esophageus diaphragmatis, *hiatus oesophageus* I. 248
 * — fasciculi atrioventricularis II. 199
 * — genitalis II. 174, 175
 * — infrapiriformis I. 246, 289, 290
 * — levatoris ani (*hiatus analis) II. 174, 175
 * — — — (* — genitalis) II. 174, 175
 — maxillaris I. 35, 64
 — oesophageus, vide: hiatus esophageus
 — sacralis, *hiatus canalis sacralis* I. 89, 90, 91
 — saphenus, *fossa ovalis* I. 235, 241, 242, III. 175, 209, 211
 * — scaleni I. 224, 225, 226, 233, 258, II. 117
 — semilunaris I. 63, II. 86
 * — sublingualis I. 245
 * — suprapiriformis I. 246, 247, 290, 291, II. 166, III. 172
 — tendineus (adductorius), *hiatus canalis adductorii* I. 299, 300, III. 165, 174
 hilus glandulae suprarenalis II. 188
 — lienis II. 71
 — nuclei dentati III. 33
 — pulmonis II. III, II. 114
 — — sinistri II. III, 120
 — renalis II. 123, 124, 125, 126
 hippocampus, *cornu Ammonis III. 15, 16, 17, 18, 19, 24, 43, 45, 46, 48, 81
 humerus, vide etiam: capitulum, caput, epicondylus lateralis, medialis humeri I. 106, 108, 172, 173, 175, 176, 177, 178, 179, 180, 183, III. 127, 128, 129, 130
 hypophysis seu glandula pituitaria II. 25, 86, 181, 182, 183, III. 1, 4, 5, 95
 hypothalamus II. 181, III. 4, 21, 22, 42, 48
 hypothenar I. 278

I

- ileum, *intestinum ileum* II. 1, 48, 49, 50, 57, 58, 74, 78, III. 156, 157, 206
 impressio cardiaca hepatis II. 63
 — — pulmonis dextri II. 112
 — — — sinistri II. 111
 — colica hepatis II. 65
 * — costalis pulmonis II. 109
 — esophagea hepatis II. 64, 65
 — gastrica hepatis II. 65
 — ligamenti costoclavicularis claviculae, *tuberositas costalis* I. 102
 — oesophagea hepatis, vide: impressio esophagea
 — renalis hepatis II. 65
 — suprarenalis hepatis II. 65
 — trigemini I. 19
 incisura (-ae)
 — acetabuli I. 118

- incisura angularis ventriculi *II*. 40, 41
 — anterior auris *III*. 242
 — apicis cordis *II*. 190
 — cardiaca pulmonis *II*. 82, 109, 111, 117, 119
 — — sinistri *II*. 212
 — cartilaginis meatus acustici, *incisura cartilaginis meatus acustici externi (Santorini)* *III*. 243
 — clavicularis sterni *I*. 95, 96, 171
 — costalis sterni *I*. 95
 — ethmoidalis ossis frontalis *I*. 26
 — fibularis tibiae *I*. 133, 134
 — frontalis sive foramen frontale *I*. 26, 27, 66
 — interarytenoidea *II*. 31, 34, 39, 96, 101, 102
 — *interlobaris pulmonis*, vide: fissura horizontalis, obliqua
 — intertragica *III*. 242, 243, 244, 245
 — ischiadica major *I*. 118, 119, 120
 — — minor *I*. 118, 119
 — jugularis ossis occipitalis *I*. 13, 14
 — — temporalis *I*. 17
 * — — —, pars anterior *I*. 17
 * — — —, pars posterior *I*. 17
 — — sterni *I*. 95, 170
 — lacrimalis *I*. 34
 — ligamenti teretis, *incisura umbilicalis hepatis* *II*. 47, 48, 51, 63, 68, 76, 77
 — mandibulae *I*. 47, 48, *II*. 14
 — mastoidea *I*. 18, 59, 60
 — nasalis maxillae *I*. 34, 68, *II*. 5, 85
 — pancreatis *II*. 45, 53
 — parietalis ossis temporalis *I*. 15, 16, 17, 21
 — pterygoidea, *fissura pterygoidea* *I*. 23
 — radialis ulnae *I*. 110, 180, 182
 — scapulae *I*. 103, 104, 172
 — *semilunaris ulnae*, vide: incisura trochlearis
 — sphenopalatina *I*. 41, 42, 43
 — thyroidea inferior *II*. 89
 — — superior *II*. 89, 90, 100
 — trochlearis ulnae, *incisura semilunaris* *I*. 110, 181, 182, 183
 — *tympanica* *III*. 251
 — ulnaris radii *I*. 113
 — *umbilicalis hepatis*, vide: incisura ligamenti teretis
 — vertebralis inferior *I*. 81, 82, 86
 — — superior *I*. 86
 ineus, vide etiam: crus breve, longum *III*. 103, 246, 250, 253
 index seu digitus manus *II*. *I*. 278
 *indusium griseum, vide: stria longitudinalis
 infundibulum *III*. 21, 78, 97
 — hypothalami *II*. 86, 181
 — tubae uterinae *II*. 168
 — ventriculi dextri, vide: conus arteriosus
 *innervatio peripherica cutis *III*. 168, 169, 185
 * — segmentalis cutis *III*. 184
inscriptio tendinea, vide: intersectio tendinea
 *insertio gastrica omenti majoris *II*. 41, 48
 * — — minoris *II*. 41
 * — muscoli semimembranosi *I*. 303, 304, 305
 * — tendinis muscoli tensoris tympani *III*. 253
 insula, *insula (Reili)* *III*. *II*. 15, 26, 40, 41, 42, 48, 62
 integumentum commune *III*. 261–275
 intersectiones tendineae, *inscriptiones tendineae* *I*. 235, 236
intestinum caecum, vide: caecum
 — crassum *II*. 50, 57–60
 — ileum, vide: ileum
 — jejunum, vide: jejunum
 — rectum, vide: rectum
 — tenue *II*. 45–48, 49, 51–56, 75, 80, *III*. 193, 195
 intumescencia cervicalis *III*. 82, 85
 — lumbalis *III*. 82, 86
 iris *III*. 216, 217, 218, 219, 220, 221, 235
 isthmus cartilaginis auris *III*. 245
 isthmus faucium *II*. 29
 — glandulae thyroideae *II*. 186
 — gyri cinguli, *isthmus gyri fornicati* *III*. 10, 20
 — — *fornicati*, vide: isthmus gyri cinguli
 — rhombencephali *III*. 50
 — tubae uterinae *II*. 165, 167, 168
 — uteri *II*. 168, 169
- J**
- jejunum, *intestinum jejunum* *II*. *I*. 45, 48, 49, 74, *III*. 156
 juga alveolaria *I*. 34, 68, *II*. 5
jugum cerebrale *I*. 24, 25
 junctura (-ae)
 — cinguli membri inferioris *I*. 192, 193, 194
 — — superioris *I*. 171–175
 — columnae vertebralis *I*. 153–169
 — cranii *I*. 150–158
 — membri inferioris liberi *I*. 195–211
 — — superioris liberi *I*. 176–191
 * — ossium capitis *I*. 52–73
 — *radiolunares* *I*. 184
 — sacrococcygeae *I*. 167, 168, 169
 — *tendinum*, vide: connexus intertendinei
 * — thoracis *I*. 160–163, 170, 171
- K**
- labium (-ia)
 — anterius portionis vaginalis cervicis uteri *II*. 168
 — externum cristae iliacae *I*. 118
 — inferius oris *II*. 2, 22, 26, 27, 29, 36, 88
 — — valvae ileocecalis, *labium inf. valvulae coli* *II*. 58
 — laterale lineae asperae *I*. 128
 * — limbi laminae vestibularis *III*. 261
 * — — tympanicum laminae vestibularis *III*. 261
 * — vestibulare laminae vestibularis *III*. 261
 — majus pudendi *II*. 80, 161, 171, *III*. 161
 — mediale lineae asperae *I*. 128
 — minus pudendi *II*. 164, 171, *III*. 161, 190
 — oris, vide etiam: labium inferius, superius oris
II. *I*. 4
 — — neonati *II*. 3
 — posterius portionis vaginalis cervicis uteri *II*. 168
 — superius oris *II*. 2, 22, 26, 29, 30, 86, 88, *III*. 104
 — — valvae ileocecalis, *labium sup. valvulae coli* *II*. 58
 — *tympanicum*, vide: labium limbi tympanicum
 — *vestibulare*, vide: labium limbi vestibulare
 labrum acetabulare, *labrum glenoidale articulationis coxae* *I*. 192, 197, 198, 199
 — glenoidale, *labrum glenoidale articulationis humeri* *I*. 174, 175
 — — *articulationis coxae*, vide: labrum acetabulare
 labyrinthus ethmoidalis *I*. 32, *II*. 87
 — membranaceus *III*. 259, 260
 — osseus *III*. 255, 256
lacertus fibrosus, vide: aponeurosis muscoli bicipitis brachii
 — muscoli recti lateralis *III*. 239
 lacuna (-ae)
 — lateralis sinus sagittalis superioris *III*. 74, 79
 * — lymphatica *I*. 213, 245, 296, 297
 — musculorum *I*. 245
 — urethrales, *lacunae urethrales (Morgagnii)* *II*. 140
 — vasorum *I*. 245, 296, 297
 lacus lacrimalis *III*. 235
 lamina (-ae)
 — affixa *III*. 81
 — alaris *III*. 54
 — anterior vaginae muscoli recti abdominis *I*. 238

- amina basalis III. 54
 cartilaginea (hyaloidea) corporis vertebrae I. 165
 cartilaginosa cricoideae II. 26, 88, 91, 92, 99, 104, 106, 107
 cribrata fasciae latae, vide: fascia cribrata
 ossis ethmoidalis I. 31, 58, 61, 62, 64, II. 26, 87, 88, III. 78, 97, 98, 105, 231
 dextra cartilaginis thyroideae II. 33, 89
 * epiglottidis II. 95
 * epithelialis, lamina chorioidea epithelialis III. 36, 81
 * externa durae matris spinalis III. 92
 fibrocartilaginea interpubica, vide: discus interpubicus
 horizontalis ossis palatini, pars horizontalis ossis palatini I. 13, 73, II. 12, 13, 16, 83
 * intereruralis penis II. 159
 * interna durae matris spinalis III. 92
 * lateralis cartilaginis tubae auditivae III. 263
 — processus pterygoidei I. 23, 24, 61, 62, 63, 67, 68, 220, II. 12, 23, 33, III. 186
 * limitans gliae perivascularis III. 79
 * medialis cartilaginis tubae auditivae III. 263
 — processus pterygoidei I. 23, 61, 62, 63, 220, II. 12
 medullaris thalami III. 47
 membranacea tubae auditivae III. 252
 muscularis mucosae III. 195
 orbitalis ossis ethmoidalis, lamina papyracea I. 30, 31, 33, 64, 66, 68, II. 87
 papyracea, vide: lamina orbitalis
 parietalis pericardii serosi II. 109, 185, 212, 213, 214
 — tunicae vaginalis testis, lamina parietalis tunicae vaginalis propriae, periorchium II. 146, 149
 perpendicularis ossis ethmoidalis I. 30, 32, 33, 60, 61, 64, II. 83, 87
 — palatini, pars perpendicularis I. 11, 12, 43, 65
 * posterior omenti majoris II. 48
 pretrachealis fasciae cervicalis, fasciae colli media I. 227, 228, 229, 230, 231, 232, II. 25
 provertebralis fasciae cervicalis, fasciae colli profunda (praevertebralis) I. 229, II. 23, 117, III. 118
 * profunda fasciae cruris I. 303, III. 177
 — thoracolumbalis, lamina prof. fasciae lumbodorsalis I. 239
 * temporalis I. 217
 * quadrangularis, vide: membrana quadrangularis
 * quadrigemina, vide: lamina tecti
 rostralis III. 21, 72
 sinistra cartilaginis thyroideae II. 89, 90
 spiralis ossea III. 254, 257, 261
 — secunda III. 256
 superficialis fasciae cervicalis, fasciae colli spf. I. 227, 228, 229, III. 116, 117
 — cruris I. 301, 302, 306
 — temporalis I. 216, II 35
 — thoracolumbalis I. 239
 suprachoroidea (suprachorioidea) III. 220
 tecti, lamina quadrigemina, corpora quadrigemina, vide etiam: colliculus inferior, superior III. 5, 21, 24, 32, 36, 61, 66, 109
 tendinea triangularis digiti I. 276, 277, 283
 terminalis, lamina terminalis cinerea II. 181, 182, 183, III. 4, 21, 48
 tragi III. 243, 244
 * custoductoria I. 297, 298, III. 171
 * visceralis pericardii serosi seu epicardium II. 215
 — tunicae vaginalis testis, lamina visceralis tunicae vaginalis propriae, epiorchium II. 148
 larynx, vide etiam: articulationes, cartilagineae, ligamenta, musculi laryngis II. 31, 82, 89–96, III. 123
 lemniscus lateralis III. 50, 51
 medialis III. 49, 50, 53
 lemniscus trigeminalis III. 50
 lens, lens crystallina III. 216, 217, 219, 220, 223, 224, 225, 227
 * leptomeninx (gr.), vide: pia mater, arachnoidea
 lien II. 1, 50, 51, 70, 71, 72, 73, 76, 81, III. 155, 187, 188, 207
 ligamentum (-ta)
 — acromioclaviculare I. 173, 174
 — alare I. 155, 156
 — anocoeygeum II. 80, 142, 154, 172, 173, 174, 175, 176, III. 160
 — anulare radii, lig. anulare radii I. 176, 177, 178, 180, 181, 182, 184
 — stapedis, lig. anulare bascos stapedis III. 254
 — tracheae, ligg. annularia II. 33, 97, 102, 106, 107
 — apicis dentis I. 156
 — arcuatum carpi dorsale I. 187
 — laterale, arcus lumbocostalis lat. I. 248, 250
 — mediale, arcus lumbocostalis med. I. 248, 250, II. 117
 — medianum I. 248, 250
 — pubis II. 155
 arteriosum, lig. arteriosum (Botalli) III. 153
 basiun ossium metacarpium, vide: ligamenta metacarpea
 bifurcatum, ligamentum calcaneocuboideum, lig. bifurcatum, pars calcaneocuboidea I. 210, 212
 — — calcaneonaviculare, lig. bifurcatum, pars calcaneonavicularis I. 210, 212
 — calcaneocuboideum dorsale I. 210
 — plantare I. 210
 calcaneofibulare I. 209, 210, 212
 * calcaneonaviculare interosseum I. 213
 — plantare I. 211, 212, 214, 316
 capitis costae radiatum, lig. capituli costae radiatum I. 153, 160, 161
 — femoris, lig. teres femoris I. 192, 198, 199
 — fibulae, ligg. capituli fibulae I. 204
 — — anterius I. 200, 201, 206, 209
 — — posterius I. 205, 206
 * cardinale uteri II. 166
 — carpi dorsale, vide: retinaculum extensorum manus
 * — palmare I. 261, III. 140, 141
 — radiatum I. 186
 — transversum, vide: retinaculum flexorum manus
 — volare I. 261
 — carpometacarpea dorsalia I. 187, 188
 — palmaria, ligg. carpometacarpea volaria I. 186, 189
 — ceratocricoideum laterale II. 98, 100, 101
 — posterius II. 98
 collaterale (articulationis interphalangeae) I. 186, 187, 189
 — (— metacarpophalangeae) I. 186, 187
 — carpi radiale I. 186, 187, 188
 — ulnare I. 186, 187
 — fibulare (articulationis genus) I. 200, 201, 202, 203, 204, 205, 206
 — radiale (articulationis cubiti) I. 177, 180
 — tibiale (articulationis genus) I. 200, 202, 204, 205
 — ulnare (articulationis cubiti) I. 176, 178, 179, 180, 188
 * — pars Cooperi I. 178
 * — humerocoronoida I. 178
 * — olecrano humeralis I. 178
 colli costae, vide: ligamentum costotransversarium
 conoideum I. 173, 174
 coracoacromiale I. 173, 174
 coracooclaviculare I. 173, 174, 175
 coracohumerale I. 172

- Ligamentum corniculopharyngeum* II. 98, 99, 103
coronarium hepatis II. 63, 64, 79, 80
cruciohaviculare I. 171
cruciohaviculare, *lig. calli costae* I. 160
cruciohaviculare, *lig. tuberculi costae* I. 160, 161, 162
laterale, *lig. tuberculi costae ant. et post.*
superioris I. 160
cruciohaviculare, *lig. cricohyoidaeum medium*
 I. 97, 99, 100, 103, 104, 186
 — *cricotracheale* II. 97, 100, 106, 107
 — *cruciatum anterius articulationis genus* I. 203, 204, 205, 207, 208
 — *posterius articulationis genus* I. 203, 204, 205, 207, 208
 — *cruciforme*, *lig. cruciatum atlantis* I. 155
 — *cuboideonaviculare dorsale* I. 210, 212
 — *plantare* I. 211
 — *cuneocuboideum dorsale* I. 210, 212
 — *cuneonaviculare dorsale*, *lig. naviculocuneiforme dors.* I. 212
 — *plantare*, *lig. naviculocuneiforme plantare* I. 211
 — *deltoidaeum, pars tibioalcaneae*, *lig. calcaneotibiale* I. 211
 — — — *tibionavicularis*, *lig. tibionaviculare* I. 211
 — — — *tibiotalaris anterior*, *lig. talotibiale ant.* I. 209
 — — — *posterior*, *lig. talotibiale post.* I. 211
 — *denticulatum* III. 87, 92, 124
 * — *dorsalia pedis* I. 210
 — *epididymidis inferius* II. 145
 — *superius* II. 145
 — *fulciforme hepatis* II. 47, 48, 51, 63, 64, 76, 79, 81, III. 148, 154, 155, 207, 213
 — *flavum* I. 162, 163, 165
 — *fundiforme penis* I. 235, 240, 241, 242, II. 149
 — *gastrolienale* II. 71, 73, 81
 * — *hamatometacarpeum* I. 186
 — *hepatoduodenale* II. 76, 77, 79, 81
 — *hepatogastricum* II. 76, 77
 — *hepatorenale* II. 79, 81
 — *hyoepiglotticum* II. 99, 103, 104
 — *hyothyroideum*, vide: *ligamentum thyrohyoideum*
 — *iliofemorale*, *lig. iliofemorale (Bertini)* I. 195
 — *iliolumbale* I. 192, 193, 194
 — *iliopectineum* I. 296, 297
 — *incudis posterius* III. 253
 — *superius* III. 253
 — *inguinale*, *lig. inguinale (Poupartii)* I. 193, 237, 242, 243, 245, 246, 247, 295, 296, 297, 298, 299, 300, II. 174, 176, III. 149
 — *intercarpea dorsalia* I. 187
 — *interosseum* I. 188
 — *interclaviculare* I. 171
 — *intercostale*, vide: *membrana intercostalis*
 — *interfoveolare*, *lig. interfoveolare (Hesslbachii)* I. 244
 — *interspinalia* I. 164, 165
 — *intertransversarium* I. 162
 — *ischiofemorale*, *lig. ischiofemorale* I. 195, 196
 — *laciniatum*, vide: *retinaculum flexorum pedis*
 — *lacunare*, *lig. lacunare (Gimbernati)* I. 243, 245, 296, 297, II. 176
 * — *laryngis* II. 98, 99
 — *laterale*, *lig. temporamandibulare* I. 150
 — *latum uteri* II. 167, 168, 169
 — *longitudinale anterius* I. 153, 161, 165, 167, 193
 — *posterius* I. 154, 159, 165
 — *mallei superius* III. 253
 — *malleoli lateralis*, vide: *ligamentum tibiofibulare*
 * — *menisci lateralis*, *lig. menisci fibularis (Roberti)* I. 205, 208

- ligamenta metacarpea dorsalia*, *ligg. basium ossium metacarpi dors.* I. 187
 — — *interossea*, *ligg. basium ossium metacarpi interossea* I. 188
 — — *palmaria*, *ligg. basium ossium metacarpi rotaria* I. 186
 — — *transversa profunda*, *ligg. capitulorum transversa* I. 186, 187
 — *metatarsea dorsalia*, *ligg. basium ossium metatarsi dors.* I. 210
 — — *interossea*, *ligg. basium ossium metatarsi interossea* I. 213
 — — *plantaria*, *ligg. basium ossium metatarsi plantaria* I. 211
 — *naviculocuneiforme*, vide: *ligamentum cuneonaviculare*
 — *nuchae* I. 158, 251, 258
 * — *ossiculorum auditus* III. 253
 — *ovarum proprium* II. 164, 165, 166, 167, 168
 — *palmaria*, *ligg. accessoria rotaria* I. 186, 189
 — *palpebrale laterale* III. 236
 — *mediale* I. 215, III. 236
 — *patellae* I. 200, 201, 206, 207, 296, III. 176
 — *pectinatum anguli iridocornealis* III. 220
 * — *pelvis* I. 193, 191
 — *phrenicocolicam* II. 50, 73, 78, 79
 — *phrenicogastricum* II. 79
 — *phrenicolienale* II. 73, 79, 81
 — *pisohamatum* I. 185, 186
 — *pisometacarpeum* I. 185, 186
 — *plantare longum* I. 209, 210, 211, 214, 316, 317
 * — *pedis* I. 211
 — *popliteum arcuatum* I. 202
 — *obliquum* I. 202, 294, 305
 * — *pubicum (Cooperi)* I. 243, 296, 297, 300
 — *superius* I. 193
 — *pubocapsulare*, vide: *ligamentum pubofemorale*
 — *pubofemorale*, *lig. pubocapsulare* I. 195
 — *puboprostaticum* II. 138, 143
 — *pulmonale* II. 111, 112, 120
 — *quadratum* I. 177
 — *radiocarpeum dorsale* I. 187
 — *palmare*, *lig. radiocarpeum rotare* I. 186
 — *reflexum*, *lig. reflexum (Collesii)* I. 235, 241, 242, 243
 — *sacrocoecygeum dorsale profundum*, *lig. sacrocoecygeum post. prof.* I. 169
 — — *superficiale*, *lig. sacrocoecygeum post. spf.* I. 168, 169, 194
 — *laterale* I. 167, 168, 169
 — *ventrale*, *lig. sacrocoecygeum ant.* I. 167, 193
 — *sacroiliacum dorsale*, *lig. sacroiliacum post.* I. 194, 291
 — *interossea* I. 192
 — *ventrale*, *lig. sacroiliacum ant.* I. 193
 — *sacrospinale*, *lig. sacrospinale* I. 193, 191, 246, 247, 291, II. 175, III. 159, 160, 161
 — *sacro tuberale*, *lig. sacrotuberosum* I. 167, 168, 169, 193, 194, 247, 289, 290, 291, II. 154, 173, 174, III. 159, 160, 162, 172, 173
 — *sphenomandibulare* I. 151
 — *sternoclaviculare anterius*, *lig. sternoclaviculare* I. 171
 — *sternocostalia intraarticularia*, *ligg. sternocostalia interarticularia* I. 170, 171
 — *radiata* I. 170, 171
 * — *sternopericardiacum inferius*, vide etiam: *pericardium fibrosum* II. 212
 — *superius*, vide etiam: *pericardium fibrosum* II. 212
 — *stylomandibulare* I. 150, 151, 152
 — *supraspinale* I. 162, 164, 165, 194
 — *suspensorium clitoridis* II. 177
 * — *mammae* II. 180
 — *ovarum* II. 164, 165, 166

- ligamentum suspensorium penis *I.* 245, *II.* 143, 150, 155, *III.* 170
- talocalcanonaviculare plantare *I.* 214
 - talocalcaneum anterius *I.* 212
 - — interosseum *I.* 209, 210, 212, 213, 214
 - — laterale *I.* 209, 210
 - — mediale *I.* 211
 - — posterius *I.* 211, 212,
 - talofibulare anterius *I.* 209, 210
 - talonaviculare *I.* 210
 - tarsometatarsa plantaria *I.* 211
 - *temporomandibulare*, vide: ligamentum laterale articulationis temporomandibularis
 - *teres femoris*, vide: ligamentum capitis femoris
 - — hepatis *II.* 47, 48, 63, 65, 73, 76, 77, 78, *III.* 148, 154, 155, 213
 - — uteri *II.* 164, 165, 166, 170, *III.* 210
 - thyroepiglotticum *II.* 98, 103, 104
 - thyrohyo.dum, *lig. hyothyroideum lat.*, vide etiam: membrana thyrohyoidea *II.* 32, 97, 98, 99, 100, 101, 102, 103, 104, 186, 187
 - — medianum, *lig. hyothyroideum medium* *II.* 97, 99, 100, 102, 103, 104, 186
 - tibiofibulare anterius, *lig. malleoli lat. ant.* *I.* 209, 210
 - transversum acetabuli *I.* 192, 198, 199, 245
 - — atlantis *I.* 155, 157, *II.* 36
 - *cruris*, vide: retinaculum extensorum pedis
 - *superius*
 - — genus *I.* 204, 208
 - — scapulae, vide: *ligg. transversa scapulae inf. et sup.*
 - — — inferior *I.* 172, *III.* 134
 - — — superior *I.* 172, 173, 175, 203, 204, 205, *III.* 134
 - * — — uteri *II.* 166
 - trapezoideum *I.* 173, 174
 - triangulare dextrum hepatis *II.* 64
 - — sinistrum hepatis *II.* 64
 - *tuberculi costae*, vide: ligamentum costotransversarium laterale
 - ulnocarpeum palmare *I.* 186
 - umbilicale laterale, *chorda a. umbilicalis* *I.* 244
 - — medianum, *chorda urachi*, *lig. umbilicale medium* *II.* 136, 137, 138, 142, 143, 151
 - — *medium*, vide: ligamentum umbilicale medianum
 - * — venae cavae *II.* 64, 65
 - venosum, *lig. venosum (Arantii)* *II.* 64, 65
 - vestibulare, *lig. ventriculare* *II.* 99, 103
 - vocale *II.* 99, 103
 - * *limbus acetabuli* *I.* 118
 - *alveolaris*, vide: areus alveolaris
 - corneae *III.* 217
 - fossae ovalis *II.* 192, 193, 204
 - laminae spiralis *III.* 261
 - *membranae tympani* *III.* 249
 - palpebralis anterior *III.* 235, 237
 - — posterior *III.* 235, 237
 - limen insulae *III.* 11
 - nasi *II.* 26, 86, 88
 - linea (-ae)
 - alba *I.* 232, 235, 236, 237, 238, 240, 241, 242, 243, 244, 245
 - * — anocutanea *II.* 62
 - * — anorectalis *II.* 62
 - * — apophysialis *I.* 2, 6
 - arcuata ossis ilium *I.* 119, *II.* 175
 - — vaginae muscoli recti abdominis, *linea semicircularis (Douglasi)* *I.* 237, 238, 244
 - aspera *I.* 128, 129
 - axialis dorsalis *III.* 184
 - — ventralis *III.* 184
 - epiphysialis *I.* 2, 3, 6
 - glutea anterior *I.* 118
 - — inferior *I.* 118
 - linea glutea posterior *I.* 118
 - * — horizontalis infraorbitalis (Frankfurt) *III.* 67
 - * — — supraorbitalis *III.* 67
 - * — intermedia *I.* 118
 - intertrochanterica *I.* 127, 195
 - *musculares scapulae* *I.* 104
 - muscoli solei, *linea poplitea* *I.* 134
 - mylohyoidea *I.* 47, 49
 - *nuchae inferior* *I.* 14, 60
 - — superior *I.* 14, 60, 258
 - — suprema *I.* 14
 - obliqua cartilaginis thyroideae *I.* 224, *II.* 89, 90, 97, 100
 - — mandibulae *I.* 47
 - — pectinea *I.* 128, 129
 - * — Rolandica *III.* 67
 - * — Sylvii *III.* 67
 - temporalis *I.* 15, 27
 - — inferior *I.* 28, 57
 - — superior *I.* 28, 54, 57
 - terminalis pelvis *I.* 123, 124, 193, 246, 247, *II.* 138, 175
 - trajectoriales femoris *I.* 6
 - transversae ossis sacri *I.* 88, 120
 - trapezoidea, *tuberositas coracoidea* *I.* 102
 - *visus* *III.* 216
 - lingua, vide etiam: apex, dorsum, margo, radix linguae *II.* 1, 21, 23, 27, 28, 29, 86, *II.* 186
 - lingula cerebelli *III.* 28, 29, 30, 32
 - *mandibulae* *I.* 49, *II.* 14, 17
 - *pulmonis sinistri* *II.* 109, 111, 113, 114, 117, 119, 212, 214,
 - *sphenoidalis* *I.* 22, 24
 - lobulus (-i)*
 - *auricularis* *III.* 242
 - biventer *III.* 29, 30, 31
 - centralis *III.* 27, 28, 29, 30, 32
 - cerebelli *III.* 28, 30
 - corticales renis *II.* 128
 - glandulae mammariae, *lobuli mammae* *II.* 179, 180
 - — thyroideae *II.* 187
 - hepatis *II.* 67
 - paracentralis *III.* 4, 5
 - parietalis inferior *III.* 3, 6, 7
 - — superior *III.* 3, 6, 7
 - *pulmonis* *II.* 121
 - *pulmonis*, vide: segmenta bronchopulmonalia
 - quadrangularis *III.* 27, 28, 30, 31
 - semilunaris inferior *III.* 27, 28, 29, 30, 31
 - — superior *III.* 27, 28, 29, 30, 31
 - testis *II.* 146
 - lobus (-i)
 - anterior hypophyseos *II.* 182, 183 *III.* 21
 - — — pars intermedia *II.* 182
 - — — tuberalis *II.* 182
 - * — axillaris glandulae mammariae *II.* 179
 - caudatus hepatis, *lobus caudatus (Spigeli)* *II.* 64, 65
 - dexter glandulae thyroideae *II.* 186, 187
 - — hepatis *II.* 1, 48, 52, 63, 64, 65, 68, 73, 76, 78, 81, *III.* 154, 155, 156, 157
 - — prostatae *II.* 137, 151
 - frontalis cerebri *III.* 10, 14, 15, 17, 21, 24, 56, 65, 71
 - glandulae mammariae, *lobus mammae* *II.* 179
 - inferior pulmonis dextri *II.* 82, 109, 110, 112, 114, 117, 118, 212
 - — — sinistri *II.* 82, 109, 111, 113, 114, 117, 119, 212
 - medius pulmonis dextri *II.* 82, 109, 112, 113, 114, 117, 212
 - occipitalis *III.* 14, 15, 17, 18, 24, 56, 65, 71
 - parietalis *III.* 17, 24
 - * — portobiliares hepatis *II.* 66, 67
 - * — — dexter *II.* 66, 67
 - * — — medius *II.* 66, 67

- *lobus portobiliaris hepatis sinister *II*. 66, 67
 — posterior hypophyseos *II*. 182, 183, *III*. 21
 — pyramidalis glandulae thyroideae *II*. 186
 — quadratus hepatis *II*. 65
 * renalis *II*. 124, 128
 — sinister glandulae thyroideae *II*. 186
 — — hepatis *II*. 1, 47, 48, 51, 52, 63, 61, 65, 68, 73, 76, *III*. 154, 155
 — — prostatae *II*. 151
 — superior pulmonis dextri *II*. 82, 109, 110, 112, 113, 114, 117, 118, 212
 — — — sinistri *II*. 82, 109, 111, 113, 114, 117, 118, 119
 — temporalis cerebri *II*. 25, *III*. 4, 15, 18, 56, 62, 73, 239
 — — dexter *III*. 65
 — — sinister *III*. 65
 * thymi *II*. 185
 locus ceruleus *III*. 37
 lunula unguis *III*. 264
 — valvulae semilunaris *II*. 193
 lymphoglandula, vide: nodus lymphaticus
 lymphonodus, vide: nodus lymphaticus

M

- macula, *macula lutea III*. 216, 222
 — acustica, vide: macula sacculi, macula utriculi
 — sacculi, *macula acustica sacculi III*. 254
 — utriculi, *macula acustica utriculi III*. 262
 mala seu bucca *II*. 2
 malleolus lateralis *I*. 133, 134, 209, 307, 310, 319, *III*. 176, 177
 — medialis *I*. 133, 134, 209, 304, 306, 318, *III*. 177
 malleus *I*. 21, *III*. 103, 246, 250
 manna *II*. 178, 179, 180
 mandibula, vide etiam: angulus, basis, caput, lingua, ramus mandibulae *I*. 17, 18, 19, 224, *II*. 6, 7, 11, 18, 24, 26, 27, 33, 35, 88, *III*. 186
 * — senilis *I*. 50
 manubrium mallei *III*. 250, 251, 253
 — sterni *I*. 95, 96, 97, 170, 171, *III*. 120, 121, 122
 manus, vide: arteriae, articulationes, digiti, dorsum, musculi, ossa, palma, venae manus
 *margo acutus cordis, vide: margo dexter
 — alveolaris, vide: arcus alveolaris
 — anterior fibulae, *crista ant. I*. 133
 — — hepatis, vide: margo inferior
 — — humeri *I*. 108
 — — lienis, vide: margo superior
 — — pulmonis dextri *II*. 109
 — — — sinistri *II*. 109, 111, 112
 — — testis *II*. 144, 145
 — tibiae, *crista anterior I*. 133
 — ulnae, *margo volaris I*. 110
acillaris scapulae, vide: margo lateralis ciliaris iridis *III*. 217
 dexter cordis, *margo acutus cordis *II*. 190, 191
 falciformis (hiatus sapheni) *I*. 240, 243, 295
 frontalis *I*. 28, 29
 inferior hepatis, *margo anterior (acutus) hepatis II*. 63
 — lienis, *margo posterior II*. 70, 71
 — pulmonis *II*. 109, 110, 111, 112, 118, 119
 infraorbitalis *I*. 66, *II*. 5
 interosseus fibulae, *crista interossea I*. 133
 — radii, *crista interossea I*. 112, 113
 — tibiae, *crista interossea I*. 133, 134
 — ulnae, *crista interossea I*. 110, 111, 134
 iris, vide: margo ciliaris, margo pupillaris lamelloideus *I*. 13
 * lateralis (fibularis) pedis *I*. 312
 — humeri *I*. 106, 108
 — lingua, vide: margo linguae renis *II*. 123, 124, 125
 margo lateralis scapulae, *margo acillaris I*. 103, 104, 105, 173
 — — unguis *III*. 266
 — — uteri, vide: margo uteri
 * liber intestini *II*. 55
 — ovarii *II*. 165, 167
 — unguis *III*. 264, 265, 266
 linguae, *margo lat. linguae II*. 21, 22, 28
 mastoideus *I*. 13
 medialis glandulae suprarenalis *II*. 188
 — humeri *I*. 106, 108
 — renis *II*. 123, 125
 — scapulae, *margo vertebralis I*. 103, 104, 105 (tibialis) pedis *I*. 312
 * mesentericus intestini *II*. 55
 — mesovarius ovarii *II*. 167, 168
 * obtusus cordis, vide: facies pulmonalis cordis
 * occipitalis ossis parietalis *I*. 28, 29
 — — sphenoidalis *I*. 23
 — — temporalis *I*. 17
 occultus unguis *III*. 264
 parietalis ossis frontalis *I*. 25, 27
 — — sphenoidalis *I*. 23
 — — temporalis *I*. 15, 16, 17
 petrosus superior *I*. 17
 posterior fibulae, *crista lateralis I*. 134
 — lienis, vide: margo inferior
 pupillaris iridis *III*. 217, 219, 220
 sagittalis ossis parietalis *I*. 28, 29
 sphenoidalis ossis frontalis *I*. 25
 — — temporalis *I*. 15, 16, 17
 squamosus alae majoris *I*. 24
 — ossis parietalis *I*. 28, 29
 * superior glandulae suprarenalis *II*. 188
 — lienis, *margo anterior II*. 70, 71
 — pancreatis *II*. 45
 — partis petrosae, *angulus sup. pyramidis I*. 17, *III*. 85
 — scapulae *I*. 103, 104
 supraorbitalis *I*. 26, 27
 uteri, *margo lat. uteri II*. 167
vertebralis scapulae, vide: margo medialis zygomaticus alae majoris *I*. 23
massa intermedia, vide: adhesio interthalamica
 — lateralis atlantis *I*. 75, 76, 157
 matrix unguis *III*. 265
 maxilla *I*. 31, 35, *II*. 5, 7, 18, 24, 33, 85, 87
 meatus acusticus externus *I*. 150, 152, *II*. 24, 33, *III*. 243, 247
 — — cartilagineus *III*. 246
 * — — osseus *III*. 246
 — — internus *I*. 156, *II*. 32, *III*. 247
 — nasi communis *II*. 87
 — inferior *II*. 26, 86, 87, 88
 — medius *I*. 62, *II*. 26, 86, 87, 88
 superior *II*. 26, 86, 87, 88
 mediastinum, *septum mediastinale II*. 109, 110, 120, *III*. 152, 153
 — anterior *III*. 151
 — superius *II*. 120
 — testis, *mediastinum testis (Highmori) II*. 147
 medulla glandulae suprarenalis, *substantia medullaris II*. 188
 — oblongata *III*. 1, 2, 4, 5, 25, 26, 31, 35, 36, 53, 54, 55, 63, 83, 109, 124
 * pili *III*. 268
 renis, *substantia medullaris renis II*. 126
 spinalis *II*. 36, *III*. 1, 26, 82, 83, 84, 90, 121
 membrana atlantooccipitalis anterior *I*. 153
 — posterior *I*. 158
 fibroelastica laryngis *II*. 99
hyothyroidea, vide: membrana thyrohyoidea
 — intercostalis externa, *ligg. intercostalia ext. I*. 170, 233
 — interna, *lig. intercostale int. I*. 161, 162, 163

- membrana interossea antebrachii I. 176, 177, 178, 181, 185, 186, 187, 188, 266, 273
 — — cruris I. 200, 201, 202, 204, 205, 209, 210, 211
 * — limitans externa retinae III. 228
 * — — interna retinae III. 228
 obturatoria I. 191, 195, 199, 245, II. 135, 150, 169
 — — stapedis, vide: membrana stapedis
 perinei II. 154, 155, 169
 quadrangularis, *lamina quadrangularis II. 99, 102, 103
 spiralis III. 261
 stapedis, membrana obturatoria stapedis III. 252
 statocooniorum III. 262
 suprapleuralis, vide: fascia endothoracica
 tectoria I. 154, 155, III. 261
 thyrohyoidea, membrana hyothyreoidea I. 225, II. 26, 28, 33, 88, 97, 98, 99, 100, 103, 186
 tympani III. 103, 246, 247, 248, 249, 251, 253
 — — secundaria III. 252
 membrum inferius, extremitas inferior, vide etiam: articulationes, musculi, ossa membri inferioris I. 1
 — superius, extremitas superior, vide etiam: articulationes, musculi, ossa membri superioris I. 1
 meninx (-ges, gr.), vide etiam: dura mater, pia mater III. 79, 80
 meniscus fibularis, vide: meniscus lateralis
 — lateralis, meniscus fibularis I. 204, 205, 208
 — medialis, meniscus tibialis I. 204, 205, 208
 — tibialis, vide: meniscus medialis
 mentum II. 2, 3, 36
 mesencephalon II. 181, III. I. 8, 25, 26, 36, 49, 72
 mesenterium II. 49, 55, 71, 80
 mesoappendix, mesenteriolum processus vermiformis II. 50, 75, 78
 mesocolon ascendens II. 79
 — descendens II. 79
 — sigmoideum, mesosigmoideum II. 50, 75, 79
 — transversum II. 49, 50, 74, 77, 78, 79, 80
 mesometrium II. 167, 168
 mesorchium II. 144
 mesosalpinx II. 167, 168
 mesovarium II. 167, 168
 metatarsus I. 137
 metathalamus III. 26
 metencephalon III. 36
 *metra (gr.), vide: uterus
 modiulus III. 254, 257
 mons pubis II. 165, 171
 monticulus, vide: culmen, declive
 musculus (-i), vide etiam: tendines, capita musculorum
 * — abdominis I. 235, 236, 237, 239
 — abductor digiti minimi manus, m. abductor digiti quinti I. 279, 280, 281, 283, 284, 337, 345, III. 131, 140, 141, 167, 181
 — — — pedis, m. abductor digiti quinti I. 313, 314
 — hallucis I. 313, 314, 345, 346
 — pollicis brevis I. 279, 280, 336, 337, III. 130, 138, 140, 141
 — — longus I. 274, 275, 276, 277, 281, 282, 336, 339, 346, III. 127, 135, 138, 139
 — adductor brevis I. 299, 339, 342, III. 165
 * — femoris I. 295, 297, 298, 299, 300, III. 165
 — hallucis III. 167
 — —, caput obliquum I. 315, 346
 — — — transversum I. 314, 346
 — longus I. 296, 297, 298, 299, 342, III. 165, 170, 171
 — magnus I. 289, 290, 292, 293, 294, 298, 299, 300, 339, 342, III. 165, 173, 174
 * — minimus I. 300
 — pollicis I. 277, 279, 280, 337, 338, III. 131, 140, 141, 143
 — —, caput obliquum I. 281
 musculus adductor pollicis, caput transversum I. 281
 — anconeus I. 274, 275, 334, 336
 — antitragicus III. 240
 * — arrector mammae II. 180
 — — pili III. 270
 — articularis genus I. 299, 300
 — aryepiglotticus II. 101
 — arytenoideus, m. arytaenoideus II. 104
 — — obliquus II. 101, 102
 — transversus II. 101, 102
 * — auriculae III. 240, 241
 — auricularis anterior I. 216, III. 240
 — — posterior I. 216, III. 241
 — superior I. 216, III. 112, 240, 241
 — biceps brachii I. 230, 232, 268, 270, 332, III. 129, 135, 136, 137, 138, 139
 — —, caput breve I. 231, 263, 264, 268, 332
 — —, — longum I. 231, 263, 264
 — femoris I. 288, 289, 292, 293, 301, 302, 307, 308, 309, 339, III. 167, 173, 174, 176
 — —, caput breve I. 294
 — —, — longum I. 293, 294
 — brachialis I. 264, 265, 266, 268, 270, 271, 272, 273, 276, 333, 334, 343, 344, III. 129, 135, 137, 138, 139
 — brachioradialis I. 263, 264, 265, 266, 267, 269, 270, 271, 272, 273, 274, 275, 276, 277, 282, 334, 335, III. 127, 135, 136, 138, 139
 — buccinator I. 215, 216, 217, 218, 219, 324, 326, II. 4, 24, 27, 33, 35, 36, 87, III. 107, 114, 122, 186
 — bulbi III. 231, 232, 233, 234
 — bulbospongiosus, m. bulbocavernosus II. 135, 150, 154, 155, 169, 172, III. 160, 162, 190
 — — femininus II. 169, 172
 — — masculinus II. 135, 150, 154, 155
 * — capitis I. 215—220, 324—328
 — ciliaris III. 219
 — coccygeus I. 246, 247, II. 171, 175, 176
 * — colli I. 221—226, 256—258
 * — compressor bulbi (musculi bulbospongiosi) II. 150, 155
 — — naris I. 324
 * — — radialis (musculi bulbospongiosi) II. 150, 155
 — constrictor pharyngis inferior, vide etiam: pars ericopharyngea, thyropharyngea musculi constrictoris pharyngis inferioris I. 229, II. 24, 28, 32, 187, III. 108, 186
 — — — medius, vide etiam: pars ceratopharyngea, chondropharyngea musculi constrictoris pharyngis medii I. 328, II. 24, 27, 28, 32, 187
 — — — superior, vide etiam: pars buccopharyngea, glossopharyngea, mylopharyngea, pterygopharyngea musculi constrictoris pharyngis superioris II. 24, 32, 36, III. 186
 — coracobrachialis I. 231, 263, 264, 265, 266, 332, 333, III. 126, 129, 137
 — corrugator supercilii I. 215, 324
 — eremaster I. 240, 242, II. 148, 149
 * — —, crus laterale I. 241
 * — —, — mediale I. 241
 * — ericoarytenoideus lateralis, m. ericoarytaenoideus II. 102, 105
 — — posterior II. 101, 102
 — ericothyroideus, m. ericothyreoideus I. 224, 225, 229, II. 28, 33, 100, 102, 105, 186, III. 120, 121, 122, 123
 — deltoideus I. 230, 231, 232, 251, 252, 263, 264, 267, 268, 329, 330, 331, 332, 333, 334, III. 128, 134, 125, 136, 137
 — depressor anguli oris, m. triangularis I. 215, 216, 217, 218, 219, 227, 229, 324, III. 107, 112
 — labii inferioris, m. quadratus labii inf. I. 215, 216, 217, 218, 324, II. 4
 — — supercilii I. 215
 * — diaphragmaticus, vide: diaphragma

- musculus digastricus, vide etiam: venter anterior.
 posterior I. 220, 222, 223, 224, 225, 229, 325, 326, II. 23, 24, 25, 27, 28, 32, 33, 36, III. 118, 119, 120, 121, 123, 186
 — dilator pupillae, *m. dilatator pupillae* III. 219
 * — dorsales scapulae I. 267, 268, 269
 * — dorsi I. 251–275, II. 81, III. 150
 * — — pedis I. 310, 311
 * — — profundi I. 252–257
 * — — superficiales I. 251
 — erector spinae, *m. sacrospinalis* I. 239, 251, 253, 254
 * — extensores antebrachii III. 127
 * — — — profundi I. 275, 276
 * — — — superficiales I. 274
 * — — brachii III. 127
 — — carpi radialis brevis I. 274, 275, 276, 277, 284, 333, 338, III. 127, 135, 138, 139
 — — — longus I. 267, 269, 271, 272, 273, 274, 275, 276, 277, 283, 284, 333, 338, III. 127, 135, 138, 139
 — — — ulnaris I. 274, 275, 283, 284, 336, 337, III. 127
 * — — cruris I. 307, 308, 309
 — — digitorum, *m. extensor digitorum comm.* I. 274, 277, 283, 338, III. 127, 135, 142
 — — — brevis I. 307, 308, 309, 310, 311, 345, III. 166, 180
 — — — longus I. 307, 308, 309, 310, 311, 343, III. 166, 176, 180
 — — — minimi, *m. extensor digiti quinti propr.* I. 274, 275, 283, 284
 * — — femoris I. 296, 297, 298, 299, 300, III. 166
 — — hallucis brevis I. 307, 310, 311, 319, III. 166
 — — — longus I. 307, 308, 309, 310, 311
 — — indicis, *m. extensor indicis propr.* I. 275, 336
 — — pollicis brevis I. 274, 275, 276, 277, 283, 284, 338, III. 127, 135, 138, 139
 — — — longus I. 275, 276, 277, 283, 284, 336, 338, III. 127, 135
 * — flexores antebrachii I. 264, III. 130, 131, 136
 * — — — profundi I. 272, 273
 * — — — superficiales I. 270, 271
 * — — — brachii I. 263, 264, 265, III. 129
 * — — — profundi I. 264, 265
 * — — — superficiales I. 263
 — — carpi radialis I. 185, 270, 271, 272, 273, 281, 282, 333, 337, III. 138, 139, 140, 141
 — — — ulnaris I. 185, 270, 271, 272, 273, 282, 335, 336, 337, 338, III. 130, 131, 137, 138, 139, 140, 141
 * — — cruris I. 301, 302, 304, 305,
 — — digitorum brevis I. 313, 314, 315, 316, 346, III. 167
 — — — longus I. 304, 305, 314, 315, 316, 344, 346, III. 177, 181
 — — — minimi manus brevis, *m. flexor digiti quinti brevis* I. 279, 280, 281, 337, III. 131, 140, 141
 — — — — pedis brevis *m. flexor digiti quinti brevis* I. 15, 346 III. 167
 — — — profundus I. 272, 273, 274, 275, 277, 279, 285, 335, 336, 337, III. 131, 139
 — — — superficialis, *m. flexor digitorum sublimis* I. 271, 272, 273, 277, 279, 280, 285, 335, 337, III. 130, 138, 139, 140
 * — — femoris I. 292, 293, 291, III. 167
 — — hallucis brevis III. 167
 — — — — caput mediale I. 315, 345
 — — — — caput laterale I. 315
 — — — longus I. 304, 305, 313, 314, 315, 316, 344, 345, 346, III. 167, 177, 181
 — — pollicis brevis I. 279, 280, 281, 337, III. 130, 131, 140
 — — — longus I. 271, 272, 273, 280, 335, 337, III. 130, 139
- musculus frontalis*, vide: venter frontalis
 — gastrocnemius III. 167
 — — — caput laterale I. 202, 292, 293, 294, 301, 302, 303, 304, 305, 307, 308, 309, 341, 342
 — — — — mediale I. 202, 292, 293, 294, 301, 302, 303, 304, 305, 342
 — genellus inferior I. 289, 290, 291, 340, III. 172, 173
 — — superior I. 289, 290, 291, 339, III. 172, 173
 — genioglossus I. 325, II. 24, 25, 26, 28, 88, III. 122
 — geniohyoideus I. 225, 325, 326, 328, II. 24, 25, 26, 88
 — glossopalatinus, vide: musculus palatoglossus
 — glutei, vide: musculi glutei
 * — glutei, *mm. glutei* III. 172
 — gluteus (*glutaeus*) maximus I. 251, 252, 253, 287, 288, 289, 290, 292, 293, 294, 339, 342, III. 160, 161, 162, 163, 172, 173, 174, 189
 — — — medius I. 289, 290, 293, 299, 300, 339, 342, III. 172, 173
 — — — minimus I. 290, 339, 341, III. 172, 173
 — gracilis I. 292, 293, 294, 296, 297, 298, 299, 300, 301, 302, 339, 343, III. 160, 165, 170, 171, 174
 — helcis major III. 240
 — — minor III. 240
 — hyoglossus I. 222, 223, 224, 328, II. 23, 24, 25, 27, 28, 33, III. 122, 186
 — hyopharyngeus I. 327
 — iliacus I. 239, 245, 247, 250, 299, 300, 340, II. 134, 169, III. 159, 164, 166, 171, 188, 206, 215
 — iliococcygeus II. 174
 — iliocostalis cervicis I. 252, 253
 — — lumborum I. 252, 253
 — — thoracis, *m. iliocostalis dorsi* I. 252, 253,
 — iliopsoas I. 244, 296, 297, 298, 299, 341, 342, II. 135, III. 170
 — incisivus I. 324
 — infrahyoidei I. 222, 223, 224
 — infraspinalis I. 267, 268, 269, 331, 334, III. 134
 * — intercostales I. 234, II. 185, III. 90, 187
 — — externus I. 233, 234, 236, 258, 322, 323, II. 180, III. 150
 — — internus I. 233, 234, 236, 322, 323, II. 180, III. 149, 150
 — interossei dorsales manus I. 283, 284, 338
 — — — I. I. 276, 277, 281, 282, 338, III. 131, 143
 — — — — II. I. 281, 282, 338, III. 131
 — — — — III. I. 281, 282, 338
 — — — — IV. I. 281, 282, 338
 — — — pedis I. 311, 345
 — — — — I. I. 316, 345
 — — — — II. I. 316, 345
 — — — — III. I. 316, 345
 — — — — IV. I. 316, 345
 — — palmaris I., *m. interosseus volaris* I. I. 281, 282, 337
 — — — II., *m. interosseus volaris* II. I. 281, 282, 337
 — — — III., *m. interosseus volaris* III. I. 281, 282, 337
 — — — pedis I. 315, III. 167
 — — plantaris I. I. 316, 346
 — — — II. I. 316, 346
 — — — III. I. 316, 346
 — interspinales I. 256
 — — cervicis I. 253, 255
 — — lumborum I. 255
 * — intertransversarii I. 234, 255, 257
 * — — posteriores I. 256
 — ischioavernosus II. 135, 150, 154, 155, 160, 172, III. 162
 — — (femininus) II. 169, 172
 — — (masculinus) II. 135, 150, 154, 155, III. 162
 — larynx II. 100–103

- musculus latissimus dorsi *I.* 230, 231, 232, 233, 239, 251, 252, 253, 263, 264, 265, 267, 333, 340, *III.* 163
 levator anguli oris, *m. caninus I.* 215, 217, 324, 326
 — ani *I.* 246, 247, 340, *II.* 61, 135, 138, 151, 154, 169, 173, *IV.* 175, 176, *III.* 159, 161, 162, 189, 190
 — costarum breves *I.* 254, 255, 256
 — longi *I.* 254, 255, 256
 — labii superioris, *caput infraorbitale m. quadrati labii sup. I.* 215, 216, 324, 326
 — — — aequae nasi, *caput angulare m. quadrati labii sup. I.* 215, 216, 217, 324
 — palpebrae superioris *II.* 87, *III.* 98, 101, 229, 231, 232, 234
 — scapulae *I.* 222, 223, 224, 225, 233, 251, 252, 253, 254, 263, 264, 265, 331, *III.* 118, 120, 122
 — veli palatini *I.* 326, *II.* 23, 25, 31, 33
 * — linguae *II.* 23, 24
 — longissimus capitis *I.* 253, 254, 326, *II.* 36
 — — cervicis *I.* 252, 253, 254
 — — dorsii, vide: musculus longissimus thoracis
 — — thoracis, *m. longissimus dorsii I.* 252, 253, 254, *III.* 163
 — longitudinalis inferior linguae *II.* 25
 — superior linguae *II.* 25, 36
 — longus capitis *I.* 223, 225, 226, 326, *II.* 36, 117
 — — colli *I.* 225, 226, *II.* 36
 — lumbricales manus *I.* 280
 — — *I.* *I.* 277, 279, *III.* 130, 140
 — — *II.* *III.* 130
 — — *III.* *III.* 131
 — — *IV.* *III.* 131
 — — pedis *I.* 314
 — — *I.* *III.* 167
 — — *II.* *III.* 167
 — — *III.* *III.* 167
 — — *IV.* *III.* 167
 — masseter *I.* 217, 222, 223, 224, 225, 324, 326, *II.* 35, 36, 87, *III.* 107, 118, 119, 120, 121, 123
 * — masticatorii profundi *I.* 219
 * — superficiales *I.* 217
 — membri (*extremitatis*) inferioris *I.* 287—319, 339—346
 — — superioris *I.* 259—286, 329—338
 — mentalis *I.* 215, 324
 — multifidus *I.* 255, 256
 — mylohyoideus *I.* 220, 222, 223, 224, 225, 229, 325, 328, *II.* 23, 24, 25, 26, 27, 28, 33, 88, *III.* 118, 119, 120, 121, 123, 186
 — nasalis *I.* 217
 — —, musculus compressor naris, *m. nasalis, pars transversa I.* 215, 216
 — — — dilator naris, *m. nasalis, pars alaris I.* 215
 — obliquus atlantis, musculus obliquus capitis inferior *I.* 254, 255, 256, *II.* 36, *III.* 163
 — — auriculae *III.* 241
 — — capitis, musculus obliquus capitis superior *I.* 254, 255, 256, 258, 326, *III.* 163
 — — inferior, vide: *musculus obliquus atlantis*
 — — superior, vide: *musculus obliquus capitis*
 — — externus abdominis *I.* 230, 231, 232, 233, 235, 238, 239, 241, 242, 243, 244, 245, 248, 249, 250, 251, 252, 339, *II.* 50, 135, 148, *III.* 148
 — — inferior (bulbi) *III.* 101, 230, 233, 234
 — — internus abdominis *I.* 236, 238, 239, 242, 243, 244, 248, 249, 250, 251, 253, 340, *II.* 50, 135, 148, *III.* 148
 — — superior (bulbi) *II.* 87, *III.* 98, 99, 100, 229, 230, 231, 232
 — obturator externus *I.* 291, 299, 300, *III.* 165
 — — internus *I.* 247, 289, 290, 291, 339, 340, *II.* 135, 169, 175, 176, *III.* 159, 172, 173
 — occipitalis, vide: venter occipitalis
 musculus occipitofrontalis, *m. frontalis et m. occipitalis*, vide etiam: venter frontalis, occipitalis *I.* 215, 216, 217, *III.* 107, 112
 — — omohyoideus *II.* 24, 25, *III.* 118, 119, 120, 121, 122
 — —, venter inferior *I.* 222, 223, 224, 228, 263, 264, 265, 328, 331, *III.* 118, 119, 120, 121, 122
 — —, — superior *I.* 222, 223, 224, 228 *III.* 118, 119
 — — opponens digiti minimi manus, *m. opponens digiti quinti I.* 280, 281, 337, *III.* 131, 141
 — — — pedis, *m. opponens digiti quinti I.* 315, 346
 — — pollicis *I.* 280, 281, 282, 337, *III.* 130, 141
 — orbicularis oculi *I.* 215, 216, 217, 324, *II.* 35, *III.* 107, 112
 — — oris *I.* 215, 216, 217, 218, 219, 324, *II.* 4, 30, 36, *III.* 112
 — — —, pars labialis *I.* 215
 — — —, — marginalis *I.* 215
 — palatoglossus, *m. glossopalatinus II.* 25, 30, 36
 — palatopharyngeus, *m. pharyngopalatinus II.* 30, 31, 36
 * — palmares *I.* 279, 280, 281, 282, *III.* 130, 131
 — — brevis *I.* 270, 271, 272, 273, 278
 — — longus *I.* 270, 271, 272, 278, *III.* 138, 139
 — papillaris anterior ventriculi dextri, *m. papillaris ventralis II.* 193, 194, 204
 — — — sinistri, *m. papillaris sin. II.* 195, 196, 197, 198, 203, 205
 — — cordis *II.* 193, 194, 195, 196, 197, 198, 203, 204, 205
 — — posterior ventriculi dextri, *mm. papillares parvi II.* 193, 194, 204
 — — — sinistri, *m. papillaris dext. II.* 195, 196, 197, 198, 203, 205
 — — septales ventriculi dextri, *mm. papillares parvi II.* 193, 194
 — pectinati *II.* 192, 193
 — pectineus *I.* 245, 296, 297, 298, 299, 339, 342, *III.* 166, 170, 171
 — pectoralis major *I.* 222, 223, 231, 235, 259, 263, 264, 320, 329, 330, 333, 340, *II.* 179, 180, 185, 212, *III.* 148
 — — —, pars abdominalis *I.* 230, 231, 232
 — — —, — clavicularis *I.* 230, 232
 — — —, — sternocostalis *I.* 230, 231, 232
 — — minor *I.* 231, 260, 263, 266, 320, 332, *II.* 180, 212, *III.* 148
 * — pelvis *I.* 246, 247
 — — peronaei, vide: musculus peronei
 * — peronei, *mm. peronaei I.* 308, 309, *III.* 166
 — peroneus (*peronaeus*) brevis *I.* 304, 305, 307, 308, 309, 310, 311, 315, 317, 319, 343, *III.* 166, 176
 — — — longus *I.* 304, 305, 307, 308, 309, 310, 311, 315, 316, 319, 343, 344, 346, *III.* 166, 176, 177, 180, 181
 — — — tertius *I.* 307, 308, 310, 319, 345, *III.* 180
 * — pharyngis *II.* 24, 32, 33
 — pharyngopalatinus, vide: musculus palatopharyngeus
 — piriformis *I.* 246, 247, 289, 290, 291, *II.* 166, 176, *III.* 159, 160, 161, 164, 172, 173, 189
 * — plantae *I.* 214
 * — — profundi *I.* 315, 316
 * — — superficiales *I.* 313, 314
 * — plantaris *I.* 294, 302, 303, 342, *III.* 167, 177
 * — popliteus *I.* 202, 294, 304, 305, 344, *III.* 174
 — procerus *I.* 215, 216
 — pronator quadratus *I.* 266, 272, 273, 281, 282, 335, 336 *III.* 130, 141
 — — teres *I.* 263, 270, 271, 333, 335, 336, *III.* 130, 138
 — psoas major *I.* 239, 245, 247, 248, 250, 299, 300, *II.* 74, 78, 79, 81, 134, *III.* 158, 159, 161, 164, 166, 171, 188, 206, 215

- musculus psoas major sinister *III.* 189, 191
 — — minor *I.* 246, 247, 248, 250
 * — pterygoidei *I.* 220, *II.* 27
 — — *externus*, vide: musculus pterygoideus lateralis
 — — *internus*, vide: musculus pterygoideus medialis
 — — lateralis, *m. pterygoideus ext. I.* 218, 219, 220, 325, 326, *II.* 27, 31
 — — medialis, *m. pterygoideus int. I.* 219, 220, 325, 326, *II.* 27, 31, 32, 36, *III.* 103, 106
 — pubococcygeus *II.* 171
 — puboprostaticus *II.* 143
 — puborectalis *II.* 171
 — pubovaginalis *II.* 171
 — pyramidalis *I.* 235, 237, 243, 339, *III.* 161
 — quadratus femoris *I.* 289, 290, 293, 294, 339, 342, *III.* 173
 — — *labii inferioris*, vide: musculus depressor labii inferioris
 — — — *superioris*, vide: musculus levator labii superioris, musculus levator labii superioris alaeque nasi, musculus zygomaticus minor
 — — lumborum *I.* 239, 250, 340, *II.* 134, *III.* 158, 164, 188, 206
 — — plantae (musculus flexor accessorius) *I.* 314, 315, 345, 346, *III.* 167, 168, 181
 — quadriceps femoris *I.* 200, 201, 206, 207, 343
 — rectouterinus *II.* 166
 — rectus abdominis *I.* 235, 236, 237, 238, 243, 244, 320, 339, *II.* 81, *III.* 148, 159, 161
 — — capitis anterior *I.* 226, 326
 — — — lateralis *I.* 226, 326
 — — — posterior major *I.* 254, 255, 256, 258, 326, *III.* 163
 — — — — minor *I.* 254, 255, 256, 258, 326, *II.* 36
 — — femoris *I.* 295, 296, 297, 298, 299, 300, 339, *III.* 166, 170, 171
 — — inferior (bulbi) *II.* 87, *III.* 229, 230, 234, 238
 — — — lateralis (bulbi) *II.* 87, *III.* 98, 99, 100, 221, 229, 230, 231, 232, 231, 239
 — — — medialis (bulbi) *II.* 87, *III.* 99, 100, 229, 230, 231, 232, 233, 239
 — — — superior (bulbi) *II.* 87, *III.* 98, 99, 100, 101, 216, 229, 230, 231, 232, 233, 234
 — rhomboideus major *I.* 251, 331
 — — minor *I.* 251, 331
 — risorius *I.* 215, 216
 — *rotatores breves I.* 255, 256
 * — femoris *I.* 289, 290, 291, 293
 — — *longi I.* 255, 256
 — *sacrospinalis*, vide: musculus erector spinae
 — salpingopharyngeus *II.* 32
 — sartorius *I.* 287, 292, 293, 294, 295, 296, 297, 298, 299, 300, 301, 302, 339, 340, 343, *III.* 166, 170, 171
 * — *scaleni I.* 257, 258
 — scalenus anterior *I.* 222, 223, 224, 225, 226, 233, 252, 257, 258, 322, *II.* 117, 120, *III.* 119, 120, 121, 122, 123, 125, 151
 — — medius *I.* 222, 223, 224, 225, 226, 233, 252, 257, 258, 322, *II.* 117, 120, *III.* 119, 120, 121, 122, 123, 125
 — — posterior *I.* 222, 223, 224, 225, 226, 233, 252, 257, 258, 323, *II.* 117, 120
 — semimembranosus *I.* 202, 290, 292, 293, 294, 298, 301, 302, 303, 304, 305, 339, 344, *III.* 167, 174, 177
 — semispinalis capitis *I.* 251, 252, 253, 257, 258, 324, 326, *III.* 163
 — — cervicis *I.* 254, 256
 — — thoracis, *m. semispinalis dorsi I.* 254
 — semitendinosus *I.* 292, 293, 294, 301, 302, 339, 343, *III.* 167, 173, 174, 177
 — serratus anterior *I.* 230, 231, 232, 233, 235, 236, 237, 251, 263, 264, 265, 322, 323, 332, *II.* 179
 musculus serratus posterior inferior *I.* 251, 252
 — — — superior *I.* 252
 — — soleus *I.* 294, 301, 302, 303, 304, 307, 308, 309, 344, *III.* 167, 174, 176, 177
 — sphincter ampullae hepatopancreaticae *II.* 53
 — — ani externus *I.* 246, *II.* 61, 62, 143, 154, 164, 172, 173, 176, *III.* 160, 161, 162
 — — — internus *II.* 62, 143, 172
 — — pupillae *III.* 219, 220
 — — pylori *II.* 42, 43, 44
 — — urethrae, *m. sphincter urethrae membranacea II.* 143, 151, 155, 173
 * — — vaginae *II.* 173
 — — vesicae, *m. sphincter urethrae int. II.* 139, 140
 — spinalis cervicis *I.* 254
 — — thoracis, *m. spinalis dorsi I.* 252, 253, 254
 — splenius capitis *I.* 216, 222, 223, 251, 252, 324, 326, *II.* 36, *III.* 163
 — — cervicis *I.* 252, 253
 — stapedius *III.* 106, 252, 254
 — sternocleidomastoideus *I.* 216, 217, 218, 221, 222, 223, 224, 225, 227, 228, 230, 231, 232, 251, 320, 324, 326, 329, *II.* 25, 27, 35, 36, *III.* 107, 108, 109, 112, 116, 117, 118, 119, 120, 121, 122, 123, 197
 — sternohyoideus *I.* 222, 223, 224, 321, 328, *II.* 24, 25, *III.* 118, 119
 — sternothyroideus, *m. sternothyroideus I.* 222, 223, 224, 225, 321, *II.* 24, *III.* 118, 119
 — styloglossus *I.* 324, 326, *II.* 23, 24, 25, 27, 28, 33, 36
 — stylohyoideus *I.* 222, 223, 224, 225, 229, 328, 330, *II.* 23, 24, 25, 27, 28, 32, 36
 — stylopharyngeus *I.* 324, 326, *II.* 23, 25, 31, 32, 33, 36, *III.* 112
 — subclavius *I.* 231, 260, 320, 322, 330
 — subcostales *I.* 234, 322, 323
 * — suboccipitales *I.* 256, 258
 — subs capularis *I.* 173, 263, 261, 265, 266, 332, 333, *III.* 136, 137
 — supinator *I.* 266, 273, 275, 276, 333, 335, 336, *III.* 135
 — suprahyoidei *I.* 222, 223, 221, 225, *II.* 24, 27, 28
 — supraspinatus *I.* 251, 252, 267, 268, 269, 333, *III.* 134, 136
 — temporalis *I.* 218, 324, 326, *II.* 25, 87, *III.* 114, 229, 239
 — tensor fasciae latae *I.* 287, 288, 296, 297, 298, *III.* 170, 172
 — — tympani *III.* 252, 253
 — — veli palatini *I.* 326, *II.* 23, 25, 31, 33
 — teres major *I.* 251, 263, 264, 265, 266, 267, 268, 269, 331, 333, *III.* 134, 135, 137
 — — minor *I.* 267, 268, 269, 331, 334, *III.* 128, 134
 — thoracis *I.* 230, 231, 231
 — thyroarytenoideus, *m. thyroarytenoideus ext. II.* 102, 105
 — thyroepiglotticus, *m. thyroepiglotticus II.* 102, 103, 105
 — thyrohyoideus, *m. thyrohyoideus I.* 223, 224, 225, 327, *II.* 24, *III.* 119
 — tibialis anterior *I.* 211, 307, 308, 309, 310, 311, 343, 346, *III.* 166, 176
 — — posterior *I.* 211, 304, 305, 316, 344, 346, *III.* 167
 — tragiacus *III.* 240
 — transversus abdominis *I.* 237, 238, 239, 242, 243, 244, 248, 249, 250, *II.* 50, 134, 135, 148, *III.* 148
 — — auriculae *III.* 241
 — — linguae *II.* 25, 36
 — — menti *I.* 215
 — — perinei profundus *I.* 340, *II.* 155, 169, *III.* 176, *III.* 190
 — — — superficialis *II.* 154, 172, *III.* 162

- musculus transversus thoracis *I.* 320, *III.* 148
 — trapezius *I.* 222, 223, 224, 225, 230, 231, 232, 251, 252, 324, 325, 326, 329, 330, 331, *II.* 36, *III.* 117, 118, 119, 120, 121, 122, 163
 — *triangularis*, vide: musculus depressor anguli oris
 — triceps brachii *I.* 267, 268, 269, 274, 336, *III.* 127, 135, 136, 137
 — — —, caput laterale *I.* 267, 268, 269, 334
 — — —, — longum *I.* 266, 267, 268, 269, 331, 332
 — — —, — mediale *I.* 263, 264, 265, 266, 267, 269, 334
 * — trunci *I.* 230, 231, 232—235, 320—323
 — uvulae *II.* 30, 31, 36
 — vastus intermedius *I.* 298, 299, 300, 341, 342
 — — lateralis *I.* 296, 297, 298, 299, 300, 308, 309, 341, 342, *III.* 166, 170, 171
 — — medialis *I.* 295, 296, 297, 298, 299, 300, *III.* 166, 170
 — verticalis linguae *II.* 25
 — vocalis *II.* 103, 105
 — *zygomaticus*, vide: musculus zygomaticus major
 — — major, *m. zygomaticus I.* 215, 216, 324, 326, *II.* 35, *III.* 112
 — — minor, *caput zygomaticum m. quadrati labii sup. I.* 215, 216, 324, 326, *III.* 112
 *myeloarchitectura *III.* 49—55
 myelencephalon *III.* 31, 36
 myocardium *II.* 200—203
 myologia *I.* 215—318
 myometrium, vide: tunica muscularis uteri
- N
- nares *II.* 2, 82, 85
 nasus *II.* 82
 *nephros (gr.), vide: ren
 nervus (-i)
 — I., vide: nervus olfactorius
 — II., vide: nervus opticus
 — III., vide: nervus oculomotorius
 — IV., vide: nervus trochlearis
 — V., vide: nervus trigeminus
 — V/1., vide: nervus ophthalmicus
 — V/2., vide: nervus maxillaris
 — V/3., vide: nervus mandibularis
 — VI., vide: nervus abducens
 — VII., vide: nervus facialis
 — VIII., vide: nervus vestibulocochlearis
 — IX., vide: nervus glossopharyngeus
 — X., vide: nervus vagus
 — XI., vide: nervus accessorius
 — XII., vide: nervus hypoglossus
 — abducens (n. VI.) *II.* 25, *III.* 1, 26, 35, 73, 95, 96, 97, 98, 99, 100
 — accessorius (n. XI.), vide etiam: radices craniales, spinales *III.* 1, 26, 35, 83, 85, 95, 96, 108, 109, 116, 117, 118, 119, 120, 121, 124, 186
 — *acusticus*, vide: nervus vestibulocochlearis
 — alveolaris inferior *II.* 27, 36, *III.* 102, 103, 114, 115, 122
 — — *superiores*, vide: rami alveolares superiores anteriores et posteriores
 — ampullaris *III.* 262
 * — anterior, *n. ampullaris sup. III.* 254, 260
 — — lateralis *III.* 254, 260
 — — posterior *III.* 260
 — — *superior*, vide: nervus ampullaris anterior
 — anteriores antebrachii *III.* 138, 139
 — — brachii *III.* 136, 137
 * — auricularis magnus *III.* 107, 112, 113, 116, 117, 118, 185
 — — posterior *III.* 112, 113
 — auriculotemporalis *II.* 27, *III.* 102, 103, 107, 112, 113, 114, 115
 * — nervi auris internae *III.* 260
 — — axillaris *III.* 125, 126, 127, 128, 132, 134, 185
 — — buccalis, *n. buccinatorius III.* 102, 107, 112, 114, 115
 — — canalis pterygoidei, *n. canalis pterygoidei (Vidii) III.* 105
 — — *cardiaci*, vide: nervi cardiaci cervicales
 — — cervicales inferiores, *nn. cardiaci inf. III.* 153, 186, 187
 — — — medii, *n. cardiacus medius III.* 108, 121, 122, 123, 153
 — — — superiores, *nn. cardiaci sup. III.* 121, 122, 123, 151
 — — caroticotympanici *III.* 106, 252
 — — caroticus internus *III.* 108, 186
 — — *cerebrales*, vide: nervi craniales
 * — cervicales, vide: nervi spinales
 * — cervicofacialis *III.* 107, 112
 — — ciliares breves *III.* 100, 101
 — — longi *III.* 98, 99, 100
 — — clunium inferiores *III.* 162, 168, 174, 185
 — — — medii *III.* 163, 168, 185
 — — — superiores *III.* 163, 168, 185
 — — coccygeus *III.* 83, 86, 87, 164
 * — colli *III.* 116, 117, 118, 119, 120, 121, 122, 123, 124, 125
 — — craniales, *nn. cerebrales III.* 1, 95—109, 112—115
 * — cruris anteriores *III.* 176
 * — — posteriores *III.* 177
 * — cutanei antebrachii *III.* 147
 — — — lateralalis, *n. cutaneus antebrachii lat. III.* 129, 132, 133, 137, 146, 147
 — — — — medialis, *n. cutaneus antebrachii med. III.* 125, 126, 132, 133, 146, 147
 — — — — posterior, *n. cutaneus antebrachii dors. III.* 133
 * — — brachii *III.* 116
 — — — — lateralalis inferior *III.* 132, 147
 — — — — — superior *III.* 128, 132
 — — — — — medialis *III.* 125, 126, 132, 133, 137, 146, 147
 — — — — — posterior *III.* 133
 * — — capitis *III.* 185
 — — — colli, vide: nervus transversus colli
 * — — cruris *III.* 178, 179
 — — — dorsalis intermedius *III.* 176, 180, 183
 — — — — lateralalis *III.* 180
 — — — — — medialis *III.* 176, 180, 183
 * — — femoris *III.* 175
 — — — — anteriores *III.* 175
 — — — — lateralalis *III.* 158, 159, 164, 169, 170, 171, 185, 215
 — — — — — posterior *III.* 162, 164, 168, 173, 174, 179, 185
 * — — membri inferioris *III.* 168, 169
 * — — — superioris *III.* 132, 133
 * — — pedis *III.* 178, 183
 — — — surae lateralis *III.* 168, 169, 174, 177, 179
 — — — — medialis *III.* 168, 169, 174, 177, 179
 * — — trunci *III.* 185
 — — digitales dorsales manus *III.* 142, 143
 * — — — pollicis *III.* 142, 143
 — — — palmares (n. mediani), *nn. digitales volares III.* 132, 133, 140, 141
 — — — — (n. ulnaris) *III.* 132, 140, 141
 — — — — communes *III.* 130, 140, 141
 — — — — proprii *III.* 130, 140, 141, 143
 — — — plantares communes *III.* 181
 — — — — proprii *III.* 181
 — — — *volares*, vide: nervi digitales palmares
 — — dorsalis penis *II.* 162, *III.* 160, 162, 189
 — — scapulae *III.* 119, 120, 121, 122, 125
 * — dorsi manus *III.* 142, 143
 * — — pedis *III.* 180
 — — erigentes, vide: nervi splanchnici pelvini

- nervus ethmoidalis anterior *III*. 98, 99, 100, 104, 105
 — posterior *III*. 98, 99, 100
 — facialis (n. V/1.) *II*. 27, 36, 181, *III*. 1, 26, 34, 35, 73, 85, 95, 96, 101, 102, 103, 106, 107, 108, 112, 113, 114, 115, 122, 186, 252, 253, 254, 268
 —, genu internum *III*. 38
 * — faciei *III*. 113, 111, 115
 — femoralis *I*. 244, 245, *II*. 135, *III*. 159, 164, 166, 168, 169, 170, 171, 175, 178, 185
 * — femoris anteriores *III*. 170, 171
 * — — posteriores *III*. 173, 171
 — frontalis *III*. 98, 101, 102, 115, 229
 — genitofemoralis *II*. 51, 52, *III*. 158, 159, 164, 169, 171, 185
 — glossopharyngeus (n. IX.) *II*. 36, *III*. 1, 26, 35, 73, 85, 95, 96, 106, 108, 109, 122, 124, 186, 252
 — glutens (*glutaceus*) inferior *III*. 164, 172, 173
 — — superior *III*. 164, 172, 173
 — haemorrhoidales, vide: nervi rectales
 — hypogastricus *III*. 189
 — hypoglossus (n. XII.) *II*. 27, 36, *III*. 1, 26, 35, 53, 54, 73, 85, 95, 96, 108, 109, 121, 122, 123, 124, 186
 — iliopogastricus *III*. 158, 164, 185
 — ilioinguinalis *I*. 241, *III*. 158, 164, 170, 171, 188
 — infraorbitalis *III*. 101, 102, 107, 112, 114, 115, 229
 — infratrochlearis *III*. 98, 99, 100, 236
 — intercostales *II*. 180, *III*. 125, 148, 150, 152, 153, 185, 186, 187
 — — (Th. 1.) *III*. 125
 — — (Th. 2.) *III*. 125
 — intercostobrachialis *III*. 125, 126, 146
 — intermedius *III*. 1, 95, 186
 — interosseus anterior antebrachii, n. *interosseus col.* *III*. 130, 139
 — — posterior antebrachii, n. *interosseus dors.* *III*. 135
 — ischiadicus *III*. 160, 161, 164, 167, 172, 173, 171
 — jugularis *III*. 186
 — lacrimalis *III*. 98, 102
 — laryngeus recurrens, n. *recurrens III*. 121, 122, 123, 126, 186, 187
 — — dexter *III*. 126, 152
 — — sinister *III*. 153
 — — superior *II*. 28, 33, *III*. 108, 120, 121, 122, 123
 — lingualis *II*. 27, *III*. 102, 103, 114, 115, 122, 186
 * — lumbales, vide: nervi spinales
 — mandibularis (n. V/3.) *II*. 181, *III*. 1, 95, 96, 97, 98, 99, 100, 101, 102, 103, 106, 113, 115, 185, 186
 — massetericus *III*. 114
 — masticatorius *II*. 27, *III*. 102
 — maxillaris (n. V/2.) *II*. 181, *III*. 1, 95, 96, 97, 98, 99, 100, 101, 102, 104, 105, 106, 112, 185, 186
 — medianus *III*. 125, 126, 129, 130, 131, 132, 133, 136, 137, 138, 139, 140, 141
 — mentalis *III*. 102, 107, 114, 122
 — musculocutaneus *III*. 125, 126, 129, 131, 132, 133, 136, 137
 — mylohyoideus *III*. 102, 103, 118, 119, 120, 121, 123
 — nasociliaris *III*. 98, 99, 100, 101, 102
 — nasopalatinus, n. *nasopalatinus (Scarpa)* *III*. 101
 — obturatorius *II*. 176, *III*. 159, 161, 164, 165, 179, 185
 — — dexter *III*. 189
 — occipitalis major *III*. 113, 163, 185
 — — minor *III*. 107, 112, 113, 116, 117, 118, 163, 185
 — — tertius *III*. 163, 185
 * — taurus, vide: nervus vestibulocochlearis
 — oculomotorius (n. III.) *II*. 25, 181, *III*. 1, 20, 21, 22, 26, 35, 72, 73, 78, 95, 96, 97, 98, 99, 100, 101, 186
 — nervi olfactorii, *fila olfactoria III*. 1, 95, 101, 105
 — — ophthalmicus (n. V/1.) *II*. 25, 181, *III*. 1, 95, 96, 97, 99, 100, 102, 106, 185, 186
 — — opticus (n. II.) *II*. 87, 181, 182, 183, *III*. 1, 8, 26, 78, 95, 96, 97, 98, 99, 100, 101, 103, 104, 105, 216, 217, 218, 219, 221, 229, 231, 232, 239
 — — sinister *III*. 10
 — — palatini *III*. 101, 103, 105, 186
 — — — major, n. *palatinus ant.* *III*. 105
 — — — minores, n. *palatinus medius*, n. *palatinus post.* *III*. 105
 — — palmae manus *III*. 110, 111
 * — palmaris proprius indicis, n. *col. propr. indicis III*. 110
 * — papillaris cutis *III*. 268
 * — parietalis pelvis *III*. 159
 * — parietis anterioris trunci *III*. 118
 * — — lateralis cavi nasi *III*. 105
 * — pectoralis lateralis, n. *thoracalis post.* *III*. 120, 125
 — — medialis, n. *thoracalis ant.* *III*. 120, 125
 — — perineales, n. *perinei III*. 189
 * — perinci *III*. 162
 * — peripheriales, vide etiam: systema nervosum periphericum *III*. 90
 * — peronei, n. *peronaci III*. 166
 — — peroneus (*peronaceus*) communis *III*. 166, 167, 168, 169, 171, 177
 — — — profundus *III*. 166, 169, 176, 180, 183
 — — — superficialis *III*. 166, 169, 176, 180, 183
 * — petrosi *III*. 106
 — — — major, n. *petrosus spf. major III*. 101, 103, 106
 — — — minor, n. *petrosus spf. minor III*. 103, 106
 — — — superficialis, vide: nervus petrosus
 — — phrenicus *I*. 229, *II*. 120, 216, 217, *III*. 119, 120, 121, 122, 123, 152, 186
 — — — dexter *II*. 214, 215, 216, *III*. 126, 151
 — — — sinister *II*. 214, 215, 216, *III*. 151, 153
 * — pili *III*. 268
 * — plantae pedis *III*. 181
 — — plantaris lateralis *III*. 167, 168, 181
 — — — medialis *III*. 167, 168, 181
 * — posteriores membri superioris *III*. 131, 135
 — — presacralis, vide: plexus (autonomicus) hypogastricus superior
 * — profundi penis *III*. 189
 — — pterygoideus medialis, n. *pterygoideus int.* *III*. 101
 — — pudendus, n. *pudendalis*, plex. (*nervosus*) *pu-*
dendus, plex. *pudendalis III*. 159, 160, 161, 162, 164, 173, 189
 — — radialis *III*. 125, 126, 127, 131, 132, 133, 135, 137, 138, 139, 142
 — — rectales inferiores, n. *haemorrhoidales inf.* *III*. 162, 189
 — — *recurrens*, vide: nervus laryngeus recurrens
 — — regionis colli posterioris *III*. 112, 163, 185
 * — — dorsi *III*. 163, 185
 * — — glutinae *III*. 162, 163, 172, 185
 * — — infrascapularis *III*. 163, 185
 * — — lumbalis *III*. 163, 165
 * — — perinealis *III*. 162
 * — — sacralis *III*. 163, 185
 * — — scapularis *III*. 163, 185
 * — — vertebralis *III*. 163, 185
 * — retroperitoneales *III*. 158
 — — sacularis *III*. 254, 260
 * — sacrales, vide: nervi spinales
 — — saphenus *III*. 166, 169, 170, 171, 175, 178, 183
 — — scrotales posteriores *III*. 162
 * — septi nasi *III*. 104
 — — spinales, vide etiam: fila radicularia *III*. 83, 84, 89, 90, 96, 150
 * — — cervicales (C.) *III*. 185
 — — — (C. 1.) *III*. 84, 85, 88, 108, 124
 — — — (C. 2.) *III*. 96, 108
 — — — (C. 3.) *III*. 185

- nervus spinalis cervicalis (C. 5.) III. 125
 — (C. 6.) III. 125
 — (C. 7.) III. 125
 — (C. 8.) III. 83, 125
 * — lumbales (L.) III. 158, 168, 185
 — (L. 1.) III. 83, 87
 — (L. 2.) III. 87
 — (L. 3.) III. 87
 — (L. 4.) III. 87
 — (L. 5.) III. 83, 87
 * — sacrales (S.) III. 168, 185
 — (S. 1.) III. 83, 87
 — (S. 2.) III. 87
 — (S. 3.) III. 87
 — (S. 4.) III. 86, 87
 — (S. 5.) III. 83, 86, 87
 * — thoracici (Th.), *nn. thoracales* III. 83, 132, 150, 163, 185
 — (Th. 1.) III. 83, 125
 — (Th. 10.) III. 87
 — (Th. 11.) III. 87
 — (Th. 12.) III. 83, 87, 164
 * — splanchnicus III. 90
 — major III. 152, 187
 — minor III. 187
 — pelvini seu erigentes III. 189
 — stapedius III. 106
 — statoacusticus, vide: nervus vestibulocochlearis
 — subcostalis, vide etiam: nervus spinalis thoracicus (Th. 12.) III. 164
 — subinguinales III. 170, 171
 — suboccipitalis III. 163
 * — superficialis faciei III. 107, 112
 — supraclaviculares III. 116, 117, 132, 133
 — — intermedii (*medii*) III. 116, 117, 185
 — — laterales (*posteriores*) III. 118, 119, 188
 — — mediales (*anteriores*) III. 118, 188
 — supraorbitalis III. 102, 107, 112, 114, 236
 — suprascapularis III. 125, 134
 — supratrochlearis III. 98, 114, 236
 — suralis III. 168, 169, 177, 179, 183
 — temporalis profundus anterior III. 114
 — — posterior III. 114
 * — temporofacialis III. 107, 112
 * — thoracici, *nn. thoracales*, vide: nervi spinales
 — longus, *n. thoracalis longus* III. 119, 120, 121, 125, 126
 * — thoracis III. 151, 152, 153
 — tibialis I. 303, III. 167, 168, 169, 174, 177, 181
 — transversus colli, *n. cutaneus colli* III. 107, 112, 113, 116, 117, 118, 185
 — trigeminus (n. V.), vide etiam: radix motoria, sensoria II. 181, III. 26, 53, 72, 73, 85, 95, 96, 97, 98, 101, 102, 103, 104, 105, 108, 124, 185
 — trochlearis (n. IV.) II. 25, 181, 184, III. 1, 26, 35, 50, 95, 96, 97, 98, 99, 100, 108, 124
 — tympanicus III. 252
 — ulnaris III. 125, 126, 131, 132, 133, 136, 137, 138, 139, 140, III. 142, 145
 — utricularis III. 254, 260, 262
 — utriculoampullaris III. 260
 — vagus (n. X.) II. 27, 36, III. 1, 26, 35, 73, 85, 95, 96, 106, 108, 109, 120, 121, 122, 123, 124, 185
 — dexter II. 214, 215, 216, 217, III. 123, 126, 151, 152, 186, 187, 191
 — sinister II. 214, 215, 216, 217, III. 123, 151, 153, 187, 188, 213
 — vestibulocochlearis seu *octavus (n. VIII.), *n. acusticus*, *n. statoacusticus*, vide etiam: pars cochlearis, pars vestibularis II. 181, III. 1, 26, 34, 35, 66, 73, 85, 95, 96, 108, 109, 124, 186, 254
 * — visceralis pelvis feminae III. 161
 * — — masculinae III. 180
 neurocranium, vide: cranium cerebrale
 neuroepithelium cristae ampullaris III. 262
 maculae utriculi III. 262
 * neuron afferens (sensorius) III. 90
 * — — (visceralis) III. 90
 * — associationis retinae III. 228
 * — efferens (motorius) III. 90
 * — intercalare III. 90
 * — — pro bacilibus III. 228
 * — — — conibus III. 228
 * — postganglionaris III. 90
 * — preganglionaris III. 90
 * nidus lienis II. 73
 — parotidicus I. 227
 nodulus lymphaticus, vide: folliculus lymphaticus
 — valvulae semilunaris, *nodulus valvulae semilunaris (Arantii)* II. 193, 199
 — vermis cerebelli III. 29, 30, 32, 48
 nodus (-i)
 — atrioventricularis, *nodus atrioventricularis (Aschoff-Tawara)* II. 204
 — lymphaticus (-ei), *lymphoglandula*, *lymphonodus*
 * — — abdominales III. 192
 * — — anorectalis III. 208
 * — — aortici abdominales III. 205, 206, 209, 210, 215
 * — — thoracici III. 203, 204
 — — axillares III. 192
 — — — apicales III. 196, 199
 — — — centrales III. 199
 — — — laterales III. 199, 200
 — — bronchopulmonales, *lyll. bronchiales* II. 111, 112, III. 201, 203
 — — buccales III. 196
 * — — capitis superficiales III. 196
 * — — cardiaci III. 213
 * — — celiacii III. 213, 215
 — — cervicales profundi III. 196, 198, 199
 * — — — inferiores III. 198
 * — — — laterales III. 197
 * — — — mediales III. 197
 * — — — superiores III. 198
 * — — — superficiales III. 196
 * — — cervicis III. 197
 * — — — superficiales III. 196
 — — colicus dexter III. 214
 — — — sinister III. 214
 * — — cubitalis III. 200
 * — — duodeni III. 207
 * — — esophagei III. 203, 204, 213
 * — — faciei profundi III. 198
 * — — femorales III. 192
 — — — profundi I. 243, III. 211
 * — — — superficiales III. 209, 211
 * — — fossae iliacaе III. 205
 — — gastrici (dextri), *lyll. gastricae inf.* III. 207, 213
 — — — (sinistri), *lyll. gastricae supp.* III. 207
 — — hepatici III. 205, 207, 213
 * — — hepatis III. 207
 — — ileocolicus anterior III. 208
 — — — posterior III. 208
 — — iliaci III. 192, 205, 206, 208, 209, 215
 — — — interni, *lyll. hypogastricae* III. 206, 208, 209
 * — — infraclaviculares III. 199
 — — inguinales profundi, *lyll. anuli femoralis (Rosenmüllerii)* I. 243, III. 192, 210, 211
 — — — superficiales III. 192, 209, 211
 — — intercostales III. 196, 199, 202
 — — jugulodigastricus III. 196
 — — juguloomohyoideus III. 196
 * — laryngeus III. 201
 * — lienales III. 205
 * — lumbales III. 192, 205, 206, 215
 * — mandibularis III. 196
 * — mediastinales III. 201, 202, 203, 204
 — — anteriores III. 198, 202
 — — posteriores III. 202, 203, 204

- *nodi lymphatici membri inferioris III. 211, 212
 * — — superioris III. 200
 — — mesenterici III. 192, 206, 208, 211
 — — inferior III. 208, 214
 — — mediales III. 214
 * — — mesocolici medii III. 208
 — — occipitales III. 196
 * — — oesophagei, vide: nodi lymphatici esophagei
 * — — organorum genitalium femininorum III. 210
 * — — masculinorum III. 209
 * — — pancreatici III. 215
 * — — inferiores III. 206
 * — — superior III. 206
 * — — pancreaticoduodenales inferiores III. 206, 207
 * — — superiores III. 206, 207, 208
 — — pancreaticolienalis III. 206, 207, 208, 215
 * — — pararectalis III. 210
 * — — parasternales III. 199, 202
 * — — parauterinus III. 210
 * — — paravesicalis III. 210
 — — parotidei profundi III. 196
 — — superficiales III. 196
 — — pectorales, *lqll. pectorales (Sorgius) III. 192, 196, 199, 204*
 — — phrenici III. 205, 206, 207, 213
 — — popliteus III. 212
 * — — prelaryngeus III. 197, 198
 * — — prevesicalis III. 209
 — — pulmonales II. 121, III. 203
 — — pyloricus III. 207, 215
 * — — rectalis III. 208
 * — — regionis axillaris III. 199
 * — — colli lateralis III. 199
 * — — infraclavicularis III. 199
 * — — mammalis III. 199
 — — retroauriculares, *lqll. auriculares post. III. 196*
 * — — retroperitoneales III. 208, 209, 215
 — — retropharyngeus III. 197
 — — sacrales III. 192, 205, 208, 210
 — — submandibulares, *lqll. submaxillares III. 196, 197, 198*
 — — submentalis III. 196, 197, 198
 — — subscapulares III. 199
 * — — thoracis superficiales III. 196
 — — tracheales III. 197, 198, 201, 202, 203, 204
 — — tracheobronchiales II. 120, III. 192
 — — inferiores III. 201, 203, 204
 — — superiores III. 201, 203
 * — — ventriculi III. 207
 * — — vesicalis superior III. 209
 — — sinuatrialis, *nodus sinuatrialis (Keith—Fluck) II. 204*
 *norma frontalis cranii I. 52
 * — lateralis cranii I. 53
 nucleus (-i)
 — accessorius (autonomicus) nervi oculomotorii, *nucl. Westphal—Edinger III. 38, 49*
 — *alae cinereae medialis*, vide: nucleus dorsalis nervi vagi
 — ambiguus III. 38, 53, 54
 — amygdalae, vide: corpus amygdaloideum
 — anterior thalami III. 42, 47
 — arcuati III. 53, 54
 — caudatus III. 15, 17, 25, 45, 46, 62, 77, 81
 — centralis thalami, *centrum medianum thalami III. 43*
 * — cerebelli III. 33
 — cochlearis dorsalis III. 38
 — ventralis III. 38
 — colliculi superioris III. 49
 — cuneatus, *nucl. funiculi cuneati III. 55*
 — dentatus III. 25, 33, 44, 48, 58, 66
 — nucleus dorsalis corporis trapezoidei, *nucl. olivaris sup. III. 51, 52*
 — — nervi vagi, *nucl. alae cinereae med. III. 38, 54*
 — emboliformis III. 33, 44, 48
 * — encephali III. 62, 61, 66
 — fastigii III. 33, 44, 48
 — *funiculi cuneati*, vide: nucleus cuneatus
 — — *gracilis*, vide: nucleus gracilis
 — globosus III. 33, 44, 48
 — gracilis, *nucl. funiculi gracilis III. 55*
 — habemulae III. 43, 61
 — hypothalamicus, vide: nucleus subthalamicus
 — lateralis (nervi vestibularis), vide: nucleus vestibularis lateralis
 — — thalami III. 42, 47
 — lemnisci lateralis III. 50
 — lentiformis III. 17, 47, 48, 59, 62
 * — masticatorius, vide: nucleus motorius nervi trigemini
 — *medialis nervi vestibularis*, vide: nucleus vestibularis medialis
 — — thalami III. 42, 47
 — *motorii*, vide: nuclei originis
 — — nervi trigemini, *nucleus masticatorius III. 38, 51
 — nervi abducentis III. 38
 — — accessorii III. 55
 — — *cerebralia*, vide: nuclei nervorum cranialium
 — — *cranialium, nuclei nervorum cerebralia III. 38*
 — — facialis III. 38
 — — hypoglossi III. 38, 53, 54, 55
 — — oculomotorii III. 38, 49
 — — trochlearis III. 38
 — — vestibulocochlearis III. 38
 — olivaris, *nucl. olivaris inf. III. 45, 53, 54*
 — — accessorius dorsalis III. 54
 — — inferior, vide: nucleus olivaris
 — — superior, vide: nucleus dorsalis corporis trapezoidei
 — — originis, *nucl. motorius III. 38, 52*
 — — pontis III. 43, 45, 46, 50, 82, 88
 — — *principalis n. trigemini*, vide: nucleus sensorius superior nervi trigemini
 — — pulposus I. 165, 166
 — — *radicis descendens nervi trigemini*, vide: nucleus tractus spinalis
 — — ruber III. 43, 48, 49, 61
 — — salivatorius inferior III. 38
 — — superior III. 38
 — — *sensorii*, vide: nuclei terminationis
 — — sensorius superior nervi trigemini, *nucl. principitlis n. trigemini III. 38, 51*
 — — spinalis nervi accessorii III. 38
 — — — *vestibularis*, vide: nucleus vestibularis inferior
 — — subthalamicus, *nucl. hypothalamicus (corpus Luysi) III. 45, 46, 48, 81*
 — — terminationis, *nucl. sensorius III. 38, 52*
 — — *alae cinereae nervi vagi, nucl. alae cinereae lat. III. 54*
 — — tractus mesencephali nervi trigemini, *nucl. mesencephalicus n. trigemini III. 38, 49, 50*
 — — solitarii III. 38, 53, 54, 55
 — — spinalis nervi trigemini, *nucl. radices descendens n. trigemini III. 38, 53, 54, 55*
 — — vestibularis inferior, *nucl. spinalis n. vestibularis III. 38, 53*
 — — lateralis, *nucl. lat. n. vestibularis (Deiters) III. 38, 52*
 — — medialis, *nucl. med. n. vestibularis (Schwalbe) III. 38, 52, 53, 54*
 — — superior, *nucl. sup. n. vestibularis (Bechterew) III. 38*

O

- obex III. 37
occiput I. 51
oculus III. 216-239
oesophagus, vide: esophagus
olecranon I. 110, 111, 179, 181, 182, 183, 184, 262, 266, 267, 269, 274, 275, III. 127, 135
oliva medullae oblongatae III. 2, 26, 31, 46, 58, 64, 66, 71, 73, 82
omentum majus I. 249, II. 47, 48, 73, 74, 76, 80, III. 154, 156, 167, 207
— minus II. 41, 76, 77, 78, 80, III. 207
operculum frontale, vide: operculum frontoparietale
— frontoparietale, operculum frontale, operculum parietale III. 11
— parietale, vide: operculum frontoparietale
— temporale III. 11
ora serrata retinae III. 216, 219, 220, 224
orbiculus ciliaris III. 223
orbita I. 66, 67, II. 24, 87, III. 98-101
organon, vide: organum
— auditus, vide: organum vestibulocochleare
organum (-a)
— genitalia feminina II. 161-177, III. 210
* — — interna II. 166-168
— masculina II. 111-163, III. 209
* — — interna II. 151
— oculi accessoria III. 229-239
— retroperitonealia II. 51, 52
— sensuum III. 216-266
* — spirale, organon spirale (Corti) III. 261
— subcommissurale III. 21
* — uropoetica II. 122-140
* — — feminina II. 138, 139, 164
— masculina II. 127-129, 140, 141
— vestibulocochleare, organon auditus, organon status et auditus III. 210-263
— visus III. 216, 239
orificium, vide: ostium
os (ora), vide etiam: labium inferius, superius oris, regio oralis II. 1, 2
os (ossa)
— capitatum I. 114, 115, 116, 117, 186, 187, 188
* — capitis, vide etiam: cranium I. 13-50
— carpi I. 114, 115
— coeeygis I. 93, 91, 120, 167, 168, 169, 194, 291, II. 142, 164, 173, 174, 175, 176, III. 86, 162
— coxae I. 118, 119, 120, 244
— cranii, vide: cranium
— cruris, vide: fibula, tibia
— cuboideum I. 136, 137, 138, III. 146, 147, 148, 149, 212, 213
— cuneiforme intermedium, os cuneiforme II. 1. 137, 138, 146, 212, 213, 214
— — laterale, os cuneiforme III. 1. 137, 138, 146, 212, 213
— — mediale, os cuneiforme I. 1. 136, 137, 138, 146, 212, 213
— — primum, vide: os cuneiforme mediale
— — secundum, vide: os cuneiforme intermedium
— — tertium, vide: os cuneiforme laterale
— digitorum manus I. 11, 116, 117, 189, 190
— pedis I. 12, 136, 137, 138, 214
— ethmoidale, vide etiam: cellulae sinus ethmoidalis, lamina cribrosa, lamina orbitalis, lamina perpendicularis I. 30, 31, 32, 33 II. 87
— frontale I. 25, 26, 27, 70, II. 24, 86, 87
— hamatum I. 114, 115, 116, 117, 187, 188
— hyoideum I. 51, 222, 223, 224, 225, 229, II. 24, 25, 26, 27, 33, 88, 97, 98, 99, 100, 101, 102, 103, 104, 186, 187, III. 107, 108, 123, 126, 186
— ilium I. 10, 118, 119, 120, 196, 197, 199, II. 142, 166, 169, III. 160
— ischii, vide etiam: ramus ossis ischii I. 119, 120, 194, II. 156
— lacrimale I. 36, 68
— lunatum I. 114, 115, 116, 117, 186, 188, 191
* — manus I. 114, 115, 116, 117
— membri (extremitatis) inferioris I. 118-149
— — superioris I. 101-117
— metacarpalia I. 116, 117, 185, 189, 284
— — II. III. 143
— — V. I. 11, 188
— — pollicis I. 116, 188
— metatarsale I. 1. 136, 213
— — II. I. 214
— — V. I. 213
— multangulum majus, vide: os trapezium
— — minus, vide: os trapezoideum
— nasale I. 37, 38, II. 24, 26, 83, 85, 86, 88, III. 105
— naviculare, os naviculare pedis I. 136, 137, 138, III. 145, 212, 213, 214
— — manus, vide: os scaphoideum
— — pedis, vide: os naviculare
— occipitale I. 13, 14, 70, II. 31, 32
— palatinum, vide etiam: lamina horizontalis, perpendicularis I. 41, 42, 43
— parietale I. 28, 29, 55, 70
* — pedis I. 136-149
— pisiforme I. 114, 115, 116, 117, 185, 186, 191, 280, III. 138
— pubis, vide etiam: ramus inferior, superior ossis pubis I. 10, 119, 120, 192, II. 154, 156, 159, III. 160, 161
— sacrum I. 74, 88, 89, 90, 91, 92, 120, 153, 191, 192, II. 138, 142, 143, 154, 174, 175, 176, 291, III. 86, 159, 161, 164, 166, 190
— scaphoideum, os naviculare manus I. 114, 115, 116, 117, 187, 188, 191
— sesamoidea I. 117, 136, 138
— sphenoidale, vide etiam: ala major, ala minor, processus pterygoideus I. 22, 23, 24, II. 25, 181
— tarsi I. 116
— temporale, vide etiam: pars hyoidea, pars mastoidea, pars petrosa, processus mastoideus, processus styloideus I. 15, 16, 17, 18, 19, 20, 70, II. 25, 32, 33, III. 101
* — — neonati I. 21
— trapezium, os multangulum majus I. 114, 115, 116, 117, 187, 188
— trapezoideum, os multangulum minus I. 114, 115, 116, 117, 187, 188
— triquetrum I. 114, 115, 116, 117, 187, 188, 191
* — trunci I. 74-100
— zygomaticum I. 39, 40, 67, 150, II. 18, 24, 33
ossicula auditus III. 247, 250, 253
osteologia I. 1-149
ostium abdominale tubae uterinae II. 168
— aortae, ostium arteriosum sin. II. 117, 196, 197, 199
— appendicis vermiformis, valvula proc. vermiformis (Gerlachi) II. 58
— arteriosum cordis, vide: ostium aortae, trunci pulmonalis
— atrioventriculare dextrum II. 117, 193, 197, 199
— — sinistrum II. 117, 195, 196, 197, 198, 199
— cardiacum, cardia II. 1, 38, 39, 40, 41, 42, 41, 76, III. 154, 187
— cordis, vide etiam: ostium aortae, atrioventriculare, trunci pulmonalis, valvae cordis II. 199
* — ductus ejaculatorii II. 140
* — — submandibularis II. 22
* — externum canalis cervicis II. 169
— — — isthmi II. 169
* — glandulae tarsalis III. 237
— ileocecale, ostium ileocaecocolicum II. 58
— internum canalis cervicis II. 169
— — — isthmi II. 169
— — uteri II. 169
— pharyngeum tubae auditivae II. 25, 26, 82, 86, 88
— pyloricum ventriculi II. 81
* — sinus coronarii II. 192, 193, 204

- ostium trunci pulmonalis, *ostium arteriosum dext. II.* 117, 193, 191, 199
 — ureteris, *orificium vesicale ureteris II.* 137, 139, 140, 143
 — urethrae externum, *orificium urethrae ext. II.* 139, 140, 143, 153, 154, 158, 160, 171, 172
 — femininae externum *II.* 139, 171, 172
 — internum, *orificium urethrae int. II.* 135, 139, 140, 143
 — masculinae externum *II.* 140, 143, 154, 157, 158, 160
 — uteri, *orificium ext. uteri, orificium ext. canalis cervicis uteri II.* 80, 164, 168, 169
 — uterinum tubae uterinae *II.* 168
 — vaginae, *orificium vaginae II.* 171, *III.* 190
 — venae cavae inferioris *II.* 192
 — — superioris *II.* 193
 — pulmonalis *II.* 195
 — *renosum cordis*, vide: ostium atrioventriculare
otoconia, vide: statoconia
 ovarium *II.* 161, 165, 167, 168, 169, *III.* 161, 210
 — dextrum *II.* 168
 — sinistrum *II.* 168

P

- pachymeninx (gr.), vide: dura mater encephali
 palatum *II.* 30, 87
 — durum *I.* 67, *II.* 1, 23, 26, 29, 83, 86, 87, 88, *III.* 105
 — molle *II.* 1, 23, 26, 29, 83, 86, 88
 — osseum *I.* 67, *II.* 12
 palma manus, *regio colaris manus, vola manus III.* 110, 111
 palpebra *III.* 235, 237, 239
 — inferior *III.* 235, 237, 238
 — superior *III.* 235, 237, 238
 pancreas, vide etiam: caput, cauda, corpus, margo superior, processus uncinatus pancreatis *II.* 1, 15, 16, 51, 77, 80, 81, *III.* 155, 187, 206, 213, 214, 215
 panniculus adiposus *III.* 267
 papilla (-ae)
 * — cutis *III.* 267, 268
 — duodeni major, *papilla duodeni major (Vateri) II.* 46, 52, 53
 — minor *II.* 46
 — foliatae *II.* 21
 — fungiformes *II.* 21, 30
 — lacrimalis *III.* 235
 — linguales *II.* 21
 — mammae *II.* 178, 179, 180
 — renalis *II.* 126, 128
 — vallatae *II.* 21, 28, 30, 31, 34, 96
paracolpium II. 169
paracystium II. 135
 parametrium *II.* 166, 169
 paries (-etes)
 * — anterior abdominis *I.* 238, 241
 * — trunci *III.* 148
 — vaginae *II.* 168
 — ventriculi *II.* 41
 caroticus cavi tympani *III.* 252
 externus ductus cochlearis *III.* 261
 jugularis cavi tympani *III.* 252
 labyrinthicus cavi tympani *III.* 252
 * — lateralis cavi nasi *I.* 62, 63, *II.* 86, *III.* 105
 mastoideus cavi tympani *III.* 251
 medialis orbitae *I.* 65, 68
 membranaceus cavi tympani *III.* 251
 — tracheae, *paries membranacea II.* 98, 101, 102, 108
 * — posterior omenti majoris *II.* 80
 * — pharyngis *II.* 28
 * — vaginae *II.* 172
 paries posterior ventriculi *III.* 155
 — tegmentalis cavi tympani *III.* 253
 — vestibularis ductus cochlearis, *membrana vestibularis (Reissneri) III.* 261
 paroophoron *II.* 167
 * parotis, vide: glandula parotis
 pars (-tes)
 * — abdominalis esophagi *II.* 73
 — musculi pectoralis majoris *I.* 230, 231, 232
 — systematis autonomici, *pars abdominalis syst. symp. III.* 188
 * — trunci sympathici *III.* 158, 164
 * accessoria lineae axialis dorsalis *III.* 184
affixa hepatis, vide: area nuda hepatis
 alaris musculi nasalis *I.* 215
 alveolaris mandibulae *I.* 47, 48
 anterior faciei diaphragmaticae hepatis *II.* 63
 — lobuli quadrangularis *III.* 27, 28
 — annularis vaginae fibrosae, *ligg. annularia vaginae tendinum I.* 279, 285
 — ascendens duodeni *II.* 1, 15, 51, 53, 74, 78, 79
 — basilaris ossis occipitalis *I.* 13, 14, 73, *II.* 86
 — buccopharyngea musculi constrictoris pharyngis superioris, *m. buccopharyngeus II.* 23, 33
 — cartilaginea septi nasi *II.* 83
 — — tubae auditivae *III.* 252
 — centralis ventriculi lateralis *III.* 15, 16, 17, 25, 41, 42, 43, 68, 81
 — cephalica systematis autonomici *III.* 186
 — ceratopharyngea musculi constrictoris pharyngis medii, *m. ceratopharyngeus II.* 33
 * — cervicalis arteriae subclaviae *III.* 120, 121
 * — — canalis vertebralis *III.* 124
 — — medullae spinalis *III.* 81, 85, 121
 — — systematis autonomici *III.* 186
 * — trunci sympathici *III.* 108, 109, 121, 122, 123, 125
 — chondropharyngea musculi constrictoris pharyngis medii, *m. chondropharyngeus I.* 328, *II.* 33
 — clavicularis musculi pectoralis majoris *I.* 230, 232
 — cochlearis nervi vestibulocochlearis, *n. cochlearis III.* 246, 260
 — costalis diaphragmatis *I.* 248, 249, 250, *II.* 81, 82, *III.* 148
 — cricopharyngea musculi constrictoris pharyngis inferioris, *m. cricopharyngeus II.* 33
 — cruciformis vaginae fibrosae, *ligg. cruciata vaginae tendinum I.* 279, 285
 — descendens duodeni *II.* 1, 41, 42, 43, 45, 46, 49, 50, 51, 53, *III.* 213, 215
 — dextra faciei diaphragmaticae hepatis *II.* 63
 — epididymica ductus deferentis *II.* 141
 * — extraduralis caudae equinae *III.* 87
 * — extrapericardica trunci pulmonalis *II.* 215
 * — — venae cavae superioris *II.* 215
 * — flaccida membranae tympani *III.* 249
 — — valvulae semilunaris *II.* 193
 * — juncularis ductus deferentis *II.* 141
 — genitales feminae externae *II.* 171, 172
 — — masculinae externae *II.* 110—163
 * — glabra labii oris *II.* 3
 — glossopharyngea musculi constrictoris pharyngis superioris, *m. glossopharyngeus II.* 33
 * — horizontalis seu inferior duodeni *II.* 45, 46, 51, 53, 77, *III.* 155
 — *hyoidea ossis temporalis*, vide etiam: processus styloideus *I.* 20
 * — inferior duodeni, vide: *pars horizontalis duodeni
 * — infraperitonealis recti *II.* 61
 — inguinalis ductus deferentis *II.* 141
 * — intermedia lobi anterioris hypophyseos *II.* 182
 * — intraduralis caudae equinae *III.* 87
 * — intrapericardica trunci pulmonalis *II.* 215
 * — — venae cavae superioris *II.* 215
 — labialis musculi orbicularis oris *I.* 215

- pars lacrymalis musculi orbicularis oculi, *pars lacrymalis (Horneri) I.* 217
- laryngea pharyngis *II.* 26, 31, 82, 88, 104
- lateralis ossis occipitalis *I.* 13, *II.* 73
- — sacri *I.* 88, 89, 92, 192, *II.* 138, 175
- lumbalis diaphragmatis *I.* 248, *II.* 81, 82, 117, 134
- — medullae spinalis *III.* 81, 86
- * — trunci sympathici *III.* 188, 189, 191
- * magnocellularis nuclei rubri *III.* 49
- * major glandulae sublingualis *II.* 22
- * marginalis musculi orbicularis oris *I.* 215
- — sulci cinguli *III.* 5, 7, 10
- mastoidea ossis temporalis, vide etiam: processus mastoideus *I.* 15, 21
- mediastinalis faciei medialis pulmonis, *facies mediastinalis II.* 111, 112
- membranacea septi interventricularis, *pars membranacea septi ventriculorum II.* 196, 197
- — urethrae *II.* 135, 140, 143, 155, 176
- * — — femininae *II.* 176
- — masculinae *II.* 135, 140, 143, 155
- * minor glandulae sublingualis *II.* 22
- muscularis septi interventricularis *II.* 197
- mylopharyngea musculi constrictoris pharyngis superioris, *m. mylopharyngeus II.* 33
- nasalis ossis frontalis *I.* 25, 26
- — pharyngis *II.* 25, 26, 34, 82, 88
- obliqua musculi cricothyroidei *II.* 33, 96, 98
- opercularis gyri frontalis inferioris *III.* 3
- optica retinae *III.* 228
- oralis pharyngis *II.* 26, 31, 82, 88
- orbitalis glandulae lacrymalis *III.* 237
- — gyri frontalis inferioris *III.* 3
- — musculi orbicularis oculi *I.* 215, 216, 217
- — ossis frontalis *I.* 25, *II.* 87
- osses septi nasi *II.* 83
- — tubae auditivae *III.* 252
- pallida nuclei lentiformis, vide: globus pallidus
- palpebralis glandulae lacrymalis *III.* 237
- — musculi orbicularis oculi *I.* 215, 216, 217
- * parvocellularis nuclei rubri *III.* 49
- pelvina ductus deferentis *II.* 141
- — systematis autonomici, *pars pelvina syst. symp. III.* 189, 190
- * — — trunci sympathici *III.* 159, 161, 171
- pericardica pleurae *II.* 120
- petrosa ossis temporalis, *pars petrosa, pyramis I.* 16, 17, 18, 19, 20, 21, 73, 151, *II.* 23
- posterior faciei diaphragmaticae hepatis *II.* 64
- — lobuli quadrangularis *III.* 27, 28
- profunda glandulae parotidis *II.* 36
- * — musculi sphincteris ani externi *II.* 176
- prostatica urethrae *II.* 135, 140, 143
- pterygopharyngea musculi constrictoris pharyngis superioris, *m. pterygopharyngeus II.* 33
- pylorica ventriculi *II.* 40, 41, 42, 43, *III.* 77, *III.* 155, 187
- radiata lobuli corticalis, *striae medullares corticis (proc. Ferreini) II.* 126, 128
- recta musculi cricothyroidei *II.* 33, 100, 102
- sacralis medullae spinalis *III.* 84
- sinistra faciei diaphragmaticae hepatis *II.* 63
- spongiosa urethrae, *pars cavernosa urethrae II.* 135, 140, 143, 156, 159, 160
- squamosa ossis temporalis, *squmata temporalis I.* 15, 16, 17, 20, 21, 67, *II.* 23, 24, *III.* 243
- sternalis diaphragmatis *I.* 248
- sternocostalis musculi pectoralis majoris *I.* 230, 231, 232
- subcutanea musculi sphincteris ani externi *II.* 154, 172
- superficialis glandulae parotidis *III.* 113
- — musculi sphincteris ani externi *II.* 154, 172
- superior duodeni *II.* 4, 42, 43, 44, 45, 46, 51, 73, 76, 78, 81, *III.* 154
- pars tensa membranae tympani *III.* 249, 251
- * — — valvulae semilunaris *II.* 193
- — testicularis ductus deferentis *II.* 148
- * — thoracica arteriae subclaviae *III.* 120, 121, 122
- — medullae spinalis *III.* 84
- — systematis autonomici, *pars thoracalis syst. symp. III.* 187
- * — — trunci sympathici *III.* 152, 153, 186
- thyropharyngea musculi constrictoris pharyngis inferioris, *m. thyropharyngeus II.* 33
- tibiocalcanea ligamenti deltoidei, *lig. calcaneo-tibiale I.* 211
- tibionavicularis ligamenti deltoidei, *lig. tibionaviculare I.* 211
- tibiotalaris anterior ligamenti deltoidei, *lig. talotibiale ant. I.* 209
- — posterior ligamenti deltoidei, *lig. talotibiale post. I.* 211
- transversa musculi nasalis *I.* 215, 216
- triangularis gyri frontalis inferioris *III.* 3
- tuberalis hypophyseos *II.* 182, 183
- — lobi anterioris hypophyseos *II.* 182
- * — — posterioris hypophyseos *II.* 182
- tympanica ossis temporalis *I.* 15, 20, *II.* 23, *III.* 243
- uterina tubae uterinae, *pars interstitialis II.* 168
- vertebralis faciei medialis pulmonis *II.* 111, 112
- vestibularis nervi vestibulocochlearis, *n. vestibuli III.* 246, 260
- * — villosa labii oris *II.* 3
- patella *I.* 131, 132, 200, 201, 203, 206, 207, *III.* 166
- pecten ossis pubis *I.* 118, 119, 120, *II.* 138
- pediculus arcus vertebrae, *radix arcus vertebrae I.* 83, 85, 159, 163
- pedunculus cerebellaris inferior, *corpus restiforme III.* 37, 52, 53, 54, 66, 85
- — medius, *brachium pontis II.* 181, 184, *III.* 25, 29, 30, 31, 37, 45, 46, 58, 63, 64, 73, 83, 85
- — superior, *brachium conjunctivum III.* 25, 29, 33, 37, 48, 58, 66, 85, 101, 109
- cerebri, vide etiam: crus cerebri, tegmentum *III.* 8, 20, 21, 25, 26, 36, 37, 58, 63, 64, 81
- flocculi *III.* 29, 30
- pelvis *I.* 1, 121, 122, 123, 124
- * — femina *I.* 122, 124, *II.* 169, 175, 176, *III.* 190
- * — masculina *I.* 121, 123, *III.* 189
- renalis, *pyelon *II.* 122, 126, 129, 131, 141, *III.* 158
- penicilli lienis *II.* 72
- penis, vide etiam: bulbus, corpus, corpus cavernosum, corpus spongiosum, crus, glans penis *II.* 141, 150, 151, 155, *III.* 189, 209
- pericardium, vide etiam: pericardium fibrosum, serosum *I.* 249, *II.* 109, 119, 120, 185, 190, 191, 212—217, *III.* 151, 152, 153
- fibrosum, vide etiam: ligamentum sternopericardiacum inferius, superius *II.* 212
- serosum, vide etiam: lamina parietalis, visceralis, epicardium *II.* 212
- perilympha *III.* 262
- perimetrium, vide: tunica serosa uteri
- perineum, vide etiam: regio perinealis *II.* 150, 151, 155, 159, 172, 173, 174, *III.* 162
- — femininum *II.* 172, 173, 174
- — masculinum *II.* 150, 151, 155, 159, *III.* 162
- periodontium, *periosteum alveolare II.* 11
- periorbita *II.* 87, *III.* 239
- periorchium, vide: lamina parietalis tunicae vaginalis testis
- periosteum alveolare, vide: periodontium
- peritoneum, *peritonaeum I.* 244, *II.* 61, 73, 74, 75, 76, 77, 78, 79, 80, 137, 142, 143, 148, 151, 161
- parietale *I.* 238, 244, *II.* 50, 79, 80, 81, 134, 135, *III.* 148

- peritoneum viscerale, vide etiam: tunica serosa intestinorum II. 80, 81
- pes, vide: arteriae, digiti, dorsum, muscoli, planta, venae pedis
- *anserinus* I. 296, 298
 - hippocampi, *digitationes hippocampi* III. 16, 17, 18, 19
- petiolus epiglottidis II. 95, 99
- phalanx (-ges)
- *digitorum*, vide: ossa digitorum
 - — *manus* I. 116, 117, 189, 190
 - — *pedis* I. 136, 137, 214
 - distalis hallucis, *phalanx secunda hallucis* I. 136
 - — *manus*, *phalanx tertia manus* I. 116, 117, 189, 190
 - — *pedis*, *phalanx tertia pedis* I. 214
 - — pollicis, *phalanx secunda pollicis* I. 116, 117
 - media manus, *phalanx secunda manus* I. 116, 117, 189, 190
 - — *pedis*, *phalanx secunda pedis* I. 214
 - proximalis hallucis, *phalanx prima hallucis* I. 136
 - — *manus*, *phalanx prima manus* I. 116, 117, 189
 - — *pedis*, *phalanx prima pedis* I. 214
 - — pollicis, *phalanx prima pollicis* I. 116, 117
- pharynx, vide etiam: pars laryngea, nasalis, oralis
- pharyngis II. 1, 28, 36, 38, 82, 187, III. 105, 108, 109, 120, 121
- philtrum II. 2, 3
- pia mater III. 79, 81
- pilum III. 270
- planta pedis, *regio plantaris pedis* III. 181
- planum occipitale I. 258
- *popliteum*, vide: facies poplitea femoris
- platysma I. 215, 216, 217, 218, 221, 227, 228, 229, 324, III. 112, 116, 117, 118
- pleura II. 73, 112, 121
- costalis II. 120, 213
 - diaphragmatica II. 120, 212
 - mediastinalis II. 120, 212, 213, 214, 216
 - parietalis II. 134
- plexus (-us)
- * — arteriosus partis tuberalis anterioris hypophyseos II. 183
 - * — — — posterioris hypophyseos II. 183
 - (autonomicus, -ci), *plexus syst. symp.*
 - — aorticus III. 153
 - — — abdominalis III. 171, 188, 189, 191, 215
 - — — thoracicus, *plex. aorticus thoracalis* III. 186
 - * — arteriae sigmoideae III. 188
 - — cardiacus III. 151
 - — caroticus internus III. 100, 105, 106, 186
 - — celiacus III. 191, 213, 215
 - * — — duodenalis III. 188
 - — esophageus III. 187
 - — gastricus III. 213
 - — — superior III. 187
 - — hepaticus III. 188, 213
 - — *hypogastricus*, vide: plexus (autonomicus) hypogastricus inferior, superior
 - — — inferior seu pelvinus, *plex. hypogastricus* III. 189, 190
 - — — superior seu nervus presacralis, *plex. hypogastricus* III. 189, 190
 - — iliacus III. 188
 - — lienalis III. 188, 213
 - — mesenterici III. 214
 - * — — inferior III. 188, 215
 - * — — superior III. 188, 214
 - — myentericus, *plex. myentericus (Auerbachi)* II. 54
 - — pelvinus, vide: plexus (autonomicus) hypogastricus inferior
 - — — prostaticus III. 189
 - — rectalis III. 190
- plexus (autonomicus) rectalis medius, *plex. haemorrhoidalis medius* III. 189
- — — superior, *plex. haemorrhoidalis sup.* III. 188, 215
 - — renalis III. 188, 191, 215
 - * — — retroperitonealis III. 215
 - — — spermaticus, vide: plexus (autonomicus) testicularis
 - — — submucosus, *plex. submucosus (Meissneri)* II. 54
 - — suprarenalis III. 191
 - — testicularis, *plex. spermaticus* III. 188
 - — uterovaginalis III. 190
 - — vesicalis III. 189, 190
 - * — villi intestinalis II. 5, 54,
 - * — visceralis abdominalis III. 188—190
- choroideus, *plexus choroideus* III. 81
- — ventriculi lateralis III. 15, 16, 21, 25, 41, 42, 43, 47, 81
 - — — quarti III. 35, 36
 - — — tertii III. 21, 81
 - * — (lymphaticus) submucosus II. 54
 - * — — subserosus II. 54
 - * — (nervi facialis) parotidicus III. 112
 - * — — (glossopharyngei) intercaroticus III. 122
 - — (vagi) esophageus III. 152, 153
 - — — pharyngeus III. 108, 109
 - — (nervorum spinalium) brachialis I. 229, III. 119, 120, 122, 123, 124, 125, 126, 131, 133, 151, 185, 186, 187
 - — — cervicalis III. 107, 112, 119, 120, 121, 122, 123, 124, 126, 132, 163, 185, 186
 - — — ischiadicus III. 159
 - — — lumbalis III. 161, 165, 168, 169, 185
 - — — lumbosacralis III. 161, 165, 166
 - — — sacralis II. 156, 176, III. 161, 168, 169, 189, 190
 - — (nervosus) pudendus, vide: nervus pudendus
 - — — tympanicus, *plex. tymp. (Jacobsoni)* III. 106, 252
 - * — *systematis sympathici*, vide: plexus autonomici
 - * — (vasculosus) episcleralis III. 223
 - * — villi intestinalis II. 5, 54
 - * — (venosus, -i) arteriae vertebralis III. 94
 - * — — atlantooccipitalis III. 94
 - * — — basilaris III. 78
 - * — — capitis III. 94
 - * — — choroideae III. 221
 - * — — ciliaris III. 221
 - * — — corporis uteri II. 170
 - * — — fundi uteri II. 170
 - * — — ligamenti teretis uteri II. 170
 - — — pampiniformis II. 146, 148
 - — — prostaticus, *plex. vesicopudendalis, plex. pudendalis* II. 135, 143
 - — — pterygoideus III. 77, 111
 - — — dexter III. 94
 - — — sinister III. 94
 - — — *pudendalis*, vide: plexus (venosus) prostaticus
 - — — thyroideus impar II. 214, 215
 - — — uterinus, *plexus venosus uterovaginalis* II. 169
 - — — uterovaginalis, vide: plexus (venosus) uterinus, plexus (venosus) vaginalis
 - — — vaginalis, *plex. venosus uterovaginalis* II. 169
 - — — vertebrales II. 36, III. 92, 93, 94
 - — — — dorsales, *plexus venosi vertebrales post.* III. 94
 - — — — externus, vide etiam: plexus venosi vertebrales dorsales, ventrales II. 36
 - — — — internus II. 36, III. 78, 90, 92, 93, 159
 - — — — ventrales, *plexus venosi vertebrales ant.* III. 94

- plexus (venosus) vesicalis, *plex. vesicopudendalis* III. 160, 161
 — — *vesicopudendalis*, vide: plexus (venosus) prostaticus, plexus (venosus) vesicalis
- plica (-ae)
 — alaris I. 203
 — ampullares II. 168
 — aryepiglottica II. 31, 34, 39, 96, 99, 101, 102, 104
 — axillaris anterior I. 261, II. 178
 — — posterior I. 261
 — ciliares III. 223
 — circulares, *plicae circulares (Kerkringi)* II. 45, 46, 55
 — *epigastrica*, vide: plica umbilicalis lateralis
 — fimbriata II. 22
 — gastricae II. 44
 — gastropancreatica II. 77
 — glossoepiglottica lateralis II. 21, 31, 34, 96
 — — mediana II. 21, 104
 — interureterica II. 139, 140
 — *isthmicae tubae uterinae* II. 168
- * lacrimalis, *plica lacrimalis (Hasneri)* II. 86, III. 238
- * laryngis II. 104, 105
 — longitudinalis duodeni II. 46
 — mallearis anterior, *plica malleolaris ant.* III. 251, 253
 — — posterior, *plica malleolaris post.* III. 251, 253
 — malleolaris, vide: plica mallearis
- * mucosae intestini II. 56
 — nervi laryngei II. 34, 96
 — palatinae transversae II. 30
 — palmatae II. 168
- * petroclinoidea anterior III. 97
 * — posterior III. 97
- * pterygomandibularis II. 29
 — rectouterina II. 165, 167, 168
 — salpingopalatina II. 86
 — salpingopharyngea II. 86
 — semilunares colli II. 57, 58, 59
 — sublingualis II. 22
 — synovialis infrapatellaris, *plica synovialis patellaris* I. 203
 — transversales recti II. 62, 143
 — triangularis II. 21
 — umbilicalis lateralis, vide: plica umbilicalis media
 — — lateralis, *plica epigastrica* I. 238, 244, 246, II. 135, III. 148
 — — media, *plica umbilicalis lat.* I. 238, 244, II. 135, II. 148
 — — media, vide: plica umbilicalis mediana
 — — mediana, *plica umbilicalis media* I. 238, 244, II. 135, III. 148
 — ventricularis laryngis, vide: plica vestibularis
 — vestibularis laryngis, *plica ventricularis* II. 26, 88, 104, 105
 — vocalis II. 26, 88, 104, 105
- pollex seu digitus manus I. 1. 278
- polus anterior lentis III. 226
 — frontalis cerebri III. 1, 4, 6, 11, 16, 47, 61, 62, 74, 95
 — occipitalis cerebri III. 4, 6, 11, 16, 74, 75
 — posterior corporis vitrei III. 225
- * lentis III. 226, 227
 — temporalis cerebri III. 1, 2, 8, 10, 11, 16, 19, 40, 71
- * pomum Adami, vide: prominentia laryngea
- pons, *pons (Varoli)* III. 1, 2, 4, 5, 21, 22, 25, 26, 34, 35, 36, 61, 66, 82, 83, 95, 186
- porta hepatis II. 53
- portio supravaginalis cervicis uteri II. 156
 — vaginalis cervicis uteri II. 164, 168, 169
- porus acusticus externus I. 15, III. 242, 246, 247
 — acusticus internus I. 17, 58, 154, 155, 156, III. 108, 247
 — sudoriferus III. 271
- precuneus, *praeuncus* III. 4, 5
- preputium clitoridis II. 171, 177
 — penis II. 143, 150, 154, 157
- processus (-us)
 — accessorius vertebrarum lumbalium I. 85, 86, 87
 — alaris ossis ethmoidalis, vide: ala cristae galli
 — alveolaris maxillae I. 35, 67, II. 5, 24, 83
 — anterior mallei III. 250
 — articularis inferior I. 77, 81, 84, 87, 164
 — — superior I. 81, 84, 85, 86, 89, 91, 92, 164
 — — vertebrae lumbalis III. 93
 — caudatus hepatis II. 65
 — ciliaris III. 216, 219, 220, 221, 223
 — clinoidens anterior I. 22, 24,
 — — medius I. 22
 — — posterior I. 24
 — cochleariformis I. 19, III. 252
 — condylaris mandibulae, *proc. condyloideus mandibulae* I. 47, 49, II. 6, 12, 14, 15, 17, 18
 — coracoideus I. 103, 104, 105, 172, 173, 174, 260, 263, 264, 265, 266, III. 136, 137
 — coronoideus mandibulae I. 47, 48, 49, 150, 151, 152, 218, II. 14, 15, 17, 18, 87
 — — ulnae I. 110, 180, 181, 182, 183, 184
 — costarius I. 85, 86, 87, 164, 239
 — *costotransversarius*, vide: processus transversus
 — ethmoidalis conchae nasalis inferioris I. 45, 46, 63, 64
 — falciformis ligamenti sacrotuberalis I. 194
 — frontalis maxillae I. 31, 35, II. 5
 — — ossis zygomatici, *proc. frontosphenoidalis* I. 39, 40
 — *frontosphenoidalis ossis zygomatici*, vide: processus frontalis
- * inferior tegminis tympani I. 20
 — infundibuli II. 182, 183
 — intrajugularis ossis occipitalis I. 13, 14
 — — partis petrosae I. 17, 58
 — jugularis ossis occipitalis I. 13
 — lacrimalis conchae nasalis inferioris I. 45, 46
 — lateralis mallei III. 250
 — — tuberi calcanei, *tuberculum lat.* I. 138, 142
 — lenticularis incudis III. 250, 253
 — mamillaris vertebrarum lumbalium I. 86, 87
 — marginalis ossis zygomatici I. 39
 — mastoideus, *pars mastoidea ossis temporalis* I. 15, 18, 19, 21, 59, 60, 73, 150, 152, 158, II. 24, 25, 32, 33, III. 76, 85, 103, 197, 243, 263
 — maxillaris conchae nasalis inferioris I. 46
 — medialis tuberi calcanei, *tuberculum med.* I. 136, 138, 142
 — muscularis cartilaginis arytenoideae II. 93, 94, 98, 99, 101
 — orbitalis ossis palatini I. 41, 42, 43, 64
 — palatinus maxillae I. 35, 62, 73, II. 12, 13, 16, 83
 — papillaris hepatis II. 65
 — posterior seu sphenoidalis septi nasi cartilaginei, *proc. sphenoidalis septi nasi cartilaginei* II. 83
 — pterygoideus I. 23, 24, 59, 60, 68, 73, II. 23, 24, III. 101, 103, 186, 263
 — pyramidalis ossis palatini I. 41, 42, 43, II. 16, 24, 25, 32, 36
 — sphenoidalis ossis palatini I. 41, 42, 43
 — — septi nasi cartilaginei, vide: processus posterior
 — spinosus I. 77, 78, 79, 80, 81, 82, 83, 84, 85, 86, 87, 165
 — — axis, *proc. spinosus epistrophei* I. 253, 255, 256
 — — vertebrae III. 92, 93
 — — thoracicae (Th. XII.) I. 251
- styloideus ossis temporalis I. 15, 17, 18, 20, 59, 60, 229, II. 24, 25, 32, 36, III. 122, 243

- processus styloideus radii *I.* 112, 113, 116, 117, 184, 188
 — — ulnae *I.* 110, 111, 184, 187, 188
 — temporalis *I.* 39, 40, 67
 — transversus, *proc. costotransversarius I.* 75, 76, 77, 78, 79, 82, 83, 84, 160, 161, 162, 234, *III.* 92
 — — atlantis *I.* 154, 155, 156, 157, 226, 255, 258, *II.* 36
 — — axis, *proc. transversus epistrophei I.* 154
 — — vertebrae thoracicae *III.* 150
 — uncinatus ossis ethmoidalis *I.* 30, 32, 33, 63, 64, 65
 — — pancreatis, *pancreas parvum (Winslowi) II.* 1, 45, 49, 53, *III.* 214
 — vaginalis *I.* 23
 — vermiformis, vide: appendix vermiformis
 — vocalis cartilaginis arytenoideae *II.* 93, 94, 99, 103
 — xiphoideus *I.* 95, 96, 97, 170, *II.* 47, 48, 49, 51
 — zygomaticus maxillae *I.* 34, *II.* 5, 18, 25
 — — ossis frontalis *I.* 26, 27
 — — — temporalis *I.* 15, 18, 67, *II.* 18, 25
 *proctos (gr.), vide: rectum
 prominentia canalis facialis *I.* 20, *III.* 52
 — — semicircularis lateralis *I.* 18, 20, *III.* 252
 — laryngea, *pomum Adami *I.* 221, 227, *II.* 24, 25, 33, 82, 89, 90, 97, 186, *III.* 203
 — mallearis, *prominentia malleolaris III.* 248, 249
 promontorium ossis sacri *I.* 90, 153, 193, 246, 247, *II.* 164, 175, *III.* 158
 — — temporalis *I.* 19, 20, *III.* 106, 252
 prostata *I.* 244, *II.* 135, 136, 137, 138, 140, *III.* 112, 113, 151, 152
 protuberantia mentalis *I.* 47
 — occipitalis externa *I.* 14, 60, 251
 — — interna *I.* 13, 58
 pubes *II.* 143, 171
 pudendum femininum *II.* 171
 pulmo *II.* 109, 110
 — dexter *II.* 82, 112, 113, 114, 115, 116, 185, *III.* 151, 204
 — sinister *II.* 82, 111, 113, 114, 212, *III.* 151, 153
 pulpa dentis *II.* 11
 — lienis *II.* 72
 pulvinar thalami *III.* 23, 25, 47
 — — sinister *III.* 26
 puncta lacrimalia *III.* 237, 238
 *— ossificationis femoris *I.* 9
 *— — ossis coxae *I.* 10
 *— — — manus *I.* 11
 *— — — pedis *I.* 12
 *— — sterni *I.* 8
 pupilla *III.* 216, 223, 235
 putamen nuclei lentiformis *III.* 15, 40, 41, 42, 46, 48, 62, 81
 *pyelon (gr.), vide etiam: pelvis renalis *II.* 126
 pylorus *II.* 10, 11, 41, 46, 77, 79, 81
 pyramis medullae oblongatae *III.* 31, 64, 82
 — ossis temporalis, vide: pars petrosa
 — renalis, *pyramides renales (Malpighii) II.* 126, 128
 — vermis cerebelli *III.* 29, 30, 32

R

- radiatio corporis callosi *III.* 11, 56, 57
 — occipitohthalmica, vide: radiatio optica
 — optica, *radiatio optica (Gratiolati), radiatio occipitohthalmica III.* 58, 63, 65
 * thalami, vide etiam: fasciculi corticothalamici et thalamocorticales *III.* 61, 65
 radius *I.* 112, 113, 117, 176, 177, 178, 185, 184, 185, 186, 187, 188, 283, *III.* 129, 130
 — lentis, *radii stellarum lentis III.* 227

- radix (-ces)
 — anterior nervorum spinalium, vide: radix ventralis
 — arcus vertebrae, vide: pediculus arcus vertebrae
 — brevis ganglii ciliaris, vide: radix oculomotoria
 * buccalis dentis *II.* 10
 — craniales nervi accessorii, *n. accessorius vagi *III.* 1, 95, 124
 — dentis *II.* 6, 7, 10
 — dorsalis nervi spinalis, *radix post. n. spinalis III.* 83, 85, 89, 90, 92, 124
 — inferior ansae cervicalis, *ramus inf. ansae hypoglossi III.* 119
 — linguae *II.* 21, 26, 34, 88, 96
 — longa ganglii ciliaris, vide: ramus communicans nervi nasociliaris cum ganglione ciliari
 — mesenterii *II.* 19, 50, 71, 77, 78, 79, 80, *III.* 214
 — motoria nervi trigemini, *portio minor n. trigemini III.* 1, 35, 95, 97, 103, 105
 * nervi hypoglossi *III.* 26
 — spinalis, vide etiam: radix dorsalis, ventralis *III.* 90
 — — (L. 1.) *III.* 86
 — — (Th. 12.) *III.* 86
 * — splanchnici *III.* 90
 — trigemini, vide etiam: radix motoria, sensoria *III.* 105
 — oculomotoria ganglionis ciliaris, *radix brevis ggl. ciliaris III.* 100, 101
 * palatinalis dentis *II.* 10
 — pili *III.* 268
 — posterior nervi spinalis, vide: radix dorsalis sensoria nervi trigemini, *portio major n. trigemini III.* 1, 35, 95, 97, 103
 — spinales nervi accessorii, *n. accessorius spinalis III.* 26, 35, 73, 95, 96, 108, 124
 * superior ansae cervicalis, *ramus sup. ansae hypoglossi III.* 119
 — unguis *III.* 264
 * venae thalamostriatae *III.* 24
 — ventralis nervi spinalis, *radix ant. n. spinalis III.* 1, 83, 88, 90, 91, 92, 95, 124
 — — — (C. 1.) *III.* 73
 ramus (-i)
 — acromialis arteriae thoracoacromialis *III.* 126
 — ad pontem *III.* 72, 73
 — alveolares superiores anteriores nervi infraorbitalis *III.* 102
 — — — posteriores arteriae infraorbitalis *III.* 114, 115
 — — — nervi maxillaris *III.* 96, 101, 102, 114, 115, 186
 — anastomaticus, vide: ramus communicans
 — anterior arteriae thyroideae superioris *III.* 120, 126
 — descendens arteriae pulmonalis *III.* 201
 — nervorum intercostalium, vide: rami ventrales
 — — obturatorii *III.* 165
 — sulci lateralis, *r. ant. horizontalis III.* 3
 * arcuatus dorsalis arteriae spinalis posterioris *III.* 91
 — ventralis arteriae spinalis anterioris *III.* 91
 * arteriae bronchialis *II.* 121
 * cerebri anterioris *III.* 71
 * — mediae *III.* 41, 71
 — hepaticae *II.* 69, 81
 — lienalis *III.* 155
 * — mesentericae superioris *III.* 214
 — pulmonalis *II.* 114
 — ascendens sulci lateralis, *r. ant. ascendens III.* 3
 * auricularis nervi vagi *III.* 106, 108, 185
 * — posterior arteriae carotidis externae *III.* 110
 — bronchiales, *an. bronchiales II.* 37
 — nervi vagi *III.* 152
 * buccales inferiores nervi facialis *III.* 112
 — nervi facialis *III.* 107, 112, 113

- * ramus buccalis superior nervi facialis III. 112
- calcanei laterales arteriae tibialis posterioris III. 180
- mediales arteriae tibialis posterioris III. 181
- cardiacus inferior nervi vagi III. 152, 153, 186, 187
- superior nervi vagi III. 121, 122, 123, 152, 153
- * caroticus nervi glossopharyngei III. 122
- carpeus palmaris arteriae radialis, *v. carpeus rad. a. radialis* III. 139
- centrales arteriarum cerebri III. 73
- * — — lenticulostriatae III. 73
- * — — thalamostriatae III. 73
- * — — venae cavernosae II. 161
- circumflexus arteriae coronariae sinistrae II. 206, 207, 208
- colli nervi facialis III. 107, 112, 113, 117, 118
- communicans, *v. anastomaticus*
- * — albus nervi spinalis, vide etiam: ramus communicans nervi spinalis III. 90, 150, 152, 153
- * — — griseus, vide etiam: ramus communicans nervi spinalis III. 90, 150, 152, 153, 187
- * — — inter nervos cervicales III. 124
- * — — — medium et ulnarem III. 140
- * — — nervi facialis cum nervo trigemino III. 112
- * — — — cum plexu cervicali III. 112
- * — — — cum plexu tympanico III. 106
- * — — — cum ramo auriculari nervi vagi III. 106
- — — nasociliaris cum ganglione ciliari III. 101
- * — — spinalis cum trunco (ganglione) sympathico III. 186, 187, 190
- * — — vagi cum ganglione cervicali superiori III. 108
- * — trunci sympathici cum plexu brachiali III. 186, 187
- * corticales, vide: *arteriae et venae corticales
- cutanei anteriores nervi femoralis III. 169, 175, 178, 185
- — — intercostalium III. 185
- * — — arteriae thoracicae internae III. 150
- — lateralis nervi iliohypogastrici III. 169
- — — intercostalium III. 133, 185
- — rami dorsalis arteriae intercostalis posterioris III. 150
- — — dorsalium nervorum thoracicorum III. 163, 185
- — medialis rami dorsalis arteriae intercostalis posterioris III. 150
- — — dorsalis nervorum thoracicorum III. 163, 185
- nervi obturatorii III. 168, 169, 179, 185
- deltoides arteriae thoraconromialis III. 126
- descendens arteriae coronariae, vide: ramus interventricularis
- dexter arteriae hepaticae propriae II. 52, III. 154
- — *pulmonalis*, vide: arteria pulmonalis
- dextra
- venae portae II. 68
- * digastricus nervi facialis III. 112, 115
- dorsalis arteriae intercostalis posterioris, *v. dors. a. intercostalis* III. 150
- nervorum cervicalium III. 185
- — (C. 3.) III. 185
- — lumbalium III. 185
- — (L. 1.) III. 163
- — sacralium III. 185
- — spinalis, *v. post. n. spinalis* III. 83, 90, 92, 150, 163
- — — (C. 4.) III. 85.
- — — (L. 1.) III. 86
- — thoracicorum III. 163, 185
- ramus dorsalis nervi ulnaris, *v. dors. manus n. ulnaris* III. 133, 135, 112
- epiploici arteriae gastroepiploicae II. 47
- — — dextrae III. 154
- esophageae aortae, *aa. oesophageae* II. 37
- externus nervi accessorii III. 26, 96, 108, 186
- — — laryngei superioris III. 120, 121, 122
- femoralis nervi genitofemoralis, *n. lumboinguinalis* III. 158, 171, 185
- frontalis arteriae meningae mediae III. 115
- — — temporalis superficialis III. 110
- — nervi facialis III. 112
- * gastrici arteriae gastroepiploicae dextrae III. 154
- genitalis nervi genitofemoralis, *n. spermaticus ext.* III. 171
- *hyoideus a. thyroideae superioris*, vide: ramus infrahyoideus
- *inferior ansae hypoglossi*, vide: radix inferior ansae cervicalis
- — arteriae gluteae superioris III. 173
- — *ossis ischii*, vide: ramus ossis ischii
- — pubis I. 118, 119, 120, II. 150, 155, 169, 172, 176
- infrahyoideus arteriae thyroideae superioris, *v. hyoideus* III. 119, 120, 121
- infrapatellaris nervi sapheni III. 175
- * intercaroticus nervi glossopharyngei III. 186
- intercostales anteriores arteriae thoracicae internae, *rr. intercostales a. mammariae int.* III. 123, 148, 150
- — — venae thoracicae internae, *rr. intercostales v. mammariae int.* III. 148
- * intermedius venae portae II. 68
- internus nervi accessorii III. 26, 96, 186
- — — laryngei superioris III. 120, 121
- interventricularis anterior arteriae coronariae sinistrae, *v. descendens ant. a. coronariae sin.* II. 206, 207
- — posterior arteriae coronariae dextrae, *v. descendens post.* II. 208, 209
- * labiales inferiores nervi facialis III. 112
- superiores nervi infraorbitalis III. 107, 112
- lateralis nervi supraorbitalis, *n. supraorbitalis* III. 98, 102, 104, 107, 236
- — (ramorum posteriorum nervorum cervicalium) III. 185
- — — (— — nervorum lumbalium) III. 185
- malleolares posteriores laterales arteriae tibialis posterioris, *a. malleolaris post. lat.* III. 180
- — — mediales arteriae tibialis posterioris, *a. malleolaris post. med.* III. 181
- mammarii arteriae intercostalis posterioris III. 150
- — — thoracicae internae III. 150
- mandibulae, vide etiam: processus condylaris, coronoides I. 47, 49, II. 6, 32, 36
- marginalis mandibulae nervi facialis III. 107, 112, 113
- * — sinister arteriae coronariae sinistrae II. 206
- medialis nervi supraorbitalis, *v. frontalis n. frontalis* III. 98, 102, 107, 112, 236
- — (ramorum posteriorum nervorum cervicalium) III. 185
- — — (— — nervorum lumbalium) III. 185
- * muscularis arteriae gluteae superioris III. 173
- * — — intercostalis posterioris III. 150
- — nervi femoralis III. 170
- — ischiadici III. 173, 174
- — mediani III. 130
- * plexus sacralis III. 190
- nasalis externus nervi ethmoidalis anterioris III. 107
- — — infraorbitalis III. 107, 112
- laterales nervi ethmoidalis anterioris III. 105

- rami nasales mediales nervi ethmoidalis anterioris *III*. 101
- — — — posteriores superiores laterales nervi maxillaris *III*. 105
 - — — — mediales nervi maxillaris *III*. 101
 - nervi facialis *II*. 27
 - ossis ischii, *r. inf. ossis ischii I*. 118, 119, *II*. 135, 150, 155, 159, 177
 - palmaris nervi mediani *III*. 130, 132
 - — — ulnaris, *r. colaris manus III*. 132
 - — profundus arteriae ulnaris, *r. colaris prof. a. ulnaris III*. 140, 141, 144
 - — superficialis arteriae radialis, *r. colaris spf. a. radialis III*. 138, 140, 144
 - palpebrales inferiores nervi infraorbitalis *III*. 107, 112
 - * — — superiores nervi supraorbitalis *III*. 107, 112
 - parietalis arteriae temporalis superficialis *III*. 110
 - perforans arteriae metatarsae *III*. 182
 - — — thoracicae internae *III*. 150
 - perineales nervi cutanei femoris posterioris *III*. 162, 185
 - * — peripheralis venae cavernosae *II*. 161
 - pharyngei nervi glossopharyngei *III*. 186
 - — — vagi *III*. 108
 - plantaris profundus arteriae dorsalis pedis *III*. 182
 - posteriores arteriarum intercostalium, vide: rami dorsales
 - — nervorum cervicalium, lumbalium, sacralium, spinalium, thoracalium, vide: rami dorsales
 - — — obturatorii *III*. 165
 - — — sulci lateralis cerebri *III*. 3
 - profundus nervi radialis *I*. 275, *III*. 127, 135
 - — — ulnaris *III*. 131, 140, 141
 - scrotales anteriores arteriarum pudendarum externarum *III*. 159
 - — — nervi ilioinguinalis *III*. 170, 171
 - — — posteriores arteriae pudendae internae *III*. 162
 - sinister arteriae hepaticae propriae *II*. 52, 53, *III*. 154
 - — — pulmonalis, vide: arteria pulmonalis sinistra
 - — — venae portae *II*. 68
 - spinalis anterior arteriae intercostalis posterioris *III*. 150
 - — arteriarum *III*. 91
 - — posterior arteriae intercostalis posterioris *III*. 150
 - stylohyoideus nervi facialis *III*. 115
 - superficialis arteriae gluteae superioris, *r. sup. a. gluteae sup. III*. 173
 - — — radialis *III*. 144
 - — — transversae colli (var.: arteria cervicalis superficialis) *III*. 118, 119, 120, 121
 - — — ulnaris *III*. 144
 - — nervi radialis *III*. 127, 132, 133, 135, 138, 139, 112, 113, 145
 - superior a. gluteae sup., vide: ramus superficialis
 - — ansae hypoglossi, vide: radix superior ansae cervicalis
 - — nervi oculomotorii *III*. 101
 - — ossis ischii, vide: corpus ossis ischii
 - — pubis *I*. 118, 119, 300, *II*. 150, 155, 159, 176, 177
 - sympathicus ad ganglionem ciliare, radix symp. ggl. ciliaris *III*. 100, 101
 - temporales nervi facialis *III*. 107, 112, 113
 - venae bronchialis *II*. 121
 - * — capitis superficialis *III*. 79
 - portae *II*. 69, 81
 - pulmonalis *II*. 121
- *rami venae thyroideae inferioris *III*. 149
- ventralis nervi spinalis, *r. ant. n. spinalis*, vide etiam: plexus (nervorum spinalium) *III*. 83, 90, 92, 150
 - — — — (C. 4.), ramus ant. *III*. 85
 - — — — (L. 1.) *III*. 86
 - colares, vide: rami palmares
 - zygomatici nervi facialis *III*. 107, 112
 - zygomaticofacialis *III*. 114, 115
- raphe medullae oblongatae *III*. 53, 54
- * — muscoli bulbospongiosi *II*. 150, 154, 155
 - * — — — mylohyoidei *I*. 224, *III*. 123
 - palati *II*. 29, 30
 - palpebralis lateralis *I*. 215
 - perinei *II*. 155
 - pharyngis *II*. 28, 32, 38, 187, *III*. 108
 - pontis *III*. 50, 52
 - pterygomandibularis *I*. 219, *II*. 24, 33, *III*. 186
- recessus (-us)
- costodiaphragmaticus, sinus phrenicocostalis *I*. 249, *II*. 117, 118, 119, 120, 134, 185, 212, 213, 214, *III*. 148
 - costomediastinalis, sinus costomediastinalis *II*. 120
 - duodenalis inferior, recessus duodenojejunalis inf. *II*. 74
 - — superior, recessus duodenojejunalis sup. *II*. 49, 74
 - ellipticus *III*. 255, 262
 - epitympanicus *III*. 251
 - iliocecalis inferior *II*. 78
 - — superior *II*. 78
 - inferior omentalis *II*. 80
 - infundibuli ventriculi tertii *II*. 182, 183, *III*. 21, 68, 72
 - intersigmoideus *II*. 50, 75, 79
 - lateralis fossae rhomboideae, vide: recessus lateralis ventriculi quarti
 - — ventriculi quarti, recessus lat. fossae rhomboideae *III*. 37, 68
 - licalis bursae omentalis *II*. 78, 81
 - membranae tympani anterior *III*. 253
 - — — posterior *III*. 253
 - opticus *III*. 4, 10, 20, 21, 81, 68
 - pharyngeus, recessus pharyngeus (Rosenmüller) *II*. 86
 - pinealis ventriculi tertii *II*. 181, *III*. 10, 21, 36, 43, 68
 - * — piriformis *II*. 21, 31, 34, 39, 96
 - precardiacus *II*. 120
 - sacciformis *I*. 177
 - sphenothmoidalis *II*. 26, 86, 88
 - sphericus *III*. 255
 - superior omentalis *II*. 80
 - suprapinealis *III*. 21, 43, 68
- rectum, *intestinum rectum II*. 1, 50, 51, 52, 61, 75, 79, 80, 122, 142, 143, 164, 165, 166, *III*. 160, 161, 188, 189, 190, 205, 210, 215
- regio (-nes)
- analis *III*. 162
 - antebrachii anterior *III*. 138, 139
 - — posterior *III*. 135
 - axillaris *III*. 126, 199
 - brachii anterior *III*. 136, 137
 - — posterior *III*. 135
 - buccalis *III*. 107, 112, 113, 114, 115
 - capitis *III*. 107, 112, 113, 114, 115
 - colli *III*. 116—123
 - — anterior *III*. 116—123
 - — lateralis *III*. 116—123, 126, 199
 - — posterior *III*. 112, 163, 185
 - cruris anterior *III*. 176
 - — posterior *III*. 177
 - cubiti anterior, vide etiam: fossa cubitalis *III*. 139

- regio cubiti posterior *III*. 135
 — deltoidea *III*. 131
 — *dorsalis manus*, vide: dorsum manus
 — — *pedis*, vide: dorsum pedis
 — dorsi *III*. 163, 185
 — epigastrica *III*. 185
 — faciei *III*. 107, 112, 113, 114, 115
 — femoris anterior *III*. 170, 171
 — — posterior *III*. 173, 174
 — frontalis *III*. 107, 112, 113, 114, 115, 185
 — genus anterior *III*. 176
 — — posterior *III*. 174, 177
 — glutea, *regio glutea III*. 163, 172, 173, 185
 — hypochondriaca *III*. 185
 — infraclavicularis *III*. 126, 199
 — infraorbitalis *III*. 107, 112, 113, 114, 115
 — infratemporalis *III*. 114, 115
 — inguinalis *III*. 170, 185
 — lumbalis *III*. 163, 185
 — mammalis *III*. 199
 — *mediana dorsi*, vide: regio vertebralis
 — mentalis *III*. 107, 112, 113, 114, 115
 — nasalis *III*. 107, 112, 113, 114, 115
 — occipitalis *III*. 107, 112, 113, 114, 115, 163, 185
 — oralis *II*. 2, *III*. 107, 112, 113, 114, 115
 — orbitalis *III*. 107, 112, 113, 114, 115
 — parietalis *III*. 107, 112, 113, 114, 115, 185
 — parotideomasseterica *III*. 107, 112, 113, 114, 115
 — *pectoris III*. 148—153
 — perinealis masculina, vide etiam: perineum *III*. 162
 — *plantaris pedis*, vide: planta pedis
 — publica *III*. 170, 171, 185
 — sacralis *III*. 163, 185
 — scapularis *III*. 134, 163, 185
 — sternocleidomastoidea *III*. 116—122
 * — subinguinalis *III*. 170, 171
 * — sublingualis *II*. 22
 — *submaxillaris*, vide: trigonum submandibulare
 — temporalis *III*. 107, 112, 113, 114, 115, 185
 — umbilicalis *III*. 185
 — urogenitalis *III*. 162
 — vertebralis, *regio mediana dorsi III*. 163, 185
 — *rolaris manus*, vide: palma manus
 — zygomatica *III*. 107, 112, 113, 114, 115
 rea *II*. 122—133, 141
 — dexter *II*. 51, 52, 53, 81, 122, 123, 134, 188, *III*. 158, 206, 207, 215
 * — lobatus *II*. 127
 — sinister *II*. 51, 52, 53, 81, 122, 124, 125, 134, 188, *III*. 158, 188, 191, 205, 214
 rete (arteriosum) articulare genus *III*. 176
 — — calcanei *III*. 180
 * — — corii *III*. 267
 — — malleolare laterale *III*. 182
 — — — mediale *III*. 182
 — — patellae *III*. 176
 * — subpapillare *III*. 267
 — testis, *rete testis (Halleri) II*. 147
 * — (venosum) calcanei *III*. 178
 * — — corii *III*. 267
 — — dorsale manus *III*. 112, 143
 — — pedis *III*. 178, 183
 * — palmare, *rete venosum volae manus III*. 145
 — — plantare *III*. 183
 * — subpapillare *III*. 267
 reticulum capillare remis *II*. 132
 retina *III*. 216, 219, 220, 221, 228
 retinaculum (-a)
 — cutis *II*. 180
 — extensorum manus, *lig. carpi dors. I*. 262, 274, 275, 276, 277, 283, 284, 286, *III*. 127, 142, 143
 — extensorum pedis inferius, *lig. cruciatum cruris I*. 306, 307, 308, 309, 310, 311, 318, 319, *III*. 166, 176, 180
 — — — superius, *lig. transversum cruris I*. 306, 307, 309, 319, *III*. 176
 — flexorum manus, *lig. carpi transversum I*. 185, 191, 279, 280, 285, *III*. 138, 140
 — — pedis, *lig. laciniatum I*. 313, 314, 315, 316, 317, 318
 — musculorum peroneorum inferius *I*. 308, 309
 — — — superius *I*. 308, 309, 319
 — patellae laterale *I*. 200, 201, 308
 — — mediale *I*. 200, 296, 297, 298, 300
 rhinencephalon *III*. 20
 rhombencephalon *III*. 35, 36, 37, 38, 82, 108
 rima oris *II*. 2, 4
 — palpebrarum *III*. 237
 — pudendi *II*. 165
 rostrum corporis callosi *III*. 4, 10, 20, 21
 — sphenoidale *I*. 23, *II*. 83
 rudimentum *processus vaginalis*, vide: vestigium
 processus vaginalis
 rugae vaginales *II*. 168

S

- sacculus *III*. 246, 254, 260
 — laryngis, *appendix ventriculi laryngis II*. 105
 *saccus durae matris *III*. 70, 87, 92, 93, 108
 — endolymphaticus *III*. 246, 259, 260
 — lacrimalis *III*. 238
 *salpinx (gr.), vide: tuba
 *scala anterior, vide: fossa cranii anterior
 * — media, vide: fossa cranii media
 * — posterior, vide: fossa cranii posterior
 — tympani *III*. 254, 257, 260, 261
 — vestibuli *III*. 254, 256, 257, 261
 scapha *III*. 242, 243
 scapula *I*. 103, 104, 105, 174
 scapus pili *III*. 268
 sclera *III*. 216, 217, 219, 220, 221
 serotum *II*. 142, 143, 148, 150, *III*. 189
 segmentum (-a)
 — anterius pulmonis dextri *II*. 114, 115, 116
 — — — sinistri *II*. 114
 — apicale lobii superioris pulmonis dextri *II*. 114, 115, 116
 — — — — pulmonis sinistri *II*. 114
 — — (superius) lobii inferioris pulmonis dextri *II*. 114, 115, 116
 — — — — inferioris pulmonis sinistri *II*. 114
 — apicoposterius *II*. 114
 — basale anterius pulmonis dextri *II*. 114, 115, 116
 — — — sinistri *II*. 114
 — laterale pulmonis dextri *II*. 114, 115, 116
 — — — sinistri *II*. 114
 — mediale seu cardiacum pulmonis dextri *II*. 114, 116
 — — posterius pulmonis dextri *II*. 116
 — — — sinistri *II*. 114
 — bronchopulmonalia, *lobuli pulmonis II*. 111, 115, 116
 — — pulmonis dextri *II*. 115, 116
 — cardiacum, vide: segmentum basale mediale
 — laterale *II*. 114
 — lingulare inferius *II*. 114
 — — superius *II*. 114
 — mediale *II*. 114, 115, 116
 * — medullae spinalis *III*. 88, 124, 184
 * — — (C. 1.) *III*. 88
 * — — (C. 5.) *III*. 88
 * — — (L. 1.) *III*. 88
 * — — (L. 3.) *III*. 88
 * — — (S. 4.) *III*. 88
 * — — (Th. 8.) *III*. 88

- segmentum posterius pulmonis dextri *II.* 114, 115, 116
 — — — sinistri *II.* 114
 — subapicale seu subsuperius *II.* 114
 — subsuperius, vide: segmentum subapicale
 sella turcica *I.* 58, 62, 151, *III.* 247
 semicanalis musculi tensoris tympani *I.* 19
 — tubae auditivae *I.* 19
 septula testis *II.* 147
 septum (-a)
 — atriorum cordis, vide: septum interatriale
 — atrioventriculare *II.* 193, 196
 — interalveolaria *I.* 48, *II.* 13, 15
 — interatriale, *septum atriorum II.* 192, 193, 210
 * — interlobularia hepatis *II.* 69
 — intermusculare brachii laterale, *septum inter-*
musculare humeri lat. I. 269
 — — — mediale, *septum intermusculare humeri*
med. I. 263, 271, 272, 273, *III.* 136, 137
 — — — cruris anterior *I.* 307, 308
 — — — posterior *I.* 304, 305
 — interradicularia, *septa intraalveolaria I.* 48, *II.* 13
 — interventriculare, *septum ventriculorum II.* 195,
 197, 205
 — linguae *II.* 25
 — mediastinale, vide: mediastinum
 — membranaceum *II.* 83
 — nasi *II.* 23, 31, 83, 87, *III.* 104, 238
 — — osseum *I.* 61
 — orbitale *III.* 236
 — pellucidum *II.* 181, *III.* 4, 10, 20, 21, 23, 24,
 25, 40, 41, 45, 46, 47, 72
 — penis, *septum penis (pectiniforme) II.* 140, 155,
 159, 160, 162, 163, *III.* 159
 — rectovaginale *II.* 176
 — rectovesicale *II.* 138, 142, 151
 — sinuum frontalia *I.* 69
 — — sphenoidalia *I.* 25
 * — tubae auditivae *III.* 252
 — ventriculorum cordis, vide: septum interven-
triaculare
 sinus (-us)
 — anales, *sinus rectales II.* 62
 — aortae *II.* 196
 — (arteriosus) caroticus, vide: sinus caroticus
 — caroticus *II.* 23, *III.* 115, 119, 120, 121
 — coronarius *II.* 208, 209, 210
 — costomediastinalis, vide: recessus costomediasti-
nalis
 — epididymidis *II.* 149
 — ethmoidalis, vide etiam: cellulae sinus ethmoi-
dalis anteriores, mediae, posteriores I. 31, 60, 63,
 64, 69, 151, *II.* 86, 87
 — frontalis *I.* 61, 62, 63, 69, *II.* 26, 83, 86, 87, 88
 — lactiferi *II.* 179, 180
 — lienis *II.* 72
 — maxillaris, *sinus maxillaris (Highmori) I.* 64,
 65, 69, *II.* 87
 — obliquus pericardii *II.* 217
 — paranasales, vide etiam: sinus ethmoidalis, fron-
talis, maxillaris, sphenoidalis I. 69, *II.* 86, 87,
III. 103, 104, 105, 106, 229, 234, 238
 — phrenicocostalis, vide: recessus costodiaphrag-
maticus
 — phrenicomediastinalis *II.* 120
 — pleurae, vide: recessus costodiaphragmaticus,
 costomediastinalis
 — — costomediastinalis, vide: recessus costomedia-
stinalis
 — — phrenicocostalis, vide: recessus costodiaphrag-
maticus
 — renalis *II.* 81
 — sphenoidalis *I.* 61, 62, 63, 151, *II.* 25, 26, 83, 86,
 88
 — tarsi *I.* 137, 143
 — transversus pericardii *II.* 216, 217
 — venarum cavarum *II.* 193
 sinus (venosus) cavernosus *II.* 25, *III.* 77, 78, 247
 — — — dexter *III.* 97, 98
 — — — durae matris *III.* 71, 75, 76, 77, 79
 * — — — baseos cranii *III.* 78
 * — — — intercavernosus anterior *II.* 182, 183, *III.* 78
 — — — posterior *II.* 182, 183, *III.* 78
 — occipitalis *III.* 76, 78
 — petrosus inferior *III.* 78, 247
 — — superior *III.* 77, 78, 247
 — — rectus *III.* 75, 77, 78, 80, 96
 — — sagittalis inferior *III.* 77
 — — superior *III.* 74, 75, 77, 76, 78, 79, 80,
 111
 — — sclerae, *sinus venosus sclerae (canalis Schlem-*
mi) III. 219, 220, 221
 — — sigmoideus *III.* 1, 75, 76, 77, 78, 85, 95, 108,
 111, 124, 247
 — — sphenoparietalis *III.* 78
 — — transversus *III.* 75, 76, 77, 78, 111, 247
 * situs cordis *II.* 212—217
 * — viscerum abdominis *II.* 47—53
 * — — thoracis *II.* 117—119
 skeleton *I.* 1
 spatium (-a)
 — intercostale *IV.* 11, 120
 — interglobularia *II.* 11
 * — parapharyngeum *II.* 33, 36
 — perichoroideale *III.* 221
 — perilymphaticum *III.* 262
 — perinei profundum *II.* 154
 — — superficiale *II.* 154
 * — perineurale *III.* 195
 * — perivascularis encephali (Virchow—Robin) *III.*
 79
 * — perivesicale *I.* 244
 — retroperitoneale *II.* 78, *III.* 158
 * — retropharyngeum *II.* 36
 — retropubicum, *spatium praevessicale (Retzii) II.*
 80, 143
 — suprasternale *I.* 227
 *speculum rhomboideum *I.* 251
 spina angularis, vide: spina ossis sphenoidalis
 — ethmoidalis *I.* 22
 — helcis *III.* 241, 243, 244, 245
 — iliaca anterior inferior *I.* 118, 119, 120, 195
 — — — superior *I.* 118, 119, 120, 193, 194, 232,
 235, 237, 239, 240, 241, 242, 245, 247, 250, 287,
 288, 290, 291, 295, 296, 297, 298, *II.* 138, 142,
 174
 — — — posterior inferior *I.* 118, 194
 — — — superior *I.* 118, 119, 194, 291, *III.* 172
 — ischiadica *I.* 118, 119, 120, 193, 195, 197, *II.*
 176
 — mentalis *I.* 48, 49, *II.* 14, 15, 17
 — nasalis, *spina nasalis post. II.* 12, 13, 16
 — — anterior *I.* 34, 35, 66, 68, *II.* 5, 7, 18, 23, 83,
 84, 85
 — — ossis frontalis, *spina frontalis I.* 25, 26, 27,
II. 26, 88
 — — palatini, *spina nasalis post. I.* 42
 — — posterior, vide: spina nasalis
 — ossis sphenoidalis, *spina angularis I.* 22, 24
 — scapulae *I.* 103, 172, 175, 251, 252, 267, 268, 269,
III. 134
 — supra mentum *I.* 15
 — trochlearis *III.* 232, 234
 — tympanica major *I.* 15
 splanchnocranium, vide: cranium viscerale
 splanchnologia *II.* 1—172
 splenium corporis callosi *II.* 181, *III.* 4, 8, 10, *II.* 20,
 21, 47, 57, 72, 109
 *spongiosa sclerae *III.* 220
 squama frontalis *I.* 25, 27, 55, 68
 — occipitalis *I.* 13, *II.* 55, 73
 stapes *III.* 106, 246, 250, 254
 statoconium, *otoconia III.* 262

- sternum, vide etiam: manubrium sterni, processus xiphoides *I.* 95, 96, *II.* 119, 120, *III.* 125, 150
- stratum
- cerebrale retinae *III.* 220
 - * — circulare myocardii *II.* 203
 - * — tunicae muscularis intestini tenuis *III.* 195
 - — — ventriculi *II.* 42, 43
 - * — vesicae urinariae *II.* 136, 137
 - corneum cutis *III.* 268
 - * — fibrarum nervearum *III.* 228
 - ganglionare nervi optici *III.* 228
 - retinae *III.* 228
 - granulosum cutis *III.* 268
 - * — externum retinae *III.* 228
 - * — internum retinae *III.* 228
 - *griseum centrale*, vide: substantia grisea centralis
 - * — internum myocardii *II.* 203
 - * — longitudinale tunicae muscularis intestini tenuis *III.* 195
 - — — recti *II.* 61
 - — — ventriculi *II.* 42, 43
 - * — vesicae urinariae *II.* 136, 137, 138
 - lucidum cutis *III.* 268
 - neuroepitheliale retinae *III.* 228
 - papillare corii, *corpus papillare corii* *III.* 267
 - pigmenti corporis ciliaris *III.* 220
 - — iridis *III.* 220
 - — retinae *III.* 220, 228
 - * — plexiforme externum retinae *III.* 228
 - * — internum retinae *III.* 228
 - * — reticulare tunicae muscularis vesicae urinariae *II.* 136
 - * — spinosum cuti *III.* 270
 - superficiale myocardii *II.* 203
- stria longitudinalis lateralis *III.* 14
- — medialis *III.* 14, 15,
 - malleolaris, *stria malleolaris* *III.* 248, 249
 - medullaris fossae rhomboideae *III.* 37, 44, 53
 - — thalami *III.* 61
 - membranae tympani anterior *III.* 248, 249
 - — posterior *III.* 248, 249
 - terminalis *III.* 15, 16, 23, 24
- *structura cutis *III.* 267
- * — dentis *II.* 11
 - * — ductus cochlearis *III.* 261
 - * — intestini *II.* 54
 - * — labyrinthi membranacei *III.* 262
 - * — lienis *II.* 72
 - * — palpebrarum *III.* 236
 - * — partis opticae retinae *III.* 228
 - * — pulmonis *II.* 121
 - * — radiceis pili *III.* 268
 - * — renis *II.* 126
 - * — retinae *III.* 228
 - * — systematis lymphatici *III.* 193—195
- subiculum promontorii *III.* 252
- substantia adamantina dentis, vide: enamelum
- alba cerebelli *III.* 33
 - compacta femoris *I.* 2
 - — processus alveolaris *II.* 11
 - corticalis, vide: cortex
 - grisea centralis, *stratum griseum centrale* *III.* 8, 49
 - * — medullaris, vide etiam: medulla
 - * — cerebelli *III.* 32
 - * — cerebri *III.* 14
 - nigra *II.* 181, *III.* 8, 10, 43, 45, 46, 48, 49, 81
 - ossea dentis vide: cementum
 - perforata anterior *III.* 8, 9, 20, 22
 - — posterior *III.* 22
 - * — spongiosa femoris *I.* 2, 3, 7
 - * — ossis temporalis *III.* 262
 - * — processus alveolaris *II.* 11
- sulcus (-ci)
- angulomarginalis *II.* 2
 - sulcus anuli tympanici, *sulcus annuli tympanici* *I.* 19, 20
 - * — aorticus (pulmonis sinistri) *II.* 111
 - arteriae alveolaris *I.* 34
 - * — — gastroduodenalis *II.* 45
 - * — — lienalis *II.* 45
 - * — — meningeae mediae *I.* 16, 17, 22, 25, 29, 55, 58
 - — occipitalis *I.* 18, 60
 - — subclaviae (costae *I.*), *sulcus subclavius* *I.* 99
 - * — — (pulmonis) *II.* 109, 111
 - — temporalis mediae *I.* 15
 - — vertebralis *I.* 75
 - arteriosi, vide: sulcus arteriae meningeae mediae
 - basilaris pontis *III.* 22, 35, 82
 - calcanei *I.* 141
 - calcarinus, *fissura calcarina* *III.* 4, 5, 9, 10, 44, 47
 - canaliculi mastoidei *I.* 18
 - caroticus *I.* 22, 24, 58
 - carpi *I.* 115, 117
 - centralis, *sulcus centralis (Rolandi)* *III.* 2, 3, 6, 7, 11, 67, 68
 - cerebri *III.* 3, 5, 7, 9
 - chiasmatis *I.* 22
 - cinguli *III.* 4, 5, 10
 - circularis insulae, *sulcus circularis (Reili)* *III.* 11, 26
 - collateralis, *fissura collateralis* *III.* 8, 9, 10, 19, 81
 - coronarius *II.* 190, 191, 200, 201, 210, 215, 216
 - cordis *II.* 160, 191, 215, 216
 - corporis callosi *III.* 5, 20
 - costae *I.* 100
 - cutis *III.* 265, 267
 - * — deltoideopectoralis *I.* 230, 232, 260, 261
 - ethmoidalis *I.* 38
 - frontalis inferior *III.* 2, 3, 6, 7
 - — superior *III.* 2, 3, 6, 7, 11
 - frontopalpebralis *III.* 235
 - hamuli pterygoidei *I.* 23
 - hippocampi, *fissura hippocampi* *III.* 9, 21
 - hypothalamicus *III.* 10, 21
 - infraorbitalis *I.* 34, 64, 66
 - infrapalpebralis, *sulcus palpebromalaris* *III.* 235
 - * — interlobaris renis *II.* 123
 - intermedius posterior *III.* 37
 - interparietalis, vide: sulcus intraparietalis
 - intertubercularis *I.* 107, 108
 - interventricularis anterior, *sulcus longitudinalis ant.* *II.* 190
 - — posterior, *sulcus longitudinalis post.* *II.* 191, 201
 - intraparietalis, *sulcus interparietalis* *III.* 2, 3, 6, 7, 67
 - juxtaauricularis *I.* 119
 - labiofemoralis *II.* 171
 - lacrimalis maxillae *I.* 35
 - — ossis lacrimalis *I.* 36
 - lateralis anterior, *sulcus lat. ant. medullae oblongatae, sulcus ventrolateralis medullae oblongatae* *III.* 34
 - — — medullae spinalis, *sulcus ventrolateralis medullae spinalis* *III.* 26, 82, 89, 91
 - — cerebri, *fissura cerebri lat. (Sylvii)* *III.* 2, 3, 67
 - — posterior, *sulcus dorsolateralis* *III.* 37
 - limitans fossae rhomboideae *III.* 37, 54
 - longitudinalis cordis, vide: sulcus interventricularis
 - malleolaris *I.* 134
 - matricis unguis *III.* 264
 - medianus fossae rhomboideae *III.* 37, 44
 - — linguae *II.* 21, 28, 30
 - — posterior medullae oblongatae, *fissura mediani post. medullae oblongatae* *III.* 37
 - — — spinalis *III.* 91
 - mentolabialis *II.* 2, 3
 - * — muscoli poplitei *I.* 128

- sulcus mylohyoideus *I.* 47, 49, 151
 — nasolabialis *II.* 2, 3
 — nervi petrosi majoris, *sulcus n. petrosi spf. majoris I.* 16, 19
 — — minoris, *sulcus n. petrosi spf. minoris I.* 16, 19
 — — radialis *I.* 106, 269
 — — spinalis *I.* 80, 81
 — — ulnaris *I.* 106, 109, 272
 * — nympholabialis *II.* 171
 — obturatorius *I.* 118
 — occipitales laterales *III.* 2, 3
 — — superiores *III.* 6, 7
 — — transversus *III.* 6, 7
 — olfactorius *III.* 8, 9, 20
 — orbitales *III.* 9, 22
 * — palatinus *II.* 12, 13, 16
 — parietooccipitalis, *fissura parietooccipitalis III.* 4, 5, 10
 * — parolivaris lateralis *III.* 2, 26, 34, 82
 * — — medialis *III.* 2, 26, 34, 82
 * — plantaris lateralis *I.* 312
 * — — medialis *I.* 312
 — postcentralis, *sulcus centralis post. III.* 6
 — precentralis, *sulcus centralis ant. III.* 3, 6, 7, 11
 — praepreputiolabialis *II.* 171
 — promontorii *I.* 20
 — pterygopalatinus *I.* 23, 35, 41
 — pulmonalis thoracis *II.* 120
 — sinus petrosi inferioris, *sulcus petrosus inf. I.* 13, 17, 18, 58
 — — superioris, *sulcus petrosus sup. I.* 16, 17, 58
 — — sagittalis superioris, *sulcus sagittalis I.* 15, 25, 29, 55
 — — sigmoidei, *sulcus sigmoideus I.* 13, 16, 17, 20, 29, 58
 — — transversus, *sulcus transversus I.* 13, 58
 * — subcallosus anterior *III.* 21
 * — — posterior *III.* 21
 — subclavius pulmonis, *sulcus n. subclaviae II.* 106, 109, 111
 — subparietalis *III.* 4, 10
 — tali *I.* 140, 143
 — temporalis inferior *III.* 9
 — — medius *III.* 2, 3, 9, 11
 — — superior *III.* 2, 3, 11
 — tendinis musculi flexoris hallucis longi *I.* 139, 140, 142
 — — — peronei longi *I.* 138, 148, 149
 — terminalis atrii dextri cordis *II.* 192
 — — linguae *II.* 21, 30
 — tubae auditivae *I.* 24
 * — venae azygos (pulmonis dextri) *II.* 112
 — — cavae, *fossa v. cavae II.* 65
 — — subclaviae *I.* 99
 supercilium *III.* 235
 sustentaculum tali *I.* 136, 138, 141, 142
 sutura (-ae)
 — coronalis *I.* 54, 55, 56, 57, *III.* 68
 — cranii *I.* 40, 54, 55, 56, 57, 58, 59, 61, 63
 — frontalis seu metopica *I.* 56
 — frontoethmoidalis *I.* 57
 — frontomaxillaris *I.* 56
 — frontonasalis *I.* 56
 — frontozygomatica, *sutura zygomaticofrontalis I.* 56, 57
 — incisiva *II.* 12, 13, 16
 — intermaxillaris *I.* 56
 — internasalis *I.* 56
 * — lacrimoethmoidalis *I.* 57
 — lacrimomaxillaris *I.* 57
 — lambdoidea *I.* 54, 57, *III.* 76
 — metopica seu frontalis *I.* 56
 — nasomaxillaris *I.* 56
 — occipitomastoidea *I.* 59
 sutura palatina mediana *I.* 59, *II.* 12, 13, 16
 — — transversa *I.* 59, 61, 63, *II.* 12, 13, 16
 — sagittalis *I.* 54, *III.* 76
 — sphenofrontalis *I.* 56, 57
 — sphenoorbitalis *I.* 58
 — sphenoparietalis *I.* 57, 58
 — sphenosquamosa *I.* 57, 58, 59
 — sphenozygomatica *I.* 56
 — squamosa *I.* 57
 — temporozygomatica, *sutura zygomaticotemporalis I.* 57, *II.* 33
 — zygomaticofrontalis, vide: sutura frontozygomatica
 — zygomaticomaxillaris *I.* 40, 56, 57, 59
 — zygomaticotemporalis, vide: sutura temporozygomatica
 symphysis ossium pubis, vide: symphysis pubica
 — pubica, *symphysis ossium pubis I.* 192, 246, 247, 298, *II.* 80, 138, 142, 143, 164, 172, 173, 174, 175, 176, 177, *III.* 159, 189, 190
 synchondrosis petrooccipitalis *I.* 60
 — sphenoooccipitalis *I.* 60
 — sternalis *I.* 95, 170
 syndesmologia *I.* 150—211
 syndesmosis tympanostapedii *III.* 254
 *syphon arteriae carotidis internae *II.* 181, *III.* 78, 98
 systema digestorium, vide: apparatus digestorius
 — lymphaticum, vide etiam: nodi, trunci lymphatici, vasa lymphatica *III.* 192—215
 — nervosum autonomicum *III.* 186—190
 — — centrale *III.* 1—91
 — — periphericum *III.* 95—185
 — respiratorium, vide: apparatus respiratorius
 — urogenitale, vide: apparatus urogenitalis
 — vasorum, vide: angiologia

T

- tenia, vide: tenia
 talus *I.* 12, 136, 137, 139, 140, 143, 213, 214
 tapetum *III.* 14
 tarsus, vide etiam: articulationes, ossa pedis *I.* 137
 — palpebrae inferior *III.* 236
 — — superior *III.* 236
 tegmen tympani *I.* 20, *III.* 253
 tegmentum mesencephali *III.* 10
 *tela adiposa sinus renalis *II.* 126
 — chorioidea, *tela chorioidea III.* 81
 — — ventriculi tertii *III.* 21, 25
 * — subcutanea cutis *III.* 268
 — — nasi *II.* 84, 85
 * — submucosa labiorum oris *II.* 1
 — — tracheae *II.* 107
 — — vesicae urinae *II.* 140
 telencephalon *III.* 1—26
 tendo (-ines)
 — calcaneus, *tendo calcaneus (Achillis) I.* 214, 301, 302, 303, 304, 305, 308, 309, 345, *III.* 177, 181
 * — conii arteriosi *II.* 199
 * — dorsi pedis *I.* 310, 311
 * — indicis *I.* 277
 — musculi abductoris pollicis longi *I.* 281, 282
 — — adductoris magni *I.* 299
 — — bicipitis brachii *I.* 175, 176, 177, 178, 184, 265, 266, 268, 270, 272, 273, 276
 — — —, caput longum *I.* 173, 174
 — — — femoris *I.* 292
 — — brachialis *III.* 139
 — — brachioradialis *I.* 271, 272, 276, 282 *III.* 138
 — — digastrici *II.* 24, 25, 27
 — — extensoris carpi radialis brevis *I.* 276, 284, *III.* 143
 — — — radialis longi *I.* 276, 283, 284, *III.* 143
 — — — ulnaris *I.* 283, 284

- tendo musculi extensoris digitorum, *tendo m. extensoris digitorum comm.* I. 274, 275, 277, 283, 284, 286, III. 143
- — — longi I. 307, 308, 309, 310, 311
 - — — minimi, *tendo m. extensoris digiti quinti propr.* I. 275, 283, 284
 - — — hallucis brevis I. 319
 - — — longi I. 307, 310, 311
 - — — indicis III. 143
 - — — pollicis brevis I. 283, 284, III. 139, 143
 - — — longi I. 276, 283, 284, III. 143
 - — — flexoris carpi radialis I. 185, 271, 272, 273, 281, 282, III. 130, 139
 - — — ulmaris I. 185, 272, 273, 282
 - — — digitorum brevis I. 314, 315, 316
 - — — longi I. 305, 314, 315, 316, III. 181
 - — — profundi I. 273, 277, 279, 285, III. 131, 139, 141
 - — — superficialis I. 272, 273, 277, 279, 280, 285, III. 130, 139, 141
 - — — hallucis longi I. 313, 314, 315, 316, III. 167, 181
 - — — pollicis longi I. 280, III. 130, 141
 - — — humbricalis I. 276
 - — — obliqui superioris III. 231, 233, 234
 - — — obturatorii interni I. 289, 290
 - — — palmaris longi I. 272, 278, III. 139
 - — — peronei brevis I. 310, 311, 315, 317, 319
 - — — longi I. 211, 309, 310, 311, 315, 316, III. 181
 - — — tertii I. 319, III. 180
 - — — quadricipitis I. 200, 206, 207
 - — — recti femoris I. 300
 - — — semimembranosi I. 202
 - — — stapedii III. 254
 - — — subscapularis I. 173
 - — — temporalis II. 87
 - — — tensoris tympani III. 252, 253
 - — — tibialis anterioris I. 211, 310, 311
 - — — posterioris I. 211, 304, 316
 - — — vasti internedii I. 300
- * pollicis I. 277
- tenia (-ae), *taenia*
- choroidea III. 16, 81
 - — — ventriculi quarti III. 37
 - coli II. 59
- * curvaturae ventriculi minoris II. 42
- *fimbriae* III. 18, 19, 81
 - fornicis III. 42, 81
- * laminae epithelialis III. 81
- libera II. 48, 49, 50, 57, 60, 74, 80
 - mesocolica II. 57, 60, 80
 - omentalis II. 60, 80
- * terminalis III. 81
- thalami III. 81
- tentorium cerebelli II. 181, III. 77, 78, 109, 186
- testis II. III, 113, III, 115, 116, 117, 118, 149
- thalamencephalon III. 23
- thalamus II. 181, 184, III. 4, 16, 20, 21, 23, 24, 43, 45, 46, 47, 56, 61, 77, 81
- thenar I. 273, 278, III. 139
- thorax, vide etiam: *cavum, musculi thoracis* I. 1, 97, 98
- thymus II. 185, 213
- tibia I. 133, 134, 135, 201, 202, 203, 204, 205, 206, 207, 209, 211, 214, 305, 318, III. 176
- tonsilla cerebelli III. 29, 30
- lingualis II. 21, 30, 31
 - palatina II. 21, 23, 29, 30, 34, 36, 96, III. 105, 198
 - pharyngea II. 26, 88, III. 105
- *topographia orbitae III. 199
- toruli tactiles III. 267
- *torus intimae arteriae (Ehmeri) II. 163
- * levatorius, *torus m. levatoris reli palatini* II. 86
- * tubarius II. 25, 26, 86, 88, III. 105
- *trabecula (-ae) arachnoideales III. 79
- trabeculae carnea II. 193, 194, 195
- corporis cavernosi penis II. 161, 162
 - lienis. II. 72
- * — osseae I. 2
- septomarginalis II. 193, 194
- trachea I. 224, 225, 229, II. 26, 28, 32, 33, 37, 38, 82, 83, 97, 98, 100, 101, 103, 104, 105, 106, 107, 108, 109, 110, 113, 185, 186, 187, 214, 215, 216, 217, III. 120, 121, 122, 123, 149, 151, 187, 203
- tractus (-us)
- * — angularis laminae superficialis fasciae colli I. 227
- *corticobulbaris*, vide: *tractus corticomuclearis*
 - corticomuclearis, *tractus corticobulbaris* III. 45
 - corticopontinus III. 51
 - corticospinalis III. 45, 46, 51
 - encephali III. 56, 57, 58, 59, 60, 61, 62, 63, 64, 65, 66
 - frontopontinus III. 66
 - iliotalibialis fasciae latae I. 287, 288, 292, 293, 294, 296, 308, 309, III. 170, 172, 173
 - mamillothalamicus, *fasciculus thalamomamillaris (Vieq' d'Azzyri)* III. 42, 56, 61
 - nervosi associationis III. 60
 - — commissurales III. 56
 - occipitopontinus III. 66
 - olfactorius III. 1, 8, 9, 10, 20, 22, 26, 64, 73, 95, 96
 - opticus II. 25, 182, 183, III. 20, 22, 26, 35, 42, 45, 46, 48, 63, 64, 65, 81, 186
 - rubrospinalis, *tractus rubrospinalis (Monakow)* III. 52, 53
 - solitarius III. 53, 55
 - spinalis nervi trigemini III. 38, 52, 53, 54, 55
 - spinocerebellaris anterior III. 53
 - spinothalamicus III. 52
 - spiralis foraminosus III. 258
 - systematis nervosi centralis III. 41—60
 - tectospinalis III. 49, 52, 53
 - tegmentalis centralis III. 49
- tragus III. 242, 245
- *trajectoria epiphysis distalis femoris I. 5
- * — — proximalis femoris I. 4
- trigonum
- caroticum III. 116—123
 - collaterale III. 15, 16, 17, 18, 24, 47
 - femorale, *trigonum femorale (fossa Scarpa major)* III. 170, 171
 - fibrosum dextrum II. 199, 204
 - — sinistrum II. 199
 - habenulae II. 184, III. 23, 47
- * — interseminale II. 137, 151
- *lemnisci* III. 37
 - lumbale, *trigonum lumbale (Petiti)* I. 232, 251, 252
- * — lumbocostale diaphragmatis I. 248
- nervi hypoglossi III. 37
 - — vagi, *ala cinerea* III. 37
 - olfactorium III. 8, 9, 10, 20, 22
 - omoclaviculare seu fossa supraclavicularis major I. 118—125, 227, III. 116—123
 - *retromolare* I. 48, II. 14, 15
- * — sternocostale diaphragmatis I. 248, III. 148
- submandibulare, *regio submaxillaris* III. 116—123
- * — suboccipitale I. 254, 258
- vesicae, *trigonum vesicae (Lichtaudi)* II. 139, 140, 143
- trochanter major I. 2, 6, 127, 128, 129, 195, 196, 197, 198, 199, 289, 290, 291, 293
- minor I. 127, 128, 129, 195, 196, 197, 198, 199
- trochlea humeri I. 106, 108, 109, 180, 183
- musculi obliqui superioris III. 231, 232, 233
 - peronealis calcanei I. 143
 - phalangis, vide: *caput phalangis*
 - tali I. 130, 139, 209, 210

- truncus (-ei)
 —, vide etiam: articulationes, juncturae (ossium trunci) I. 153—171
 — brachiocephalicus, *a. anonyma* II. 37, 109, 110, 189, 190, 191, 206, 211, 213, 214, 215, 216, 217, III. 123, 129, 126, 148, 149
 — celiacus, *a. coeliacus* II. 51, 52, 53, 117, 122, 134, 211, III. 194, 199, 158, 191, 207
 * — cerebri III. 29, 26
 — coeliacus, vide: truncus celiacus
 — corporis callosi III. 4, 10, 20, 21, 57
 — costocervicalis II. 34, 38, III. 122, 123
 — fasciculi atrioventricularis II. 204
 — inferior plexus brachialis III. 120, 121, 122, 123, 124, 129, 129
 * — (lymphaticus -ei), *tr. lymphaticus* III. 192
 — — bronchomediastinalis dexter III. 192, 202
 — — — sinister III. 192, 201
 — — dexter III. 192, 198
 — — intestinalis III. 192, 206, 209
 — — jugularis III. 201
 — — — dexter III. 192
 — — — sinister III. 192, 197, 198, 199
 — — lumbalis III. 210
 — — — dexter III. 192, 206, 209
 — — — sinister III. 192, 206
 — — pulmonalis III. 204
 — — subclavius III. 199
 — — — dexter III. 192
 — — — sinister III. 192, 198, 201
 — medius plexus brachialis III. 120, 121, 122, 123, 124—126
 —, musculi I. 230—255
 —, ossa I. 74—100
 — pulmonalis, *a. pulmonalis* II. 189, 192, 193, 194, 198, 200, 202, 208, 211, 214, 216, 217, III. 151
 — superior plexus brachialis III. 120, 121, 122, 123, 124, 125, 126
 — sympathicus, vide etiam: pars cervicalis, lumbalis, thoracica II. 36, III. 108, 109, 121, 122, 123, 164, 171
 — —, rami interganglionares III. 90
 — thyrocervicalis II. 37, 38, III. 120, 121, 122, 123, 126, 149
 tuba auditiva II. 82, III. 246, 247, 263
 — uterina, *tuba uterina (Fallopia)* II. 164, 165, 166, 167, 168, 169, III. 161, 190, 205, 210
 tuber calcanei I. 112, 143, 209, 212, 312, 313, 314, 315, 316
 — cinereum II. 182, 183, III. 1, 4, 8, 22, 35, 64, 95
 — frontale I. 27
 — ischiadicum, I. 118, 119, 120, 194, 196, 197, 245, 293, 294, II. 142, 154, 155, 172, 173, 174, III. 159, 160, 162, 172
 — maxillae, *tuber maxillare* I. 34, 68, II. 5, III. 101, 114
 — omentale II. 45, 46
 — parietale I. 28
 — vermis cerebelli III. 27, 28, 30, 32
 tuberculum (-a)
 — anterius atlantis I. 75, 76, 157
 — — vertebrae cervicalis I. 80, 81
 — articulare I. 15, 18
 * — buccale dentis II. 10, 12, 14, 16
 — conoideum, *tuberositas coracoidea* I. 102
 — corniculatum, *tuberculum corniculatum (Santorini)* II. 31, 34, 39, 96, 102, 104
 — costae I. 99, 100
 — cuneiforme, *tuberculum cuneiforme (Wrisbergi)* II. 34, 39, 96, 98, 102, 104
 * — dentis II. 10, 12, 14
 — infraglenoidale, *tuberositas infraglenoidalis* I. 105, 174
 — intercondylare laterale, *tuberculum intercondyloideum lat.* I. 135
 — intercondylare mediale, *tuberculum intercondyloideum med.* I. 135
 — — *intercondyloideum*, vide: tuberculum intercondylare
 — intervenosum, *tuberculum intervenosum (Loweri)* II. 192, 210
 — jugulare I. 13
 — labii superioris II. 2, 3
 — laterale processus posterioris tali I. 139
 * — lingualia dentis II. 12, 14
 — majus humeri I. 106, 107, 108, 265, 268, 269
 — mentale I. 47
 — minus humeri I. 107, 108, 265
 — musculi scaleni anterioris, *tuberculum scaleni (Lisfranci)* I. 99
 — nuclei cuneati, *tuberculum cuneatum* III. 37, 85
 — — gracilis, *clava fasciculi gracilis* III. 37, 85
 — obturatorium anterius I. 118
 — — posterius I. 118
 — ossis scaphoidei, *tuberculum ossis navicularis* I. 186
 — — trapezii, *tuberculum ossis multanguli majoris* I. 117
 * — palatinale dentis II. 10
 — pharyngeum I. 14, 59
 — posterius atlantis I. 75, 76, 157, 256
 — — vertebrae cervicalis I. 80, 81
 — pubicum I. 118, 119, 193, 247, II. 155, 156, 175, 177
 — sellae I. 22
 — supraglenoidale, *tuberositas supraglenoidalis* I. 105
 — thyroideum inferius II. 89, 90, 97, 100
 — — superius II. 89, 90, 97, 100
tuberositas coracoidea, vide: tuberculum conoideum, linea trapezoidea
 — costalis, vide: impressio ligamenti costoclavicularis
 — deltoidea I. 106, 108
 — glutea I. 128
 — iliaca I. 119
 — masseterica I. 47
 * — musculi serrati anterioris I. 99
 — ossis cuboidei I. 138, 148, 149
 — — metatarsalis V. I. 137, 138, 308, 315, 316
 — — navicularis I. 138, 144, 145
 — phalangis distalis, *tuberositas unguicularis* I. 116
 — pterygoidea I. 47, 49
 — radii I. 112, 113, 181
 — sacralis I. 89, 90
 — tibiae I. 133, 135, 206, 207, 209, 307
 — ulnae I. 110, 180, 181, 182
 tubuli seminiferi contorti II. 147
 tunica (-ae)
 — albuginea corporis cavernosi penis II. 155, 158, 159, 161, 162, 163
 — — — spongiosi penis, *tunica albuginea corporis cavernosi urethrae* II. 162, 163
 — — testis II. 147
 — conjunctiva (*conjunctiva*) bulbi III. 217, 219, 235
 — — — palpebrae III. 237
 — dartos II. 148, 149, 150
 — fibrosa bulbi, *tunica fibrosa oculi* III. 217
 — — renis, vide: capsula fibrosa
 * — funiculi spermatici II. 119, 150
 — mucosa cavi nasi II. 87
 — — — tympani III. 246
 * — esophagi II. 34, 96
 — faucium II. 23
 — — intestini crassi II. 59, 60
 — — — tenuis III. 195
 — laryngis II. 105
 — oris II. 23, 27, 87
 — pharyngis II. 104
 — recti, *tunica mucosa intestini recti* II. 62
 — sinus maxillaris II. 87
 — tracheae II. 103, 107

tunica mucosa tubae auditivae III. 246
 — — uteri seu endometrium II. 168
 — — vesicae urinariae II. 140
 — muscularis esophagi II. 42, 43
 — — intestini II. 54
 — — — crassi II. 60
 — — — tenuis III. 195
 * — — mucosae II. 54
 — — recti II. 61
 — — tracheae II. 107
 — — uteri seu myometrium II. 168
 * — — ventriculi, vide etiam: fibrae obliquae, stratum circulare ventriculi II. 42, 43, 44
 — — vesicae urinariae II. 136, 137, 138, 140
 — propria corii III. 267
 — serosa intestini II. 54
 — — — crassi II. 60
 — — — tenuis III. 195
 * — — recti II. 61
 — — uteri seu perimetrium II. 168
 — — ventriculi II. 80
 * — — viscerum abdominalium, vide: peritoneum viscerale
 — submusoca II. 54
 — testis II. 118, 119
 — vaginalis testis, *tunica vaginalis propria*, vide etiam: lamina parietalis, visceralis tunicae vaginalis testis II. 143, 144, 145, 148, 149
 — vasculosa bulbi, *tunica vasculosa oculi* III. 218

U

ulna I. 110, III. 116, 117, 178, 180, 183, 184, 185, 186, 187, 188, 266, 273, 283, III. 127, 129
 umbilicus I. 232, 236, 237, 243, II. 211
 umbo membranae tympani III. 248, 249
 uncus, *uncus gyri hippocampi* III. 8, 9, 10, 18, 20
 unguis III. 264
 urachus II. 211
 ureter II. 51, 52, 53, 74, 78, 79, 122, 123, 124, 125, 126, 129, 134, 136, 137, 138, 142, 143, 151, 165, 188, III. 158, 171
 — dexter II. 122, 137, 138, 151, III. 189, 191, 215
 — sinister II. 122, 137, 138, 151, III. 188, 189, 190, 210
 urethra II. 80, 136, 139, 140, 141, 142, 151, 152, 155, 156, 158, 159, 162, 163, 164, 173, 176, III. 162
 — feminina II. 80, 139, 164, 173, 176
 — masculina II. 136, 110, III. 142, 151, 152, 155, 156, 158, 159, 162, 163
 uterus, vide etiam: cervix, fundus uteri II. 80, 164, 165, 166, 167, 168, III. 161, 190, 205, 210
 utriculus III. 246, 254, 259, 260, 262
 — prostaticus II. 140
 uvula, *uvula palatina* II. 29, 30, 34, 36, 96, III. 105
 — vermis cerebelli III. 30, 32
 — vesicae II. 140

V

vagina (-ae) II. 80, 161, 167, 169, 171, 172, 173, 176, III. 210
 — bulbi, *fascia bulbi (Tenoni)* III. 239
 — carotica I. 228
 — externa nervi optici, *vagina n. optici* III. 1, 95, 239
 * — Henlei III. 268
 * — Huxleyi III. 268
 — mucosa, vide: vagina synovialis
 — musculi recti abdominis I. 232, 235, 236, 237
 — — — lamina posterior I. 237
 — processus styloidei I. 18
 * — radiceis pili externa III. 268

vagina synovialis communis musculorum flexorum, *vagina tendinum mm. flexorum* I. 285
 — — digitorum manus, *vaginae mucosae digitorum manus* I. 285
 — — — pedis, *vaginae mucosae digitorum pedis* I. 315
 — — intertubercularis, *vagina mucosa intertubercularis* I. 265, 268
 — — tendinis musculi flexoris carpi radialis, *bursa m. flexoris carpi radialis* I. 285
 — — — flexoris hallucis longi, *vagina tendinis m. flexoris hallucis longi* I. 317, 319
 — — — flexoris pollicis longi, *vagina tendinis m. flexoris pollicis longi* I. 285
 — — — peroneorum communis, *vagina tendinum mm. peroneorum comm.* I. 317, 319
 — — — tibialis posterioris, *vagina tendinis m. tibialis post.* I. 317, 318
 — tendinis, (-um), vide etiam: vagina synovialis tendinis III. 130
 — — carpi I. 285, 286
 * — — dorsales I. 286
 * — — palmares I. 285
 * — — digitorum pedis I. 317
 * — — dorsi manus I. 286
 — — musculorum abductoris longi et extensoris brevis pollicis I. 286
 — — — extensorum carpi radialis I. 286
 — — — carpi ulnaris I. 286
 — — — digitorum et extensoris indicis I. 286
 — — — digiti minimi, *vagina tendinis m. catenatoris digiti V.* I. 286
 * — — — digitorum longi I. 319
 — — — — hallucis longi I. 318, 319
 * — — — pedis I. 317, 318
 — — — — pollicis longi I. 286
 * — — — flexoris digitorum longi I. 317, 318
 * — — — manus I. 280, 281, 282, 285
 * — — — pedis I. 318
 — — — — pollicis longi I. 282, III. 141
 — — — peroneorum I. 317
 — — — — longi plantaris I. 317
 — — — — tibialis anterioris I. 318, 319
 * — — palmares, *vaginae tendinum volares* I. 285
 * — — plantares I. 317
 vallecule cerebelli III. 27, 29, 33
 — epiglottica II. 21, 34, 96, 102
 vallum unguis III. 264
 valva aortae, *valvulae semilunares aortae* II. 196, 197, 199, 205
 — atrioventricularis dextra seu valva tricuspidalis, *valvula tricuspidalis* II. 192, 193, 194, 197, 199, 204
 — — sinistra seu valva mitralis, *valvula bicuspidalis seu mitralis* II. 195, 196, 197, 198, 199, 203, 205
 — cordis, *valvula cordis*, vide: valva aortae, atrioventricularis, trunci pulmonalis
 — ileocecalis, *valvula coli* II. 58
 — mitralis, vide: valva atrioventricularis sinistra
 — tricuspidalis, vide: valva atrioventricularis dextra
 — trunci pulmonalis, *valvulae semilunares a. pulmonalis* II. 193, 194, 199, 204
 valvula (-ae)
 — bicuspidalis, vide: valva atrioventricularis sinistra
 — coli, vide: valva ileocecalis
 — cordis, vide: valvae cordis
 — foraminis ovalis, *valvula septi* II. 195
 * — infundibularis II. 161
 — semilunaris anterior valvae trunci pulmonalis, *valvula semilunaris ant. a. pulmonalis* II. 193, 194, 199, 204
 — — dextra valvae aortae, *valvula semilunaris dext. aortae* II. 196, 197, 199
 — — — trunci pulmonalis, *valvula semilunaris dext. a. pulmonalis* II. 193, 194, 199

- valvula semilunaris posterior valvae aortae, *valvula semilunaris post. aortae* II. 196, 199
- — sinistra valvae aortae, *valvula semilunaris sin. aortae* II. 196, 197, 199
 - — — trunci pulmonalis, *valvula semilunaris a. pulmonalis* II. 193, 194, 199
 - — valvae aortae, *valvula semilunaris aortae* II. 196, 199, 205
 - — — trunci pulmonalis, *valvulae semilunares a. pulmonalis* II. 193, 194, 199
 - sinus coronarii, *valvula sinus coronarii (Thebesii)* II. 192, 210
 - *tricuspidalis*, vide: valva atrioventricularis dextra
 - venae cavae inferioris, *valvula v. cavae inf. (Eustachii)* II. 192, 193, 210
- vas (-a)
- afferens II. 130, 132, 133
 - * — capillaria corticalia renis II. 133
 - efferens II. 132, 133
 - * — hepatis II. 68
 - * — hypophysialis II. 183
 - * — lymphatica capitis superficiales III. 196
 - * — — centrale II. 54, III. 195
 - * — — cervicis III. 197
 - * — — — profundi III. 198
 - * — cordis III. 204
 - * — cruris subcutanea III. 212
 - — — subfascialia III. 212
 - — — superficialia III. 212
 - * — dorsi manus III. 200
 - * — duodeni III. 207
 - * — efferens telae submucosae III. 195
 - — — subserosae III. 195
 - * — epididymidis III. 209
 - * — faciei profunda III. 198
 - * — hepatis III. 194, 205, 207
 - * — intestini tenuis III. 193, 195
 - * — lienis III. 205
 - * — mediastinalia III. 201—204
 - * — — membri inferioris III. 211, 212
 - — — superioris III. 200
 - * — mesenterica III. 208
 - organorum genitalium femininorum III. 210
 - — — masculinorum III. 209
 - * — ovarica III. 205
 - * — penis superficialia III. 209
 - * — perifolliculares intestini tenuis III. 195
 - * — portae hepatis III. 205
 - * — profunda membri inferioris III. 211
 - — — hepatis III. 194
 - — — pulmonis III. 201
 - * — pulmonis II. 121
 - * — regionis axillaris III. 199
 - — — colli lateralis III. 199
 - — — infraclavicularis III. 199
 - * — — mammalis III. 198
 - * — retroperitonealia III. 205, 206
 - * — scroti III. 209
 - * — superficiale hepatis III. 194
 - — — membri inferioris III. 211, 212
 - * — suprarenalia III. 201
 - * — telae submucosae III. 195
 - — — subserosae III. 195
 - * — testis III. 209
 - * — ventriculi III. 207
 - * — vesicae felleae III. 205
 - * — villi intestinalis III. 195
 - * — omenti minoris II. 53
 - * — portalia lobi anterioris hypophyseos II. 175
 - * — sinusoida intralobularia hepatis II. 69
 - — — lobi anteriores hypophyseos II. 175
 - * — spermatica interna II. 51, 52
 - * — terminalia III. 223
- velum medullare inferius, *velum medullare post.* III. 32, 36
- velum medullare superius, *velum medullare ant.* III. 4, 29, 30, 32, 33, 36
- palatinum II. 25, 34, 96
- vena (-ae)
- * — abdominis III. 151, 155, 156
 - angularis III. 77, 98, III. 113
 - *anonyma*, vide: vena brachiocephalica
 - arcuata II. 129
 - *auditiva interna*, vide: vena labyrinthi
 - auricularis posterior III. 111
 - * — auris internae III. 260
 - azygos II. 110, III. 119, 150, 152, 187, 202, 203, 204, 205
 - basilica III. 112, 115, 146, 147
 - brachiocephalica, v. *anonyma* II. 189
 - — dextra, v. *anonyma dext.* II. 109, 185, 211, 213, 214, 215, III. 123, 126, 149, 151, 152, 192, 204
 - — sinistra, v. *anonyma sin.* II. 109, 211, 213, 214, 215, 216, III. 120, 122, 126, 149, 151, 192, 202
 - bronchialis II. 121
 - * — bulbi oculi III. 221
 - — penis, v. *bulbi urethrae* II. 159
 - * — capitis III. 77
 - cava inferior I. 249, II. 51, 52, 64, 65, 68, 79, 81, 122, 134, 189, 191, 192, 193, 201, 204, 208, 210, 211, 217, III. 149, 152, 158, 159, 160, 171, 187, 188, 192, 202, 205, 214
 - — superior II. 109, 117, 189, 190, 191, 192, 193, 194, 200, 201, 204, 206, 208, 210, 211, 213, 214, 215, 216, 217, III. 123, 126, 148, 149, 151, 152, 153, 187, 192, 202, 204
 - cavernosa II. 161
 - centralis lobuli hepatis II. 69
 - — retinae III. 221
 - cephalica I. 259, III. 126, 142, 143, 145, 146, 147
 - cerebelli posterior III. 76
 - cerebri III. 74, 76, 79
 - — interna III. 21, 42, 77
 - — magna, v. *cerebri magna (Galeni)* III. 24, 77, 80
 - — superiores III. 74, 76
 - choroidea oculi, vide etiam: vena vorticiosa III. 218, 219
 - — ventriculi lateralis III. 15, 21
 - ciliaris anterior III. 219, 221
 - * — — brevis III. 221
 - colica dextra III. 214
 - colli III. 116, 117, 118, 119, 120, 121, 122, 123
 - cordis anteriores II. 206
 - — magna II. 195, 206, 207, 208, 209
 - — media II. 208, 209
 - — parva II. 208
 - * — corticales III. 79
 - * — cruris anteriores III. 176
 - — — posteriores III. 177
 - diploica I. 55, III. 79
 - dorsalis penis II. 143, 158, 159, 162, 163, III. 159, 160, 189
 - * — dorsi manus III. 142, 143
 - * — — pedis III. 180
 - * — emissaria, *emissarium* III. 79, 111
 - — bulbi oculi III. 223
 - — mastoidea, *emissarium mastoideum* III. 94
 - epigastrica inferior III. 148
 - — superficialis III. 170
 - — superior III. 148
 - episcleralis III. 221
 - facialis, v. *facialis ant. et v. facialis comm.* II. 35, 36, III. 111, 118, 119, 120, 121, 123
 - — anterior, vide: vena facialis
 - — communis, vide: vena facialis
 - — posterior, vide: vena retromandibularis faciei III. 113, 114, 115

- vena femoralis I. 235, 240, 243, 245, 297, II. 135, 189, III. 158, 170, 171
 * -- femoris anteriores III. 170, 171
 * -- posteriores III. 173, 174
 gastrica sinistra, v. coronaria ventriculi III. 154
 gastroepiploica dextra III. 154, 155
 -- sinistra III. 154
 glutea inferior III. 159
 hemiazygos II. 110, III. 119, 150, 153
 -- accessoria III. 119, 153
 hepatica II. 64, 68, 122, 189, III. 158
 -- dextra II. 68
 * -- intermedia II. 68
 * -- sinistra II. 68
 * hypogastrica, vide: vena iliaca interna
 * hypophysae inferiores II. 183
 * -- superiores II. 183
 * hypothalamicae inferiores III. 172
 ileocolica III. 156, 157
 iliaca communis II. 134, 189, 211, III. 158, 159, 215
 -- dextra II. 134, III. 149
 -- -- sinistra II. 134, 211, III. 171, 192
 -- externa I. 243, 244, 246, 247, II. 176, III. 158, 159, 171
 -- dextra III. 148, 149
 -- -- sinistra III. 161
 -- interna, v. hypogastrica III. 159, 160, 190
 -- dextra III. 149, 199
 intercostalis anterior II. 180
 -- posterior, v. intercostalis III. 149, 150, 152, 153, 180
 interlobaris renis II. 128, 129
 interlobularis hepatis II. 69
 -- renis II. 128
 * intestini crassi III. 157
 * -- tenuis III. 193, 195
 jugularis II. 189
 -- anterior III. 149
 -- externa II. 35, III. 111, 113, 116, 117, 118, 119, 120, 121, 123, 149
 -- -- dextra III. 123
 -- interna I. 228, II. 23, 36, 117, 185, 213, 214, 215, 216, 217, III. 1, 76, 77, 94, 95, 109, III. 115, 119, 120, 121, 122, 123, 149, 151
 -- -- dextra II. 23, 36, 117, 185, 213, 216, III. 123, 151, 192, 198, 202
 -- -- sinistra II. 117, 213, 214, 215, 216, 217, III. 123, 126, 151, 192, 197, 201, 204
 labiales (labiorum pudendi) III. 190
 -- posteriores II. 169
 labyrinthi, v. auditiva int. III. 260
 lienalis II. 51, 53, 71, 72, 79, 80, 81, III. 154, 155
 lumbalis (L. 4.) III. 158
 -- ascendens dextra III. 119
 -- -- sinistra III. 119, 160
 * manus III. 145
 maxillaris, v. maxillaris int. III. 111
 mediana cubiti III. 146, 147
 mesenterica inferior II. 51, 52, 53, 122, III. 157
 -- superior II. 49, 51, 52, 53, 81, III. 154, 155, 156, 157, 214
 nasofrontalis III. 111
 obliqua atrii sinistri, v. obliqua atrii sin. (Marshalli) II. 208
 obturatoria III. 159
 occipitalis III. 111, 113, 114
 ophthalmicae III. 94
 * -- inferior III. 77
 * -- superior III. 77, 98, 111
 ovarica II. 167, III. 161, 205
 * papillaris cutis III. 268
 * parambilicales, vv. parambilicales (Sappey) III. 148, 154
 * parietales pelvis III. 159
 * parietis posterioris trunci III. 119
 pericardiacophrenica II. 214, 215, 216, 217
 vena peronea I. 303
 -- pharyngeae II. 36
 -- phrenica inferior dextra III. 158
 * -- plantae pedis III. 181
 -- poplitea I. 299, III. 174, 177
 -- portae II. 53, 65, 68, 79, 189, 211, III. 154, 155, 205
 * -- hypophysiales II. 183
 -- profunda faciei III. 77.
 -- -- femoris III. 171
 -- -- penis II. 159, 161
 -- pudenda externa, v. pudendalis ext. III. 170
 -- -- interna, v. pudendalis int. II. 135, III. 159, 173
 -- pulmonales II. 111, 112, 115, 120, 121, 189, 191, 195, 201, 205, 208, 210, 217
 -- -- dextrae II. 112, 115, 191, 201, 208, 210, 217, III. 152
 * -- sinistrae II. III. 120, 191, 195, 201, 205, 217, III. 153
 -- renales II. 53, 122, 123, 124, 125, 129, 134, 188, III. 158, 188
 -- -- dextra II. 122, 123, 134, III. 158
 -- -- sinistra II. 53, 122, 121, 125, 134, 188
 * -- retinae III. 222
 -- retromandibularis, v. facialis post. II. 35, 36, III. 77, III. 118, 119, 120, 121, 123
 -- retroperitoneales III. 158
 -- sacralis lateralis III. 158
 -- -- mediana II. 134, III. 149, 158
 -- saphena accessoria III. 175
 -- magna I. 235, 240, 243, 295, III. 158, 170, 175, 176, 177, 178, 183
 -- parva III. 175, 177, 178, 179, 180, 183
 -- septi pellucidi III. 24
 -- spermatica, vide: vena testicularis
 -- spinalis posterior III. 87
 * -- spirales III. 260
 -- -- modioli III. 260
 -- stellatae, venulae stellatae II. 128, 129, 131
 -- subclavia II. 117, 185, 189, 213, 214, 217, III. 120, 121, 123, 126
 -- -- dextra II. 117, 185, III. 123, 149, 151, 152, 198, 202
 -- -- sinistra II. 117, 213, 214, 217, III. 148, 149, 153, 192, 197, 198, 201, 204
 * -- sublinguales III. 170, 171
 * -- sublobulares hepatis II. 69
 -- submentalis II. 35, III. 111
 * -- superficiales antebraechii III. 147
 -- -- brachii III. 116
 * -- capitis III. 111
 * -- eruris III. 178, 179
 * -- femoris III. 175
 * -- pedis III. 178, 183
 -- supraorbitalis III. 115
 -- suprarenales II. 134, 188
 -- temporalis superficialis II. 35, III. 111, 113
 -- terminalis, vide: vena thalamostriata
 -- testicularis, v. spermatica int. I. 244, II. 51, 52, 122, 134, 135, III. 158, 171, 209
 -- -- dextra II. 122, 131, 135
 -- -- sinistra II. 122, 131
 -- thalamostriata, v. terminalis III. 16, 24, 25, 41, 42, 47, 77
 -- thoracica interna, v. mammaria int. III. 123
 -- -- sinistra, v. mammaria int. sin. III. 118
 * thoracis III. 151, 152, 159
 * thymicae superiores II. 213
 -- thyroidea inferior II. 213, III. 120, 121, 122, 123
 -- -- superior III. 123
 tibialis anterior I. 304, 305
 * trabecularis lienis II. 72
 umbilicalis II. 211
 uterinae II. 170
 * vaginae nervi optici III. 221

- vena vertebralis *III.* 92, 94
 * — viscerales abdominis *III.* 157
 * — pelvis femininae *III.* 161
 * — — masculinae *III.* 160
 — vorticiosa seu vena choroidea oculi *III.* 77, 99, 100, 217, 218, 219, 221
 venter anterior musculi digastrici *I.* 220, 222, 223, 224, 229, *II.* 23, 24, 25, 27, 33, *III.* 118, 119, 120, 121, 123
 — frontalis musculi occipitofrontalis, *m. frontalis* *I.* 215, 216, 217, *III.* 107, 112
 — inferior musculi omohyoidei *I.* 222, 223, 224, 228, 263, 264, 265, *III.* 118, 119, 120, 121, 122
 — occipitalis musculi occipitofrontalis, *m. occipitalis* *I.* 216, 217, 324
 — posterior musculi digastrici *I.* 222, 223, 224, 225, 229, *II.* 23, 24, 25, 27, 28, 32, *III.* 119, 120, 121
 — superior musculi omohyoidei *I.* 222, 223, 224, 228, *II.* 24, 25, *III.* 118, 119
 ventriculus seu gaster, vide etiam: corpus, curvaturae, fundus, parietes ventriculi *I.* 249, *II.* 1, 38, 39, 40, *II.* 42, 43, 44, 47, 48, 76, 78, 80, 81, *III.* 154, 155, 187, 188, 207
 — cerebri *III.* 69, 70
 — cordis, vide etiam: ventriculus dexter, sinister *II.* 189, 191, 193, 194, 197, 202, 210, 211
 — dexter *II.* 189, 191, 193, 194, 197, 202, 210, 211
 — laryngis, *ventriculus laryngis (Morgagnii)* *II.* 26, 88, 99, 103, 104, 105
 — lateralis cerebri *III.* 15, 16, 17, 25, 40, 41, 42, 43, 45, 46, 47, 48, 109
 — quartus *III.* 5, 25, 32, 36, 37, 52, 53, 68, 70, 80, 124
 — sinister *II.* 189, 191, 195, 196, 197, 202, 203
 — tertius *II.* 181, 184, *III.* 21, 23, 36, 42, 45, 46, 47, 48, 68, 69, 80, 81
 venulae stellatae, vide: *venae stellatae*
 — temporalis retinae inferior *III.* 222
 — — superior *III.* 222
 vermis cerebelli *II.* 184, *III.* 5, 21, 27, 28, 29, 30, 31, 36, 44, 47, 48
 vertebra (-ae)
 — cervicales *I.* 74, *II.* 120
 — — (C. I.), vide: atlas
 — — (C. II.), vide: axis
 — — (C. IV.) *III.* 125
 — — (C. V.) *I.* 80, 81
 — — (C. VII.), vide: vertebra prominens
 — coccygeae *I.* 74, 93
 — lumbales *I.* 74
 — — (L. I.) *I.* 97, 98, *II.* 40, 117, 118, 119, *III.* 86, 164
 vertebra lumbalis (L. II.) *I.* 85, 86, 87
 — — (L. IV.) *I.* 120, 194
 — — (L. V.) *I.* 120, 194, 248, *II.* 40, 176, *III.* 86, 164
 — prominens (C. VII.) *I.* 158, 258, *II.* 117, 119, 120, *III.* 125
 — sacrales *I.* 91
 — thoracicae, *vertebrae thoracales* *I.* 74, *III.* 90
 — — (Th. I.) *I.* 97, 98, *II.* 118, 119
 — — (Th. VI.) *I.* 82, 83, 81
 — — (Th. X.) *II.* 40
 — — (Th. XII.) *II.* 40, 118, 119, *III.* 164
 vertex corneae *III.* 217
 — vesicae, vide: apex vesicae
 vesica fellea *II.* 1, 48, 52, 53, 63, 73, 76, 77, 78, 81, *III.* 154, 155, 207, 213, 215
 — urinaria *I.* 244, *II.* 50, 51, 52, 75, 78, 79, 80, 122, 128, 135, 137, 139, 140, 141, 142, 143, 151, 164, 165, 166, 211, *III.* 148, 157, 160, 161, 171, 188, 189, 190, 210, 215
 — — feminina *II.* 80, 139, 164, 165, 166
 — — masculina *II.* 50, 51, 52, 75, 78, 79, 122, 135, 137, 138, 141, 142, 143, 151
 vesicula seminalis *II.* 136, 137, 138, 141, 142, 143, 151, 152, 153
 vestibulum bursae omentalis *II.* 77, 81
 — labyrinthi *III.* 217, 255
 — laryngis *II.* 26, 88, 101, 105
 — nasi *II.* 26, 82, 86, 88
 — oris *II.* 1, 26, 29, 36, 83, 86, 87, 88
 — vaginae *II.* 164, 172, *III.* 161
 vestigium processus vaginalis, *rudimentum pro-cervicalis peritonaei* *II.* 148, 149
 villus intestinalis *III.* 195
 vincula tendinum *I.* 277
 vinculum lingulae cerebelli *III.* 28, 30
 vola manus, vide: palma manus
 vomer *I.* 44, 61, 73, *II.* 83, 87
 vortex coccygeus *III.* 266
 — cordis *II.* 200, 201, 203
 — pilorum *III.* 266

Z

- *zona columnaris recti *II.* 62
 — hemorrhoidalis recti, *annulus haemorrhoidalis* *II.* 62
 — orbicularis *I.* 197, 198, 199
 zonula ciliaris, *zonula ciliaris (Zinni)* *III.* 216, 219

ABBREVIATIONES — СОКРАЩЕНИЯ

a.	arteria	n. VI.	n. abducens
ant.	anterior, -ius	n. VII.	n. facialis
C.	cervicalis, -e	n. VIII.	n. vestibulocochlearis
circ.	circularis, -e	n. IX.	n. glossopharyngeus
comm.	communis, -e	n. X.	n. vagus
dext.	dexter, -ra, -rum	n. XI.	n. accessorius
dist.	distalis, -e	n. XII.	n. hypoglossus
dors.	dorsalis, -e	nucle.	nucleus
ext.	externus, -a, -um	obl.	obliquus, -a, -um
front.	frontalis, -e	post.	posterior, -ius
gl.	glandula	proc.	processus
inf.	inferior, -ius	prof.	profundus, -a, -um
int.	internus, -a, -um	prox.	proximalis, -e
L.	lumbalis, -e	r.	ramus
lat.	lateralis, -e	S.	sacralis, -e
lig.	ligamentum	sin.	sinister, -ra, -rum
lymph.	lymphaticus, -a, -um	spf.	superficialis, -e
m.	musculus	sup.	superior, -ius
med.	medialis, -e	symp.	sympathicus, -a, -um
n.	nervus	Th.	thoracicus, -a, -um
n. III.	n. oculomotorius	tr.	truncus
n. IV.	n. trochlearis	transv.	transversus, -a, -um
n. V.	n. trigeminus	v.	vena
n. V.1.	n. ophthalmicus	var.	varietas
n. V.2.	n. maxillaris	ventr.	ventralis, -e
n. V.3.	n. mandibularis		

Удвоение последней буквы в сокращениях обозначает множественное число (например, aa. arteriae dorsales, dorsales, -ia и т. д.). Склонение сокращенных выражений (родительный падеж) не обозначено.

Выражения, не относящиеся к номенклатурам, приведенные на латинском языке:

ablatus	удаленный	origo	начало
apertus	вскрытый	paramedianus	паремедиальный
aspectus	вид	partim	отчасти
color	цвет	periphericus	периферический
corrosum	коррозионный	perpendicularis	перпендикулярный
cum	с (вместе)	preparatum	препарат
etiam	также	projectio	проекция
fecit	изготовлен	ramificatio	разветвление
fig. (figura)	рисунок	retrobulbaris	ретробульбарный
fixans	фиксированный	sectio	разрез
flavus	желтый	secundum	согласно
gr. (grecus)	по-гречески	sen	или
infimus	самый нижний	situs	положение
innervatio	иннервация	sive	или
insertio	вложенный	sonda	зонд
intracranialis	внутричерепной	structura	строение
l. (lateris)	сторона	topographia	топография
neuron	нейрон	vide	смотри
orientatio	ориентация	viridis	зеленый

REGISTER FIGURARUM

SYSTEMA NERVOSUM CENTRALE — ЦЕНТРАЛЬНАЯ НЕРВНАЯ СИСТЕМА

ОЛИГИА НЕРВ СИСТЕМА

- Fig. 1. Basis cerebri (arteriae baseos cerebri et nervi craniales). Основание черепа (артерии основания черепа и черепные нервы)
- Fig. 2. Encephalon I. (aspectus lateralis dext.). Головной мозг I (боковой вид справа)
- Fig. 3. Sulci et gyri cerebri I. (facies supero-lateralis hemispherii, aspectus dext.). Борозды и извилины мозга I (верхне-боковая поверхность полушария, вид справа)
- Fig. 4. Encephalon II. (sectio sagittalis, aspectus medialis, l. dext.). Головной мозг II (сагиттальный разрез, вид с медиальной стороны, справа)
- Fig. 5. Sulci et gyri cerebri II. (facies medialis hemispherii, sectio sagittalis encephali). Борозды и извилины мозга II (медиальная поверхность полушария, сагиттальный разрез)
- Fig. 6. Encephalon III. (aspectus superior). Головной мозг III (вид сверху)
- Fig. 7. Sulci et gyri cerebri III. (facies supero-laterales hemispheriorum, aspectus superior). Борозды и извилины головного мозга III (верхне-боковая поверхность полушарий, вид сверху)
- Fig. 8. Facies inferior cerebri (aspectus inferior). Нижняя поверхность головного мозга (вид снизу)
- Fig. 9. Sulci et gyri cerebri IV. (facies inferiores hemispheriorum). Борозды и извилины головного мозга IV (нижняя поверхность полушарий)
- Fig. 10. Facies medialis et inferior hemispherii (telencephalon et diencephalon, aspectus infero-medialis hemispherii dextri). Медиальная и нижняя поверхности полушария мозга (конечный мозг и промежуточный мозг, вид на правое полушарие снизу и с медиальной стороны)
- Fig. 11. Insula (opercula frontoparietale et temporale ablata). Островок (покрывающие островок части мозга удалены)
- Fig. 12. Areae corticis cerebri I. (areae cytoarchitectonicae secundum Brodmann, facies supero-lateralis cerebri, hemispherium sin.). Поля коры головного мозга I (классификация по Бродману, верхне-боковая поверхность головного мозга, левое полушарие)
- Fig. 13. Areae corticis cerebri II. (areae cytoarchitectonicae secundum Brodmann, facies medialis et inferior cerebri, hemispherium dext.). Поля коры головного мозга II (классификация по Бродману, медиальная и нижняя поверхности мозга, правое полушарие)
- Fig. 14. Corpus callosum (sectio horizontalis cerebri, aspectus superior). Мозолистое тело (горизонтальный разрез большого мозга, вид сверху)
- Fig. 15. Ventriculi laterales I. (aspectus superior). Боковые желудочки I (вид сверху)
- Fig. 16. Ventriculi laterales II. (aspectus superior, corpus callosum ablatum). Боковые желудочки II (вид сверху, мозолистое тело удалено)
- Fig. 17. Ventriculus lateralis III. (aspectus lateralis, l. dext.). Боковой желудочек III. (вид сбоку, правая сторона)
- Fig. 18. Cornu inferius ventriculi lateralis I. (aspectus superior, l. sin.). Нижний рог бокового желудочка I (вид сверху, левая сторона)
- Fig. 19. Cornu inferius ventriculi lateralis II. (apex cornus inferioris). Нижний рог бокового желудочка II (верхушка нижнего рога)
- Fig. 20. Rhinencephalon (aspectus infero-medialis, l. dext.). Обонятельный мозг (вид снизу-медиально, правая сторона)
- Fig. 21. Diencephalon (ventriculus tertius, thalamus et hypothalamus, sectio sagittalis, l. dext.). Промежуточный мозг (третий мозговой желудочек, зрительный бугор и гипоталамус, сагиттальный разрез, правая сторона)
- Fig. 22. Centrum baseos encephali (diencephalon, hypothalamus, aspectus inferior). Средняя часть основы головного мозга (промежуточный мозг и гипоталамус, вид снизу)
- Fig. 23. Ventriculus tertius et thalamus (thalamencephalon, epithalamus, aspectus superior). Третий желудочек мозга и зрительный бугор (связанные с таламусом части головного мозга, вид сверху)
- Fig. 24. Tela choroidea ventriculi tertii (venae internae cerebri, aspectus superior). Мягкая мозговая оболочка третьего желудочка мозга (внутренние вены головного мозга, вид сверху)
- Fig. 25. Truncus cerebri I. (aspectus posterior). Ствол мозга I (вид сзади)
- Fig. 26. Truncus cerebri II. (aspectus infero-lateralis dexter). Ствол мозга II (правосторонний нижне-боковой вид)
- Fig. 27. Cerebellum I. (vermis et facies superiores hemispheriorum, aspectus superior). Мозжечок I (червячок и верхние поверхности полушарий, вид сверху)
- Fig. 28. Cerebellum II. (vermis et lobuli, aspectus superior). Мозжечок II (червячок и дольки, вид сверху)
- Fig. 29. Cerebellum III. (vermis et hemispherii, aspectus anterior). Мозжечок III (червячок и полушария, вид спереди)
- Fig. 30. Cerebellum IV. (vermis et lobuli, aspectus anterior). Мозжечок IV (червячок и дольки, вид спереди)
- Fig. 31. Cerebellum V. (aspectus dexter). Мозжечок V (вид справа)

- Fig. 32. *Cerebellum VI. (vermis, sectio mediana)*. Мозжечок VI (червячок, срединный разрез)
- Fig. 33. *Cerebellum VII. (nuclei cerebelli, sectio transversalis obliqua, aspectus superior)*. Мозжечок VII (ядра мозжечка, косой поперечный разрез, вид сверху)
- Fig. 34. *Myelencephalon (medulla oblongata, aspectus anterior)*. Задний отдел головного мозга (продолговатый мозг, вид спереди)
- Fig. 35. *Rhombencephalon I. (cerebellum, pons et medulla oblongata, aspectus antero-inferior)*. Ромбический мозг I (мозжечок, мост и продолговатый мозг, вид спереди-снизу)
- Fig. 36. *Rhombencephalon II. (mesencephalon, metencephalon et myelencephalon, sectio sagittalis mediana, aspectus dexter)*. Ромбический мозг II (средний мозг, задний мозг: мост, мозжечок и продолговатый мозг, срединный сагиттальный разрез, вид справа)
- Fig. 37. *Rhombencephalon III. (ventriculus quartus, fossa rhomboidea, aspectus posterior)*. Ромбический мозг III (четвертый желудочек мозга, ромбовидная ямка, вид сзади)
- Fig. 38. *Rhombencephalon IV. (nuclei nervorum cranialium)*. Ромбический мозг IV (ядра черепномозговых нервов)
- Fig. 39. *Sectiones cerebri (sectio sagittalis mediana, aspectus sin., l. dext. ad orientationem figurarum 40—55.)*. Разрезы головного мозга (срединный сагиттальный разрез, вид слева, правая сторона, для ориентировки на рисунках 40—55, плоскости разрезов)
- Fig. 40. *Sectio frontalis cerebri I. (aspectus anterior)*. Фронтальный разрез головного мозга I (вид спереди)
- Fig. 41. *Sectio frontalis cerebri II. (aspectus anterior)*. Фронтальный разрез головного мозга II (вид спереди)
- Fig. 42. *Sectio frontalis cerebri III. (aspectus anterior)*. Фронтальный разрез головного мозга III (вид спереди)
- Fig. 43. *Sectio frontalis cerebri IV. (aspectus anterior)*. Фронтальный разрез головного мозга IV. (вид спереди)
- Fig. 44. *Sectio frontalis cerebri V. (aspectus posterior)*. Фронтальный разрез головного мозга V (вид сзади)
- Fig. 45. *Sectio obliqua cerebri I. (sectio fronto-obliqua, aspectus posterior)*. Косой разрез головного мозга I (фронтально-косой разрез, вид сзади)
- Fig. 46. *Sectio obliqua cerebri II. (sectio fronto-obliqua, aspectus anterior)*. Косой разрез головного мозга II (фронтально-косой разрез, вид спереди)
- Fig. 47. *Sectio obliqua cerebri III. (sectiones horizonto-obliquae secundum Flechsig, aspectus superior)*. Косой разрез головного мозга III (горизонтально-косые разрезы по Флехсигу, вид сверху)
- Fig. 48. *Sectio horizontalis cerebri (aspectus superior)*. Горизонтальный разрез головного мозга (вид сверху)
- Fig. 49. *Sectio transversa mesencephali (l. sin. figurae: myeloarchitectura; l. dext. figurae: cytoarchitectura)*. Поперечный разрез среднего мозга (на левой стороне рисунка: волокнистая структура, на правой стороне: клеточная структура)
- Fig. 50. *Sectio transversa isthmi rhombencephali (myeloarchitectura)*. Поперечный разрез перешейка ромбического мозга (волокнистая структура)
- Fig. 51. *Sectio transversa pontis I. (pars superior, myeloarchitectura)*. Поперечный разрез моста I (верхняя часть, окраска миелинового влагалища)
- Fig. 52. *Sectio transversa pontis II. (pars inferior, myeloarchitectura)*. Поперечный разрез моста II (нижняя часть, окраска миелинового влагалища)
- Fig. 53. *Sectio transversa medullae oblongatae I. (pars superior, myeloarchitectura)*. Поперечный разрез продолговатого мозга I (верхняя часть, окраска миелинового влагалища)
- Fig. 54. *Sectio transversa medullae oblongatae II. (pars media, cyto- et myeloarchitecturae)*. Поперечный разрез продолговатого мозга II (средняя часть, клеточная и волокнистая структура)
- Fig. 55. *Sectio transversa medullae oblongatae III. (pars infima, cyto- et myeloarchitecturae)*. Поперечный разрез продолговатого мозга III (самая нижняя часть, клеточная и волокнистая структура)
- Fig. 56. *Tractus encephali I. (tractus nervosi commissurales, corpus callosum, preparatum fecit: S. B. Dzugaeva)*. Пути головного мозга I (коммиссуральные нервные пути, мозолистое тело. Препарировала проф. С. Б. Дзугаева, Нейроанатомическая лаборатория Научно-исследовательского института мозга АМН СССР)
- Fig. 57. *Tractus encephali II. (corpus callosum, hemisphaerium sin.)*. Пути головного мозга II (мозолистое тело, левое полушарие)
- Fig. 58. *Tractus encephali III. (corona radiata et capsula interna)*. Пути головного мозга III (лучистый венец и внутренняя капсула чечевицеобразного ядра).
- Fig. 59. *Tractus encephali IV. (corona radiata, l. dext.)*. Пути головного мозга IV (волокнистая структура правого полушария)
- Fig. 60. *Tractus encephali V. (tractus nervosi associationis)*. Пути головного мозга V (ассоциационные нервные пути)
- Fig. 61. *Tractus encephali VI. (radiatio thalami, tractus mamillothalamicus et fasciculus retroflexus, l. dext.)*. Пути головного мозга VI (лучистость зрительного бугра и прочие пути, связанные с таламусом)
- Fig. 62. *Tractus et nuclei encephali I. (nucleus caudatus et nucleus lentiformis, aspectus lateralis, l. sin.)*. Ядра и пути головного мозга I (хвостатое и чечевицеобразное ядра, вид сбоку, левая сторона)
- Fig. 63. *Tractus encephali VII. (radiatio optica)*. Пути головного мозга VII (зрительная лучистость)
- Fig. 64. *Tractus et nuclei encephali II. (aspectus infero-lateralis, l. sin.)*. Ядра и пути головного мозга II (нижне-боковой вид, левая сторона)
- Fig. 65. *Tractus encephali VIII. (radiatio optica et commissura anterior, aspectus infero-lateralis dexter)*. Пути головного мозга VIII (зрительная лучистость и передняя коммиссура, правосторонний нижне-боковой вид. Препарировала проф. С. Б. Дзугаева, Нейроанатомическая лаборатория Научно-исследовательского института мозга АМН СССР)
- Fig. 66. *Tractus et nuclei encephali III. (aspectus supero-lateralis, l. sin.)*. Пути и ядра головного мозга III (верхне-боковой вид, левая сторона. Препарировала проф. С. Б. Дзугаева, Нейроанатомическая лабора-

- тория Научно-исследовательского ин-та мозга АМН СССР)
- Fig. 67. Topographia craniocerebralis I. (secundum Krönlein). Топографическая анатомия мозгового черепа (по Крөндлейну)
- Fig. 68. Topographia craniocerebralis II. (ventriculi cerebri, aspectus lateralis). Топографическая анатомия мозгового черепа II (желудочки мозга, вид сбоку)
- Fig. 69. Topographia craniocerebralis III. (ventriculi cerebri, aspectus antero-posterior). Топографическая анатомия мозгового черепа III (желудочки мозга, вид спереди-сзади)
- Fig. 70. Topographia craniocerebralis IV. (ventriculi cerebri, aspectus postero-anterior). Топографическая анатомия мозгового черепа IV (желудочки мозга, вид сзади-спереди)
- Fig. 71. Arteriae encephali I. (arteriae laterales cerebri). Артерии головного мозга I (артерии боковой поверхности)
- Fig. 72. Arteriae encephali II. (arteriae mediales cerebri). Артерии головного мозга II (артерии медиальной поверхности)
- Fig. 73. Arteriae encephali III. (arteriae basales cerebri, circulus arteriosus). Артерии головного мозга III (артерии основания мозга и артериальное кольцо)
- Fig. 74. Sinus durae matris et venae cerebri I. (aspectus superior). Венозные синусы твердой мозговой оболочки и вены мозга I (вид сверху)
- Fig. 75. Dura mater encephali et sinus durae matris (aspectus posterior). Твердая мозговая оболочка и ее венозные синусы (вид сзади)
- Fig. 76. Sinus durae matris et venae cerebri II. (aspectus posterior). Венозные синусы твердой мозговой оболочки и вены мозга II (вид сзади)
- Fig. 77. Sinus durae matris et venae capitis. Венозные синусы твердой мозговой оболочки и вены головы
- Fig. 78. Sinus venosi durae matris basales cranii. Венозные синусы твердой мозговой оболочки на основании мозга
- Fig. 79. Sinus venosi durae matris, meninges, arteriae et venae corticales encephali (sinus sagittalis superior, sectio transversalis). Венозные синусы твердой мозговой оболочки, мозговые оболочки, артерии и вены коры мозга (верхний сагиттальный синус, поперечный разрез)
- Fig. 80. Meninges encephali et cisternae subarachnoidales (sectio sagittalis paramediana). Оболочки головного мозга и цистерны мягкой мозговой оболочки (сагиттальный разрез возле срединной линии)
- Fig. 81. Plexus choroidei (tela choroidea, lamina epithelialis et teniae, sectio frontalis cerebri). Сосудистые сплетения желудочков мозга (фронтальный разрез головного мозга)
- Fig. 82. Medulla spinalis (aspectus anterior). Спинальный мозг (вид спереди)
- Fig. 83. Medulla spinalis et nervi spinales (aspectus dexter). Спинальный мозг и спинномозговые нервы (вид справа)
- Fig. 84. Medulla spinalis in situ (aspectus sinister). Спинальный мозг in situ (вид слева)
- Fig. 85. Pars cervicalis medullae spinalis (canalis vertebralis et dura mater spinalis aperta, aspectus posterior). Шейный отрезок спинного мозга (спинномозговой канал и твердая мозговая оболочка вскрыты, вид сзади)
- Fig. 86. Pars lumbalis medullae spinalis et cauda equina (canalis vertebralis et dura mater spinalis aperta, aspectus posterior). Поясничная часть спинного мозга и конский хвост (спинномозговой канал и твердая мозговая оболочка вскрыты, вид сзади)
- Fig. 87. Cauda equina et saccus durae matris (dura mater spinalis aperta, aspectus posterior). Конский хвост и мешок твердой мозговой оболочки (твердая мозговая оболочка вскрыта, вид сзади)
- Fig. 88. Sectiones transversae medullae spinalis (segmenta medullae spinalis). Поперечные разрезы спинного мозга (сегменты спинного мозга)
- Fig. 89. Structura medullae spinalis et nervi spinales. Структура спинного мозга и спинномозговых нервов
- Fig. 90. Structura medullae spinalis et nervorum peripheralium. Структура спинного мозга и периферических нервов
- Fig. 91. Arteriae medullae spinalis. Артерии спинного мозга
- Fig. 92. Plexus venosi vertebrales I. (sectio transversa partis cervicalis columnae vertebralis). Венозные сплетения позвоночника I (поперечный разрез шейной части позвоночника)
- Fig. 93. Plexus venosi vertebrales II. (sectio transversa partis lumbalis columnae vertebralis). Венозные сплетения позвоночника II (поперечный разрез шейной части позвоночника)
- Fig. 94. Plexus venosi vertebrales et capitis (preparatum corrosum fecerunt G. Szikla et Zolnai). Венозные сплетения позвоночника и головы (коррозивный препарат сделан Г. Сикла и Б. Зольнай)

СИСТЕМА NERVOSUM PERIPHERICUM — ANGIOLOGIA

ПЕРИФЕРИЧЕСКАЯ НЕРВНАЯ СИСТЕМА — СОСУДИСТАЯ СИСТЕМА

- Fig. 95. Arteriae basales cerebri et nervi craniales (basis cerebri). Артерии основания мозга и черепномозговые нервы (основание мозга)
- Fig. 96. Nervi craniales (situs intracranialis). Черепномозговые нервы (их положение внутри черепа)
- Fig. 97. Nervi craniales et dura mater (aspectus postero-supero-lateralis, sinus cavernosus dexter apertus). Черепномозговые нервы и твердая мозговая оболочка (задне-верхне-боковой вид, правая пещеристая пазуха вскрыта)
- Fig. 98. Orbita I. (stratum superficiale, aspectus superior). Глазница I (поверхностный слой, вид сверху)
- Fig. 99. Orbita II. (stratum medium, aspectus superior). Глазница II (средний слой, вид сверху)

- Fig. 100. Orbita III. (stratum profundum, aspectus superior). Глазница III (глубокий слой, вид сверху)
- Fig. 101. Orbita IV. (aspectus lateralis). Глазница IV (вид сбоку)
- Fig. 102. Nervus trigeminus I. (ramificatio profunda). Тройничный нерв I (разветвление нерва в глубине)
- Fig. 103. Nervus trigeminus II. et nervus facialis I. (ganglia autonómica capitis, aspectus medialis, l. sin.). Тройничный нерв II и лицевой нерв I (вегетативные узлы головы, вид с медиальной стороны, левая сторона)
- Fig. 104. Nervus trigeminus III. (nervi septi nasi, aspectus sinister). Тройничный нерв III (нервы носовой перегородки, вид слева)
- Fig. 105. Nervus trigeminus IV. (nervus maxillaris, ganglion pterygopalatinum, nervi parietis lateralis cavi nasi et nervi palatini, aspectus medialis, l. sin.). Тройничный нерв IV (верхнечелюстной нерв и его узел, нервы боковой стенки носовой полости и нёба, вид с медиальной стороны, левая сторона)
- Fig. 106. Nervus facialis II. (plexus tympanicus et nervi petrosi, aspectus lateralis, l. dext.). Лицевой нерв II (тимпаническое сплетение и каменистые нервы, вид сбоку, правая сторона)
- Fig. 107. Nervus facialis III. (nervi superficiales faciei). Лицевой нерв III (поверхностные нервы лица)
- Fig. 108. Nervus vagus, nervus accessorius et pars cervicalis trunci sympathici I. (aspectus posterior). Блуждающий нерв, добавочный нерв и шейная часть симпатического ствола I (вид сзади)
- Fig. 109. Nervus vagus, nervus accessorius et pars cervicalis trunci sympathici II. (sectio frontalis capitis et cervicis). Блуждающий нерв, добавочный нерв и шейная часть симпатического ствола II (фронтальный разрез головы и шеи. Препарат II-го Московского медицинского ин-та)
- Fig. 110. Arteriae superficiales capitis. Поверхностные артерии головы
- Fig. 111. Venae superficiales capitis. Поверхностные вены головы
- Fig. 112. Nervi superficiales faciei (rami communicantes inter nervos facialem, trigeminum et cervicales). Поверхностные нервы лица (сообщения между черепномозговыми и шейными спинномозговыми нервами)
- Fig. 113. Arteriae, venae, et nervi faciei I. (stratum superficiale). Артерии, вены и нервы лица I (поверхностный слой)
- Fig. 114. Arteriae, venae et nervi faciei II. (stratum medium). Артерии, вены и нервы лица II (средний слой)
- Fig. 115. Arteriae, venae et nervi faciei III. (stratum profundum). Артерии, вены и нервы лица III (глубокий слой)
- Fig. 116. Arteriae, venae et nervi colli I. (stratum superficiale, platysma). Артерии, вены и нервы шеи I (поверхностный слой, платизма)
- Fig. 117. Arteriae, venae et nervi colli II. (stratum superficiale, lamina superficialis fasciae cervicalis). Артерии, вены и нервы шеи II (поверхностный слой, поверхностный листок шейной фасции)
- Fig. 118. Arteriae, venae et nervi colli III. (stratum medium, musculi superficiales). Артерии, вены и нервы шеи III (средний слой, поверхностные мышцы)
- Fig. 119. Arteriae, venae et nervi colli IV. (stratum medium, vena jugularis interna). Артерии, вены и нервы шеи IV (средний слой, внутренняя яремная вена)
- Fig. 120. Arteriae, venae et nervi colli V. (stratum profundum, arteriae carotides). Артерии, вены и нервы шеи V (глубокий слой, сонные артерии)
- Fig. 121. Arteriae, venae et nervi colli VI. (stratum profundum, arteria subclavia). Артерии, вены и нервы шеи VI (глубокий слой, подключичная артерия)
- Fig. 122. Arteriae, venae et nervi colli VII. (stratum profundum, plexus cervicalis et brachialis). Артерии, вены и нервы шеи VII (глубокий слой, шейное и плечевое сплетения)
- Fig. 123. Arteriae, venae et nervi colli VIII. (stratum profundum, aspectus anterior). Артерии, вены и нервы шеи VIII (глубокий слой, вид спереди)
- Fig. 124. Plexus cervicalis et brachialis (partes cervicales vertebralis et medullae spinalis, aspectus posterior). Шейное и плечевое сплетения (шейный отрезок спинномозгового канала и спинного мозга, вид сзади)
- Fig. 125. Plexus brachialis I. (structura plexus). Плечевое сплетение I (структура сплетения)
- Fig. 126. Plexus brachialis II. (topographia plexus, regiones colli lateralis et axillaris). Плечевое сплетение II (топография сплетения, боковая шейная и подмышечная области)
- Fig. 127. Nervus radialis (musculi extensores brachii et antebrachii). Лучевой нерв (иннервация разгибателей плеча и предплечья)
- Fig. 128. Nervus axillaris (musculus deltoideus). Подмышечный нерв (иннервация дельтовидной мышцы)
- Fig. 129. Nervus musculocutaneus (musculi flexores brachii). Мышечнокожный нерв (иннервация сгибателей плеча)
- Fig. 130. Nervus medianus (musculi flexores antebrachii et palmares). Срединный нерв (иннервация сгибателей предплечья и мышц ладони)
- Fig. 131. Nervus ulnaris (musculi flexores antebrachii et palmares). Локтевой нерв (иннервация сгибателей предплечья и мышц ладони)
- Fig. 132. Nervi cutanei membri superioris I. (innervatio peripherica, aspectus anterior). Кожные нервы верхней конечности I (периферическая иннервация, вид спереди)
- Fig. 133. Nervi cutanei membri superioris II. (innervatio peripherica, aspectus posterior). Кожные нервы верхней конечности II (периферическая иннервация, вид сзади)
- Fig. 134. Arteriae et nervi posteriores membri superioris I. (regiones deltoidea et scapularis, l. sin.). Тыльные артерии и нервы верхней конечности I (области плеча и лопатки, левая сторона)
- Fig. 135. Arteriae et nervi posteriores membri superioris II. (regiones brachii, cubiti et antebrachii posteriores, l. dext.). Тыльные артерии и нервы верхней конечности II (задние области плеча, локти и предплечья, правая сторона)
- Fig. 136. Arteriae et nervi anteriores brachii I. (regio brachii anterior, stratum superficiale). Передние артерии и нервы плеча I (передняя область плеча, поверхностный слой)
- Fig. 137. Arteriae et nervi anteriores brachii II. (regio brachii anterior, stratum profundum). Пе-

- редние артерии и нервы плеча II (передняя область плеча, глубокий слой)
- Fig. 138. Arteriae et nervi anteriores antebrachii I. (fossa cubitalis et regio antebrachii anterior, stratum superficiale). Передние артерии и нервы предплечья I (локтевая впадина и передняя область предплечья, поверхностный слой)
- Fig. 139. Arteriae et nervi anteriores antebrachii II. (regiones cubiti et antebrachii anteriores, stratum profundum). Передние артерии и нервы предплечья II (передние области локтя и предплечья, глубокий слой)
- Fig. 140. Arteriae et nervi palmar manus I. (stratum superficiale). Артерии и нервы ладони I (поверхностный слой)
- Fig. 141. Arteriae et nervi palmar manus II. (stratum profundum). Артерии и нервы ладони II (глубокий слой)
- Fig. 142. Arteriae, venae et nervi dorsi manus I. (aspectus dorsalis). Артерии, вены и нервы тыла кисти I (вид сзади)
- Fig. 143. Arteriae, venae et nervi dorsi manus II. (aspectus radialis). Артерии, вены и нервы тыла кисти II (вид с лучевой стороны)
- Fig. 144. Arteriae manus (arcus palmares). Артерии кисти (ладонные дуги)
- Fig. 145. Venae manus (rete venosum palmare). Вены кисти (венозная сеть ладони)
- Fig. 146. Venae superficiales et nervi cutanei brachii. Поверхностные вены и кожные нервы плеча
- Fig. 147. Venae superficiales et nervi cutanei antebrachii. Поверхностные вены и кожные нервы предплечья
- Fig. 148. Arteriae et nervi parietis anterioris trunci (arteriae thoracica interna et epigastricae, aspectus posterior). Артерии и нервы передней стенки ствола (внутренняя грудная и надчревная артерии, вид сзади)
- Fig. 149. Venae parietis posterioris trunci (vena azygos). Вены задней стенки ствола (парная вена)
- Fig. 150. Arteriae, venae et nervi intercostales (structura parietis thoracis). Межреберные артерии, вены и нервы (структура стенки грудной клетки)
- Fig. 151. Arteriae, venae et nervi thoracis I. (mediastinum anterius). Артерии, вены и нервы грудной клетки I (переднее средостение)
- Fig. 152. Arteriae, venae et nervi thoracis II. (cavum pleurae dextrum et mediastinum). Артерии, вены и нервы грудной клетки II (правосторонняя грудная полость и средостение)
- Fig. 153. Arteriae, venae et nervi thoracis III. (cavum pleurae sinistrum et mediastinum). Артерии, вены и нервы грудной стенки III (левосторонняя грудная полость и средостение)
- Fig. 154. Arteriae et venae viscerales abdominis I. (truncus coeliacus). Висцеральные артерии и вены брюшной полости I (чревный ствол)
- Fig. 155. Arteriae et venae viscerales abdominis II. (truncus coeliacus, arteria mesenterica superior, venae portae et mesenterica superior). Висцеральные артерии и вены брюшной полости II (чревный ствол, верхняя брыжеечная артерия, воротная вена и верхняя брыжеечная вена)
- Fig. 156. Arteriae et venae viscerales abdominis III. (arteria et vena mesentericae superiores). Висцеральные артерии и вены брюшной полости III (верхние брыжеечные артерия и вена)
- Fig. 157. Arteriae et venae viscerales abdominis IV. (vasa intestini crassi). Висцеральные арте-
- рии и вены брюшной полости IV (сосуды толстой кишки)
- Fig. 158. Arteriae, venae et nervi retroperitoneales (spatium retroperitoneale, nervi lumbales). Забрюшинные артерии, вены и нервы (забрюшинное пространство, поясничные нервы)
- Fig. 159. Arteriae, venae et nervi parietales pelvis (sectio sagittalis mediana). Артерии, вены и нервы стенки таза (срединный сагиттальный разрез)
- Fig. 160. Arteriae, venae et nervi viscerales pelvis masculinae (sectio sagittalis paramediana sin.). Висцеральные артерии, вены и нервы мужского таза (левосторонний околосрединный сагиттальный разрез)
- Fig. 161. Arteriae, venae et nervi viscerales pelvis femininae (sectio sagittalis paramediana sin.). Висцеральные артерии, вены и нервы женского таза (левосторонний околосрединный сагиттальный разрез)
- Fig. 162. Arteriae et nervi regionis perinealis (regio perinealis masculina). Артерии и нервы области промежности (область мужской промежности)
- Fig. 163. Rami dorsales nervorum spinalium. Задние ветви спинномозговых нервов
- Fig. 164. Plexus lumbosacralis (structura plexus, cum partibus abdominali et pelvina systematis autonomici). Поясничнокрестцовое сплетение (структура сплетения с брюшной и тазовой частями вегетативной нервной системы)
- Fig. 165. Nervus obturatorius (musculi adductores femoris). Запирательный нерв (иннервация приводящих мышц бедра)
- Fig. 166. Nervus femoralis et nervi peronei (musculi extensores femoris et cruris). Бедренный нерв и нервы таза (иннервация разгибателей бедра и голени)
- Fig. 167. Nervus ischiadicus et nervus tibialis (musculi flexores femoris et cruris, musculi plantares). Седалищный нерв и большеберцовый нерв (иннервация сгибателей бедра и голени и мышцы подошвы)
- Fig. 168. Nervi cutanei membri inferioris I. (innervatio peripherica, aspectus posterior). Кожные нервы нижней конечности I (периферическая иннервация, вид сзади)
- Fig. 169. Nervi cutanei membri inferioris II. (innervatio peripherica, aspectus anterior). Кожные нервы нижней конечности II (периферическая иннервация, вид спереди)
- Fig. 170. Arteriae, venae et nervi subinguinales et femoris anteriores I. (trigonum femorale, regiones subinguinales et femoris anterior, stratum superficiale). Артерии, вены и нервы подпаховой области и передней области бедра I (бедренный треугольник, подпаховая и передняя бедренная области, поверхностный слой)
- Fig. 171. Arteriae, venae et nervi subinguinales et femoris anteriores II. (trigonum femorale, regiones subinguinalis et femoris anterior, stratum profundum). Артерии, вены и нервы подпаховой области и передней области бедра II (бедренный треугольник, подпаховая область и передняя бедренная область, глубокий слой)
- Fig. 172. Nervi regionis gluteae (musculi glutei). Нервы ягодичной области (иннервация ягодичных мышц)
- Fig. 173. Arteriae, venae et nervi femoris posteriores I. (regiones gluteae et femoris posterior). Задние артерии, вены и нервы бедра I (ягодичная область и задняя бедренная область)

- Fig. 174. Arteriae, venae et nervi femoris posteriores II. (regiones femoris et genus posteriores et fossa poplitea). Задние артерии, вены и нервы бедра II (задние области бедра и колена и подколенная ямка)
- Fig. 175. Venae superficiales et nervi cutanei femoris. Поверхностные вены и кожные нервы бедра
- Fig. 176. Arteriae, venae et nervi cruris anteriores (regiones genus et cruris anteriores). Передние артерии, вены и нервы голени (передние области колена и голени)
- Fig. 177. Arteriae, venae et nervi cruris posteriores (fossa poplitea et regiones genus et cruris posteriores). Задние артерии, вены и нервы голени (подколенная ямка, задние области колена и голени)
- Fig. 178. Venae superficiales et nervi cutanei cruris et pedis I. Поверхностные вены и кожные нервы голени и стопы I
- Fig. 179. Venae superficiales et nervi cutanei cruris II. Поверхностные вены и кожные нервы голени II.
- Fig. 180. Arteriae, venae et nervi dorsii pedis. Артерии, вены и нервы тыла стопы
- Fig. 181. Arteriae, venae et nervi plantae pedis. Артерии, вены и нервы подошвы
- Fig. 182. Arteriae pedis (aspectus dorsalis). Артерии стопы (вид сзади)
- Fig. 183. Venae superficiales et nervi cutanei pedis II. Поверхностные вены и кожные нервы стопы II
- Fig. 184. Innervatio segmentalis cutis. Сегментарная иннервация кожи
- Fig. 185. Innervatio peripherica cutis (arcus nervorum cutaneorum capitis, colli et trunci). Периферическая иннервация кожи (кожные нервы головы, шеи и туловища)

SYSTEMA NERVOSUM AUTONOMICUM

ВЕГЕТАТИВНАЯ НЕРВНАЯ СИСТЕМА

- Fig. 186. Pars cephalica et pars cervicalis systematis nervosi autonomici. Головная и шейная части вегетативной нервной системы
- Fig. 187. Pars thoracica systematis nervosi autonomici I. (aspectus lateralis dexter). Грудная часть вегетативной нервной системы I (вид сбоку и справа)
- Fig. 188. Pars abdominalis systematis nervosi autonomici. Брюшная часть вегетативной нервной системы
- Fig. 189. Pars pelvina systematis autonomici I. (plexus hypogastricus inferior seu pelvinus, sectio sagittalis paramediana pelvis masculinae). Тазовая часть вегетативной нервной системы I (нижнее подчревное или тазовое сплетение, околосоитальный сакральный разрез мужского таза)
- Fig. 190. Pars pelvina systematis nervosi autonomici II. (sectio sagittalis paramediana pelvis femininae). Тазовая часть вегетативной нервной системы II (околосоитальный сакральный разрез женского таза)
- Fig. 191. Ganglia celiaca (plexus coeliacus, aorticus abdominalis, renalis et suprarenalis). Чревный узел (чревной, брюшно-аортальный, почечный и надпочечный сплетения)

SYSTEMA LYMPHATICUM — ЛИМФАТИЧЕСКАЯ СИСТЕМА

- Fig. 192. Systema lymphaticum (trunci lymphatici). Лимфатическая система (лимфатические стволы)
- Fig. 193. Structura systematis lymphatici I. (intestinum tenue, preparatum injectum, sectio transversa, fecit A. V. Borisov). Структура лимфатической системы I (тонкая кишка, поперечный разрез, инъецированный препарат А. В. Борисова)
- Fig. 194. Structura systematis lymphatici II. (hepar, preparatum injectum, aspectus e superficie, fecit M. A. Dolgova). Структура лимфатической системы II (печень, вид с поверхностной стороны, инъецированный препарат М. А. Долговой)
- Fig. 195. Structura systematis lymphatici III. (intestinum tenue, angiarchitectura, sectio longitudinalis, secundum A. V. Borisov). Структура лимфатической системы III (тонкая кишка, ангиоархитектура, продольный разрез, по А. В. Борисову)
- Fig. 196. Vasa lymphatica et nodi lymphatici capitis cervicis et thoracis superficiales. Поверхностные лимфатические сосуды и узлы головы, шеи и грудной клетки
- Fig. 197. Vasa lymphatica et nodi lymphatici cervicis. Лимфатические сосуды и узлы шеи
- Fig. 198. Vasa lymphatica et nodi lymphatici faciei et cervicales profundi. Глубокие лимфатические сосуды и узлы лица и шеи
- Fig. 199. Vasa lymphatica et nodi lymphatici regionum mammalis, axillaris, infraclavicularis et colli lateralis. Лимфатические сосуды и узлы области грудной железы, подмышечной, подключичной и боковой шейной областей
- Fig. 200. Vasa lymphatica et nodi lymphatici membri superioris. Лимфатические сосуды и узлы верхней конечности
- Fig. 201. Vasa lymphatica et nodi lymphatici mediastinales I. Лимфатические сосуды и узлы средостения I
- Fig. 202. Vasa lymphatica et nodi lymphatici mediastinales II. Лимфатические сосуды и узлы средостения II
- Fig. 203. Vasa lymphatica et nodi lymphatici mediastinales III. (fecerunt Mascagni et Fontana, anno 1788.). Лимфатические сосуды и узлы средостения III (на основании препарата Маскани и Фонтана, 1788 г.)
- Fig. 204. Vasa lymphatica et nodi lymphatici mediastinales IV. (fecerunt Mascagni et Fontana, anno 1788.). Лимфатические сосуды и узлы средостения IV (на основа-

- нии препарата Масканы и Фонтана, 1788 г.)
- Fig. 205. *Vasa lymphatica et nodi lymphatici retroperitoneales I.* (fecerunt Mascagni et Fontana, anno 1788.). Забрюшинные лимфатические сосуды и узлы I (на основании препарата Масканы и Фонтана, 1788 г.)
- Fig. 206. *Vasa lymphatica et nodi lymphatici retroperitoneales II.* Забрюшинные лимфатические сосуды и узлы II
- Fig. 207. *Vasa lymphatica et nodi lymphatici ventriculi, hepatis et duodeni.* Лимфатические сосуды и узлы желудка, печени и двенадцатиперстной кишки
- Fig. 208. *Vasa lymphatica et nodi lymphatici mesenterici.* Лимфатические сосуды и узлы брыжейки
- Fig. 209. *Vasa lymphatica et nodi lymphatici organorum genitalium masculinorum.* Лимфатические сосуды и узлы мужских половых органов
- Fig. 210. *Vasa lymphatica et nodi lymphatici organorum genitalium femininorum.* Лимфатические сосуды и узлы женских половых органов
- Fig. 211. *Vasa lymphatica et nodi lymphatici membri inferioris I. (aspectus anterior).* Лимфатические сосуды и узлы нижней конечности I (вид спереди)
- Fig. 212. *Vasa lymphatica et nodi lymphatici membri inferioris II. (aspectus posterior).* Лимфатические сосуды и узлы нижней конечности II (вид сзади)
- Fig. 213. *Nodi lymphatici et plexus autonomicus celiaci.* Лимфатические узлы и вегетативное сплетение брюшной полости
- Fig. 214. *Nodi lymphatici et plexus autonomici mesenterici.* Лимфатические узлы и вегетативные сплетения брыжейки
- Fig. 215. *Nodi lymphatici et plexus autonomici retroperitoneales.* Забрюшинные лимфатические узлы и вегетативные сплетения

ORGANA SENSUUM — ОРГАНЫ ЧУВСТВ

- Fig. 216. *Organum visus, oculus (sectio horizontalis bulbi oculi).* Орган зрения. Глаз (горизонтальный разрез глазного яблока)
- Fig. 217. *Bulbus oculi I. (tunica fibrosa bulbi).* Глазное яблоко I (фиброзная оболочка глазного яблока)
- Fig. 218. *Bulbus oculi II. (tunica vasculosa bulbi).* Глазное яблоко II (сосудистая оболочка глазного яблока)
- Fig. 219. *Bulbus oculi III. (structura bulbi).* Глазное яблоко III (структура глазного яблока)
- Fig. 220. *Corpus ciliare et iris (structura partis anterioris bulbi).* Ресничное тело и радужная оболочка (структура передней части глазного яблока)
- Fig. 221. *Arteriae et venae bulbi oculi (secundum F. Kiss et T. Orbán, sectio horizontalis).* Артерии и вены глазного яблока (по Ф. Кишшу и Т. Орбану, горизонтальный разрез)
- Fig. 222. *Arteriae et venae retinae (fundus oculi, discus nervi optici et macula).* Артерии и вены сетчатой оболочки (глазное дно, сосок зрительного нерва и желтое пятно)
- Fig. 223. *Plexus vasculosus episcleralis (aspectus anterior partis anterioris bulbi).* Эписклеральное сосудистое сплетение (вид спереди на переднюю часть глазного яблока)
- Fig. 224. *Corpus ciliare (aspectus posterior partis anterioris bulbi).* Ресничное тело (вид сзади на переднюю часть глазного яблока)
- Fig. 225. *Corpus vitreum.* Стекловидное тело
- Fig. 226. *Lens I. (aspectus lateralis).* Хрусталик I (вид сбоку)
- Fig. 227. *Lens II. (aspectus postero-lateralis).* Хрусталик II (вид сзади-сбоку)
- Fig. 228. *Retina (structura partis opticae retinae).* Сетчатая оболочка (структура зрительной части сетчатой оболочки)
- Fig. 229. *Organa oculi accessoria (sectio frontalis retrobulbaris orbitae).* Добовочные органы глаза (фронтальный разрез глазницы позади глазного яблока)
- Fig. 230. *Actio musculorum bulbi (bulbus dexter, aspectus anterior).* Действие глазодвигательных мышц (правое глазное яблоко, вид спереди)
- Fig. 231. *Musculi bulbi I. (aspectus superior).* Мышцы глаза I (вид сверху)
- Fig. 232. *Musculi bulbi II. (aspectus superior, I. dext.).* Мышцы глаза II (вид сверху, правая сторона)
- Fig. 233. *Musculi bulbi III. (aspectus anterior, I. dext.).* Мышцы глаза III (вид спереди, правая сторона)
- Fig. 234. *Musculi bulbi IV. (aspectus lateralis, I. dext.).* Мышцы глаза IV (вид сбоку, правая сторона)
- Fig. 235. *Palpebrae I. (palpebrae et supercilium, I. dext.).* Веки I (веки и брови, правая сторона)
- Fig. 236. *Palpebrae II. (structura palpebrarum, I. sin.).* Веки II (структура век, левая сторона)
- Fig. 237. *Apparatus lacrimalis I. (facies posterior palpebrarum et glandula lacrimalis, I. dext.).* Слезный аппарат I (задняя поверхность век и слезная железа, правая сторона)
- Fig. 238. *Apparatus lacrimalis II. (saccus lacrimalis, I. sin.).* Слезный аппарат II (слезный мешок, левая сторона)
- Fig. 239. *Topographia orbitae (vaginae bulbi, sectio horizontalis).* Топография глазницы (оболочки глаза, горизонтальный разрез)
- Fig. 240. *Auricula I. (musculi auriculae, aspectus lateralis).* Ушная раковина I (мышцы ушной раковины, вид сбоку)
- Fig. 241. *Auricula II. (musculi auriculae, aspectus medialis).* Ушная раковина II (мышцы ушной раковины, вид с медиальной стороны)
- Fig. 242. *Auricula III. (aspectus lateralis).* Ушная раковина III (вид сбоку)
- Fig. 243. *Auricula IV. (cartilago auriculae et meatus acustici externi, aspectus anterior, I. sin.).* Ушная раковина IV (хрящ ушной раковины и наружного слухового прохода, вид спереди, левая сторона)
- Fig. 244. *Auricula V. (cartilago auriculae, aspectus lateralis, I. sin.).* Ушная раковина V (хрящ ушной раковины, вид сбоку, левая сторона)
- Fig. 245. *Auricula VI. (cartilago auriculae, aspectus medialis, I. sin.).* Ушная раковина VI (хрящ ушной раковины, вид с медиальной стороны, левая сторона)

- Fig. 246. Organum vestibulocochleare I. (sectio frontalis, 1. dext.). Вестибулярно-кохлеарный орган I (фронтальный разрез, правая сторона)
- Fig. 247. Organum vestibulocochleare II. (situs partium organi projectus, aspectus superior). Вестибулярно-кохлеарный орган II (проекция частей органа, вид сверху)
- Fig. 248. Membrana tympani I. (aspectus lateralis, 1. dext.). Барабанная перепонка I (вид сбоку, правая сторона)
- Fig. 249. Membrana tympani II. (aspectus lateralis, in situ). Барабанная перепонка II (вид сбоку, in situ)
- Fig. 250. Ossicula auditus (auris mediae dextrae). Слуховые косточки (правой барабанной полости)
- Fig. 251. Cavum tympani I. (paries membranaceus, 1. dext.). Барабанная полость I (перепончатая стенка, правая сторона)
- Fig. 252. Cavum tympani II. (paries labyrinthicus, 1. dext.). Барабанная полость II (стенка лабиринта, правая сторона)
- Fig. 253. Cavum tympani III. (ossicula auditus in situ, articulationes et ligamenta ossiculorum, aspectus medialis, 1. sin.). Барабанная полость III (слуховые косточки in situ, их суставы и связки, вид с медиальной стороны, левая сторона)
- Fig. 254. Auris interna (sectio obliqua, aspectus supero-lateralis, 1. sin.). Внутреннее ухо (косой разрез, вид сверху-сбоку, левая сторона)
- Fig. 255. Labyrinthus osseus I. (preparatum corrosum, aspectus lateralis, 1. sin.). Костный лабиринт I (коррозионный препарат, вид сбоку, левая сторона)
- Fig. 256. Labyrinthus osseus II. (preparatum corrosum, aspectus superior, 1. sin.). Костный лабиринт II (коррозионный препарат, вид сверху, левая сторона)
- Fig. 257. Cochlea (sectio longitudinalis). Улитка (продольный разрез)
- Fig. 258. Fundus meatus acustici interni (aspectus medialis, 1. dext.). Дно внутреннего слухового хода (вид с медиальной стороны, правая сторона)
- Fig. 259. Labyrinthus membranaceus I. (aspectus lateralis, 1. dext.). Перепончатый лабиринт I (вид сбоку, правая сторона)
- Fig. 260. Labyrinthus membranaceus II. (arteriae, venae et nervi auris internaе, aspectus medialis, 1. dext.). Перепончатый лабиринт II (артерии, вены и нервы внутреннего уха, вид с медиальной стороны, правая сторона)
- Fig. 261. Ductus cochlearis (organum spirale Corti, structura organi, sectio transversa). Перепончатая часть улитки (Кортиев орган, структура органа, поперечный разрез)
- Fig. 262. Crista ampullaris et macula utriculi (structura labyrinthi membranacei). Ампулярный гребень и пятно мешочка (структура перепончатого лабиринта)
- Fig. 263. Tuba auditiva (cartilago tubae auditivae). Слуховая труба (хрящ слуховой трубы)

INTEGUMENTUM COMMUNE — НАРУЖНЫЙ ПОКРОВ

- Fig. 264. Unguis. Ноготь.
- Fig. 265. Sulci cutis. Борозды кожи
- Fig. 266. Flumina pilorum. Расположение волосатости
- Fig. 267. Cutis (structura cutis). Кожа (структура кожи)
- Fig. 268. Pilum (structura radice pilii). Волосок (структура корня волоска)

СОДЕРЖАНИЕ

SYSTEMA NERVOSUM CENTRALE — ЦЕНТРАЛЬНАЯ НЕРВНАЯ СИСТЕМА	5
SYSTEMA NERVOSUM PERIPHERICUM . ANGIOLOGIA — ПЕРИФЕРИЧЕСКАЯ НЕРВНАЯ СИСТЕМА . СОСУДИСТАЯ СИСТЕМА	79
SYSTEMA NERVOSUM AUTONOMICUM — ВЕГЕТАТИВНАЯ НЕРВНАЯ СИСТЕМА	173
SYSTEMA LYMPHATICUM — ЛИМФАТИЧЕСКАЯ СИСТЕМА	181
ORGANA SENSUUM — ОРГАНЫ ЧУВСТВ	205
INTEGUMENTUM COMMUNE — НАРУЖНЫЙ ПОКРОВ	239
INDEX — УКАЗАТЕЛЬ	247
ABBREVIATIONES — СОКРАЩЕНИЯ	297
REGISTER FIGURARUM — СПИСОК РИСУНКОВ	299

Ответственный издатель
ДЬЕРДЬ БЕРНАТ
директор Издательства и Типографии
Академии Наук Венгрии

Редактор издательства
К. ЭРДИ

Технический редактор
И. ЧЕРГЕ

Заказ: 61106. Типография Академии Наук Венгрии
Будапешт

