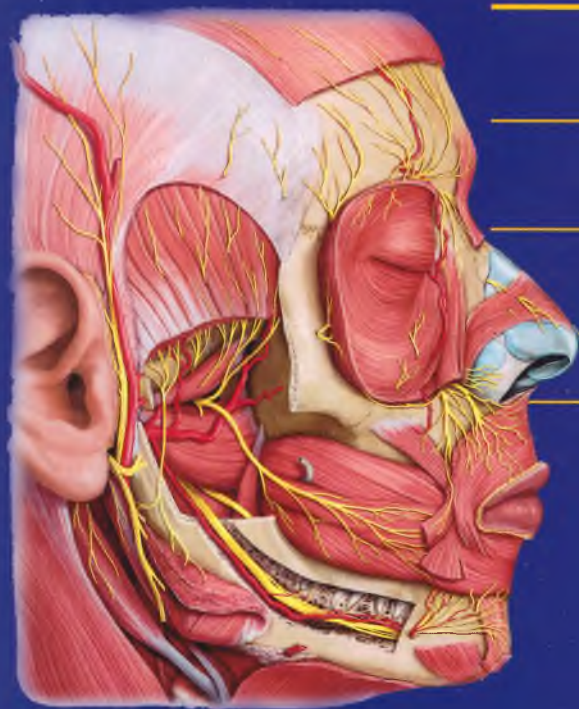


# АТЛАС

Г.Л. БИЛИЧ  
В.А. КРЫЖАНОВСКИЙ

# АНАТОМИЯ ЧЕЛОВЕКА



---

Центральная  
нервная система

---

Периферическая  
нервная система

---

Вегетативная  
нервная система

---

Органы чувств

---

Том 3



ИЗДАТЕЛЬСКАЯ ГРУППА  
«ГЭОТАР-Медиа»

**Г.Л. БИЛИЧ, В.А. КРЫЖАНОВСКИЙ**

# **АТЛАС**

# **АНАТОМИЯ**

# **ЧЕЛОВЕКА**

**В ТРЕХ ТОМАХ**

Министерство образования и науки РФ

Рекомендовано ГОУ ВПО «Московская медицинская академия им. И.М. Сеченова» в качестве учебного пособия для студентов учреждений высшего профессионального образования, обучающихся по специальностям 060101.65 «Лечебное дело», 060103.65 «Педиатрия», 060104.65 «Медико-профилактическое дело», 060105.65 «Стоматология» по дисциплине «Анатомия человека»

Регистрационный номер рецензии 516 от 6 июля 2009 г.  
ФГУ «Федеральный институт развития образования»



**Москва**  
ИЗДАТЕЛЬСКАЯ ГРУППА  
**«ГЭОТАР-Медиа»**  
**2013**

**Г.Л. БИЛИЧ, В.А. КРЫЖАНОВСКИЙ**

**АТЛАС**  
**АНАТОМИЯ**  
**ЧЕЛОВЕКА**

**В ТРЕХ ТОМАХ**

**ТОМ 3**



**Москва**  
**ИЗДАТЕЛЬСКАЯ ГРУППА**  
**«ГЭОТАР-Медиа»**  
**2013**

## ПРЕДИСЛОВИЕ ОТ АВТОРОВ

Анатомия человека – одна из основных фундаментальных дисциплин в системе медицинского образования. Анатомия – часть биологии, а именно морфологии, изучающей форму и строение организмов. В то же время современная анатомия является функциональной: она рассматривает структуры в тесной связи с выполняемой ими функцией. Подготовка врачей начинается с изучения строения человеческого тела на всех его иерархических уровнях. Анатомия человека состоит из макроскопической, микроскопической, ультрамикроскопической анатомии, рентгеноанатомии. Однако макроанатомия превалирует.

Будучи наукой описательной, анатомия базируется на изучении натуральных (трупных) препаратов. И это главное! Однако для эффективного обучения недостаточно одних лишь препаратов. Наряду с учебниками необходимы атласы, которые содержат четкие и понятные информативные схемы, рисунки, созданные на основе настоящих трупных препаратов. Только такие иллюстрации помогают проникнуть в тайную мудрость и познать уникальное строение человеческого тела, его аппаратов, систем и органов.

В России, как и во всем мире, в качестве главной используется латинская анатомическая терминология, в каждой стране наряду с ней – эквиваленты латинских терминов на национальном языке. Как правило, студент испытывает серьезные трудности при одновременном заучивании терминов на двух языках – латинском и русском. Вместо громоздких подрисовочных подписей каждая структура обозначена непосредственно на самом рисунке. Впервые латинские термины в атласе полностью соответствуют последней Международной анатомической номенклатуре, утвержденной на XV Международном анатомическом конгрессе в Риме в 1990 г. Русская терминология утверждена в качестве официальной IV Всероссийским съездом анатомов, гистологов и эмбриологов (Ижевск, 1999). Сегодня в мире широко распространен английский язык. В вузах России обучается множество иностранных студентов, поэтому под каждым рисунком приведены и английские термины.

Атлас построен по принципам систематической функциональной анатомии, это определило его структуру. Издание состоит из трех томов. Первый том посвящен опорно-двигательному аппарату (системы костей и их соединений, мышечная система). Во втором представлены внутренние органы: пищеварительная, дыхательная, мочевая, половая (мужская и женская), сердечно-сосудистая, лимфоидная и лимфатическая системы, полости живота и таза, эндокринные железы. Третий том знакомит читателя с нервной системой и органами чувств.

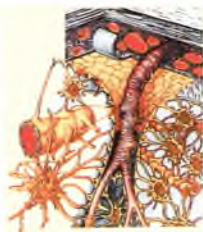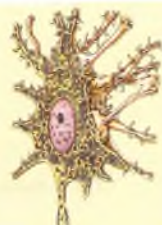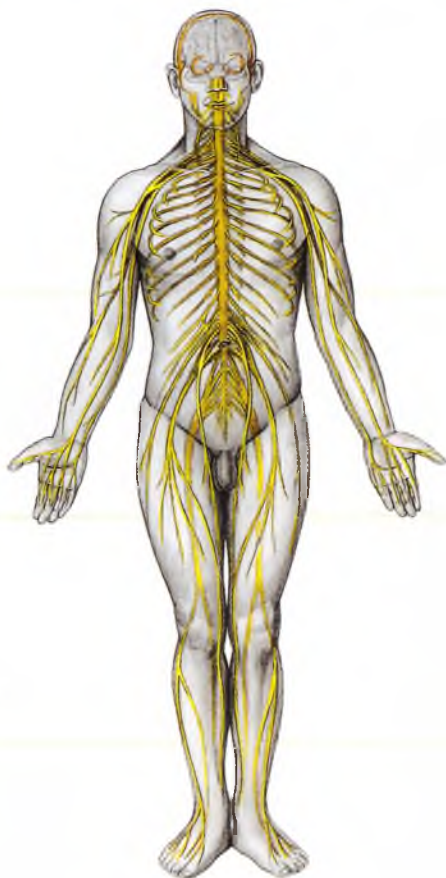
Атлас предназначен для преподавателей и студентов всех медицинских специальностей, врачей, аспирантов, научных работников.

Авторский коллектив старался создать полный атлас анатомии человека, который востребован в XXI веке. Насколько это удалось, предоставляем судить читателю. Авторы с благодарностью примут все замечания и пожелания коллег.

Авторы считают своим приятным долгом сердечно поблагодарить акад. РАМН, проф. Л.Л. Колесникова, акад. РАМН, проф. С.К. Тернового, чл.-кор. РАМН, проф. А.Ю. Васильева, проф. Б.И. Нигматулина, К.И. Сайткулова, А.В. Сокола, П.И. Куренкова, Kenneth P. Moses, John C. Banks, Pedro V. Nava, Darrell Petersen, Walter Thiel, Alessandro Riva, Roberta Ballestriero, Luigi Cattaneo, Bruno Zanolio, доц. С.С. Виноградову, проф. Л.М. Литвиненко, Е.А. Егорову, А.Б. Абдураимова, И.С. Федотенкову, С.П. Паша, Л.С. Кокова, В.Е. Синицына, Д.В. Устюжанина, И.А. Крыжановского, Д.В. Туманову, С.А. Нерубайло, Д.А. Потемкина, П.К. Конторщикова, В.И. Рамееву.

Авторы всегда будут с благодарностью помнить художника В.В. Ирикова, который внес неоценимый вклад в создание оригинальных рисунков.

# НЕРВНАЯ СИСТЕМА



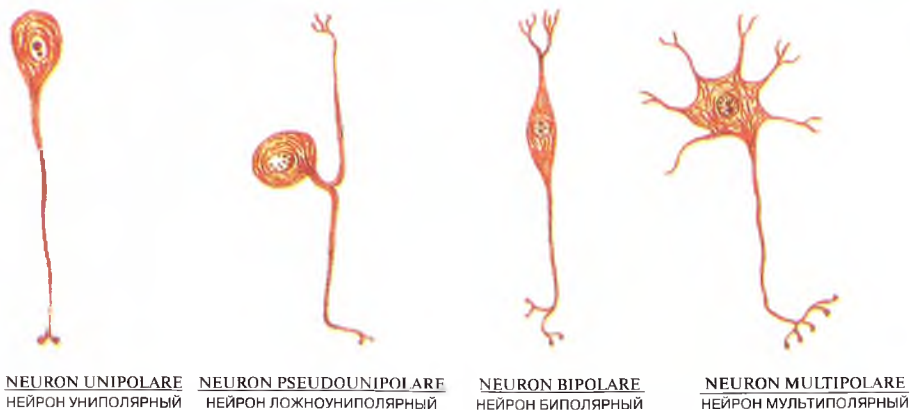


Рис. 4. Типы нейронов (нервных клеток)

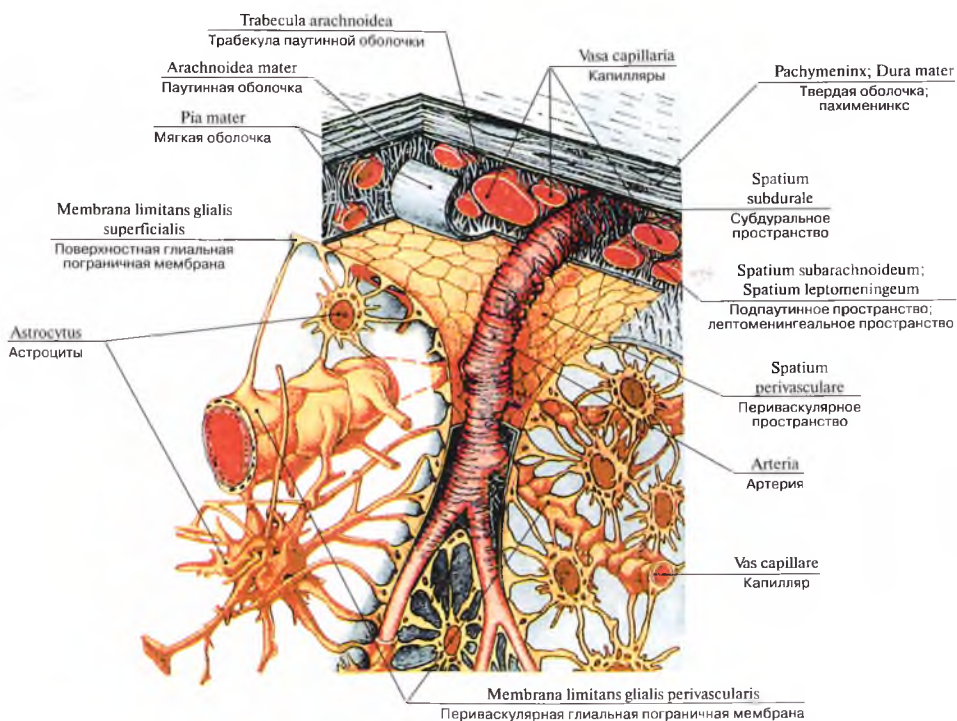
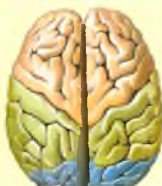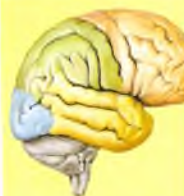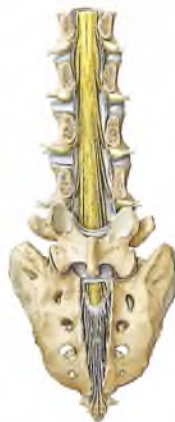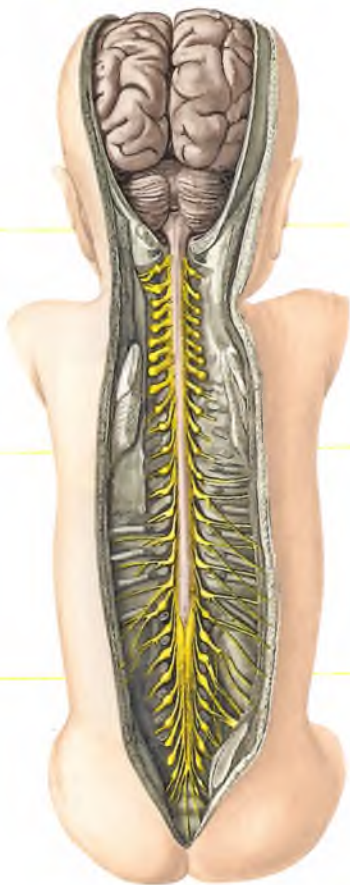


Рис. 5. Оболочки мозга и гемато-энцефалический барьер (схема)

# ЦЕНТРАЛЬНАЯ НЕРВНАЯ СИСТЕМА



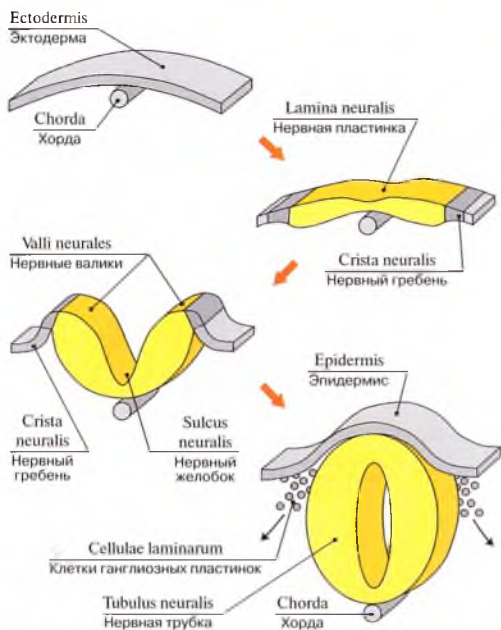


Рис. 9. Ранние стадии формирования нервной системы

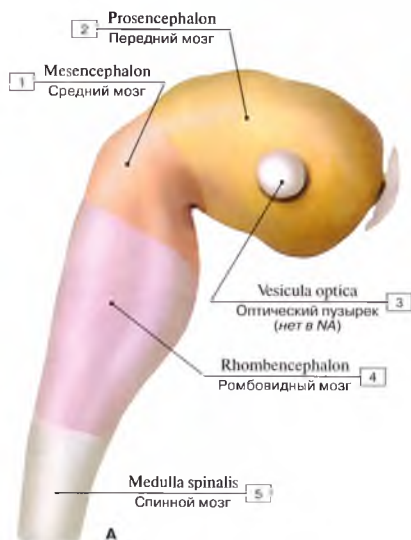
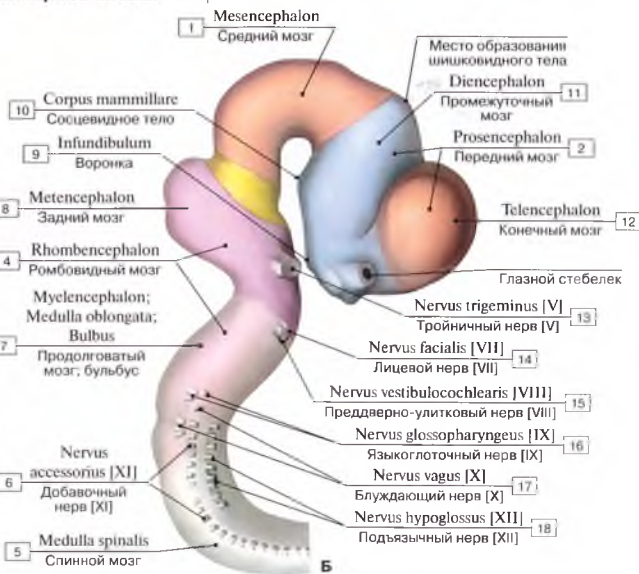


Рис. 10. Головной мозг эмбриона, вид справа (реконструкция) (А – стадия трех мозговых пузырей; Б – эмбрион длиной 10,2 мм, стадия пяти мозговых пузырей):

1 – Mesencephalon; Midbrain; 2 – Prosencephalon; Forebrain; 3 – Optic vesicle; 4 – Rhombencephalon; Hindbrain; 5 – Spinal cord; 6 – Accessory nerve [XI]; 7 – Myelencephalon; Medulla oblongata; Bulb; 8 – Metencephalon; 9 – Infundibulum; 10 – Mammillary body; 11 – Diencephalon; 12 – Telencephalon; 13 – Trigeminal nerve [V]; 14 – Facial nerve [VII]; 15 – Vestibulocochlear nerve [VIII]; 16 – Glossopharyngeal nerve [IX]; 17 – Vagus nerve [X]; 18 – Hypoglossal nerve [XII]





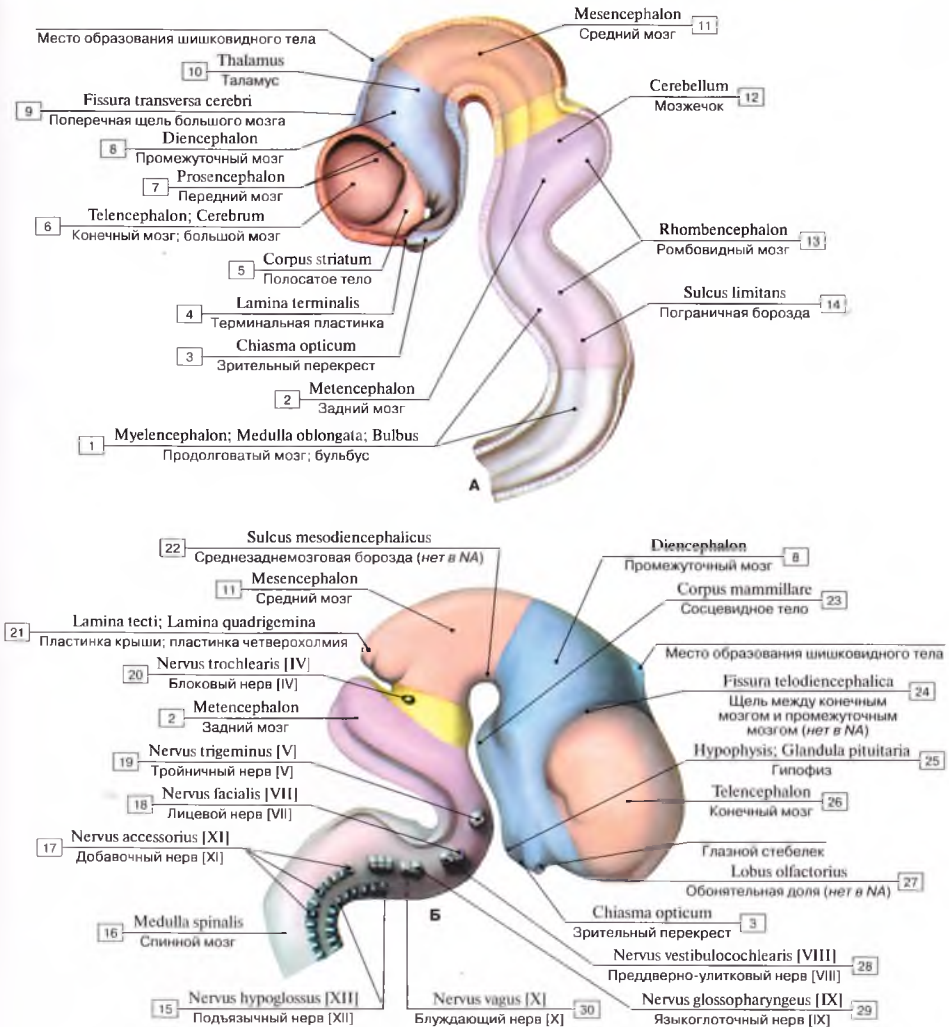


Рис. 11. Головной мозг эмбриона (реконструкция)

(А – эмбрион длиной 10,2 мм, правая половина, вид изнутри; Б – эмбрион длиной 13,6 мм, вид справа):

- 1 – Myelencephalon; Medulla oblongata; Bulb; 2 – Metencephalon; 3 – Optic chiasm; Optic chiasma; 4 – Lamina terminalis; 5 – Corpus striatum; 6 – Telencephalon; Cerebrum; 7 – Prosencephalon; Forebrain; 8 – Dienecephalon; 9 – Transverse cerebral fissure; 10 – Thalamus; Dorsal thalamus; 11 – Mesencephalon; Midbrain; 12 – Cerebellum; 13 – Rhombencephalon; Hindbrain; 14 – Sulcus limitans; 15 – Hypoglossal nerve [XII]; 16 – Spinal cord; 17 – Accessory nerve [XI]; 18 – Facial nerve [VII]; 19 – Trigeminal nerve [V]; 20 – Trochlear nerve [IV]; 21 – Tectal plate; Quadrigeminal plate; 22 – Mesodiencephalic groove; 23 – Mammillary body; 24 – Telodiencephalic fissure; 25 – Pituitary gland; 26 – Telencephalon; 27 – Olfactory lobe; 28 – Vestibulocochlear nerve [VIII]; 29 – Glossopharyngeal nerve [IX]; 30 – Vagus nerve [X]

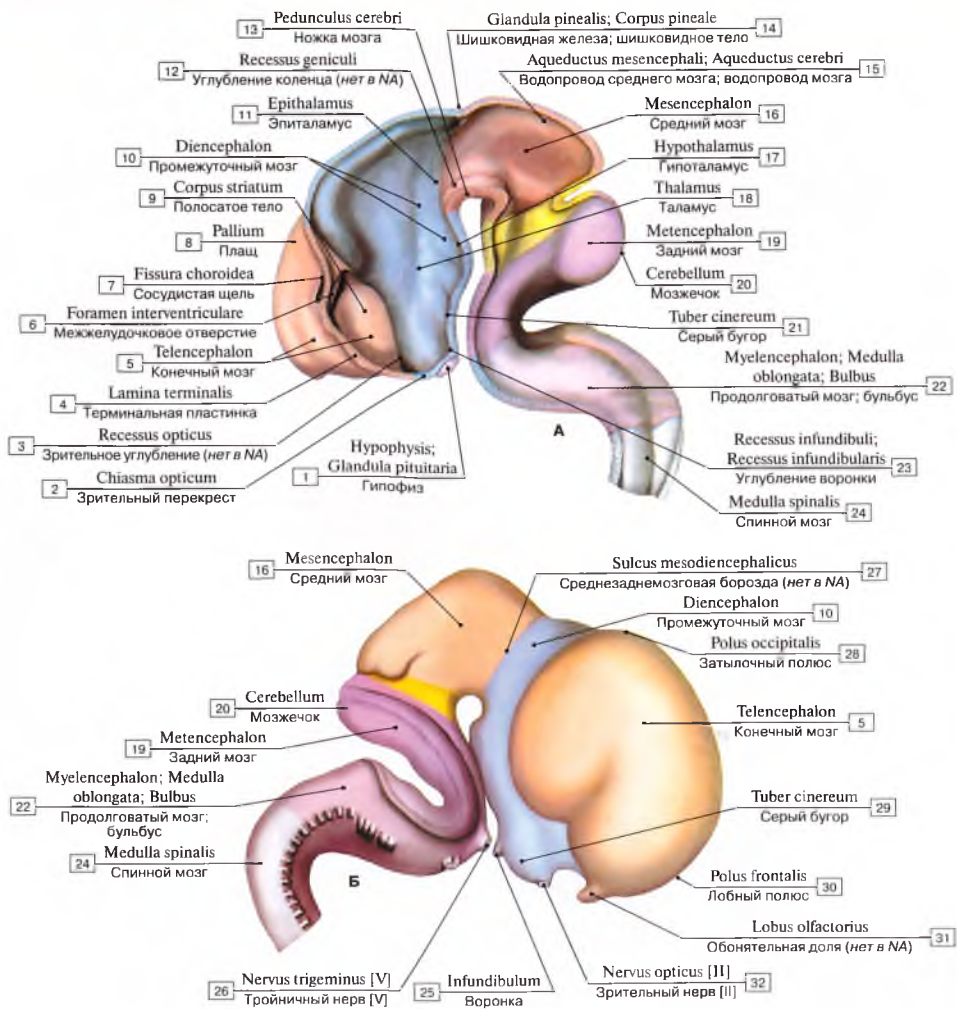


Рис. 12. Головной мозг эмбриона (реконструкция)

(А – эмбрион длиной 13,6 мм, правая половина, вид изнутри; Б – эмбрион длиной 50 мм, вид справа)

1 – Pituitary gland; 2 – Optic chiasm; Optic chiasma; 3 – Optic recess; 4 – Lamina terminalis; 5 – Telencephalon; 6 – Interventricular foramen; 7 – Choroidal fissure; 8 – Cerebral cortex; 9 – Corpus striatum; 10 – Diencerephalon; 11 – Epithalamus; 12 – Geniculate recess; 13 – Cerebral peduncle; 14 – Pineal gland; Pineal body; 15 – Aqueduct of midbrain; Cerebral aqueduct; 16 – Mesencephalon; Midbrain; 17 – Hypothalamus; 18 – Thalamus; Dorsal thalamus; 19 – Metencephalon; 20 – Cerebellum; 21 – Tuber cinereum; 22 – Myelencephalon; Medulla oblongata; Bulb; 23 – Infundibular recess; 24 – Spinal cord; 25 – Infundibulum; 26 – Trigeminal nerve [V]; 27 – Mesodiencephalic groove; 28 – Occipital pole; 29 – Tuber cinereum; 30 – Frontal pole; 31 – Olfactory lobe; 32 – Optic nerve [II]

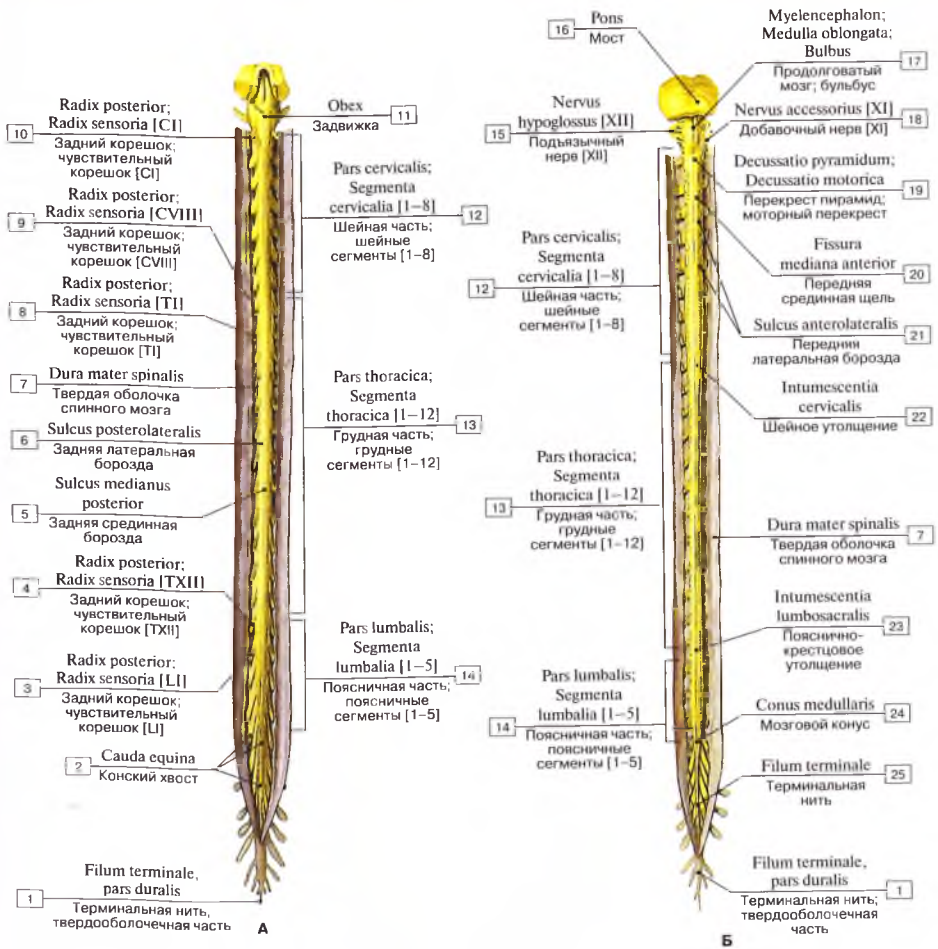


Рис. 13. Спинальный мозг, оболочки вскрыты (А – вид сзади; Б – вид спереди):

1 – Filum terminale; Terminal filum, dural part; coccygeal ligament; filum terminale externum; 2 – Cauda equina; 3 – Posterior root; Sensory root; Dorsal root [L1]; 4 – Posterior root; Sensory root; Dorsal root [TXII]; 5 – Posterior median sulcus; Dorsal median sulcus; 6 – Posterolateral sulcus; Dorsolateral sulcus; 7 – Spinal dura mater; 8 – Posterior root; Sensory root; Dorsal root [TI]; 9 – Posterior root; Sensory root; Dorsal root [CVIII]; 10 – Posterior root; Sensory root; Dorsal root [C1]; 11 – Obex; 12 – Cervical part; Cervical segments [1–8]; 13 – Thoracic part; Thoracic segments [1–12]; 14 – Lumbar part; Lumbar segments [1–5]; 15 – Hypoglossal nerve [XII]; 16 – Pons; 17 – Myelencephalon; Medulla oblongata; Bulb; 18 – Accessory nerve [XI]; 19 – Decussation of pyramids; Motor decussation; 20 – Anterior median fissure; 21 – Anterolateral sulcus; Ventrolateral sulcus; 22 – Cervical enlargement; 23 – Lumbosacral enlargement; 24 – Conus medullaris; Medullary cone; 25 – Filum terminale; Terminal filum

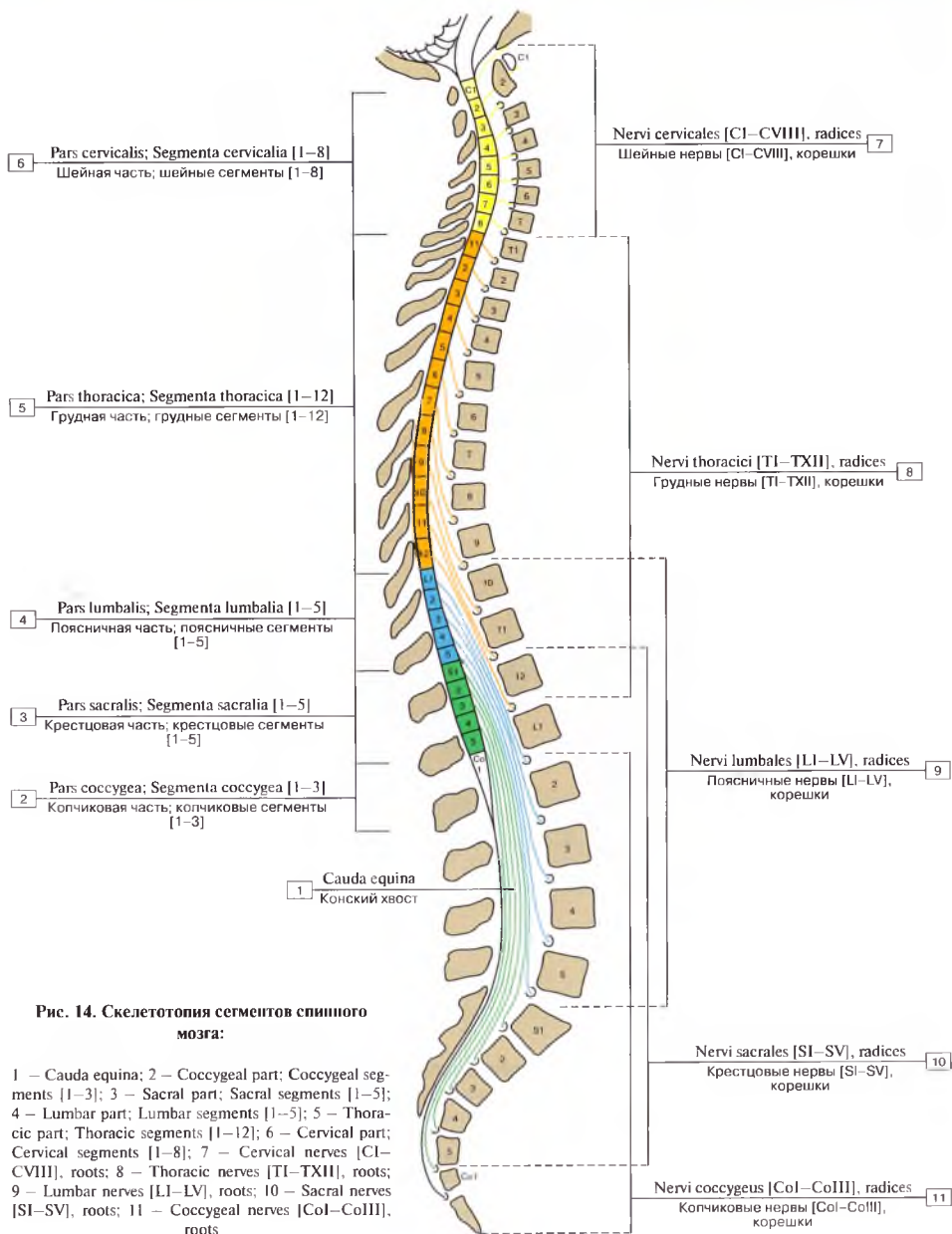


Рис. 14. Скелетотопия сегментов спинного мозга:

1 – Cauda equina; 2 – Coccygeal part; Coccygeal segments [1-3]; 3 – Sacral part; Sacral segments [1-5]; 4 – Lumbar part; Lumbar segments [1-5]; 5 – Thoracic part; Thoracic segments [1-12]; 6 – Cervical part; Cervical segments [1-8]; 7 – Cervical nerves [C1-CVIII], roots; 8 – Thoracic nerves [T1-TXII], roots; 9 – Lumbar nerves [L1-LV], roots; 10 – Sacral nerves [S1-SV], roots; 11 – Coccygeal nerves [CoI-CoIII], roots

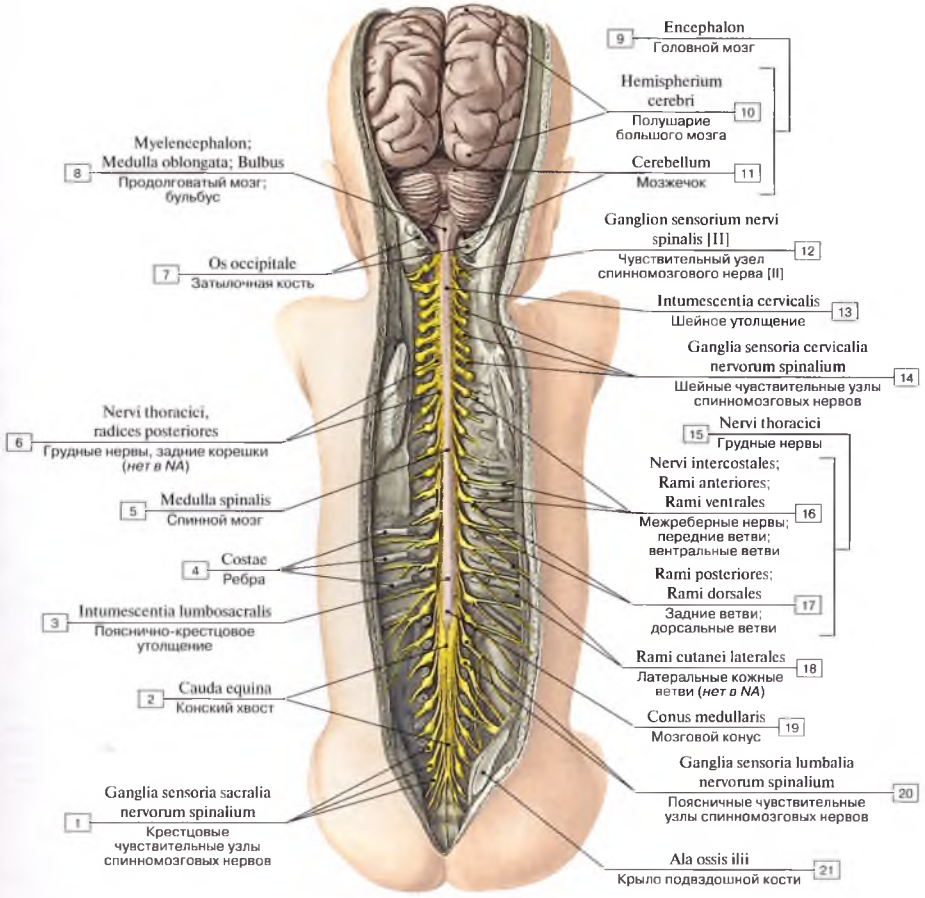


Рис. 15. Головной и спинной мозг, спинномозговые нервы новорожденного, вид сзади:

1 – Sacral spinal ganglia; Sacral dorsal root ganglia; 2 – Cauda equina; 3 – Lumbosacral enlargement; 4 – Ribs; 5 – Spinal cord; 6 – Thoracic nerves, posterior roots; 7 – Occipital bone; 8 – Myelencephalon; Medulla oblongata; Bulb; 9 = 10 + 11 – Brain; 10 – Cerebral hemisphere; 11 – Cerebellum; 12 – Spinal ganglion; Dorsal root ganglion [II]; 13 – Cervical enlargement; 14 – Cervical spinal ganglia; Cervical dorsal root ganglia; 15 = 16 + 17 – Thoracic nerves; 16 – Intercostal nerves; Anterior branches; Ventral branches; 17 – Posterior branches; Dorsal branches; 18 – Lateral cutaneous branches; 19 – Conus medullaris; Medullary cone; 20 – Lumbar spinal ganglia; Lumbar dorsal root ganglia; 21 – Ala of ilium; Wing of ilium

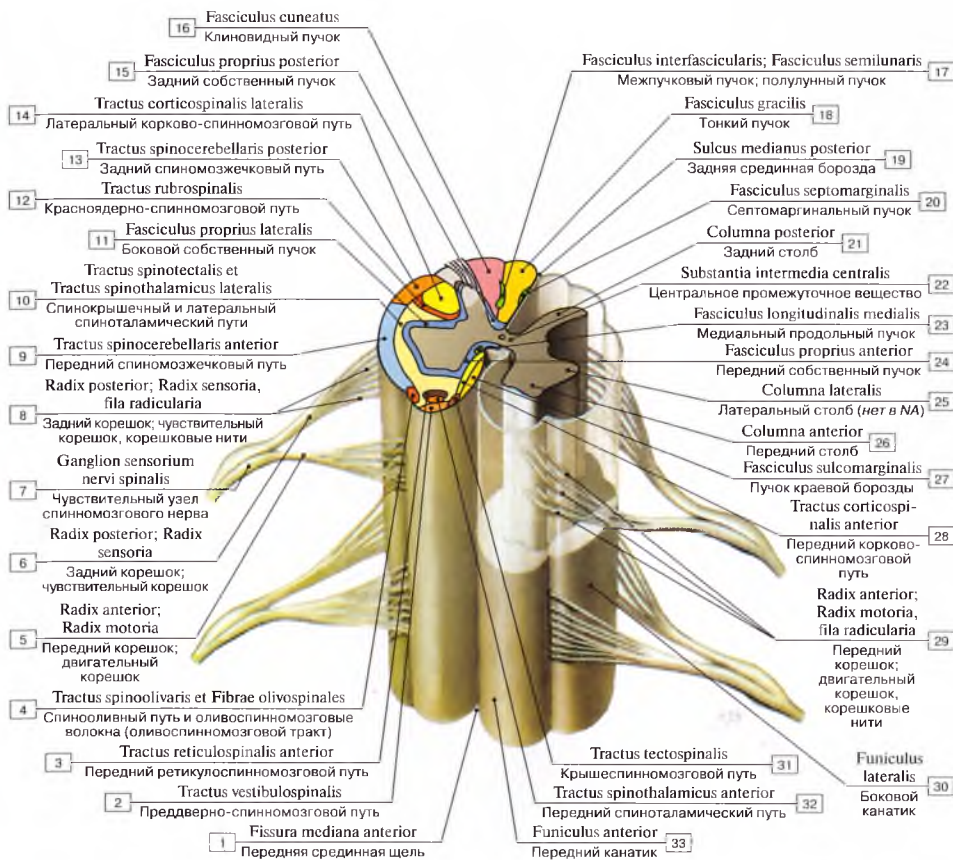


Рис. 16. Два сегмента спинного мозга, вид спереди, справа и сверху (схема). Справа показана топография белого вещества, слева — белое вещество удалено, видно серое вещество:

1 — Anterior median fissure; Ventral median fissure; 2 — Vestibulospinal tract; 3 — Anterior reticulospinal tract; Ventral reticulospinal tract; 4 — Spino-olivary tract and Olivospinal fibres; 5 — Anterior root; Motor root; Ventral root; 6 — Posterior root; Sensory root; Dorsal root; 7 — Spinal ganglion; Dorsal root ganglion; 8 — Posterior root; Sensory root; Dorsal root, rootlets; 9 — Anterior spinocerebellar tract; Ventral spinocerebellar tract; 10 — Spinotectal tract and Lateral spinothalamic tract; 11 — Lateral fasciculus proprius; 12 — Rubrospinal tract; 13 — Posterior spinocerebellar tract; Dorsal spinocerebellar tract; 14 — Lateral corticospinal tract; 15 — Posterior fasciculus proprius; Dorsal fasciculus proprius; 16 — Cuneate fasciculus; 17 — Interfascicular fasciculus; 18 — Gracile fasciculus; 19 — Posterior median sulcus; Dorsal median sulcus; 20 — Septomarginal fasciculus; 21 — Posterior column; Dorsal column; 22 — Central intermediate substance; 23 — Medial longitudinal fasciculus; 24 — Anterior fasciculus proprius; Ventral fasciculus proprius; 25 — Lateral column; 26 — Anterior column; Ventral column; 27 — Sulcomarginal fasciculus; 28 — Anterior corticospinal tract; Ventral corticospinal tract; 29 — Anterior root; Motor root; Ventral root, rootlets; 30 — Lateral funiculus; 31 — Tectospinal tract; 32 — Anterior spinothalamic tract; Ventral spinothalamic tract; 33 — Anterior funiculus; Ventral funiculus

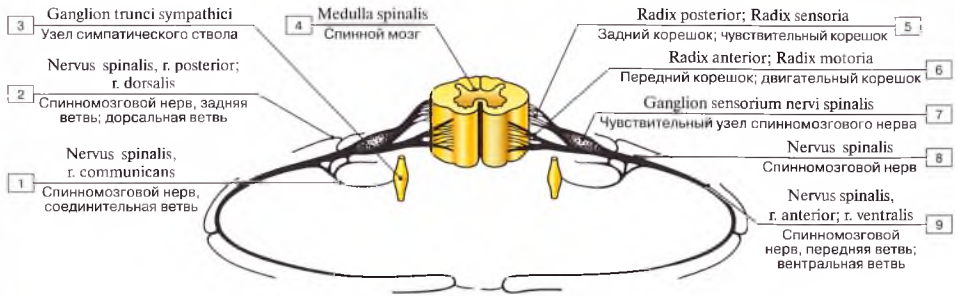


Рис. 17. Сегмент спинного мозга, вид спереди и сверху (схема):

1 – Spinal nerve, communicating branch; 2 – Spinal nerve, posterior branch; dorsal branch; 3 – Ganglion of sympathetic trunk; 4 – Spinal cord; 5 – Posterior root; Sensory root; Dorsal root; 6 – Anterior root; Motor root; Ventral root; 7 – Spinal ganglion; Dorsal root ganglion; 8 – Spinal nerve; 9 – Spinal nerve, anterior branch; ventral branch

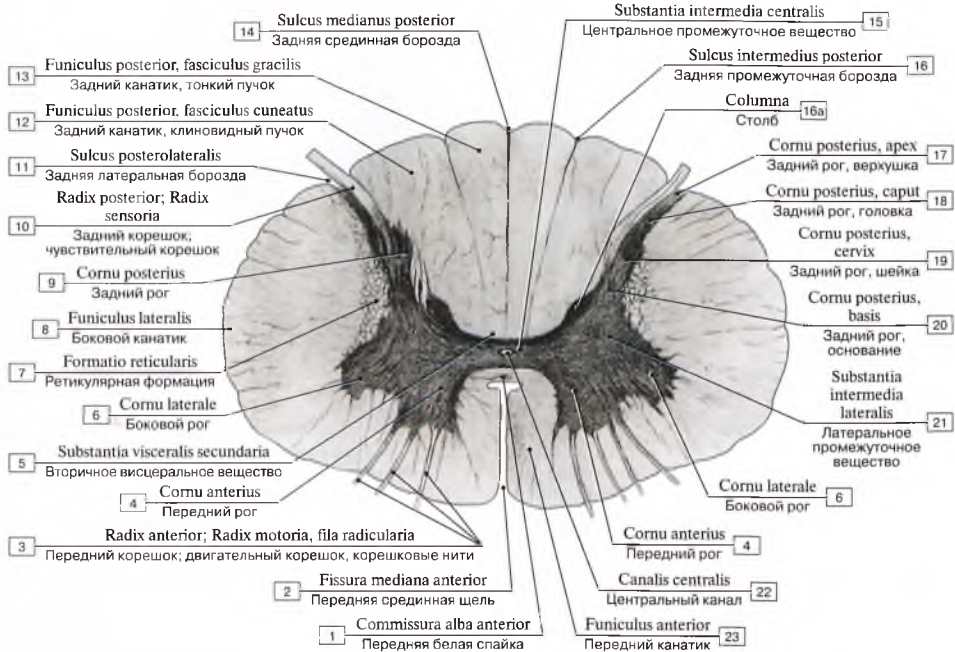


Рис. 18. Верхний отдел грудной части спинного мозга, поперечный разрез:

1 – Anterior white commissure; 2 – Anterior median fissure; Ventral median fissure; 3 – Anterior root; Motor root; Ventral root, rootlets; 4 – Anterior horn; Ventral horn; 5 – Secondary visceral grey substance; 6 – Lateral horn; 7 – Reticular formation; 8 – Lateral funiculus; 9 – Posterior horn; Dorsal horn; 10 – Posterior root; Sensory root; Dorsal root; 11 – Posterolateral sulcus; Dorsolateral sulcus; 12 – Posterior funiculus; Dorsal funiculus, cuneate fasciculus; 13 – Posterior funiculus; Dorsal funiculus, gracile fasciculus; 14 – Posterior median sulcus; Dorsal median sulcus; 15 – Central intermediate substance; 16 – Posterior intermediate sulcus; Dorsal intermediate sulcus; 16a – Columna; 17 – Posterior horn; Dorsal horn, apex; 18 – Posterior horn; Dorsal horn, head; 19 – Posterior horn; Dorsal horn, neck; 20 – Posterior horn; Dorsal horn, base; 21 – Lateral intermediate substance; 22 – Central canal; 23 – Anterior funiculus; Ventral funiculus

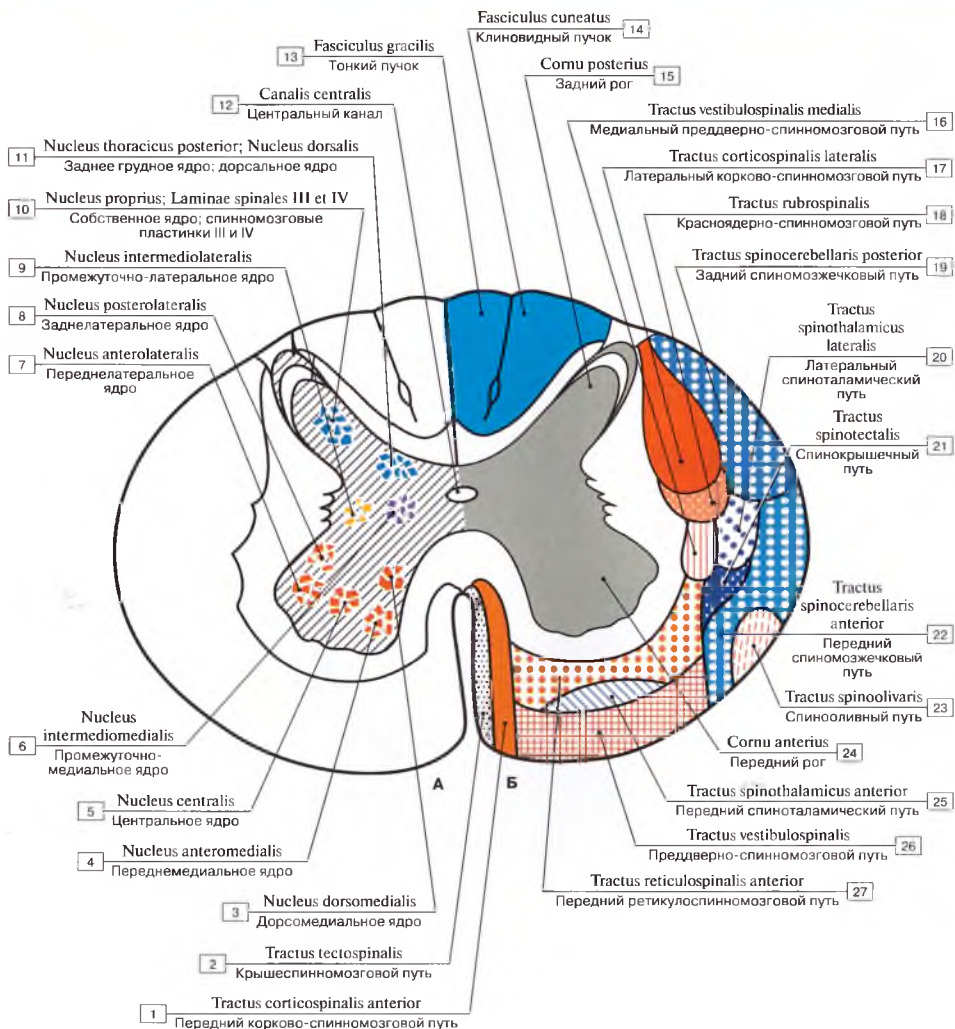


Рис. 19. Ядра (А) и проводящие пути (Б) спинного мозга (схема):

1 – Anterior corticospinal tract; Ventral corticospinal tract; 2 – Tectospinal tract; 3 – Dorsomedial nucleus; 4 – Anteromedial nucleus; Ventromedial nucleus; 5 – Central nucleus; 6 – Intermediomedial nucleus; 7 – Anterolateral nucleus; Ventrolateral nucleus; 8 – Posterolateral nucleus; Dorsolateral nucleus; 9 – Intermediolateral nucleus; 10 – Nucleus proprius; Spinal laminae III and IV; 11 – Posterior thoracic nucleus; Dorsal thoracic nucleus; 12 – Central canal; 13 – Gracile fasciculus; 14 – Cuneate fasciculus; 15 – Posterior horn; Dorsal horn; 16 – Medial vestibulospinal tract; 17 – Lateral corticospinal tract; 18 – Rubrospinal tract; 19 – Posterior spinocerebellar tract; Dorsal spinocerebellar tract; 20 – Lateral spinothalamic tract; 21 – Spinoctectal tract; 22 – Anterior spinocerebellar tract; Ventral spinocerebellar tract; 23 – Spino-olivary tract; 24 – Anterior horn; Ventral horn; 25 – Anterior spinothalamic tract; Ventral spinothalamic tract; 26 – Vestibulospinal tract; 27 – Anterior reticulospinal tract; Ventral reticulospinal tract



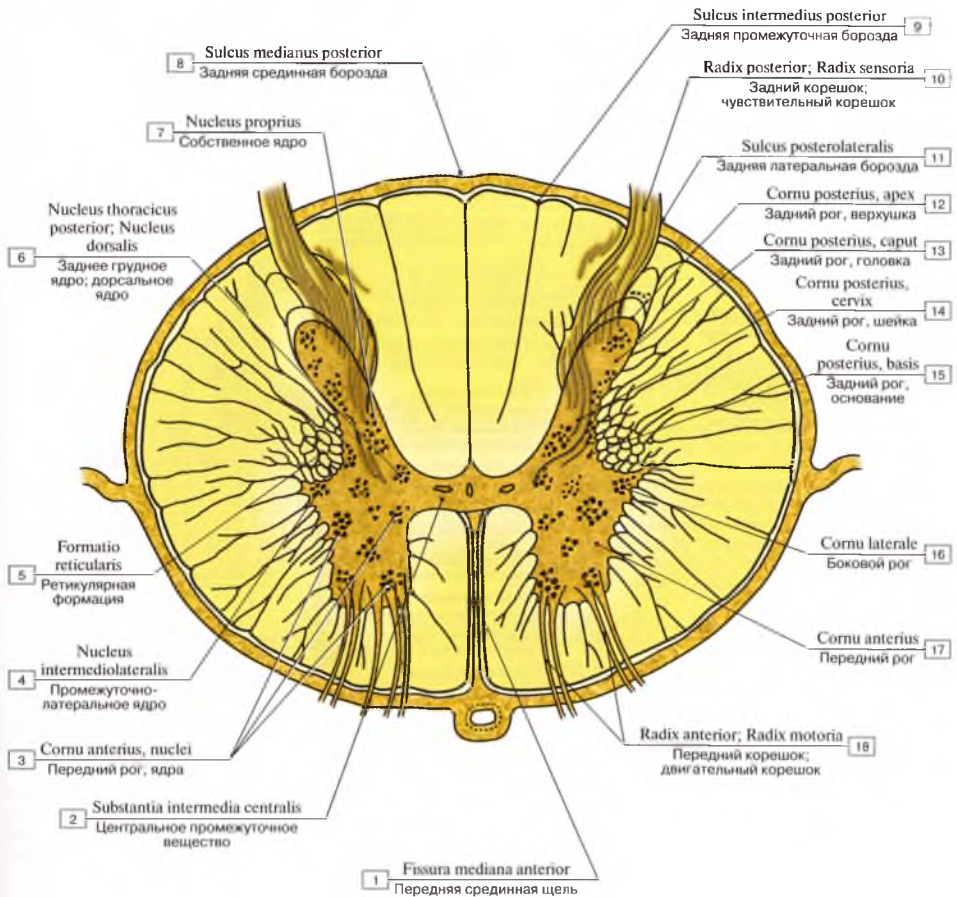


Рис. 20. Ядра серого вещества спинного мозга, поперечный разрез (схема):

1 – Anterior median fissure; Ventral median fissure; 2 – Central intermediate substance; 3 – Anterior horn; Ventral horn, nuclei; 4 – Intermediolateral nucleus; 5 – Reticular formation; 6 – Posterior thoracic nucleus; Dorsal thoracic nucleus; 7 – Nucleus proprius; 8 – Posterior median sulcus; Dorsal median sulcus; 9 – Posterior intermediate sulcus; Dorsal intermediate sulcus; 10 – Posterior root; Sensory root; 11 – Posterolateral sulcus; Dorsolateral sulcus; 12 – Posterior horn; Dorsal horn, apex; 13 – Posterior horn; Dorsal horn, head; 14 – Posterior horn; Dorsal horn, neck; 15 – Posterior horn; Dorsal horn, base; 16 – Lateral horn; 17 – Anterior horn; Ventral horn; 18 – Anterior root; Motor root; Ventral root

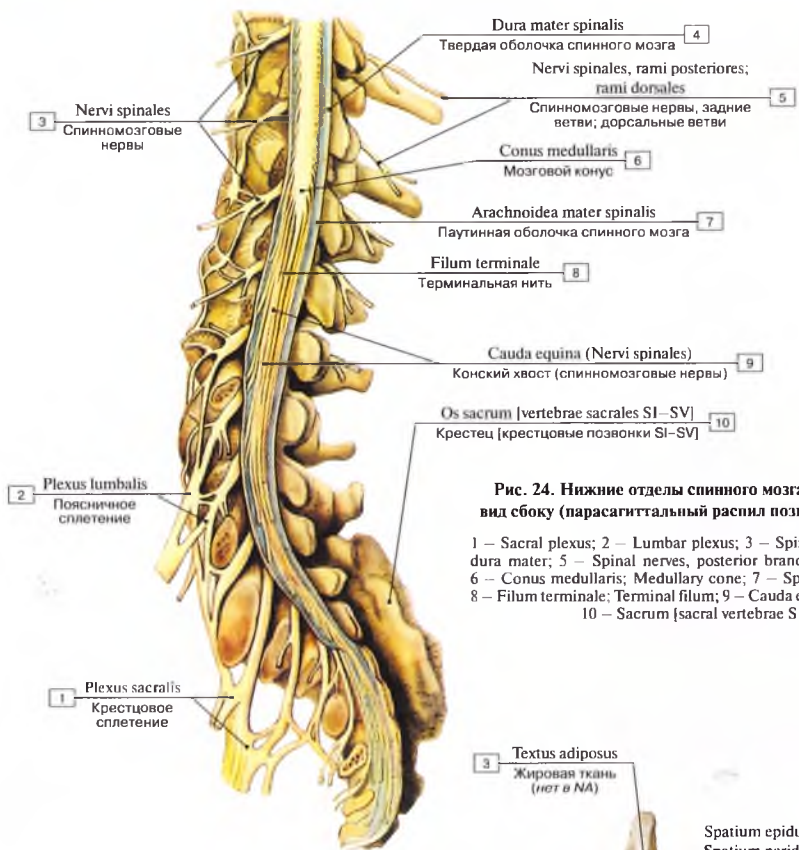
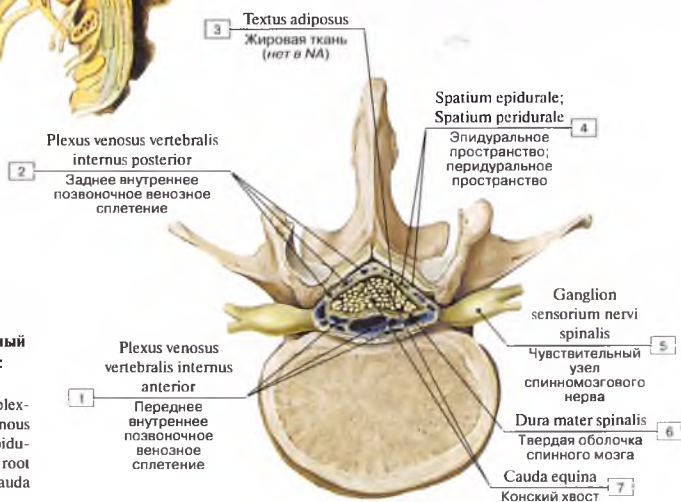


Рис. 24. Нижние отделы спинного мозга и его оболочек, вид сбоку (парасагитальный распил позвоночного столба):

1 – Sacral plexus; 2 – Lumbar plexus; 3 – Spinal nerves; 4 – Spinal dura mater; 5 – Spinal nerves, posterior branches; 6 – Conus medullaris; 7 – Spinal arachnoid mater; 8 – Filum terminale; 9 – Cauda equina (Spinal nerves); 10 – Sacrum [sacral vertebrae SI-SV]

Рис. 25. Конский хвост, поперечный разрез на уровне LII позвонка:

1 – Anterior internal vertebral venous plexus; 2 – Posterior internal vertebral venous plexus; 3 – Adipose tissue; 4 – Epidural space; 5 – Spinal ganglion; 6 – Spinal dura mater; 7 – Cauda equina



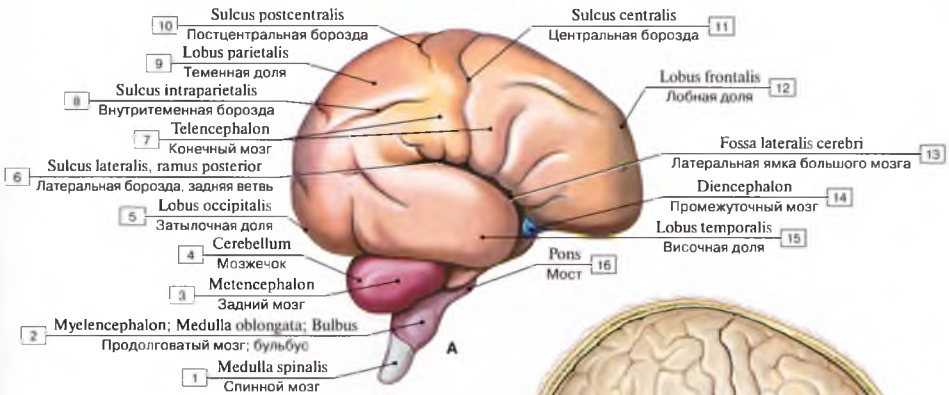
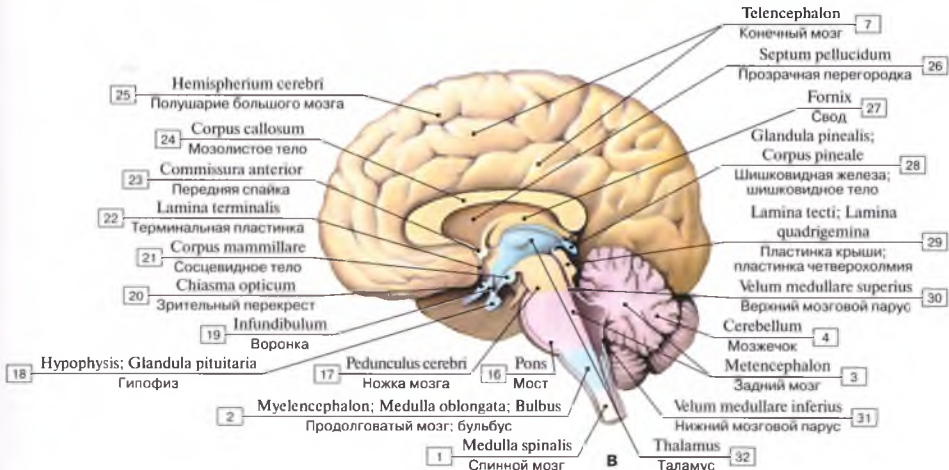
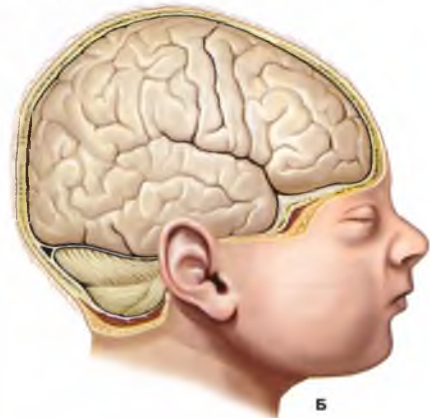


Рис. 26. Головной мозг (А – эмбрион длиной 13 см, вид справа, реконструкция; Б – головной мозг новорожденного, правое полушарие; В – головной мозг взрослого человека, правое полушарие):

1 – Spinal cord; 2 – Myelencephalon; Medulla oblongata; Bulb; 3 – Metencephalon; 4 – Cerebellum; 5 – Occipital lobe; 6 – Lateral sulcus, posterior branch; 7 – Telencephalon; 8 – Intraparietal sulcus; 9 – Parietal lobe; 10 – Postcentral sulcus; 11 – Central sulcus; 12 – Frontal lobe; 13 – Lateral cerebral fossa; 14 – Dienecephalon; 15 – Temporal lobe; 16 – Pons; 17 – Cerebral peduncle; 18 – Pituitary gland; 19 – Infundibulum; 20 – Optic chiasm; Optic chiasma; 21 – Mammillary body; 22 – Lamina terminalis; 23 – Anterior commissure; 24 – Corpus callosum; 25 – Cerebral hemisphere; 26 – Septum pellucidum; 27 – Fornix; 28 – Pineal gland; Pineal body; 29 – Tectal plate; Quadrigeminal plate; 30 – Superior medullary velum; 31 – Inferior medullary velum; 32 – Thalamus; Dorsal thalamus



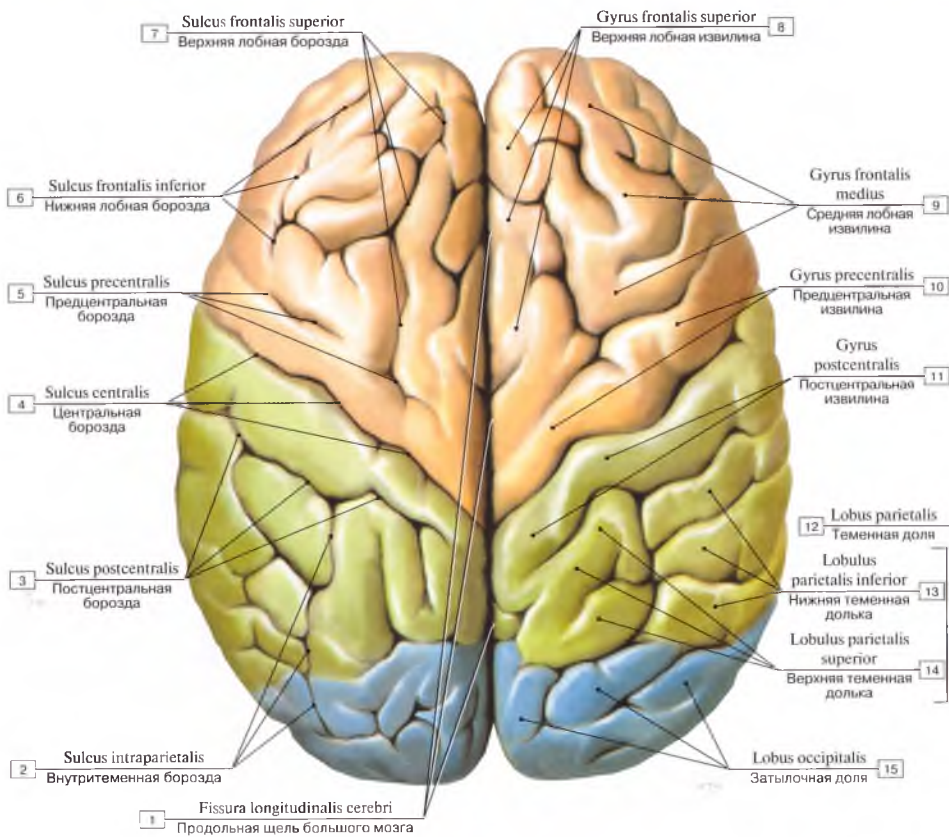


Рис. 27. Борозды и извилины верхней поверхности полушарий большого мозга:

1 – Longitudinal cerebral fissure; 2 – Intraparietal sulcus; 3 – Postcentral sulcus; 4 – Central sulcus; 5 – Precentral sulcus; 6 – Inferior frontal sulcus; 7 – Superior frontal sulcus; 8 – Superior frontal gyrus; 9 – Middle frontal gyrus; 10 – Precentral gyrus; 11 – Postcentral gyrus; 12 = 13 + 14 – Parietal lobe; 13 – Inferior parietal lobule; 14 – Superior parietal lobule; 15 – Occipital lobe

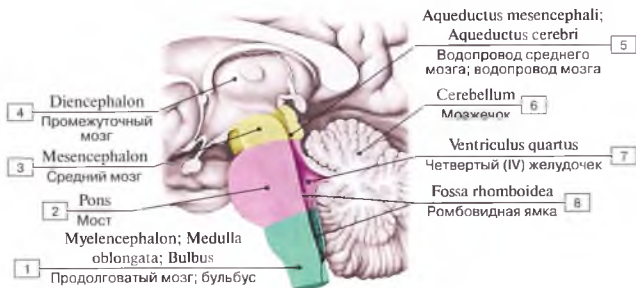


Рис. 28. Ствол мозга:

1 – Myelencephalon; Medulla oblongata; Bulb; 2 – Pons; 3 – Mesencephalon; Midbrain; 4 – Diencephalon; 5 – Aqueduct of midbrain; Cerebral aqueduct; 6 – Cerebellum; 7 – Fourth ventricle; 8 – Rhomboid fossa; Floor of fourth ventricle

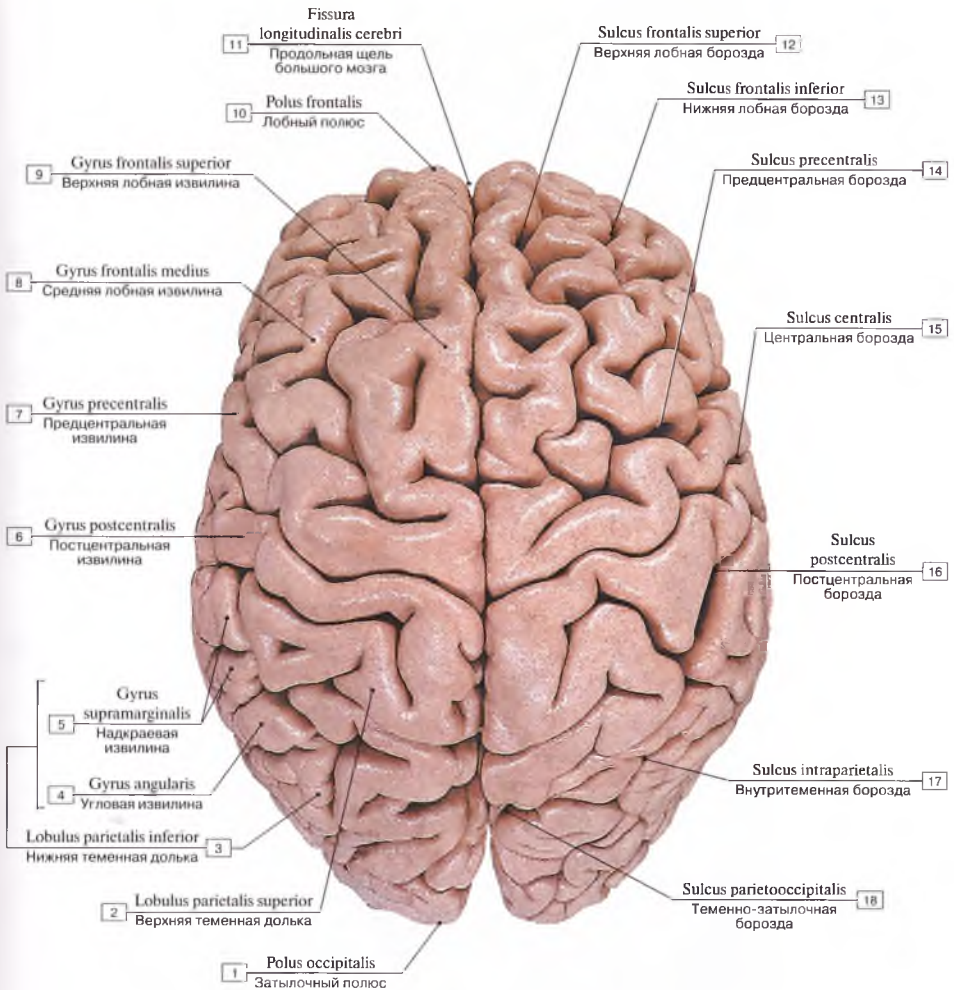


Рис.29. Головной мозг, верхняя поверхность:

1 – Occipital pole; 2 – Superior parietal lobe; 3 = 4 + 5 – Inferior parietal lobe; 4 – Angular gyrus; 5 – Supramarginal gyrus; 6 – Post-central gyrus; 7 – Precentral gyrus; 8 – Middle frontal gyrus; 9 – Superior frontal gyrus; 10 – Frontal pole; 11 – Longitudinal cerebral fissure; 12 – Superior frontal sulcus; 13 – Inferior frontal sulcus; 14 – Precentral sulcus; 15 – Central sulcus; 16 – Postcentral sulcus; 17 – Intraparietal sulcus; 18 – Parieto-occipital sulcus

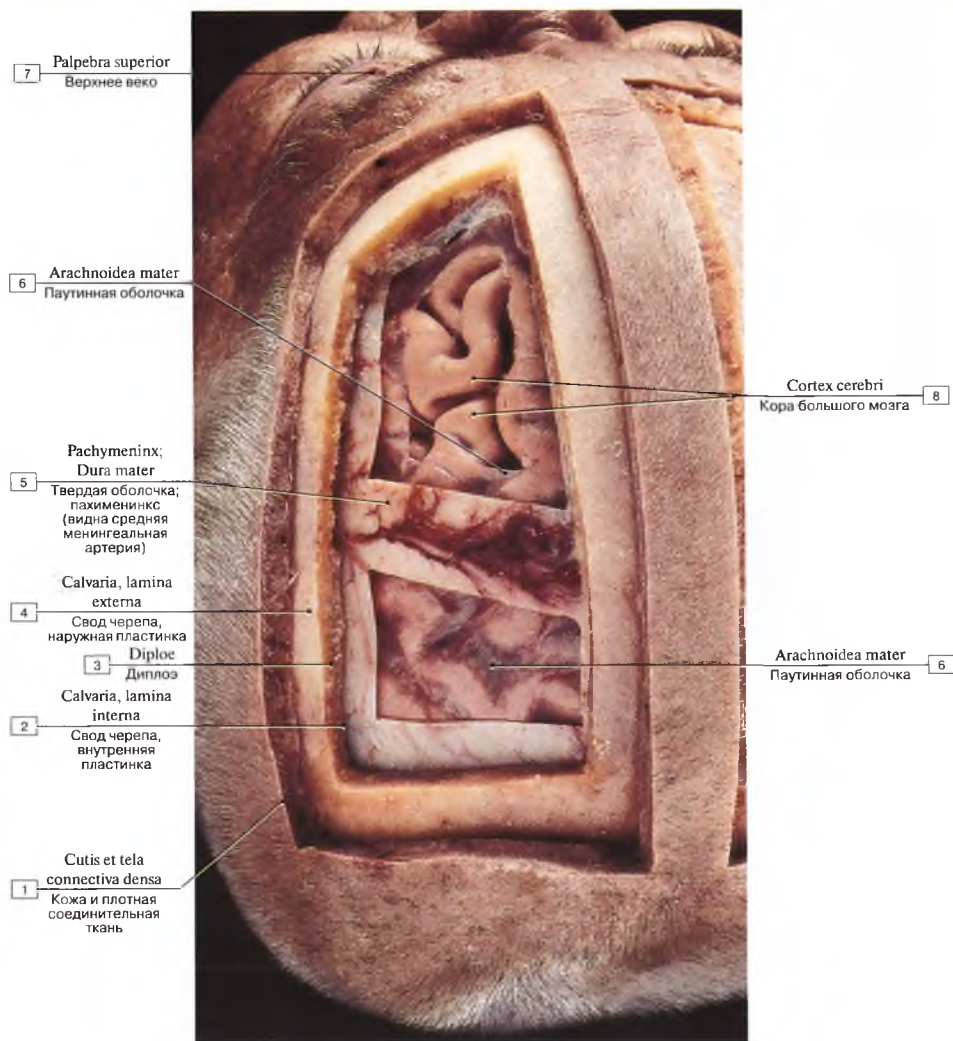


Рис. 30. Оболочки мозга, натуральный фиксированный препарат:

1 – Skin and dense connective tissue; 2 – Calvaria, internal table; 3 – Diploe; 4 – Calvaria, external table; 5 – Pachymeninx; Dura mater; 6 – Arachnoid mater; 7 – Superior eyelid; Upper eyelid; 8 – Cerebral cortex

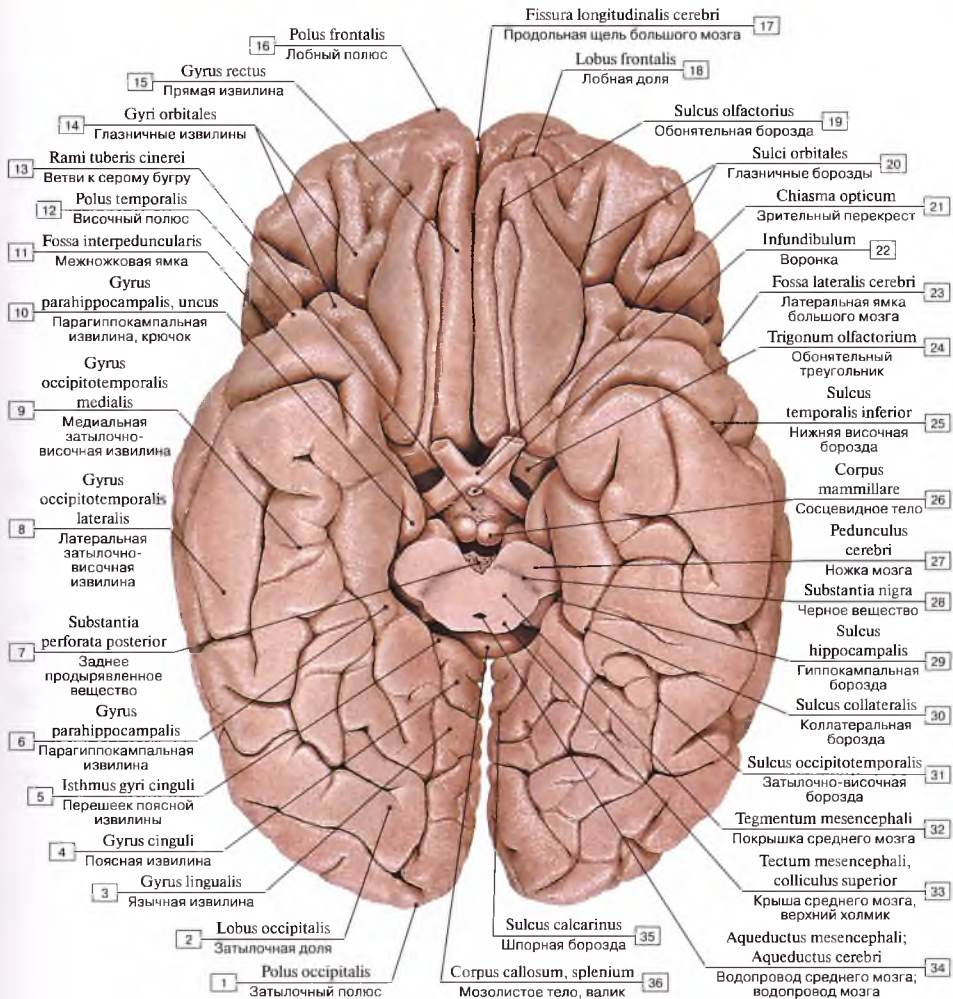


Рис. 31. Головной мозг, нижняя поверхность:

1 – Occipital pole; 2 – Occipital lobe; 3 – Lingual gyrus; 4 – Cingulate gyrus; 5 – Isthmus of cingulate gyrus; 6 – Parahippocampal gyrus; 7 – Posterior perforated substance; 8 – Lateral occipitotemporal gyrus; 9 – Medial occipitotemporal gyrus; 10 – Parahippocampal gyrus, uncus; 11 – Interpeduncular fossa; 12 – Temporal pole; 13 – Branches to tuber cinereum; 14 – Orbital gyri; 15 – Straight gyrus; 16 – Frontal pole; 17 – Longitudinal cerebral fissure; 18 – Frontal lobe; 19 – Olfactory sulcus; 20 – Orbital sulci; 21 – Optic chiasm; Optic chiasma; 22 – Infundibulum; 23 – Lateral cerebral fossa; 24 – Olfactory trigone; 25 – Inferior temporal sulcus; 26 – Mammillary body; 27 – Cerebral peduncle; 28 – Substantia nigra; 29 – Hippocampal sulcus; 30 – Collateral sulcus; 31 – Occipitotemporal sulcus; 32 – Tegmentum of midbrain; 33 – Tectum of midbrain, superior colliculus; 34 – Aqueduct of midbrain; Cerebral aqueduct; 35 – Calcarine sulcus; 36 – Corpus callosum, splenium

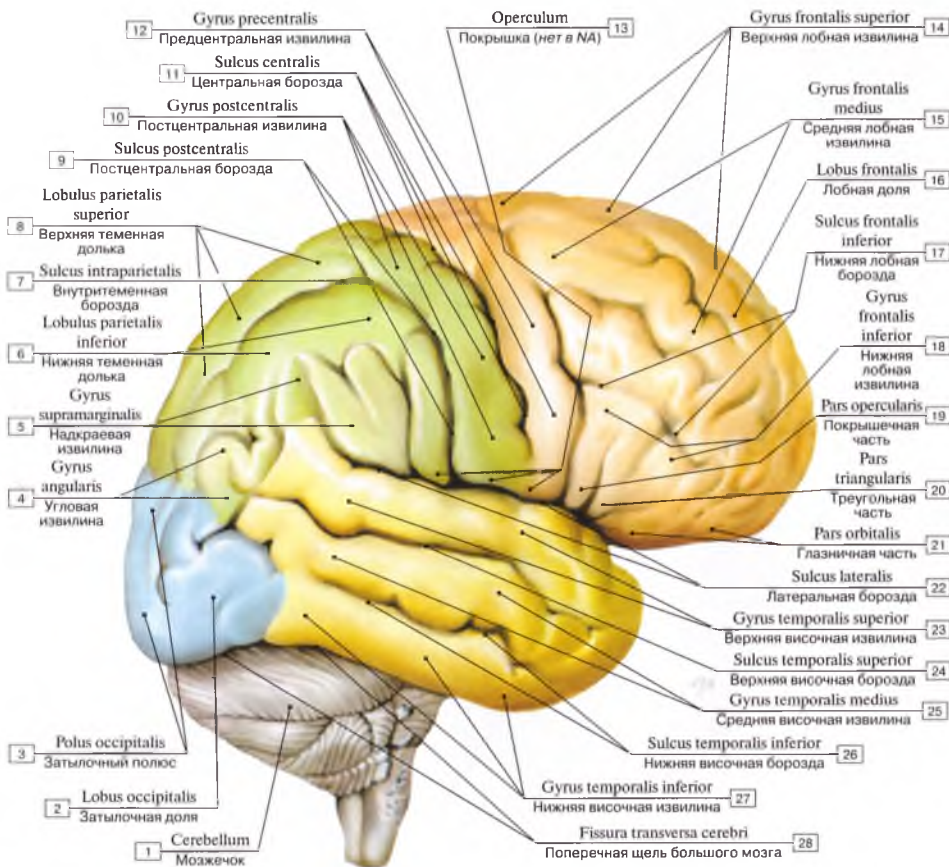


Рис. 32. Борозды и извилины верхнелатеральной поверхности правого полушария большого мозга, вид сбоку:

1 – Cerebellum; 2 – Occipital lobe; 3 – Occipital pole; 4 – Angular gyrus; 5 – Supramarginal gyrus; 6 – Inferior parietal lobule; 7 – Intraparietal sulcus; 8 – Superior parietal lobule; 9 – Postcentral sulcus; 10 – Postcentral gyrus; 11 – Central sulcus; 12 – Precentral gyrus; 13 – Operculum; 14 – Superior frontal gyrus; 15 – Middle frontal gyrus; 16 – Frontal lobe; 17 – Inferior frontal sulcus; 18 – ; 19 – Opercular part; 20 – Triangular part; 21 – Orbital part; 22 – Lateral sulcus; 23 – Superior temporal gyrus; 24 – Superior temporal sulcus; 25 – Middle temporal gyrus; 26 – Inferior temporal sulcus; 27 – Inferior temporal gyrus; 28 – Transverse cerebral fissure



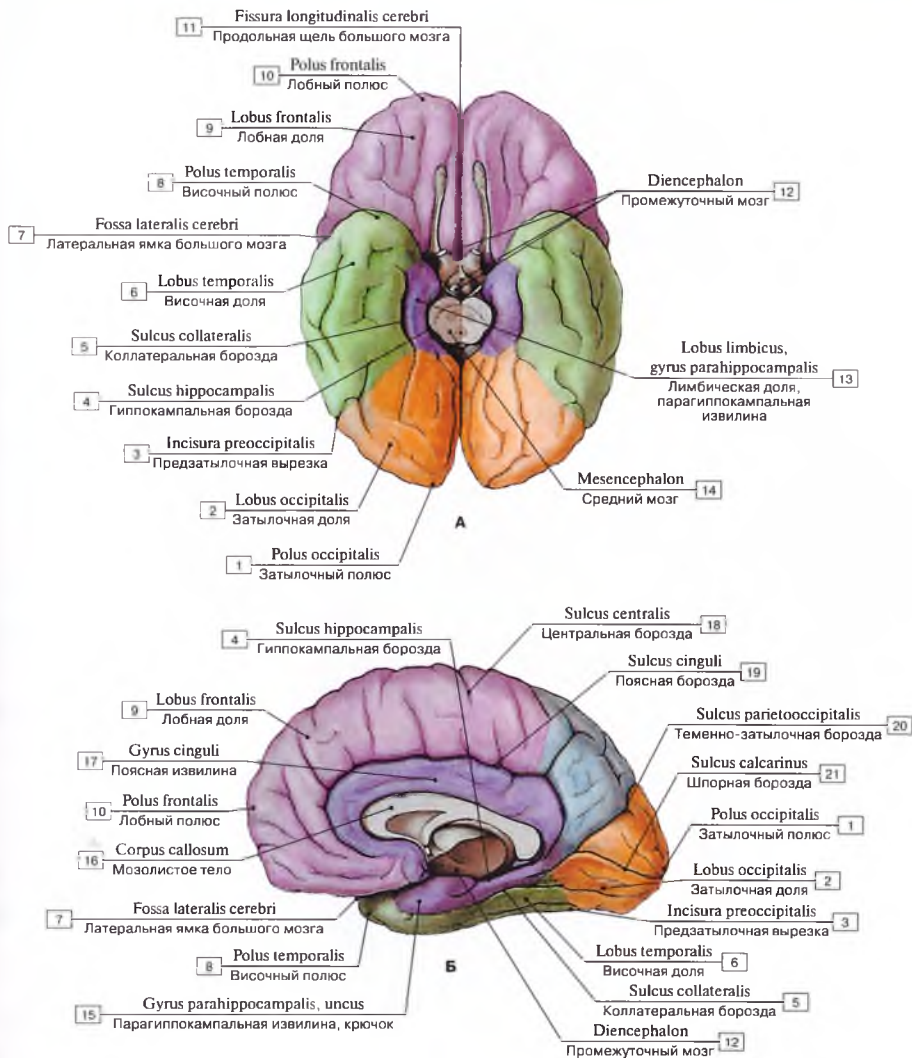


Рис. 33. Доли полушарий большого мозга (А – нижняя поверхность; Б – медиальная поверхность):

1 – Occipital pole; 2 – Occipital lobe; 3 – Pre-occipital notch; 4 – Hippocampal sulcus; 5 – Collateral sulcus; 6 – Temporal lobe; 7 – Lateral cerebral fossa; 8 – Temporal pole; 9 – Frontal lobe; 10 – Frontal pole; 11 – Longitudinal cerebral fissure; 12 – Diencephalon; 13 – Limbic lobe, parahippocampal gyrus; 14 – Mesencephalon; 15 – Parahippocampal gyrus, uncus; 16 – Corpus callosum; 17 – Cingulate gyrus; 18 – Central sulcus; 19 – Cingulate sulcus; 20 – Parieto-occipital sulcus; 21 – Calcarine sulcus

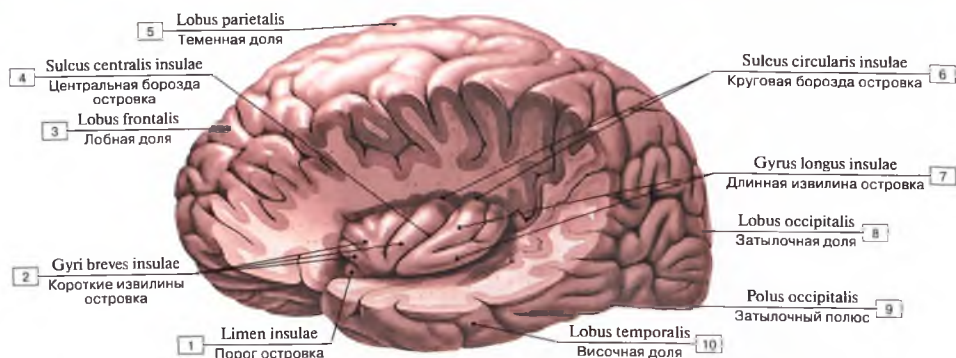


Рис. 34. Головной мозг, левое полушарие, вид сбоку. Островок, удалены части лобной, теменной и височной долей:

1 – Limen insulae; Insular threshold; 2 – Short gyri of insula; 3 – Frontal lobe; 4 – Central sulcus of insula; 5 – Parietal lobe; 6 – Circular sulcus of insula; 7 – Long gyrus of insula; 8 – Occipital lobe; 9 – Occipital pole; 10 – Temporal lobe

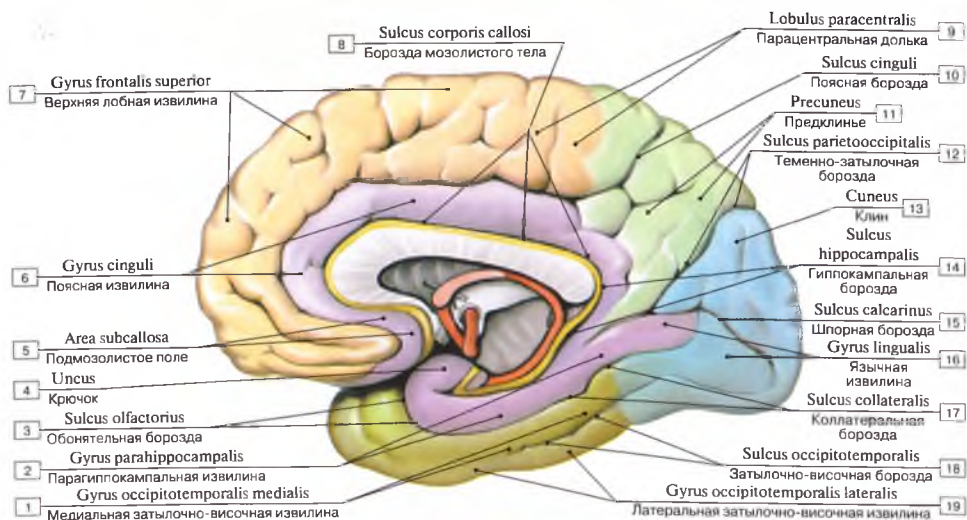


Рис. 35. Борозды и извилины правого полушария большого мозга, медиальная поверхность:

1 – Medial occipitotemporal gyrus; 2 – Parahippocampal gyrus; 3 – Olfactory sulcus; 4 – Uncus; 5 – Subcallosal area; Subcallosal gyrus; 6 – Cingulate gyrus; 7 – Superior frontal gyrus; 8 – Sulcus of corpus callosum; 9 – Paracentral lobule; 10 – Cingulate sulcus; 11 – Precuneus; 12 – Parieto-occipital sulcus; 13 – Cuneus; 14 – Hippocampal sulcus; 15 – Calcarine sulcus; 16 – Lingual gyrus; 17 – Collateral sulcus; 18 – Occipitotemporal sulcus; 19 – Lateral occipitotemporal gyrus

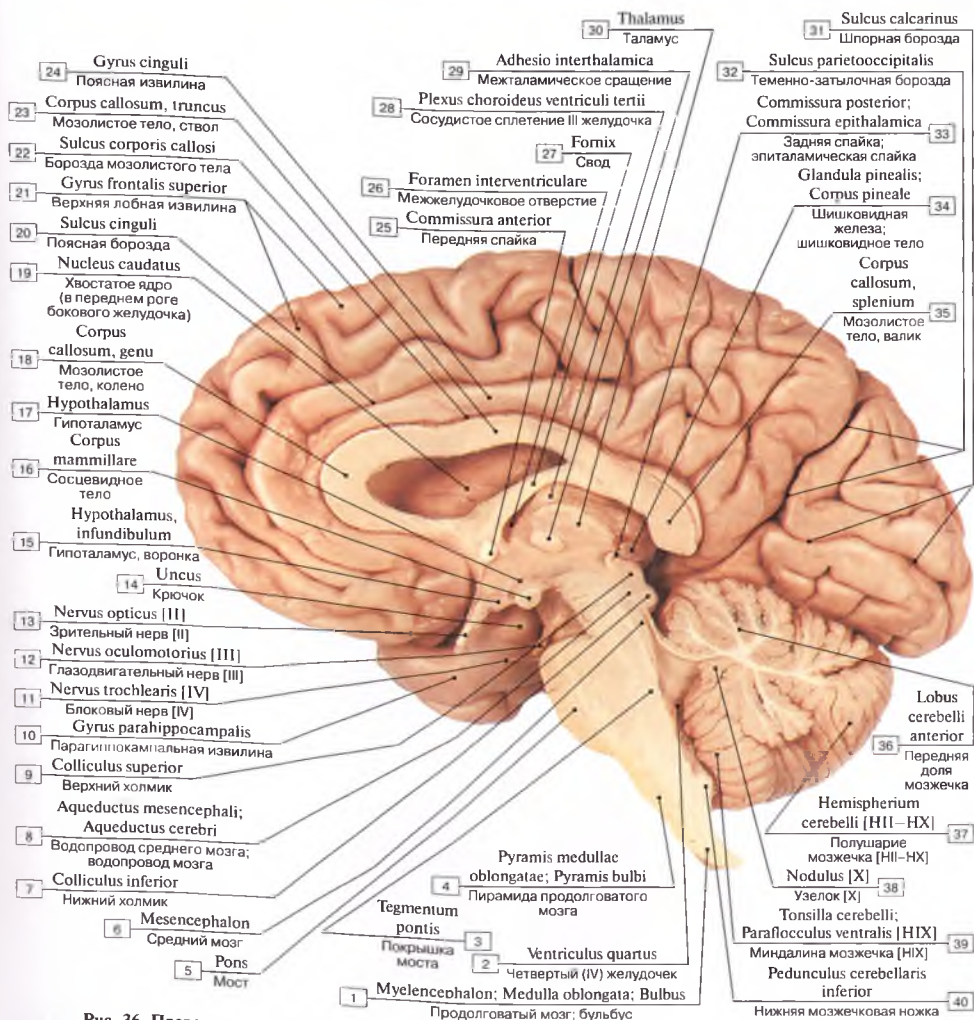


Рис. 36. Правая половина головного мозга, вид изнутри, паутинная и мягкая мозговые оболочки удалены (фотография натурального препарата):

- 1 — Myelencephalon; Medulla oblongata; Bulb; 2 — Fourth ventricle; 3 — Tegmentum of pons; 4 — Pyramid; 5 — Pons; 6 — Mesencephalon; Midbrain; 7 — Inferior colliculus; 8 — Aqueduct of midbrain; Cerebral aqueduct; 9 — Superior colliculus; 10 — Parahippocampal gyrus; 11 — Trochlear nerve [IV]; 12 — Oculomotor nerve [III]; 13 — Optic nerve [II]; 14 — Uncus; 15 — Hypothalamus, infundibulum; 16 — Mammillary body; 17 — Hypothalamus; 18 — Corpus callosum, genu; 19 — Caudate nucleus; 20 — Cingulate sulcus; 21 — Superior frontal gyrus; 22 — Sulcus of corpus callosum; 23 — Corpus callosum, body; trunk; 24 — Cingulate gyrus; 25 — Anterior commissure; 26 — Interventricular foramen; 27 — Fornix; 28 — Choroid plexus of third ventricle; 29 — Interthalamic adhesion; Massa intermedia; 30 — Thalamus; Dorsal thalamus; splenium; 31 — Calcarine sulcus; 32 — Parieto-occipital sulcus; 33 — Posterior commissure; 34 — Pineal gland; Pineal body; 35 — Corpus callosum, splenium; 36 — Anterior lobe of cerebellum; 37 — Hemisphere of cerebellum [HII—HX]; 38 — Nodule [X]; 39 — Tonsil of cerebellum; Ventral paraflocculus [HIX]; 40 — Inferior cerebellar peduncle

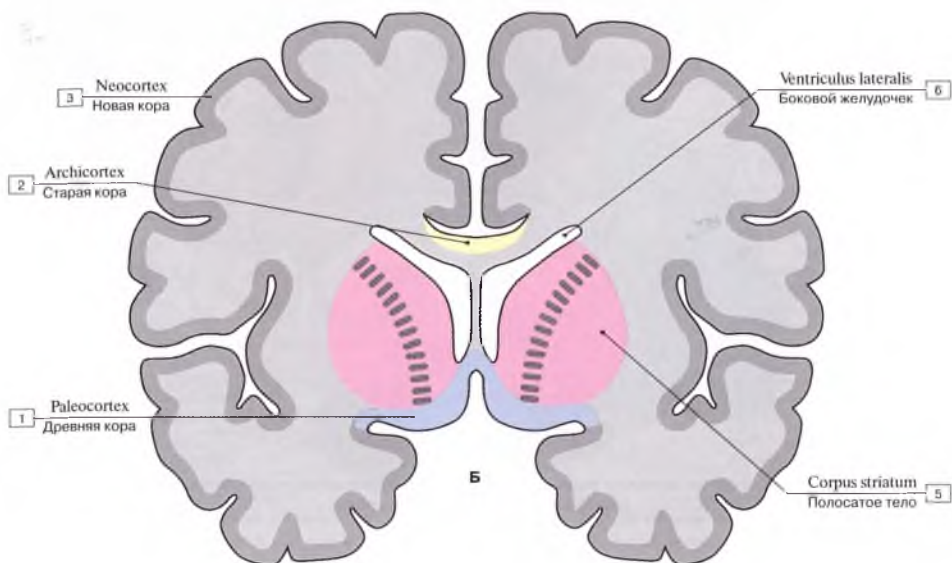
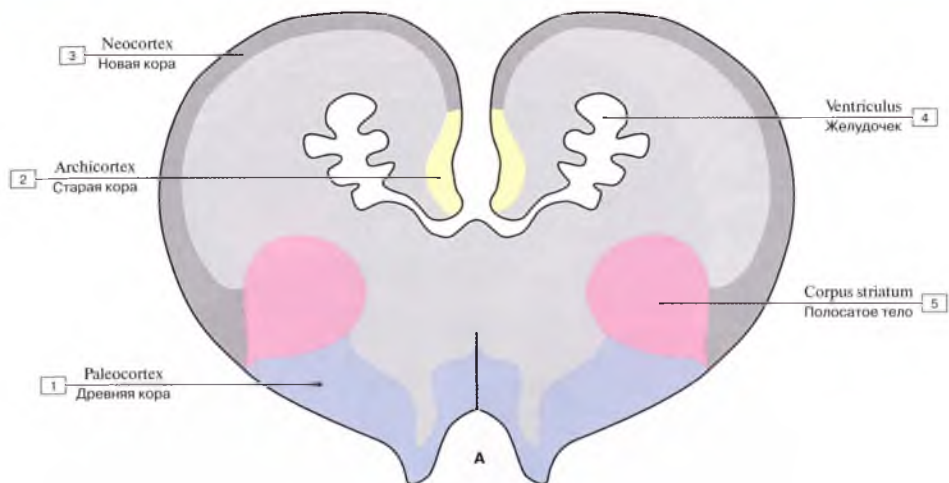


Рис. 37. Кора и базальные ядра полушария большого мозга  
(А – эмбриона; Б – взрослого человека):

1 – Paleocortex; 2 – Archicortex; 3 – Neocortex; 4 – Ventricle; 5 – Corpus striatum; 6 – Lateral ventricle

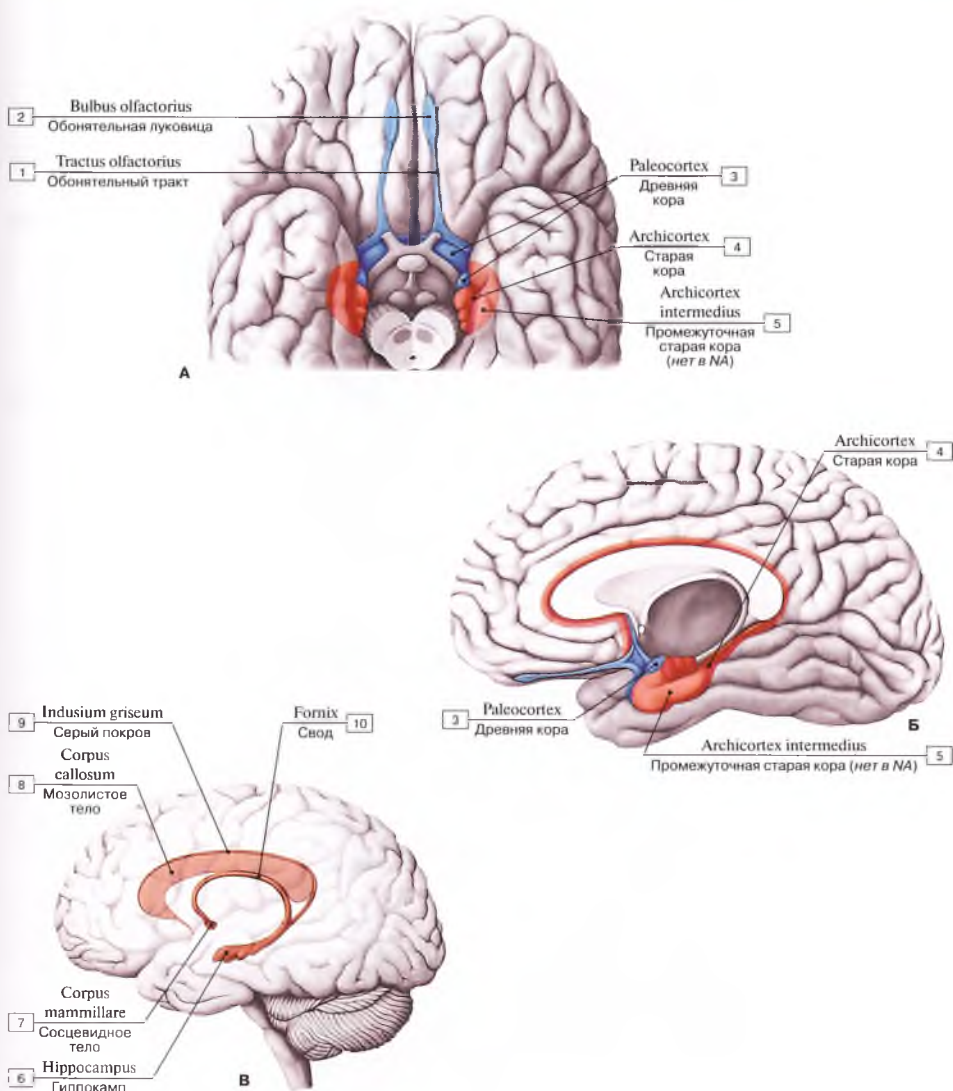


Рис. 38. Аллокортекс (А – основание мозга; Б – медиальная поверхность правого полушария; В – архипаллиум, вид сбоку):

1 – Olfactory tract; 2 – Olfactory bulb; 3 – Paleocortex; 4 – Archicortex; 5 – Intermediate archicortex; 6 – Hippocampus; 7 – Mammillary body; 8 – Corpus callosum; 9 – Indisium griseum; 10 – Fornix

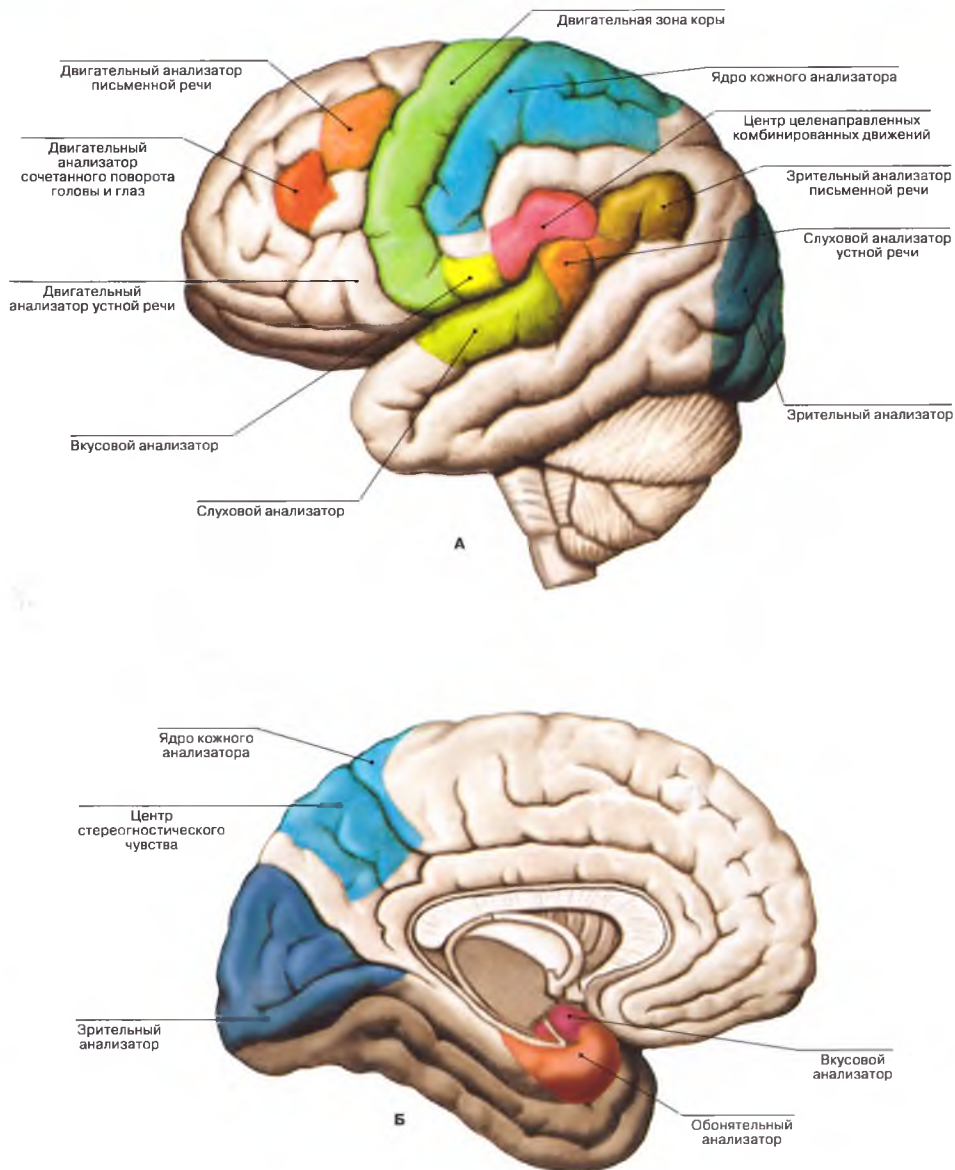


Рис. 39. Локализация функций в коре полушарий большого мозга (А – верхнелатеральная поверхность; Б – медиальная и нижняя поверхности)

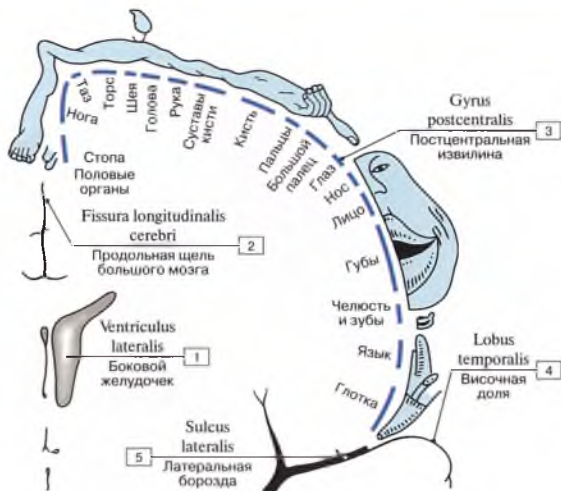


Рис. 40. Проекция чувствительных зон в коре постцентральной извилины полушарий большого мозга (чувствительный «гомункулус»);

1 – Lateral ventricle; 2 – Longitudinal cerebral fissure; 3 – Postcentral gyrus; 4 – Temporal lobe; 5 – Lateral sulcus (из В. Пенфилда и И. Расмуссена)

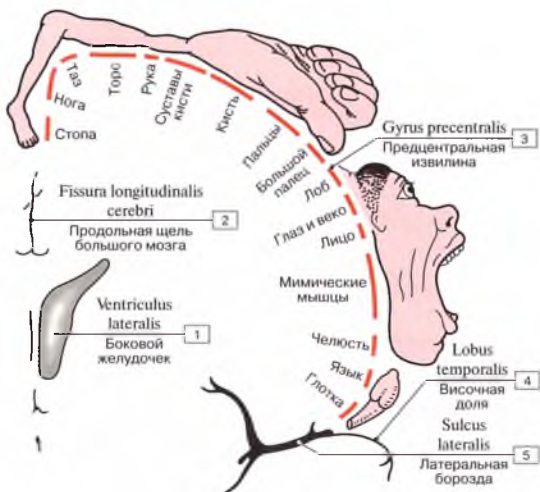


Рис. 41. Проекция двигательных зон в коре постцентральной извилины полушарий большого мозга (двигательный «гомункулус»);

1 – Lateral ventricle; 2 – Longitudinal cerebral fissure; 3 – Precentral gyrus; 4 – Temporal lobe; 5 – Lateral sulcus (из В. Пенфилда и И. Расмуссена)

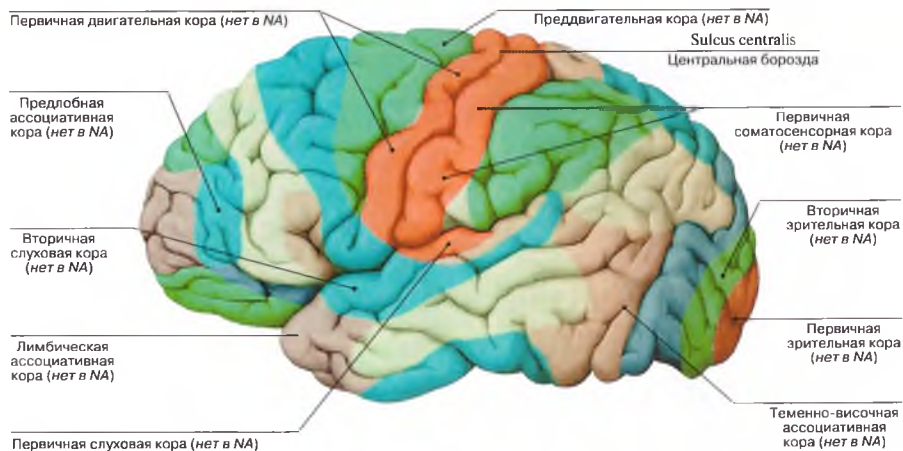


Рис. 42. Функциональные области коры

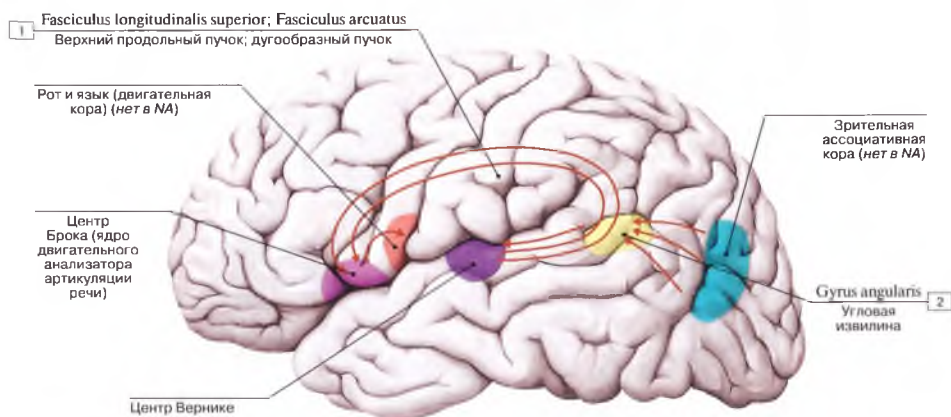


Рис. 43. Речевые центры коры, вид сбоку:

1 – Superior longitudinal fasciculus; Arcuate fasciculus; 2 – Angular gyrus



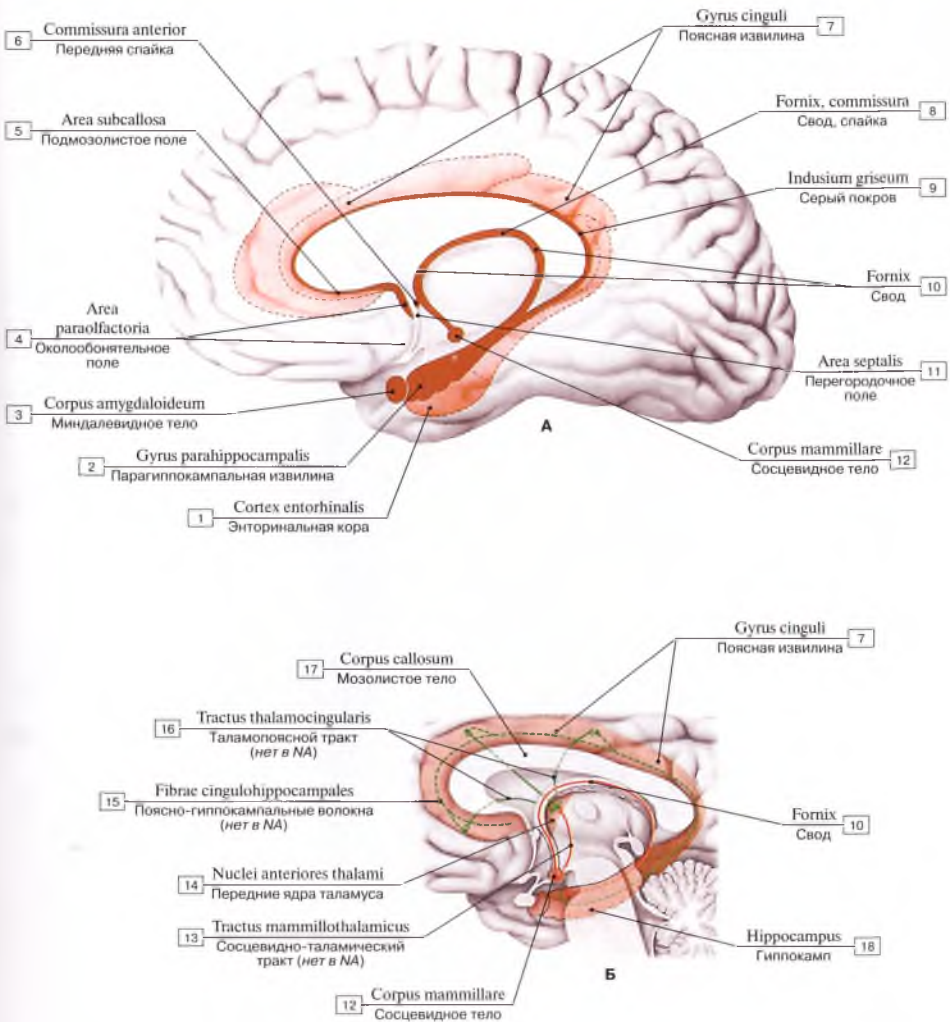


Рис. 44. Лимбическая система (А – схема; Б – нейронный круг (круг Пейпса):

1 – Entorhinal cortex; 2 – Parahippocampal gyrus; 3 – Amygdaloid body; Amygdaloid complex; 4 – Para-olfactory area; 5 – Subcallosal area; Subcallosal gyrus; 6 – Anterior commissure; 7 – Cingulate gyrus; 8 – Fornix, commissure; 9 – Indusium griseum; 10 – Fornix; 11 – Septal area; 12 – Mammillary body; 13 – Mamillothalamic tract; 14 – Anterior nuclei of thalamus; 15 – Cingulo-hippocampal fibres; 16 – Thalamocingular tract; 17 – Corpus callosum; 18 – Hippocampus

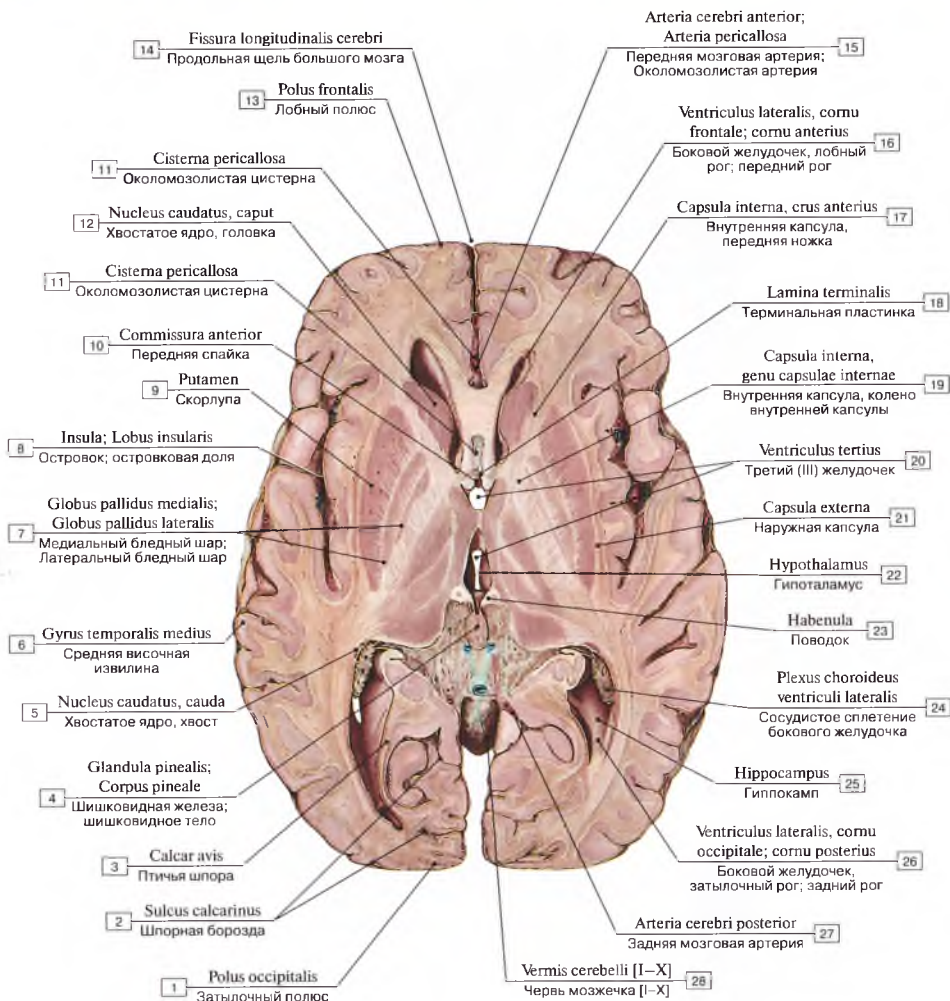
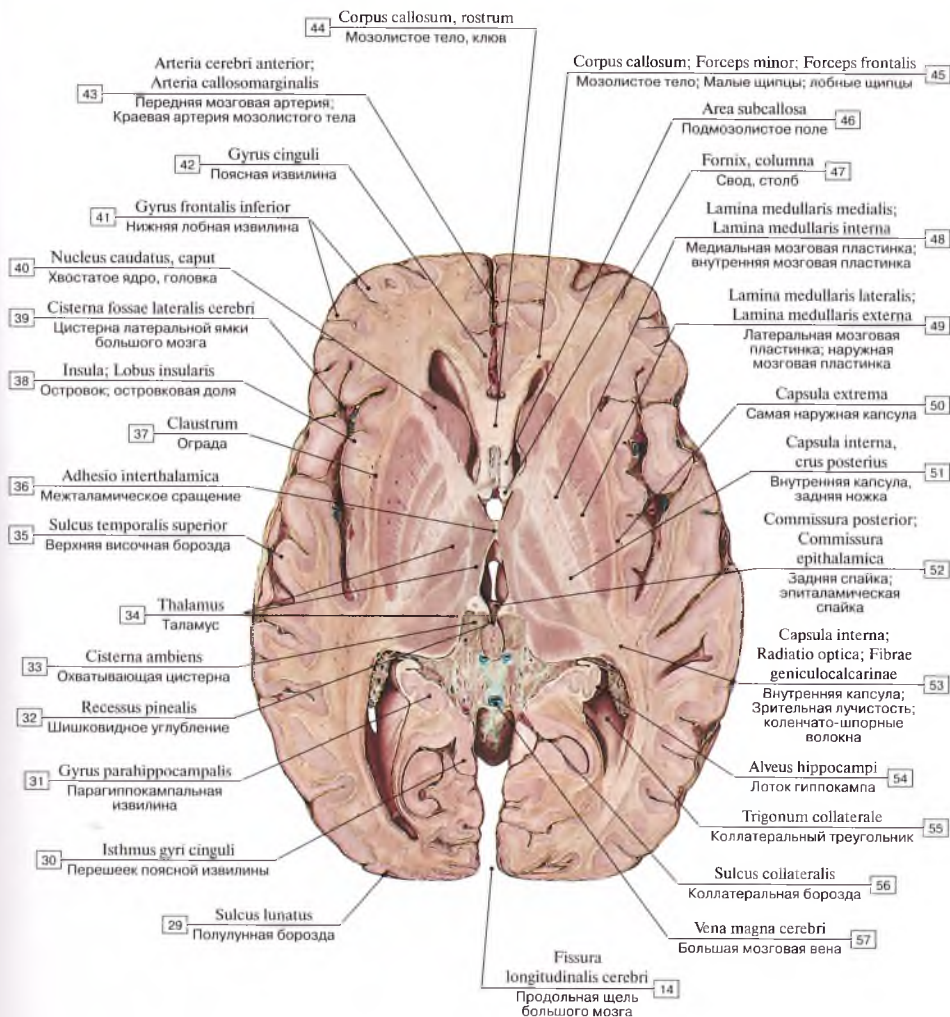


Рис. 45. Базальные ядра, горизонтальный разрез мозга через третий желудочек на уровне межталамической спайки:

1 – Occipital pole; 2 – Calcarine sulcus; 3 – Calcarine spur; 4 – Pineal gland; 5 – Caudate nucleus, tail; 6 – Middle temporal gyrus; 7 – Globus pallidus medial segment; Globus pallidus internal segment; Globus pallidus lateral segment; Globus pallidus external segment; 8 – Insula; Insular lobe; 9 – Putamen; 10 – Anterior commissure; 11 – Pericallosal cistern; 12 – Caudate nucleus, head; 13 – Frontal pole; 14 – Longitudinal cerebral fissure; 15 – Anterior cerebral artery; Pericallosal artery; 16 – Lateral ventricle, frontal horn; anterior horn; 17 – Internal capsule, anterior limb; 18 – Lamina terminalis; 19 – Internal capsule, genu of internal capsule; 20 – Third ventricle; 21 – External capsule; 22 – Hypothalamus; 23 – Habenula; 24 – Choroid plexus of lateral ventricle; 25 – Hippocampus;



26 – Lateral ventricle, occipital horn; posterior horn; 27 – Posterior cerebral artery; 28 – Vermis of cerebellum [I–X]; 29 – Lunate sulcus; 30 – Isthmus of cingulate gyrus; 31 – Parahippocampal gyrus; 32 – Pineal recess; 33 – Cisterna ambiens; Ambient cistern; 34 – Thalamus; Dorsal thalamus; 35 – Superior temporal sulcus; 36 – Interthalamic adhesion; Massa intermedia; 37 – Claustrum; 38 – Insula; Insular lobe; 39 – Cistern of lateral cerebral fossa; 40 – Caudate nucleus, head; 41 – Inferior frontal gyrus; 42 – Cingulate gyrus; 43 – Anterior cerebral artery; Callosomarginal artery; 44 – Corpus callosum, rostrum; 45 – Corpus callosum; Minor forceps; Frontal forceps; 46 – Subcallosal area; Subcallosal gyrus; 47 – Fornix, column; 48 – Medial medullary lamina; Internal medullary lamina; 49 – Lateral medullary lamina; External medullary lamina; 50 – Extreme capsule; 51 – Internal capsule, posterior limb; 52 – Posterior commissure; 53 – Internal capsule; Optic radiation; Geniculocalcarine fibres; 54 – Alveus; 55 – Collateral trigone; 56 – Collateral sulcus; 57 – Great cerebral vein

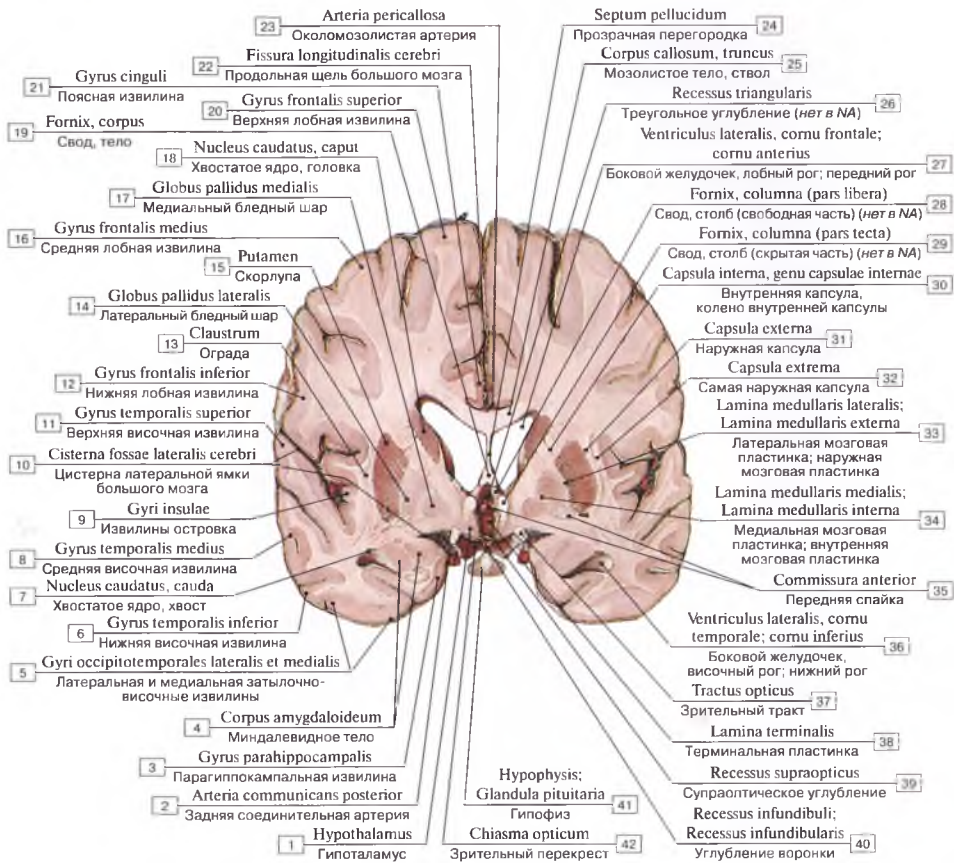


Рис. 46. Базальные ядра, фронтальный разрез мозга на уровне межжелудочкового отверстия:

1 – Hypothalamus; 2 – Posterior communicating artery; 3 – Parahippocampal gyrus; 4 – Amygdaloid body; Amygdaloid complex; 5 – Lateral and medial occipitotemporal gyri; 6 – Inferior temporal gyrus; 7 – Caudate nucleus, tail; 8 – Middle temporal gyrus; 9 – Insular gyri; 10 – Cistern of lateral cerebral fossa; 11 – Superior temporal gyrus; 12 – Inferior frontal gyrus; 13 – Claustrum; 14 – Globus pallidus lateral segment; Globus pallidus external segment; 15 – Putamen; 16 – Middle frontal gyrus; 17 – Globus pallidus medial segment; Globus pallidus internal segment; 18 – Caudate nucleus, head; 19 – Fornix, body; 20 – Superior frontal gyrus; 21 – Cingulate gyrus; 22 – Longitudinal cerebral fissure; 23 – Pericallosal artery; 24 – Septum pellucidum; 25 – Corpus callosum, body; 26 – Triangular recess; 27 – Lateral ventricle, frontal horn; anterior horn; 28 – Fornix, column (free part); 29 – Fornix, column (hidden part); 30 – Internal capsule, genu of internal capsule; 31 – External capsule; 32 – Extreme capsule; 33 – Lateral medullary lamina; External medullary lamina; 34 – Medial medullary lamina; Internal medullary lamina; 35 – Anterior commissure; 36 – Lateral ventricle, temporal horn; inferior horn; 37 – Optic tract; 38 – Lamina terminalis; 39 – Supra-optic recess; 40 – Infundibular recess; 41 – Pituitary gland; 42 – Optic chiasm; Optic chiasm

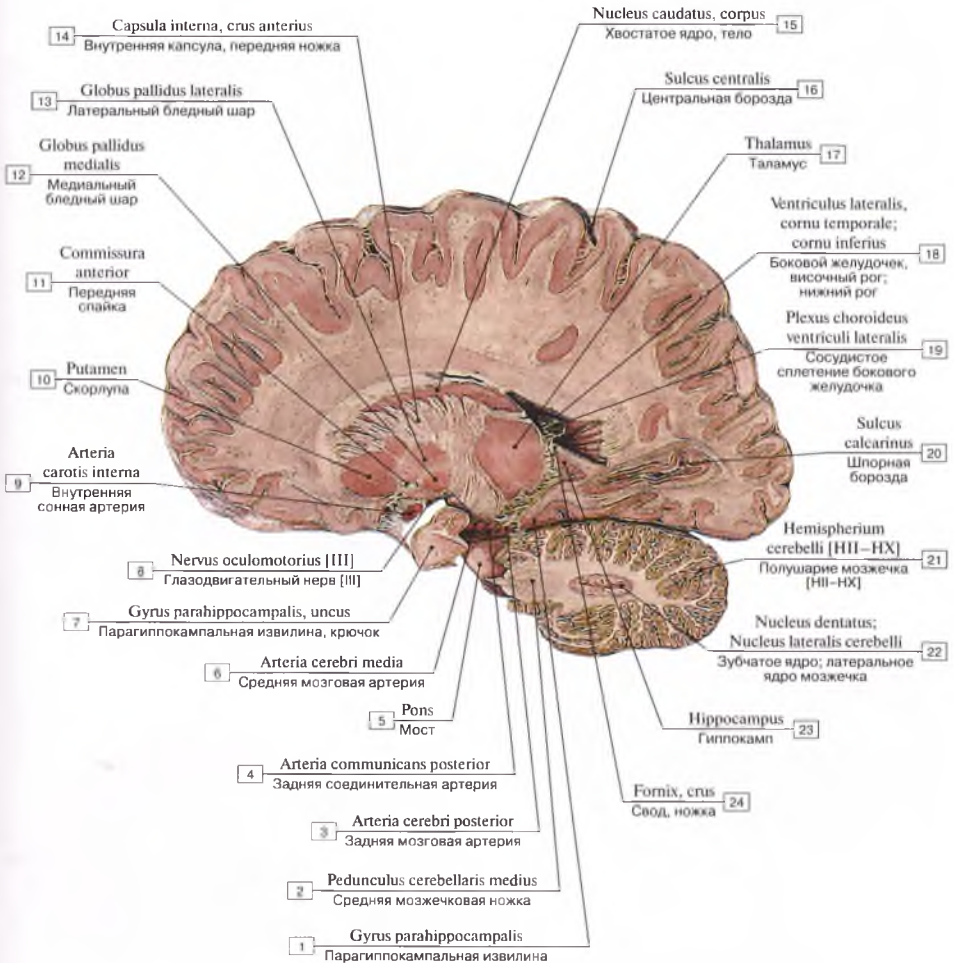


Рис. 47. Базальные ядра, сагиттальный разрез левого полушария на уровне тела хвостатого ядра:

1 – Parahippocampal gyrus; 2 – Middle cerebellar peduncle; 3 – Posterior cerebral artery; 4 – Posterior communicating artery; 5 – Pons; 6 – Middle cerebral artery; 7 – Parahippocampal gyrus, uncus; 8 – Oculomotor nerve [III]; 9 – Internal carotid artery; 10 – Putamen; 11 – Anterior commissure; 12 – Globus pallidus medial segment; Globus pallidus internal segment; 13 – Globus pallidus lateral segment; Globus pallidus external segment; 14 – Internal capsule, anterior limb; 15 – Caudate nucleus, body; 16 – Central sulcus; 17 – Thalamus; Dorsal thalamus; 18 – Lateral ventricle, temporal horn; inferior horn; 19 – Choroid plexus of lateral ventricle; 20 – Calcarine sulcus; 21 – Hemisphere of cerebellum [HII–HX]; 22 – Dentate nucleus; Nucleus lateralis cerebelli; 23 – Hippocampus; 24 – Fornix, crus

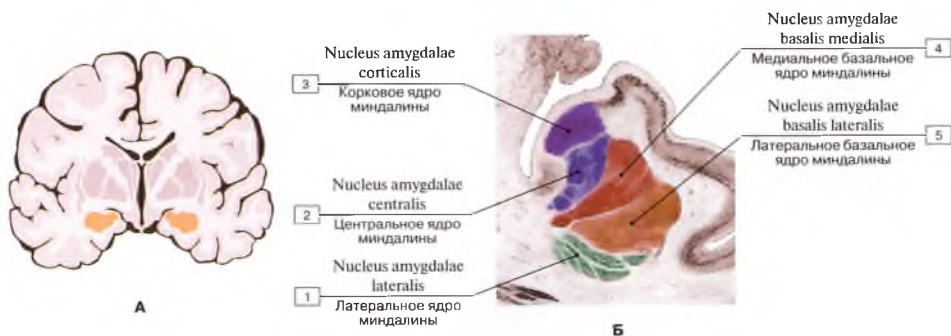


Рис. 48. Миндалевидное тело (А – фронтальный разрез на уровне межжелудочкового отверстия; Б – структуры миндалевидного тела):

1 – Lateral amygdaloid nucleus; 2 – Central amygdaloid nucleus; 3 – Cortical amygdaloid nucleus; 4 – Basomedial amygdaloid nucleus; 5 – Basolateral amygdaloid nucleus

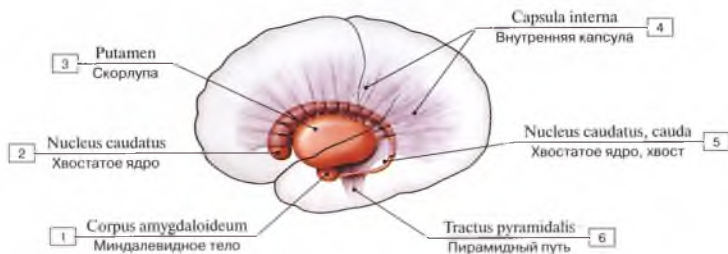


Рис. 49. Взаимоотношения миндалевидного тела с другими структурами мозга:

1 – Amygdaloid body; Amygdaloid complex; 2 – Caudate nucleus; 3 – Putamen; 4 – Internal capsule; 5 – Caudate nucleus, tail; 6 – Pyramidal tract

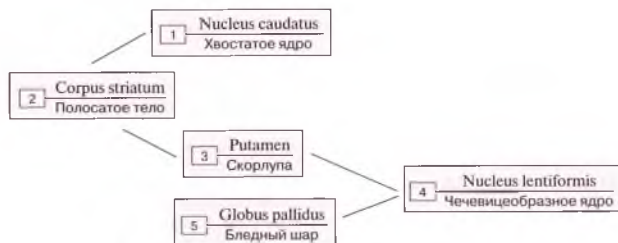


Рис. 50. Взаимоотношения полосатого тела и чечевицеобразного ядра:

1 – Caudate nucleus; 2 – Corpus striatum; 3 – Putamen; 4 – Lentiform nucleus; 5 – Globus pallidus

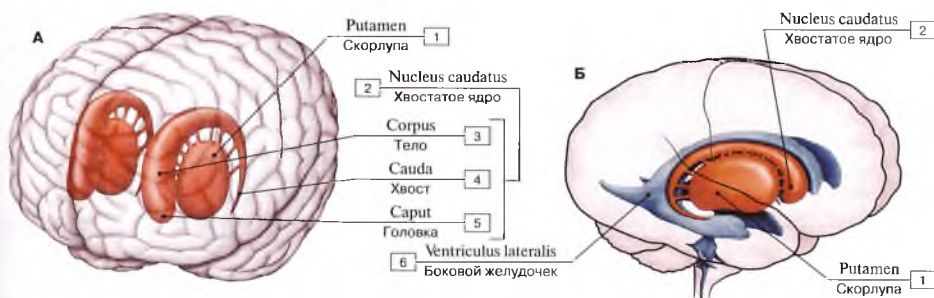


Рис. 51. Проекция базальных ядер на поверхность мозга и систему желудочков (схемы)  
(А – общий вид; Б – хвостатое ядро и скорлупа):

1 – Putamen; 2 = 3 + 4 + 5 – Caudate nucleus; 3 – Body; 4 – Tail; 5 – Head; 6 – Lateral ventricle

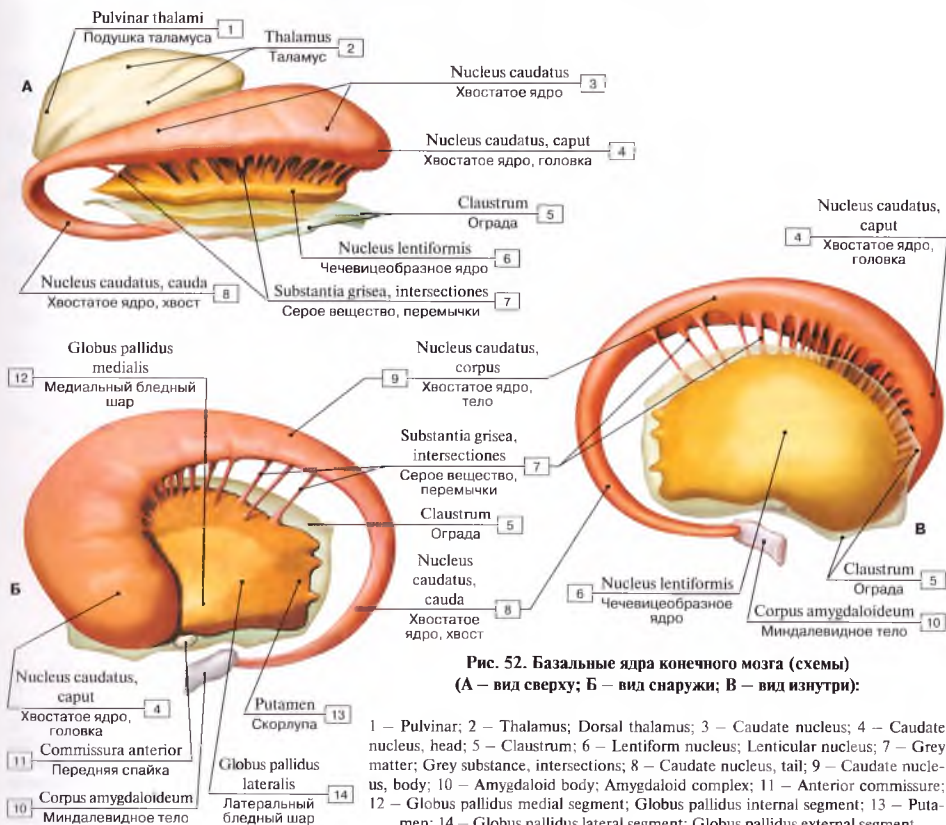


Рис. 52. Базальные ядра конечного мозга (схемы)  
(А – вид сверху; Б – вид снаружи; В – вид изнутри):

1 – Pulvinar; 2 – Thalamus; Dorsal thalamus; 3 – Caudate nucleus; 4 – Caudate nucleus, head; 5 – Claustrum; 6 – Lentiform nucleus; Lenticular nucleus; 7 – Grey matter; Grey substance, intersecciones; 8 – Caudate nucleus, tail; 9 – Caudate nucleus, body; 10 – Amygdaloid body; Amygdaloid complex; 11 – Anterior commissure; 12 – Globus pallidus medial segment; Globus pallidus internal segment; 13 – Putamen; 14 – Globus pallidus lateral segment; Globus pallidus external segment

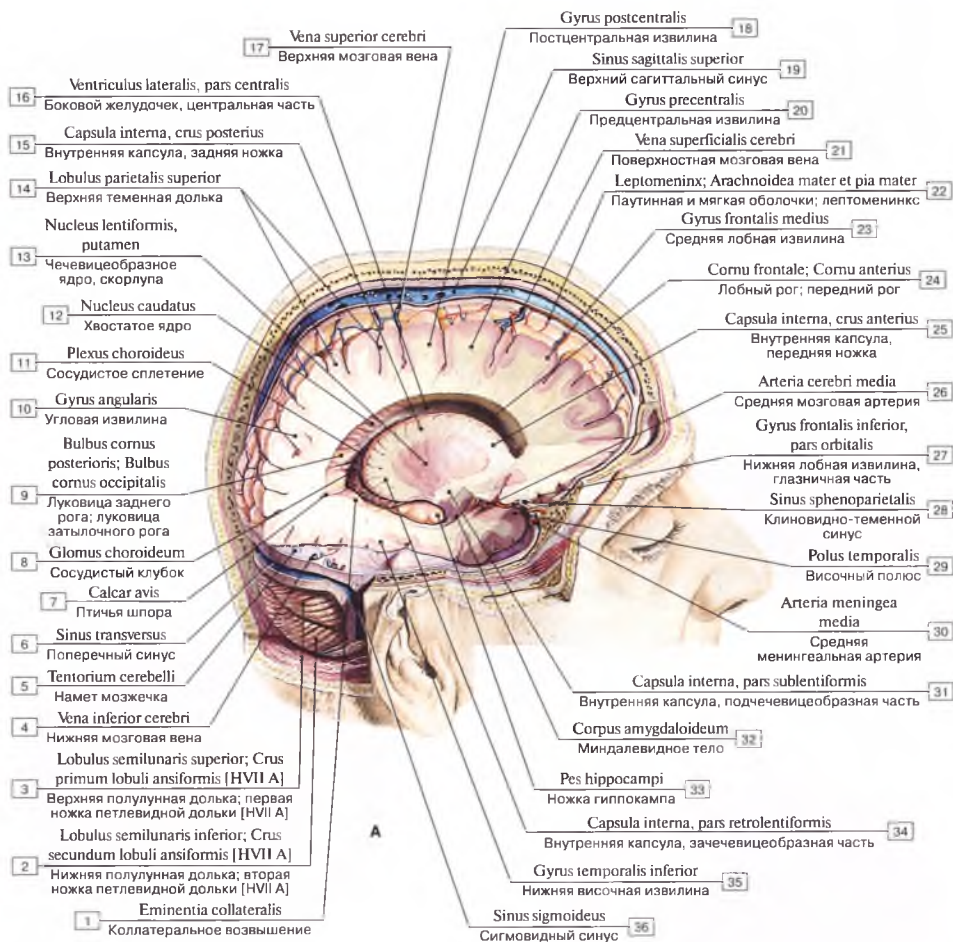
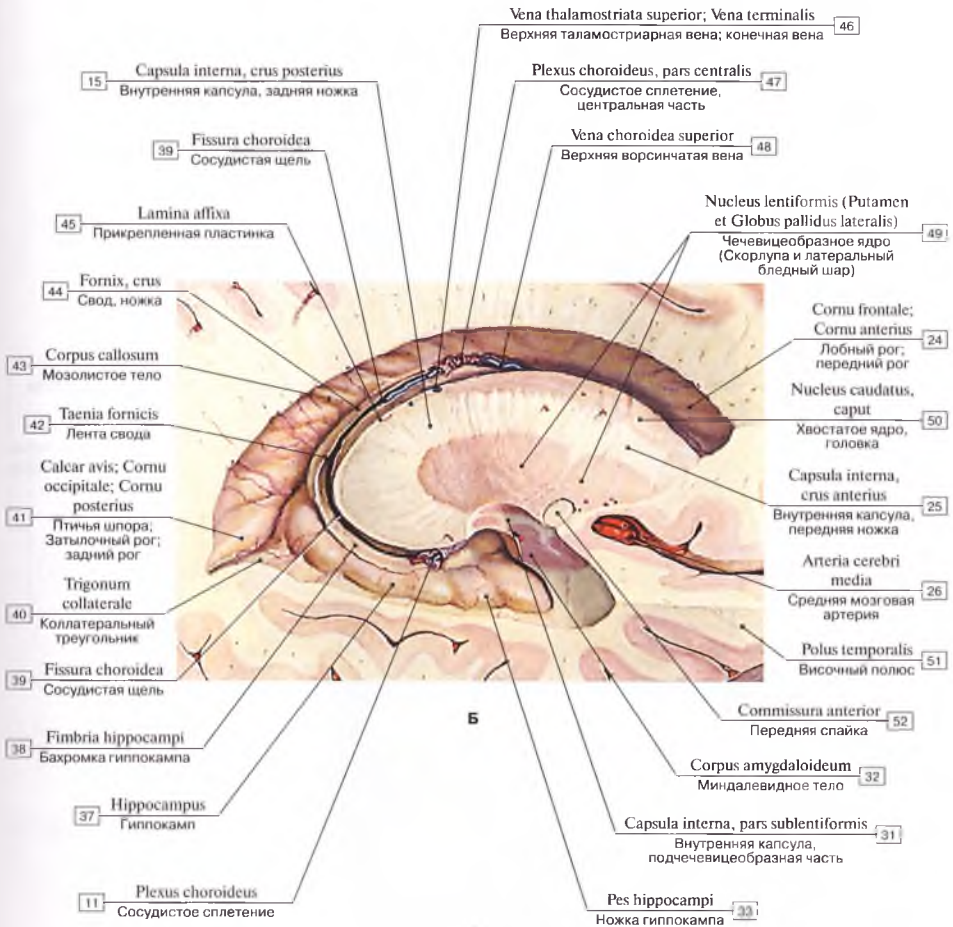


Рис. 53. Головной мозг, вид изнутри сбоку, правый боковой желудочек (А);  
сосудистое сплетение частично удалено (Б):

1 – Collateral eminence; 2 – Inferior semilunar lobule; Second crus of ansiform lobule [HVII A]; 3 – Superior semilunar lobule; First crus of ansiform lobule [HVII A]; 4 – Inferior cerebral vein; 5 – Tentorium cerebelli; Cerebellar tentorium; 6 – Transverse sinus; 7 – Calcarine spur; 8 – Choroid enlargement; 9 – Bulb of posterior horn; Bulb of occipital horn; 10 – Angular gyrus; 11 – Choroid plexus; 12 – Caudate nucleus; 13 – Lentiform nucleus; Lenticular nucleus, putamen; 14 – Superior parietal lobule; 15 – Internal capsule, posterior limb; 16 – Lateral ventricle, central part; 17 – Superior cerebral vein; 18 – Postcentral gyrus; 19 – Superior sagittal sinus;





- 20 – Precentral gyrus; 21 – Superficial cerebral vein; 22 – Leptomeninx; Arachnoid mater and pia mater; 23 – Middle frontal gyrus; 24 – Frontal horn; Anterior horn; 25 – Internal capsule, anterior limb; 26 – Middle cerebral artery; 27 – Inferior frontal gyrus, orbital part; 28 – Sphenoparietal sinus; 29 – Temporal pole; 30 – Middle meningeal artery; 31 – Internal capsule, sublentiform part; sublenticular part; 32 – Amygdaloid complex; Amygdaloid body; 33 – Pes of hippocampus; 34 – Internal capsule, retrolentiform part; retrolenticular part; 35 – Inferior temporal gyrus; 36 – Sigmoid sinus; 37 – Hippocampus; 38 – Fimbria of hippocampus; 39 – Choroidal fissure; 40 – Collateral trigone; 41 – Calcarine spur; Occipital horn; Posterior horn; 42 – Taenia of fornix; 43 – Corpus callosum; 44 – Fornix, crus; 45 – Lamina affixa; 46 – Superior thalamostriate vein; Terminal vein; 47 – Choroid plexus, central part; body; 48 – Superior choroid vein; 49 – Lentiform nucleus; Lenticular nucleus (Putamen and Globus pallidus lateral segment; Globus pallidus external segment); 50 – Caudate nucleus, head; 51 – Temporal pole; 52 – Anterior commissure

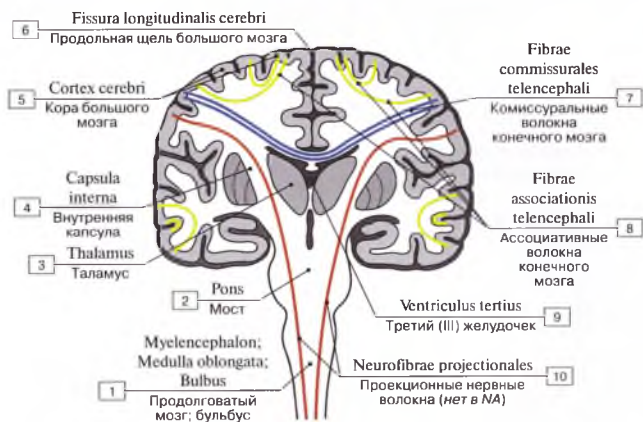


Рис. 54. Положение ассоциативных, комиссуральных и проекционных проводящих путей в головном мозге человека (схема):

1 – Myelencephalon; Medulla oblongata; Bulb; 2 – Pons; 3 – Thalamus; Dorsal thalamus; 4 – Internal capsule; 5 – Cerebral cortex; 6 – Longitudinal cerebral fissure; 7 – Commissural fibres of telencephalon; 8 – Association fibres of telencephalon; 9 – Third ventricle; 10 – Projection nerve fibres

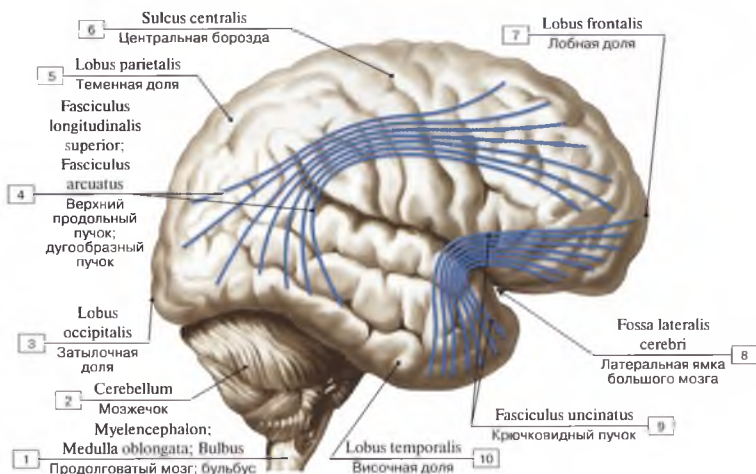


Рис. 55. Ассоциативные пути, верхнелатеральная поверхность правого полушария (проекция волокон на поверхность полушария) (схема):

1 – Myelencephalon; Medulla oblongata; Bulb; 2 – Cerebellum; 3 – Occipital lobe; 4 – Superior longitudinal fasciculus; Arcuate fasciculus; 5 – Parietal lobe; 6 – Central sulcus; 7 – Frontal lobe; 8 – Lateral cerebral fossa; 9 – Uncinate fasciculus; 10 – Temporal lobe

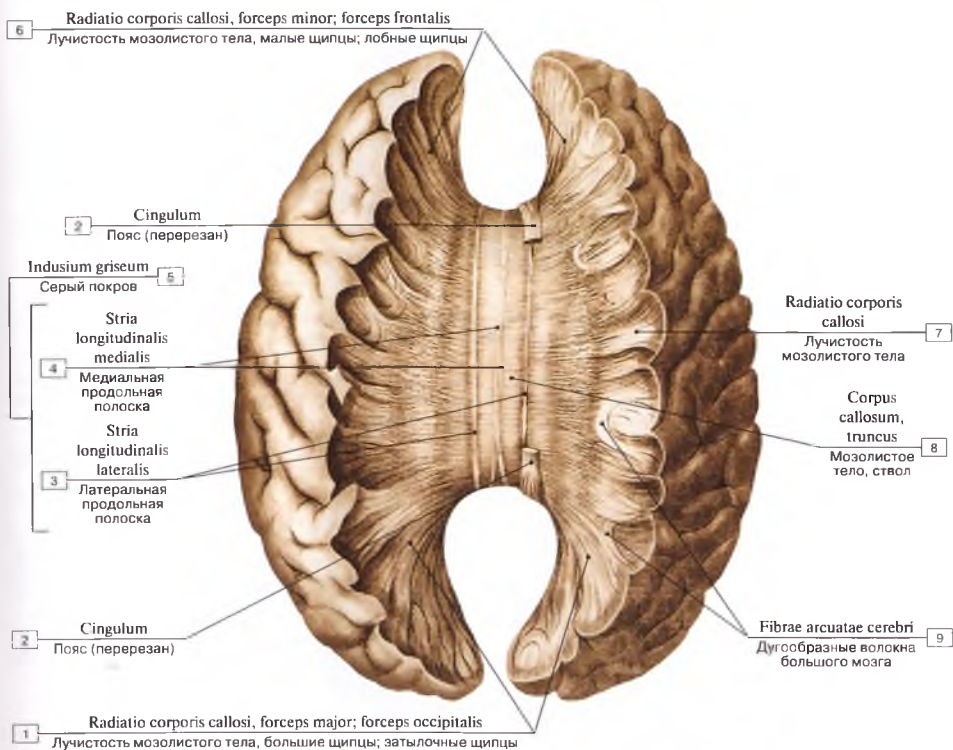


Рис. 56. Мозолистое тело и лучистость мозолистого тела, вид сверху:

1 – Radiation of corpus callosum, major forceps; occipital forceps; 2 – Cingulum; 3 – Lateral longitudinal stria; 4 – Medial longitudinal stria; 5 = 3 + 4 – Indisium griseum; 6 – Radiation of corpus callosum, minor forceps; frontal forceps; 7 – Radiation of corpus callosum; 8 – Corpus callosum, body; trunk; 9 – Arcuate fibres

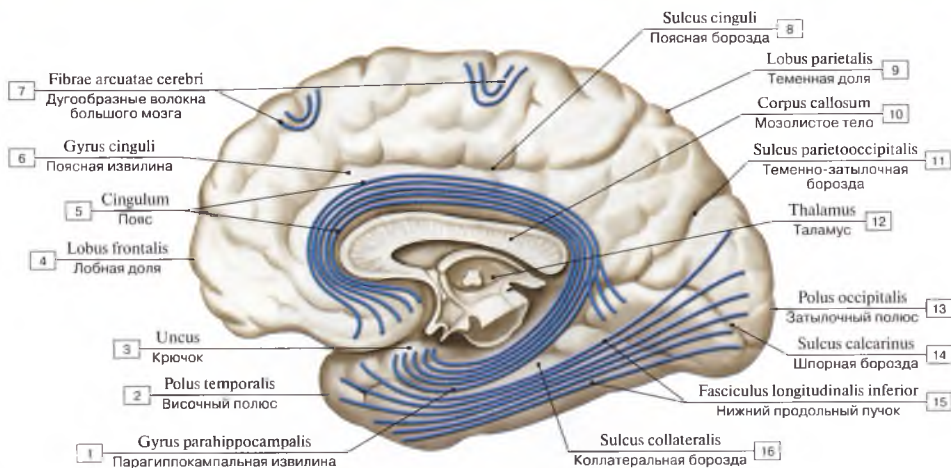


Рис. 57. Ассоциативные волокна, медиальная поверхность правого полушария (проекция волокон на поверхность полушария) (схема):

1 - Parahippocampal gyrus; 2 - Temporal pole; 3 - Uncus; 4 - Frontal lobe; 5 - Cingulum; 6 - Cingulate gyrus; 7 - Arcuate fibres; 8 - Cingulate sulcus; 9 - Parietal lobe; 10 - Corpus callosum; 11 - Parieto-occipital sulcus; 12 - Thalamus; Dorsal thalamus; 13 - Occipital pole; 14 - Calcarine sulcus; 15 - Inferior longitudinal fasciculus; 16 - Collateral sulcus

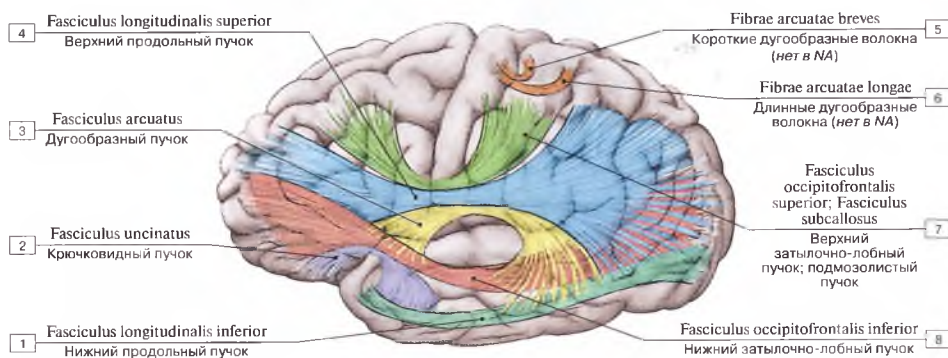
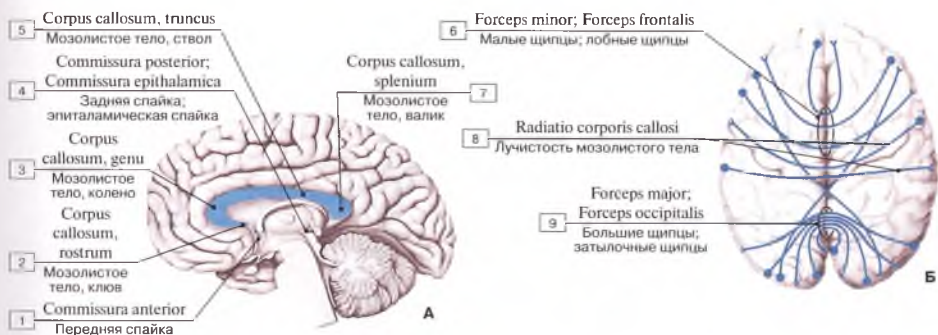


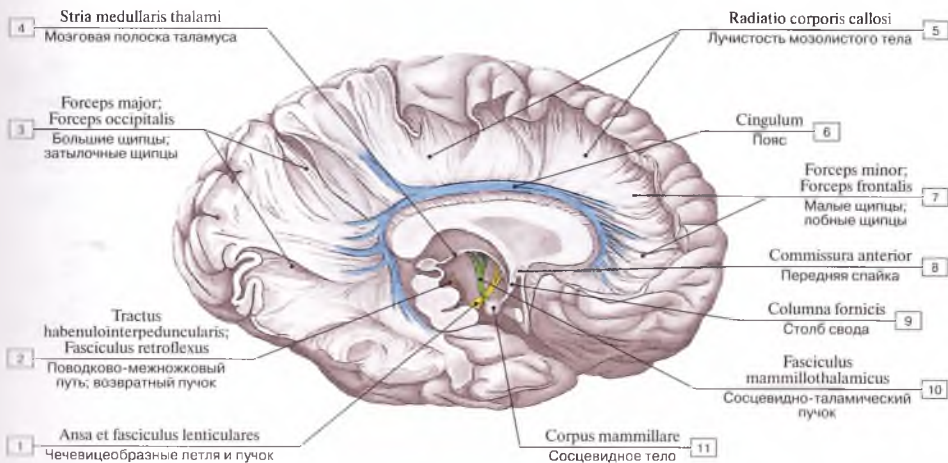
Рис. 58. Ассоциативные волокна:

1 - Inferior longitudinal fasciculus; 2 - Uncinate fasciculus; 3 - Arcuate fasciculus; 4 - Superior longitudinal fasciculus; 5 - Short arcuate fibres; 6 - Long arcuate fibres; 7 - Superior occipitofrontal fasciculus; Subcallosal fasciculus; 8 - Inferior occipitofrontal fasciculus



**Рис. 59. Комиссуральные волокна**  
(А – вид на правое полушарие с медиальной стороны; Б – вид сверху) (схема):

1 – Anterior commissure; 2 – Corpus callosum, rostrum; 3 – Corpus callosum, genu; 4 – Posterior commissure; 5 – Corpus callosum, body (trunk); 6 – Minor forceps; Frontal forceps; 7 – Corpus callosum, splenium; 8 – Radiation of corpus callosum; 9 – Major forceps; Occipital forceps



**Рис. 60. Взаиморасположение комиссуральных волокон (схема):**

1 – Ansa and fasciculus lenticularis; 2 – Habenuol-interpeduncular tract; Fasciculus retroflexus; 3 – Major forceps; Occipital forceps; 4 – Stria medullaris of thalamus; 5 – Radiation of corpus callosum; 6 – Cingulum; 7 – Minor forceps; Frontal forceps; 8 – Anterior commissure; 9 – Column of fornix; 10 – Mammillothalamic fasciculus; 11 – Mammillary body

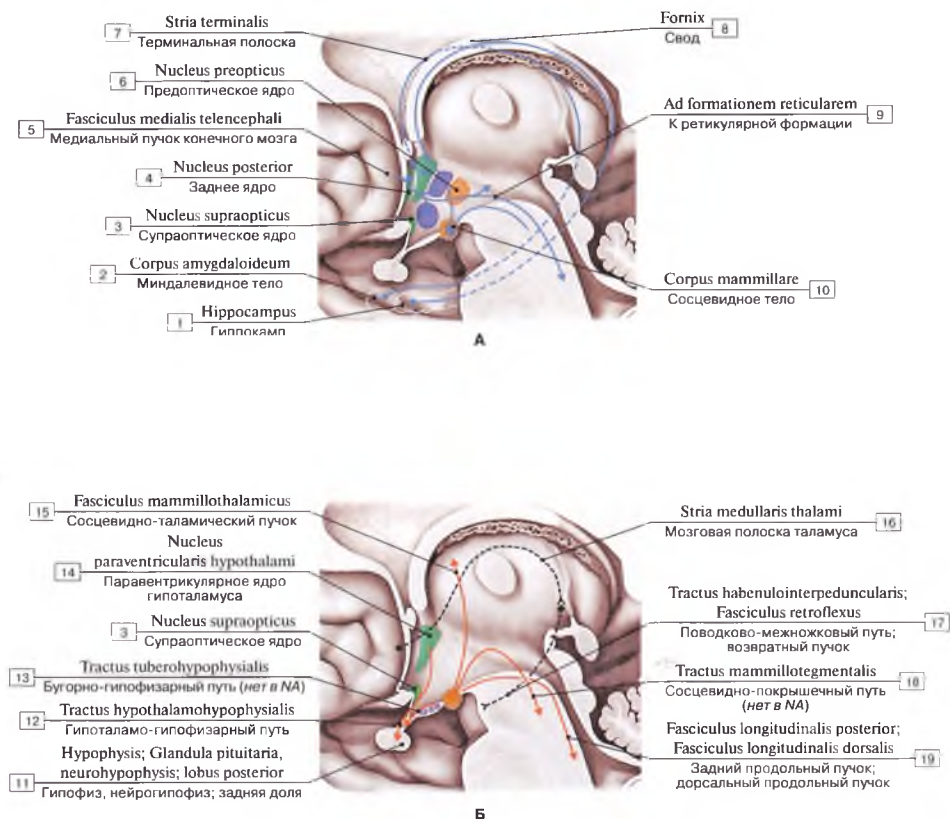


Рис. 61. Взаимосвязи гипоталамуса с другими структурами мозга, среднесагиттальный разрез правого полушария, вид с медиальной стороны (А – афферентные связи (к гипоталамусу); Б – эфферентные связи (от гипоталамуса):

1 – Hippocampus; 2 – Amygdaloid body; Amygdaloid complex; 3 – Supra-optic nucleus; 4 – Posterior nucleus; Dorsal nucleus; 5 – Medial forebrain bundle; 6 – Pre-optic nucleus; 7 – Stria terminalis; 8 – Fornix; 9 – To reticular formation; 10 – Mammillary body; 11 – Pituitary gland, neurohypophysis; Posterior lobe; 12 – Hypothalamohypophysial tract; 13 – Tuberohypophysial tract; 14 – Paraventricular nucleus; 15 – Mammillothalamic fasciculus; 16 – Stria medullaris; 17 – Habenulo-interpeduncular tract; Fasciculus retroflexus; 18 – Mammillotegmental tract; 19 – Posterior longitudinal fasciculus; Dorsal longitudinal fasciculus

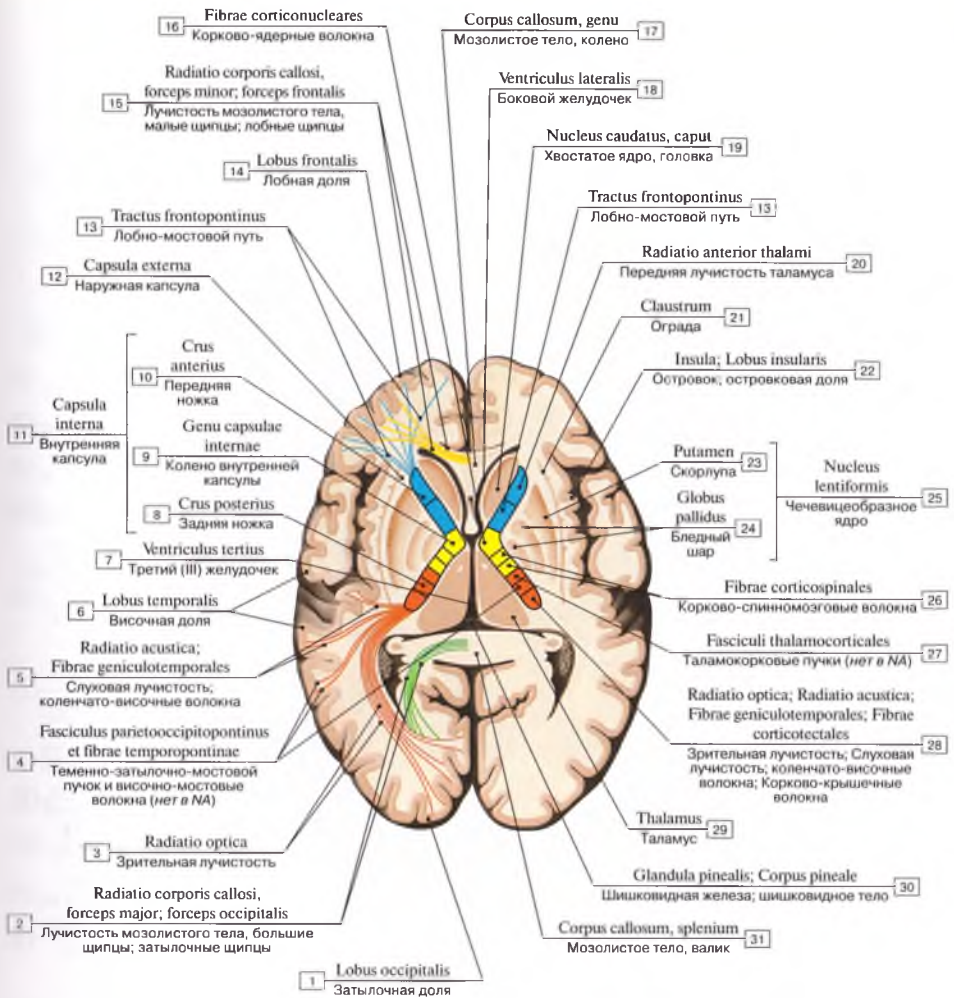


Рис. 62. Внутренняя капсула, горизонтальный разрез мозга на уровне третьего желудочка:

1 – Occipital lobe; 2 – Radiation of corpus callosum, major forceps; occipital forceps; 3 – Optic radiation; 4 – Parieto-occipitopontine fasciculus and Temporopontine fibres; 5 – Acoustic radiation; Genuiculotemporal fibres; 6 – Temporal lobe; 7 – Third ventricle; 8 – Posterior limb; 9 – Genu of internal capsule; 10 – Anterior limb; 11 = 8 + 9 + 10 – Internal capsule; 12 – External capsule; 13 – Frontopontine tract; 14 – Frontal lobe; 15 – Radiation of corpus callosum, minor forceps; frontal forceps; 16 – Corticonuclear fibres; 17 – Corpus callosum, genu; 18 – Lateral ventricle; 19 – Caudate nucleus, head; 20 – Anterior thalamic radiation; 21 – Claustrum; 22 – Insula; Insular lobe; 23 – Putamen; 24 – Globus pallidus; 25 = 23 + 24 – Lentiform nucleus; Lenticular nucleus; 26 – Corticospinal fibres; 27 – Thalamocortical fasciculi; 28 – Optic radiation; Acoustic radiation; Genuiculotemporal fibres; Corticotectal fibres; 29 – Thalamus; Dorsal thalamus; 30 – Pineal gland; Pineal body; 31 – Corpus callosum, splenium

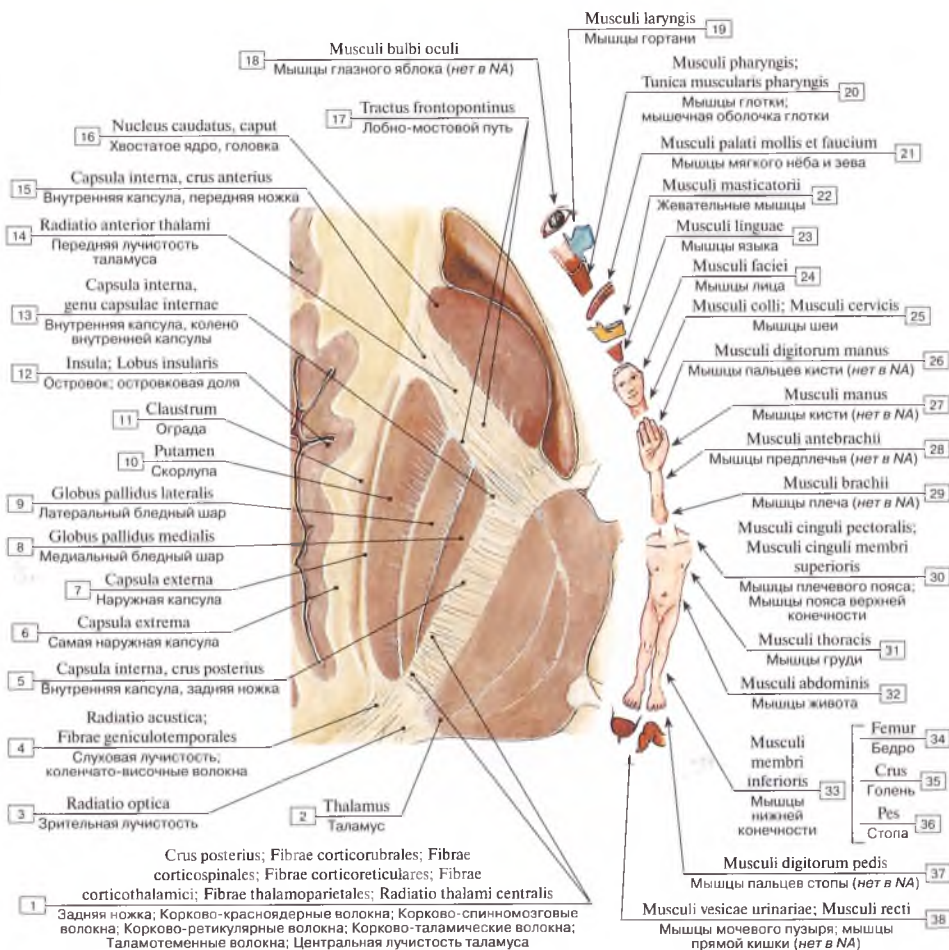


Рис. 63. Внутренняя капсула:

1 – Posterior limb; Corticorubral fibres; Corticospinal fibres; Corticoreticular fibres; Corticothalamic fibres; Thalamoparietal fibres; Central thalamic radiation; 2 – Thalamus; Dorsal thalamus; 3 – Optic radiation; 4 – Acoustic radiation; Genuiculotemporal fibres; 5 – Internal capsule, posterior limb; 6 – Extreme capsule; 7 – External capsule; 8 – Globus pallidus medial segment; Globus pallidus internal segment; 9 – Globus pallidus lateral segment; Globus pallidus external segment; 10 – Putamen; 11 – Claustrum; 12 – Insula; Insular lobe; 13 – Internal capsule, genu of internal capsule; 14 – Anterior thalamic radiation; 15 – Internal capsule, anterior limb; 16 – Caudate nucleus, head; 17 – Frontopontine tract; 18 – Muscles of eyeball; 19 – Laryngeal muscles; 20 – Pharyngeal muscles; Muscle layer of pharynx; 21 – Muscles of soft palate and fauces; 22 – Masticatory muscles; 23 – Muscles of tongue; 24 – Facial muscles; 25 – Muscles of neck; 26 – Muscles of digits of hand; 27 – Muscles of hand; 28 – Muscles of forearm; 29 – Muscles of arm; 30 – Muscles of pectoral girdle; Muscles of shoulder girdle; 31 – Muscles of thorax; 32 – Muscles of abdomen; 33 = 34 + 35 + 36 – Muscles of lower limb; 34 – Thigh; 35 – Leg; 36 – Foot; 37 – Muscles of toes; 38 – Muscles of bladder; Muscles of rectum



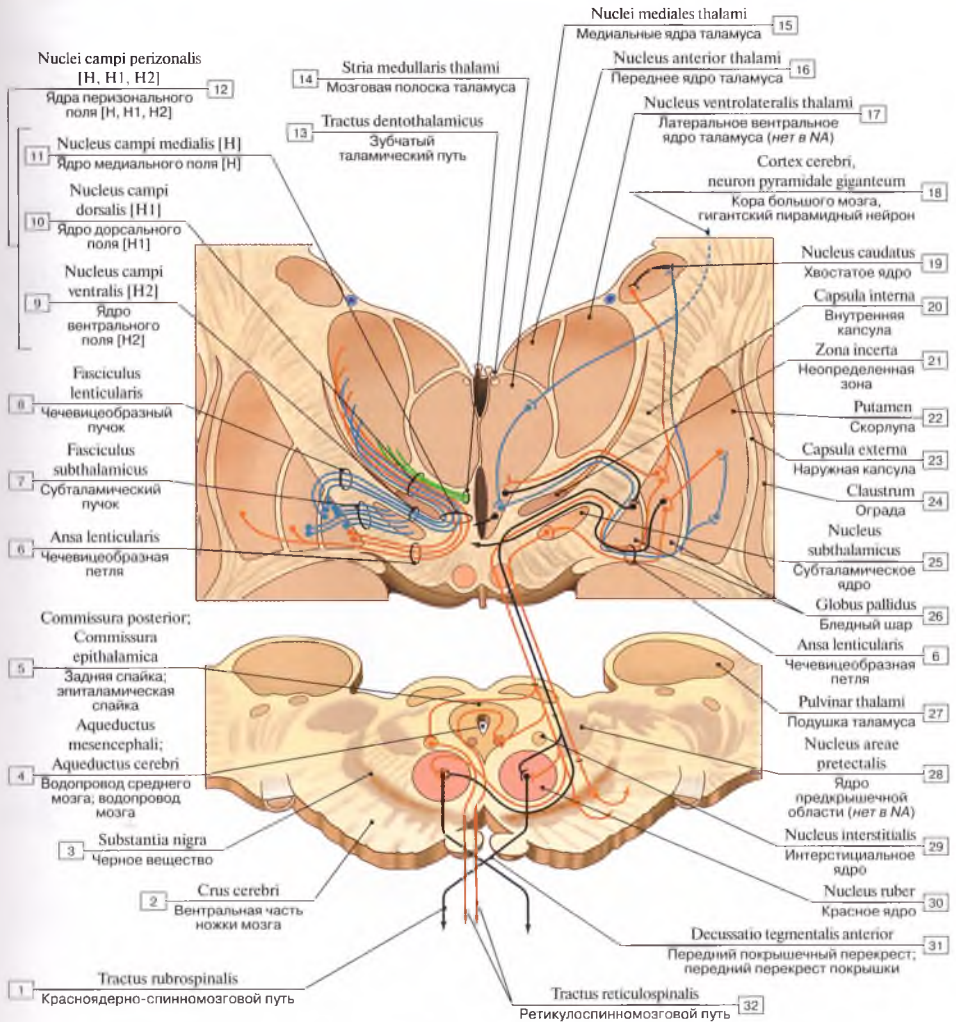


Рис. 64. Проводящие пути внутренней капсулы и ножек мозга (схема):

1 – Rubrospinal tract; 2 – Cerebral crus; 3 – Substantia nigra; 4 – Aqueduct of midbrain; Cerebral aqueduct; 5 – Posterior commissure; 6 – Ansa lenticularis; 7 – Subthalamic fasciculus; 8 – Lenticular fasciculus; 9 – Nucleus of perizonal field [H2]; 10 – Nucleus of perizonal field [H1]; 11 – Nucleus of perizonal field [H]; 12 = 9 + 10 + 11 – Nuclei of perizonal fields [H, H1, H2]; 13 – Dentothalamic tract; 14 – Stria medullaris of thalamus; 15 – Medial nuclei of thalamus; 16 – Anterior nuclei of thalamus; 17 – Nucleus ventrolateral of thalamus; 18 – Cerebral cortex, giant pyramidal neuron; 19 – Caudate nucleus; 20 – Internal capsule; 21 – Zona incerta; 22 – Putamen; 23 – External capsule; 24 – Claustrum; 25 – Subthalamic nucleus; 26 – Globus pallidus; 27 – Pulvinar; 28 – Nucleus of pretectal area; 29 – Interstitial nucleus; 30 – Red nucleus; 31 – Anterior tegmental decussation; Ventral tegmental decussation; 32 – Reticulospinal tract

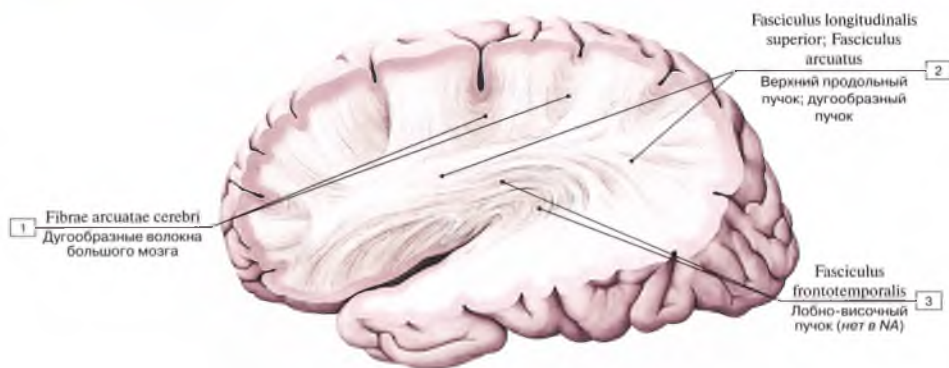


Рис. 65. Белое вещество полушария большого мозга, поверхностный слой:

1 – Arcuate fibres; 2 – Superior longitudinal fasciculus; Arcuate fasciculus; 3 – Frontotemporal fasciculus

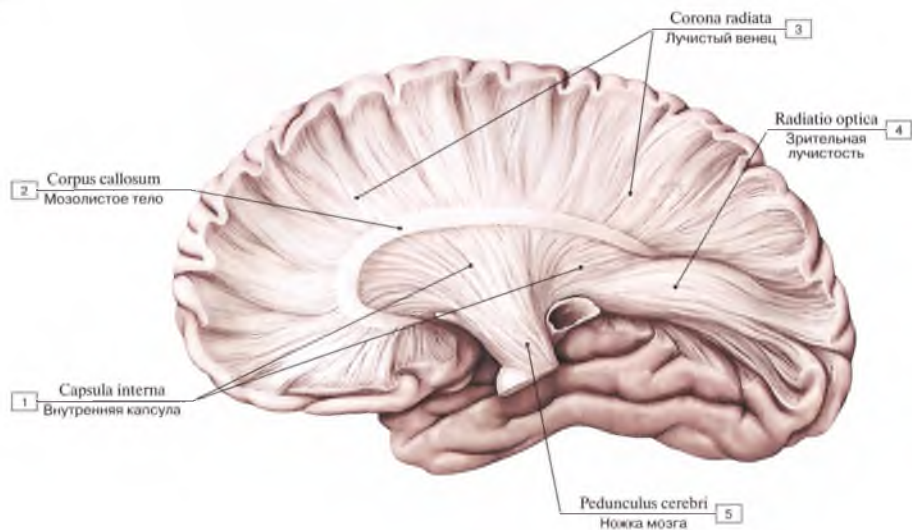


Рис. 66. Белое вещество полушария большого мозга, глубокий слой:

1 – Internal capsule; 2 – Corpus callosum; 3 – Corona radiata; 4 – Optic radiation; 5 – Cerebral peduncle

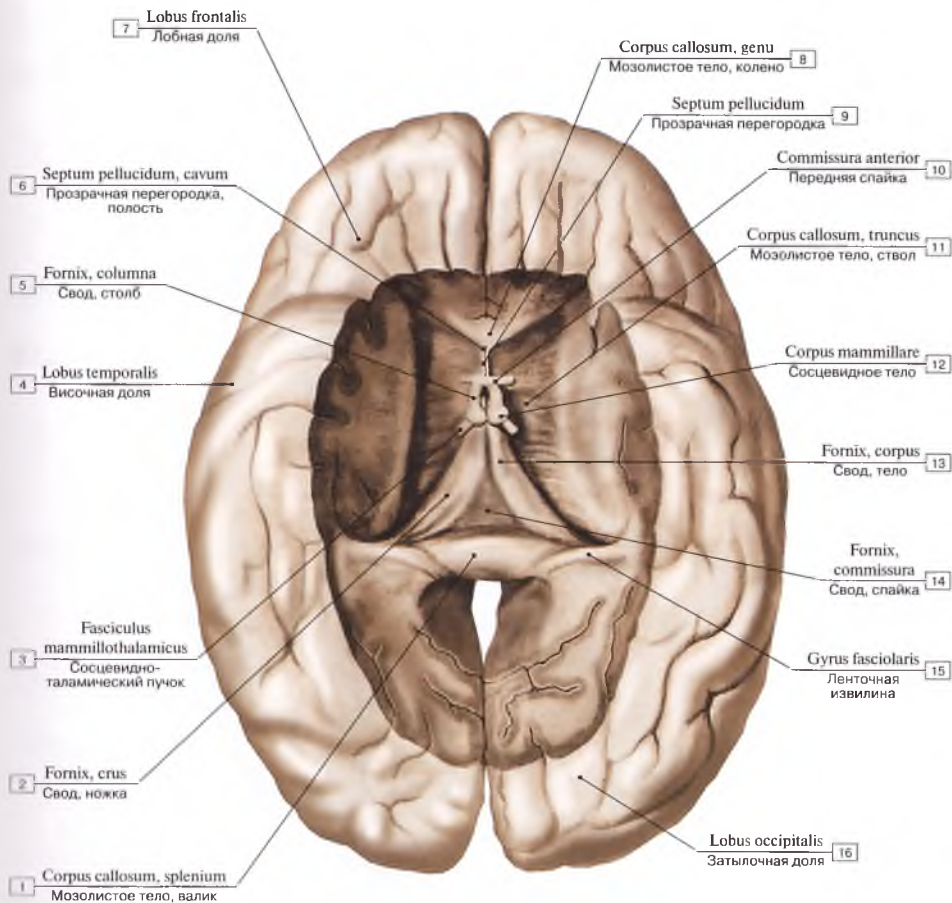


Рис. 67. Мозолистое тело и свод, вид снизу:

1 – Corpus callosum, splenium; 2 – Fornix, crus; 3 – Mamillothalamic fasciculus; 4 – Temporal lobe; 5 – Fornix, column; 6 – Septum pellucidum, cave; 7 – Frontal lobe; 8 – Corpus callosum, genu; 9 – Septum pellucidum; 10 – Anterior commissure; 11 – Corpus callosum, body; trunk; 12 – Mammillary body; 13 – Fornix, body; 14 – Fornix, commissure; 15 – Fasciolar gyrus; 16 – Occipital lobe

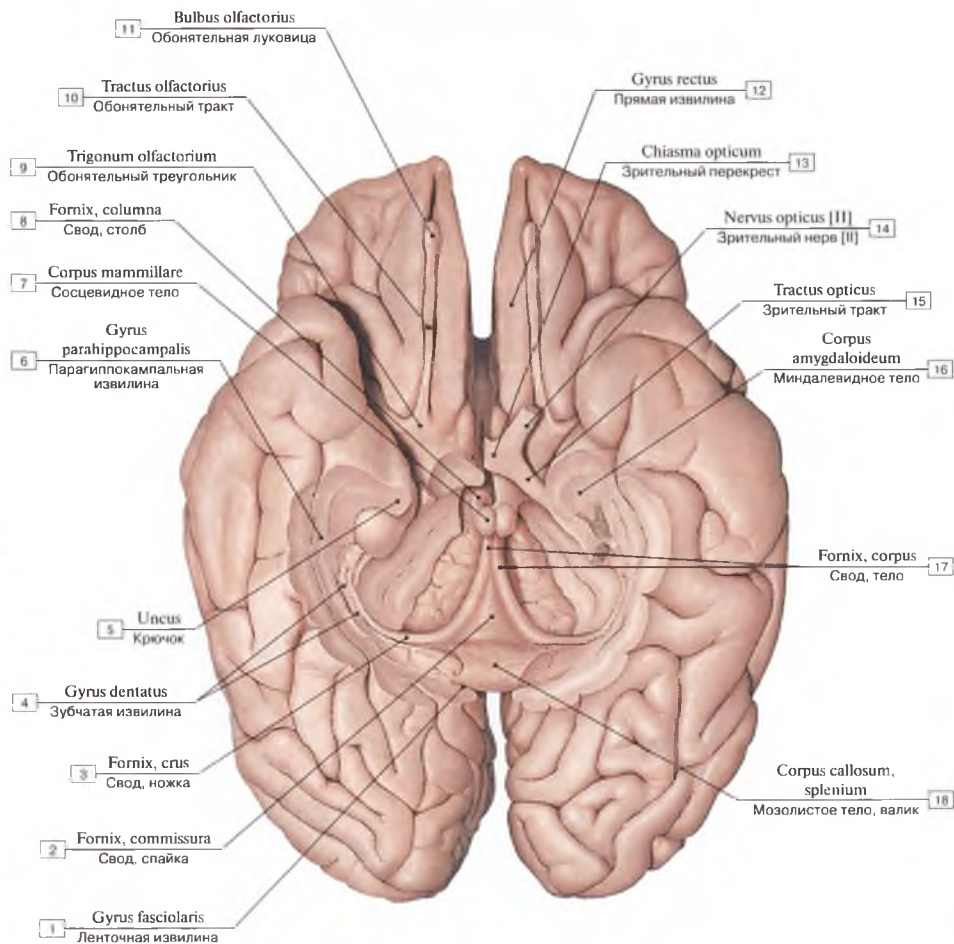


Рис. 68. Свод и гиппокамп, вид снизу:

1 – Fasciolar gyrus; 2 – Fornix, commissure; 3 – Fornix, crus; 4 – Dentate gyrus; 5 – Uncus; 6 – Parahippocampal gyrus; 7 – Mammillary body; 8 – Fornix, column; 9 – Olfactory trigone; 10 – Olfactory tract; 11 – Olfactory bulb; 12 – Straight gyrus; 13 – Optic chiasm; Optic chiasma; 14 – Optic nerve [III]; 15 – Optic tract; 16 – Amygdaloid body; Amygdaloid complex; 17 – Fornix, body; 18 – Corpus callosum, splenium

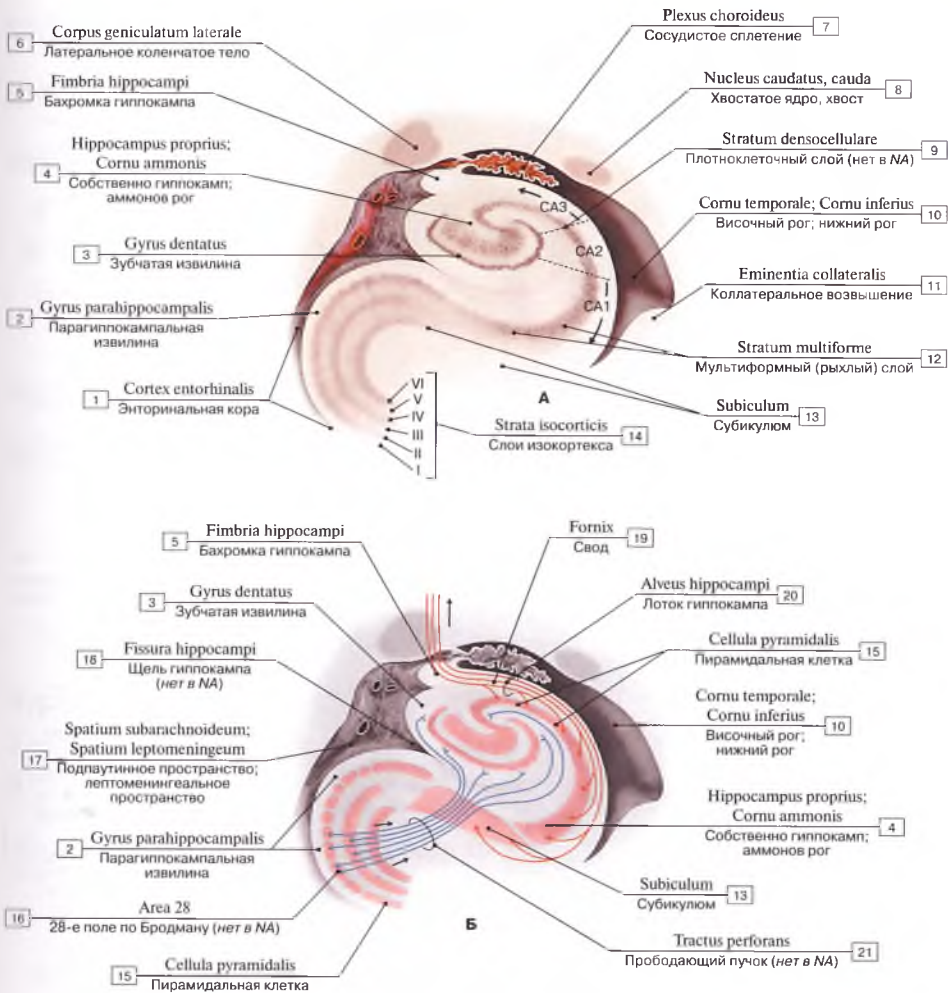


Рис. 69. Гиппокамп, вид спереди слева (А – цитоархитектоника; Б – связи гиппокампа):

1 – Entorhinal cortex; 2 – Parahippocampal gyrus; 3 – Dentate gyrus; 4 – Hippocampus proper; Ammon’s horn; 5 – Fimbria of hippocampus; 6 – Lateral geniculate body; 7 – Choroid plexus; 8 – Caudate nucleus, tail; 9 – Dense cellular layer; 10 – Temporal horn; Inferior horn; 11 – Collateral eminence; 12 – Multifiform layer; 13 – Subiculum; 14 – Layers of isocortex; 15 – Pyramidal cell; 16 – Area 28 (entorhinal region); 17 – Subarachnoid space; Leptomeningeal space; 18 – Fissure; 19 – Fornix; 20 – Alveus; 21 – Perforant path

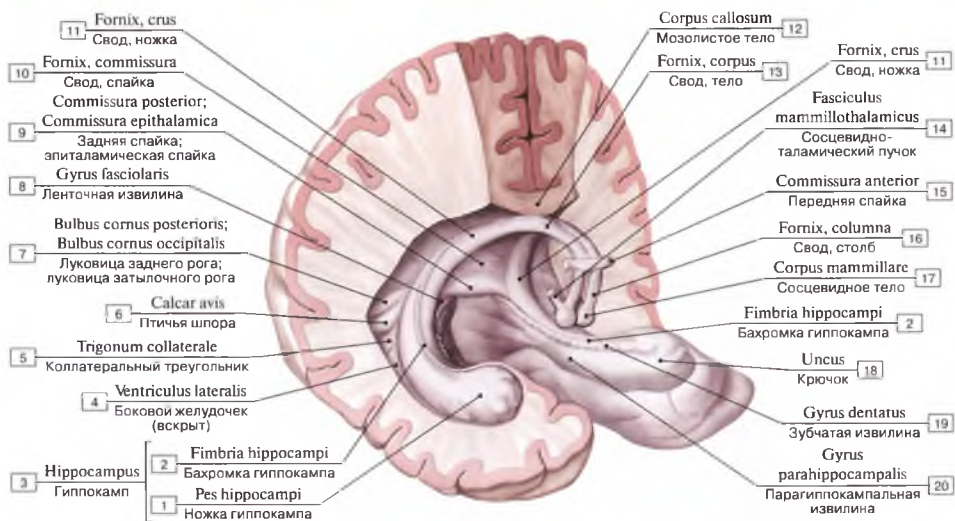


Рис. 70. Свод мозга и гиппокамп, вид сбоку:

1 – Pes of hippocampus; 2 – Fimbria of hippocampus; 3 = 1+2 – Hippocampus; 4 – Lateral ventricle; 5 – Collateral trigone; 6 – Calcarine spur; 7 – Bulb of posterior horn; 8 – Fasciolar gyrus; 9 – Posterior commissure; 10 – Fornix, commissure; 11 – Fornix, crus; 12 – Corpus callosum; 13 – Fornix, body; 14 – Mammillothalamic fasciculus; 15 – Anterior commissure; 16 – Fornix, column; 17 – Mammillary body; 18 – Uncus; 19 – Dentate gyrus; 20 – Parahippocampal gyrus

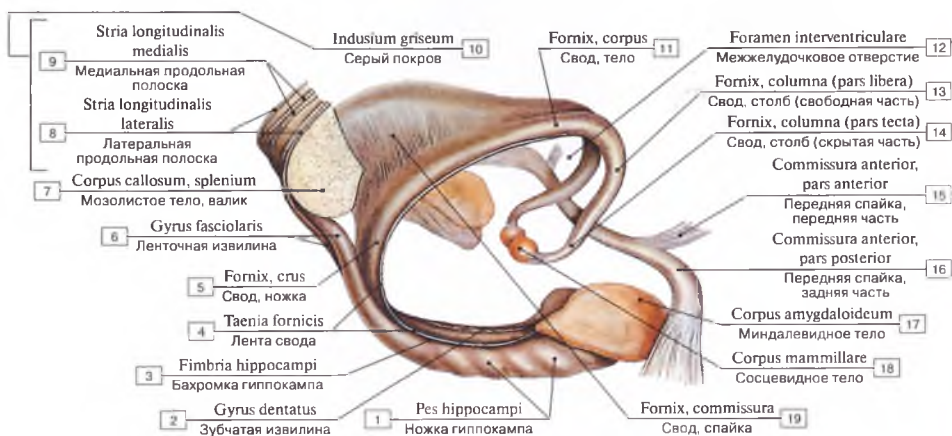


Рис. 71. Свод мозга, передняя спайка и гиппокамп, вид сбоку, ткань мозга удалена:

1 – Pes of hippocampus; 2 – Dentate gyrus; 3 – Fimbria of hippocampus; 4 – Taenia of fornix; 5 – Fornix, crus; 6 – Fasciolar gyrus; 7 – Corpus callosum, splenium; 8 – Lateral longitudinal stria; 9 – Medial longitudinal stria; 10 = 8 + 9 – Indusium griseum; 11 – Fornix, body; 12 – Interventricular foramen; 13 – Fornix, column (free part); 14 – Fornix, column (hidden part); 15 – Anterior commissure, anterior part; 16 – Anterior commissure, posterior part; 17 – Amygdaloid body; Amygdaloid complex; 18 – Mammillary body; 19 – Fornix, commissure

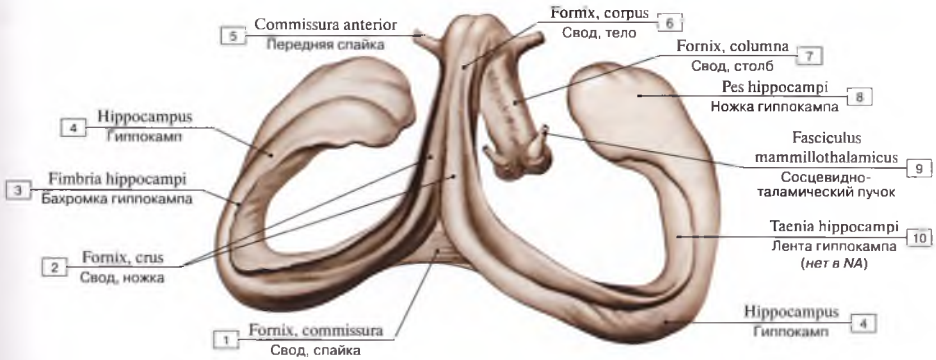


Рис. 72. Гиппокамп и свод мозга, вид сверху, ткань мозга удалена:

1 – Fornix, commissure; 2 – Fornix, crus; 3 – Fimbria of hippocampus; 4 – Hippocampus; 5 – Anterior commissure; 6 – Fornix, body; 7 – Fornix, column; 8 – Pes of hippocampus; 9 – Mammillothalamic fasciculus; 10 – Taenia of hippocampus

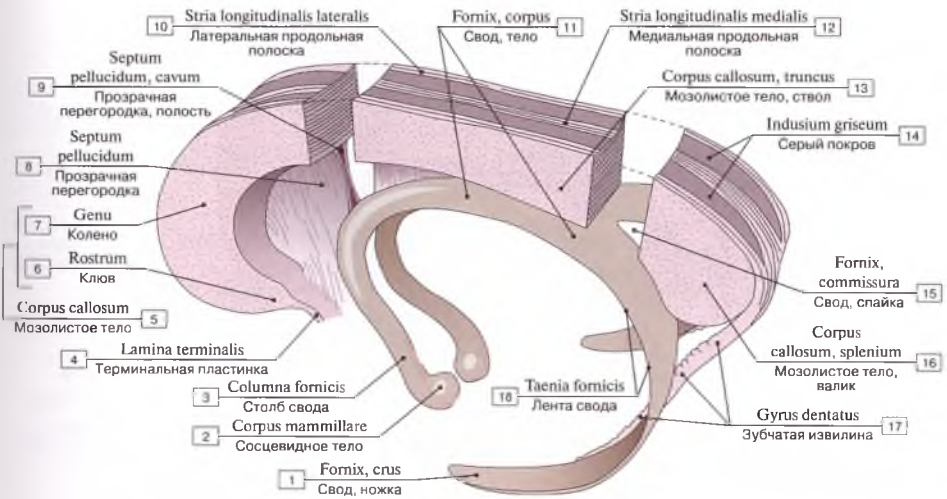


Рис. 73. Свод, мозолистое тело и прозрачная перегородка (схема):

1 – Fornix, crus; 2 – Mammillary body; 3 – Column of fornix; 4 – Lamina terminalis; 5 = 6 + 7 – Corpus callosum; 6 – Rostrum; 7 – Genu; 8 – Septum pellucidum; 9 – Septum pellucidum, cave; 10 – Lateral longitudinal stria; 11 – Fornix, body; 12 – Medial longitudinal stria; 13 – Corpus callosum, body; trunk; 14 – Indusium griseum; 15 – Fornix, commissure; 16 – Corpus callosum, splenium; 17 – Dentate gyrus; 18 – Taenia

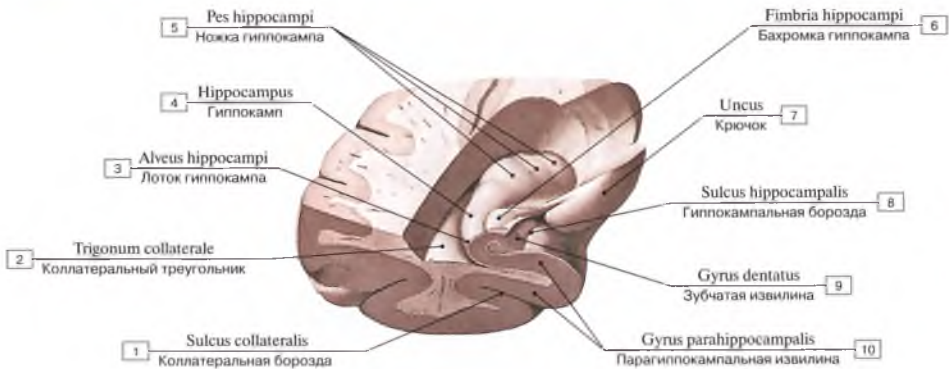


Рис. 74. Расположение гиппокампа в левой височной доле:

1 – Collateral sulcus; 2 – Collateral trigone; 3 – Alveus; 4 – Hippocampus; 5 – Pes of hippocampus; 6 – Fimbria of hippocampus; 7 – Uncus; 8 – Hippocampal sulcus; 9 – Dentate gyrus; 10 – Parahippocampal gyrus

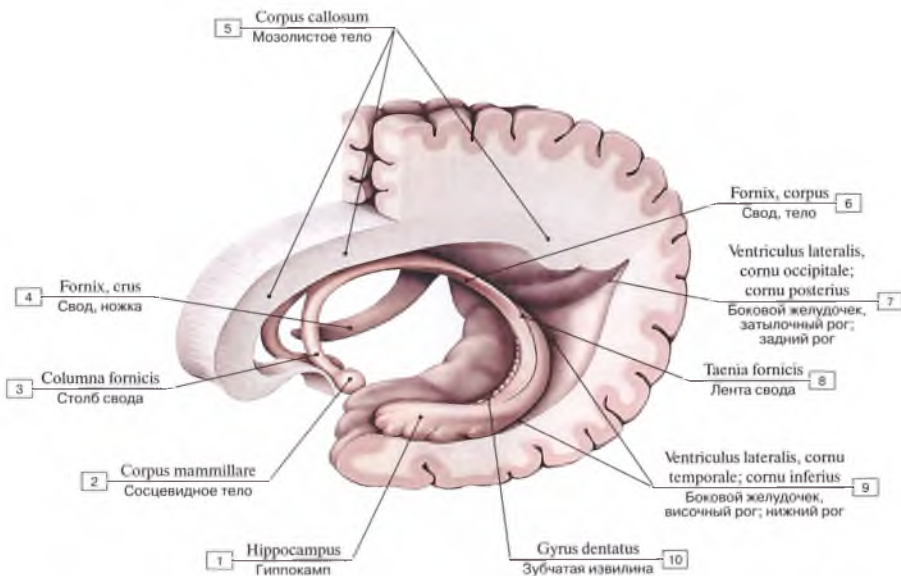


Рис. 75. Топография гиппокампа, свода и мозолистого тела  
(нервные волокна соединяют гиппокамп с сосцевидными телами):

1 – Hippocampus; 2 – Mammillary body; 3 – Column of fornix; 4 – Fornix, crus; 5 – Corpus callosum; 6 – Fornix, body; 7 – Lateral ventricle, occipital horn; posterior horn; 8 – Taenia; 9 – Lateral ventricle, temporal horn; inferior horn; 10 – Dentate gyrus



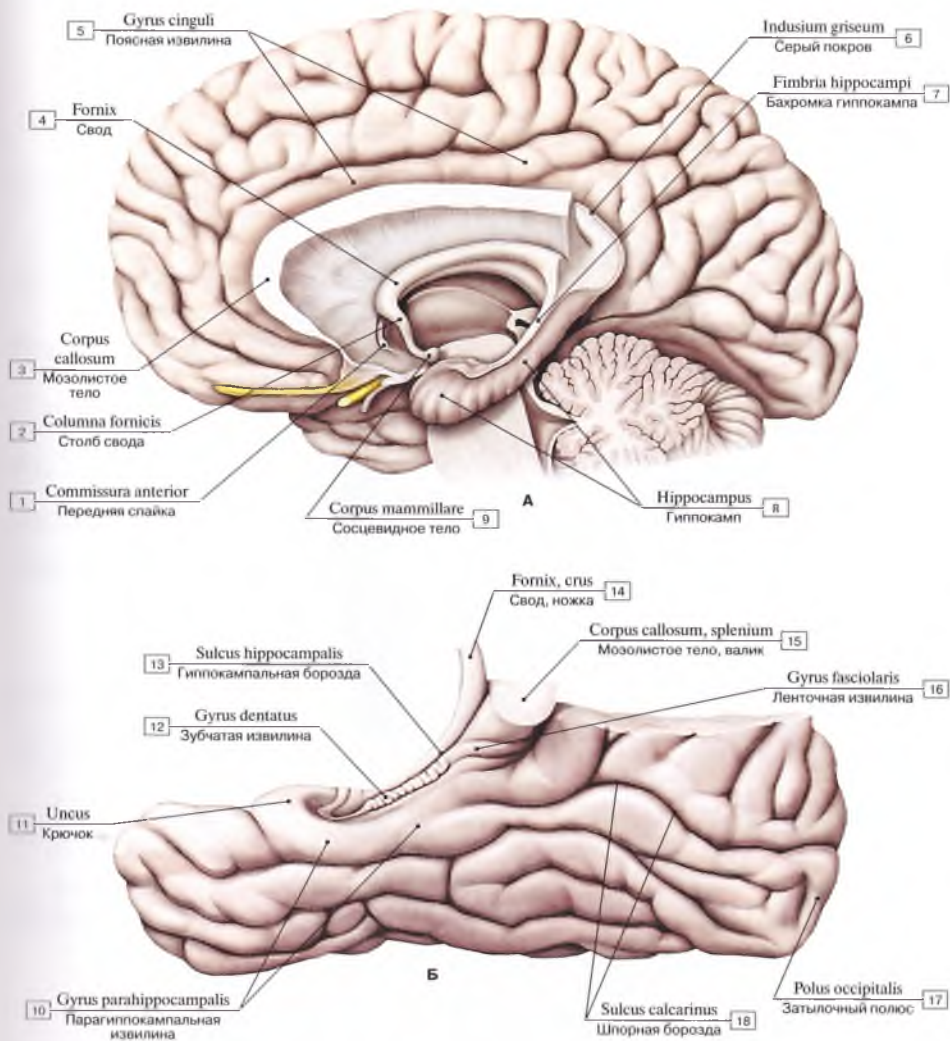


Рис. 76. Гиппокамп (А – вид сбоку, большая часть левого полушария отсечена, оставлены только мозолистое тело, свод и гиппокамп; Б – вид слева, с медиальной стороны):

1 – Anterior commissure; 2 – Column of fornix; 3 – Corpus callosum; 4 – Fornix; 5 – Cingulate gyrus; 6 – Indisium griseum; 7 – Fimbria of hippocampus; 8 – Hippocampus; 9 – Mammillary body; 10 – Parahippocampal gyrus; 11 – Uncus; 12 – Dentate gyrus; 13 – Hippocampal sulcus; 14 – Fornix, crus; 15 – Corpus callosum, splenium; 16 – Fasciolar gyrus; 17 – Occipital pole; 18 – Calcarine sulcus

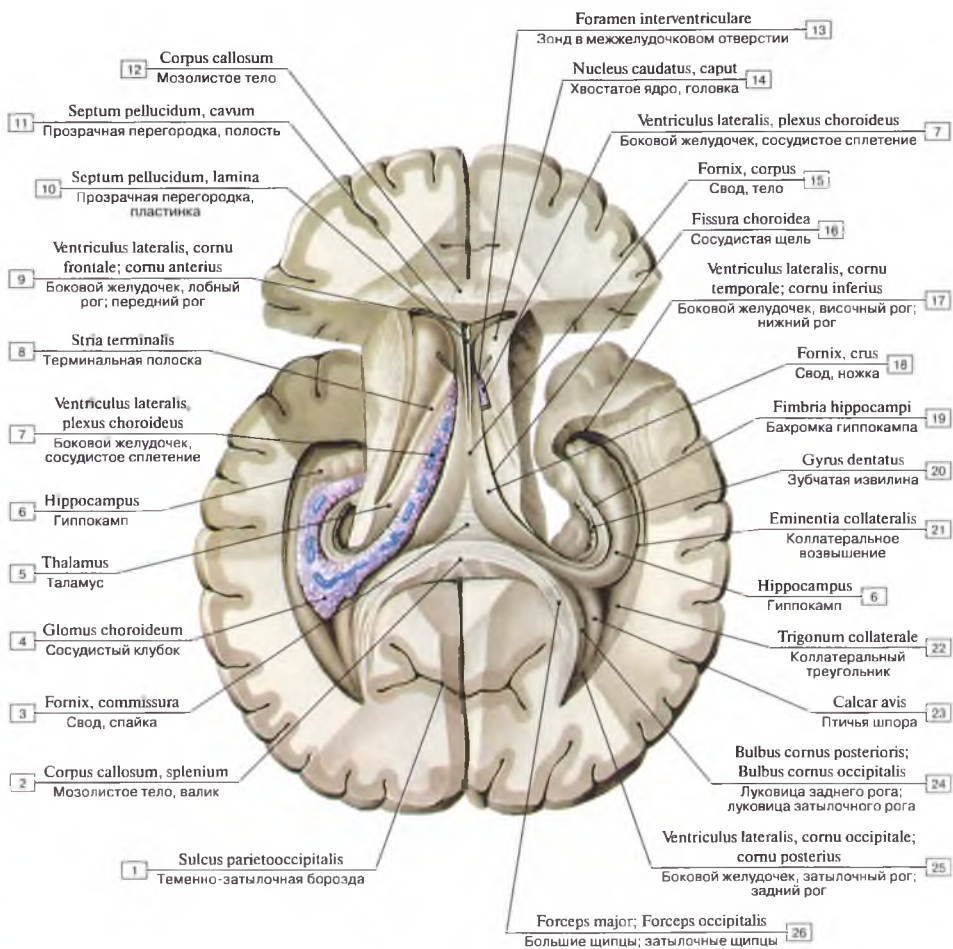


Рис. 77. Свод и боковые желудочки, вид сверху.  
Горизонтальный разрез мозга. Боковые желудочки вскрыты:

1 – Parieto-occipital sulcus; 2 – Corpus callosum, splenium; 3 – Fornix, commissure; 4 – Choroid enlargement; 5 – Thalamus; Dorsal thalamus; 6 – Hippocampus; 7 – Lateral ventricle, choroid plexus; 8 – Stria terminalis; 9 – Lateral ventricle, frontal horn; anterior horn; 10 – Septum pellucidum, lamina; 11 – Septum pellucidum, cave; 12 – Corpus callosum; 13 – Interventricular foramen; 14 – Caudate nucleus, head; 15 – Fornix, body; 16 – Choroidal fissure, cave; 17 – Lateral ventricle, temporal horn; inferior horn; 18 – Fornix, crus; 19 – Fimbria of hippocampus; 20 – Dentate gyrus; 21 – Collateral eminence; 22 – Collateral trigone; 23 – Calcarine spur; 24 – Bulb of posterior horn; Bulb of occipital horn; 25 – Lateral ventricle, occipital horn; posterior horn; 26 – Major forceps; Occipital forceps

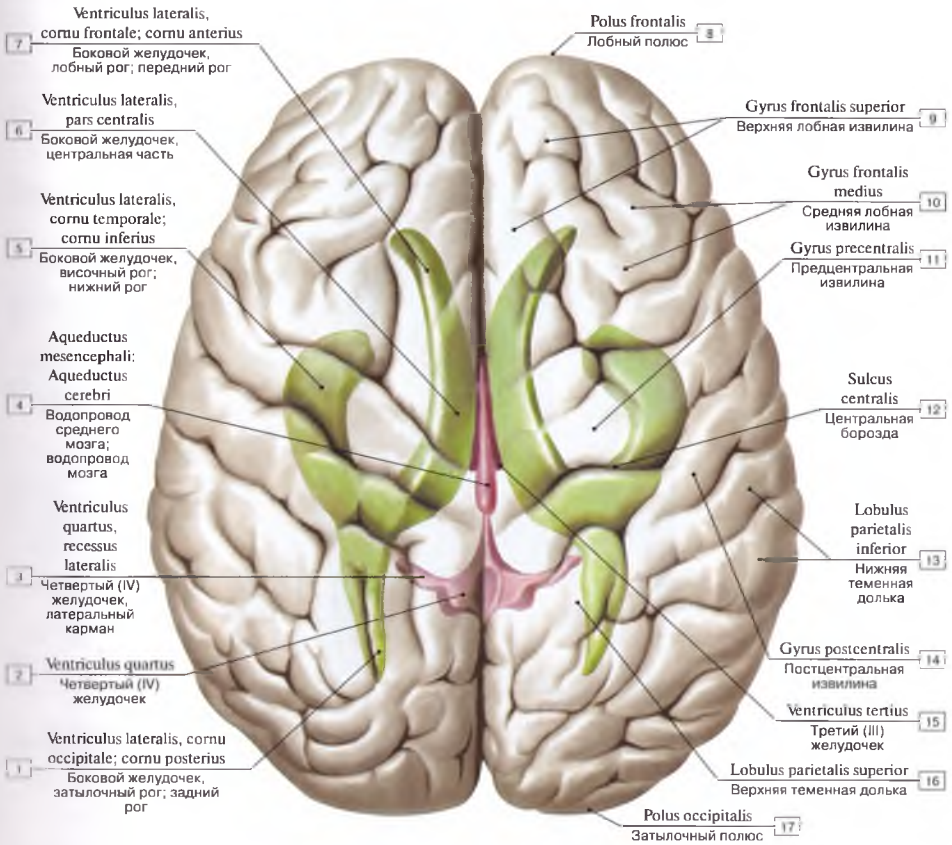


Рис. 78. Проекция желудочков мозга на поверхность больших полушарий, вид сверху:

1 – Lateral ventricle, occipital horn; posterior horn; 2 – Fourth ventricle; 3 – Fourth ventricle, lateral recess; 4 – Aqueduct of midbrain; Cerebral aqueduct; 5 – Lateral ventricle, temporal horn; inferior horn; 6 – Lateral ventricle, central part; body; 7 – Lateral ventricle, frontal horn; anterior horn; 8 – Frontal pole; 9 – Superior frontal gyrus; 10 – Middle frontal gyrus; 11 – Precentral gyrus; 12 – Central sulcus; 13 – Inferior parietal lobule; 14 – Postcentral gyms; 15 – Third ventricle; 16 – Superior parietal lobule; 17 – Occipital pole

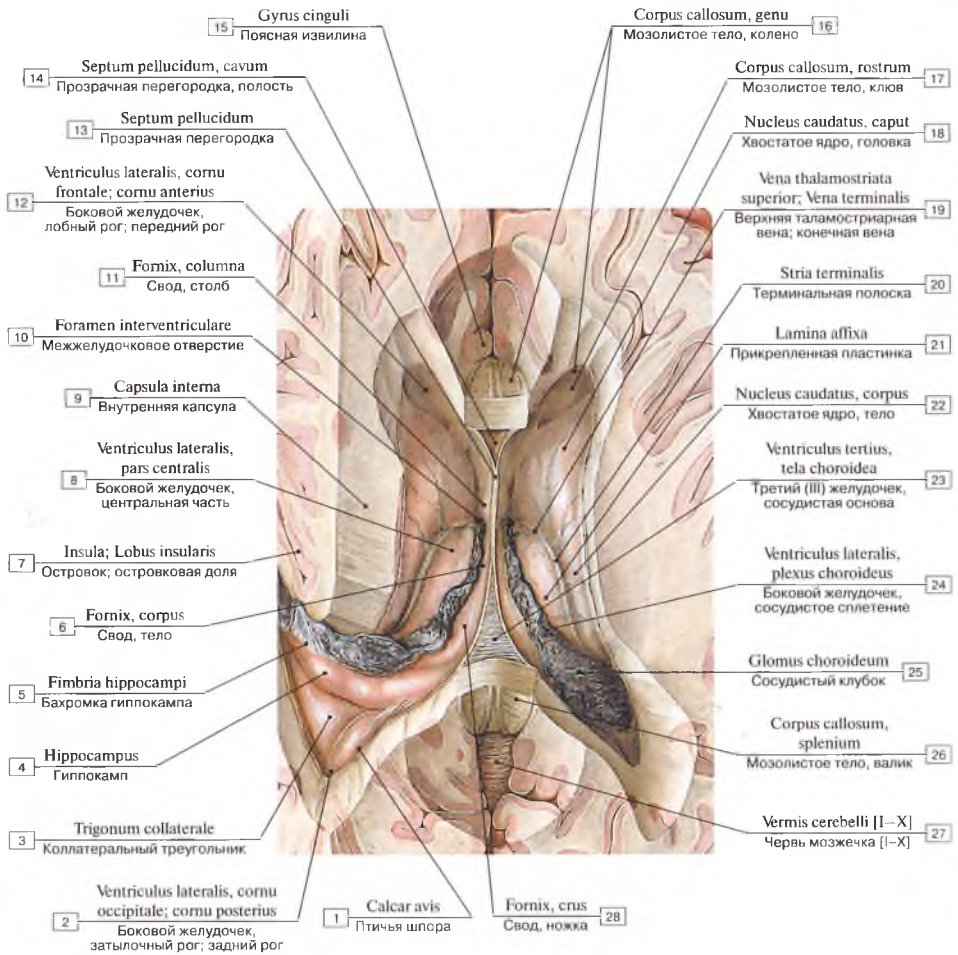


Рис. 79. Боковые желудочки мозга, верхняя часть полушарий большого мозга удалена:

1 – Calcarine spur; 2 – Lateral ventricle, occipital horn; posterior horn; 3 – Collateral trigone; 4 – Hippocampus; 5 – Fimbria of hippocampus; 6 – Fornix, body; 7 – Insula; Insular lobe; 8 – Lateral ventricle, central part; body; 9 – Internal capsule; 10 – Interventricular foramen; 11 – Fornix, column; 12 – Lateral ventricle, frontal horn; anterior horn; 13 – Septum pellucidum; 14 – Septum pellucidum, cave; 15 – Cingulate gyrus; 16 – Corpus callosum, genu; 17 – Corpus callosum, rostrum; 18 – Caudate nucleus, head; 19 – Superior thalamostriate vein; 20 – Stria terminalis; 21 – Lamina affixa; 22 – Caudate nucleus, body; 23 – Third ventricle, choroid membrane; 24 – Lateral ventricle, choroid plexus; 25 – Choroid enlargement; 26 – Corpus callosum, splenium; 27 – Vermis of cerebellum [I-X]; 28 – Fornix, crus

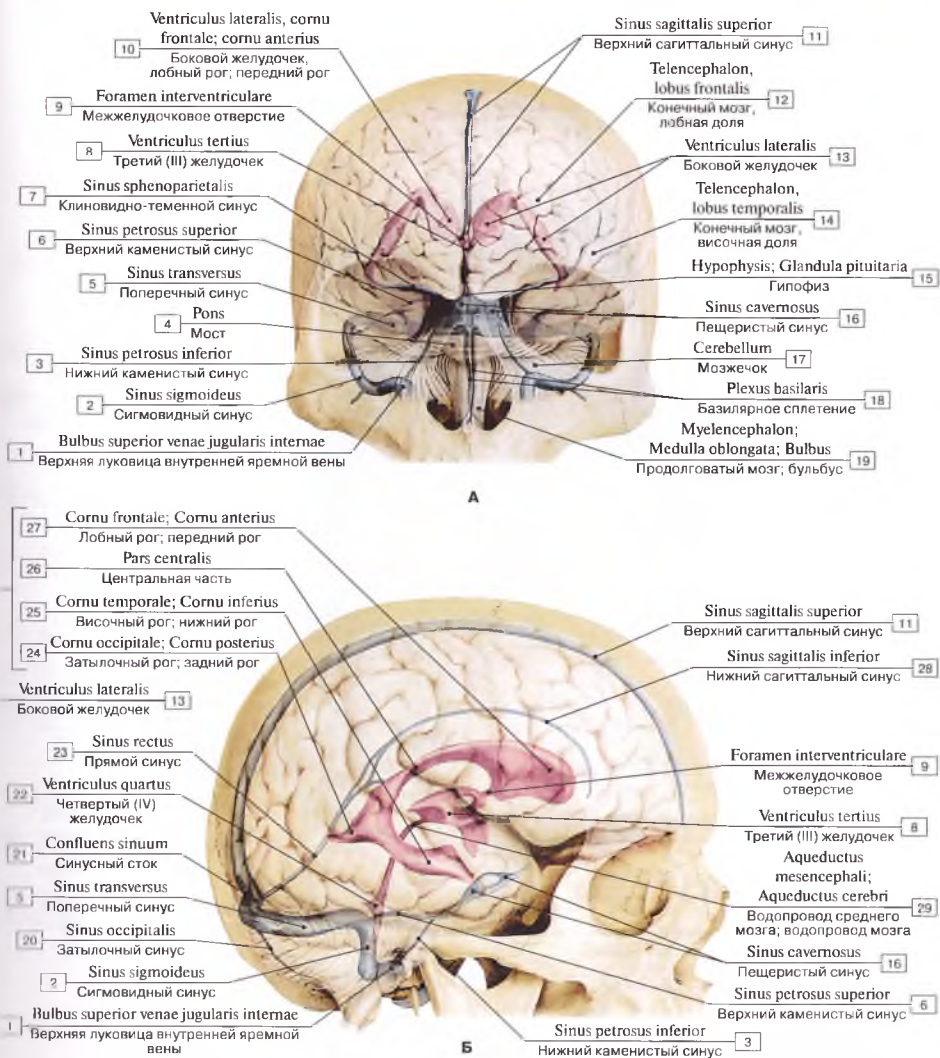


Рис. 80. Проекция желудочков мозга и синусов твердой мозговой оболочки (А – вид спереди; Б – вид сбоку):

1 – Superior bulb of internal jugular vein; 2 – Sigmoid sinus; 3 – Inferior petrosal sinus; 4 – Pons; 5 – Transverse sinus; 6 – Superior petrosal sinus; 7 – Sphenoparietal sinus; 8 – Third ventricle; 9 – Interventricular foramen; 10 – Lateral ventricle, frontal horn; anterior horn; 11 – Superior sagittal sinus; 12 – Telencephalon, frontal lobe; 13 = 24 + 25 + 26 + 27 – Lateral ventricle; 14 – Telencephalon, temporal lobe; 15 – Pituitary gland; 16 – Cavernous sinus; 17 – Cerebellum; 18 – Basilar plexus; 19 – Myelencephalon; Medulla oblongata; Bulb; 20 – Occipital sinus; 21 – Confluence of sinuses; 22 – Fourth ventricle; 23 – Straight sinus; 24 – Occipital horn; Posterior horn; 25 – Temporal horn; Inferior horn; 26 – Central part; Body; 27 – Frontal horn; Anterior horn; 28 – Inferior sagittal sinus; 29 – Aqueduct of midbrain; Cerebral aqueduct

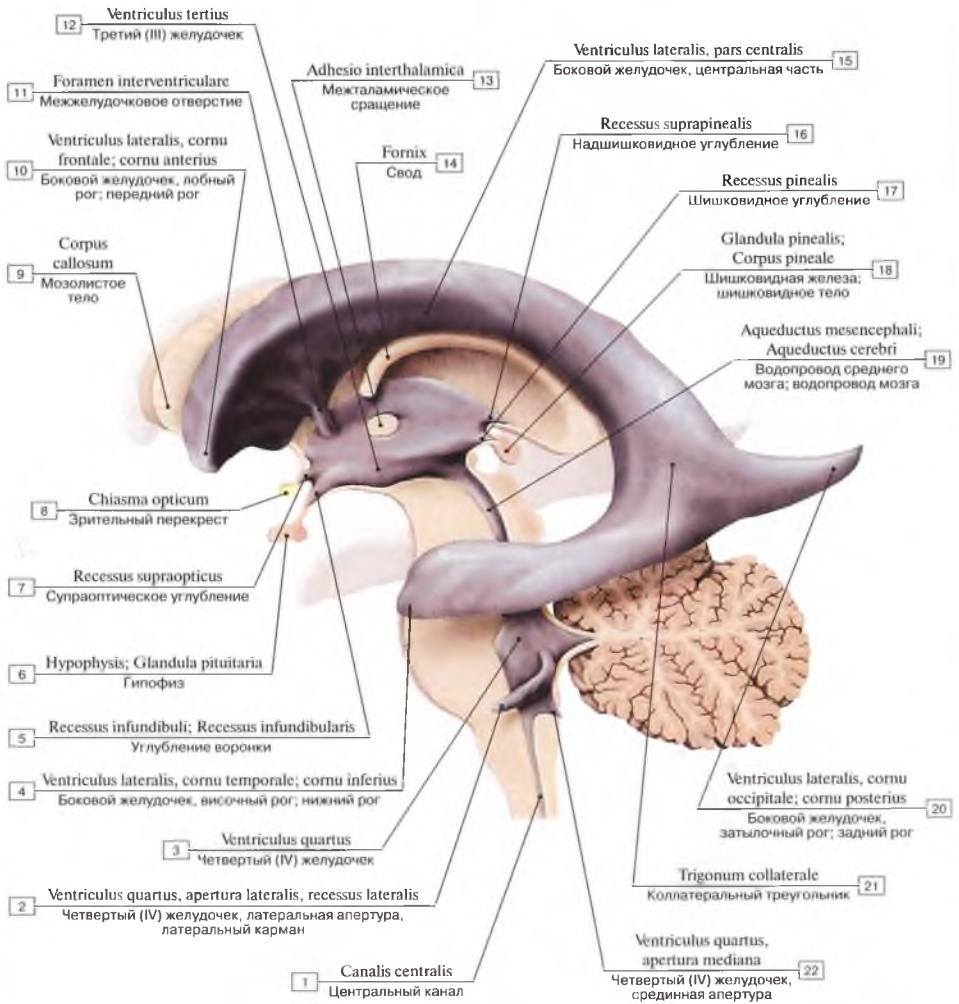


Рис. 81. Желудочки мозга (реконструкция):

1 – Central canal; 2 – Fourth ventricle, lateral aperture, lateral recess; 3 – Fourth ventricle; 4 – Lateral ventricle, temporal horn; inferior horn; 5 – Infundibular recess; 6 – Pituitary gland; 7 – Supra-optic recess; 8 – Optic chiasm; Optic chiasma; 9 – Corpus callosum; 10 – Lateral ventricle, frontal horn; anterior horn; 11 – Interventricular foramen; 12 – Third ventricle; 13 – Interthalamic adhesion; Massa intermedia; 14 – Fornix; 15 – Lateral ventricle, central part; 16 – Suprapineal recess; 17 – Pineal recess; 18 – Pineal gland; Pineal body; 19 – Aqueduct of midbrain; Cerebral aqueduct; 20 – Lateral ventricle, occipital horn; posterior horn; 21 – Collateral trigone; 22 – Fourth ventricle, median aperture

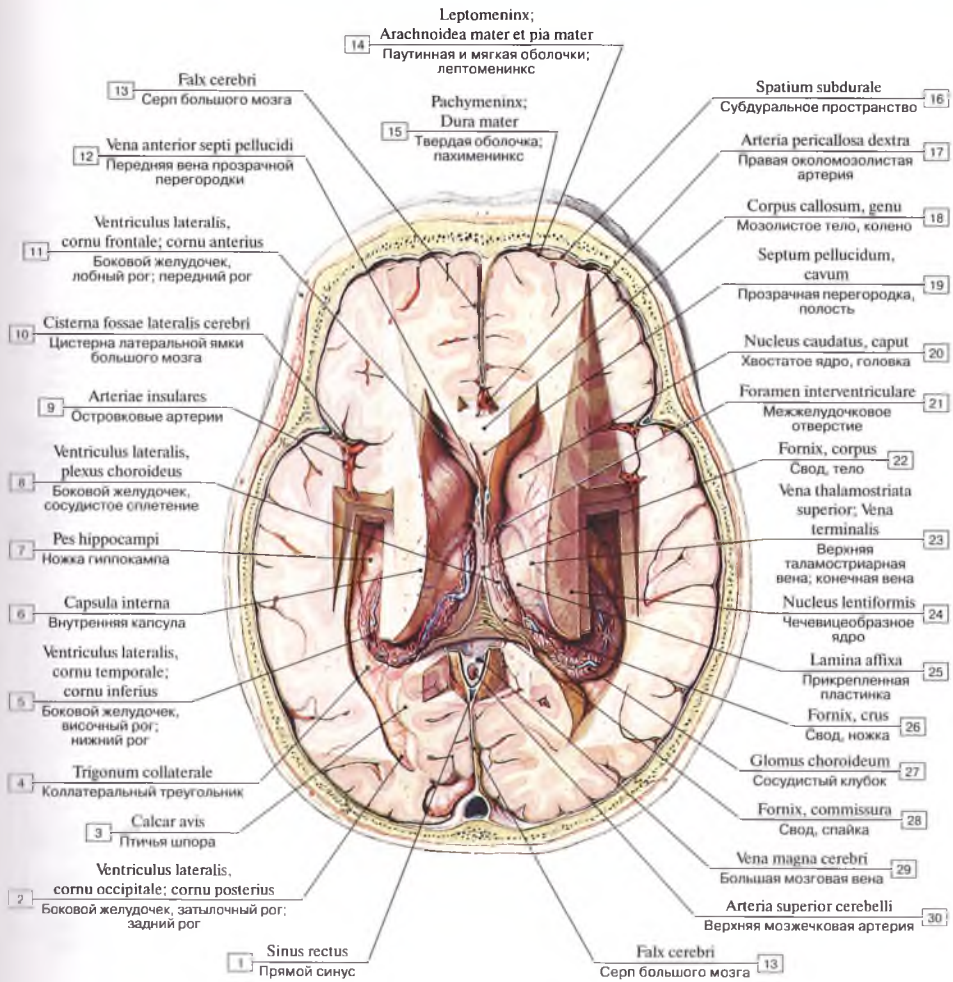


Рис. 82. Мозг, вид сверху на поперечном срезе, свод и боковые желудочки:

1 – Straight sinus; 2 – Lateral ventricle, occipital horn; posterior horn; 3 – Calcarine spur; 4 – Collateral trigone; 5 – Lateral ventricle, temporal horn; inferior horn; 6 – Internal capsule; 7 – Pes of hippocampus; 8 – Lateral ventricle, choroid plexus; 9 – Insular arteries; 10 – Cistern of lateral cerebral fossa; 11 – Lateral ventricle, frontal horn; anterior horn; 12 – Anterior vein of septum pellucidum; 13 – Falx cerebri; Cerebral falx; 14 – Leptomeninx; Arachnoid mater and pia mater; 15 – Pachymeninx; Dura mater; 16 – Subdural space; 17 – Right pericallosal artery; 18 – Corpus callosum, genu; 19 – Septum pellucidum, cave; 20 – Caudate nucleus, head; 21 – Interventricular foramen; 22 – Fornix, body; 23 – Superior thalamostriate vein; 24 – Lentiform nucleus; Lenticular nucleus; 25 – Lamina affixa; 26 – Fornix, crus; 27 – Choroidal enlargement; 28 – Fornix, commissure; 29 – Great cerebral vein; 30 – Superior cerebellar artery

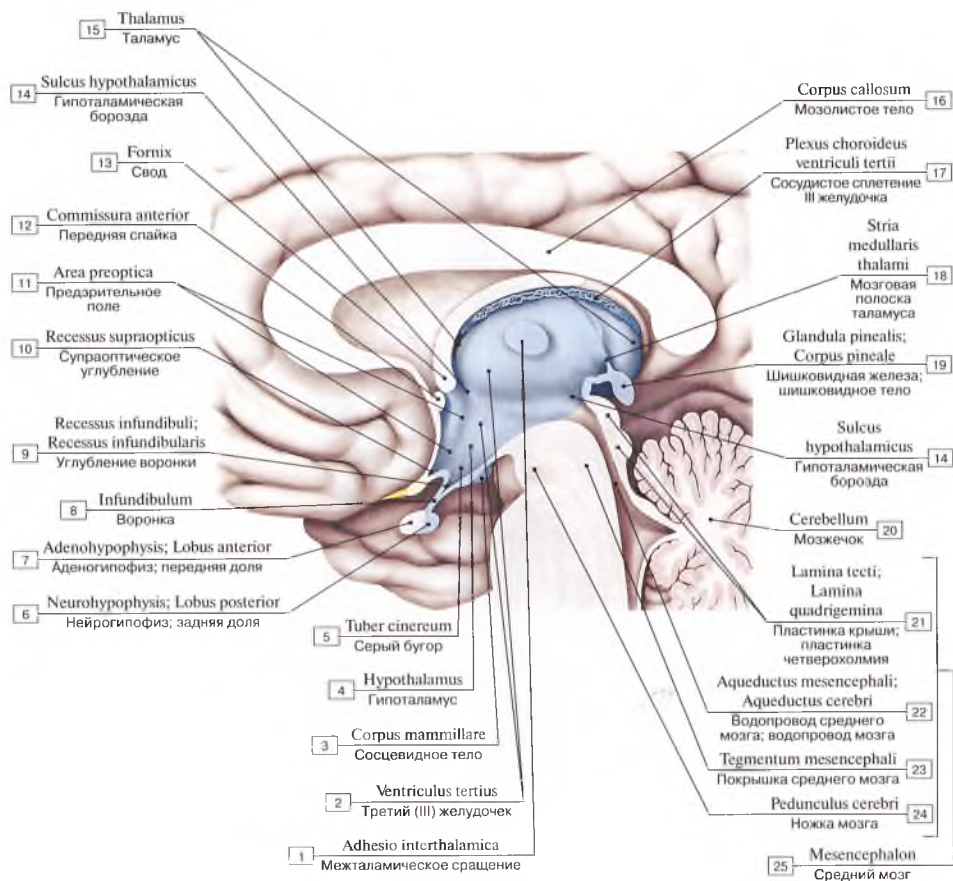


Рис. 83. Промежуточный мозг, вид с медиальной стороны:

1 – Interthalamic adhesion; Massa intermedia; 2 – Third ventricle; 3 – Mammillary body; 4 – Hypothalamus; 5 – Tuber cinereum; 6 – Neurohypophysis; Posterior lobe; 7 – Adenohypophysis; Anterior lobe; 8 – Infundibulum; 9 – Infundibular recess; 10 – Supra-optic recess; 11 – Pre-optic area; 12 – Anterior commissure; 13 – Fornix; 14 – Hypothalamic sulcus; 15 – Thalamus; Dorsal thalamus; 16 – Corpus callosum; 17 – Choroid plexus of third ventricle; 18 – Stria medullaris of thalamus; 19 – Pineal gland; Pineal body; 20 – Cerebellum; 21 – Tectal plate; Quadrigeminal plate; 22 – Aqueduct of midbrain; Cerebral aqueduct; 23 – Tegmentum of midbrain; 24 – Cerebral peduncle; 25 = 21 + 22 + 23 + 24 – Mesencephalon; Midbrain



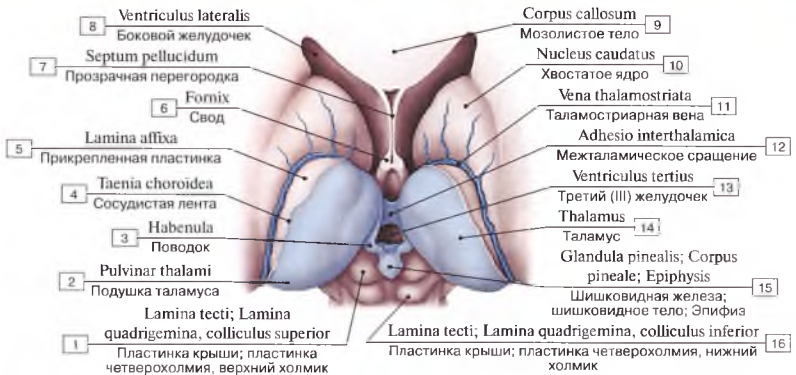


Рис. 84. Промежуточный мозг, вид сверху и снизу; эпителиум:

1 – Tectal plate; Quadrigeminal plate, superior colliculus; 2 – Pulvinar; 3 – Habenula; 4 – Choroid line; 5 – Lamina affixa; 6 – Fornix; 7 – Septum pellucidum; 8 – Lateral ventricle; 9 – Corpus callosum; 10 – Caudate nucleus; 11 – Thalamostriate vein; 12 – Interthalamic adhesion; Massa intermedia; 13 – Third ventricle; 14 – Thalamus; Dorsal thalamus; 15 – Pineal gland; Pineal body; Epiphysis; 16 – Tectal plate; Quadrigeminal plate, inferior colliculus

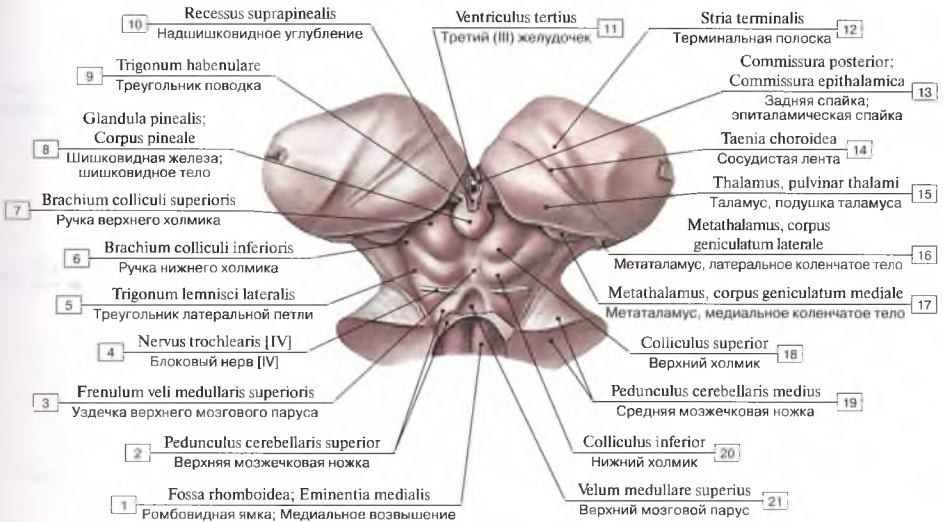


Рис. 85. Промежуточный и средний мозг, вид сверху:

1 – Rhomboid fossa; Floor of fourth ventricle; Medial eminence; 2 – Superior cerebellar peduncle; 3 – Frenulum of superior medullary velum; 4 – Trochlear nerve [IV]; 5 – Trigone of lateral lemniscus; 6 – Brachium of inferior colliculus; 7 – Brachium of superior colliculus; 8 – Pineal gland; Pineal body; 9 – Habenular trigone; 10 – Suprapineal recess; 11 – Third ventricle; 12 – Stria terminalis; 13 – Posterior commissure; 14 – Choroid line; 15 – Thalamus; Dorsal thalamus, pulvinar; 16 – Metathalamus, lateral geniculate body; 17 – Metathalamus, medial geniculate body; 18 – Superior colliculus; 19 – Middle cerebellar peduncle; 20 – Inferior colliculus; 21 – Superior medullary velum

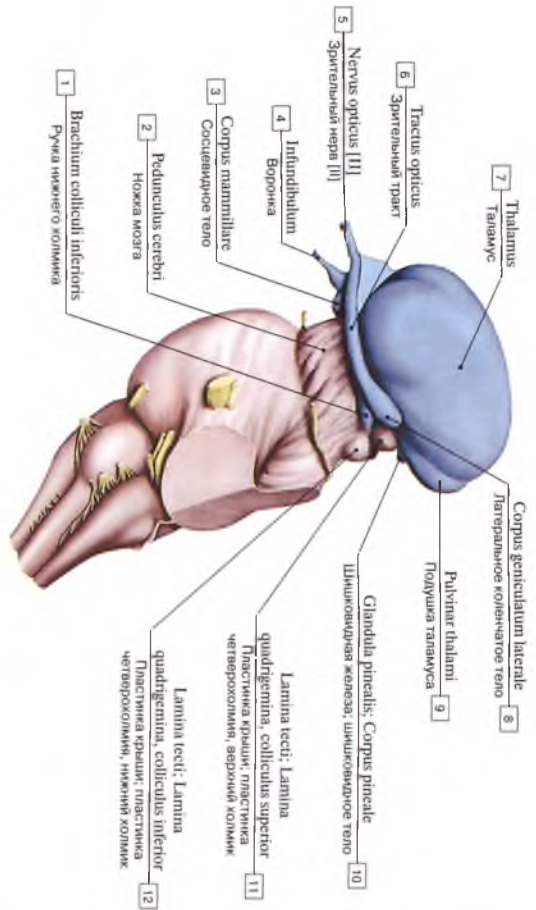


Рис. 86. Промежуточный мозг, вид сбоку.

- 1 – Brachium of inferior colliculus; 2 – Tectal peduncle; 3 – Mammillary body; 4 – Infundibulum; 5 – Optic nerve (III); 6 – Optic tract; 7 – Thalamus; Dorsal thalamus; 8 – Lateral geniculate body; 9 – Pulvinar; 10 – Pineal gland; Pineal body; 11 – Tectal plate; Quadrigeminal plate; superior colliculus; 12 – Tectal plate; Quadrigeminal plate; inferior colliculus

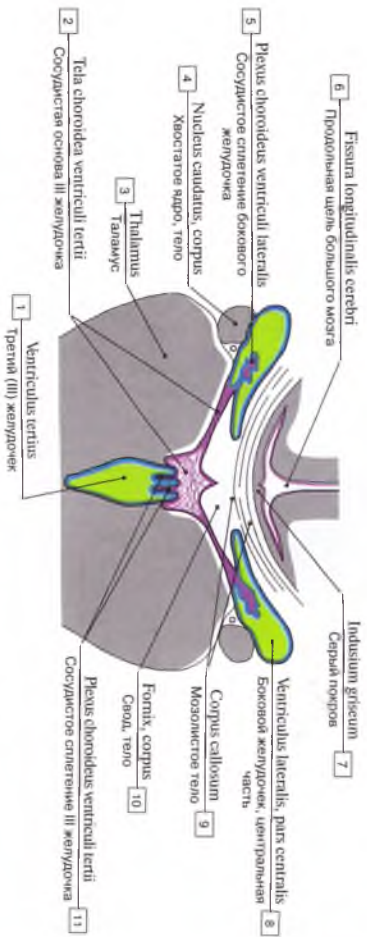


Рис. 87. Сосудистые сплетения боковых и третьего желудочков (схема).

- 1 – Third ventricle; 2 – Tela choroidea of third ventricle; 3 – Thalamus; Dorsal thalamus; 4 – Claustrum nucleus, body; 5 – Claustrum nucleus, head; 6 – Longitudinal cerebral fissure; 7 – Indusium griseum; 8 – Lateral ventricle, central part; 9 – Corpus callosum; 10 – Fornix, body; 11 – Choroid plexus of third ventricle

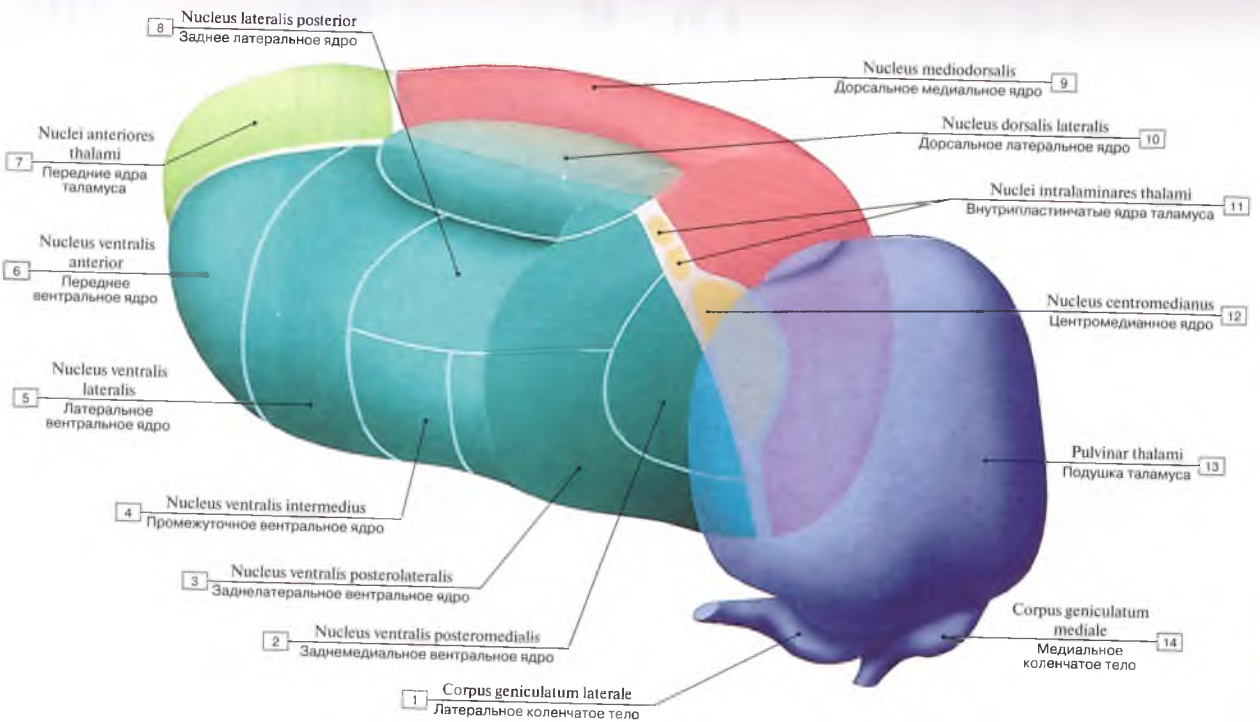


Рис. 88. Пространственная организация групп ядер левого таламуса, вид сбоку снизу.

- 1 – Lateral geniculate body; 2 – Ventral posteromedial nucleus; 3 – Ventral posterolateral nucleus; 4 – Ventral intermediate nucleus; 5 – Ventral anterior nucleus; 6 – Ventral anterior nucleus; 7 – Anterior nuclei of thalamus; 8 – Lateral posterior nucleus; 9 – Medial dorsal nucleus; Dorsomedial nucleus; 10 – Lateral dorsal nucleus; 11 – Intralaminar nuclei of thalamus; 12 – Centromedian nucleus; 13 – Pulvinar; 14 – Medial geniculate body

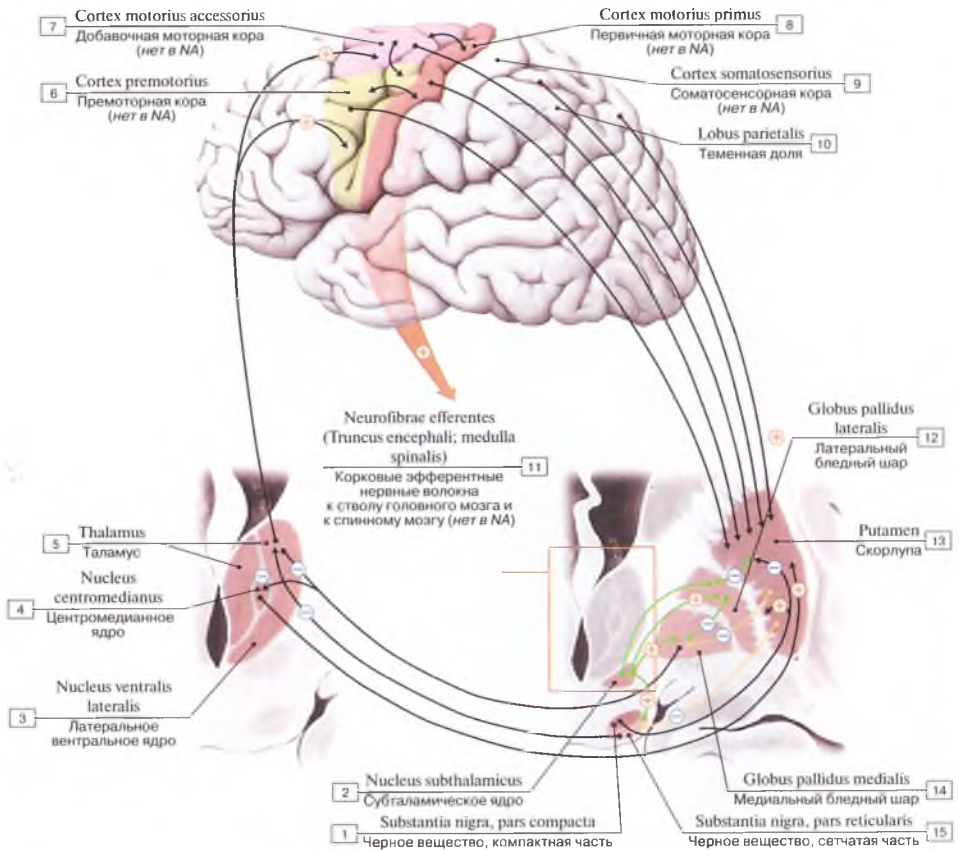


Рис. 89. Взаимосвязи двигательных зон коры с базальными ядрами и таламусом (схема):

1 – Substantia nigra, compact part; 2 – Subthalamic nucleus; 3 – Ventral lateral nucleus; 4 – Centromedian nucleus; 5 – Thalamus; Dorsal thalamus; 6 – Premotor cortex; 7 – Accessory motor cortex; 8 – First motor cortex; 9 – Somatosensory cortex; 10 – Parietal lobe; 11 – Efferent nerve fibres (Brainstem; Spinal cord); 12 – Globus pallidus lateral segment; 13 – Putamen; 14 – Globus pallidus medial segment; Globus pallidus internal segment; 15 – Substantia nigra, reticular part

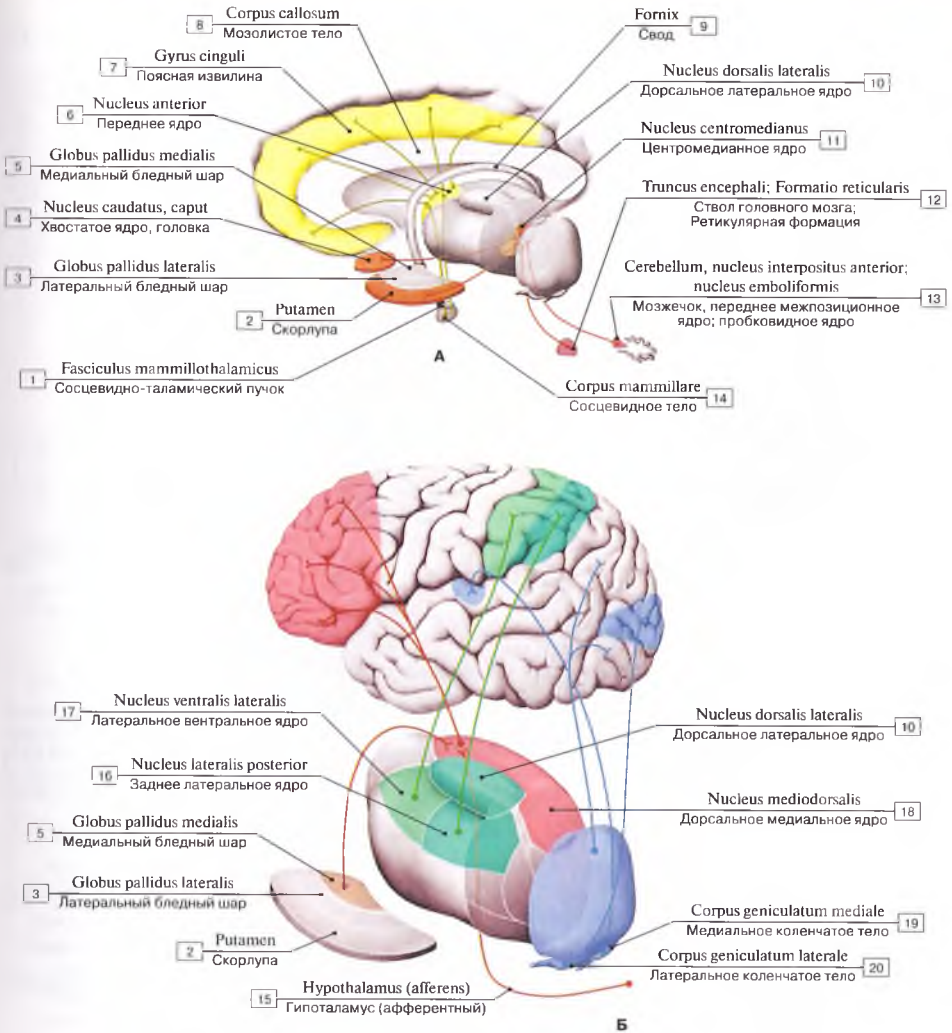


Рис. 90. Ядра таламуса (А – переднее ядро и центромедианное ядро: афферентные и эфферентные связи; Б – медиальное, дорсальное и латеральное ядра таламуса: афферентные и эфферентные связи):

1 – Mamillothalamic fasciculus; 2 – Putamen; 3 – Globus pallidus lateral segment; Globus pallidus external segment; 4 – Caudate nucleus, head; 5 – Globus pallidus medial segment; Globus pallidus internal segment; 6 – Anterior nucleus; 7 – Cingulate gyrus; 8 – Corpus callosum; 9 – Fornix; 10 – Lateral dorsal nucleus; 11 – Centromedian nucleus; 12 – Brainstem; Reticular formation; 13 – Cerebellum, anterior interpositus nucleus; emboliform nucleus; 14 – Mammillary body; 15 – Hypothalamus (afferent); 16 – Lateral posterior nucleus; 17 – Ventral lateral nucleus; 18 – Medial dorsal nucleus; Dorsomedial nucleus; 19 – Medial geniculate body; 20 – Lateral geniculate body

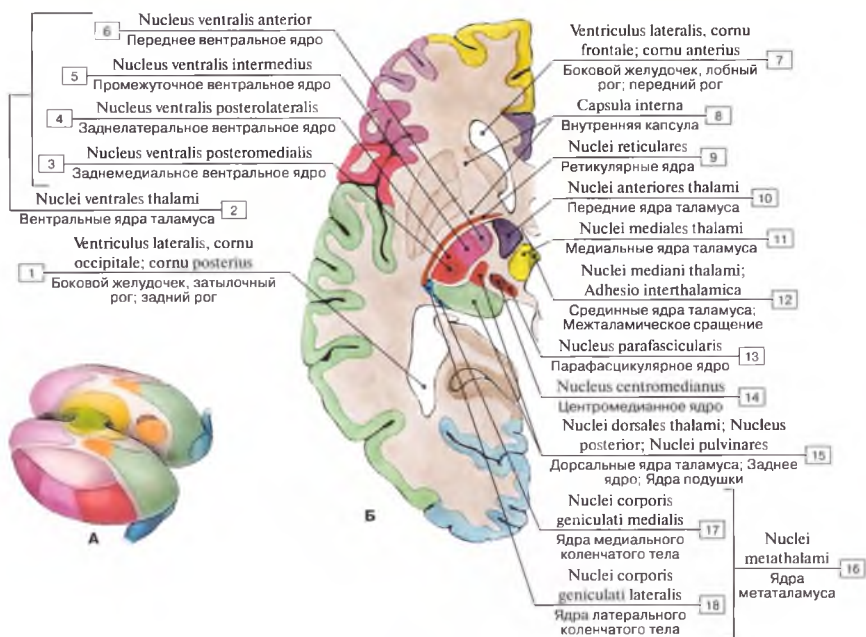


Рис. 91. Расположение ядер таламуса (А — объемное изображение; Б — поперечный срез):

1 — Lateral ventricle, occipital horn; posterior horn; 2 = 3 + 4 + 5 + 6 — Ventral nuclei of thalamus; 3 — Ventral posterolateral nucleus; 4 — Ventral posterolateral nucleus; 5 — Ventral intermediate nucleus; 6 — Ventral anterior nucleus; 7 — Lateral ventricle, frontal horn; anterior horn; 8 — Internal capsule; 9 — Reticular nuclei; 10 — Anterior nuclei of thalamus; 11 — Medial nuclei of thalamus; 12 — Median nuclei of thalamus; Interthalamic adhesion; Massa intermedia; 13 — Parafascicular nucleus; 14 — Centromedian nucleus; 15 — Dorsal nuclei of thalamus; Posterior nucleus; Pulvinar nuclei; 16 = 17 + 18 — Nuclei of metathalamus; 17 — Nuclei of medial geniculate body; 18 — Nuclei of lateral geniculate body

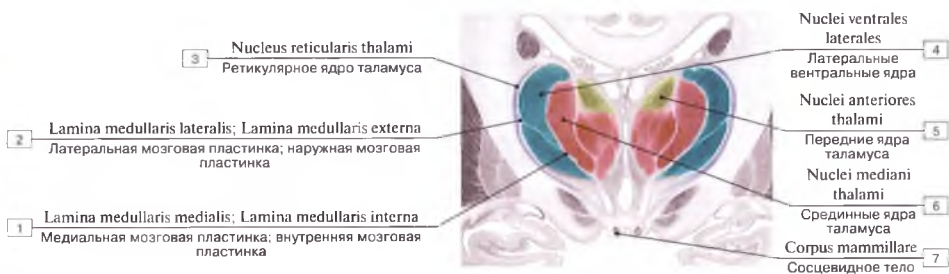


Рис. 92. Ядра таламуса, венечное сечение на уровне сосцевидных тел:

1 — Medial medullary lamina; Internal medullary lamina; 2 — Lateral medullary lamina; External medullary lamina; 3 — Reticular nucleus of thalamus; 4 — Ventral lateral complex; 5 — Anterior nuclei of thalamus; 6 — Median nuclei of thalamus; 7 — Mammillary body

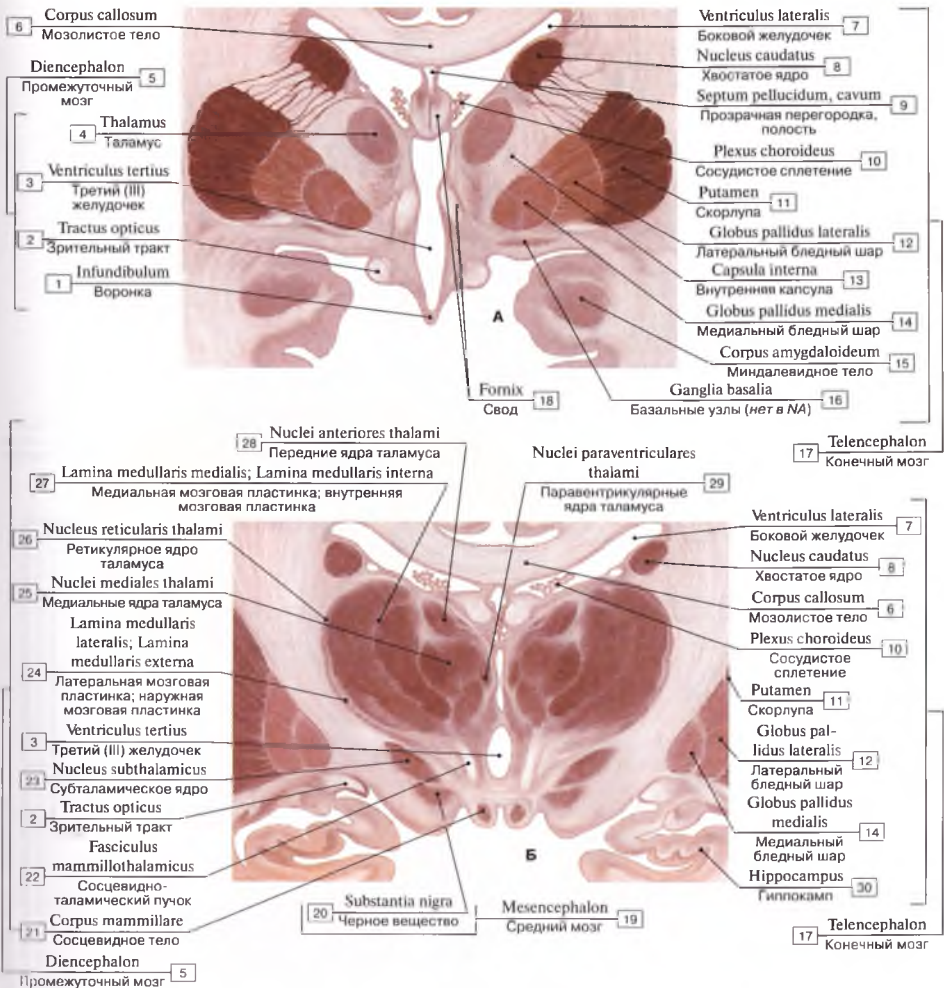


Рис. 93. Ядра таламуса

(А – фронтальный разрез на уровне серого бугра; Б – фронтальный разрез на уровне сосцевидных тел):

1 – Infundibulum; 2 – Optic tract; 3 – Third ventricle; 4 – Thalamus; Dorsal thalamus; 5 = 1 + 2 + 3 + 4 = 2 + 3 + 21 + 22 + 23 + 24 + 25 + 26 + 27 + 28 + 29 – Dienecephalon; 6 – Corpus callosum; 7 – Lateral ventricle; 8 – Caudate nucleus; 9 – Septum pellucidum, cave; 10 – Choroid plexus; 11 – Putamen; 12 – Globus pallidus lateral segment; 13 – Internal capsule; 14 – Globus pallidus medial segment; Globus pallidus internal segment; 15 – Amygdaloid body; Amygdaloid complex; 16 – Basal ganglia; 17 = 7 + 8 + 9 + 10 + 11 + 12 + 13 + 14 + 15 + 16 + 18 = 6 + 7 + 8 + 10 + 11 + 12 + 14 + 30 – Telencephalon; 18 – Fornix; 19 – Mesencephalon; Midbrain; 20 – Substantia nigra; 21 – Mammillary body; 22 – Mammillothalamic fasciculus; 23 – Subthalamic nucleus; 24 – Lateral medullary lamina; External medullary lamina; 25 – Medial nuclei of thalamus; 26 – Reticular nucleus of thalamus; 27 – Medial medullary lamina; Internal medullary lamina; 28 – Anterior nuclei of thalamus; 29 – Paraventricular nuclei of thalamus; 30 – Hippocampus

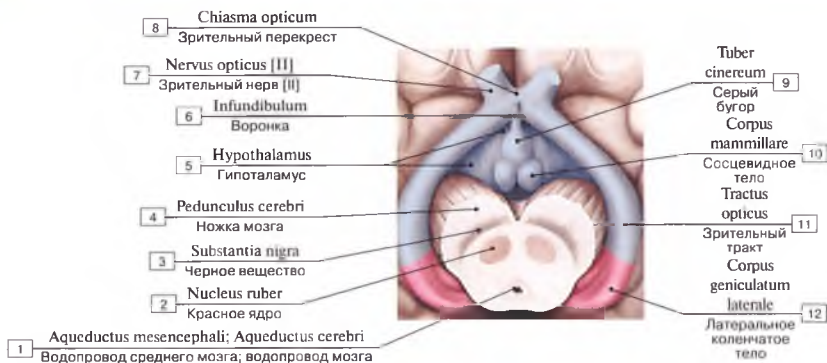


Рис. 94. Гипоталамус и средний мозг, вид снизу;

1 – Aqueduct of midbrain; Cerebral aqueduct; 2 – Red nucleus; 3 – Substantia nigra; 4 – Cerebral peduncle; 5 – Hypothalamus; 6 – Infundibulum; 7 – Optic nerve [III]; 8 – Optic chiasm; Optic chiasma; 9 – Tuber cinereum; 10 – Mammillary body; 11 – Optic tract; 12 – Lateral geniculate body

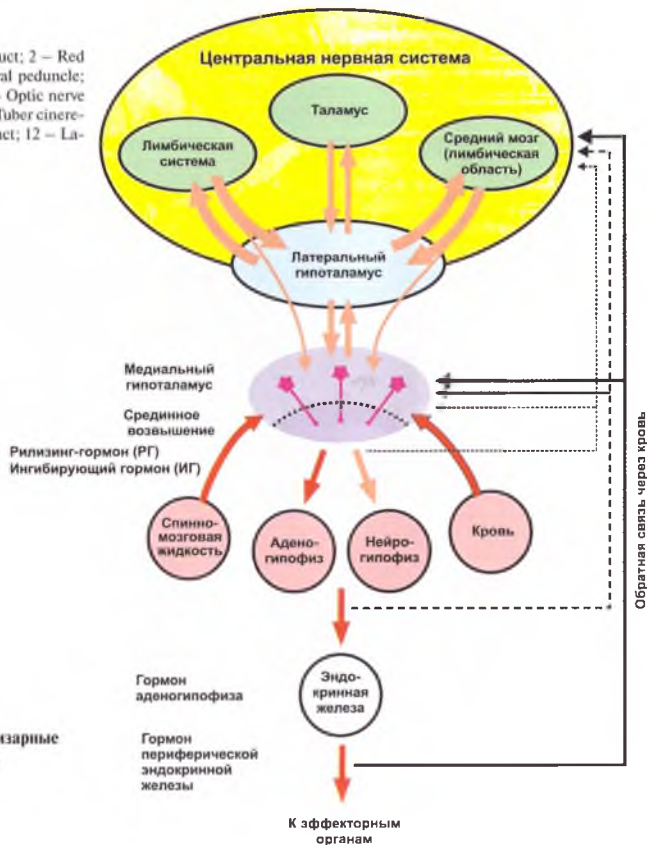


Рис. 95. Гипоталамо-гипофизарные отношения (схема)

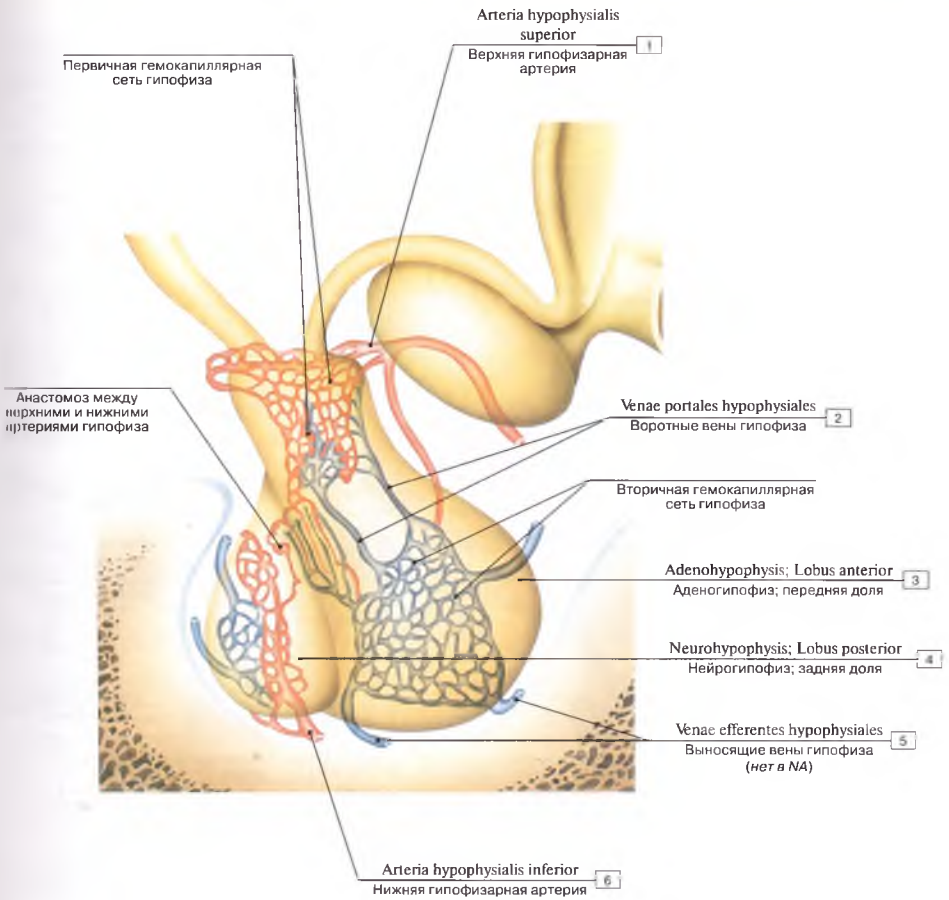


Рис. 96. Кровоснабжение гипофиза (схема):

- 1 – Superior hypophysial artery; 2 – Portal veins of hypophysis; 3 – Adenohypophysis; Anterior lobe; 4 – Neurohypophysis; Posterior lobe; 5 – Efferent veins of hypophysis; 6 – Inferior hypophysial artery



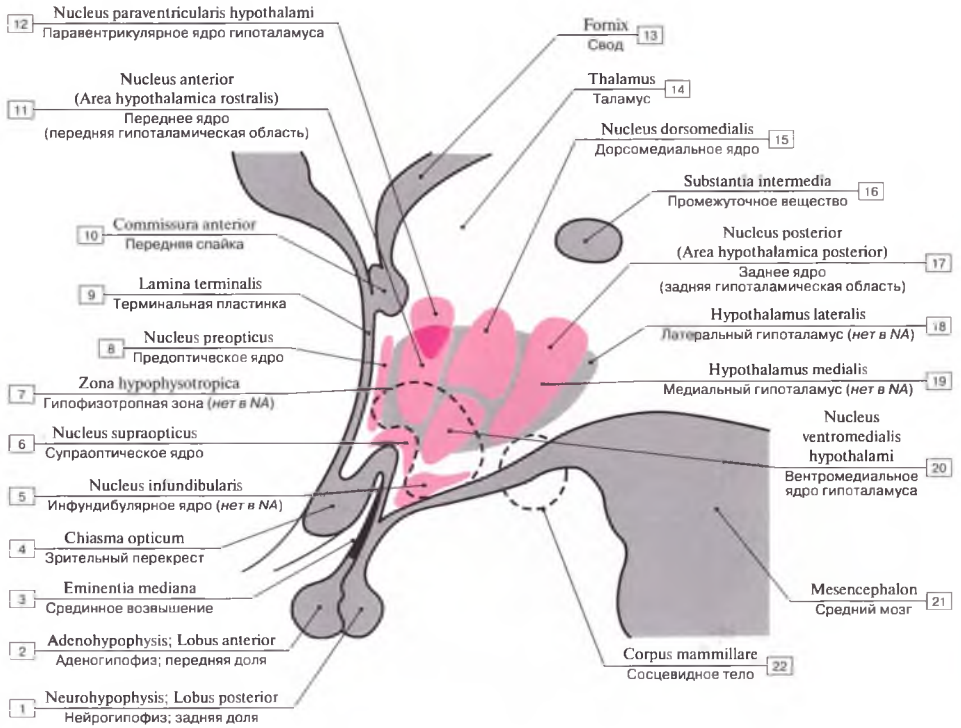


Рис. 97. Ядерные зоны гипоталамуса (схема):

1 – Neurohypophysis; Posterior lobe; 2 – Adenohypophysis; Anterior lobe; 3 – Median eminence; 4 – Optic chiasm; Optic chiasma; 5 – Infundibular nucleus; 6 – Supra-optic nucleus; 7 – Hypophysiotropic zona; 8 – Pre-optic nucleus; 9 – Lamina terminalis; 10 – Anterior commissure; 11 – Anterior nucleus (Anterior hypothalamic area; Anterior hypothalamic region); 12 – Paraventricular nucleus; 13 – Fornix; 14 – Thalamus; Dorsal thalamus; 15 – Dorsomedial nucleus; 16 – Intermediate substance; 17 – Posterior nucleus; Dorsal nucleus (Posterior hypothalamic area; Posterior hypothalamic region); 18 – Lateral hypothalamus; 19 – Medial hypothalamus; 20 – Ventromedial nucleus of hypothalamus; 21 – Mesencephalon; Midbrain; 22 – Mammillary body  
(по Р. Шмидту и Г. Теусу)

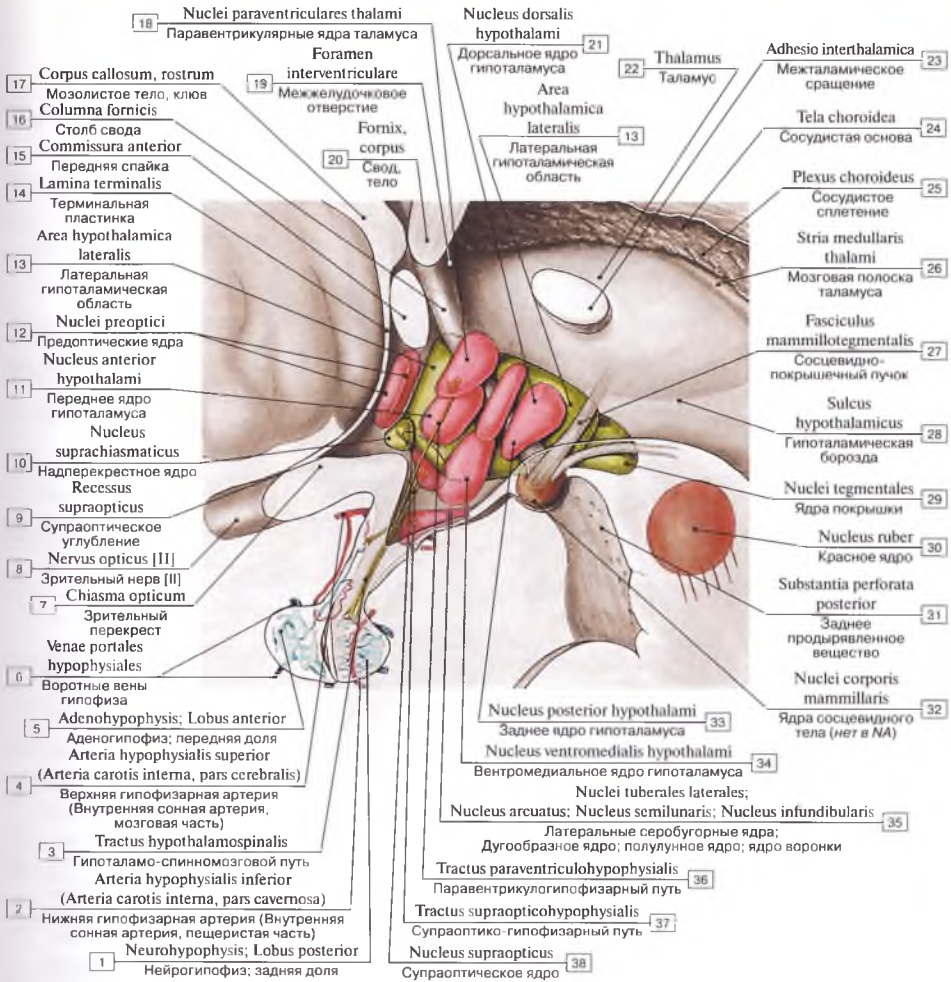


Рис. 98. Ядра гипоталамуса (реконструкция):

- 1 — Neurohypophysis; Posterior lobe; 2 — Inferior hypophysial artery (Internal carotid artery, cavernous part); 3 — Hypothalamospinal tract; 4 — Superior hypophysial artery (Internal carotid artery, cerebral part); 5 — Adenohypophysis; Anterior lobe; 6 — Portal veins of hypophysis; 7 — Optic chiasm; Optic chiasma; 8 — Optic nerve [II]; 9 — Supra-optic recess; 10 — Suprachiasmatic nucleus; 11 — Anterior hypothalamic nucleus; 12 — Pre-optic nucleus; 13 — Lateral hypothalamic area; 14 — Lamina terminalis; 15 — Anterior commissure; 16 — Column of fornix; 17 — Corpus callosum, rostrum; 18 — Paraventricular nuclei of thalamus; 19 — Interventricular foramen; 20 — Fornix, body; 21 — Dorsal nucleus; 22 — Thalamus; Dorsal thalamus; 23 — Interthalamic adhesion; Massa intermedia; 24 — Choroid membrane; 25 — Choroid plexus; 26 — Stria medullaris of thalamus; 27 — Mammillothalamic fasciculus; 28 — Hypothalamic sulcus; 29 — Tegmental nuclei; 30 — Red nucleus; 31 — Posterior perforated substance; 32 — Nuclei of mammillary body; 33 — Posterior nucleus of hypothalamus; 34 — Ventromedial nucleus of hypothalamus; 35 — Arcuate nucleus; Arcuate nucleus; Infundibular nucleus; 36 — Paraventriculohypophysial tract; 37 — Supra-opticohypophysial tract; 38 — Supra-optic nucleus

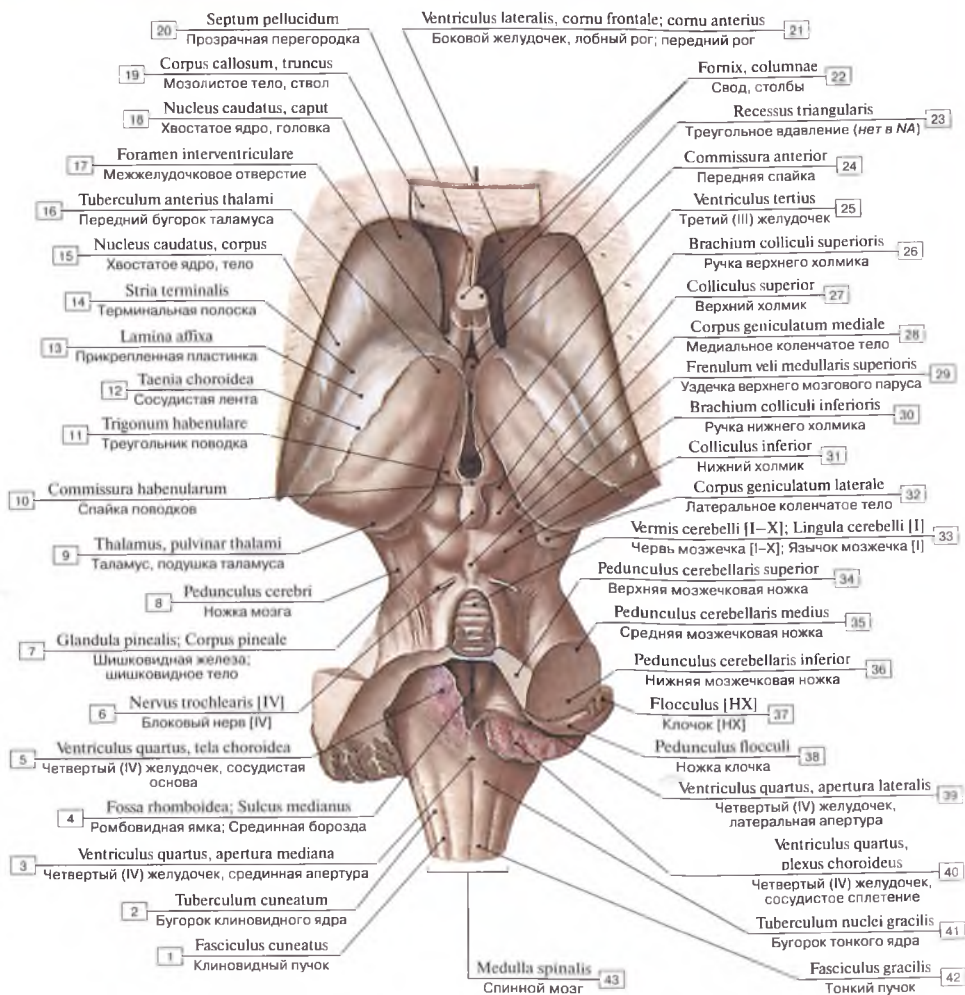


Рис. 99. Ствол мозга, вид сверху:

1 – Cuneate fasciculus; 2 – Cuneate tubercle; 3 – Fourth ventricle, median aperture; 4 – Rhomboid fossa; Floor of fourth ventricle; Median sulcus; 5 – Fourth ventricle, choroid membrane; 6 – Trochlear nerve [IV]; 7 – Pineal gland; Pineal body; 8 – Cerebral peduncle; 9 – Thalamus; Dorsal thalamus, pulvinar; 10 – Habenuular commissure; 11 – Habenuular trigone; 12 – Choroid line; 13 – Lamina affixa; 14 – Stria terminalis; 15 – Caudate nucleus, body; 16 – Anterior thalamic tubercle; 17 – Interventricular foramen; 18 – Caudate nucleus, head; 19 – Corpus callosum, body; trunk; 20 – Septum pellucidum; 21 – Lateral ventricle, frontal horn; anterior horn; 22 – Fornix, columnae; 23 – Triangular recess; 24 – Anterior commissure; 25 – Third ventricle; 26 – Brachium of superior colliculus; 27 – Superior colliculus; 28 – Medial geniculate body; 29 – Frenulum of superior medullary velum; 30 – Brachium of inferior colliculus; 31 – Inferior colliculus; 32 – Lateral geniculate body; 33 – Vermis of cerebellum [I–X]; Lingula [I]; 34 – Superior cerebellar peduncle; 35 – Middle cerebellar peduncle; 36 – Inferior cerebellar peduncle; 37 – Flocculus [HX]; 38 – Peduncle of flocculus; 39 – Fourth ventricle, lateral aperture; 40 – Fourth ventricle, choroid plexus; 41 – Gracile tubercle; 42 – Gracile fasciculus; 43 – Spinal cord

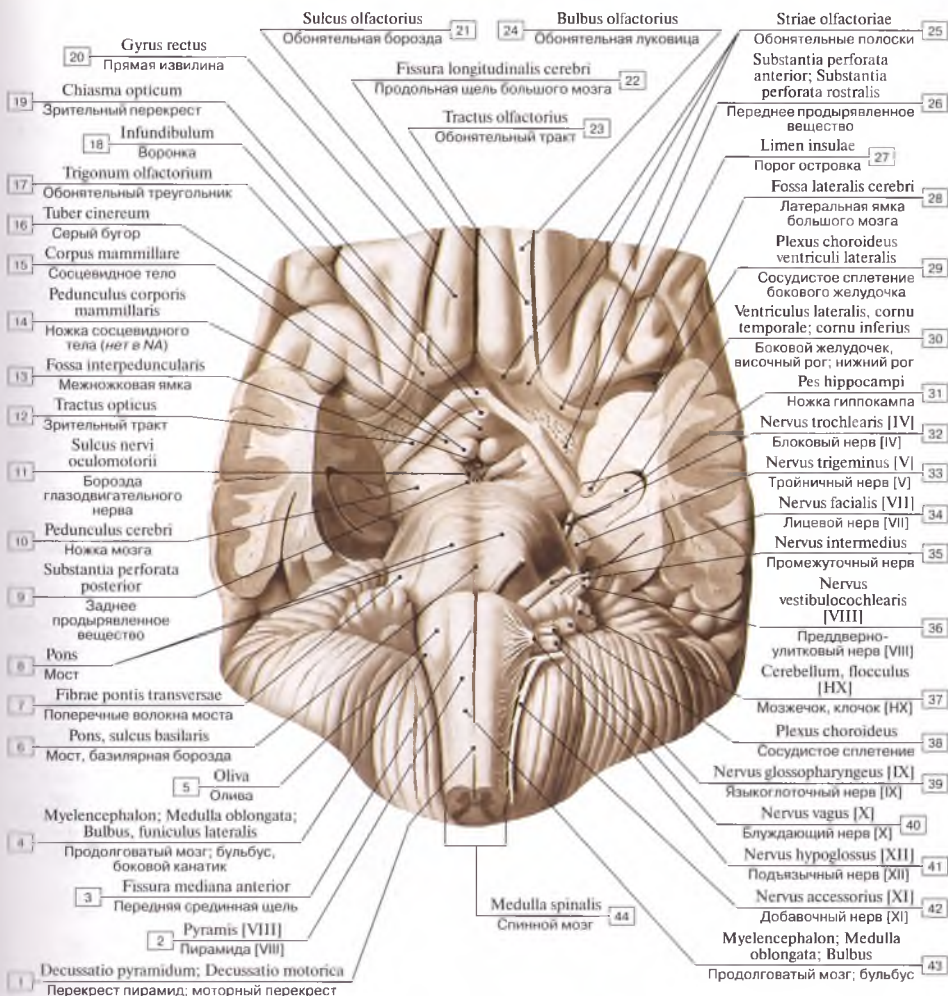


Рис. 100. Ствол мозга, вид снизу:

1 – Decussation of pyramids; Motor decussation; 2 – Pyramid [VIII]; 3 – Anterior median fissure; Ventral median fissure; 4 – Myelencephalon; Medulla oblongata; Bulb. lateral funiculus; 5 – Inferior olive; 6 – Pons, basilar sulcus; 7 – Transverse pontine fibres; 8 – Pons; 9 – Posterior perforated substance; 10 – Cerebral peduncle; 11 – Oculomotor sulcus; 12 – Optic tract; 13 – Interpeduncular fossa; 14 – Peduncle of mammillary body; 15 – Mammillary body; 16 – Tuber cinereum; 17 – Olfactory trigone; 18 – Infundibulum; 19 – Optic chiasm; Optic chiasma; 20 – Straight gyrus; 21 – Olfactory sulcus; 22 – Longitudinal cerebral fissure; 23 – Olfactory tract; 24 – Olfactory bulb; 25 – Olfactory striae; 26 – Anterior perforated substance; 27 – Limen insulae; 28 – Lateral cerebral fossa; 29 – Choroid plexus of lateral ventricle; 30 – Lateral ventricle, temporal horn; inferior horn; 31 – Pes of hippocampus; 32 – Trochlear nerve [IV]; 33 – Trigeminal nerve [V]; 34 – Facial nerve [VII]; 35 – Intermediate nerve; 36 – Vestibulocochlear nerve [VIII]; 37 – Cerebellum, flocculus [HX]; 38 – Choroid plexus; 39 – Glossopharyngeal nerve [IX]; 40 – Vagus nerve [X]; 41 – Hypoglossal nerve [XII]; 42 – Accessory nerve [XI]; 43 – Myelencephalon; Medulla oblongata; Bulb; 44 – Spinal cord

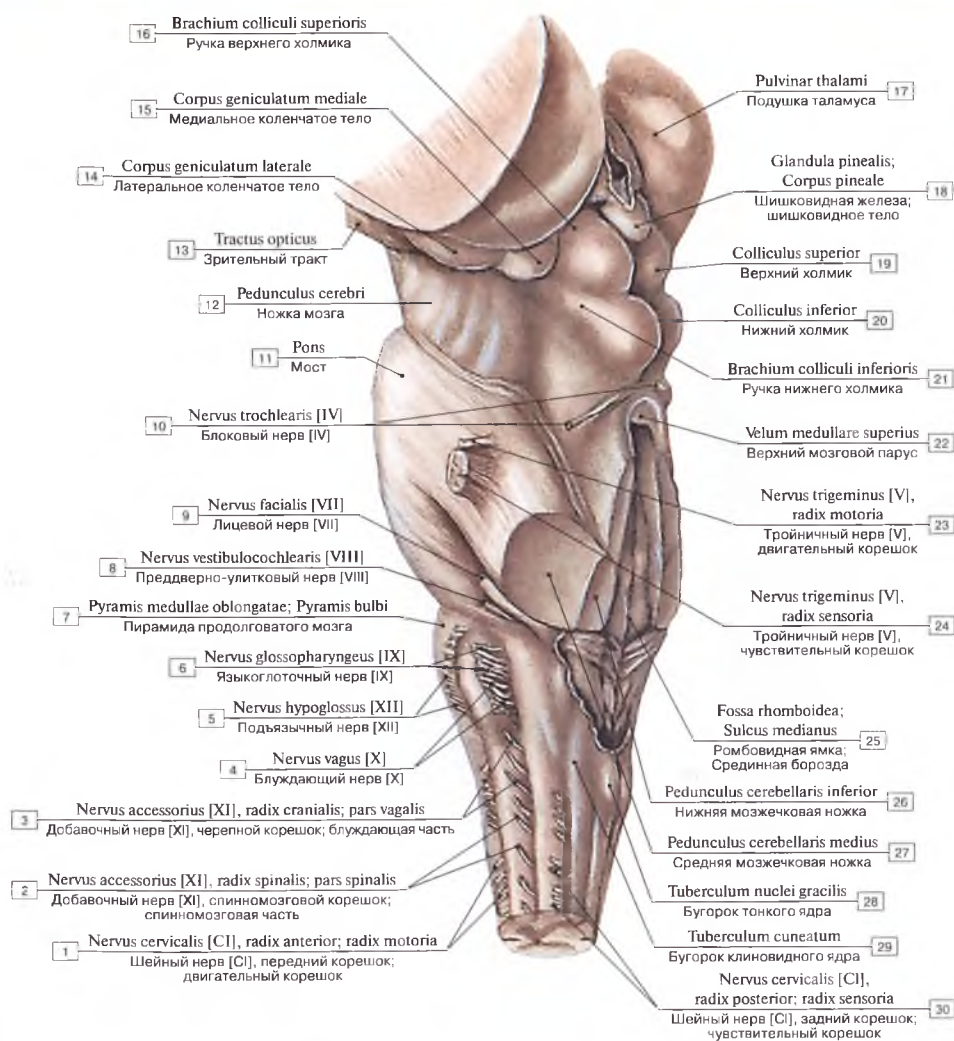


Рис. 101. Средний мозг, продолговатый мозг, вид сбоку:

1 – Cervical nerve [C], anterior root; motor root; ventral root; 2 – Accessory nerve [XI], spinal root; spinal part; 3 – Accessory nerve [XI], cranial root; vagal part; 4 – Vagus nerve [X]; 5 – Hypoglossal nerve [XII]; 6 – Glossopharyngeal nerve [IX]; 7 – Pyramid; 8 – Vestibulocochlear nerve [VIII]; 9 – Facial nerve [VII]; 10 – Trochlear nerve [IV]; 11 – Pons; 12 – Cerebral peduncle; 13 – Optic tract; 14 – Lateral geniculate body; 15 – Medial geniculate body; 16 – Brachium of superior colliculus; 17 – Pulvinar; 18 – Pineal gland; Pineal body; 19 – Superior colliculus; 20 – Inferior colliculus; 21 – Brachium of inferior colliculus; 22 – Superior medullary velum; 23 – Trigeminal nerve [V], motor root; 24 – Trigeminal nerve [V], sensory root; 25 – Rhomboid fossa; Floor of fourth ventricle; Median sulcus; 26 – Inferior cerebellar peduncle; 27 – Middle cerebellar peduncle; 28 – Gracile tubercle; 29 – Cuneate tubercle; 30 – Cervical nerve [C], posterior root; sensory root; dorsal root

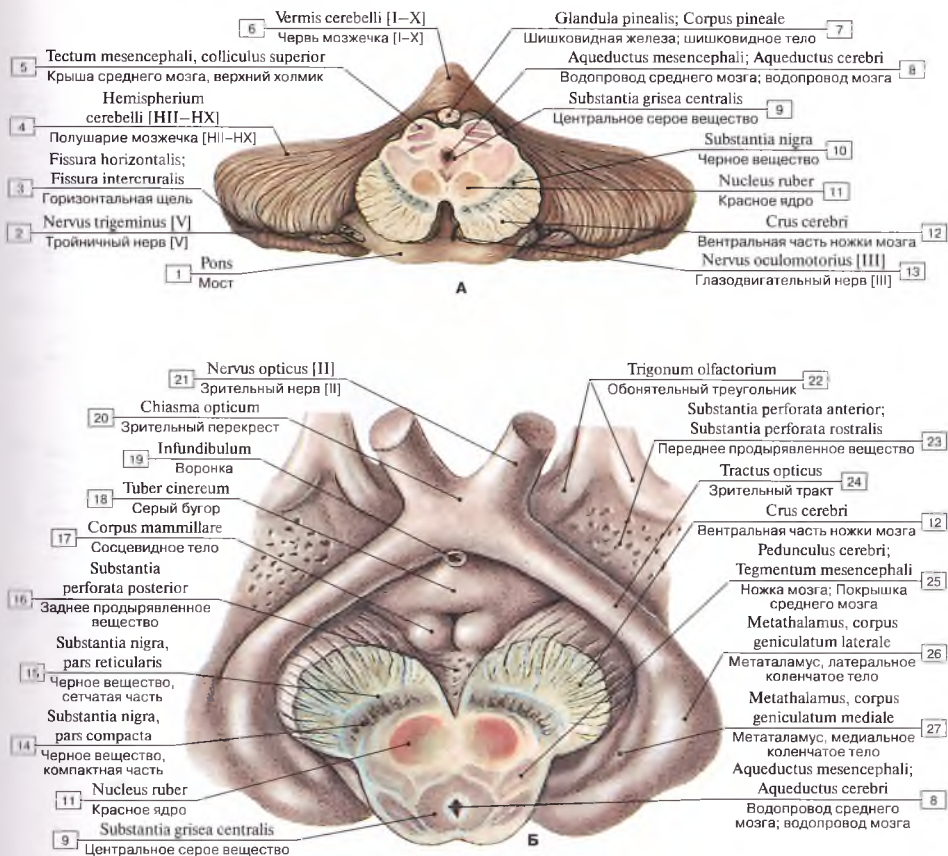


Рис. 102. Средний мозг  
(А – поперечный разрез на уровне верхних холмиков пластинки четверохолмия, вид спереди;  
Б – поперечный разрез, промежуточный и средний мозг, вид снизу, реконструкция):

1 – Pons; 2 – Trigeminal nerve [V]; 3 – Horizontal fissure; Intercrural fissure; 4 – Hemisphere of cerebellum [HII–HX]; 5 – Tectum of midbrain; superior colliculus; 6 – Vermis of cerebellum [I–X]; 7 – Pineal gland; Pineal body; 8 – Aqueduct of midbrain; Cerebral aqueduct; 9 – Periaqueductal grey substance; Central grey substance; 10 – Substantia nigra; 11 – Red nucleus; 12 – Cerebral crus; 13 – Oculomotor nerve [III]; 14 – Substantia nigra, compact part; 15 – Substantia nigra, reticular part; 16 – Posterior perforated substance; 17 – Mammillary body; 18 – Tuber cinereum; 19 – Infundibulum; 20 – Optic chiasm; Optic chiasma; 21 – Optic nerve [II]; 22 – Olfactory trigone; 23 – Anterior perforated substance; 24 – Optic tract; 25 – Cerebral peduncle; Tegmentum of midbrain; 26 – Metathalamus, lateral geniculate body; 27 – Metathalamus, medial geniculate body

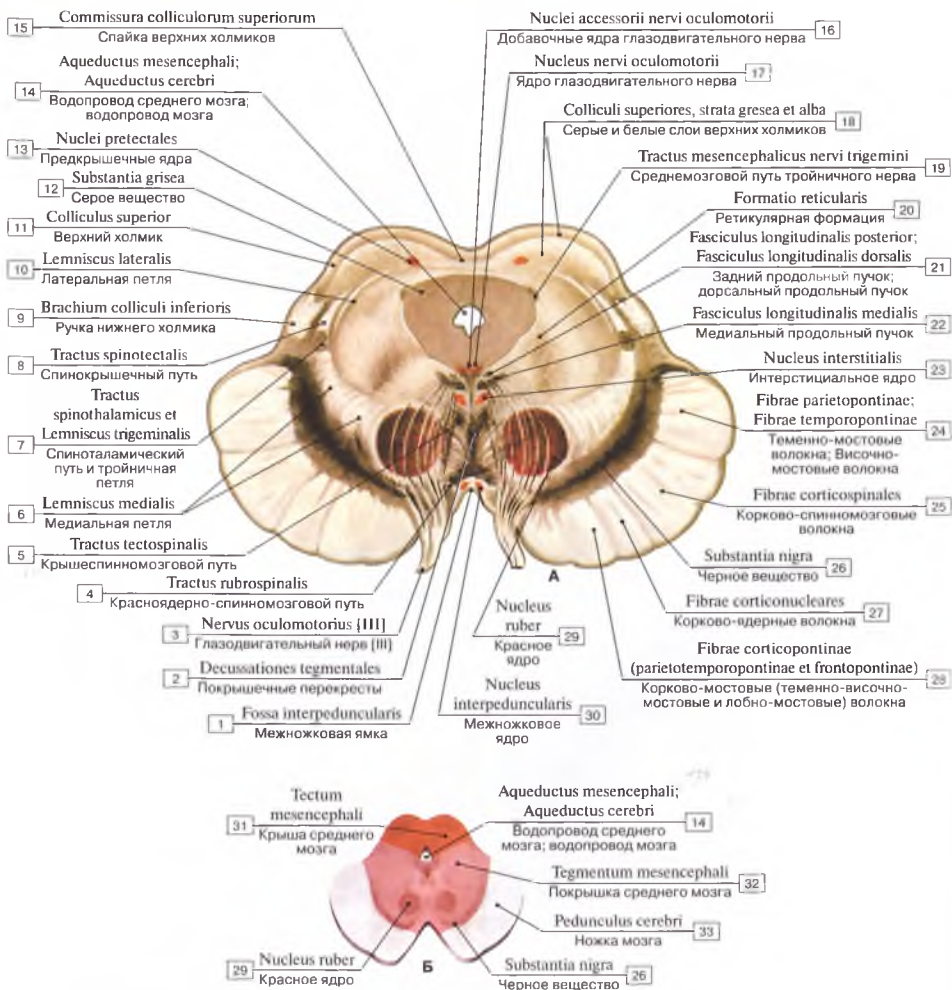


Рис. 103. Средний мозг, поперечный разрез (А – общий план строения; Б – отдели):

1 – Interpeduncular fossa; 2 – Tegmental decussations; 3 – Oculomotor nerve [III]; 4 – Rubrospinal tract; 5 – Tectospinal tract; 6 – Medial lemniscus; 7 – Spinothalamic tract and Trigeminal lemniscus; 8 – Spinotectal tract; 9 – Brachium of caudal colliculus; 10 – Lateral lemniscus; 11 – Superior colliculus; 12 – Grey substance; 13 – Pretectal nuclei; 14 – Aqueduct of midbrain; Cerebral aqueduct; 15 – Commissure of superior colliculus; 16 – Accessory nuclei of oculomotor nerve; 17 – Nucleus of oculomotor nerve; 18 – Superior colliculus, layers grey and white; 19 – Mesencephalic tract of trigeminal nerve; 20 – Reticular formation; 21 – Posterior longitudinal fasciculus; Dorsal longitudinal fasciculus; 22 – Medial longitudinal fasciculus; 23 – Interstitial nucleus; 24 – Parietopontine fibres; Temporopontine fibres; 25 – Corticospinal fibres; 26 – Substantia nigra; 27 – Corticonuclear fibres; 28 – Fibres corticopontine (parietotemporo-pontine and frontopontine); 29 – Red nucleus; 30 – Interpeduncular nucleus; 31 – Tectum of midbrain; 32 – Tegmentum of midbrain; 33 – Cerebral peduncle

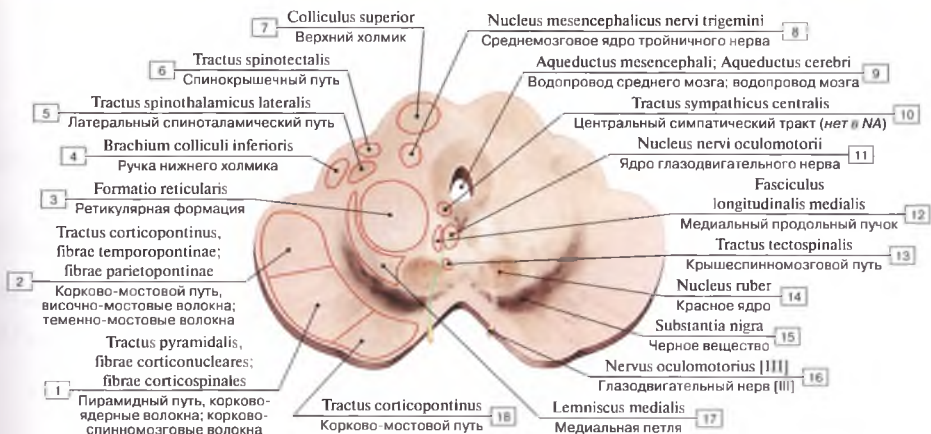


Рис. 104. Средний мозг, поперечный разрез:

1 – Pyramidal tract, corticonuclear fibres; corticospinal fibres; 2 – Corticopontine tract, temporo-pontine fibres; parietopontine fibres; 3 – Reticular formation; 4 – Brachium of inferior colliculus; 5 – Lateral spinothalamic tract; 6 – Spinotectal tract; 7 – Superior colliculus; 8 – Mesencephalic nucleus of trigeminal nerve; 9 – Aqueduct of midbrain; Cerebral aqueduct; 10 – Central sympathetic tract; 11 – Nucleus of oculomotor nerve; 12 – Medial longitudinal fasciculus; 13 – Tectospinal tract; 14 – Red nucleus; 15 – Substantia nigra; 16 – Oculomotor nerve [III]; 17 – Medial lemniscus; 18 – Corticopontine tract

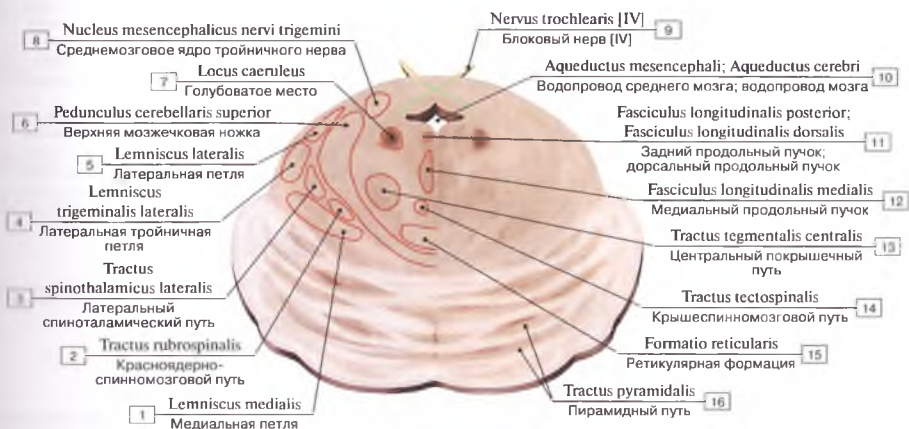


Рис. 105. Мост, поперечный разрез:

1 – Medial lemniscus; 2 – Rubrospinal tract; 3 – Lateral spinothalamic tract; 4 – Lateral trigeminal lemniscus; 5 – Lateral lemniscus; 6 – Superior cerebellar peduncle; 7 – Locus caeruleus; 8 – Mesencephalic nucleus of trigeminal nerve; 9 – Trochlear nerve [IV]; 10 – Aqueduct of midbrain; Cerebral aqueduct; 11 – Posterior longitudinal fasciculus; Dorsal longitudinal fasciculus; 12 – Medial longitudinal fasciculus; 13 – Central tegmental tract; 14 – Tectospinal tract; 15 – Reticular formation; 16 – Pyramidal tract



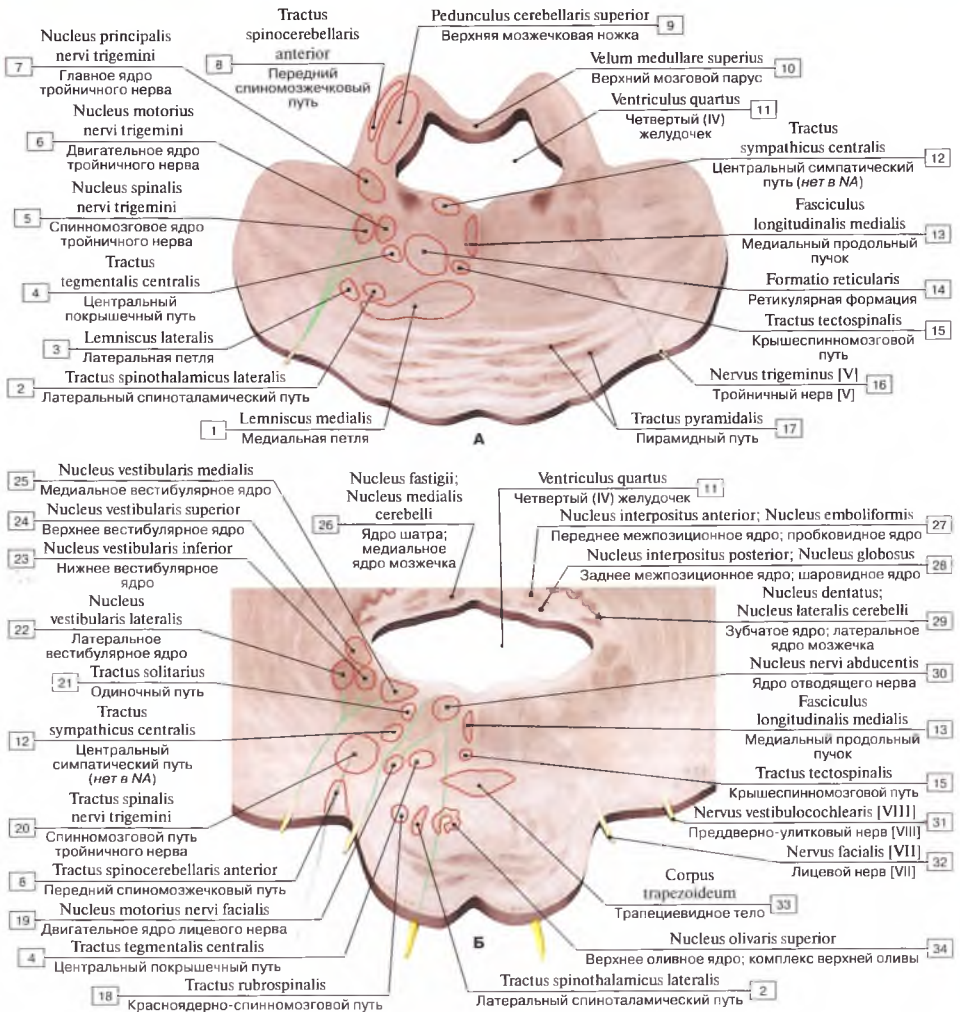


Рис. 106. Мост, поперечные срезы (А – через средний отдел; Б – через нижний отдел):

1 – Medial lemniscus; 2 – Lateral spinothalamic tract; 3 – Lateral lemniscus; 4 – Central tegmental tract; 5 – Spinal nucleus of trigeminal nerve; 6 – Motor nucleus of trigeminal nerve; 7 – Principal sensory nucleus of trigeminal nerve; 8 – Anterior spinocerebellar tract; 9 – Superior cerebellar peduncle; 10 – Superior medullary velum; 11 – Fourth ventricle; 12 – Central sympathetic tract; 13 – Medial longitudinal fasciculus; 14 – Reticular formation; 15 – Tectospinal tract; 16 – Trigeminal nerve [V]; 17 – Pyramidal tract; 18 – Rubrospinal tract; 19 – Motor nucleus of facial nerve; 20 – Spinal tract of trigeminal nerve; 21 – Solitary tract; 22 – Lateral vestibular nucleus; 23 – Inferior vestibular nucleus; 24 – Superior vestibular nucleus; 25 – Medial vestibular nucleus; 26 – Fastigial nucleus; 27 – Anterior interpositus nucleus; 28 – Posterior interpositus nucleus; 29 – Dentate nucleus; 30 – Nucleus of abducens nerve; 31 – Vestibulocochlear nerve [VIII]; 32 – Facial nerve [VII]; 33 – Trapezoid body; 34 – Superior olivary nucleus; Superior olivary complex

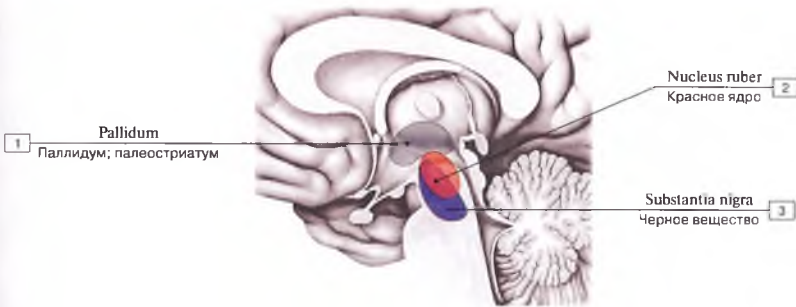


Рис. 107. Средний мозг, черное вещество и красное ядро:

1 – Pallidum; Paleostriatum; 2 – Red nucleus; 3 – Substantia nigra

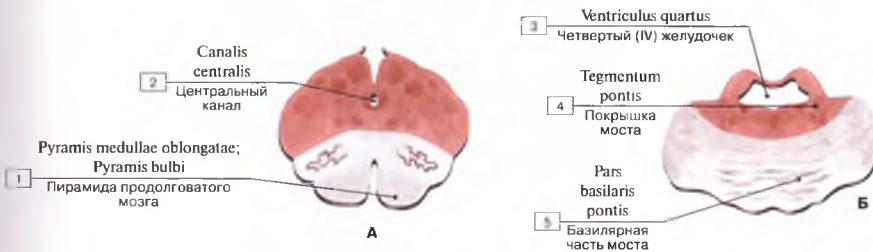


Рис. 108. Структура ствола мозга в поперечных сечениях через продолговатый мозг (А) и мост (Б), вид сверху:

1 – Pyramid; 2 – Central canal; 3 – Fourth ventricle; 4 – Tegmentum of pons; 5 – Basilar part of pons

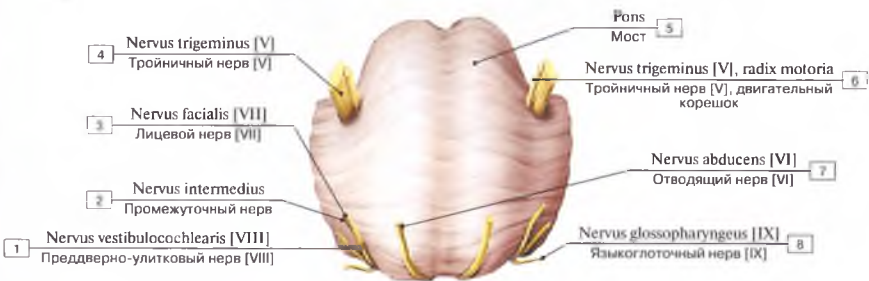


Рис. 109. Мост:

1 – Vestibulocochlear nerve [VIII]; 2 – Intermediate nerve; 3 – Facial nerve [VII]; 4 – Trigeminal nerve [V]; 5 – Pons; 6 – Trigeminal nerve [V], motor root; 7 – Abducent nerve; Abducens nerve [VI]; 8 – Glossopharyngeal nerve [IX]

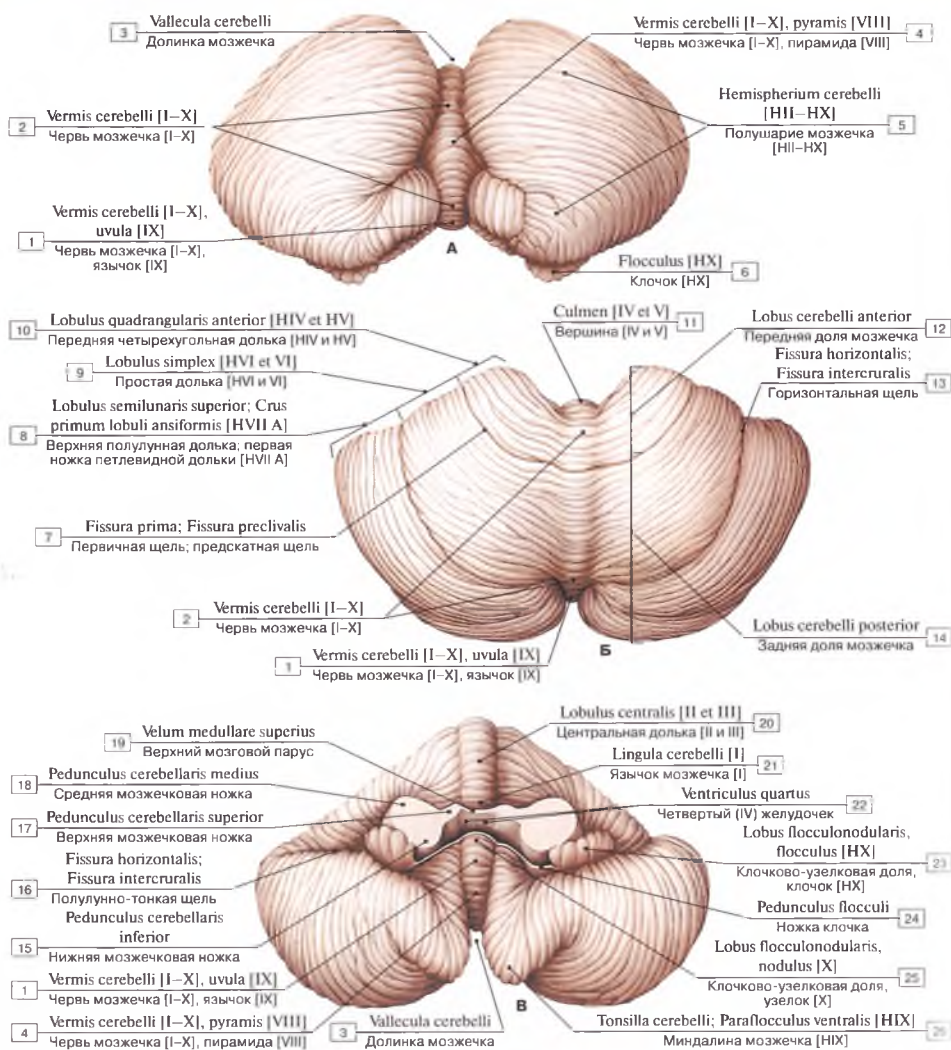


Рис. 110. Мозжечок, отделенный от головного мозга (А – вид снизу; Б – вид сверху; В – вид спереди):

1 – Vermis of cerebellum [I-X], uvula [IX]; 2 – Vermis of cerebellum [I-X]; 3 – Vallecule of cerebellum; 4 – Vermis of cerebellum [I-X], pyramid [VIII]; 5 – Hemisphere of cerebellum [HII-HX]; 6 – Flocculus [HX]; 7 – Primary fissure; Preclival fissure; 8 – Superior semilunar lobe; First crus of ansiform lobe [HVII A]; 9 – Simple lobe [HVI et VI]; 10 – Anterior quadrangular lobe [HIV and HV]; 11 – Culmen [IV and V]; 12 – Anterior lobe of cerebellum; 13 – Horizontal fissure; Intercrural fissure; 14 – Anterior lobe of cerebellum; 15 – Inferior cerebellar peduncle; 16 – Horizontal fissure; Intercrural fissure; 17 – Superior cerebellar peduncle; 18 – Middle cerebellar peduncle; 19 – Superior medullary velum; 20 – Central lobule [II and III]; 21 – Lingula [I]; 22 – Fourth ventricle; 23 – Flocculonodular lobe, flocculus [HX]; 24 – Peduncle of flocculus; 25 – Flocculonodular lobe, nodule [X]; 26 – Tonsil of cerebellum; Ventral parafocculus [HIX]

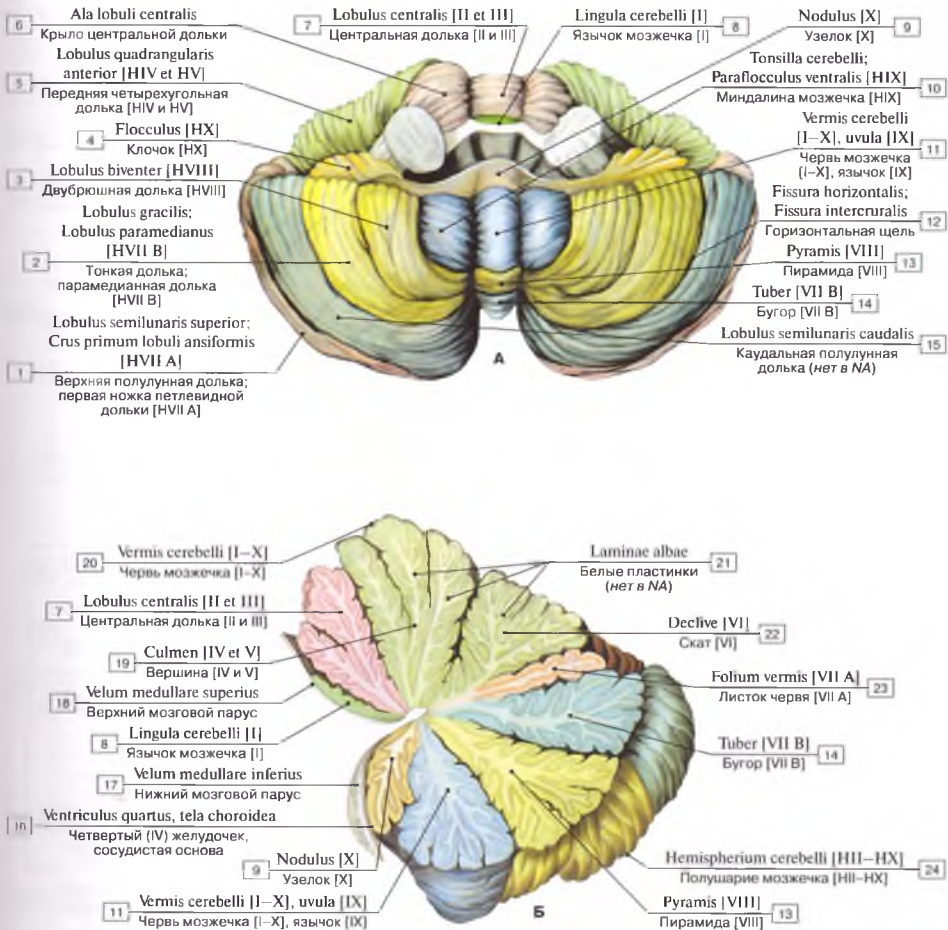


Рис. 111. Отделы мозжечка (А – вид сверху; Б – срединный разрез через червь):

1 – Superior semilunar lobule; First crus of ansiform lobule [HVII A]; 2 – Gracile lobule; Paramedian lobule [HVII B]; 3 – Biventral lobule [HVIII]; 4 – Flocculus [HX]; 5 – Anterior quadrangular lobule [HIV and HV]; 6 – Wing of central lobule; 7 – Central lobule [II and III]; 8 – Lingula [I]; 9 – Nodule [X]; 10 – Tonsil of cerebellum; Ventral paraflocculus [HIX]; 11 – Vermis of cerebellum [I–X], uvula [IX]; 12 – Horizontal fissure; Intercruial fissure; 13 – Pyramid [VIII]; 14 – Tuber [VII B]; 15 – Caudate semilunar lobule; 16 – Fourth ventricle, choroid membrane; 17 – Inferior medullary velum; 18 – Superior medullary velum; 19 – Culmen [IV and V]; 20 – Vermis of cerebellum [I–X]; 21 – White plate; 22 – Declive [VI]; 23 – Folium of vermis [VII A]; 24 – Hemisphere of cerebellum [HII–HX]

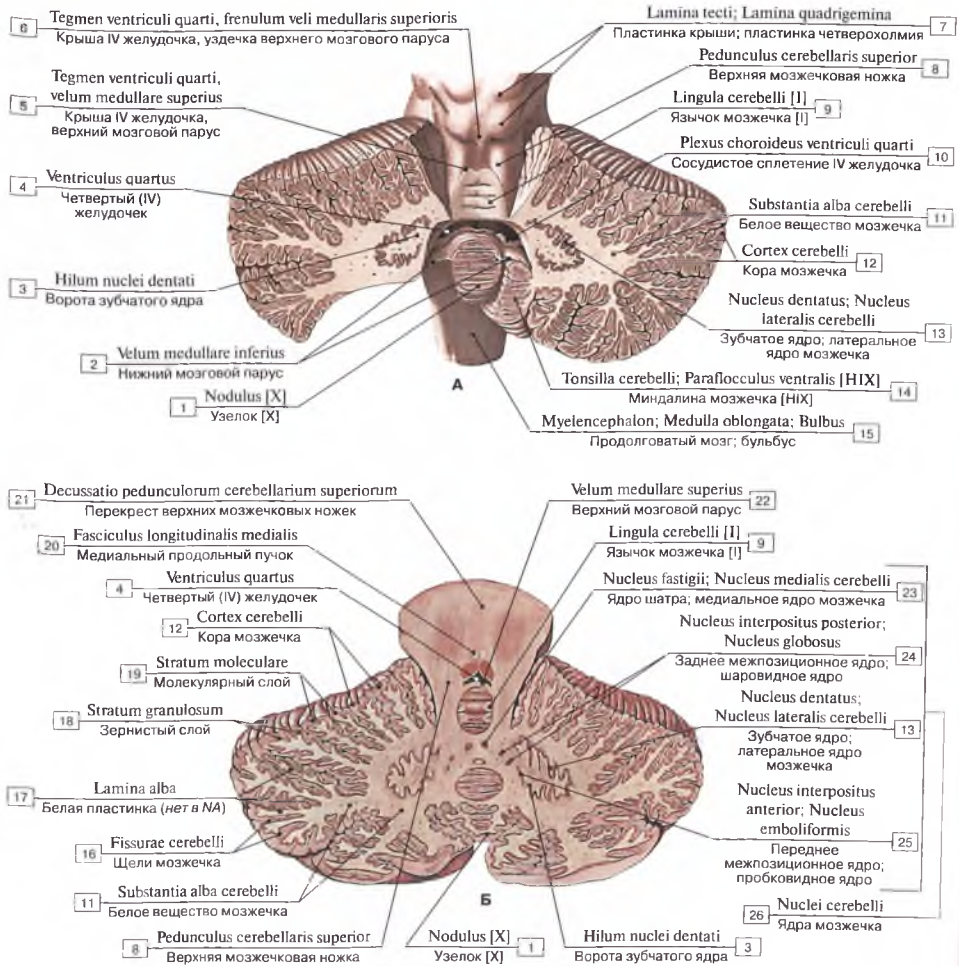


Рис. 112. Кора и зубчатые ядра мозжечка, косой срез, вид сзади (А); мозжечок, косой срез на уровне верхних мозжечковых ножек, вид сзади (Б):

1 – Nodule [X]; 2 – Inferior medullary velum; 3 – Hilum of dentate nucleus; 4 – Fourth ventricle; 5 – Root of fourth ventricle, superior medullary velum; 6 – Root of fourth ventricle, frenulum of superior medullary velum; 7 – Tectal plate; Quadrigeminal plate; 8 – Superior cerebellar peduncle; 9 – Lingula [I]; 10 – Choroid plexus of fourth ventricle; 11 – White substance of cerebellum; 12 – Cerebellar cortex; 13 – Dentate nucleus; Nucleus lateralis cerebelli; 14 – Tonsil of cerebellum; Ventral parafocculus [HIX]; 15 – Myelencephalon; Medulla oblongata; Bulb; 16 – Cerebellar fissures; 17 – White lamina; 18 – Granular layer; 19 – Molecular layer; 20 – Medial longitudinal fasciculus; 21 – Decussation of superior cerebellar peduncles; 22 – Superior medullary velum; 23 – Fastigial nucleus; Nucleus medialis cerebelli; 24 – Posterior interpositus nucleus; Globose nucleus; 25 – Anterior interpositus nucleus; Emboliform nucleus; 26 = 13 + 23 + 24 + 25 – Cerebellar nuclei

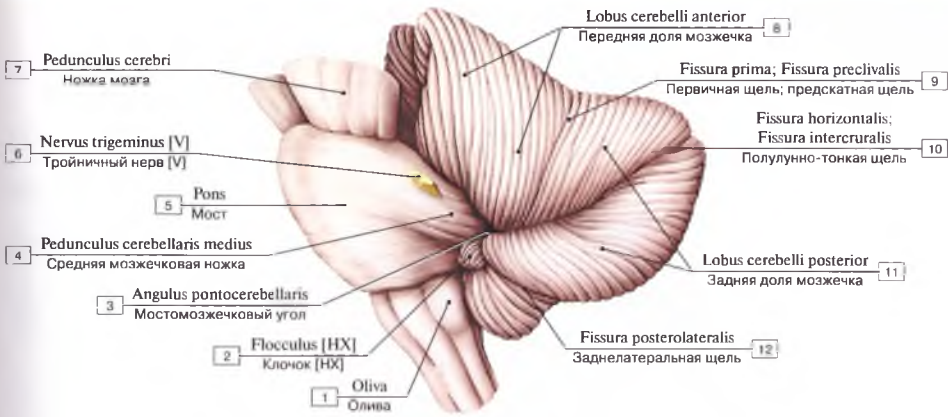


Рис. 113. Мозжечок и ствол мозга, вид слева:

- 1 – Inferior olive; 2 – Flocculus [HX]; 3 – Cerebellopontine angle; 4 – Middle cerebellar peduncle; 5 – Pons; 6 – Trigeminal nerve [V]; 7 – Cerebral peduncle; 8 – Anterior lobe of cerebellum; 9 – Primary fissure; Preclival fissure; 10 – Horizontal fissure; Intercrural fissure; 11 – Posterior lobe of cerebellum; 12 – Posterolateral fissure

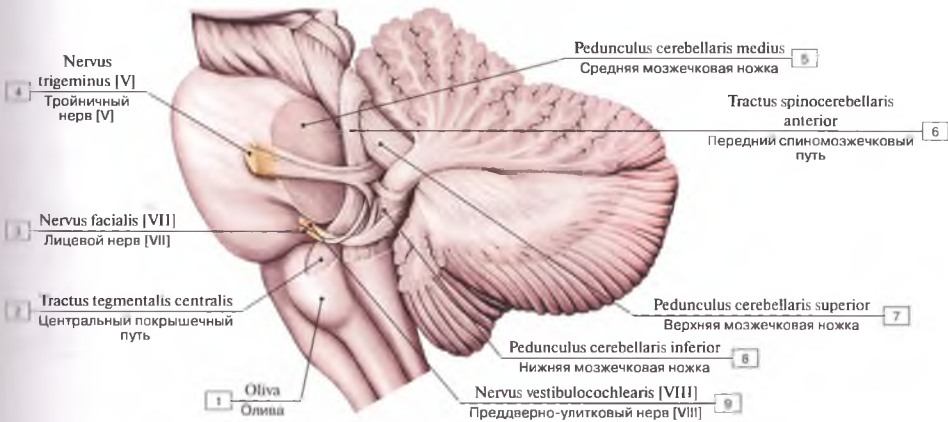
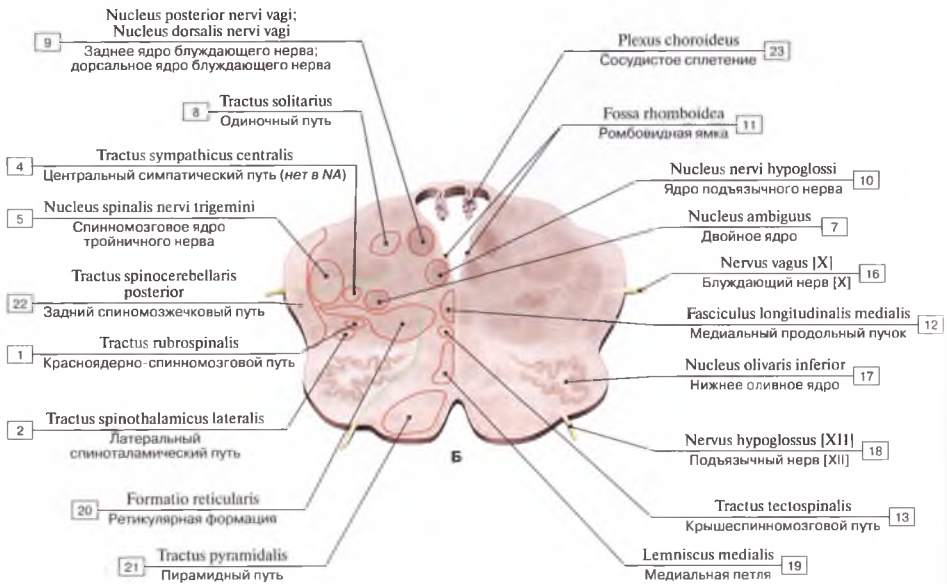
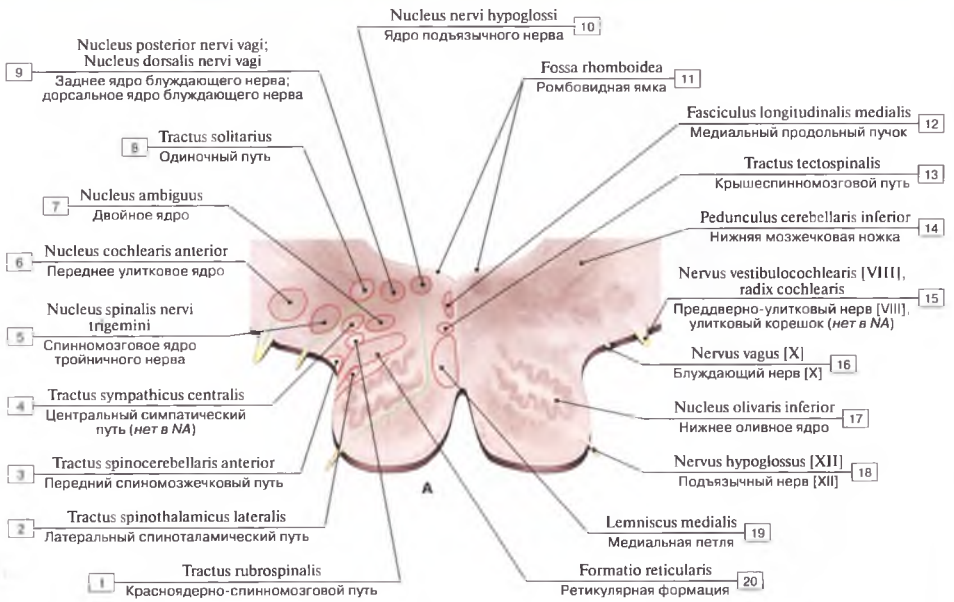


Рис. 114. Ножки мозжечка, вид слева (верхняя часть мозжечка и латеральные части моста удалены):

- 1 – Inferior olive; 2 – Central tegmental tract; 3 – Facial nerve [VII]; 4 – Trigeminal nerve [V]; 5 – Middle cerebellar peduncle; 6 – Anterior spinocerebellar tract; 7 – Superior cerebellar peduncle; 8 – Inferior cerebellar peduncle; 9 – Vestibulocochlear nerve [VIII]



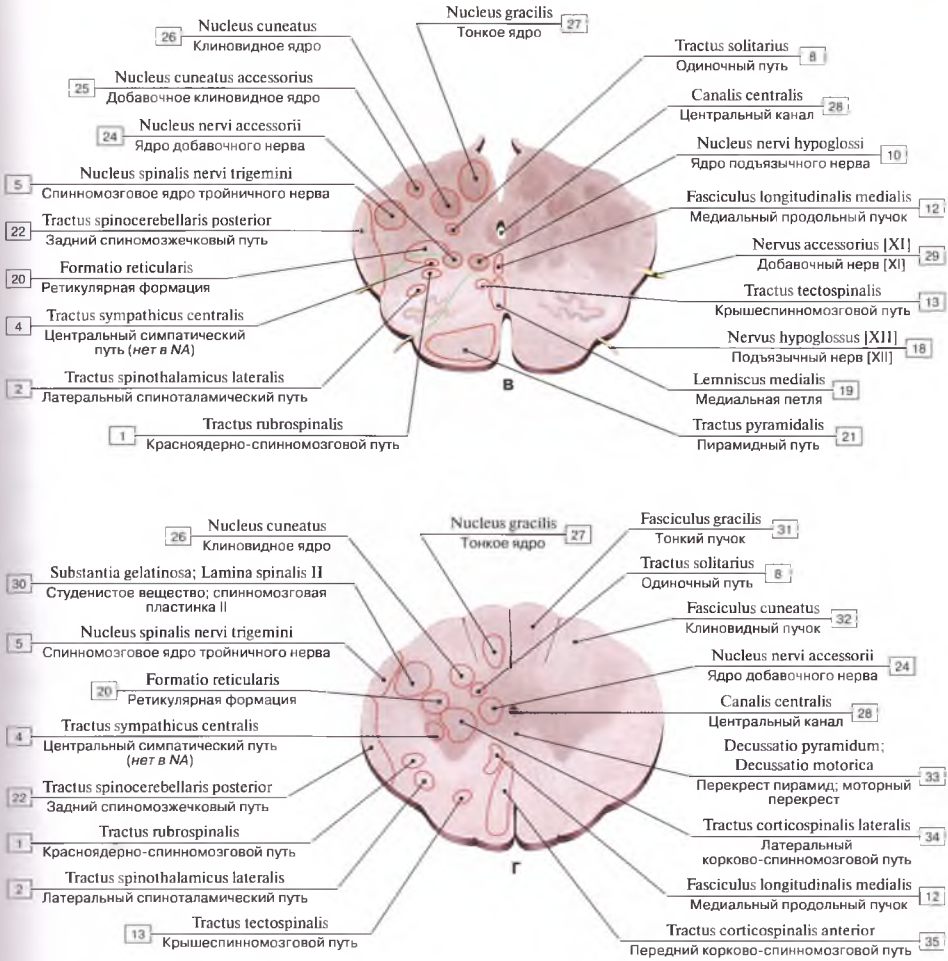


Рис. 115. Продолговатый мозг — поперечные разрезы на разных уровнях:

1 — Rubrospinal tract; 2 — Lateral spinothalamic tract; 3 — Anterior spinocerebellar tract; Ventral spinocerebellar tract; 4 — Central sympathetic tract; 5 — Spinal nucleus of trigeminal nerve; 6 — Anterior cochlear nucleus; Ventral cochlear nucleus; 7 — Nucleus ambiguus; 8 — Solitary tract; 9 — Posterior nucleus of vagus nerve; Dorsal nucleus of vagus nerve; 10 — Nucleus of hypoglossal nerve; 11 — Rhomboid fossa; Floor of fourth ventricle; 12 — Medial longitudinal fasciculus; 13 — Tectospinal tract; 14 — Inferior cerebellar peduncle; 15 — Vestibulocochlear nerve [VIII], cochlear root; 16 — Vagus nerve [X]; 17 — Inferior olivary nucleus; 18 — Hypoglossal nerve [XII]; 19 — Medial lemniscus; 20 — Reticular formation; 21 — Pyramidal tract; 22 — Posterior spinocerebellar tract; Dorsal spinocerebellar tract; 23 — Choroid plexus; 24 — Nucleus of accessory nerve; 25 — Accessory cuneate nucleus; 26 — Cuneate nucleus; 27 — Gracile nucleus; 28 — Central canal; 29 — Accessory nerve [XI]; 30 — Gelatinous substance; Spinal lamina II; 31 — Gracile fasciculus; 32 — Cuneate fasciculus; 33 — Decussation of pyramids; Motor decussation; 34 — Lateral corticospinal tract; 35 — Anterior corticospinal tract; Ventral corticospinal tract



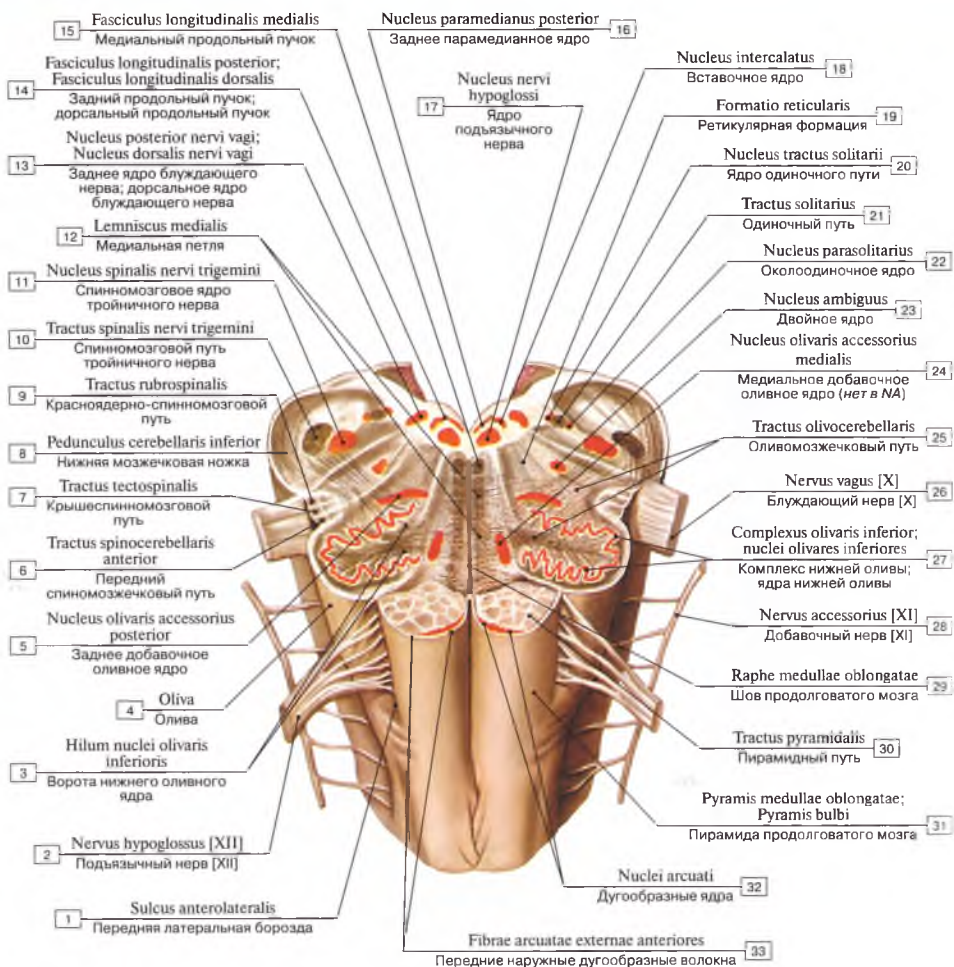
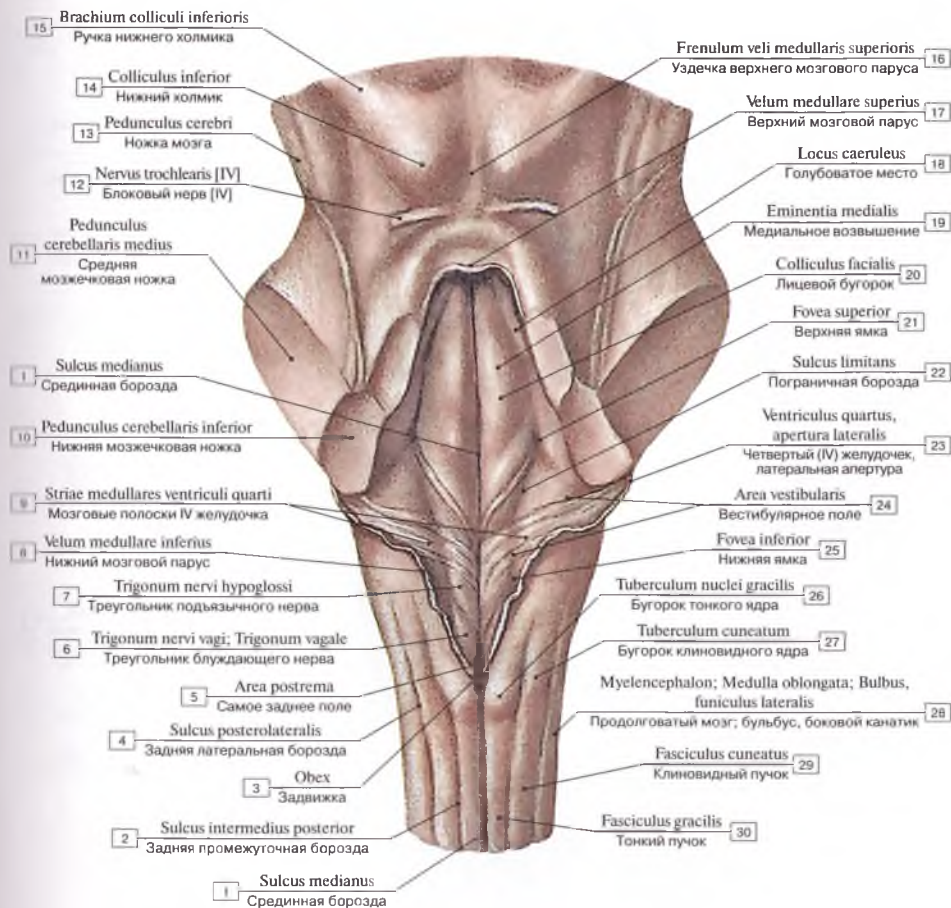


Рис. 116. Продолговатый мозг, вид спереди:

1 – Anterolateral sulcus; Ventrolateral sulcus; 2 – Hypoglossal nerve [XII]; 3 – Hilum of inferior olivary nucleus; 4 – Inferior olive; 5 – Posterior accessory olivary nucleus; Dorsal accessory olivary nucleus; 6 – Anterior spinocerebellar tract; Ventral spinocerebellar tract; 7 – Tectospinal tract; 8 – Inferior cerebellar peduncle; 9 – Rubrospinal tract; 10 – Spinal tract of trigeminal nerve; 11 – Spinal nucleus of trigeminal nerve; 12 – Medial lemniscus; 13 – Posterior nucleus of vagus nerve; Dorsal nucleus of vagus nerve; 14 – Posterior longitudinal fasciculus; Dorsal longitudinal fasciculus; 15 – Medial longitudinal fasciculus; 16 – Posterior paramedian nucleus; Dorsal paramedian nucleus; 17 – Nucleus of hypoglossal nerve; 18 – Intercalated nucleus; 19 – Reticular formation; 20 – Nucleus of solitary tract; Solitary nucleus; 21 – Solitary tract; 22 – Parasolitary nucleus; 23 – Nucleus ambiguus; 24 – Medial accessory olivary nucleus; 25 – Olivocerebellar tract; 26 – Vagus nerve [X]; 27 – Inferior olivary complex; 28 – Accessory nerve [XI]; 29 – Raphe of medulla oblongata; 30 – Pyramidal tract; 31 – Pyramid; 32 – Arcuate nuclei; 33 – Anterior external arcuate fibres; Ventral external arcuate fibres



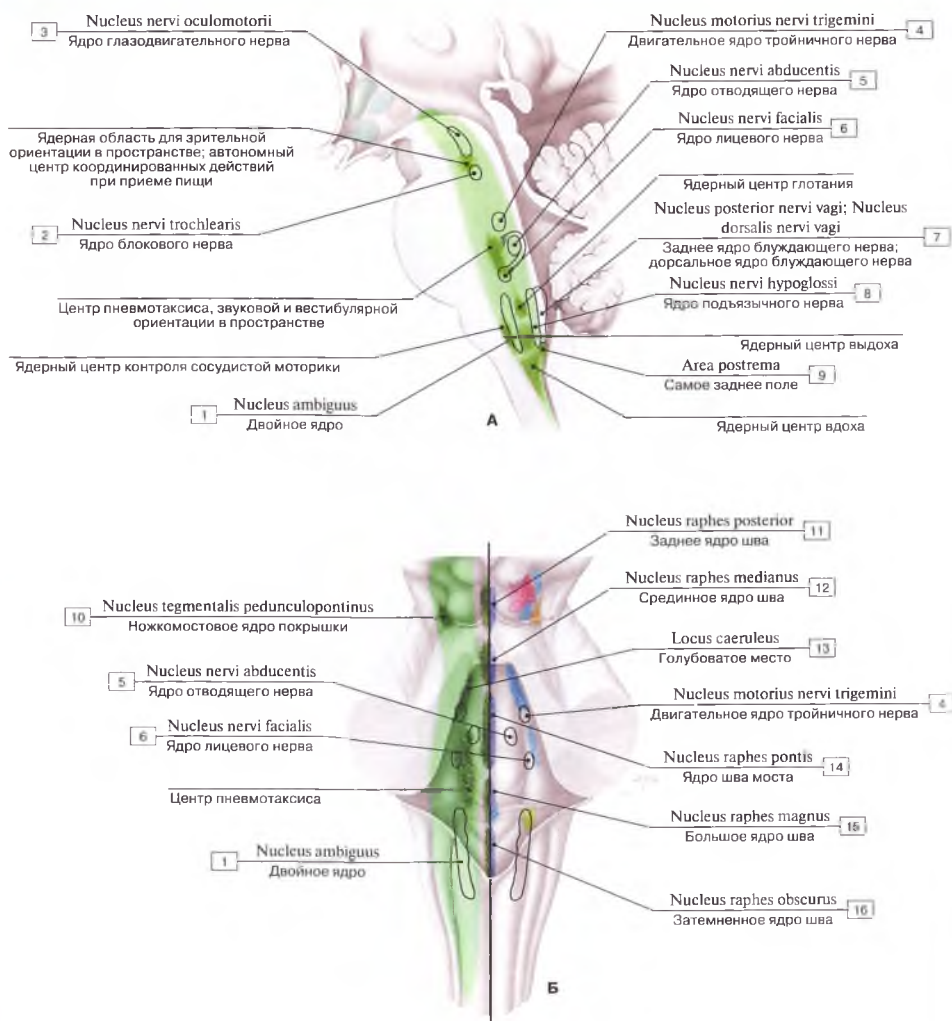


Рис. 118. Ядра продолговатого мозга (А – структурно-функциональные взаимоотношения в ретикулярной формации; Б – области ядер и нейромедиаторы в ретикулярной формации):

1 – Nucleus ambiguus; 2 – Nucleus of trochlear nerve; 3 – Nucleus of oculomotor nerve; 4 – Motor nucleus of trigeminal nerve; 5 – Nucleus of abducens nerve; 6 – Motor nucleus of facial nerve; 7 – Posterior nucleus of vagus nerve; Dorsal nucleus of vagus nerve; 8 – Nucleus of hypoglossal nerve; 9 – Area postrema; 10 – Pedunculo-pontine tegmental nucleus; 11 – Posterior raphe nucleus; Dorsal raphe nucleus; 12 – Median raphe nucleus; Superior central nucleus; 13 – Locus caeruleus; 14 – Pontine raphe nucleus; 15 – Magnus raphe nucleus; 16 – Obscure raphe nucleus

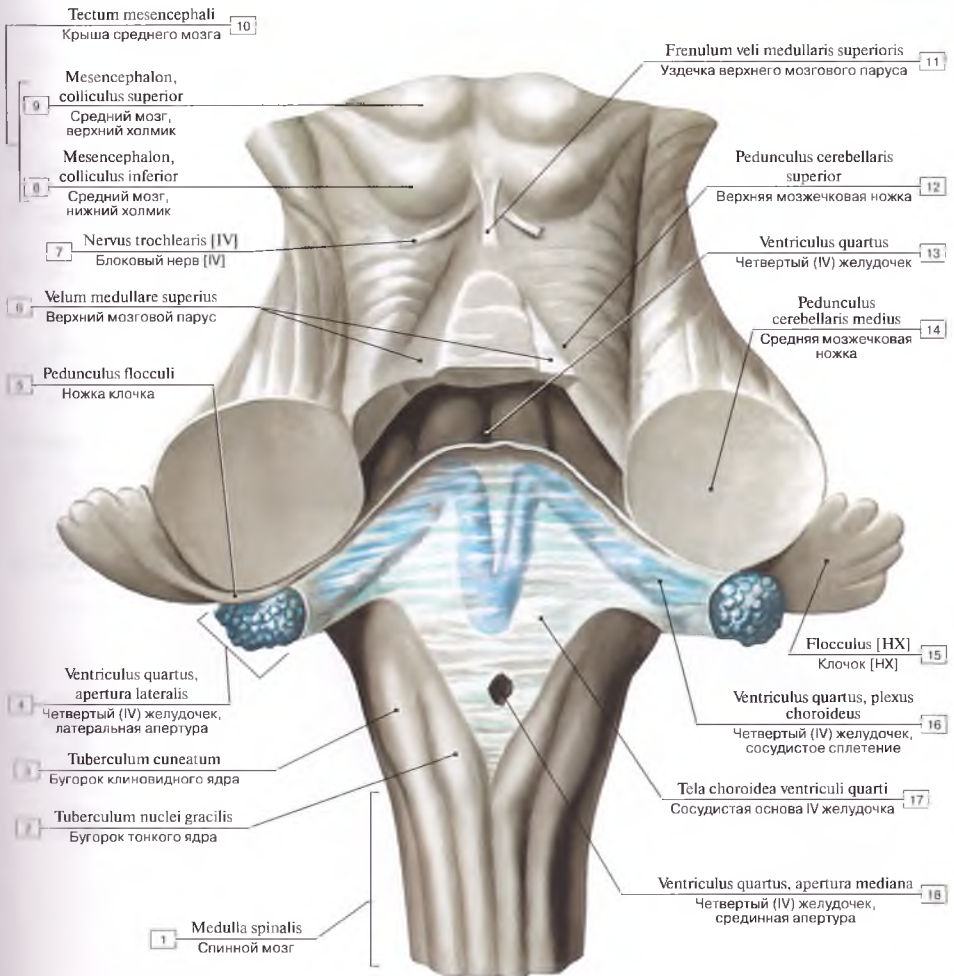


Рис. 119. Сосудистая основа четвертого (IV) желудочка:

1 – Spinal cord; 2 – Gracile tubercle; 3 – Cuneate tubercle; 4 – Fourth ventricle, lateral aperture; 5 – Peduncle of flocculus; 6 – Superior medullary velum; 7 – Trochlear nerve [IV]; 8 – Mesencephalon; Midbrain, inferior colliculus; 9 – Mesencephalon; Midbrain, superior colliculus; 10 – Tectum of midbrain; 11 – Frenulum of superior medullary velum; 12 – Superior cerebellar peduncle; 13 – Fourth ventricle; 14 – Middle cerebellar peduncle; 15 – Flocculus [HX]; 16 – Fourth ventricle, choroid plexus; 17 – Tela choroidea of fourth ventricle; 18 – Fourth ventricle, median aperture

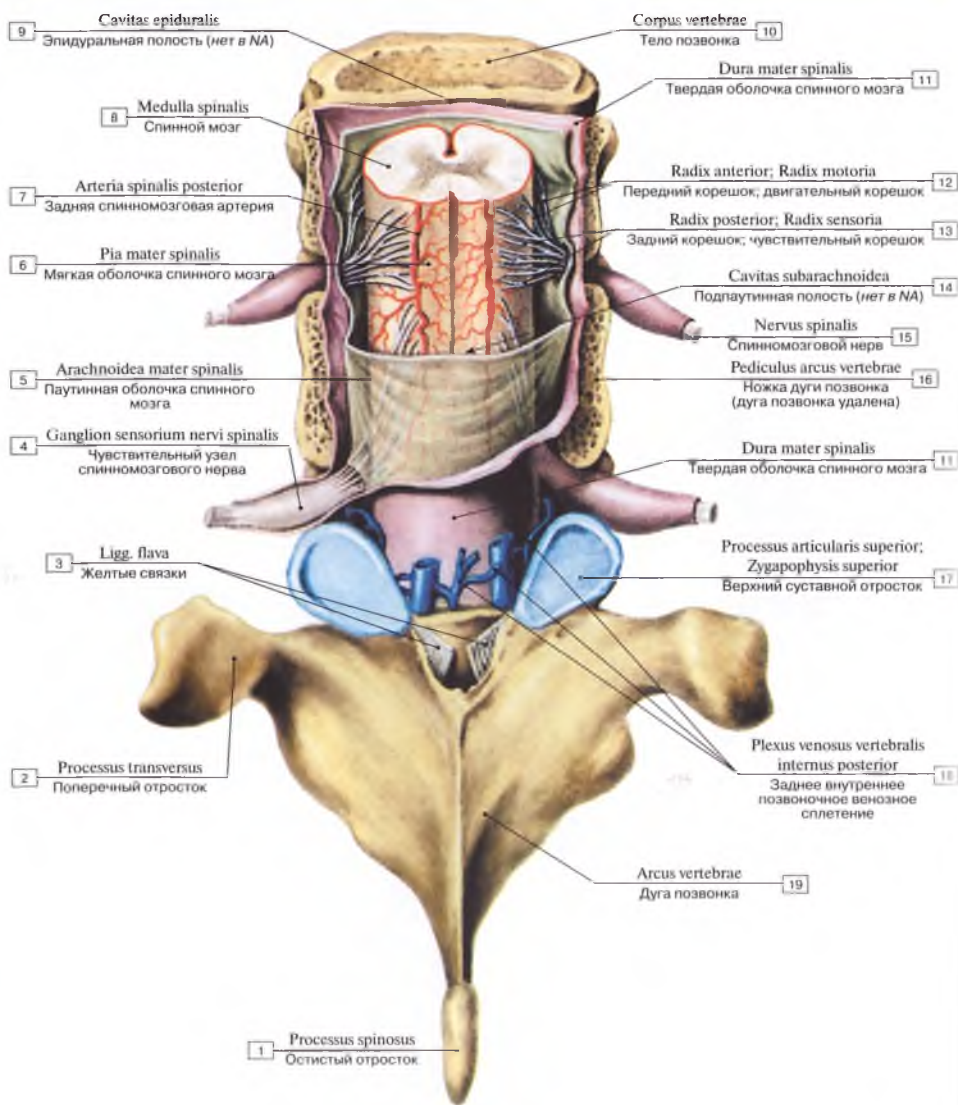


Рис. 120. Оболочки спинного мозга, вид сзади (дуги и остистые отростки двух позвонков удалены):

1 – Spinous process; 2 – Transverse process; 3 – Ligamenta flava; 4 – Spinal ganglion; Dorsal root ganglion; 5 – Spinal arachnoid mater; 6 – Spinal pia mater; 7 – Posterior spinal artery; 8 – Spinal cord; 9 – Epidural cavity; 10 – Vertebral body; 11 – Spinal dura mater; 12 – Anterior root; Motor root; Ventral root; 13 – Posterior root; Sensory root; Dorsal root; 14 – Subarachnoid cavity; 15 – Spinal nerve; 16 – Pedicle of vertebral arch; 17 – Superior articular process; 18 – Posterior internal vertebral venous plexus; 19 – Vertebral arch

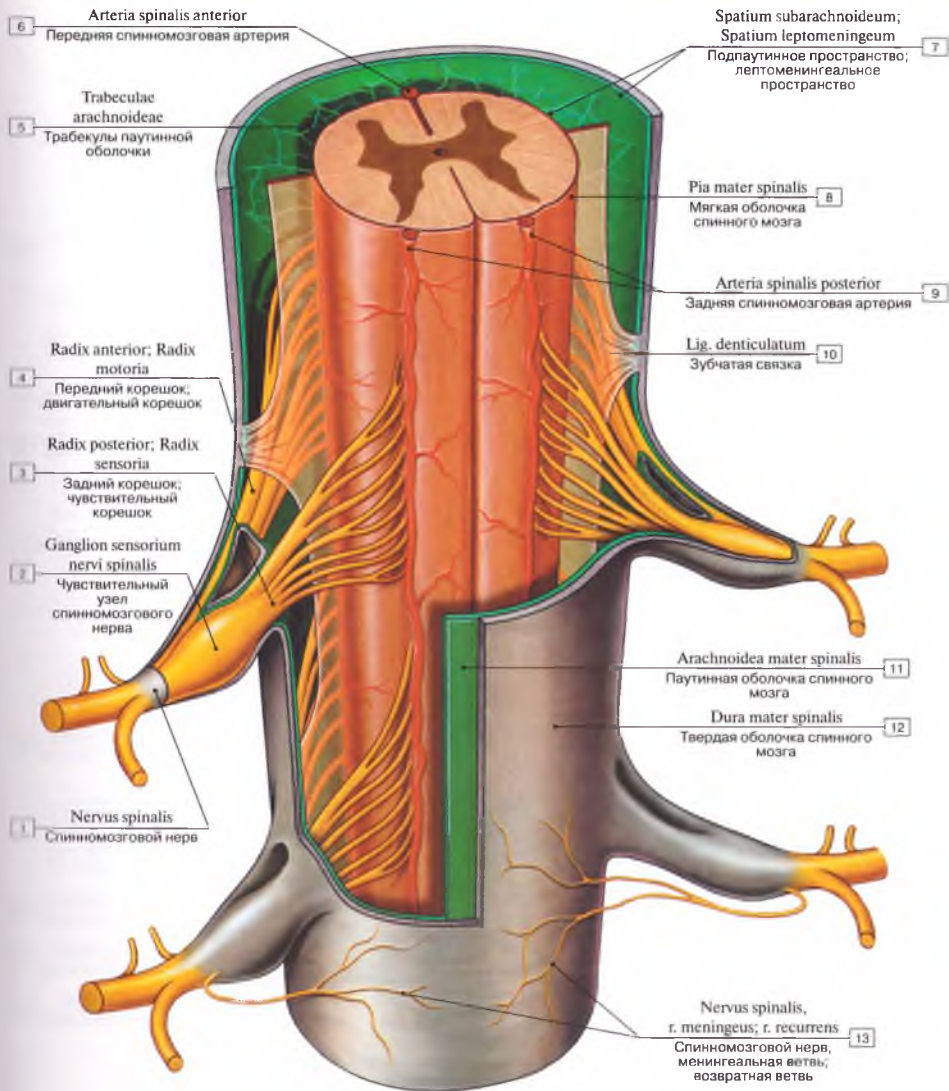


Рис. 121. Оболочки спинного мозга, грудная часть, вид сзади:

1 – Spinal nerve; 2 – Spinal ganglion; Dorsal root ganglion; 3 – Posterior root; Sensory root; Dorsal root; 4 – Anterior root; Motor root; Ventral root; 5 – Arachnoid trabeculae; 6 – Anterior spinal artery; 7 – Subarachnoid space; Leptomeningeal space; 8 – Spinal pia mater; 9 – Posterior spinal artery; 10 – Denticulate ligament; 11 – Spinal arachnoid mater; 12 – Spinal dura mater; 13 – Spinal nerve, meningeal branch; recurrent branch

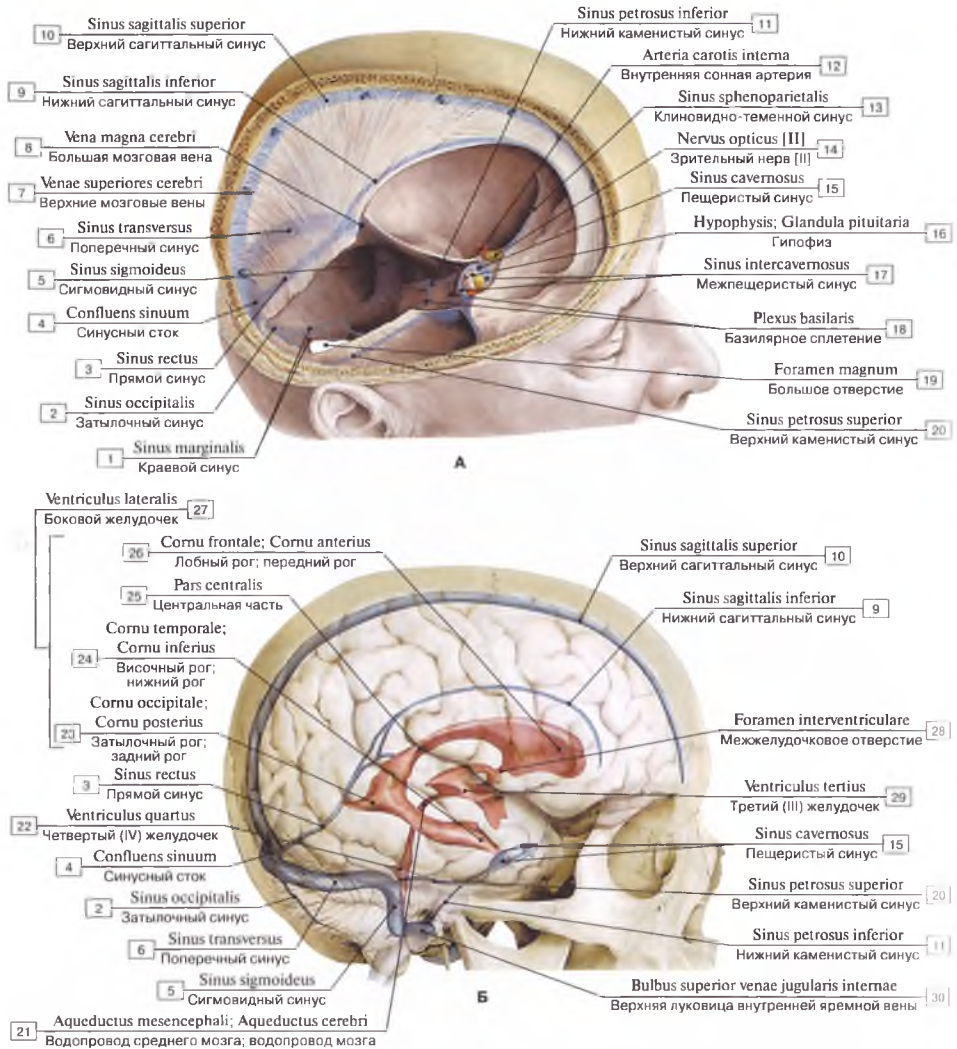


Рис. 122. Синусы твердой оболочки головного мозга, вид сбоку  
(А — головной мозг удален; Б — головной мозг сохранен, видны желудочки мозга):

1 — Marginal sinus; 2 — Occipital sinus; 3 — Straight sinus; 4 — Confluence of sinuses; 5 — Sigmoid sinus; 6 — Transverse sinus; 7 — Superior cerebral veins; 8 — Great cerebral vein; 9 — Inferior sagittal sinus; 10 — Superior sagittal sinus; 11 — Inferior petrosal sinus; 12 — Internal carotid artery; 13 — Sphenoparietal sinus; 14 — Optic nerve [III]; 15 — Cavernous sinus; 16 — Pituitary gland; 17 — Intercavernous sinus; 18 — Basilar plexus; 19 — Foramen magnum; 20 — Superior petrosal sinus; 21 — Aqueduct of midbrain; Cerebral aqueduct; 22 — Fourth ventricle; 23 — Occipital horn; Posterior horn; 24 — Temporal horn; Inferior horn; 25 — Central part; Body; 26 — Frontal horn; Anterior horn; 27 = 23 + 24 + 25 + 26 — Lateral ventricle; 28 — Interventricular foramen; 29 — Third ventricle; 30 — Superior bulb of internal jugular vein

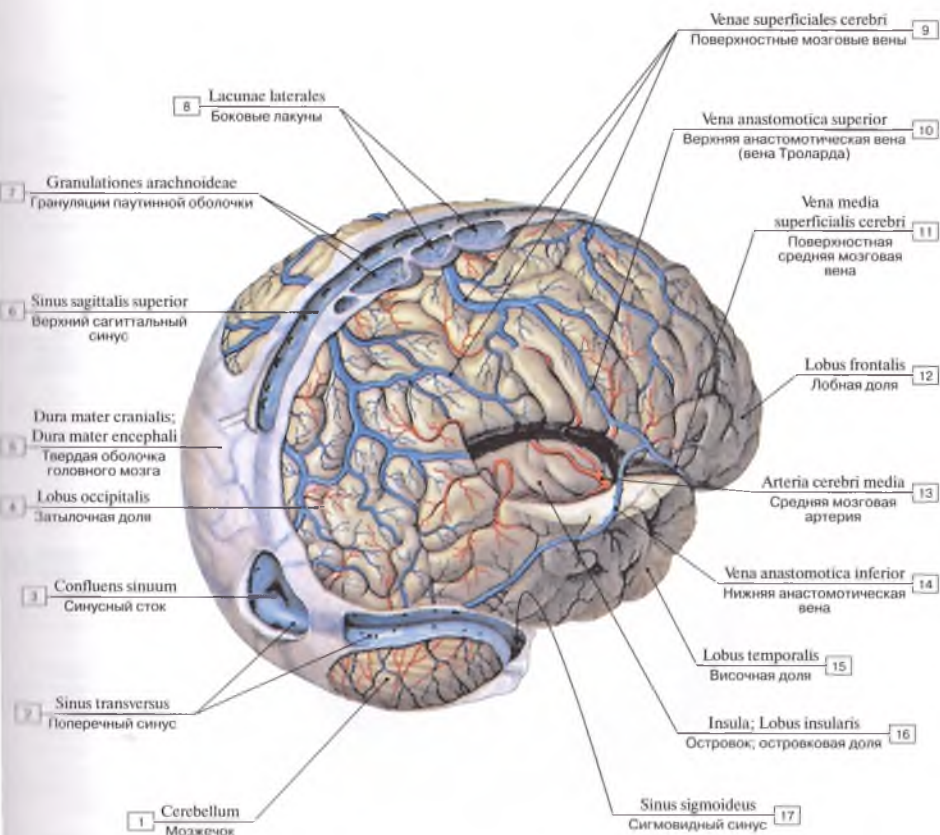


Рис. 123. Синусы твердой оболочки головного мозга и впадающие в них вены большого мозга, часть твердой оболочки и височной доли мозга удалена, часть верхнего сагиттального и поперечного синусов, а также синусный сток вскрыты, вид сбоку (справа) и сзади:

1 – Cerebellum; 2 – Transverse sinus; 3 – Confluence of sinuses; 4 – Occipital lobe; 5 – Cranial dura mater; 6 – Superior sagittal sinus; 7 – Arachnoid granulations; 8 – Lateral lacuna; 9 – Superficial cerebral veins; 10 – Superior anastomotic vein; 11 – Superficial middle cerebral vein; 12 – Frontal lobe; 13 – Middle cerebral artery; 14 – Inferior anastomotic vein; 15 – Temporal lobe; 16 – Insula; Insular lobe; 17 – Sigmoid sinus



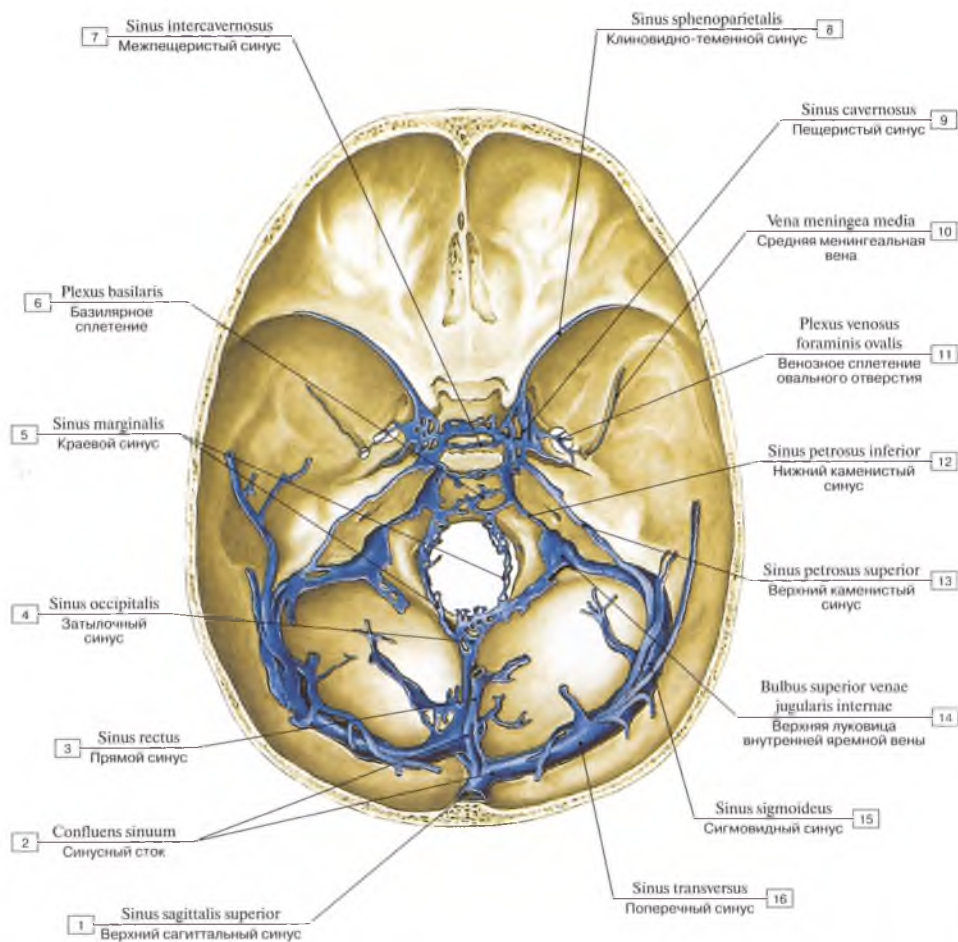


Рис. 124. Синусы твердой оболочки головного мозга, внутреннее основание черепа:

1 – Superior sagittal sinus; 2 – Confluence of sinuses; 3 – Straight sinus; 4 – Occipital sinus; 5 – Marginal sinus; 6 – Basilar plexus; 7 – Intercavernous sinus; 8 – Sphenoparietal sinus; 9 – Cavernous sinus; 10 – Middle meningeal vein; 11 – Venous plexus of foramen ovale; 12 – Inferior petrosal sinus; 13 – Superior petrosal sinus; 14 – Superior bulb of internal jugular vein; 15 – Sigmoid sinus; 16 – Transverse sinus

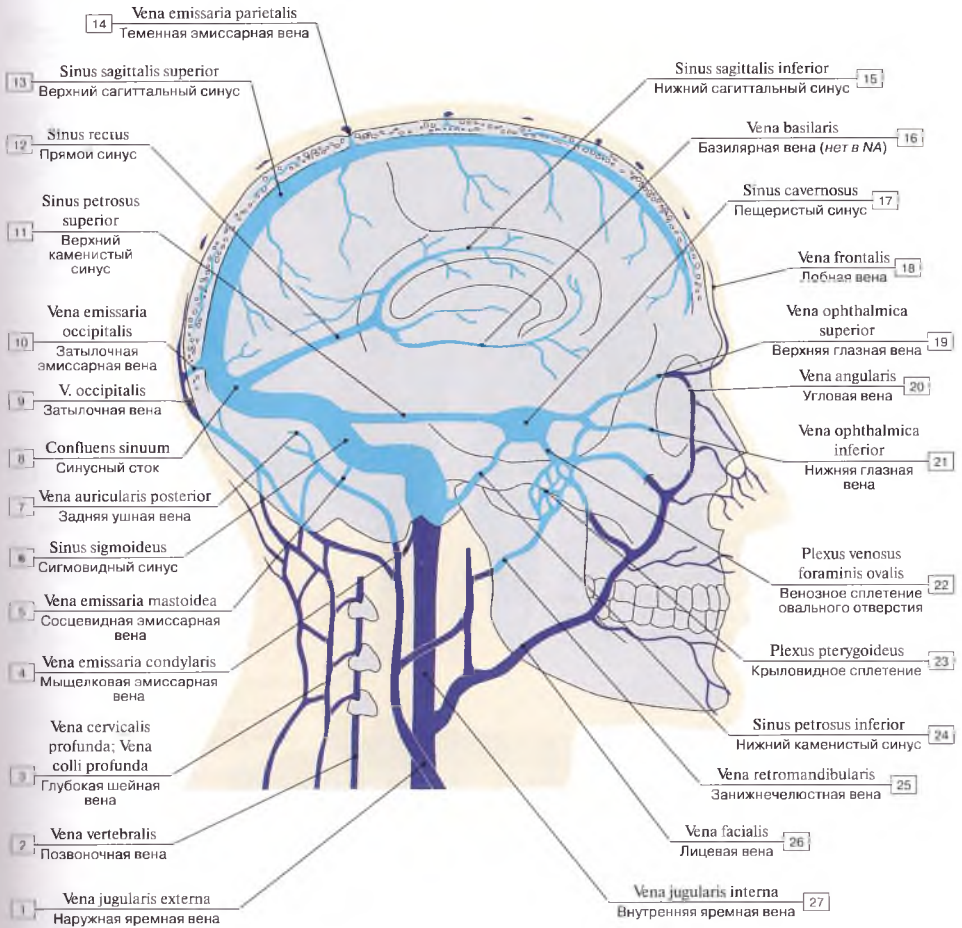


Рис. 125. Дополнительный дренаж синусов твердой оболочки головного мозга (схема):

1 – External jugular vein; 2 – Vertebral vein; 3 – Deep cervical vein; 4 – Condylar emissary vein; 5 – Mastoid emissary vein; 6 – Sigmoid sinus; 7 – Posterior auricular vein; 8 – Confluence of sinuses; 9 – Occipital vein; 10 – Occipital emissary vein; 11 – Superior petrosal sinus; 12 – Straight sinus; 13 – Superior sagittal sinus; 14 – Parietal emissary vein; 15 – Inferior sagittal sinus; 16 – Basilar vein; 17 – Cavernous sinus; 18 – Frontal vein; 19 – Superior ophthalmic vein; 20 – Angular vein; 21 – Inferior ophthalmic vein; 22 – Venous plexus of foramen ovale; 23 – Pterygoid plexus; 24 – Inferior petrosal sinus; 25 – Retromandibular vein; 26 – Facial vein; 27 – Internal jugular vein

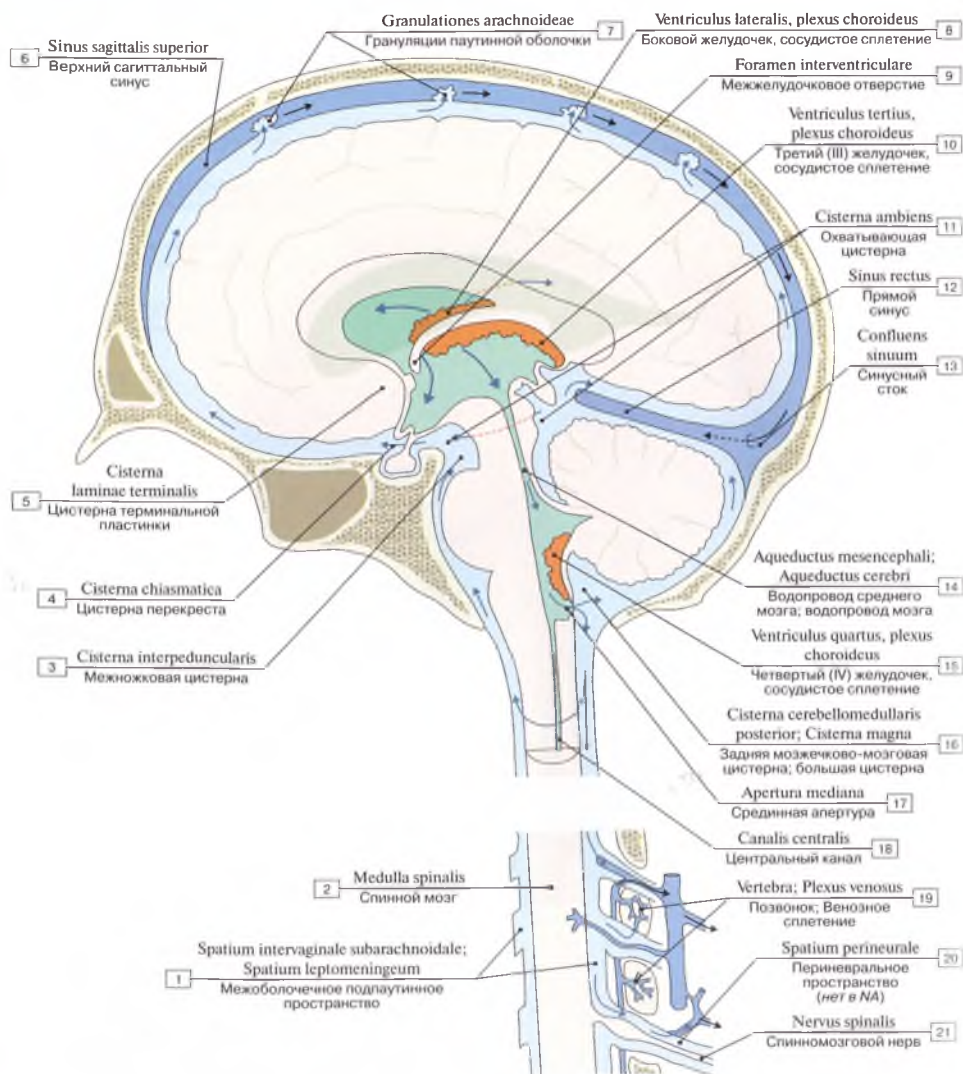


Рис. 126. Циркуляция спинномозговой жидкости, цистерны (схема):

1 – Subarachnoid space; Leptomeningeal space; 2 – Spinal cord; 3 – Interpeduncular cistern; 4 – Chiasmatic cistern; 5 – Cistern of lamina terminalis; 6 – Superior sagittal sinus; 7 – Arachnoid granulations; 8 – Lateral ventricle, choroid plexus; 9 – Interventricular foramen; 10 – Third ventricle, choroid plexus; 11 – Cisterna ambiens; Ambient cistern; 12 – Straight sinus; 13 – Confluence of sinuses; 14 – Aqueduct of midbrain; Cerebral aqueduct; 15 – Fourth ventricle, choroid plexus; 16 – Posterior cerebellomedullary cistern; Cisterna magna; 17 – Median aperture; 18 – Central canal; 19 – Vertebra; Venous plexus; 20 – Perineural space; 21 – Spinal nerve

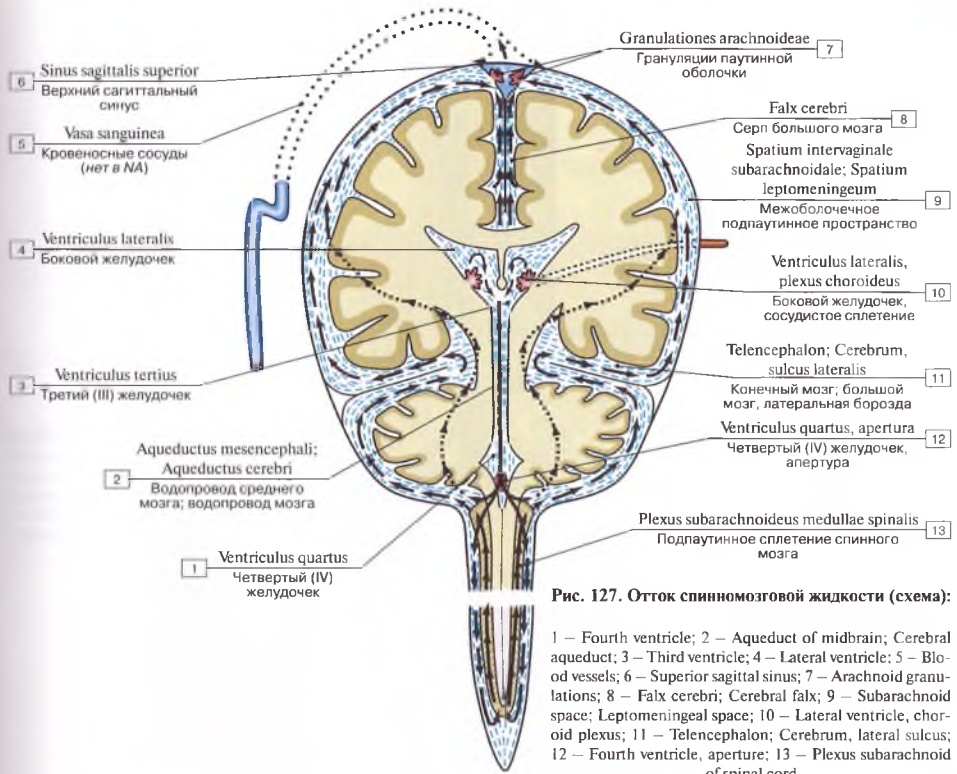


Рис. 127. Отток спинномозговой жидкости (схема):

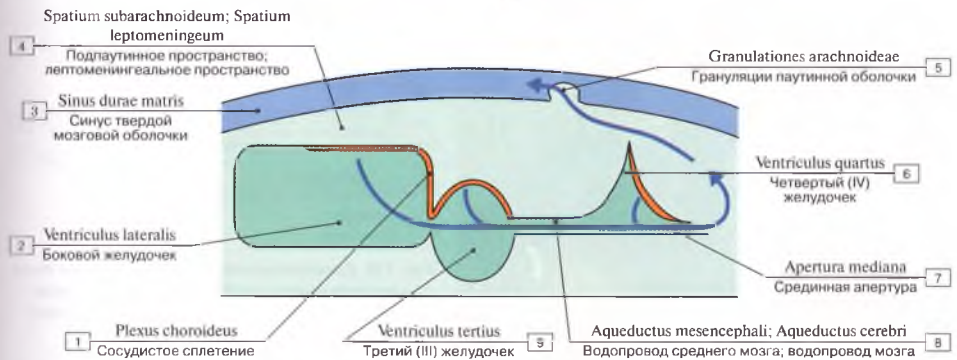


Рис. 128. Отток спинномозговой жидкости в синус твердой мозговой оболочки (схема):

1 – Choroid plexus; 2 – Lateral ventricle; 3 – Dural venous sinus; 4 – Subarachnoid space; Leptomeningeal space; 5 – Arachnoid granulations; 6 – Fourth ventricle; 7 – Median aperture; 8 – Aqueduct of midbrain; Cerebral aqueduct; 9 – Third ventricle

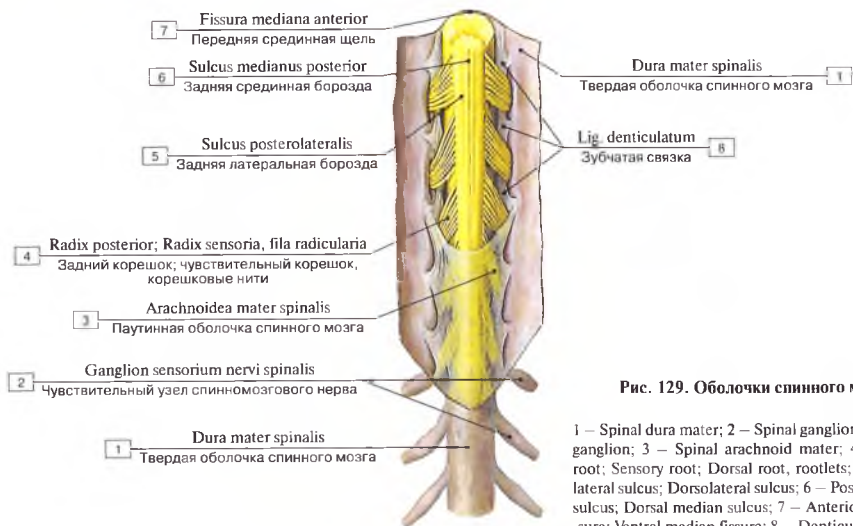


Рис. 129. Оболочки спинного мозга:

1 – Spinal dura mater; 2 – Spinal ganglion; Dorsal root ganglion; 3 – Spinal arachnoid mater; 4 – Posterior root; Sensory root; Dorsal root, rootlets; 5 – Posterolateral sulcus; Dorsolateral sulcus; 6 – Posterior median sulcus; Dorsal median sulcus; 7 – Anterior median fissure; Ventral median fissure; 8 – Denticulate ligament

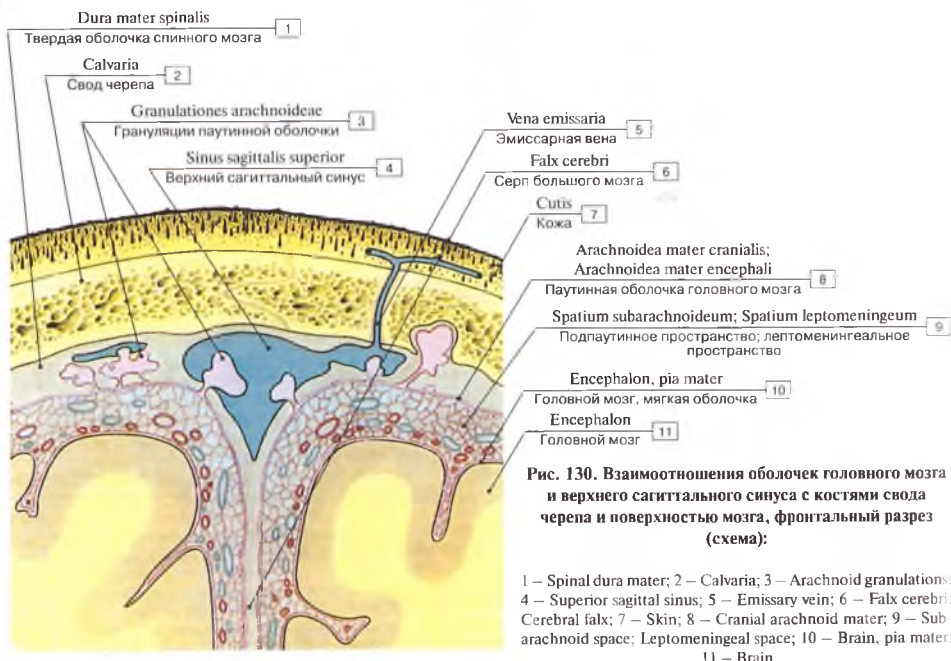


Рис. 130. Взаимоотношения оболочек головного мозга и верхнего сагиттального синуса с костями свода черепа и поверхностью мозга, фронтальный разрез (схема):

1 – Spinal dura mater; 2 – Calvaria; 3 – Arachnoid granulations; 4 – Superior sagittal sinus; 5 – Emissary vein; 6 – Falx cerebri; Cerebral falx; 7 – Skin; 8 – Cranial arachnoid mater; 9 – Subarachnoid space; Leptomeningeal space; 10 – Brain, pia mater; 11 – Brain

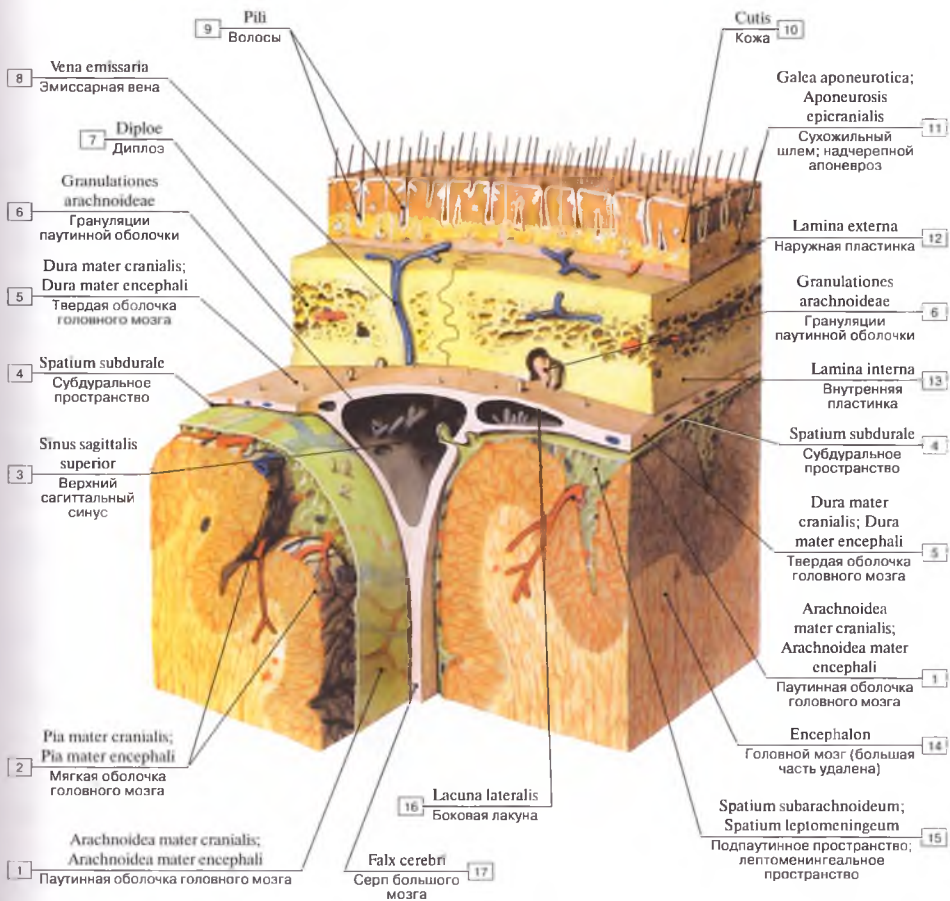


Рис. 131. Взаиморасположение оболочек мозга и свода черепа:

1 – Cranial arachnoid mater; 2 – Cranial pia mater; 3 – Superior sagittal sinus; 4 – Subdural space; 5 – Cranial dura mater; 6 – Arachnoid granulations; 7 – Diploe; 8 – Emissary vein; 9 – Hairs; 10 – Skin; 11 – Epicranial aponeurosis; 12 – External table; 13 – Internal table; 14 – Brain; 15 – Subarachnoid space; Leptomeningeal space; 16 – Lateral lacunae; 17 – Falx cerebri; Cerebral falx

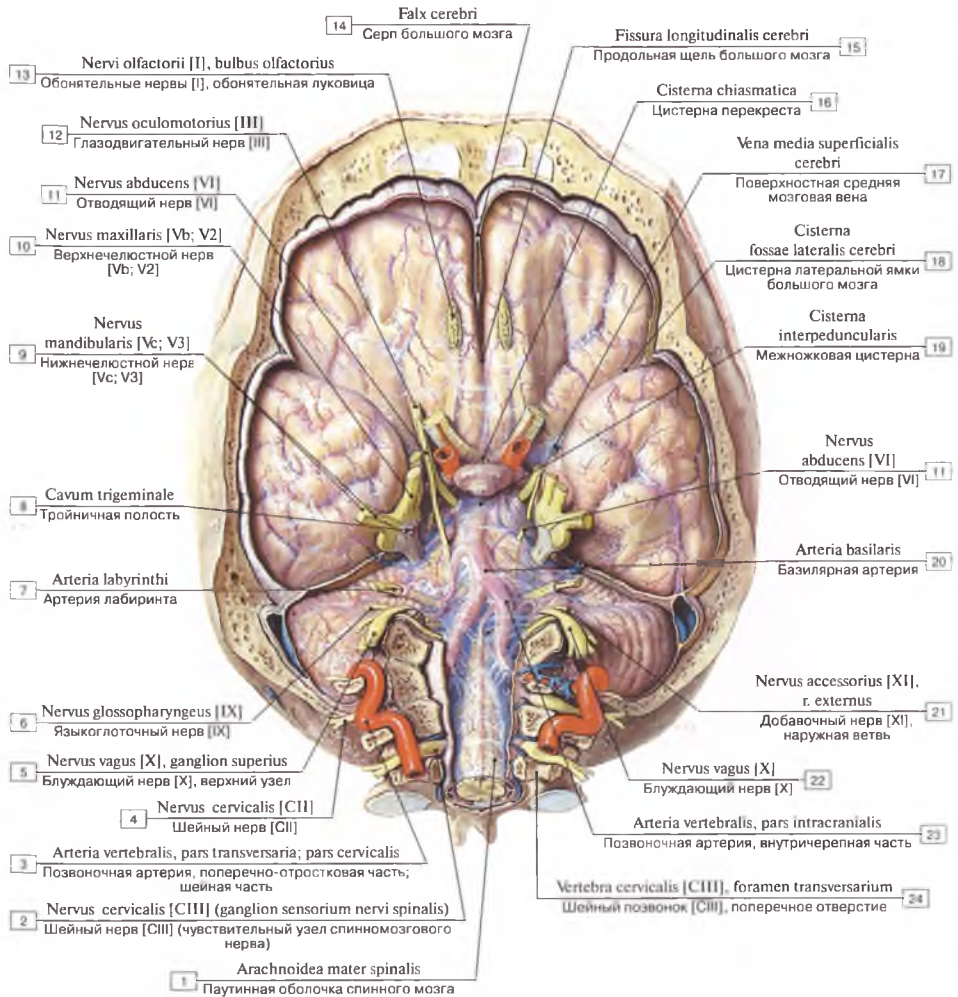
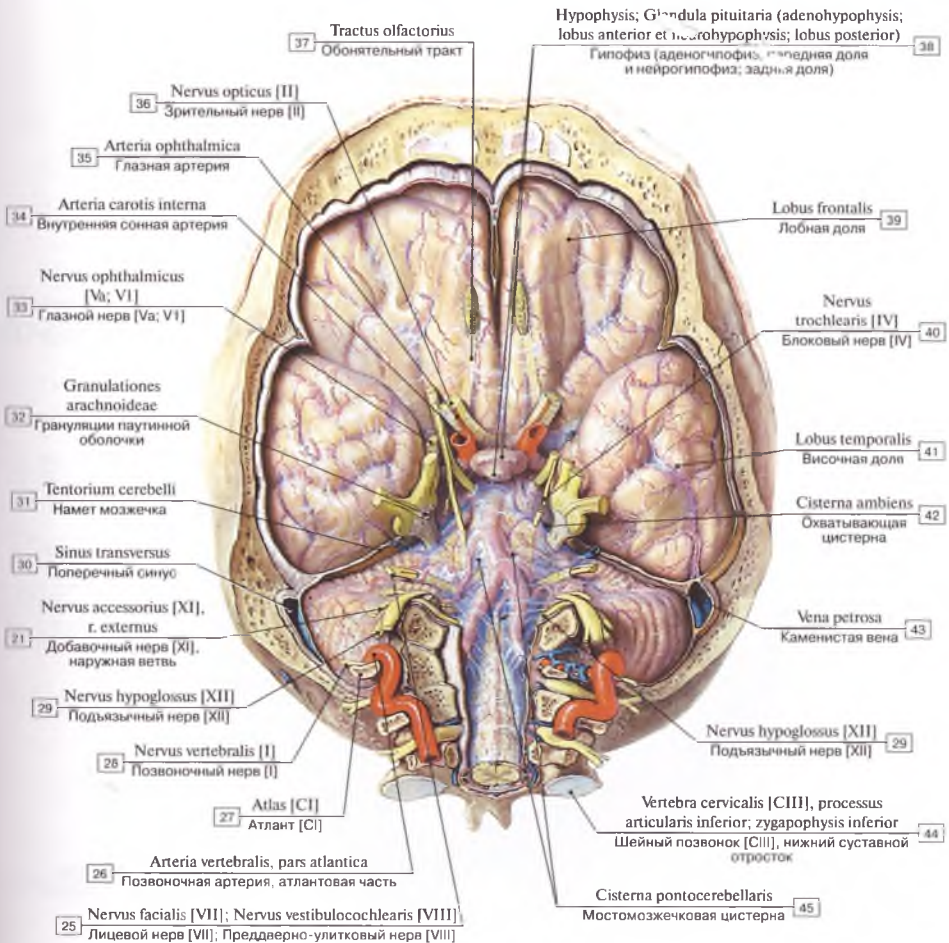


Рис. 132. Мозг, твердая оболочка удалена, паутинная оболочка сохранена, вид снизу:

1 — Spinal arachnoid mater; 2 — Cervical nerve [CIII] (spinal ganglion; dorsal root ganglion); 3 — Vertebral artery, cervical part; 4 — Cervical nerve [CII]; 5 — Vagus nerve [X], superior ganglion; 6 — Glossopharyngeal nerve [IX]; 7 — Labyrinthine artery; 8 — Trigeminal cave; Trigeminal cavity; 9 — Mandibular nerve; Mandibular division [Vc; V3]; 10 — Maxillary nerve; Maxillary division [Vb; V2]; 11 — Abducent nerve; Abducent nerve [VI]; 12 — Oculomotor nerve [III]; 13 — Olfactory nerves [I], olfactory bulb; 14 — Falx cerebri; Cerebral falx; 15 — Longitudinal cerebral fissure; 16 — Chiasmatic cistern; 17 — Superficial middle cerebral vein; 18 — Cistern of lateral cerebral fossa; 19 — Interpeduncular cistern; 20 — Basilar artery; 21 — Accessory nerve [XI], external branch; 22 — Vagus nerve [X]; 23 — Vertebral artery, intracranial part;



34 – Cervical vertebra [CIII], foramen transversarium; 25 – Facial nerve [VII]; Vestibulocochlear nerve [VIII]; 26 – Vertebral artery, atlantic part; 27 – Atlas [C1]; 28 – Vertebral nerve [I]; 29 – Hypoglossal nerve [XII]; 30 – Transverse sinus; 31 – Tentorium cerebelli; Cerebellar tentorium; 32 – Arachnoid granulations; 33 – Ophthalmic nerve; Ophthalmic division [Va; VI]; 34 – Internal carotid artery; 35 – Ophthalmic artery; 36 – Optic nerve [II]; 37 – Olfactory tract; 38 – Pituitary gland (adenohypophysis; anterior lobe and neurohypophysis; posterior lobe); 39 – Frontal lobe; 40 – Trochlear nerve [IV]; 41 – Temporal lobe; 42 – Cisterna ambiens; Ambient cistern; 43 – Petrosal vein; 44 – Cervical vertebra [CIII], inferior articular process; 45 – Pontocerebellar cistern



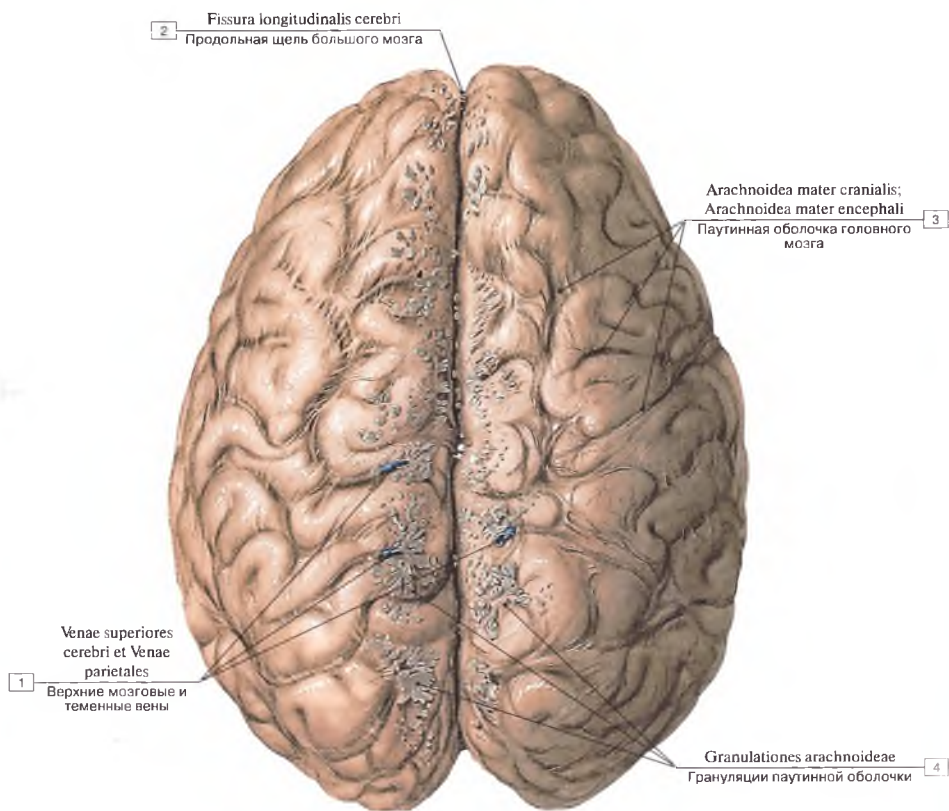


Рис. 133. Паутинная оболочка головного мозга, вид сверху:

1 – Superior cerebral veins and Parietal veins; 2 – Longitudinal cerebral fissure; 3 – Cranial arachnoid mater; 4 – Arachnoid granulations.

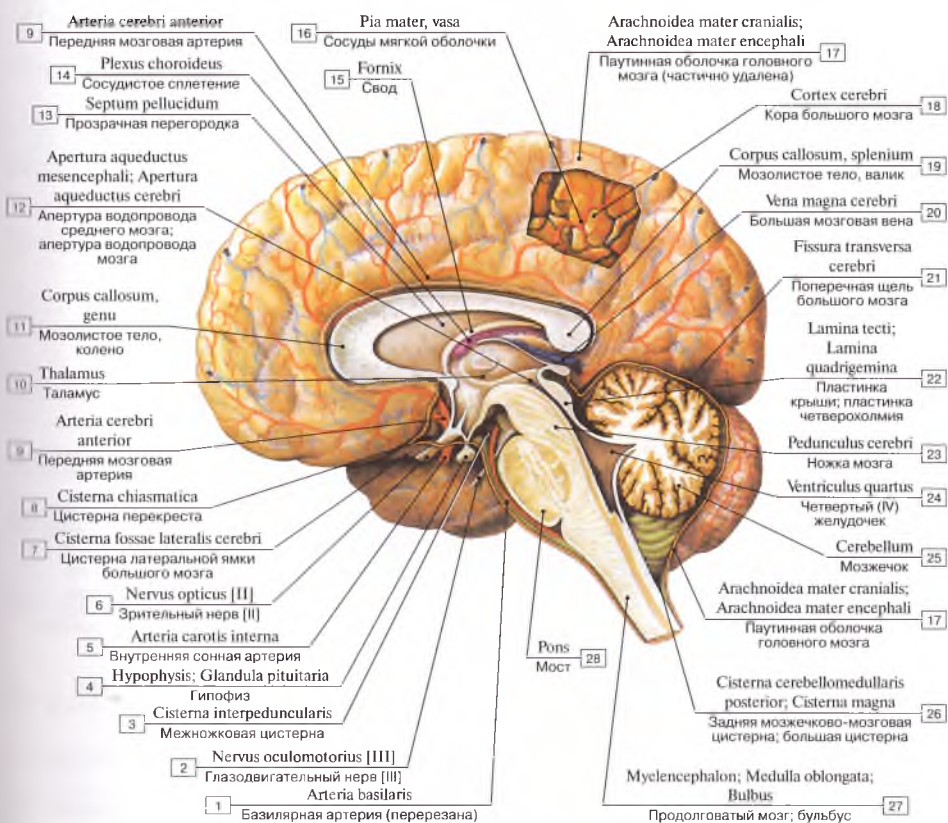


Рис. 134. Паутинная оболочка головного мозга с медиальной стороны:

- 1 - Basilar artery; 2 - Oculomotor nerve [III]; 3 - Interpeduncular cistern; 4 - Pituitary gland; 5 - Internal carotid artery; 6 - Optic nerve [II]; 7 - Cistern of lateral cerebral fossa; 8 - Chiasmatic cistern; 9 - Anterior cerebral artery; 10 - Thalamus; Dorsal thalamus; 11 - Corpus callosum, genu; 12 - Opening of aqueduct of midbrain; Opening of cerebral aqueduct; 13 - Septum pellucidum; 14 - Choroid plexus; 15 - Fornix; 16 - Pia mater vessels; 17 - Cranial arachnoid mater; 18 - Cerebral cortex; 19 - Corpus callosum, splenium; 20 - Great cerebral vein; 21 - Transverse cerebral fissure; 22 - Tectal plate; 23 - Cerebral peduncle; 24 - Fourth ventricle; 25 - Cerebellum; 26 - Posterior cerebellomedullary cistern; Cisterna magna; 27 - Myelencephalon; Medulla oblongata; Bulb; 28 - Pons

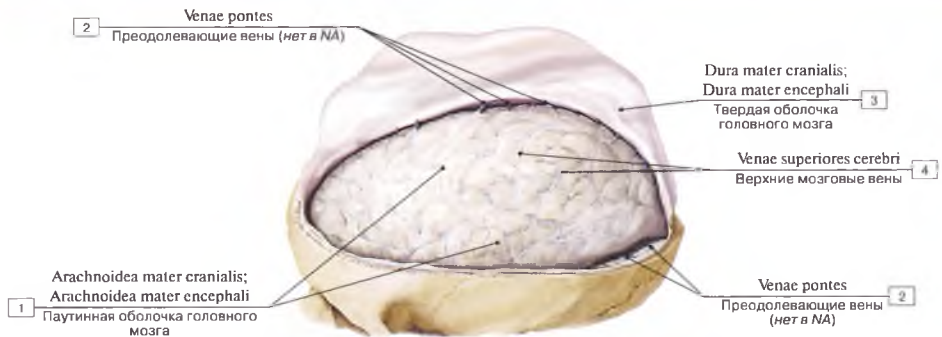


Рис. 135. Головной мозг и его оболочки, твердая мозговая оболочка частично отделена от паутинной, вид сверху, намет мозжечка справа удален:

1 – Cranial arachnoid mater; 2 – Bridging veins; 3 – Cranial dura mater; 4 – Superior cerebral veins

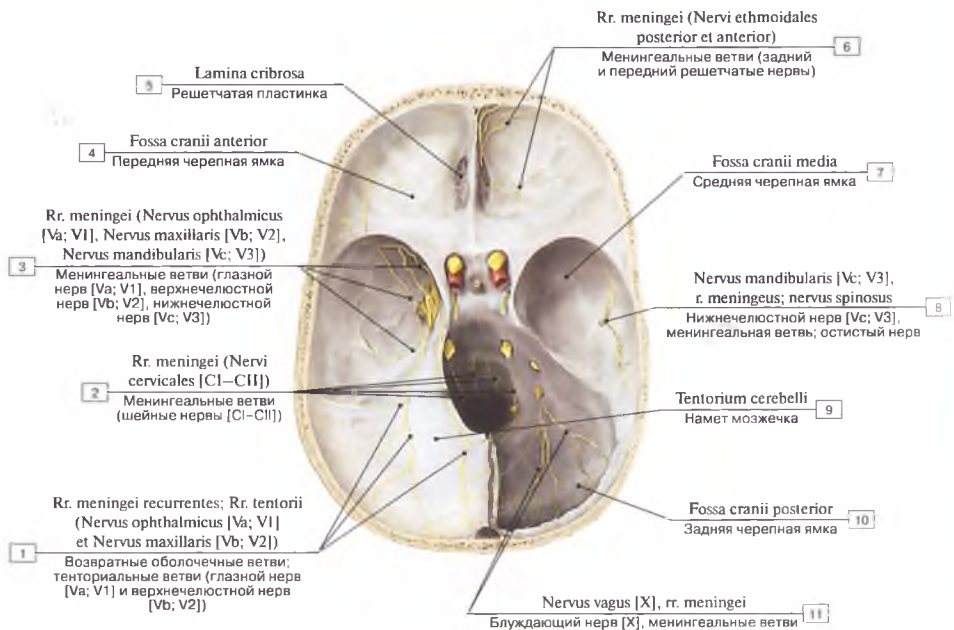


Рис. 136. Иннервация твердой оболочки головного мозга:

1 – Tentorial nerves (Ophthalmic nerve; ophthalmic division [Va; V1] and Maxillary nerve; maxillary division [Vb; V2]); 2 – Meningeal branches (Cervical nerves [CI–CII]); 3 – Meningeal branches (Ophthalmic nerve; Ophthalmic division [Va; V1], Maxillary nerve; Maxillary division [Vb; V2], Mandibular nerve; Mandibular division [Vc; V3]); 4 – Anterior cranial fossa; 5 – Cribriform plate; 6 – Meningeal branches (Posterior and anterior ethmoidal nerves); 7 – Middle cranial fossa; 8 – Mandibular nerve; Mandibular division [Vc; V3], meningeal branch, nervus spinosus; 9 – Tentorium cerebelli; Cerebellar tentorium; 10 – Posterior cranial fossa; 11 – Vagus nerve [X], meningeal branches.

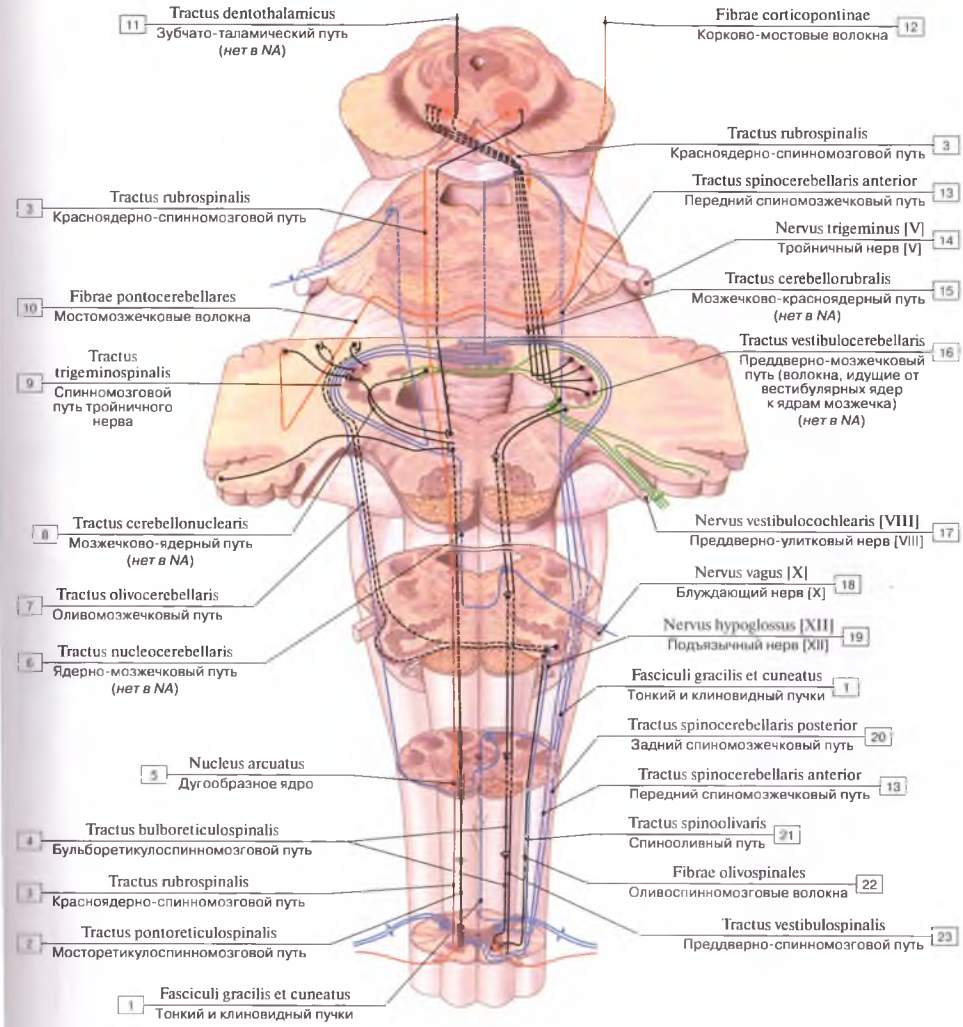


Рис. 137. Восходящие и нисходящие пути ствола головного мозга (схема):

- 1 — Gracile and cuneate fascicles; 2 — Pontoreticulospinal tract; Medial reticulospinal tract; 3 — Rubrospinal tract; 4 — Reticulospinal tract; Lateral reticulospinal tract; 5 — Arcuate nucleus; 6 — Nucleocerebellar tract; 7 — Olivocerebellar tract; 8 — Cerebellonuclear tract; 9 — Trigemino-spinal tract; 10 — Pontocerebellar fibres; 11 — Dentothalamic tract; 12 — Corticopontine fibres; 13 — Anterior spinocerebellar tract; 14 — Trigeminal nerve [V]; 15 — Cerebellorubral tract; 16 — Vestibulocerebellar tract; 17 — Vestibulocochlear nerve [VIII]; 18 — Vagus nerve [X]; 19 — Hypoglossal nerve [XII]; 20 — Posterior spinocerebellar tract; 21 — Spino-olivary tract; 22 — Olivospinal fibres; 23 — Vestibulospinal tract

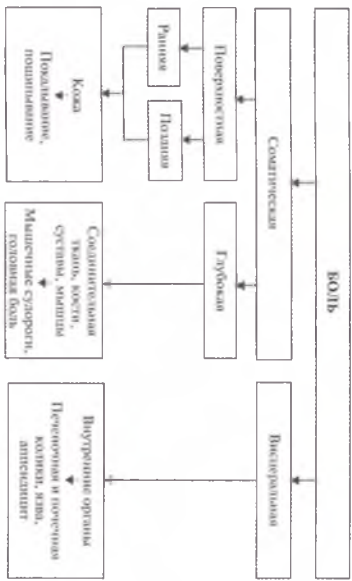
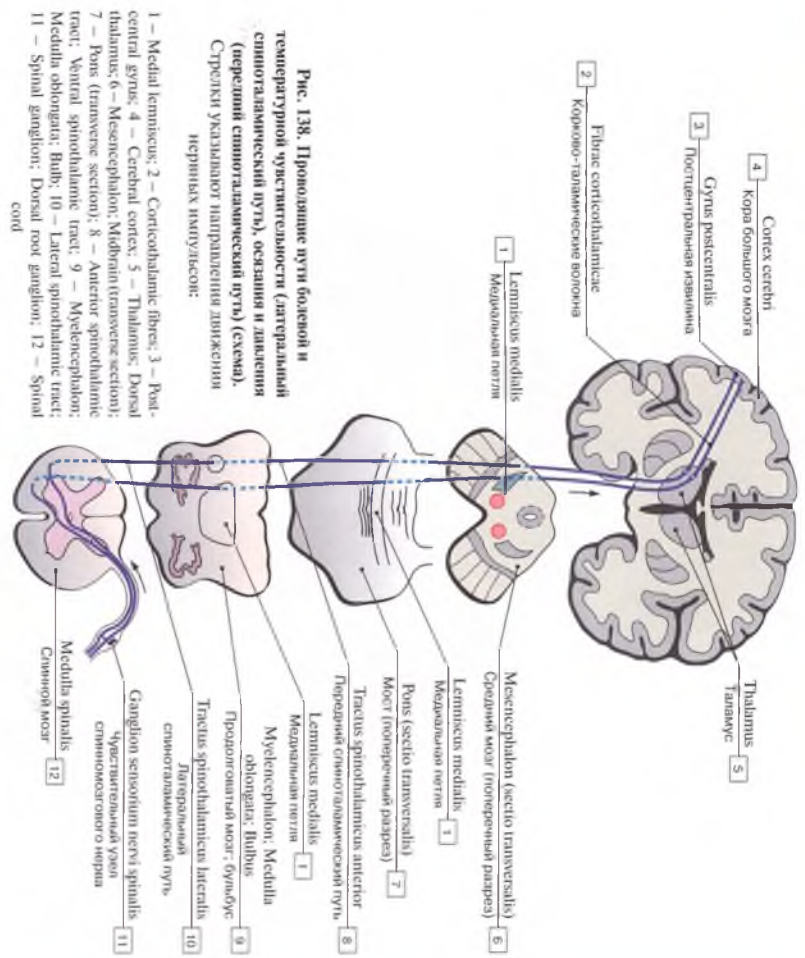
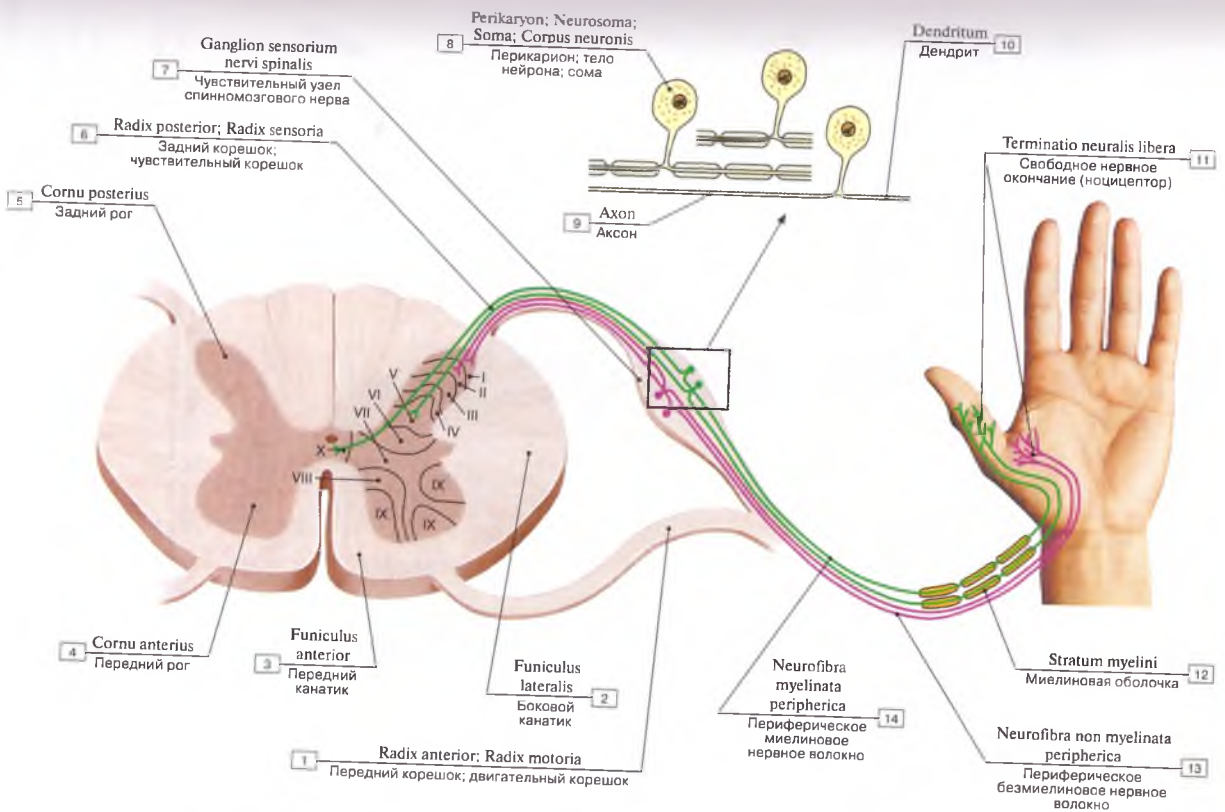


Рис. 139. Качество боли (по Р. Шидлеру)



1 – Anterior root; 2 – Lateral funiculus; 3 – Anterior funiculus; 4 – Anterior horn; 5 – Posterior horn; 6 – Posterior root; 7 – Spinal ganglion; 8 – Nerve cell body; 9 – Axon; 10 – Dendrite; 11 – Free nerve ending; 12 – Myelin sheath; 13 – Peripheral nonmyelinated nerve fibre; 14 – Peripheral myelinated nerve fibre

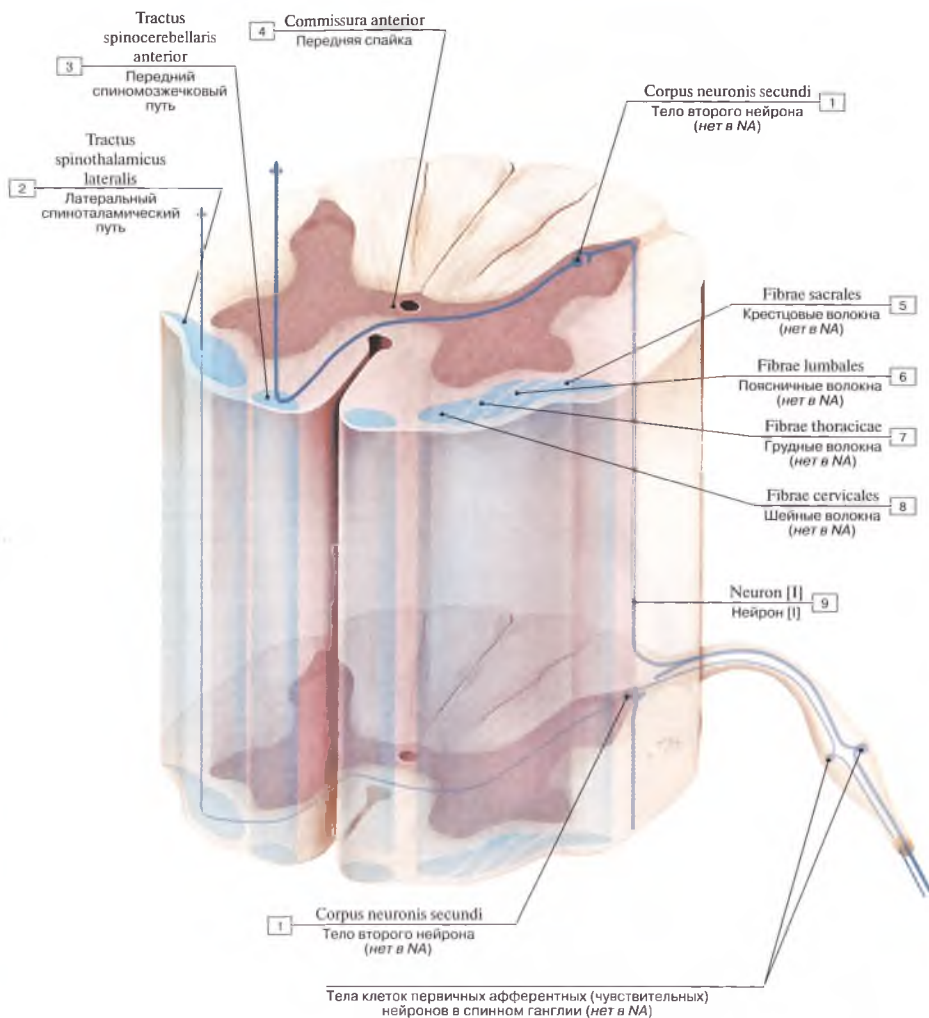


Рис. 141. Передний и боковой спиноталамические пути (поперечное сечение спинного мозга) (реконструкция):

1 – Cell body of second neuron; 2 – Lateral spinothalamic tract; 3 – Anterior spinocerebellar tract; 4 – Anterior commissure; 5 – Sacral fibres; 6 – Lumbar fibres; 7 – Thoracic fibres; 8 – Cervical fibres; 9 – Neuron [I]

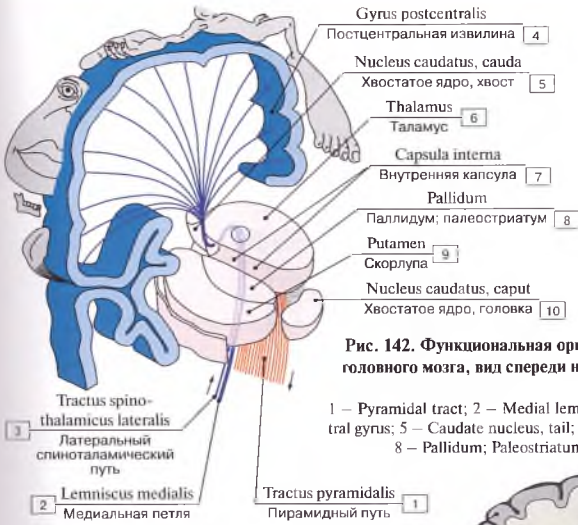


Рис. 142. Функциональная организация чувствительных проводящих путей головного мозга, вид спереди на правую постцентральную извилину (схема):

1 – Pyramidal tract; 2 – Medial lemniscus; 3 – Lateral spinothalamic tract; 4 – Postcentral gyrus; 5 – Caudate nucleus, tail; 6 – Thalamus; Dorsal thalamus; 7 – Internal capsule; 8 – Pallidum; Paleostriatum; 9 – Putamen; 10 – Caudate nucleus, head

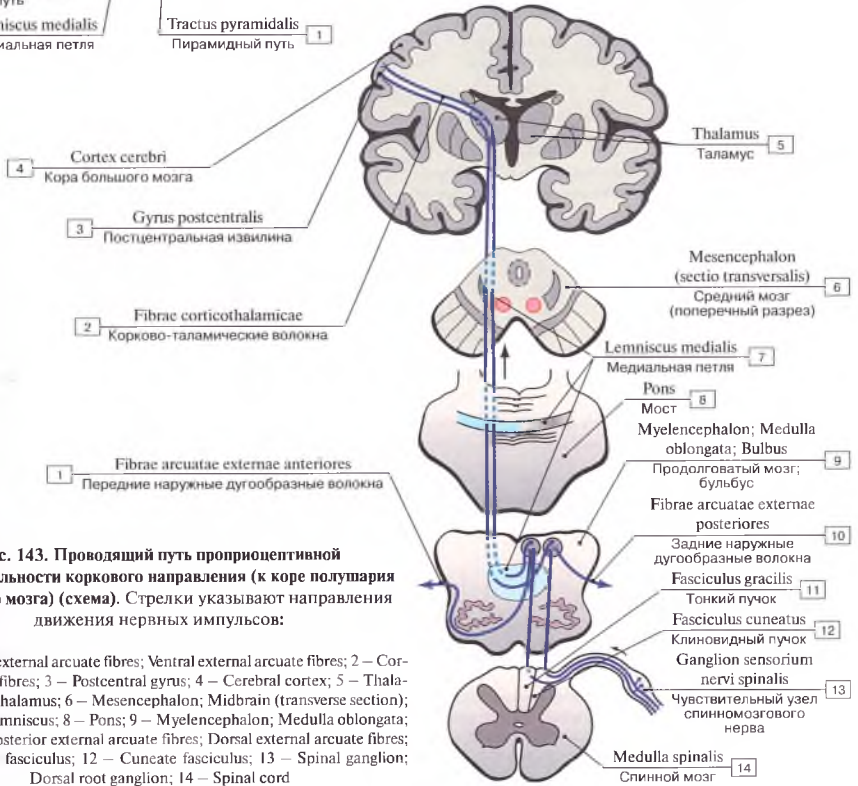


Рис. 143. Проводящий путь проприоцептивной чувствительности коркового направления (к коре полушария головного мозга) (схема). Стрелки указывают направления движения нервных импульсов:

1 – Anterior external arcuate fibres; Ventral external arcuate fibres; 2 – Corticothalamic fibres; 3 – Postcentral gyrus; 4 – Cerebral cortex; 5 – Thalamus; Dorsal thalamus; 6 – Mesencephalon; Midbrain (transverse section); 7 – Medial lemniscus; 8 – Pons; 9 – Myelencephalon; Medulla oblongata; Bulb; 10 – Posterior external arcuate fibres; Dorsal external arcuate fibres; 11 – Gracile fasciculus; 12 – Cuneate fasciculus; 13 – Spinal ganglion; Dorsal root ganglion; 14 – Spinal cord

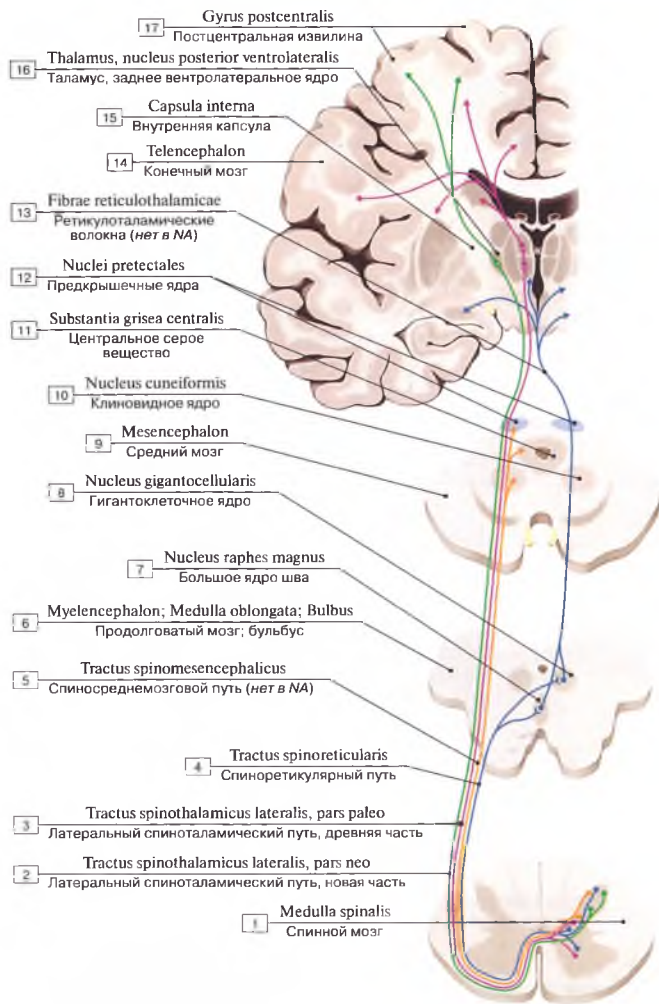


Рис. 144. Восходящие проводящие пути болевой чувствительности от туловища и конечностей (схема):

1 – Spinal cord; 2 – Lateral spinothalamic tract, new part; 3 – Lateral spinothalamic tract, ancient part; 4 – Spinoreticular tract; 5 – Spinomesencephalic tract; 6 – Myelencephalon; Medulla oblongata; Bulb; 7 – Magnus raphe nucleus; 8 – Gigantocellular reticular nucleus; 9 – Mesencephalon; Midbrain; 10 – Cuneiform nucleus; 11 – Periaqueductal grey substance; Central grey substance; 12 – Pretectal nuclei; 13 – Reticulothalamic fibres; 14 – Telencephalon; 15 – Internal capsule; 16 – Thalamus; Dorsal thalamus, posterior ventrolateral nucleus; 17 – Postcentral gyrus



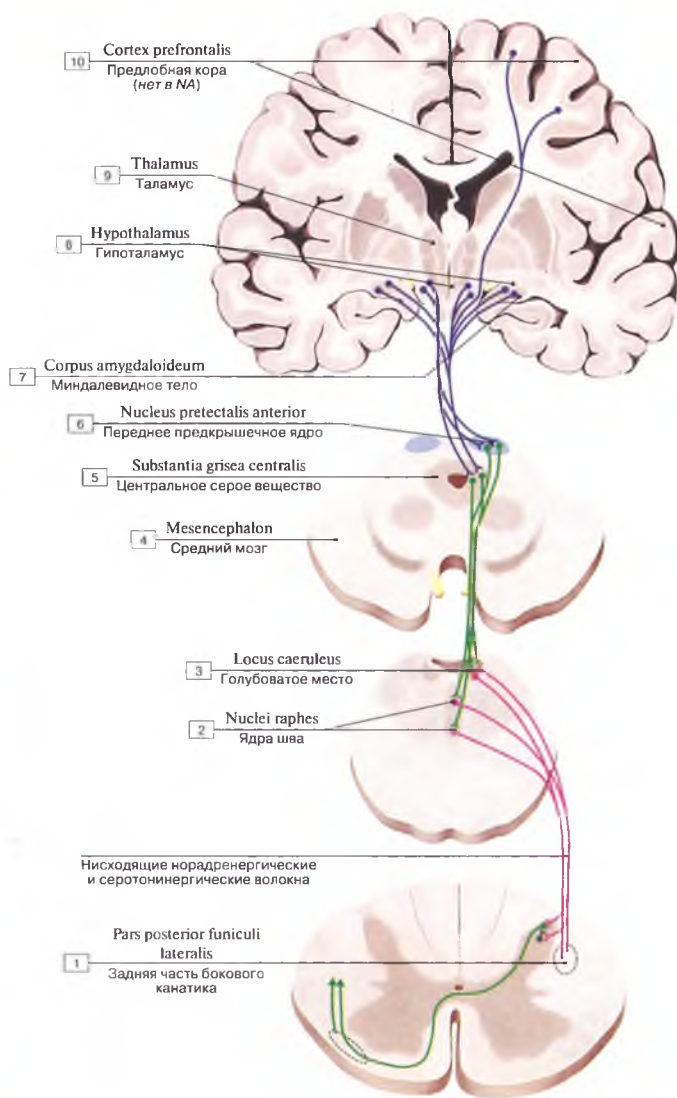
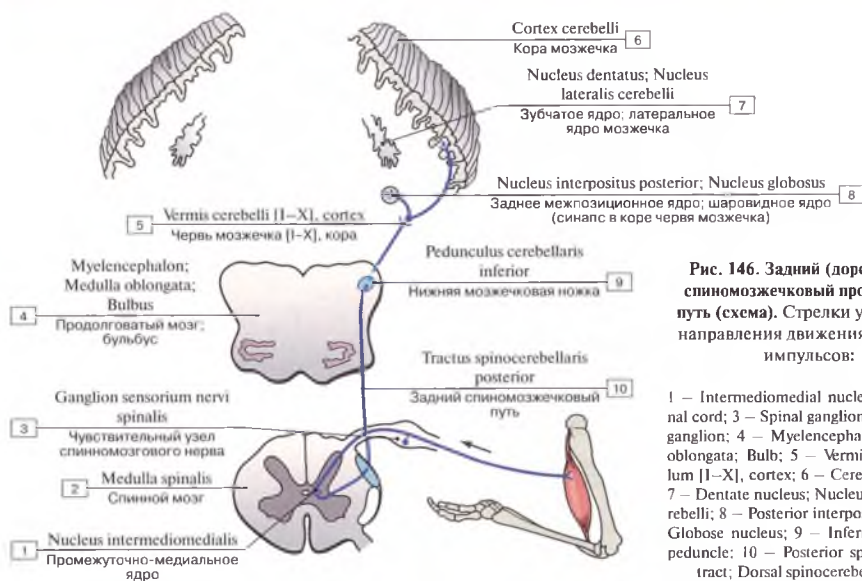


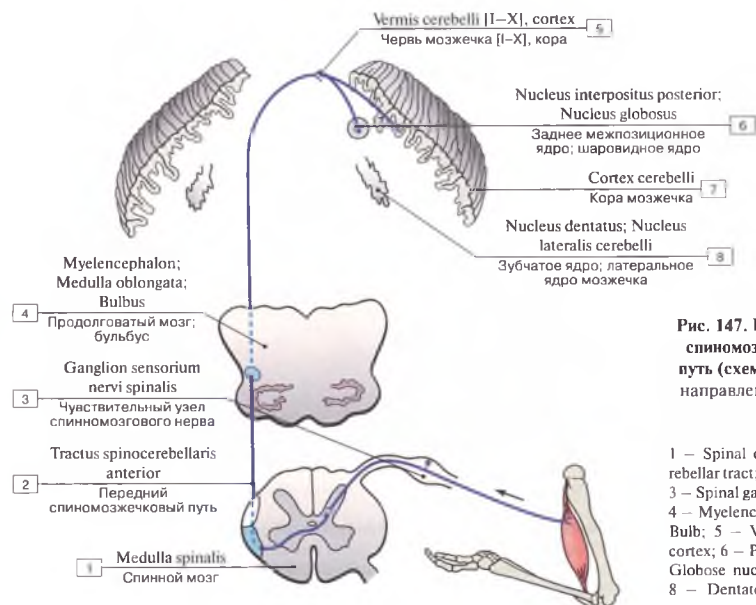
Рис. 145. Проводящие пути центральной нисходящей обезболивающей системы (схема):

1 – Posterior part of lateral funiculus; 2 – Raphe nuclei; 3 – Locus caeruleus; 4 – Mesencephalon; Midbrain; 5 – Periaqueductal grey substance; Central grey substance; 6 – Anterior pretectal nucleus; 7 – Amygdaloid body; Amygdaloid complex; 8 – Hypothalamus; 9 – Thalamus; Dorsal thalamus; 10 – Prefrontal cortex



**Рис. 146. Задний (дорсальный) спинномозжечковый проводящий путь (схема).** Стрелки указывают направления движения нервных импульсов:

1 – Intermediomedial nucleus; 2 – Spinal cord; 3 – Spinal ganglion; Dorsal root ganglion; 4 – Myelencephalon; Medulla oblongata; Bulb; 5 – Vermis of cerebellum [I–X], cortex; 6 – Cerebellar cortex; 7 – Dentate nucleus; Nucleus lateralis cerebelli; 8 – Posterior interpositus nucleus; Globose nucleus; 9 – Inferior cerebellar peduncle; 10 – Posterior spinocerebellar tract; Dorsal spinocerebellar tract



**Рис. 147. Передний (вентральный) спинномозжечковый проводящий путь (схема).** Стрелки указывают направления движения нервных импульсов:

1 – Spinal cord; 2 – Anterior spinocerebellar tract; Ventral spinocerebellar tract; 3 – Spinal ganglion; Dorsal root ganglion; 4 – Myelencephalon; Medulla oblongata; Bulb; 5 – Vermis of cerebellum [I–X], cortex; 6 – Posterior interpositus nucleus; Globose nucleus; 7 – Cerebellar cortex; 8 – Dentate nucleus; Nucleus lateralis cerebelli

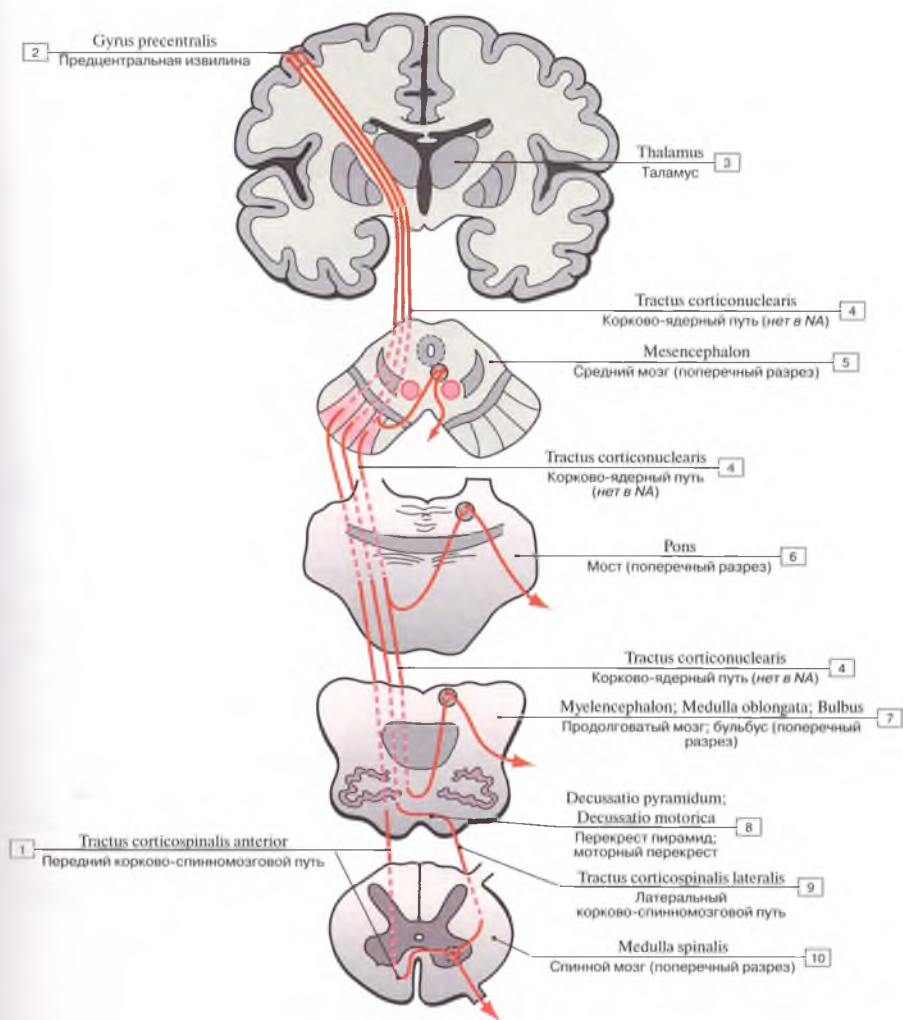


Рис. 148. Пирамидный путь, стрелками показано направление движения нервных импульсов (схема):

1 – Anterior corticospinal tract; Ventral corticospinal tract; 2 – Precentral gyrus; 3 – Thalamus; Dorsal thalamus; 4 – Corticonuclear tract; Mesencephalon; Midbrain; 6 – Pons; 7 – Myelencephalon; Medulla oblongata; Bulb; 8 – Decussation of pyramids; Motor decussation; 9 – Lateral corticospinal tract; 10 – Spinal cord

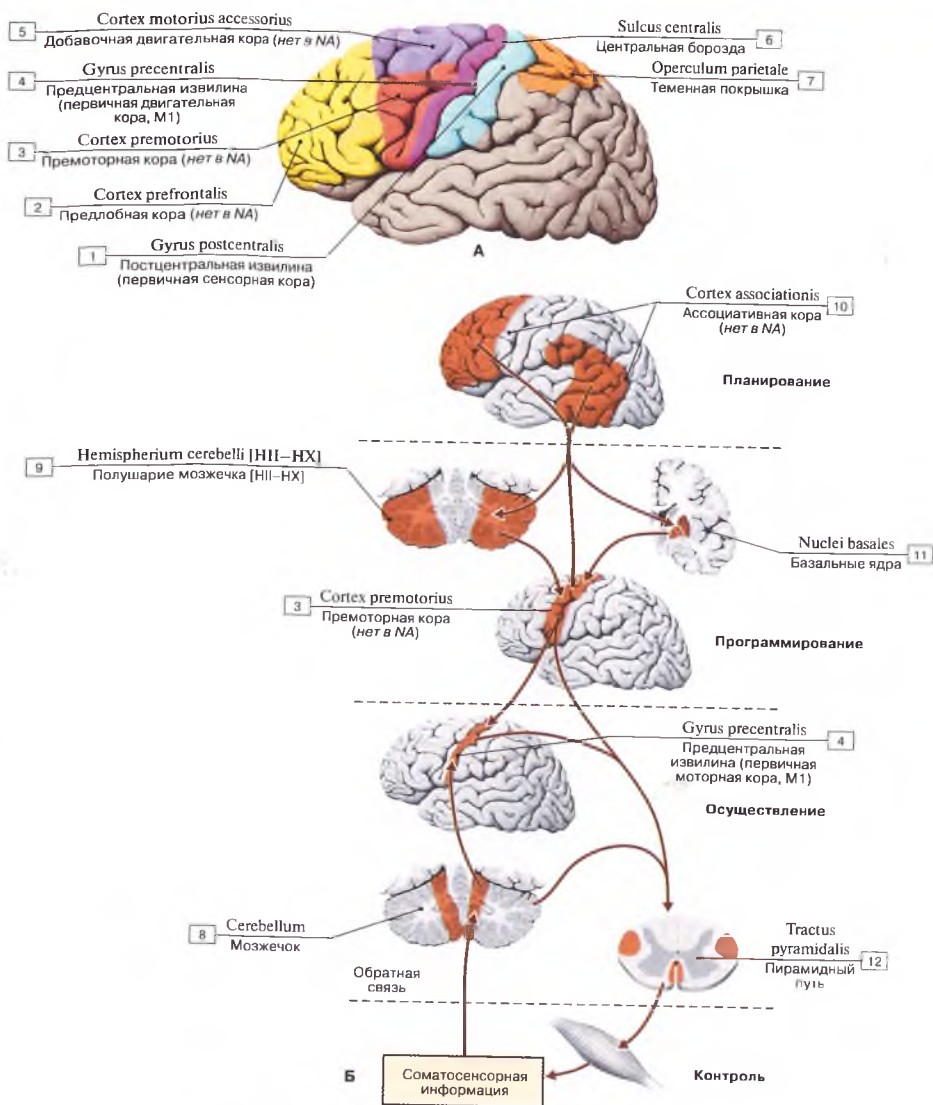


Рис. 149. Двигательная система (схема) (А – двигательные центры коры; Б – анатомические структуры пирамидного пути);

- 1 – Postcentral gyrus; 2 – Prefrontal cortex; 3 – Premotor cortex; 4 – Precentral gyrus; 5 – Accessory motor cortex; 6 – Central sulcus; 7 – Parietal operculum; 8 – Cerebellum; 9 – Hemisphere of cerebellum [HII–HX]; 10 – Association cortex; 11 – Basal nuclei; 12 – Pyramidal tract

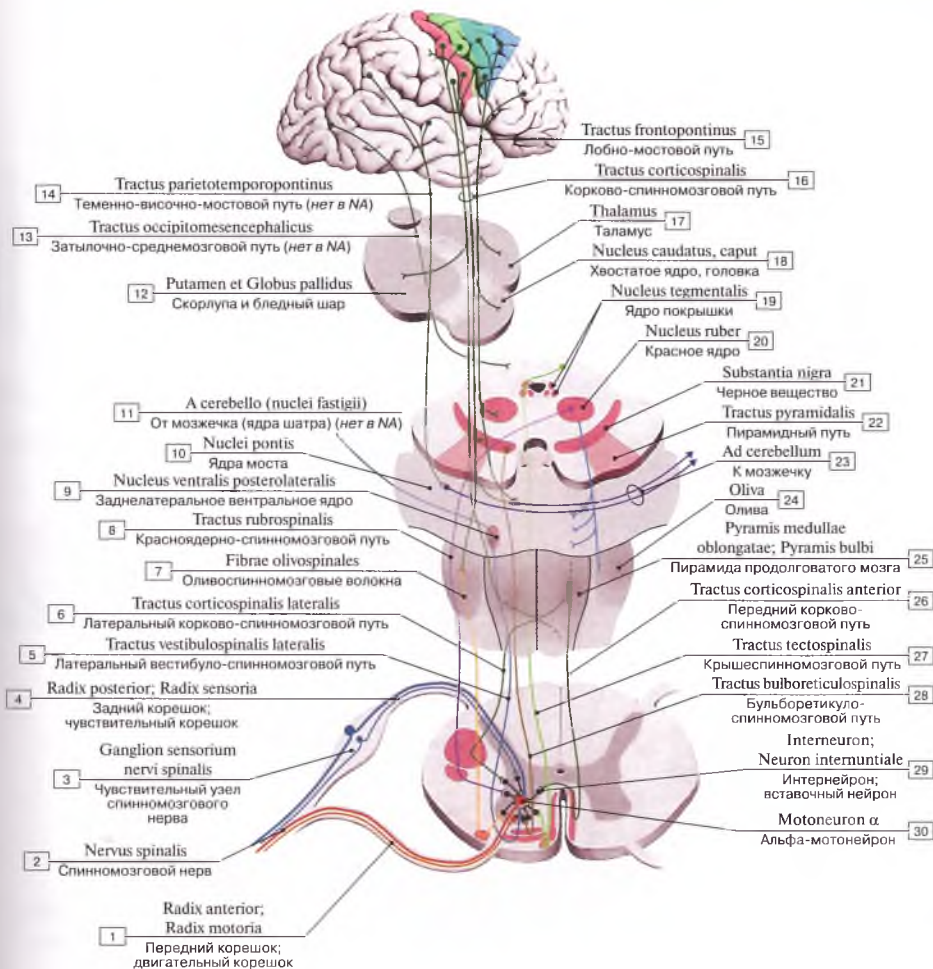


Рис. 150. Основные экстрапирамидные пути (схема):

1 - Anterior root; Motor root; Ventral root; 2 - Spinal nerve; 3 - Spinal ganglion; Dorsal root ganglion; 4 - Posterior root; Sensory root; Dorsal root; 5 - Lateral vestibulospinal tract; 6 - Lateral corticospinal tract; 7 - Olivospinal fibres; 8 - Rubrospinal tract; 9 - Ventral posterolateral nucleus; 10 - Pontine nuclei; 11 - From cerebellum (fastigial nucleus); 12 - Putamen and Globus pallidus; 13 - Occipitomesencephalic tract; 14 - Parietotemporo-pontine tract; 15 - Frontopontine tract; 16 - Corticospinal tract; 17 - Thalamus; Dorsal thalamus; 18 - Caudate nucleus, head; 19 - Tegmental nucleus; 20 - Red nucleus; 21 - Substantia nigra; 22 - Pyramidal tract; 23 - To cerebellum; 24 - Inferior olive; 25 - Pyramid; 26 - Anterior corticospinal tract; Ventral corticospinal tract; 27 - Tectospinal tract; 28 - Reticulospinal tract; Lateral reticulospinal tract; 29 - Interneuron; Internuncial neuron; 30 - Alpha motor neuron

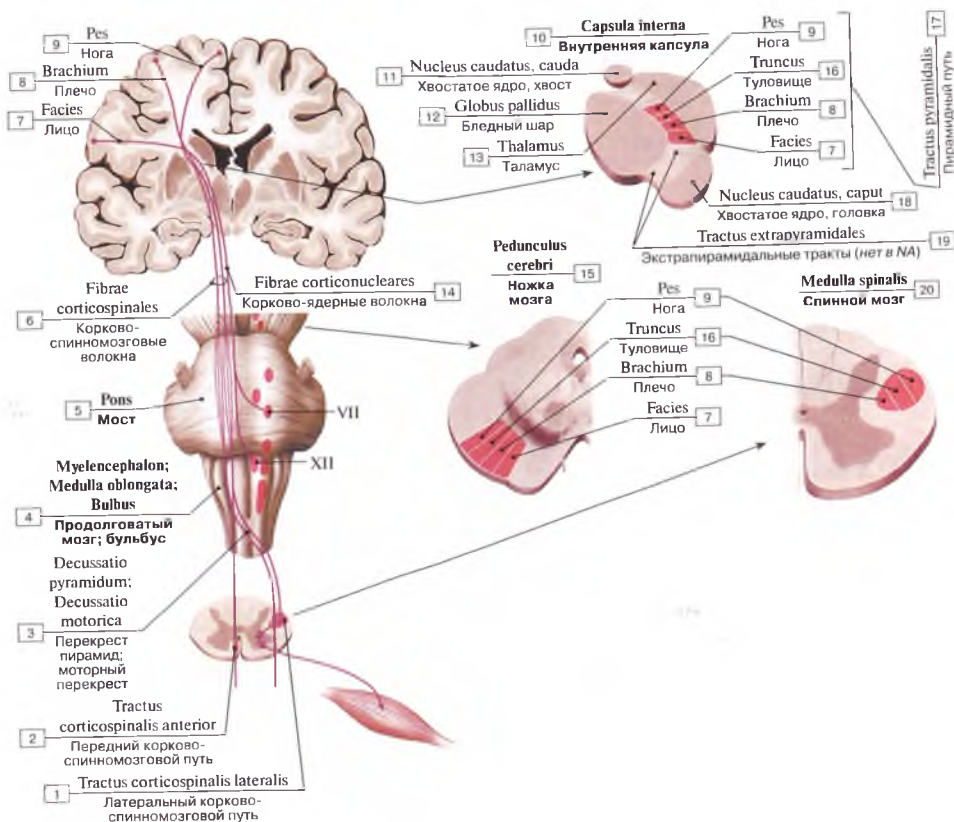


Рис. 151. Ход пирамидных путей (схема):

1 – Lateral corticospinal tract; 2 – Anterior corticospinal tract; 3 – Decussation of pyramids; 4 – Myelencephalon; 5 – Pons; 6 – Corticospinal fibres; 7 – Face; 8 – Arm; 9 – Leg; 10 – Internal capsule; 11 – Caudate nucleus, tail; 12 – Globus pallidus segment; 13 – Thalamus; 14 – Corticonuclear fibres; 15 – Cerebral peduncle; 16 – Trunk; 17 – Pyramidal tract; 18 – Caudate nucleus, head; 19 – Extrapyramidal tracts; 20 – Spinal cord

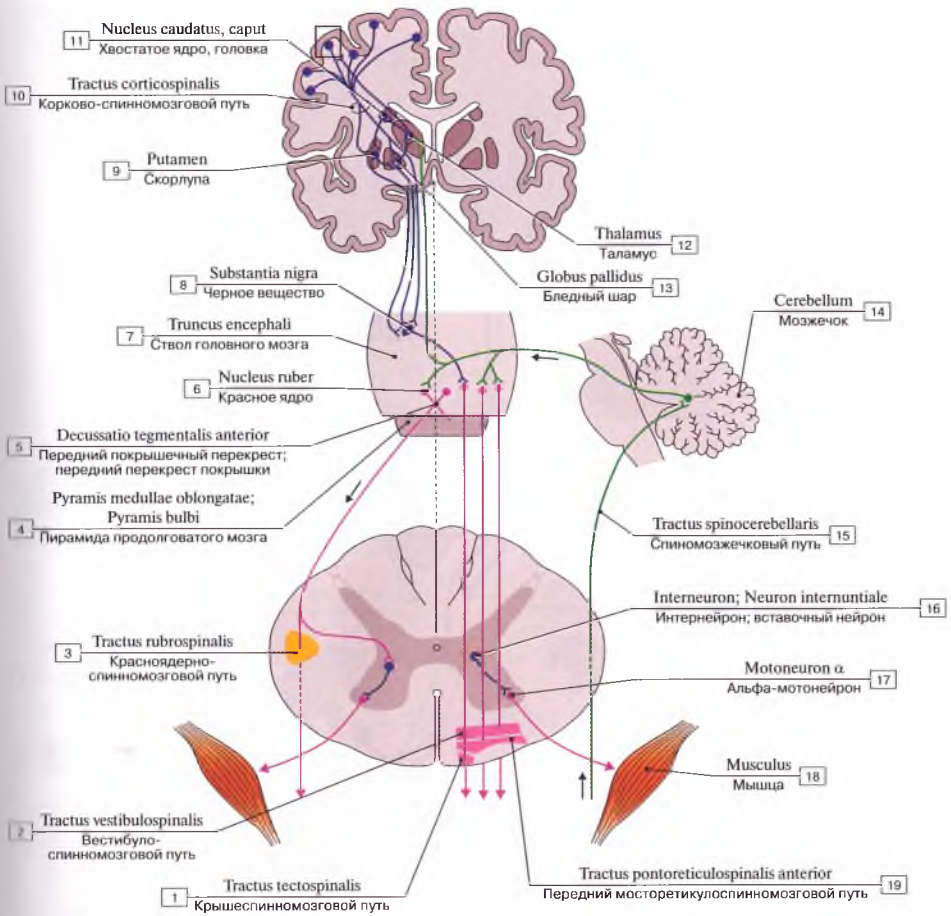


Рис. 152. Основные экстрапирамидные пути (схема):

1 – Tectospinal tract; 2 – Vestibulospinal tract; 3 – Rubrospinal tract; 4 – Pyramid; 5 – Anterior tegmental decussation; Ventral tegmental decussation; 6 – Red nucleus; 7 – Brainstem; 8 – Substantia nigra; 9 – Putamen; 10 – Corticospinal tract; 11 – Caudate nucleus, head; 12 – Thalamus; Dorsal thalamus; 13 – Globus pallidus; 14 – Cerebellum; 15 – Spinocerebellar tract; 16 – Interneuron; Internuncial neuron; 17 – Alpha motor neuron; 18 – Muscle; 19 – Anterior pontoreticulospinal tract; Ventral pontoreticulospinal tract

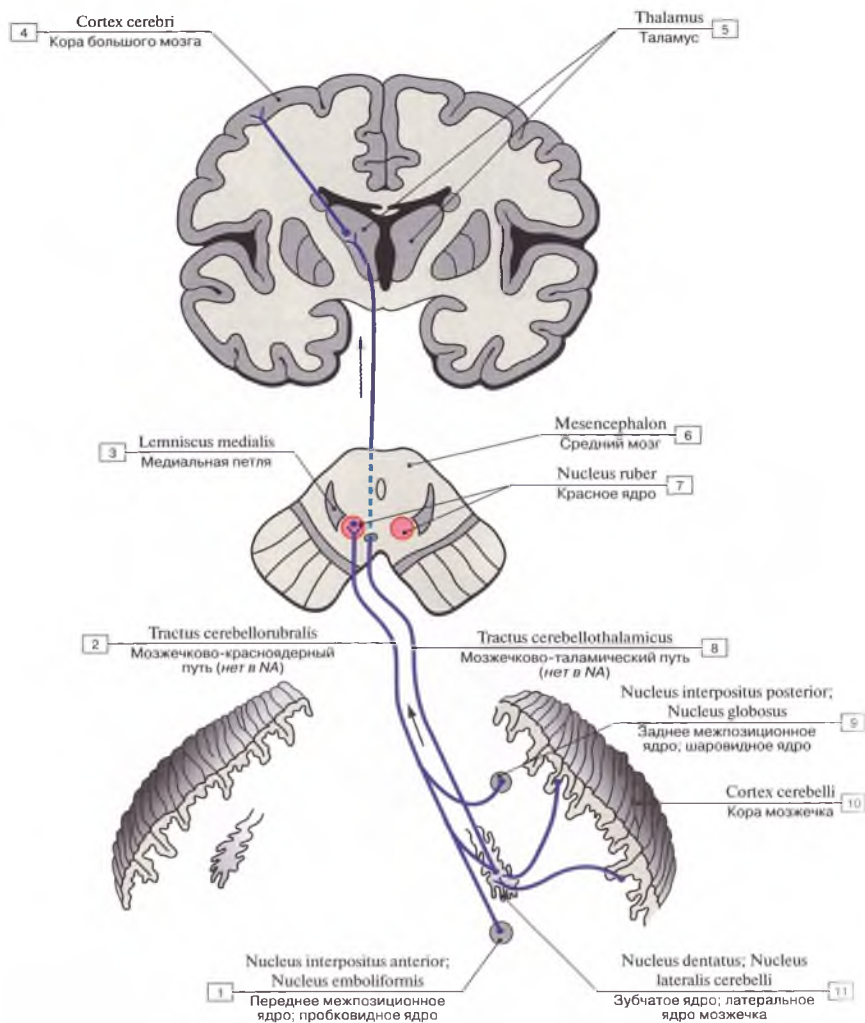


Рис. 153. Мозжечково-покрышечный и мозжечково-таламический проводящие пути (схема):

1 – Anterior interpositus nucleus; Emboliform nucleus; 2 – Cerebellorubral tract; 3 – Medial lemniscus; 4 – Cerebral cortex; 5 – Thalamus, Dorsal thalamus; 6 – Mesencephalon; Midbrain; 7 – Red nucleus; 8 – Cerebellothalamic tract; 9 – Posterior interpositus nucleus; Globose nucleus; 10 – Cerebellar cortex; 11 – Dentate nucleus; Nucleus lateralis cerebelli



Рис. 154. Красноядерно-спинномозговой путь (схема).  
Стрелками показано направление движения нервных импульсов:

1 – Dentate nucleus; Nucleus lateralis cerebelli; 2 – Mesencephalon; Midbrain; 3 – Red nucleus; 4 – Rubrospinal tract; 5 – Cerebellar cortex; 6 – Myelencephalon; Medulla oblongata; Bulb; 7 – Spinal cord

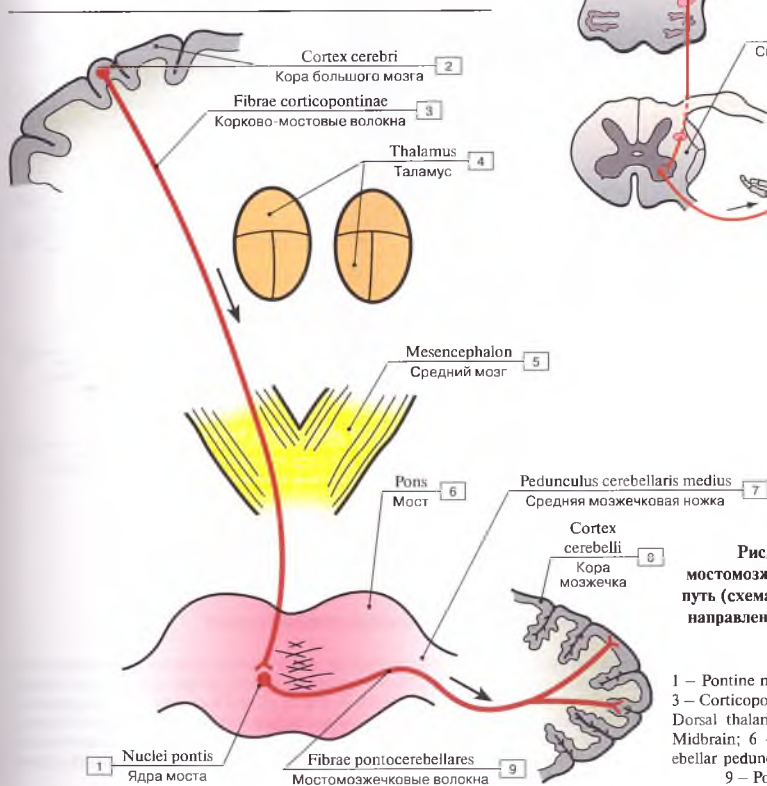
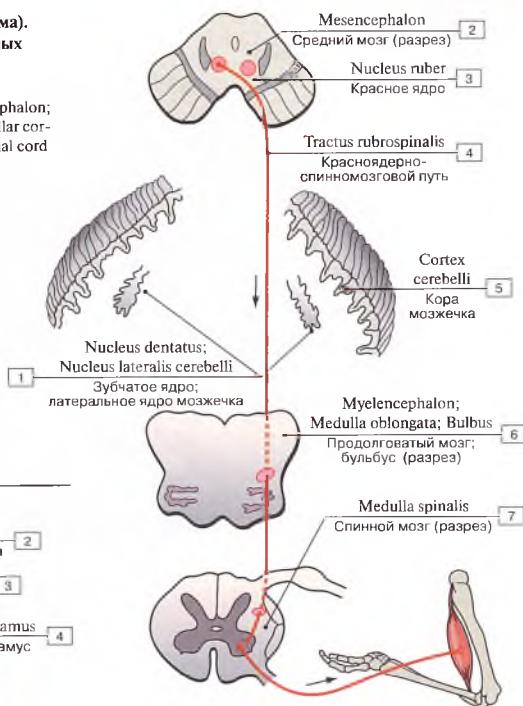


Рис. 155. Корково-мостомозжечковый проводящий путь (схема). Стрелки указывают направления движения нервных импульсов:

1 – Pontine nuclei; 2 – Cerebral cortex; 3 – Corticopontine fibres; 4 – Thalamus; Dorsal thalamus; 5 – Mesencephalon; Midbrain; 6 – Pons; 7 – Middle cerebellar peduncle; 8 – Cerebellar cortex; 9 – Pontocerebellar fibres

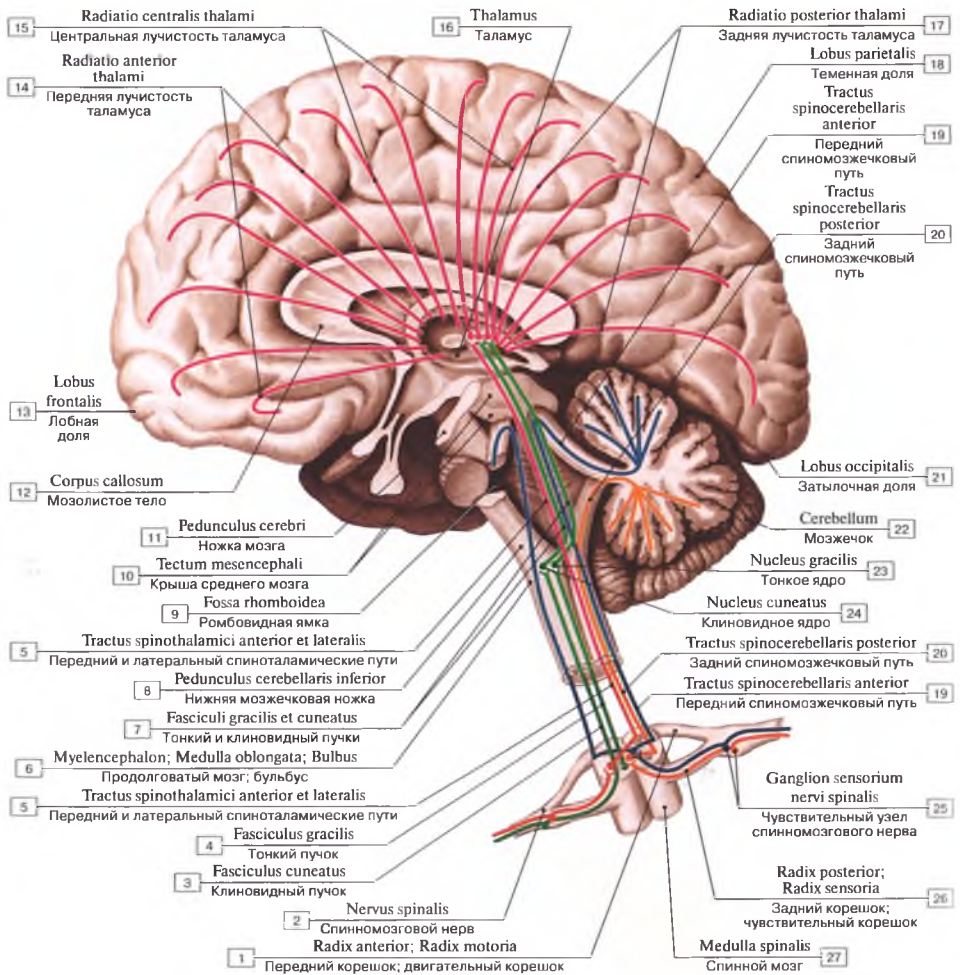


Рис. 156. Восходящие пути ствола мозга, правое полушарие (схема):

1 — Anterior root; Motor root; Ventral root; 2 — Spinal nerve; 3 — Cuneate fasciculus; 4 — Gracile fasciculus; 5 — Anterior spinothalamic tract; Ventral spinothalamic tract; Lateral spinothalamic tract; 6 — Myelencephalon; Medulla oblongata; Bulb; 7 — Gracile and cuneate fascicles; 8 — Inferior cerebellar peduncle; 9 — Rhomboid fossa; Floor of fourth ventricle; 10 — Tectum of midbrain; 11 — Cerebral peduncle; 12 — Corpus callosum; 13 — Frontal lobe; 14 — Anterior thalamic radiation; 15 — Central thalamic radiation; 16 — Thalamus; Dorsal thalamus; 17 — Posterior thalamic radiation; 18 — Parietal lobe; 19 — Anterior spinocerebellar tract; Ventral spinocerebellar tract; 20 — Posterior spinocerebellar tract; Dorsal spinocerebellar tract; 21 — Occipital lobe; 22 — Cerebellum; 23 — Gracile nucleus; 24 — Cuneate nucleus; 25 — Spinal ganglion; Dorsal root ganglion; 26 — Posterior root; Sensory root; Dorsal root; 27 — Spinal cord

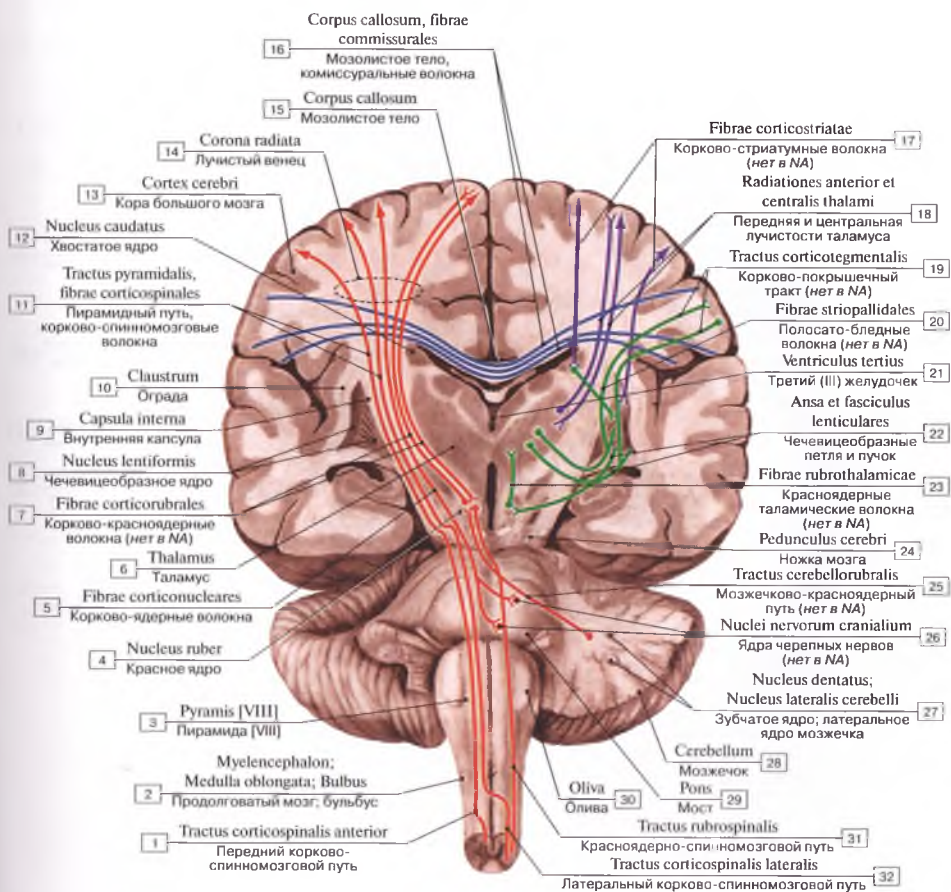


Рис. 157. Нисходящие пути ствола мозга, фронтальный разрез (схема):

1 — Anterior corticospinal tract; Ventral corticospinal tract; 2 — Myelencephalon; Medulla oblongata; Bulb; 3 — Pyramid [VIII]; 4 — Red nucleus; 5 — Corticonuclear fibres; 6 — Thalamus; Dorsal thalamus; 7 — Corticorebral fibres; 8 — Lentiform nucleus; Lenticular nucleus; 9 — Internal capsule; 10 — Claustrum; 11 — Pyramidal tract, corticospinal fibres; 12 — Caudate nucleus; 13 — Cerebral cortex; 14 — Corona radiata; 15 — Corpus callosum; 16 — Corpus callosum, commissural fibres; 17 — Corticospinal fibres; 18 — Anterior and central thalamic radiations; 19 — Corticotegmental tract; 20 — Striopallidal fibres; 21 — Third ventricle; 22 — Ansa et fasciculus lenticularis and Lenticular fasciculus; 23 — Rubrothalamic fibres; 24 — Cerebral peduncle; 25 — Cerebellorubral tract; 26 — Nuclei nervorum cranialium; 27 — Dentate nucleus; Nucleus lateralis cerebelli; 28 — Cerebellum; 29 — Pons; 30 — Inferior olive; 31 — Tractus rubrospinalis; 32 — Lateral corticospinal tract

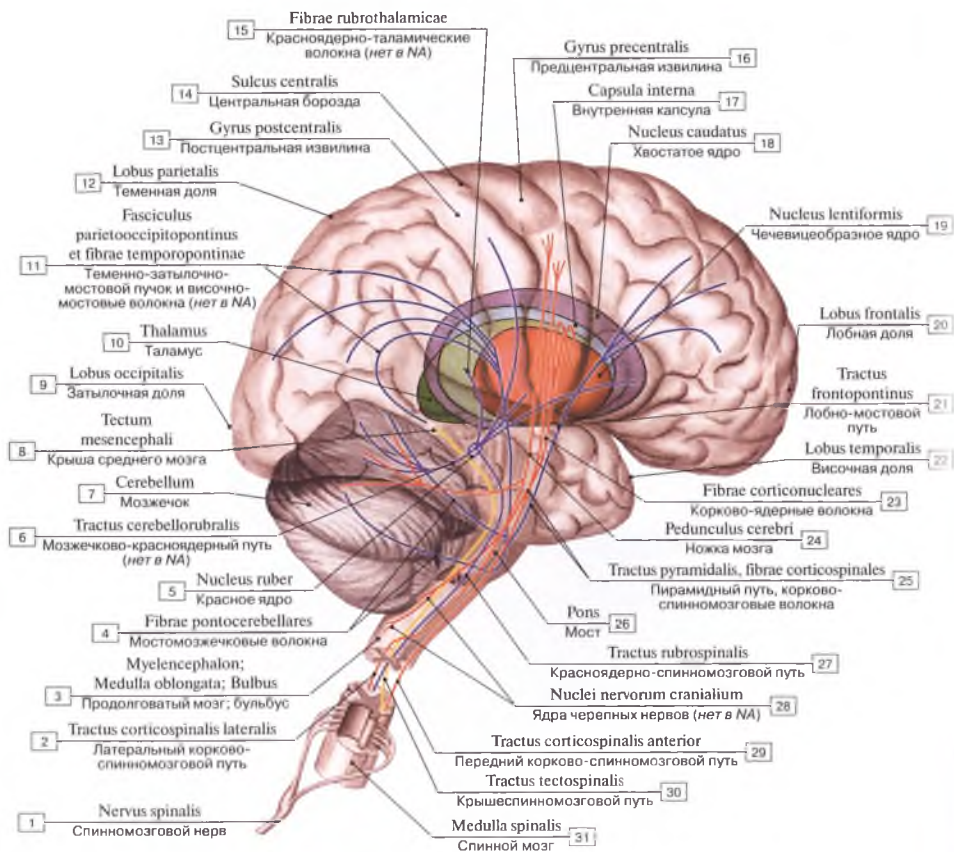


Рис. 158. Нисходящие пути ствола мозга, вид сбоку:

1 – Spinal nerve; 2 – Lateral corticospinal tract; 3 – Myelencephalon; Medulla oblongata; Bulb; 4 – Pontocerebellar fibres; 5 – Red nucleus; 6 – Cerebellar-brainstem tract; 7 – Cerebellum; 8 – Tectum of midbrain; 9 – Occipital lobe; 10 – Thalamus; Dorsal thalamus; 11 – Parieto-occipitopontine fasciculus and Temporopontine fibres; 12 – Parietal lobe; 13 – Postcentral gyrus; 14 – Central sulcus; 15 – Rubrothalamic fibres; 16 – Precentral gyrus; 17 – Internal capsule; 18 – Caudate nucleus; 19 – Lentiform nucleus; Lenticular nucleus; 20 – Frontal lobe; 21 – Frontopontine tract; 22 – Temporal lobe; 23 – Corticonuclear fibres; 24 – Cerebral peduncle; 25 – Pyramidal tract, corticospinal fibres; 26 – Pons; 27 – Rubrospinal tract; 28 – Nuclei of cranial nerves; 29 – Anterior corticospinal tract; Ventral corticospinal tract; 30 – Tectospinal tract; 31 – Spinal cord

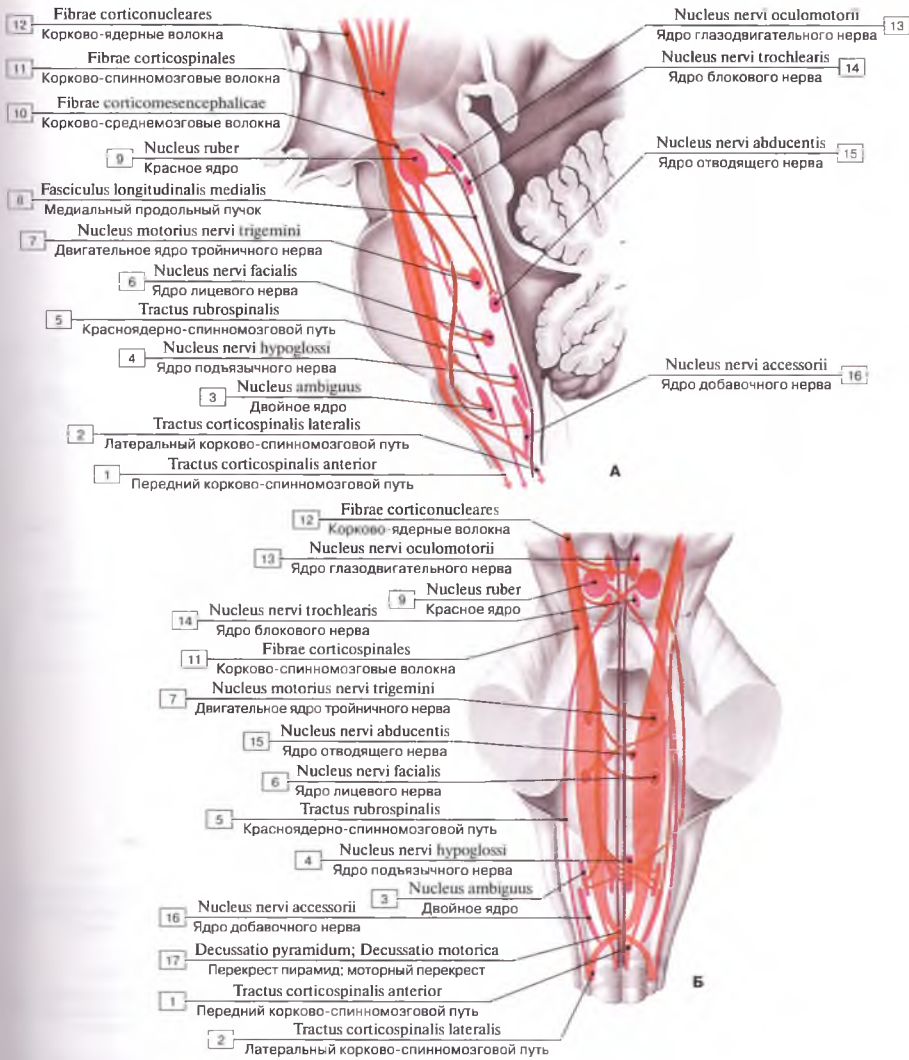


Рис. 159. Нисходящие пути ствола мозга (А – сагиттальный разрез, вид слева; Б – фронтальный разрез, вид сзади, мозжечок удален) (схема):

1 – Anterior corticospinal tract; Ventral corticospinal tract; 2 – Lateral corticospinal tract; 3 – Nucleus ambiguus; 4 – Nucleus of hypoglossal nerve; 5 – Rubrospinal tract; 6 – Motor nucleus of facial nerve; 7 – Motor nucleus of trigeminal nerve; 8 – Medial longitudinal fasciculus; 9 – Red nucleus; 10 – Corticomesecephalic fibres; 11 – Corticospinal fibres; 12 – Corticonuclear fibres; 13 – Nucleus of oculomotor nerve; 14 – Nucleus of trochlear nerve; 15 – Nucleus of abducent nerve; 16 – Nucleus of accessory nerve; 17 – Decussation of pyramids; Motor decussation

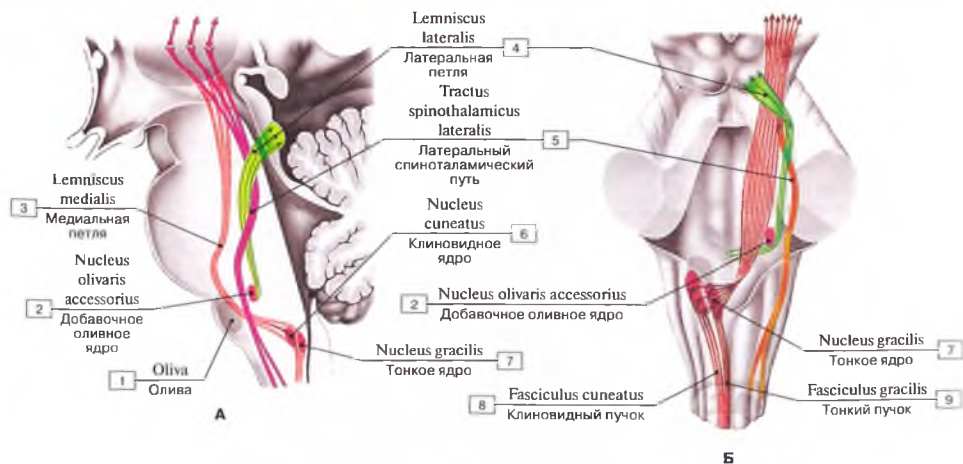


Рис. 160. Восходящие пути ствола мозга (А – вид слева; Б – вид сзади) (схема):

1 – Inferior olive; 2 – Accessory olivary nucleus; 3 – Medial lemniscus; 4 – Lateral lemniscus; 5 – Lateral spinothalamic tract; 6 – Cuneate nucleus; 7 – Gracile nucleus; 8 – Cuneate fasciculus; 9 – Gracile fasciculus

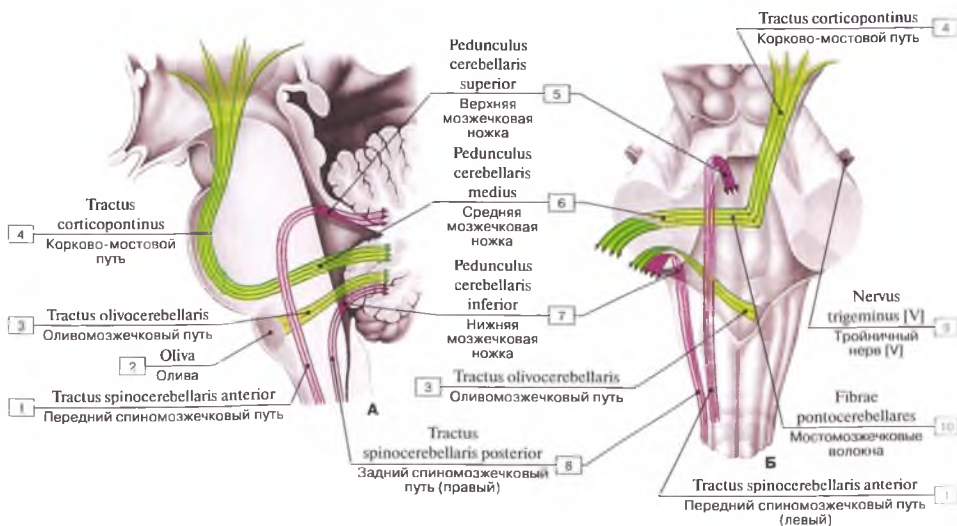
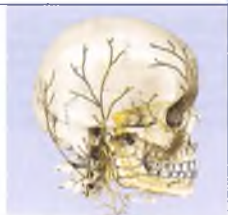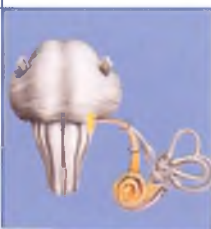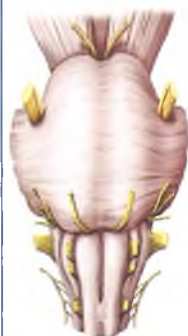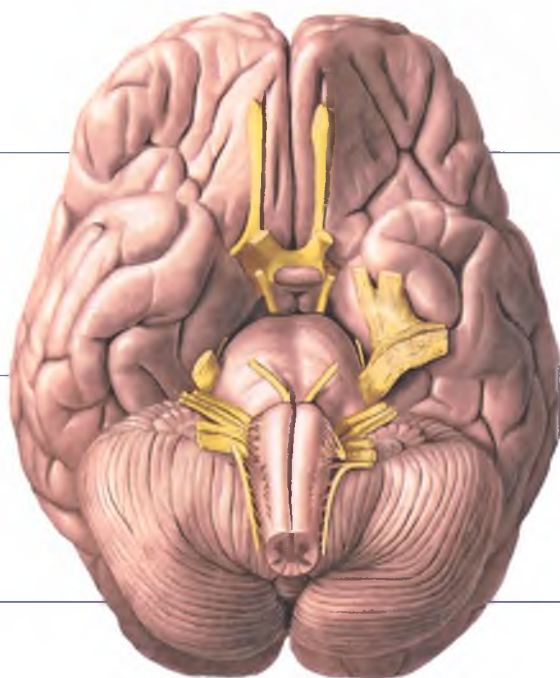


Рис. 161. Основные проводящие пути мозжечка в стволе мозга (А – сагиттальный разрез, вид слева; Б – вид сзади, мозжечок удален) (схема):

1 – Anterior spinocerebellar tract; 2 – Inferior olive; 3 – Olivocerebellar tract; 4 – Corticopontine tract; 5 – Superior cerebellar peduncle; 6 – Middle cerebellar peduncle; 7 – Inferior cerebellar peduncle; 8 – Posterior spinocerebellar tract; 9 – Dorsal spinocerebellar tract; 10 – Pontocerebellar fibres

# ПЕРИФЕРИЧЕСКАЯ НЕРВНАЯ СИСТЕМА

## Черепные нервы



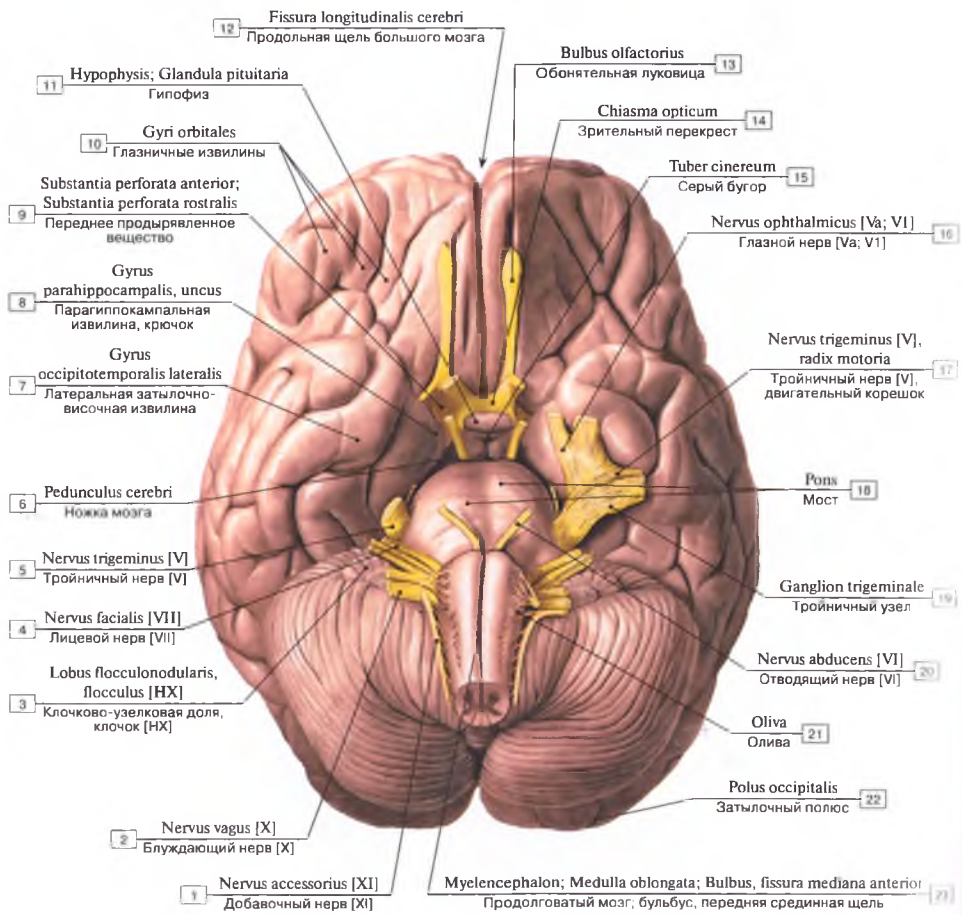
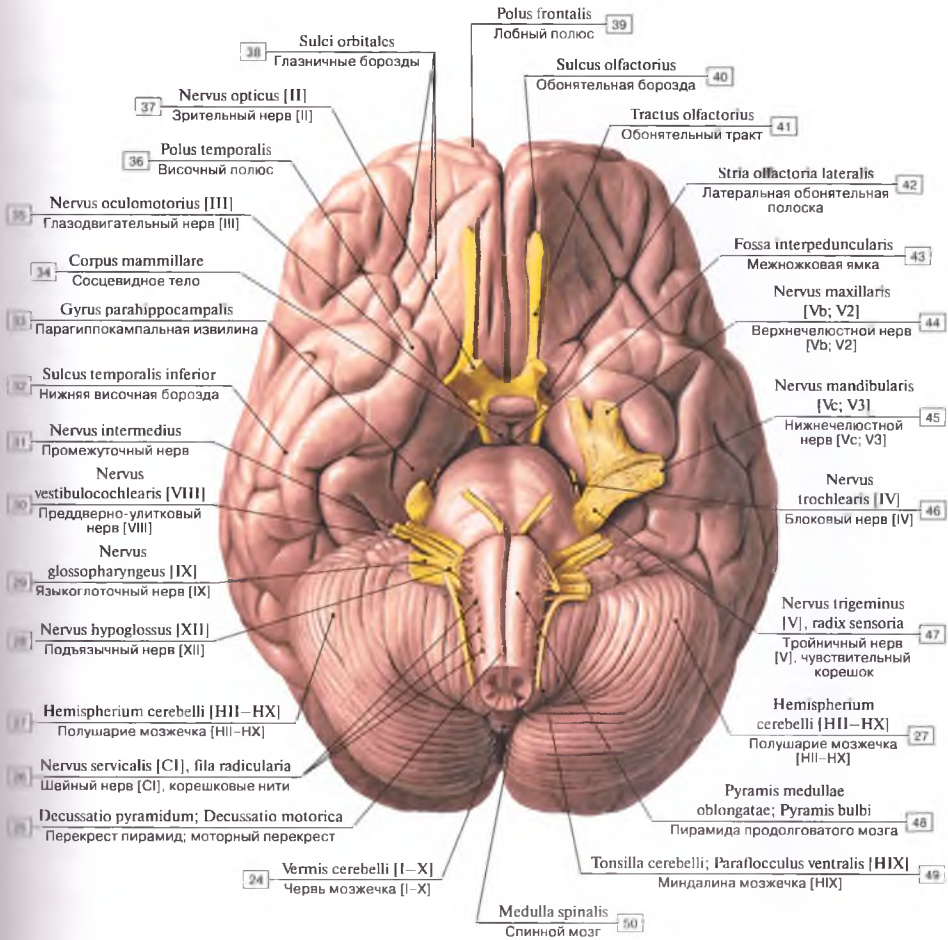


Рис. 162. Выход черепных нервов из ствола мозга, вид снизу:

1 – Accessory nerve [XI]; 2 – Vagus nerve [X]; 3 – Flocculonodular lobe, flocculus [HX]; 4 – Facial nerve [VII]; 5 – Trigeminal nerve [V]; 6 – Cerebral peduncle; 7 – Lateral occipitotemporal gyrus; 8 – Parahippocampal gyrus, uncus; 9 – Anterior perforated substance; 10 – Orbital gyri; 11 – Pituitary gland; 12 – Longitudinal cerebral fissure; 13 – Olfactory bulb; 14 – Optic chiasma; 15 – Tuber cinereum; 16 – Ophthalmic nerve; Ophthalmic division [Va; V1]; 17 – Trigeminal nerve [V] motor root; 18 – Pons; 19 – Trigeminal ganglion; 20 – Abducent nerve; Abducent nerve [VI]; 21 – Inferior olive; 22 – Occipital pole; 23 – Myelencephalon; Medulla oblongata; Bulb, anterior median fissure; ventral median fissure; 24 – Vermis of cerebellum [I, X].





31 – Decussation of pyramids; Motor decussation; 26 – Cervical nerve [CI], rootlets; 27 – Hemisphere of cerebellum [HII-HX]; 28 – Hypoglossal nerve [XII]; 29 – Glossopharyngeal nerve [IX]; 30 – Vestibulocochlear nerve [VIII]; 31 – Intermediate nerve; 32 – Inferior temporal sulcus; 33 – Parahippocampal gyrus; 34 – Mammillary body; 35 – Oculomotor nerve [III]; 36 – Temporal pole; 37 – Optic nerve [II]; 38 – Orbital sulci; 39 – Frontal pole; 40 – Olfactory groove; 41 – Olfactory tract; 42 – Lateral olfactory stria; 43 – Interpeduncular fossa; 44 – Maxillary nerve; Maxillary division [Vb; V2]; 45 – Mandibular nerve; Mandibular division [Vc; V3]; 46 – Trochlear nerve [IV]; 47 – Trigeminal nerve [V], sensory root; 48 – Pyramid; 49 – Tonsil of cerebellum; 50 – Spinal cord

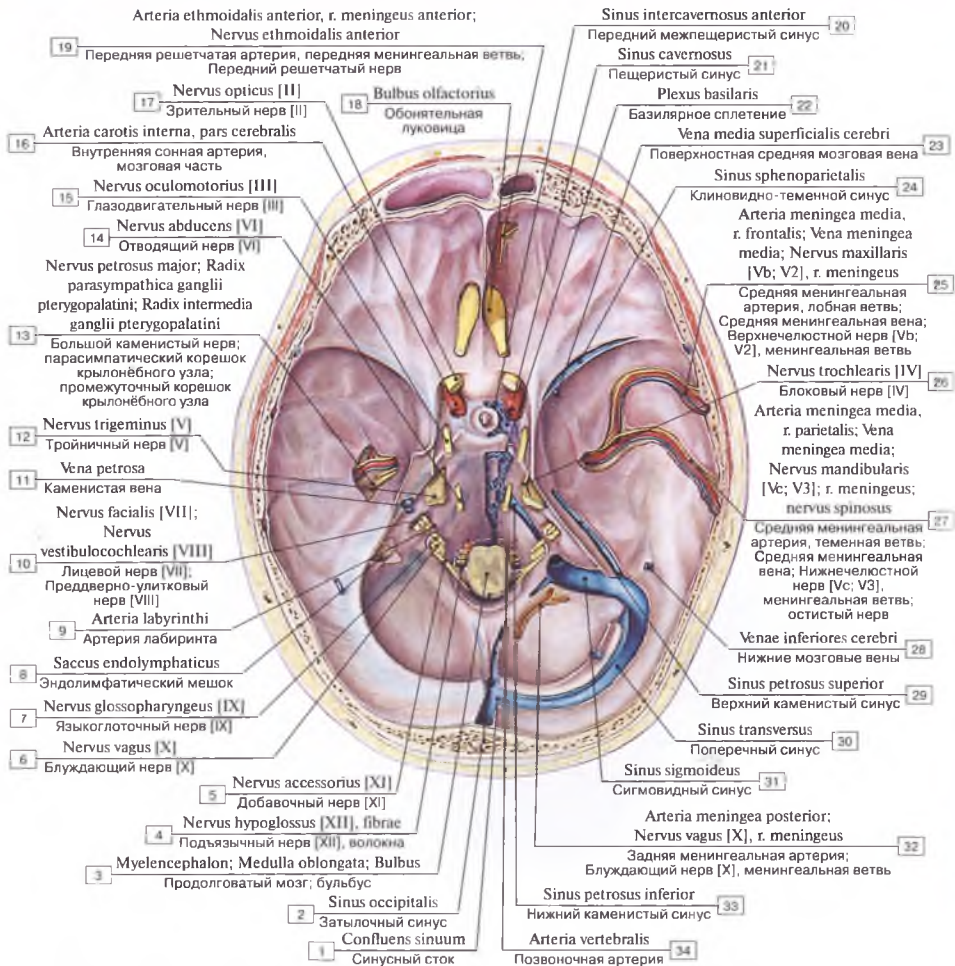


Рис. 163. Выход нервов из черепа:

1 — Confluence of sinuses; 2 — Occipital sinus; 3 — Myelencephalon; Medulla oblongata; Bulb; 4 — Hypoglossal nerve [XII], fibres; 5 — Accessory nerve [XI]; 6 — Vagus nerve [X]; 7 — Glossopharyngeal nerve [IX]; 8 — Endolymphatic sac; 9 — Labyrinthine artery; 10 — Facial nerve [VII]; Vestibulocochlear nerve [VIII]; 11 — Petrosal vein; 12 — Trigeminal nerve [V]; 13 — Greater petrosal nerve; Parasympathetic root of pterygopalatine ganglion; 14 — Abducent nerve; Abducens nerve [VI]; 15 — Oculomotor nerve [III]; 16 — Internal carotid artery, cerebral part; 17 — Optic nerve [II]; 18 — Olfactory bulb; 19 — Anterior ethmoidal artery, anterior meningeal branch; Anterior ethmoidal nerve; 20 — Anterior intercavernous sinus; 21 — Cavernous sinus; 22 — Basilar plexus; 23 — Superficial middle cerebral vein; 24 — Sphenoparietal sinus; 25 — Middle meningeal artery, frontal branch; Middle meningeal vein; Maxillary nerve; Maxillary division [Vb; V2], meningeal branch; 26 — Trochlear nerve [IV]; 27 — Middle meningeal artery, parietal branch; Middle meningeal vein; Mandibular nerve; Mandibular division [Vc; V3], meningeal branch; nervus spinosus; 28 — Inferior cerebral veins; 29 — Superior petrosal sinus; 30 — Transverse sinus; 31 — Sigmoid sinus; 32 — Posterior meningeal artery; Vagus nerve [X], meningeal branch; 33 — Inferior petrosal sinus; 34 — Vertebral artery

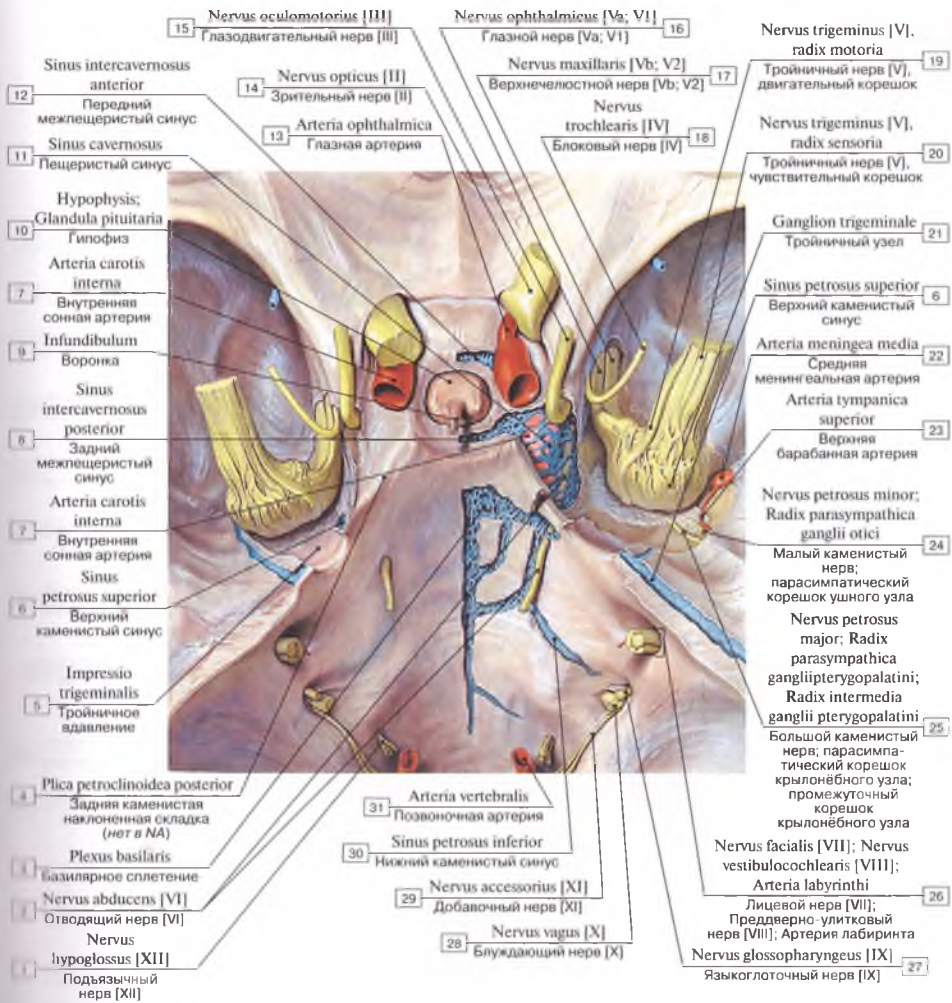


Рис. 164. Черепные нервы на внутреннем основании черепа:

1 – Hypoglossal nerve [XII]; 2 – Abducent nerve; Abducent nerve [VI]; 3 – Basilar plexus; 4 – Posterior petroclinoid fold; 5 – Trigeminal depression; 6 – Superior petrosal sinus; 7 – Internal carotid artery; 8 – Posterior intercavernous sinus; 9 – Infundibulum; 10 – Pituitary gland; 11 – Cavernous sinus; 12 – Anterior intercavernous sinus; 13 – Ophthalmic artery; 14 – Optic nerve [II]; 15 – Oculomotor nerve [III]; 16 – Ophthalmic nerve; Ophthalmic division [Va; V1]; 17 – Maxillary nerve; Maxillary division [Vb; V2]; 18 – Trochlear nerve [IV]; 19 – Trigeminal nerve [V], motor root; 20 – Trigeminal nerve [V], sensory root; 21 – Trigeminal ganglion; 22 – Middle meningeal artery; 23 – Superior tympanic artery; 24 – Lesser petrosal nerve; Parasympathetic root of otic ganglion; 25 – Greater petrosal nerve; Parasympathetic root of pterygopalatine ganglion; 26 – Facial nerve [VII]; Vestibulocochlear nerve [VIII]; Labyrinthine artery; 27 – Glossopharyngeal nerve [IX]; 28 – Vagus nerve [X]; 29 – Accessory nerve [XI]; 30 – Inferior petrosal sinus; 31 – Vertebral artery

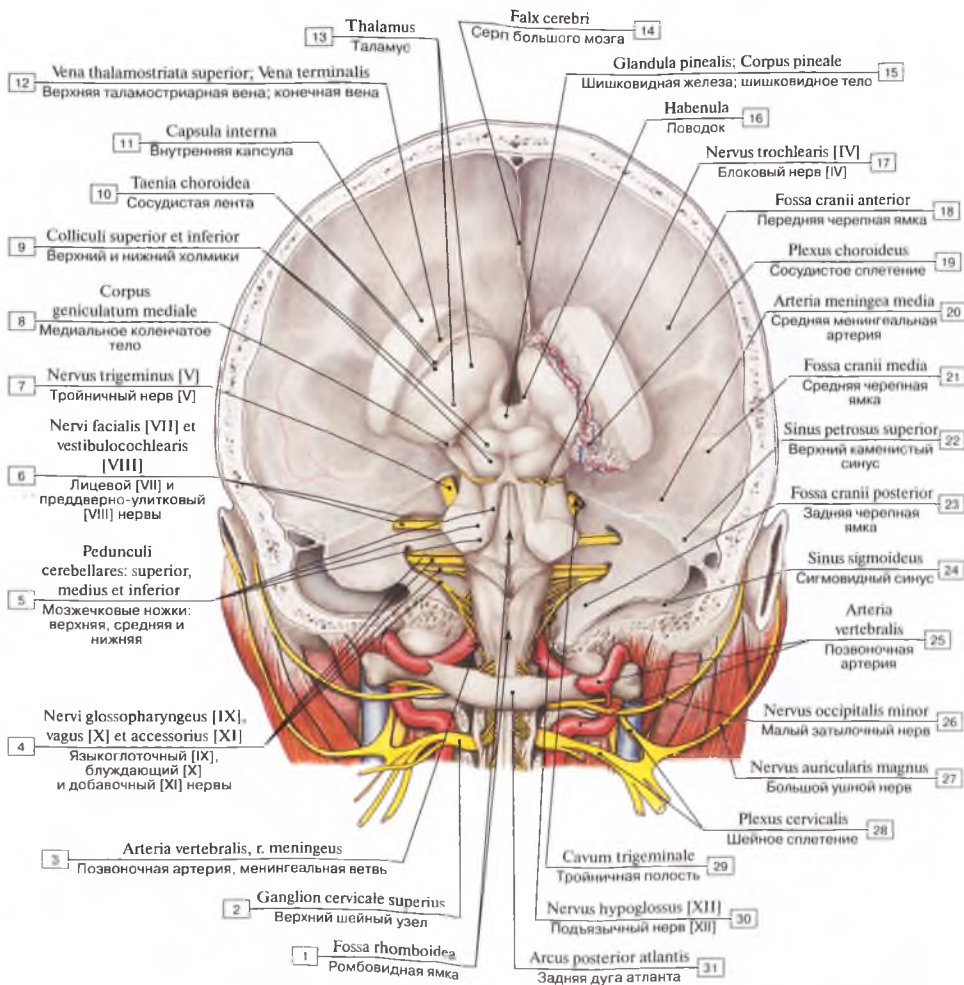


Рис. 165. Выход нервов из черепа, фронтальный разрез:

1 – Rhomboid fossa; Floor of fourth ventricle; 2 – Superior cervical ganglion; 3 – Vertebral artery, meningeal branch; 4 – Glossopharyngeal [IX], vagus [X] and accessory [XI] nerves; 5 – Cerebellar peduncles: superior, middle and inferior; 6 – Facial [VII] and vestibulocochlear [VIII] nerves; 7 – Trigeminal nerve [V]; 8 – Medial geniculate body; 9 – Superior and inferior colliculus; 10 – Choroid line; 11 – Internal capsule; 12 – Superior thalamostriate vein; 13 – Thalamus; Dorsal thalamus; 14 – Falx cerebri; Cerebral falx; 15 – Pineal gland; Pineal body; 16 – Habenula; 17 – Trochlear nerve [IV]; 18 – Anterior cranial fossa; 19 – Choroid plexus; 20 – Middle meningeal artery; 21 – Middle cranial fossa; 22 – Superior petrosal sinus; 23 – Posterior cranial fossa; 24 – Sigmoid sinus; 25 – Vertebral artery; 26 – Lesser occipital nerve; 27 – Great auricular nerve; 28 – Cervical plexus; 29 – Trigeminal cave; Trigeminal cavity; 30 – Hypoglossal nerve [XII]; 31 – Posterior arch

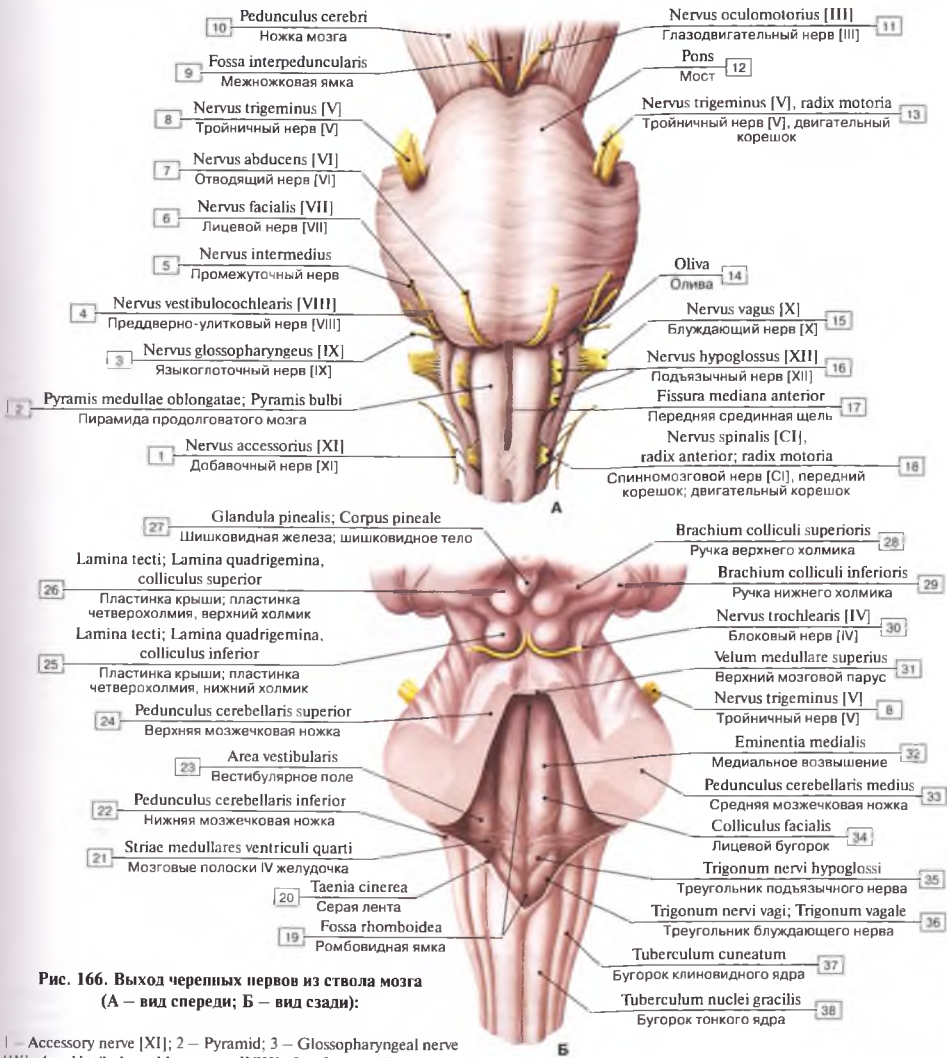


Рис. 166. Выход черепных нервов из ствола мозга (А – вид спереди; Б – вид сзади):

1 – Accessory nerve [XI]; 2 – Pyramid; 3 – Glossopharyngeal nerve [IX]; 4 – Vestibulocochlear nerve [VIII]; 5 – Intermediate nerve; 6 – Facial nerve [VII]; 7 – Abducent nerve; Abducens nerve [VI]; 8 – Trigeminal nerve [V]; 9 – Interpeduncular fossa; 10 – Cerebral peduncle; 11 – Oculomotor nerve [III]; 12 – Pons; 13 – Trigeminal nerve [V], motor root; 14 – Inferior olive; 15 – Vagus nerve [X]; 16 – Hypoglossal nerve [XII]; 17 – Anterior median fissure; Ventral median fissure; 18 – Spinal nerve [C1], anterior root; ventral root; 19 – Rhomboid fossa; Floor of fourth ventricle; 20 – Grey line; Taenia cinerea; 21 – Medullary striae of fourth ventricle; 22 – Inferior cerebellar peduncle; 23 – Vestibular area; 24 – Superior cerebellar peduncle; 25 – Tectal plate; 26 – Tectal plate; Quadrigeminal plate, superior colliculus; 27 – Pineal gland; Pineal body; 28 – Brachium of superior colliculus; 29 – Brachium of inferior colliculus; 30 – Trochlear nerve [IV]; 31 – Superior medullary velum; 32 – Medial eminence; 33 – Middle cerebellar peduncle; 34 – Facial colliculus; 35 – Hypoglossal trigone; Trigone of hypoglossal nerve; 36 – Vagal trigone; Trigone of vagal nerve; 37 – Cuneate tubercle; 38 – Gracile tubercle

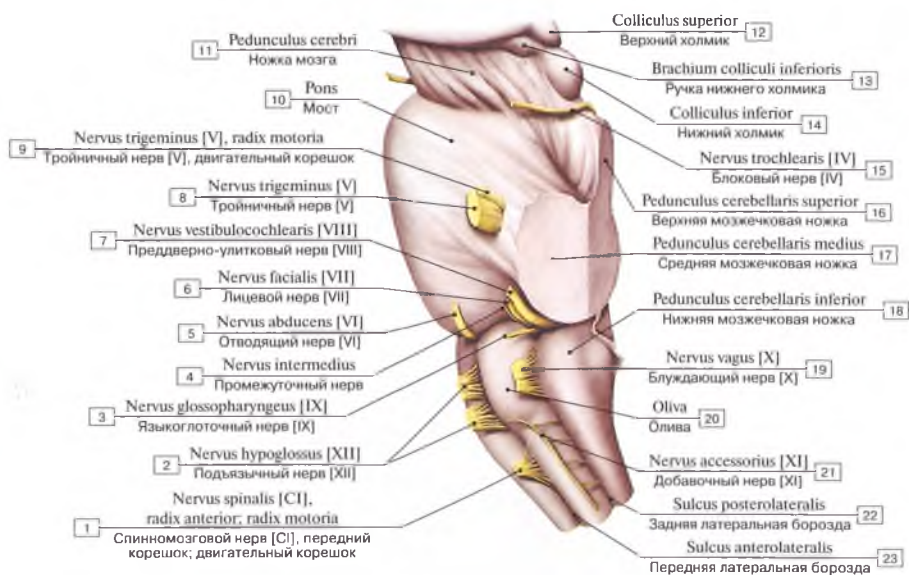


Рис. 167. Выход черепных нервов из ствола мозга, вид сбоку:

1 – Spinal nerve [CI], anterior root; motor root; ventral root; 2 – Hypoglossal nerve [XII]; 3 – Glossopharyngeal nerve [IX]; 4 – Intermediate nerve; 5 – Abducent nerve; Abducens nerve [VI]; 6 – Facial nerve [VII]; 7 – Vestibulocochlear nerve [VIII]; 8 – Trigeminal nerve [V], 9 – Trigeminal nerve [V], motor root; 10 – Pons; 11 – Cerebral peduncle; 12 – Superior colliculus; 13 – Brachium of inferior colliculus; 14 – Inferior colliculus; 15 – Trochlear nerve [IV]; 16 – Superior cerebellar peduncle; 17 – Middle cerebellar peduncle; 18 – Inferior cerebellar peduncle; 19 – Vagus nerve [X]; 20 – Inferior olive; 21 – Accessory nerve [XI]; 22 – Posterolateral sulcus; Dorsolateral sulcus; 23 – Anterolateral sulcus; Ventrolateral sulcus

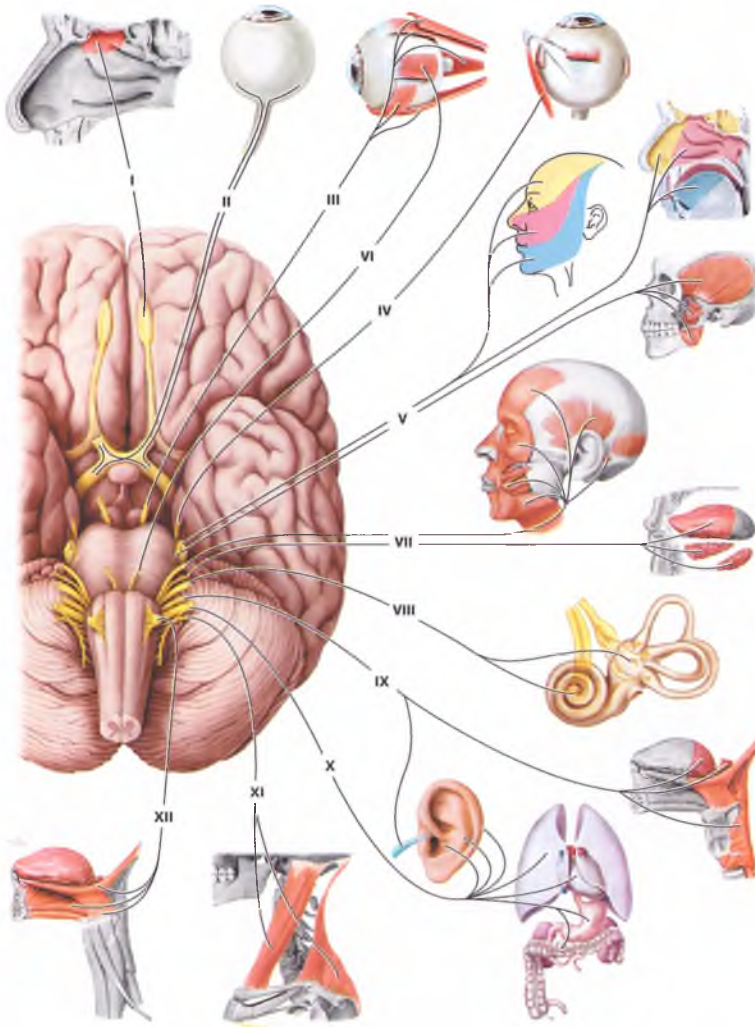
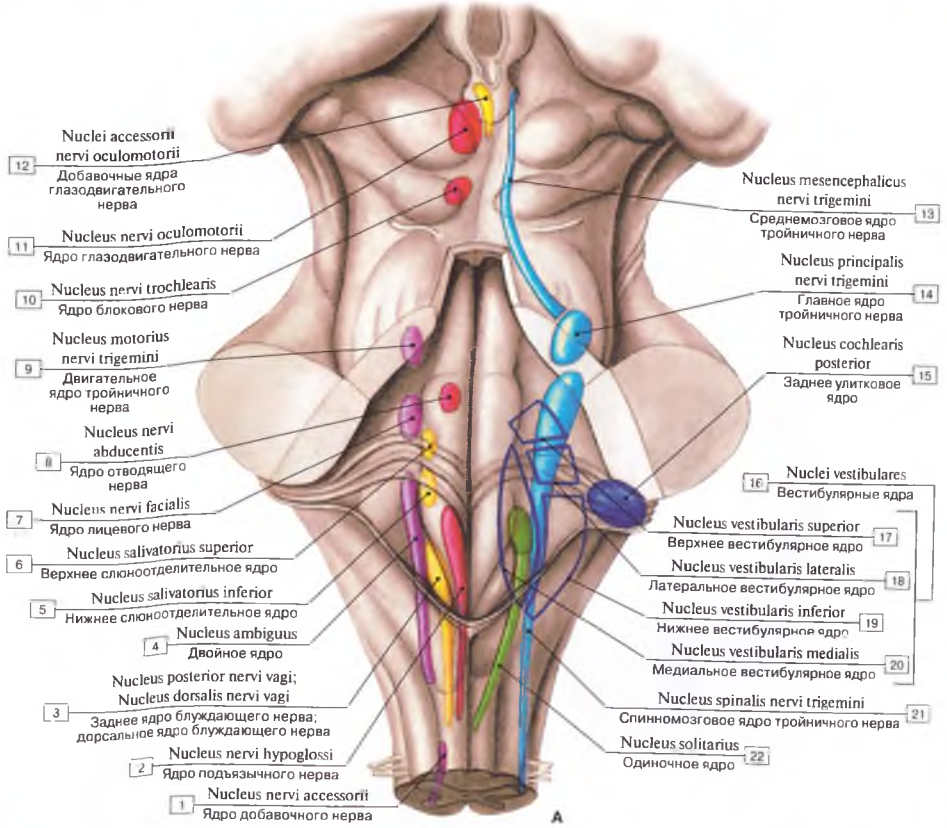
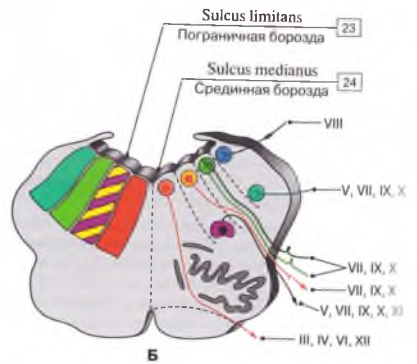


Рис. 168. Черепные нервы — управление органами (схема):

I — Nervus olfactorius [I]; Обонятельный нерв [I]; Olfactory nerve [I]; II — Nervus opticus [II]; Зрительный нерв [II]; Optic nerve [II]; III — Nervus oculomotorius [III]; Глазодвигательный нерв [III]; Oculomotor nerve [III]; IV — Nervus trochlearis [IV]; Блоковый нерв [IV]; Trochlear nerve [IV]; V — Nervus trigeminus [V]; Тройничный нерв [V]; Trigeminal nerve [V]; VI — Nervus abducens [VI]; Отводящий нерв [VI]; Abducent nerve; Abducens nerve [VI]; VII — Nervus facialis [VII]; Лицевой нерв [VII]; Facial nerve [VII]; VIII — Nervus vestibulocochlearis [VIII]; Преддверно-улитковый нерв [VIII]; Vestibulocochlear nerve [VIII]; IX — Nervus glossopharyngeus [IX]; Языкоглоточный нерв [IX]; Glossopharyngeal nerve [IX]; X — Nervus vagus [X]; Блуждающий нерв [X]; Vagus nerve [X]; XI — Nervus accessorius [XI]; Добавочный нерв [XI]; Accessory nerve [XI]; XII — Nervus hypoglossus [XII]; Подъязычный нерв [XII]; Hypoglossal nerve [XII].



- Общесоматические эфферентные ядра (GSE)
- Общие висцеральные эфферентные ядра (GVE)
- Специфические висцеральные эфферентные ядра (SVE)
- Общие и специфические висцеральные эфферентные ядра (G/SVA)
- Общесоматические афферентные ядра (GSA)
- Специфические соматические афферентные ядра (SSA)





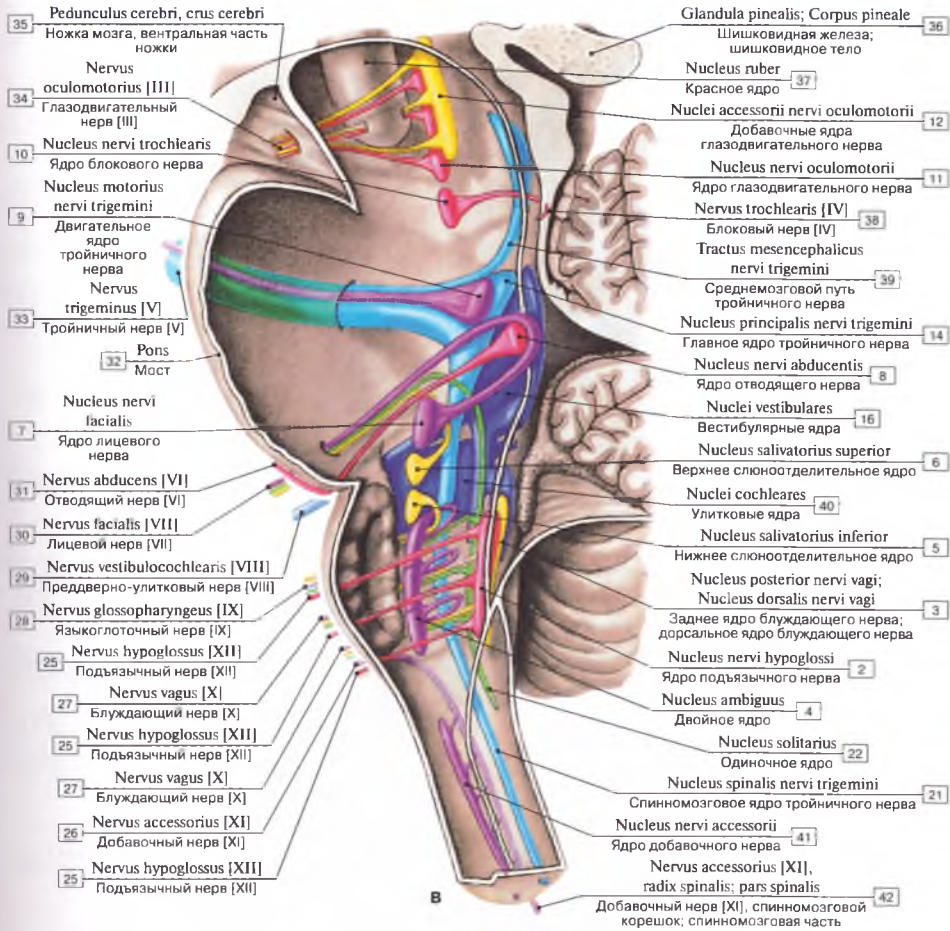


Рис. 169. Проекция ядер черепных нервов в стволе мозга (А – вид сзади; Б – вид на поперечном разрезе; В – вид сбоку):

1 – Nucleus of accessory nerve; 2 – Nucleus of hypoglossal nerve; 3 – Posterior nucleus of vagus nerve; Dorsal nucleus of vagus nerve; 4 – Nucleus ambiguus; 5 – Inferior salivatory nucleus; 6 – Superior salivatory nucleus; 7 – Motor nucleus of facial nerve; 8 – Nucleus of abducens nerve; 9 – Motor nucleus of trigeminal nerve; 10 – Nucleus of trochlear nerve; 11 – Nucleus of oculomotor nerve; 12 – Accessory nuclei of oculomotor nerve; 13 – Mesencephalic nucleus of trigeminal nerve; 14 – Principal sensory nucleus of trigeminal nerve; 15 – Posterior cochlear nucleus; Dorsal cochlear nucleus; 16 = 17 + 18 + 19 + 20 – Vestibular nuclei; 17 – Superior vestibular nucleus; 18 – Lateral vestibular nucleus; 19 – Inferior vestibular nucleus; 20 – Medial vestibular nucleus; 21 – Spinal nucleus of trigeminal nerve; 22 – Solitary nucleus; 23 – Sulcus limitans; 24 – Median sulcus; 25 – Hypoglossal nerve [XII]; 26 – Accessory nerve [XI]; 27 – Vagus nerve [X]; 28 – Glossopharyngeal nerve [IX]; 29 – Vestibulocochlear nerve [VIII]; 30 – Facial nerve [VII]; 31 – Abducent nerve; Abducens nerve [VI]; 32 – Pons; 33 – Trigeminal nerve [V]; 34 – Oculomotor nerve [III]; 35 – Cerebral peduncle, cerebral crus; 36 – Pineal gland; Pineal body; 37 – Red nucleus; 38 – Trochlear nerve [IV]; 39 – Mesencephalic tract of trigeminal nerve; 40 – Cochlear nuclei; 41 – Nucleus of accessory nerve; 42 – Accessory nerve [XI], spinal root; spinal

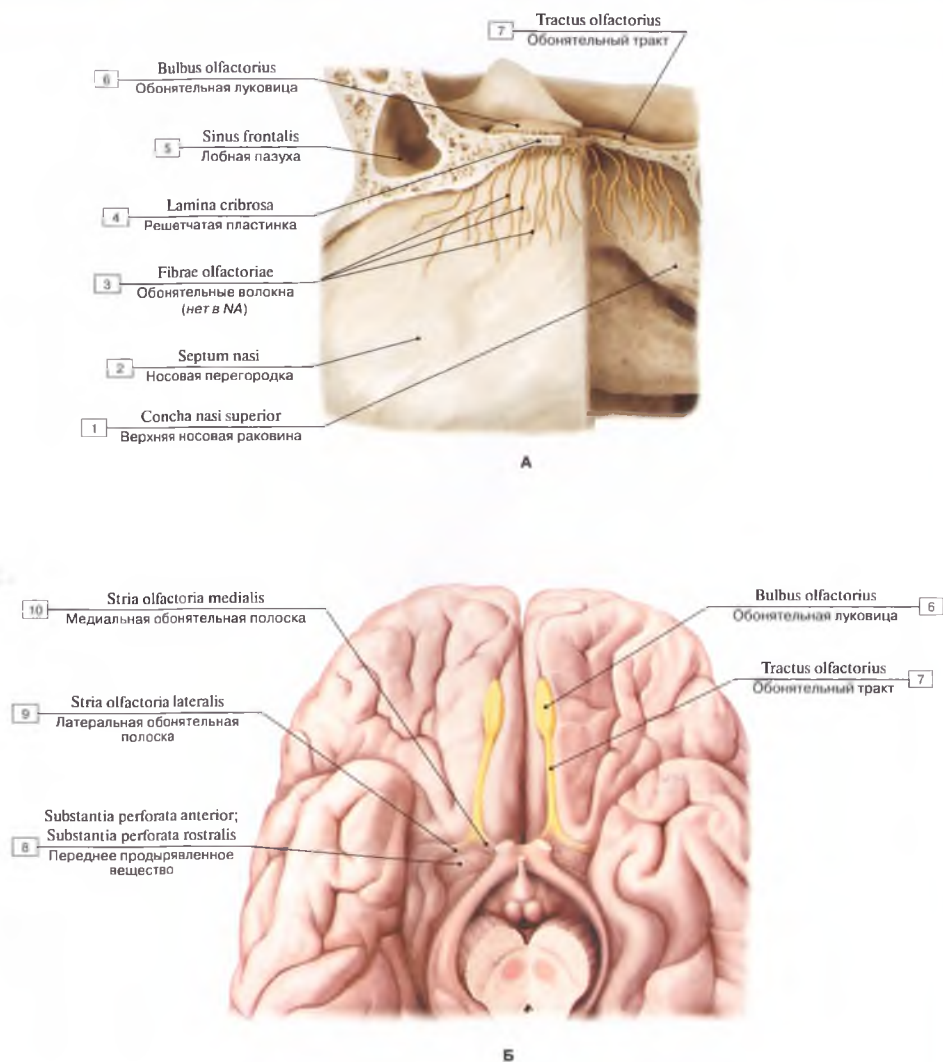


Рис. 170. Обонятельные нервы, сагиттальный разрез (А); обонятельный тракт, вид снизу (Б):

1 – Superior nasal concha; 2 – Nasal septum; 3 – Olfactory fibres; 4 – Cribriform plate; 5 – Frontal sinus; 6 – Olfactory bulb; 7 – Olfactory tract; 8 – Anterior perforated substance; 9 – Lateral olfactory stria; 10 – Medial olfactory stria

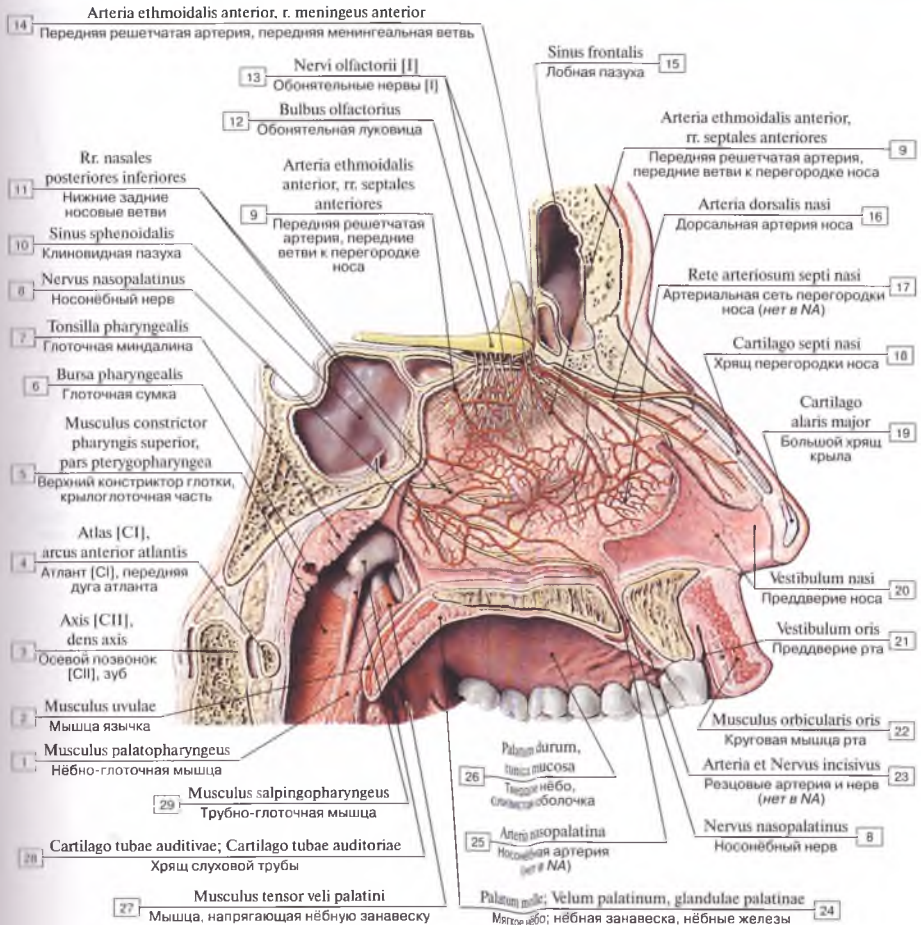


Рис. 171. Формирование обонятельных нервов:

1 — Palatopharyngeus; 2 — Musculus uvulae; 3 — Axis [CII], dens axis; 4 — Atlas [CI], anterior arch; 5 — Superior constrictor, pterygopharyngeal part; 6 — Pharyngeal bursa; 7 — Pharyngeal tonsil; 8 — Nasopalatine artery, anterior septal branches; 9 — Anterior ethmoidal artery, anterior meningeal branch; 10 — Sphenoidal sinus; 11 — Posterior inferior nasal branches; 12 — Olfactory bulb; 13 — Olfactory nerve [I]; 14 — Anterior ethmoidal artery, external meningeal branch; 15 — Frontal sinus; 16 — Dorsal nasal artery; External nasal cartilage; 17 — Arterial network of the nasal septum (arterial rete); 18 — Septal nasal cartilage; 19 — Major alar cartilage; 20 — Nasal vestibule; 21 — Oral vestibule; 22 — Orbicularis oris; 23 — Incisive artery and nerve; 24 — Soft palate, palatine glands; 25 — Nasopalatine artery; 26 — Hard palate, mucosa, mucous membrane; 27 — Tensor veli palatini; 28 — Cartilage of tube; 29 — Salpingopharyngeus

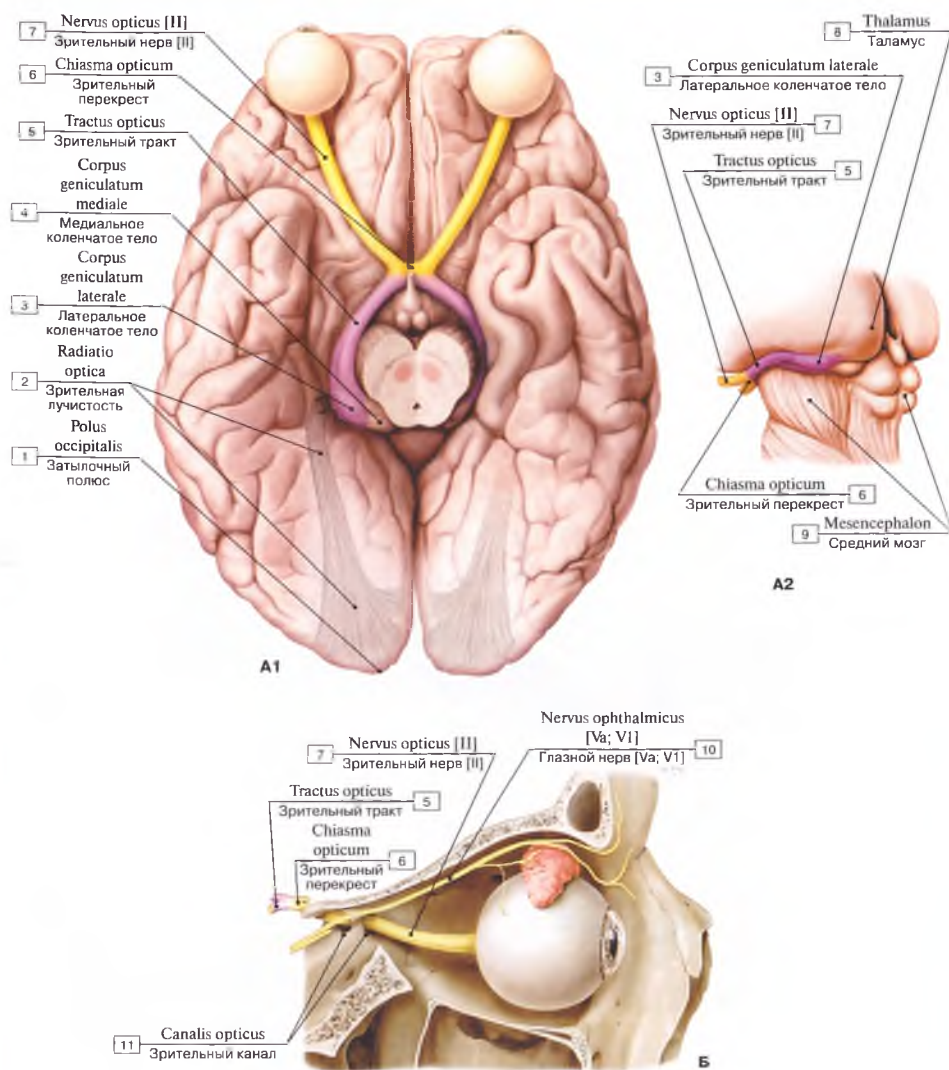
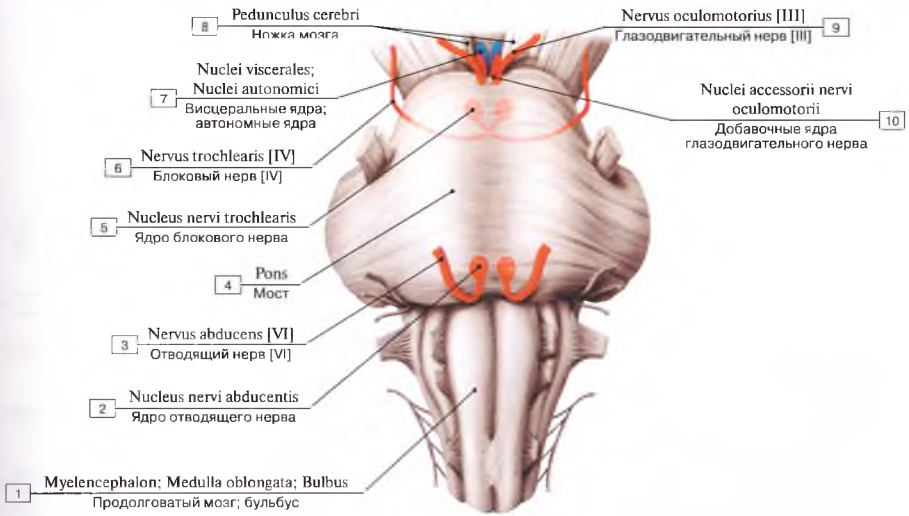
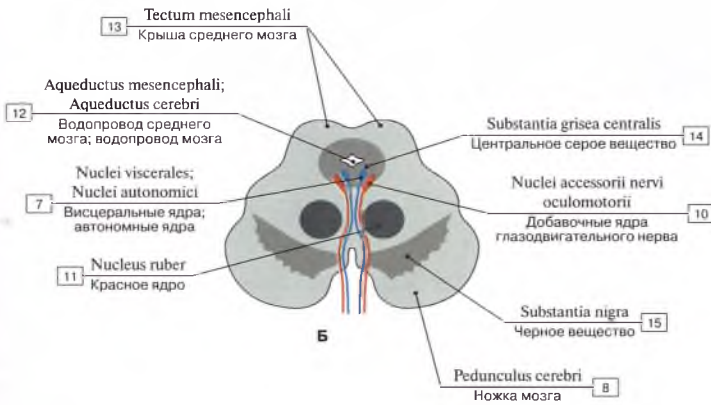


Рис. 172. Зрительный нерв (А – глаз, глазной нерв, оптический перекрест и зрительный тракт: А1 – вид со стороны основания черепа, А2 – заднелатеральный вид левой стороны ствола мозга; Б – прохождение зрительного нерва в правой глазнице);

1 – Occipital pole; 2 – Optic radiation; 3 – Lateral geniculate body; 4 – Medial geniculate body; 5 – Optic tract; 6 – Optic chiasm; Optic chiasma; 7 – Optic nerve [III]; 8 – Thalamus; Dorsal thalamus; 9 – Mesencephalon; Midbrain; 10 – Ophthalmic nerve; Ophthalmic division [Va; VI]; 11 – Optic canal



А



Б

Рис. 173. Глазодвигательный, блоковый и отводящий нервы  
(А – появление нервов из ствола мозга; Б – топография глазодвигательных ядер):

1 – Myelencephalon; Medulla oblongata; Bulb; 2 – Nucleus of abducens nerve; 3 – Abducent nerve; Abducens nerve [VI]; 4 – Pons; 5 – Nucleus of trochlear nerve; 6 – Trochlear nerve [IV]; 7 – Visceral nuclei; Autonomic nuclei; 8 – Cerebral peduncle; 9 – Oculomotor nerve [III]; 10 – Accessory nuclei of oculomotor nerve; 11 – Red nucleus; 12 – Aqueduct of midbrain; Cerebral aqueduct; 13 – Tectum of midbrain; 14 – Periaqueductal grey substance; Central grey substance; 15 – Substantia nigra

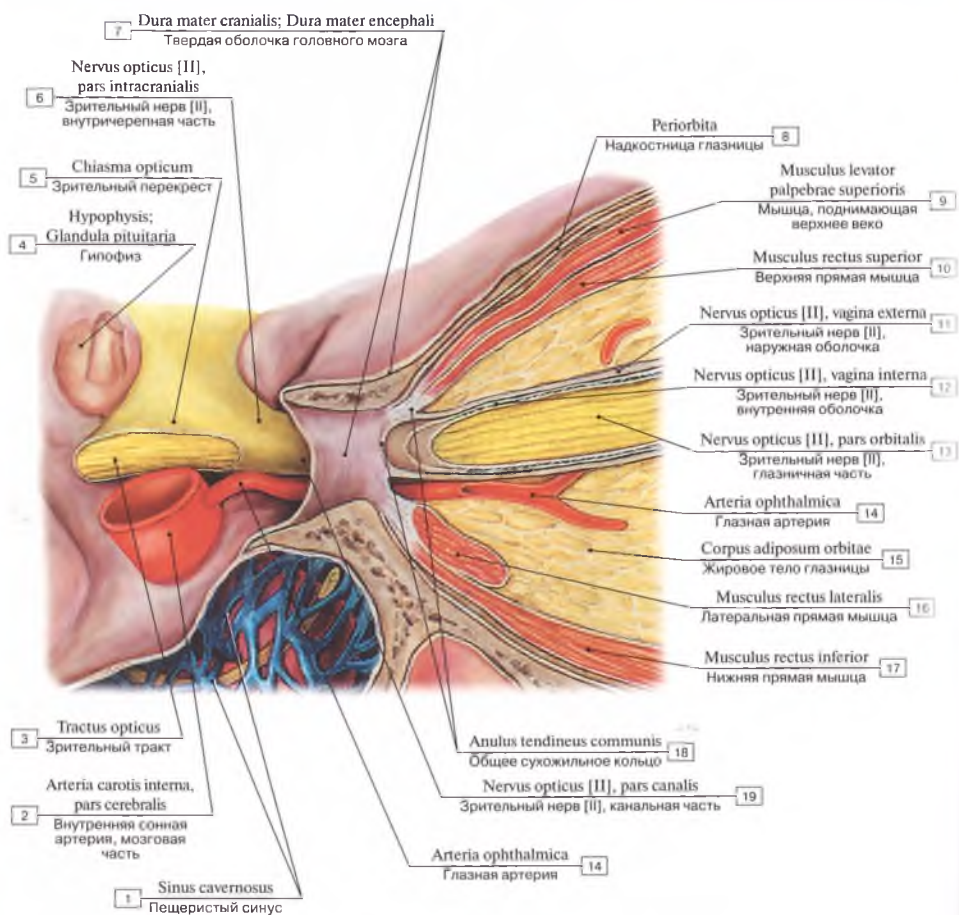


Рис. 174. Зрительный нерв:

1 – Cavernous sinus; 2 – Internal carotid artery, cerebral part; 3 – Optic tract; 4 – Pituitary gland; 5 – Optic chiasm; Optic chiasm  
 6 – Optic nerve [II], intracranial part; 7 – Cranial dura mater; 8 – Periorbita; 9 – Levator palpebrae superioris; 10 – Superior rectus  
 11 – Optic nerve [III], outer sheath; 12 – Optic nerve [III], inner sheath; 13 – Optic nerve [III], orbital part; 14 – Ophthalmic artery  
 15 – Retrobulbar fat; Orbital fat body; 16 – Lateral rectus; 17 – Inferior rectus; 18 – Common tendinous ring; Common annular tendon  
 19 – Optic nerve [III], part in canal

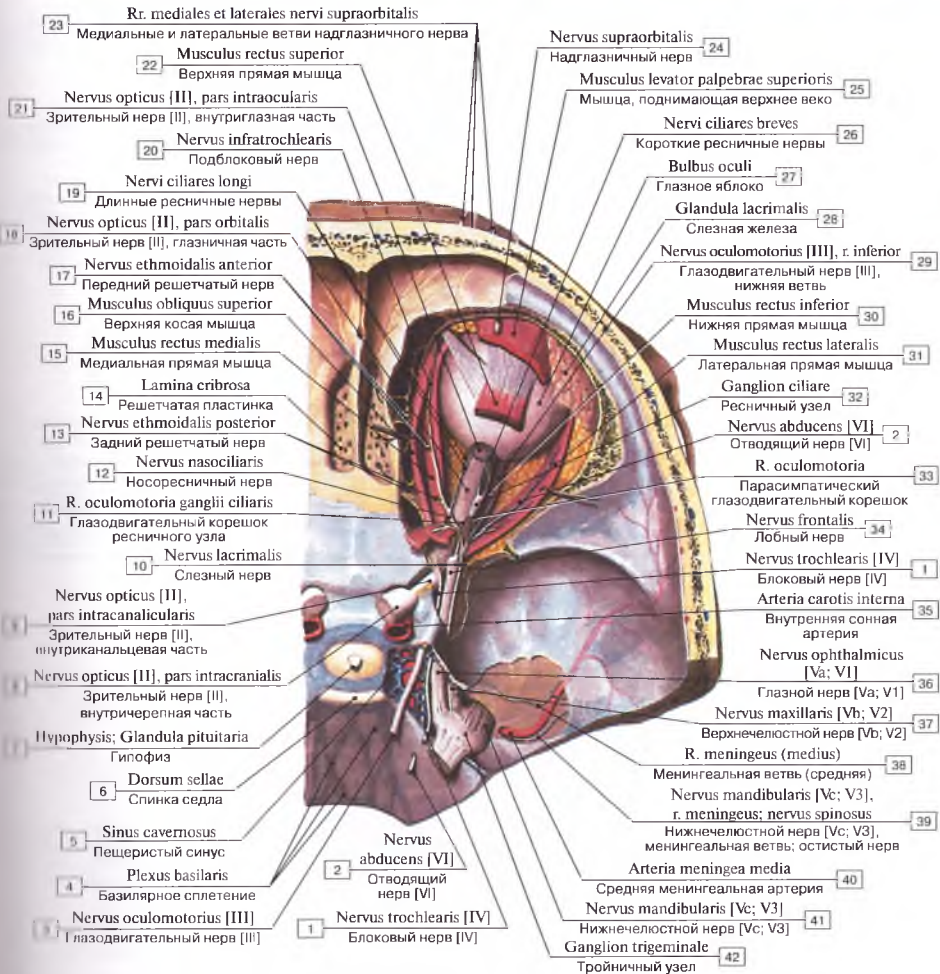
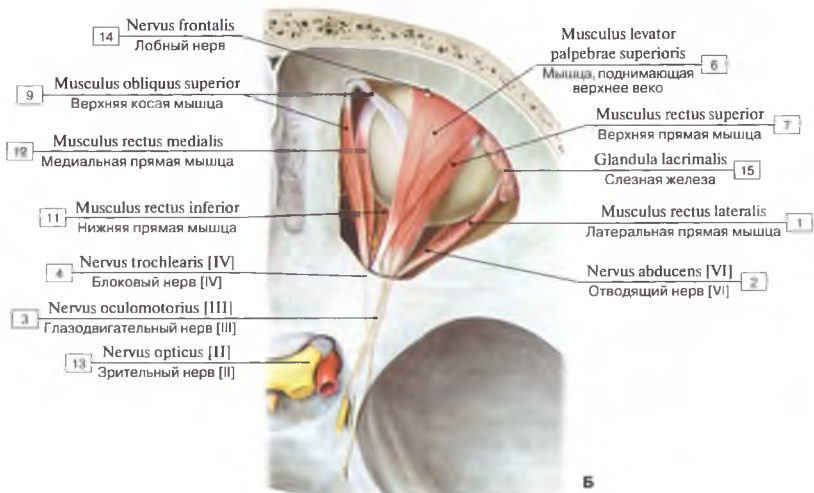
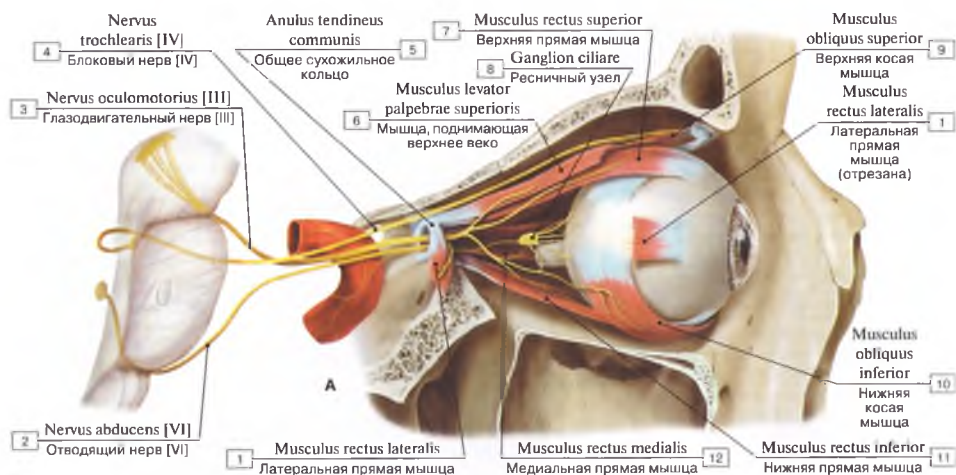


Рис. 175. Нервы глазницы, правой (вид сверху) (верхняя стенка глазницы и частично мышца, поднимающая верхнее веко, и верхняя прямая мышца удалены; пещеристый синус вскрыт, твердая оболочка головного мозга в области узла тройничного нерва удалена):

- 1 – Trochlear nerve [IV]; 2 – Abducent nerve; Abducent nerve [VI]; 3 – Oculomotor nerve [III]; 4 – Basilar plexus; 5 – Cavernous sinus; 6 – Dorsum sellae; 7 – Pituitary gland; 8 – Optic nerve [II], intracranial part; 9 – Optic nerve [II], intracanalicular part; 10 – Lacrimal nerve; 11 – Oculomotor root of ciliary ganglion; 12 – Nasociliary nerve; 13 – Posterior ethmoidal nerve; 14 – Cribriform plate; 15 – Medial rectus; 16 – Superior oblique; 17 – Anterior ethmoidal nerve; 18 – Optic nerve [II], orbital part; 19 – Long ciliary nerve; 20 – Infratrochlear nerve; 21 – Optic nerve [II], intra-ocular part; 22 – Superior rectus; 23 – Supra-orbital nerve, medial and lateral branches; 24 – Supra-orbital nerve; 25 – Levator palpebrae superioris; 26 – Short ciliary nerves; 27 – Eyeball; 28 – Lacrimal gland; 29 – Oculomotor nerve [III], inferior branch; 30 – Inferior rectus; 31 – Lateral rectus; 32 – Ciliary ganglion; 33 – Oculomotor root; 34 – Frontal nerve; 35 – Internal carotid artery; 36 – Ophthalmic nerve; Ophthalmic division [V<sub>a</sub>; V<sub>1</sub>]; 37 – Maxillary nerve; Maxillary division [V<sub>b</sub>; V<sub>2</sub>]; 38 – Middle meningeal artery; 39 – Mandibular nerve; Mandibular division [V<sub>c</sub>; V<sub>3</sub>], meningeal branch; nervus spinosus; 40 – Middle meningeal artery; 41 – Mandibular nerve; Mandibular division [V<sub>c</sub>; V<sub>3</sub>]; 42 – Trigeminal ganglion





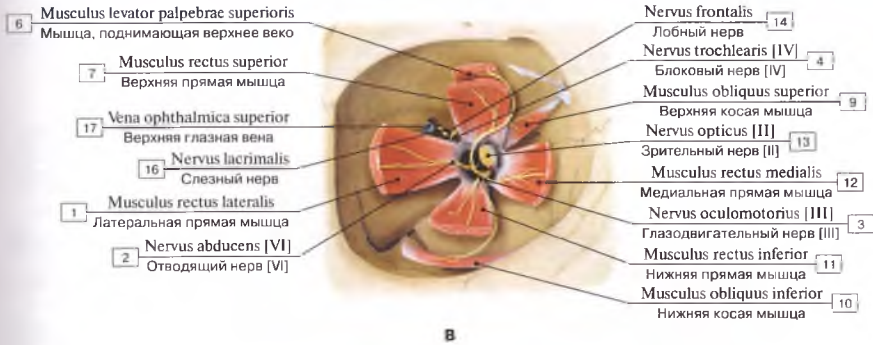


Рис. 176. Путь нервов, иннервирующих глазодвигательные мышцы, правая глазница (А – вид сбоку; Б – вид сверху; В – вид спереди):

1 – Lateral rectus; 2 – Abducent nerve; Abducens nerve [VI]; 3 – Oculomotor nerve [III]; 4 – Trochlear nerve [IV]; 5 – Common tendinous ring; Common anular tendon; 6 – Levator palpebrae superioris; 7 – Superior rectus; 8 – Ciliary ganglion; 9 – Superior oblique; 10 – Inferior oblique; 11 – Inferior rectus; 12 – Medial rectus; 13 – Optic nerve [II]; 14 – Frontal nerve; 15 – Lacrimal gland; 16 – Lacrimal nerve; 17 – Superior ophthalmic vein

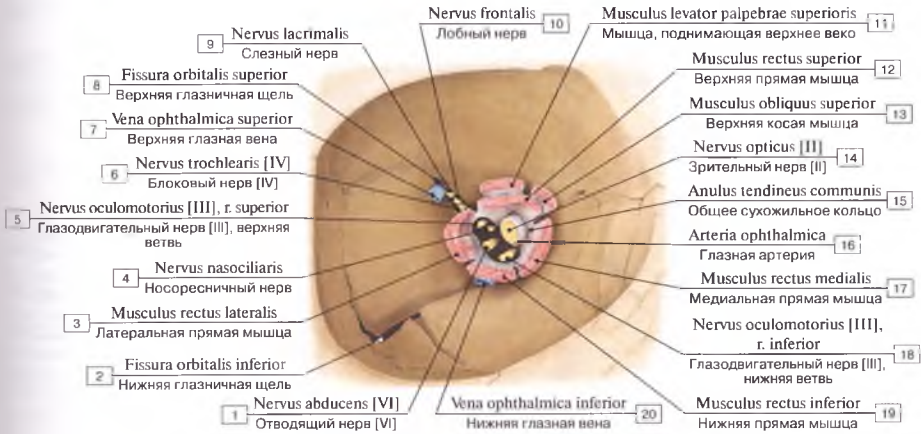
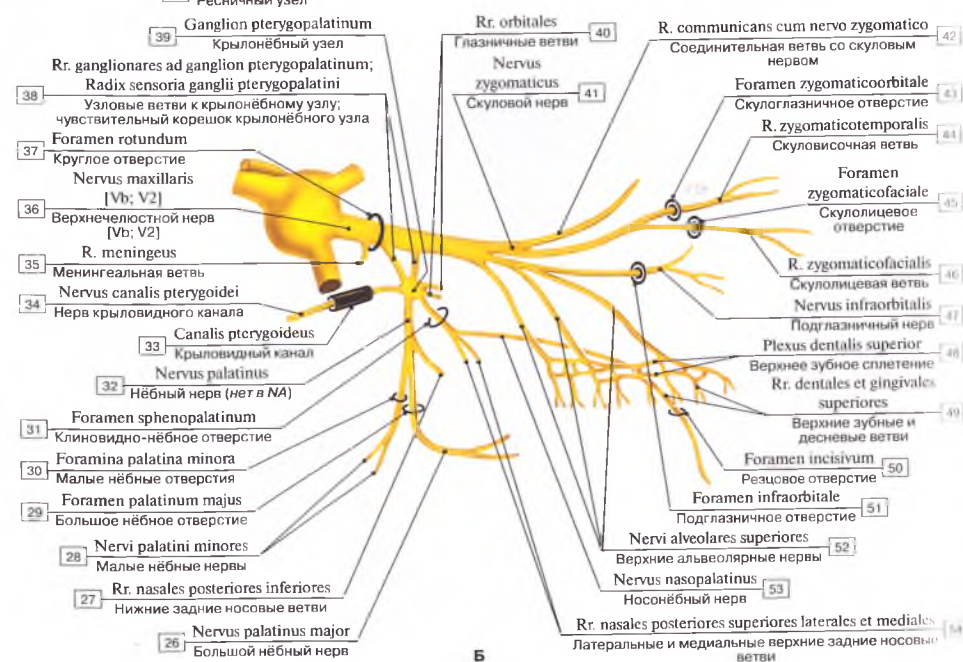
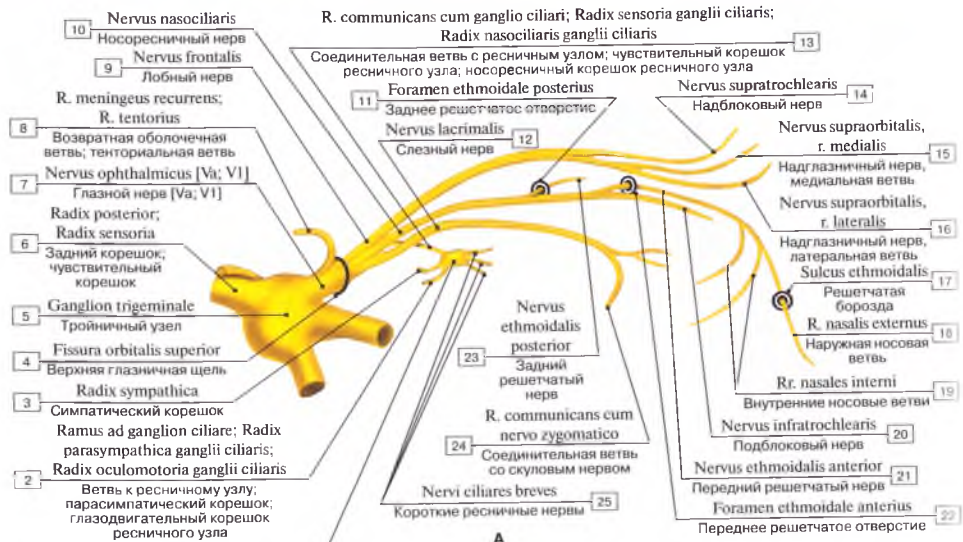


Рис. 177. Нервы глазницы, правой, вид спереди, сухожильное кольцо:

1 – Abducent nerve; Abducens nerve [VI]; 2 – Inferior orbital fissure; 3 – Lateral rectus; 4 – Nasociliary nerve; 5 – Oculomotor nerve [III], superior branch; 6 – Trochlear nerve [IV]; 7 – Superior ophthalmic vein; 8 – Superior orbital fissure; 9 – Lacrimal nerve; 10 – Frontal nerve; 11 – Levator palpebrae superioris; 12 – Superior rectus; 13 – Superior oblique; 14 – Optic nerve [II]; 15 – Common tendinous ring; Common anular tendon; 16 – Ophthalmic artery; 17 – Medial rectus; 18 – Oculomotor nerve [III], inferior branch; 19 – Inferior rectus; 20 – Inferior ophthalmic vein



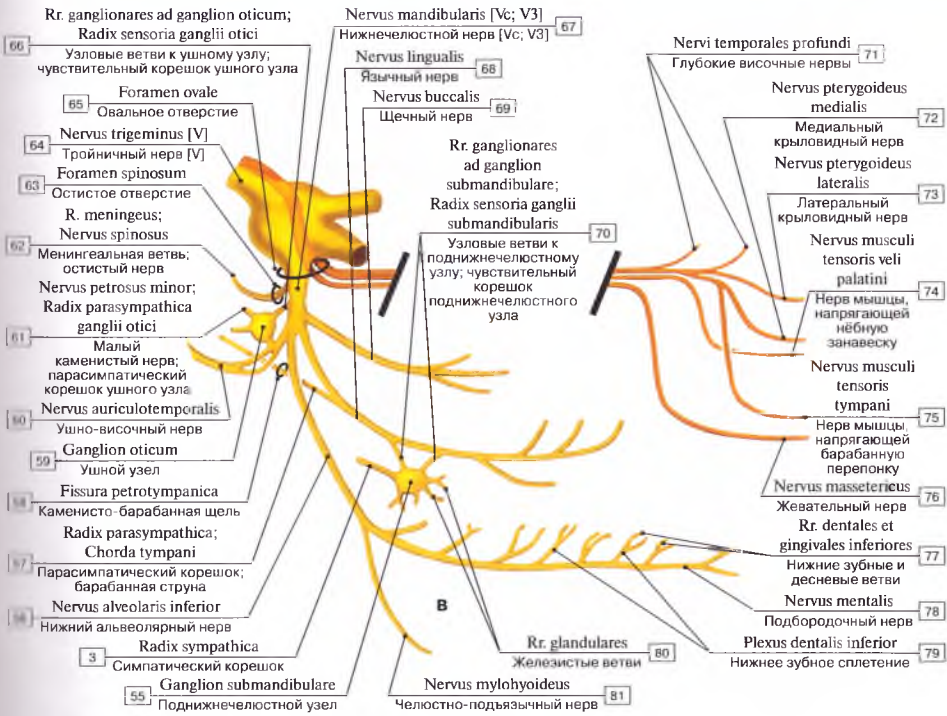


Рис. 178. Ветви тройничного нерва (А – глазной нерв; Б – верхнечелюстной нерв; В – нижнечелюстной нерва) (схема):

- 1 – Ciliary ganglion; 2 – Parasympathetic roof; Oculomotor root; Branch of oculomotor nerve to ciliary ganglion; 3 – Sympathetic root;
- 4 – Superior orbital fissure; 5 – Trigeminal ganglion; 6 – Posterior root; Sensory root; Dorsal root; 7 – Ophthalmic nerve; Ophthalmic division [Va; V1]; 8 – Tentorial nerve; 9 – Frontal nerve; 10 – Nasociliary nerve; 11 – Posterior ethmoidal foramen; 12 – Lacrimal nerve; 13 – Communicating branch with ciliary ganglion; Sensory root of ciliary ganglion; Nasociliary root of ciliary ganglion; 14 – Supratrochlear nerve; 15 – Supra-orbital nerve, medial branch; 16 – Supra-orbital nerve, lateral branch; 17 – Ethmoidal groove; 18 – External nasal nerve; 19 – Internal nasal branches; 20 – Infratrochlear nerve; 21 – Anterior ethmoidal nerve; 22 – Anterior ethmoidal foramen; 23 – Posterior ethmoidal nerve; 24 – Communicating branch with zygomatic nerve; 25 – Short ciliary nerves; 26 – Greater palatine nerve; 27 – Posterior orbital nasal nerves; 28 – Lesser palatine nerves; 29 – Greater palatine foramen; 30 – Lesser palatine foramina; 31 – Sphenopalatine foramen; 32 – Palatine nerve; 33 – Pterygoid canal; 34 – Nerve of pterygoid canal; 35 – Meningeal branch; 36 – Maxillary nerve; Maxillary division [Vb; V2]; 37 – Foramen rotundum; 38 – Ganglionic branches to pterygopalatine ganglion; Sensory root of pterygopalatine ganglion; 39 – Pterygopalatine ganglion; 40 – Orbital branches; 41 – Zygomatic nerve; 42 – Communicating branch with zygomatic nerve; 43 – Zygomatico-orbital foramen; 44 – Zygomaticotemporal branch; 45 – Zygomaticofacial foramen; 46 – Zygomaticofacial branch; 47 – Infra-orbital nerve; 48 – Superior dental plexus; 49 – Superior dental and gingival branches; 50 – Incisive foramen; 51 – Infra-orbital foramen; 52 – Superior alveolar nerves; 53 – Nasopalatine nerve; 54 – Posterior superior lateral and medial nasal branches; 55 – Submandibular ganglion; 56 – Inferior alveolar nerve; 57 – Parasympathetic root; Chorda tympani; 58 – Petrotympanic fissure; 59 – Otic ganglion; 60 – Auriculotemporal nerve; 61 – Lesser petrosal nerve; Parasympathetic root of otic ganglion; 62 – Meningeal branch; Nervus spinosus; 63 – Foramen spinosum; 64 – Trigeminal nerve [V]; 65 – Foramen ovale; 66 – Branches to otic ganglion; Sensory root of otic ganglion; 67 – Mandibular nerve; Mandibular division [Vc; V3]; 68 – Lingual nerve; 69 – Buccal nerve; 70 – Ganglionic branches to submandibular ganglion; Sensory root of submandibular ganglion; 71 – Deep temporal nerves; 72 – Nerve to medial pterygoid; 73 – Nerve to lateral pterygoid; 74 – Nerve to tensor veli palatini; 75 – Nerve to tensor tympani; 76 – Masseteric nerve; 77 – Inferior dental and gingival branches; 78 – Mental nerve; 79 – Inferior dental plexus; 80 – Glandular branches; 81 – Nerve to mylohyoid

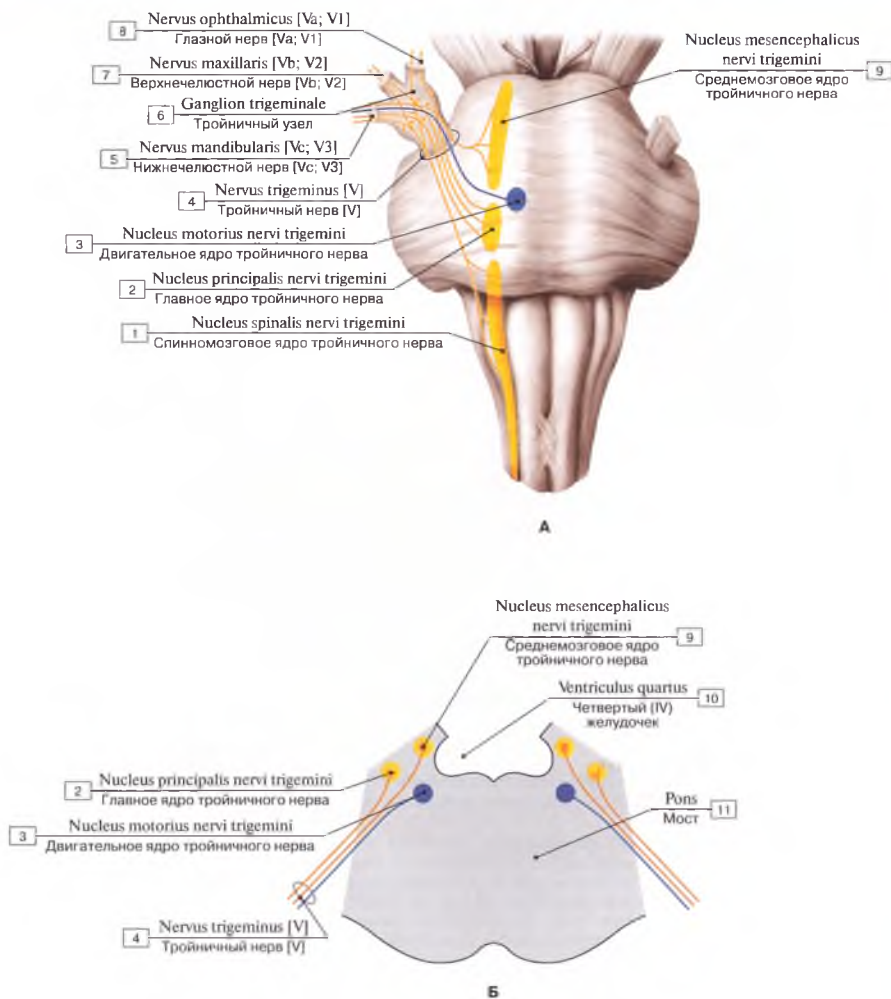


Рис. 179. Ядра моста и отходящие от него нервы  
(А – вид сверху; Б – ядра тройничного нерва, поперечное сечение через мост):

1 – Spinal nucleus of trigeminal nerve; 2 – Principal sensory nucleus of trigeminal nerve; 3 – Motor nucleus of trigeminal nerve; 4 – Trigeminal nerve [V]; 5 – Mandibular nerve; Mandibular division [Vc; V3]; 6 – Trigeminal ganglion; 7 – Maxillary nerve; Maxillary division [Vb; V2]; 8 – Ophthalmic nerve; Ophthalmic division [Va; V1]; 9 – Mesencephalic nucleus of trigeminal nerve; 10 – Fourth ventricle; 11 – Pons

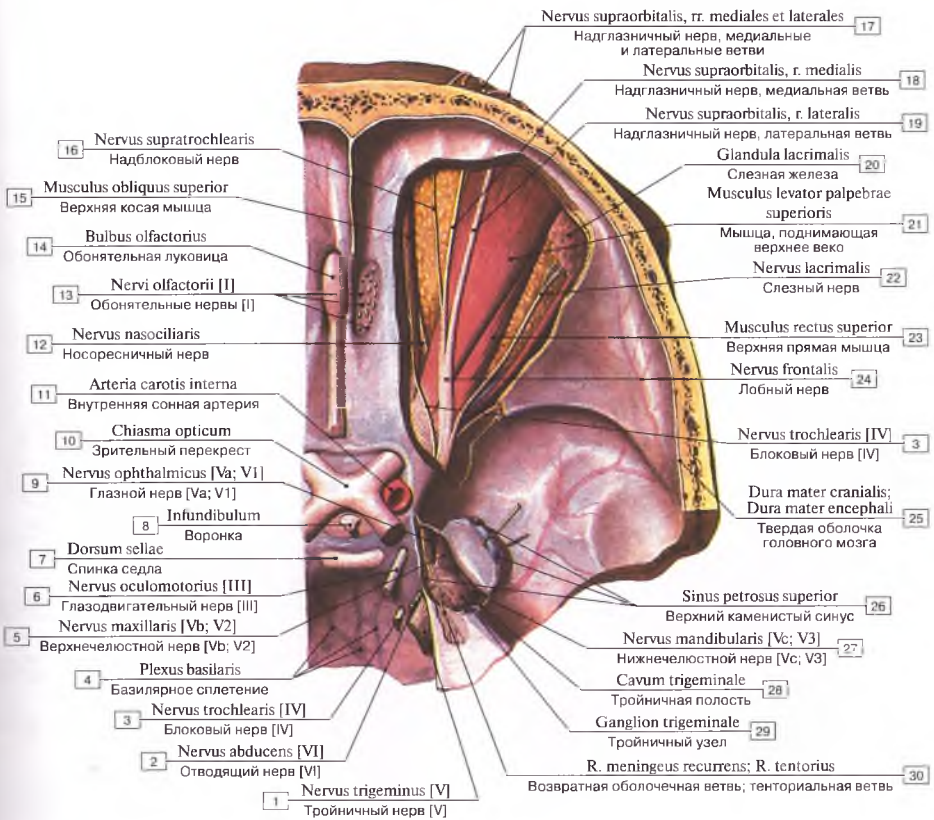


Рис. 180. Нервы первой ветви тройничного нерва (вид сверху):

1 – Trigeminal nerve [V]; 2 – Abducent nerve; Abducens nerve [VI]; 3 – Trochlear nerve [IV]; 4 – Basilar plexus; 5 – Maxillary nerve; Maxillary division [Vb; V2]; 6 – Oculomotor nerve [III]; 7 – Dorsum sellae; 8 – Infundibulum; 9 – Ophthalmic nerve; Ophthalmic division [Va; V1]; 10 – Optic chiasm; Optic chiasma; 11 – Internal carotid artery; 12 – Nasociliary nerve; 13 – Olfactory nerves [I]; 14 – Olfactory bulb; 15 – Superior oblique; 16 – Supratrochlear nerve; 17 – Supra-orbital nerve, medial and lateral branches; 18 – Supra-orbital nerve, medial branch; 19 – Supra-orbital nerve, lateral branch; 20 – Lacrimal gland; 21 – Levator palpebrae superioris; 22 – Lacrimal nerve; 23 – Superior rectus; 24 – Frontal nerve; 25 – Cranial dura mater; 26 – Superior petrosal sinus; 27 – Mandibular nerve; Mandibular division [Vc; V3]; 28 – Trigeminal cave; Trigeminal cavity; 29 – Trigeminal ganglion; 30 – Tentorial nerve

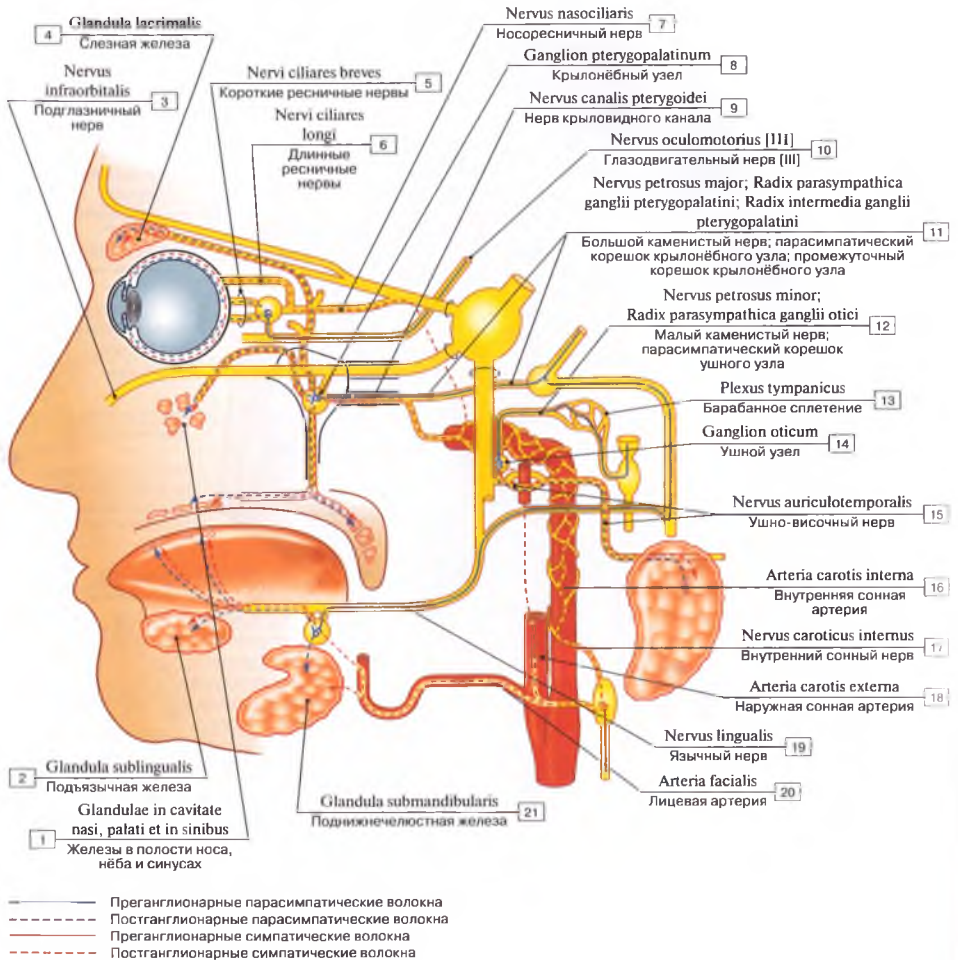
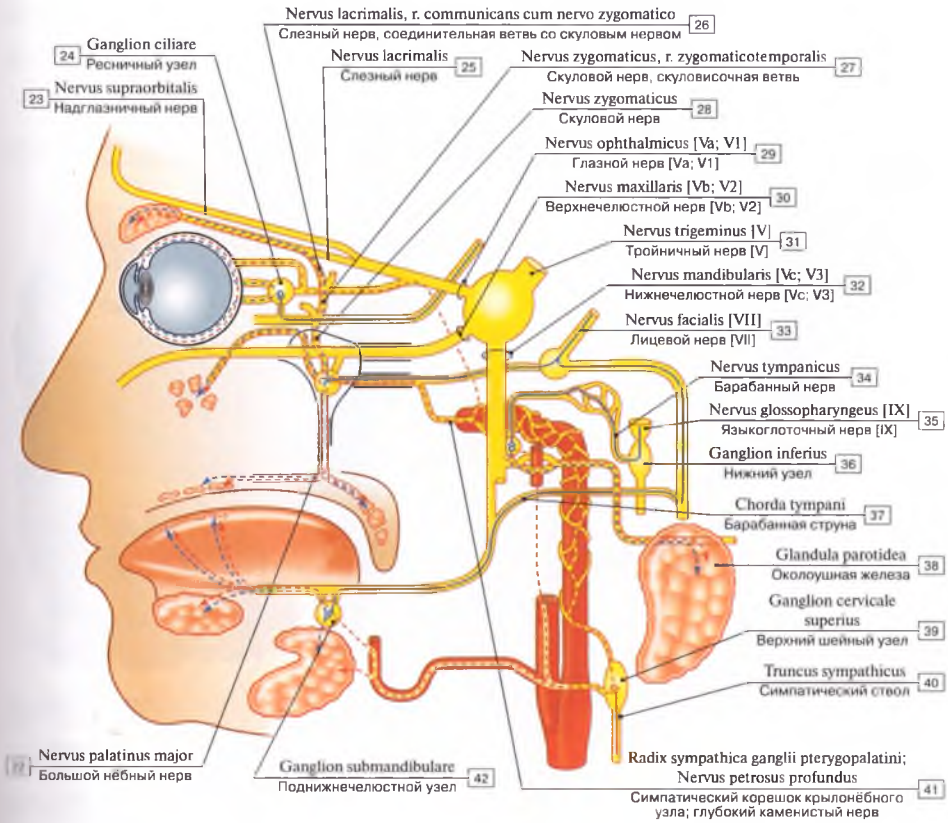


Рис. 181. Эфферентная иннервация черепными нервами (III, VII, IX) слезной и слюнных желез (схема):

1 – Glands in nasal cavity, palate and sinuses; 2 – Sublingual gland; 3 – Infra-orbital nerve; 4 – Lacrimal gland; 5 – Short ciliary nerves; 6 – Long ciliary nerves; 7 – Nasociliary nerve; 8 – Pterygopalatine ganglion; 9 – Nerve of pterygoid canal; 10 – Oculomotor nerve [III]; 11 – Greater petrosal nerve; Parasympathetic root of pterygopalatine ganglion; 12 – Lesser petrosal nerve; Parasympathetic root of otic ganglion; 13 – Tympanic plexus; 14 – Otic ganglion; 15 – Auriculotemporal nerve; 16 – Internal carotid artery; 17 – Internal carotid nerve; 18 – External carotid artery; 19 – Lingual nerve; 20 – Facial artery; 21 – Submandibular gland; 22 – Greater palatine nerve



23 – Supra-orbital nerve; 24 – Ciliary ganglion; 25 – Lacrimal nerve; 26 – Lacrimal nerve, communicating branch with zygomatic nerve; 27 – Zygomatic nerve, zygomaticotemporal branch; 28 – Zygomatic nerve; 29 – Ophthalmic nerve; Ophthalmic division [Va; V1]; 30 – Maxillary nerve; Maxillary division [Vb; V2]; 31 – Trigeminal nerve [V]; 32 – Mandibular nerve; Mandibular division [Vc; V3]; 33 – Facial nerve [VII]; 34 – Tympanic nerve; 35 – Glossopharyngeal nerve [IX]; 36 – Inferior ganglion; 37 – Chorda tympani; 38 – Parotid gland; 39 – Superior cervical ganglion; 40 – Sympathetic trunk; 41 – Sympathetic root of pterygopalatine ganglion; Deep petrosal nerve; 42 – Submandibular ganglion

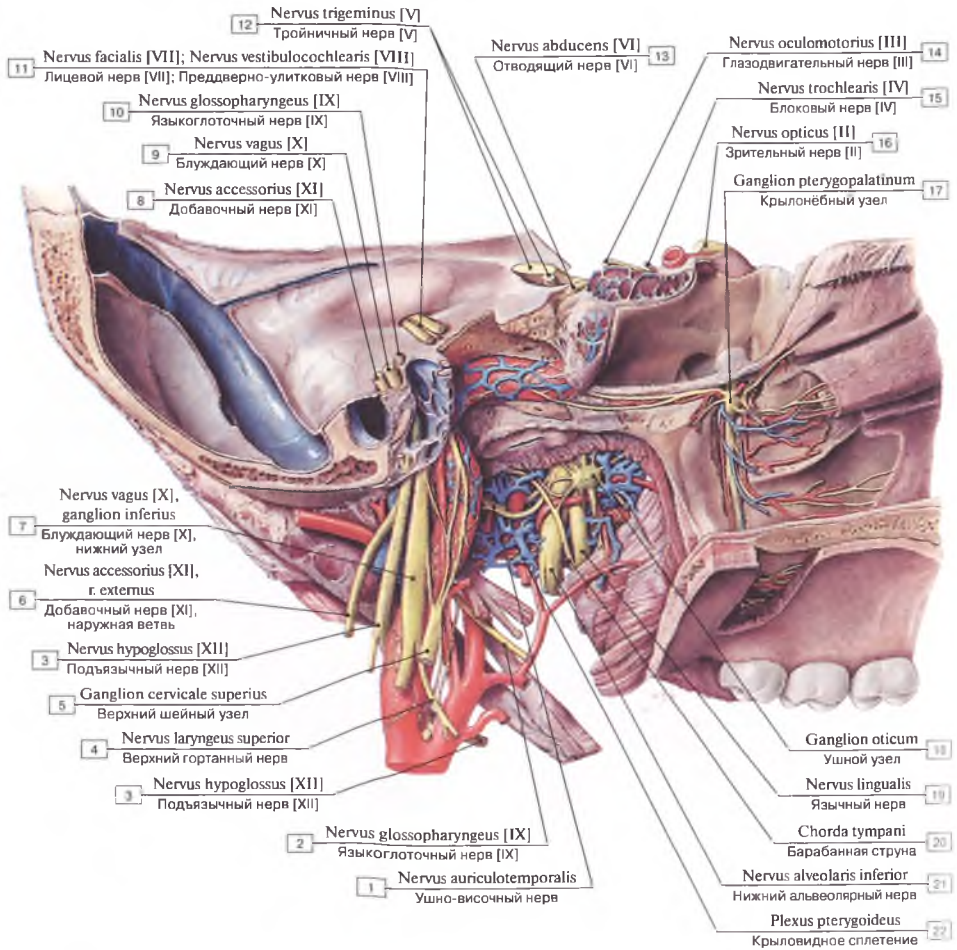


Рис. 182. Крылобланный узел:

1 – Auriculotemporal nerve; 2 – Glossopharyngeal nerve [IX]; 3 – Hypoglossal nerve [XII]; 4 – Superior laryngeal nerve; 5 – Superior cervical ganglion; 6 – Accessory nerve [XI], external branch; 7 – Vagus nerve [X], inferior ganglion; 8 – Accessory nerve [XI]; 9 – Vagus nerve [X]; 10 – Glossopharyngeal nerve [IX]; 11 – Facial nerve [VII]; Vestibulocochlear nerve [VIII]; 12 – Trigeminal nerve [V]; 13 – Abducent nerve; Abducent nerve [VI]; 14 – Oculomotor nerve [III]; 15 – Trochlear nerve [IV]; 16 – Optic nerve [II]; 17 – Pterygopalatine ganglion; 18 – Otic ganglion; 19 – Lingual nerve; 20 – Chorda tympani; 21 – Inferior alveolar nerve; 22 – Pterygoid plexus



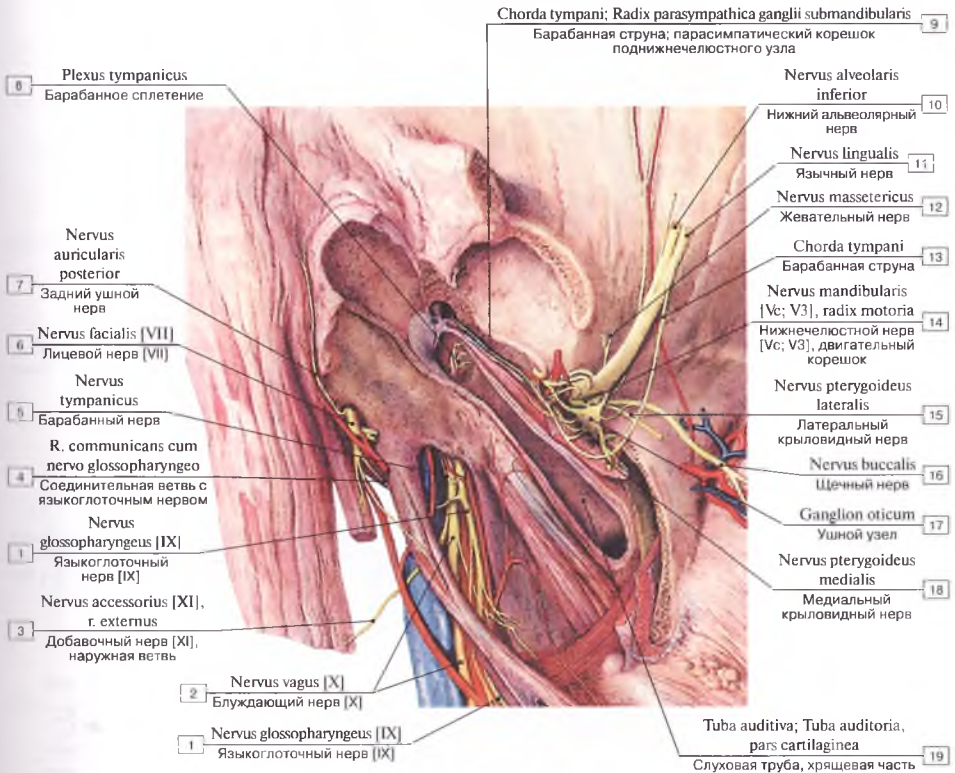


Рис. 183. Ушной узел:

1 – Glossopharyngeal nerve [IX]; 2 – Vagus nerve [X]; 3 – Accessory nerve [XI], external branch; 4 – Communicating branch with glossopharyngeal nerve; 5 – Tympanic nerve; 6 – Facial nerve [VII]; 7 – Posterior auricular nerve; 8 – Tympanic plexus; 9 – Chorda tympani; Parasympathetic root of submandibular ganglion; 10 – Inferior alveolar nerve; 11 – Lingual nerve; 12 – Masseteric nerve; 13 – Chorda tympani; 14 – Mandibular nerve; Mandibular division [Vc; V3], motor root; 15 – Nerve to lateral pterygoid; 16 – Buccal nerve; 17 – Otic ganglion; 18 – Nerve to medial pterygoid; 19 – Pharyngotympanic tube; Auditory tube, cartilaginous part

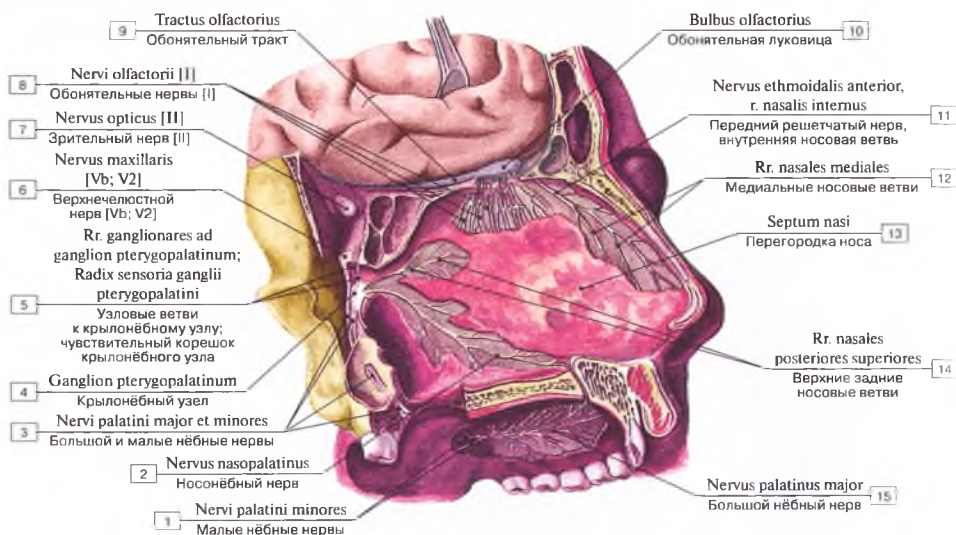


Рис. 184. Нервы перегородки носа и твердого нёба; правая поверхность перегородки носа; левая половина твердого нёба:

1 – Lesser palatine nerves; 2 – Nasopalatine nerve; 3 – Lesser and superior palatine nerves; 4 – Pterygopalatine ganglion; 5 – Cnanglionic branches to pterygopalatine ganglion; Sensory root of pterygopalatine ganglion; 6 – Maxillary nerve; Maxillary division [Vb; V2]; 7 – Optic nerve [II]; 8 – Olfactory nerves [I]; 9 – Olfactory tract; 10 – Olfactory bulb; 11 – Anterior ethmoidal nerve, internal nasal branch; 12 – Medial nasal branches; 13 – Nasal septum; 14 – Posterior superior nasal branches; 15 – Greater palatine nerve

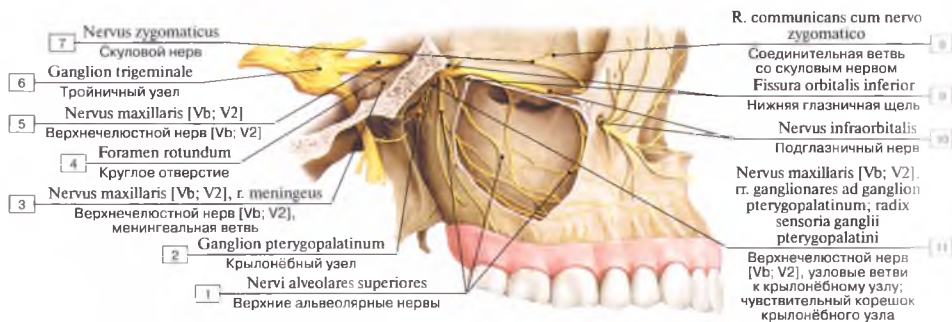


Рис. 185. Ветви верхнечелюстного нерва, вид сбоку, частично вскрыт верхнечелюстной синус, скуловая дуга удалена:

1 – Superior alveolar nerves; 2 – Pterygopalatine ganglion; 3 – Maxillary nerve; Maxillary division [Vb; V2], meningeal branch; 4 – Foramen rotundum; 5 – Maxillary nerve; Maxillary division [Vb; V2]; 6 – Trigeminal ganglion; 7 – Zygomatic nerve; 8 – Communicating branch with zygomatic nerve; 9 – Inferior orbital fissure; 10 – Infra-orbital nerve; 11 – Maxillary nerve; Maxillary division [Vb; V2], canglionic branches to pterygopalatine ganglion; sensory root of pterygopalatine ganglion

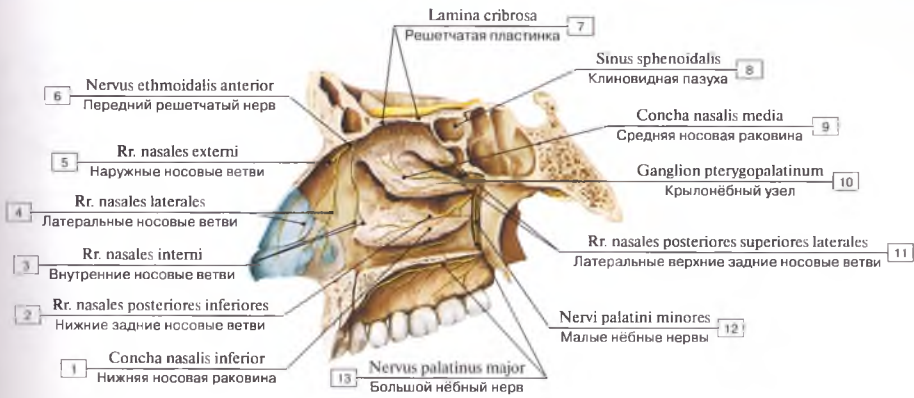


Рис. 186. Нервы латеральной стенки носовой полости, вид изнутри:

1 – Inferior nasal concha; 2 – Posterior inferior nasal branches; 3 – Internal nasal branches; 4 – Lateral nasal branches; 5 – External nasal branches; 6 – Anterior ethmoidal nerve; 7 – Cribriform plate; 8 – Sphenoidal sinus; 9 – Middle nasal concha; 10 – Pterygopalatine ganglion; 11 – Posterior superior lateral nasal branches; 12 – Lesser palatine nerves; 13 – Greater palatine nerve

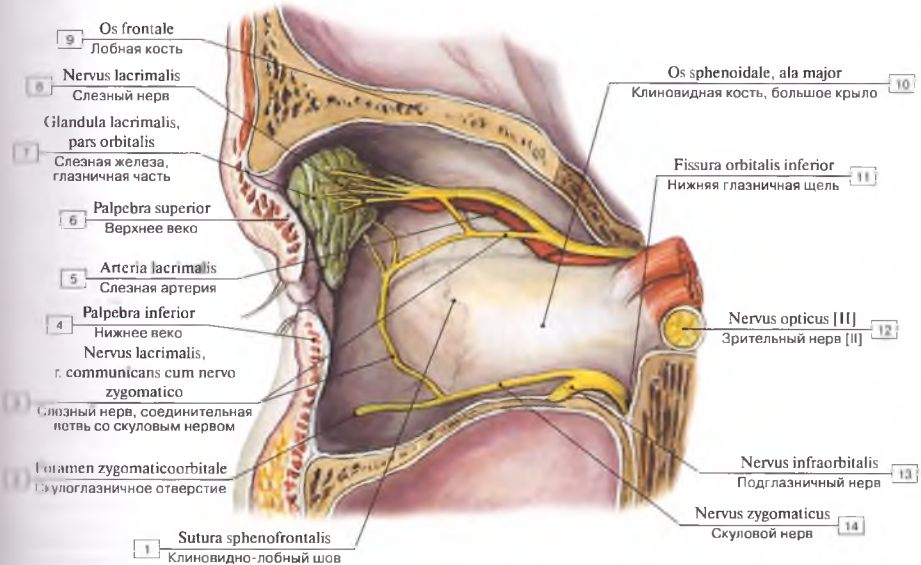


Рис. 187. Иннервация слезной железы, глазница, вид изнутри:

1 – Sphenofrontal suture; 2 – Zygomatico-orbital foramen; 3 – Lacrimal nerve, communicating branch with zygomatic nerve; 4 – Inferior eyelid; 5 – Lacrimal artery; 6 – Superior eyelid; 7 – Lacrimal gland, orbital part; 8 – Lacrimal nerve; 9 – Frontal bone; 10 – Sphenoid; Sphenoidal bone, greater wing; 11 – Inferior orbital fissure; 12 – Optic nerve [III]; 13 – Infra-orbital nerve; 14 – Zygomatic nerve

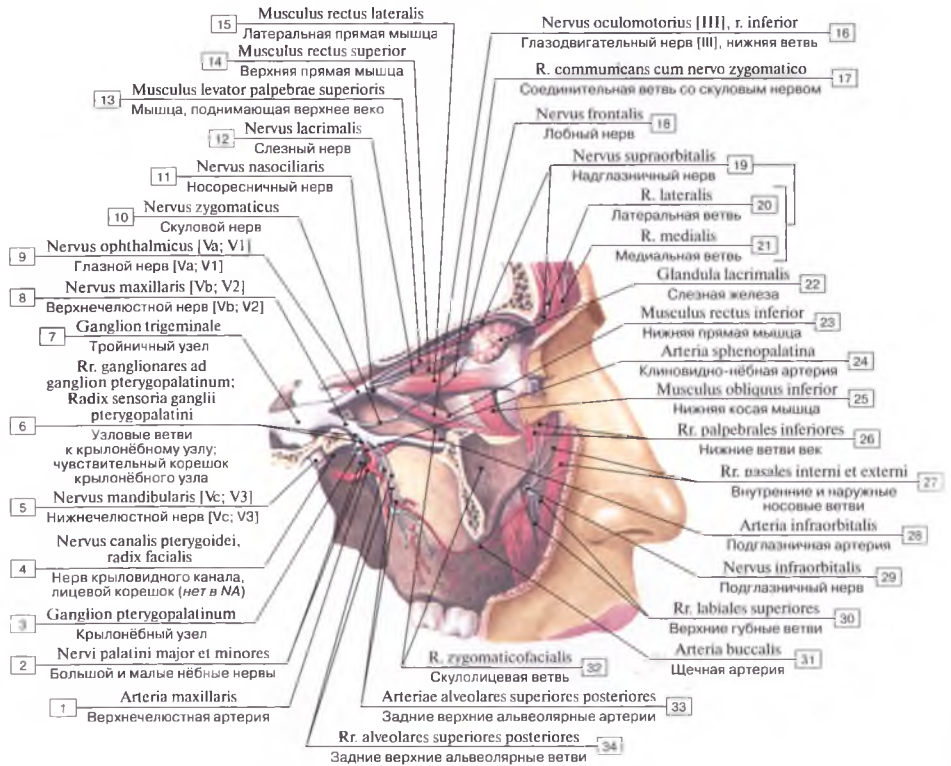


Рис. 188. Тройничный нерв (вид сбоку, боковая стенка глазницы удалена):

1 – Maxillary artery; 2 – Greater and lesser palatine nerves; 3 – Pterygopalatine ganglion; 4 – Nerve of pterygoid canal; 5 – Mandibular nerve; Mandibular division [Vc; V3]; 6 – Ganglionic branches to pterygopalatine ganglion; Sensory root of pterygopalatine ganglion; 7 – Trigeminal ganglion; 8 – Maxillary nerve; Maxillary division [Vb; V2]; 9 – Ophthalmic nerve; Ophthalmic division [Va; V1]; 10 – Zygomatic nerve; 11 – Nasociliary nerve; 12 – Lacrimal nerve; 13 – Levator palpebrae superioris; 14 – Superior rectus; 15 – Lateral rectus; 16 – Oculomotor nerve [III], inferior branch; 17 – Communicating branch with zygomatic nerve; 18 – Frontal nerve; 19 – Supra-orbital nerve; 20 – Lateral branch; 21 – Medial branch; 22 – Lacrimal gland; 23 – Inferior rectus; 24 – Sphenopalatine artery; 25 – Inferior oblique; 26 – Inferior palpebral branches; 27 – Internal and external nasal branches; 28 – Infra-orbital artery; 29 – Infra-orbital nerve; 30 – Superior labial branches; 31 – Buccal artery; 32 – Zygomaticofacial branch; 33 – Posterior superior alveolar arteries; 34 – Posterior superior alveolar branches

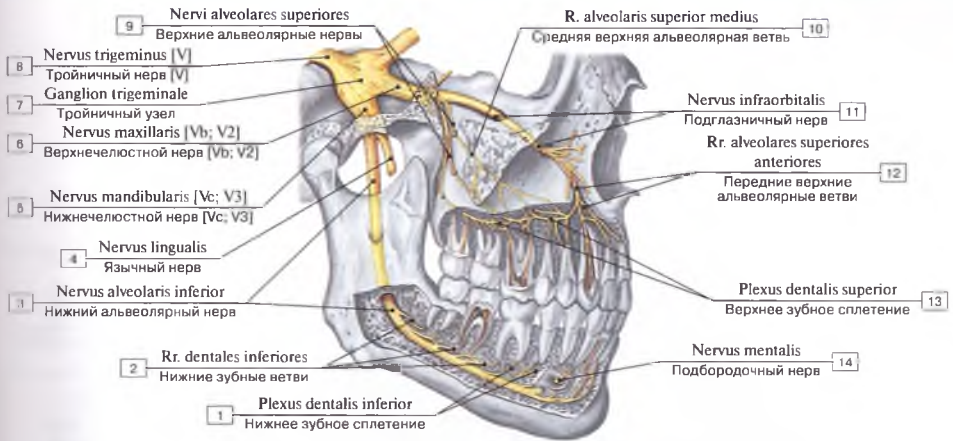


Рис. 189. Верхнечелюстной и нижнечелюстной нервы и их альвеолярные ветви, вид справа (наружная стенка верхнечелюстной кости и нижней челюсти удалены):

- 1 — Inferior dental plexus; 2 — Inferior dental branches; 3 — Inferior alveolar nerve; 4 — Lingual nerve; 5 — Mandibular nerve; Mandibular division [Vc; V3]; 6 — Maxillary nerve; Maxillary division [Vb; V2]; 7 — Trigeminal ganglion; 8 — Trigeminal nerve [V]; 9 — Superior alveolar nerves; 10 — Middle superior alveolar branch; 11 — Infra-orbital nerve; 12 — Anterior superior alveolar branches; 13 — Superior dental plexus; 14 — Mental nerve

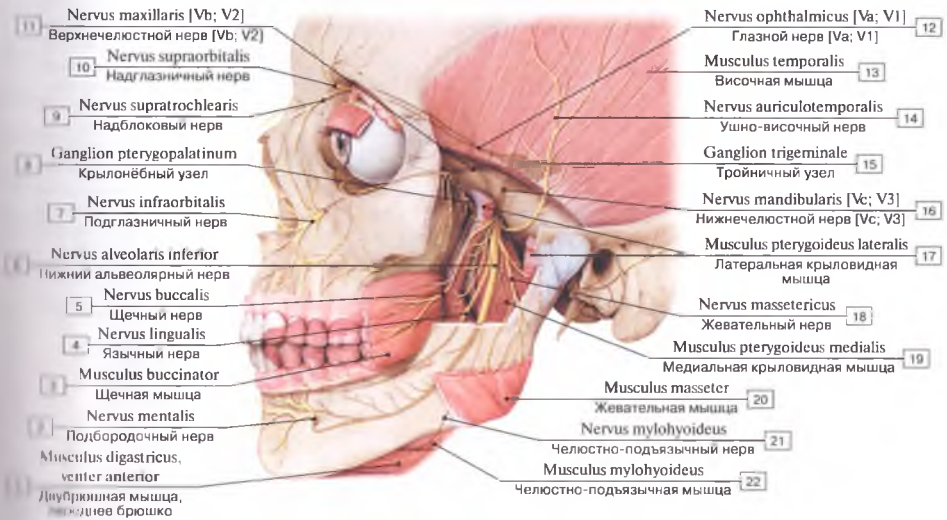


Рис. 190. Тройничный нерв, вид слева:

- 1 — Diaphragm, anterior belly; 2 — Mental nerve; 3 — Buccinator; 4 — Lingual nerve; 5 — Buccal nerve; 6 — Inferior alveolar nerve; 7 — Infra-orbital nerve; 8 — Pterygopalatine ganglion; 9 — Supratrochlear nerve; 10 — Supra-orbital nerve; 11 — Maxillary nerve; Maxillary division [Vb; V2]; 12 — Ophthalmic nerve; Ophthalmic division [Va; V1]; 13 — Temporalis; 14 — Auriculotemporal nerve; 15 — Trigeminal ganglion; 16 — Mandibular nerve; Mandibular division [Vc; V3]; 17 — Lateral pterygoid; 18 — Masseteric nerve; 19 — Medial pterygoid; 20 — Masseter; 21 — Nerve to mylohyoid; 22 — Mylohyoid

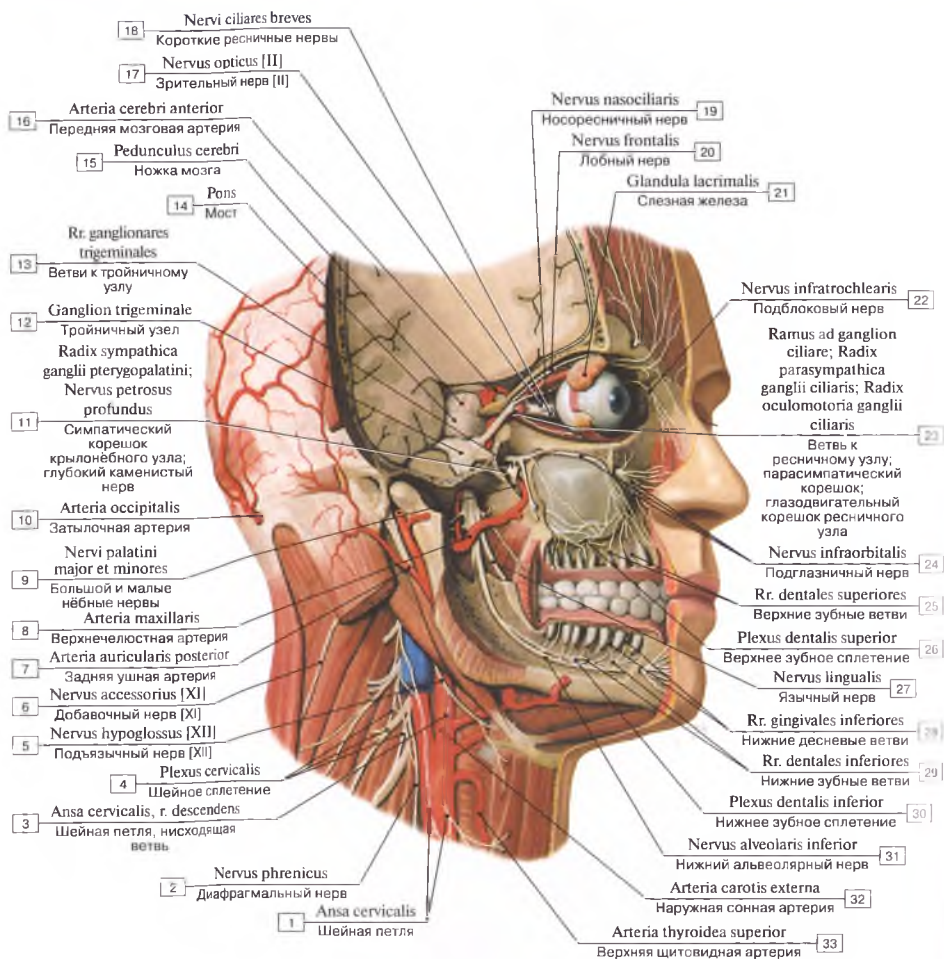


Рис. 191. Ветви тройничного нерва (схема):

1 – Ansa cervicalis; 2 – Phrenic nerve; 3 – Ansa cervicalis, descending branch; 4 – Cervical plexus; 5 – Hypoglossal nerve [XII]; 6 – Accessory nerve [XI]; 7 – Posterior auricular artery; 8 – Maxillary artery; 9 – Greater and lesser palatine nerves; 10 – Occipital artery; 11 – Sympathetic root of pterygopalatine ganglion; Deep petrosal nerve; 12 – Trigeminal ganglion; 13 – Branches to trigeminal ganglion; 14 – Pons; 15 – Cerebral peduncle; 16 – Anterior cerebral artery; 17 – Optic nerve [II]; 18 – Short ciliary nerves; 19 – Nasociliary nerve; 20 – Frontal nerve; 21 – Lacrimal gland; 22 – Infratrochlear nerve; 23 – Parasympathetic root; Oculomotor root; Branch of oculomotor nerve to ciliary ganglion; 24 – Infra-orbital nerve; 25 – Superior dental branches; 26 – Superior dental plexus; 27 – Lingual nerve; 28 – Inferior gingival

R. communicans cum ganglio ciliari; Radix sensoria ganglii ciliaris; Radix nasociliaris ganglii ciliaris

47 Соединительная ветвь с ресничным узлом; чувствительный корешок ресничного узла; носоресничный корешок ресничного узла

45 Nervus ophthalmicus [Va; V1]

Глазной нерв [Va; V1]

44 Arteria carotis interna

Внутренняя сонная артерия

Nervus petrosus major; Radix parasympathica ganglii pterygopalatini; Radix intermedia ganglii pterygopalatini

43 Большой каменистый нерв; парасимпатический корешок крылоносового узла; промежуточный корешок крылоносового узла

Nervus mandibularis [Vc; V3]

42 Нижнечелюстной нерв [Vc; V3]

41 Arteria meningea media

Средняя менингеальная артерия

40 Arteria temporalis superficialis

Поверхностная височная артерия (отрезана)

Rr. alveolares superiores posteriores

39 Задние верхние альвеолярные ветви

Vena jugularis interna

38 Внутренняя яремная вена

37 Arteria carotis externa

Наружная сонная артерия

36 Arteria carotis interna

Внутренняя сонная артерия

35 Arteria lingualis

Язычная артерия

34 Arteria carotis communis

Общая сонная артерия

46 Ganglion ciliare

Ресничный узел

Nervus supraorbitalis, r. lateralis

48 Надглазничный нерв, латеральная ветвь

Nervus supraorbitalis, r. medialis

49 Надглазничный нерв, медиальная ветвь

Nervus supratrochlearis

50 Надблоковый нерв

Nervus oculomotorius [III]

51 Глазодвигательный нерв [III]

Ganglion

52 Крылоносовый узел

Rr. alveolares superiores anteriores

53 Передние верхние альвеолярные ветви

R. alveolaris superior medius

54 Средняя верхняя альвеолярная ветвь

Rr. gingivales superiores

55 Верхние десневые ветви

Nervus mylohyoideus

56 Челюстно-подъязычный нерв

Nervus mentalis

57 Подбородочный нерв

Arteria submental

58 Подподбородочная артерия

Arteria facialis

59 Лицевая артерия

branches; 29 – Inferior dental branches; 30 – Inferior dental plexus; 31 – Inferior alveolar nerve; 32 – External carotid artery; 33 – Superior facial artery; 34 – Common carotid artery; 35 – Lingual artery; 36 – Internal carotid artery; 37 – External carotid artery; 38 – Internal jugular vein; 39 – Posterior superior alveolar branches; 40 – Superficial temporal artery; 41 – Middle meningeal artery; 42 – Mandibular nerve, Mandibular division [Vc; V3]; 43 – Greater petrosal nerve; Parasympathetic root of pterygopalatine ganglion; 44 – Internal carotid artery; 45 – Ophthalmic nerve; Ophthalmic division [Va; V1]; 46 – Ciliary ganglion; 47 – Communicating branch with ciliary ganglion; Sensory root of ciliary ganglion; Nasociliary root of ciliary ganglion; 48 – Supra-orbital nerve, lateral branch; 49 – Supra-orbital nerve, medial branch; 50 – Supratrochlear nerve; 51 – Oculomotor nerve [III]; 52 – Pterygopalatine ganglion; 53 – Anterior superior alveolar branches; 54 – Middle superior alveolar branch; 55 – Superior gingival branches; 56 – Nerve to mylohyoid; 57 – Mental nerve; 58 – Submental artery; 59 – Facial artery

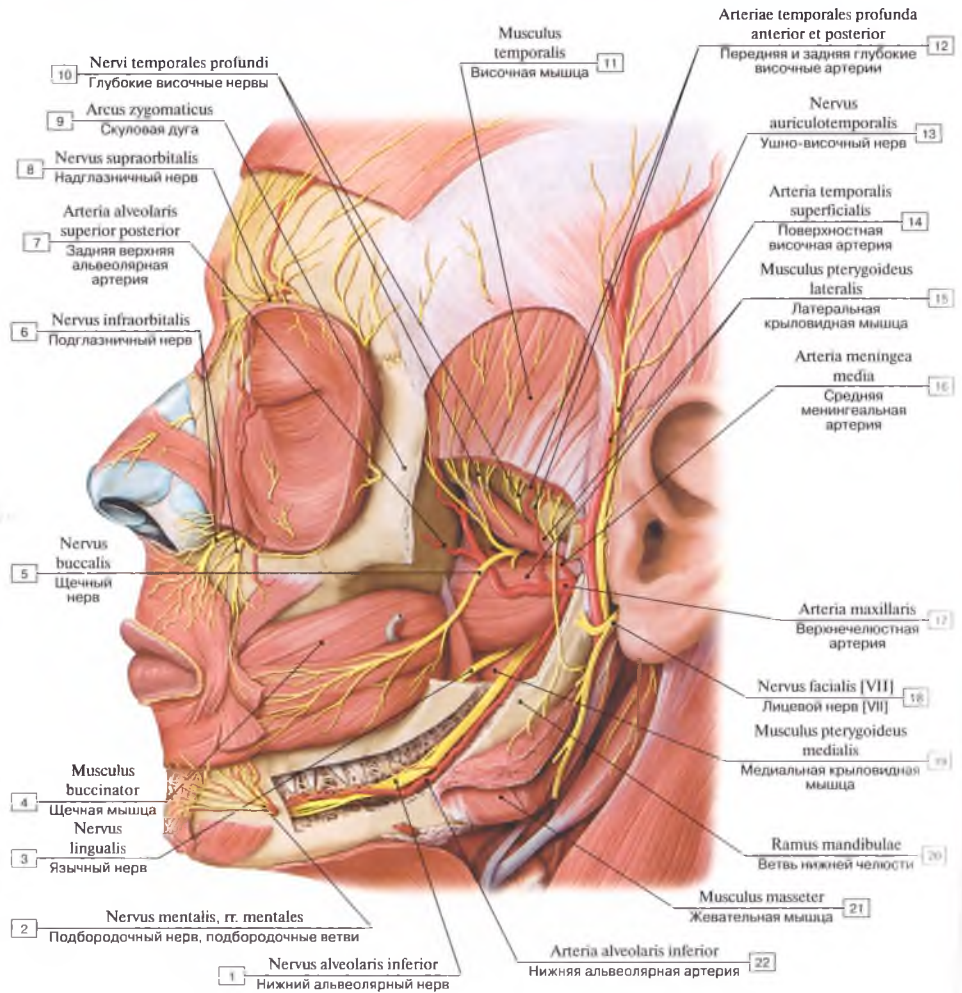


Рис. 192. Нижний альвеолярный нерв:

1 – Inferior alveolar nerve; 2 – Mental nerve, mental branches; 3 – Lingual nerve; 4 – Buccinator; 5 – Buccal nerve; 6 – Infra-orbital nerve; 7 – Posterior superior alveolar artery; 8 – Supra-orbital nerve; 9 – Zygomatic arch; 10 – Deep temporal nerves; 11 – Temporalis; Temporalis muscle; 12 – Anterior and posterior deep temporal arteries; 13 – Auriculotemporal nerve; 14 – Superficial temporal artery; 15 – Lateral pterygoid; 16 – Middle meningeal artery; 17 – Maxillary artery; 18 – Facial nerve [VII]; 19 – Medial pterygoid; 20 – Mandibular branch; 21 – Masseter; 22 – Inferior alveolar artery



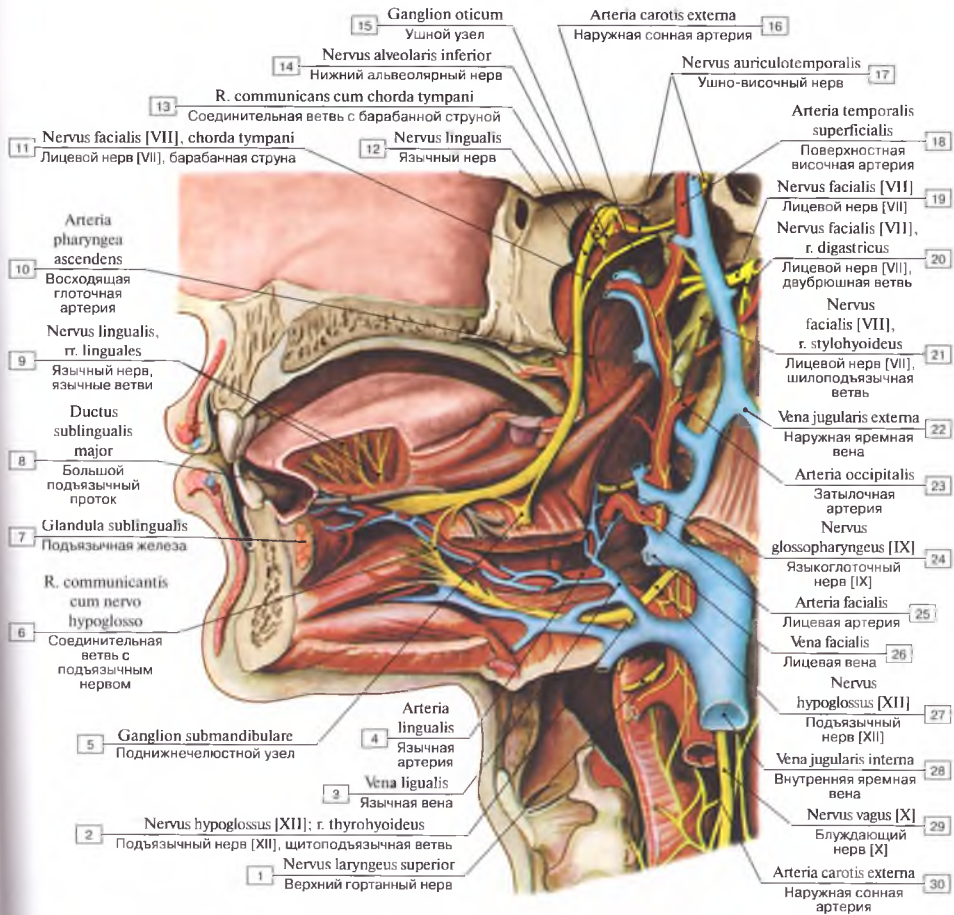


Рис. 193. Язычный нерв (схема):

1 – Superior laryngeal nerve; 2 – Hypoglossal nerve [XII], thyrohyoid branch; 3 – Lingual vein; 4 – Lingual artery; 5 – Submandibular ganglion; 6 – Communicating branch with hypoglossal nerve; 7 – Sublingual gland; 8 – Major sublingual duct; 9 – Lingual nerve, lingual branches; 10 – Ascending pharyngeal artery; 11 – Facial nerve [VII], chorda tympani; 12 – Lingual nerve; 13 – Communicating branch with chorda tympani; 14 – Inferior alveolar nerve; 15 – Otic ganglion; 16 – External carotid artery; 17 – Auriculotemporal nerve; 18 – Superficial temporal artery; 19 – Facial nerve [VII]; 20 – Facial nerve [VII], digastric branch; 21 – Facial nerve [VII], stylohyoid branch; 22 – External jugular vein; 23 – Occipital artery; 24 – Glossopharyngeal nerve [IX]; 25 – Facial artery; 26 – Facial vein; 27 – Hypoglossal nerve [XII]; 28 – Internal jugular vein; 29 – Vagus nerve [X]; 30 – External carotid artery

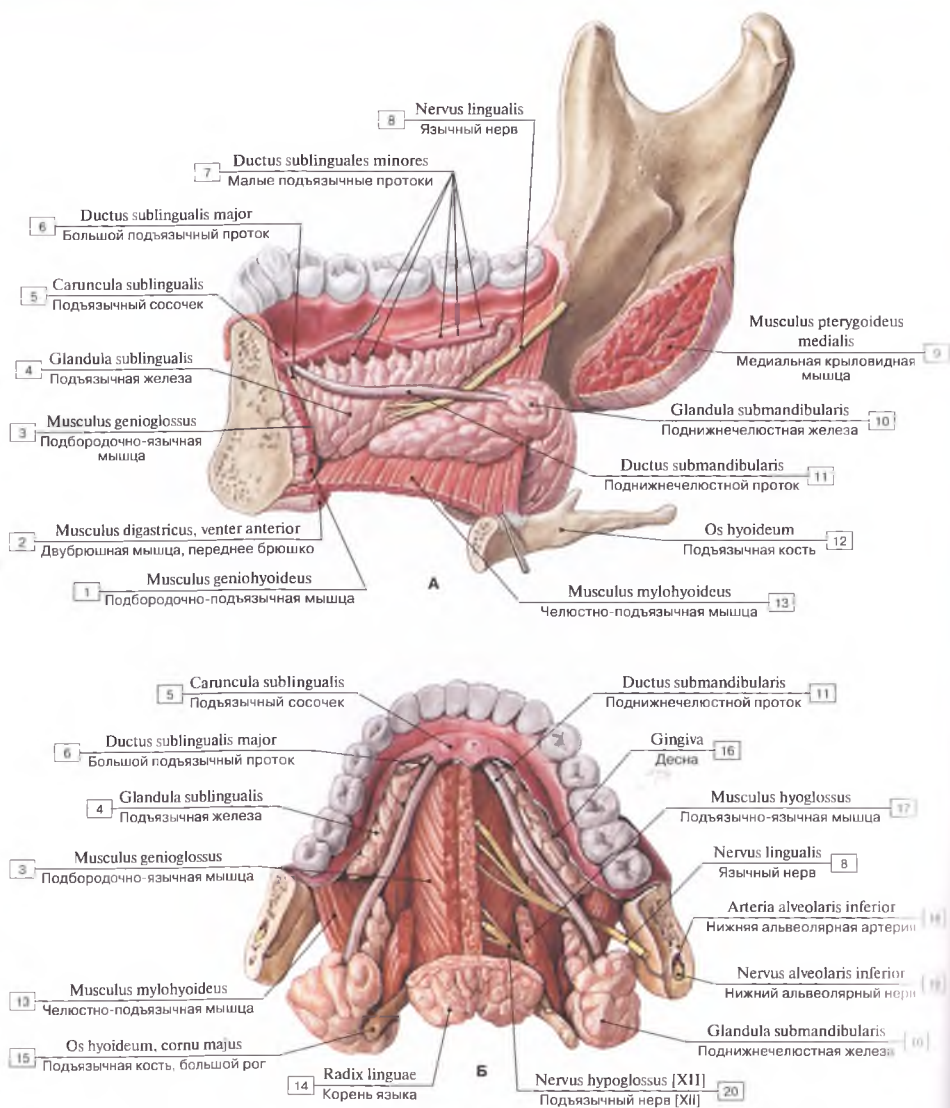
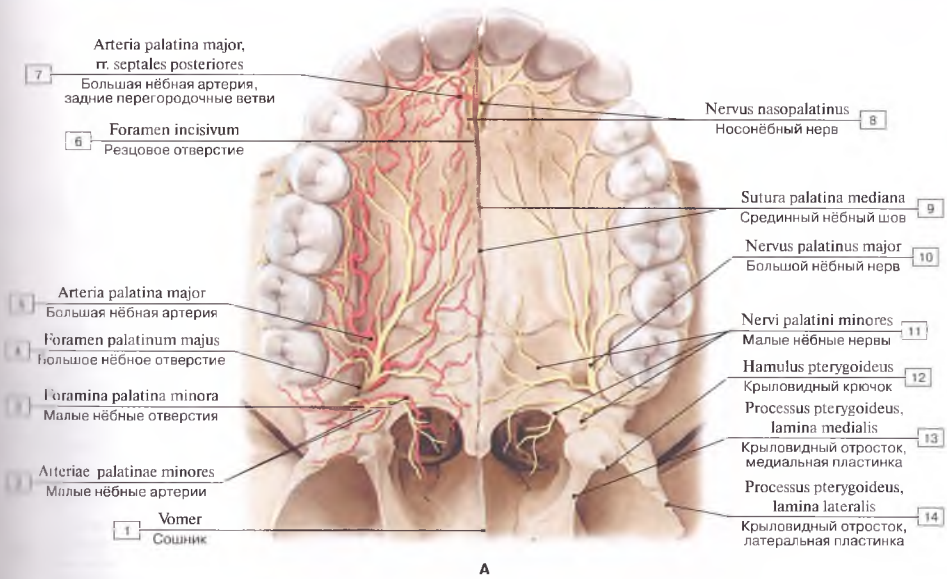
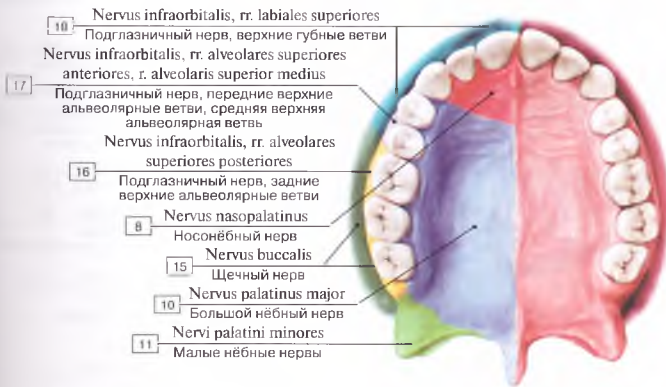


Рис. 194. Нервы диафрагмы рта (А – вид сбоку; Б – вид сверху):

1 – Geniohyoid; 2 – Digastric, anterior belly; 3 – Genioglossus; 4 – Sublingual gland; 5 – Sublingual caruncle; 6 – Major sublingual duct; 7 – Minor sublingual ducts; 8 – Lingual nerve; 9 – Medial pterygoid; 10 – Submandibular gland; 11 – Submandibular duct; 12 – Hyoid bone; 13 – Mylohyoid; 14 – Root of tongue; 15 – Hyoid bone, greater horn; 16 – Gingiva; 17 – Hyoglossus; 18 – Inferior alveolar artery; 19 – Inferior alveolar nerve; 20 – Hypoglossal nerve [XII]



A



Б

Рис. 195. Большой нёбный нерв (А – нейроваскулярные структуры твердого нёба, вид снизу); Б – чувствительная иннервация слизистой нёба, верхней губы, щеки и десны, вид снизу);

1 – Vomer; 2 – Lesser palatine arteries; 3 – Lesser palatine foramina; 4 – Greater palatine foramen; 5 – Greater palatine artery; 6 – Incisive foramen; 7 – Greater palatine artery, posterior septal branches; 8 – Nasopalatine nerve; 9 – Median palatine suture; 10 – Greater palatine nerve; 11 – Lesser palatine nerves; 12 – Pterygoid hamulus; 13 – Pterygoid process, medial plate; 14 – Pterygoid process, lateral plate; 15 – Buccal nerve; 16 – Infra-orbital nerve, posterior superior alveolar branches; 17 – Infra-orbital nerve, anterior superior alveolar branches, middle superior alveolar branch; 18 – Infra-orbital nerve, superior labial branches

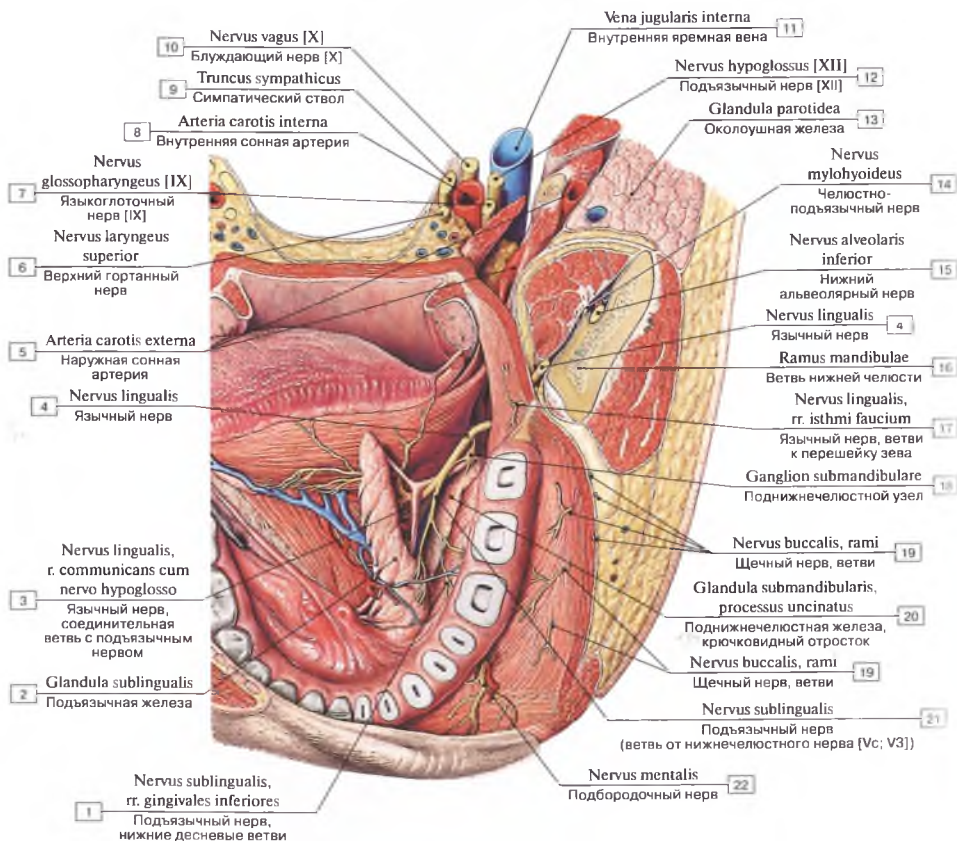


Рис. 196. Нервы дна ротовой полости:

1 – Sublingual nerve, inferior gingival branches; 2 – Sublingual gland; 3 – Lingual nerve, communicating branch with hypoglossal nerve; 4 – Lingual nerve; 5 – External carotid artery; 6 – Superior laryngeal nerve; 7 – Glossopharyngeal nerve [IX]; 8 – Internal carotid artery; 9 – Sympathetic trunk; 10 – Vagus nerve [X]; 11 – Internal jugular vein; 12 – Hypoglossal nerve [XII]; 13 – Parotid gland; 14 – Nerve to mylohyoid; 15 – Inferior alveolar nerve; 16 – Mandibular branch; 17 – Lingual nerve, branches to isthmus of fauces; 18 – Submandibular ganglion; 19 – Buccal nerve, branches; 20 – Submandibular gland, uncinata process; 21 – Sublingual nerve; 22 – Mental nerve

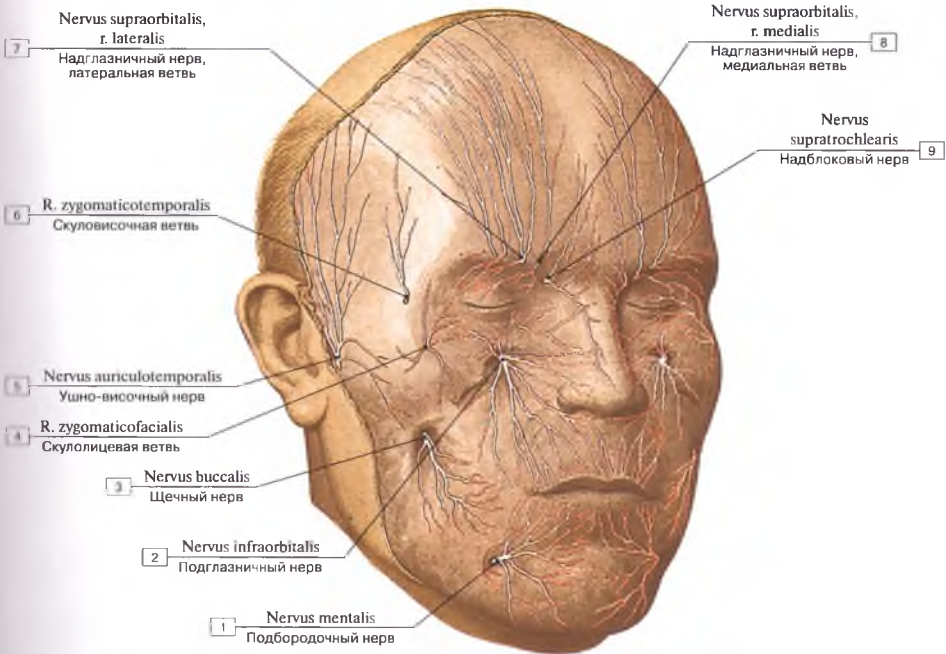


Рис. 197. Кожные ветви тройничного нерва:

1 – Mental nerve; 2 – Infra-orbital nerve; 3 – Buccal nerve; 4 – Zygomaticofacial branch; 5 – Auriculotemporal nerve; 6 – Zygomaticofacial branch; 7 – Supra-orbital nerve, lateral branch; 8 – Supra-orbital nerve, medial branch; 9 – Supratrochlear nerve

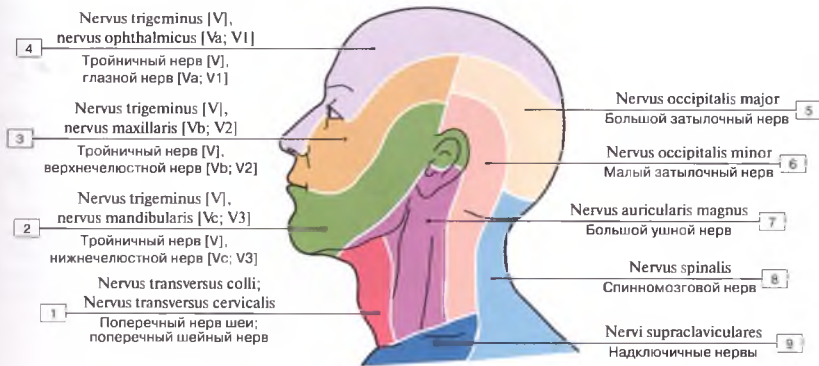


Рис. 198. Иннервация кожи лица, вид сбоку слева:

1 – Transverse cervical nerve; 2 – Trigeminal nerve [V], mandibular nerve; mandibular division [Vc; V3]; 3 – Trigeminal nerve [V], maxillary division [Vb; V2]; 4 – Trigeminal nerve [V], ophthalmic nerve; ophthalmic division [Va; V1]; 5 – Greater occipital nerve; 6 – Lesser occipital nerve; 7 – Great auricular nerve; 8 – Spinal nerve; 9 – Supraclavicular nerves

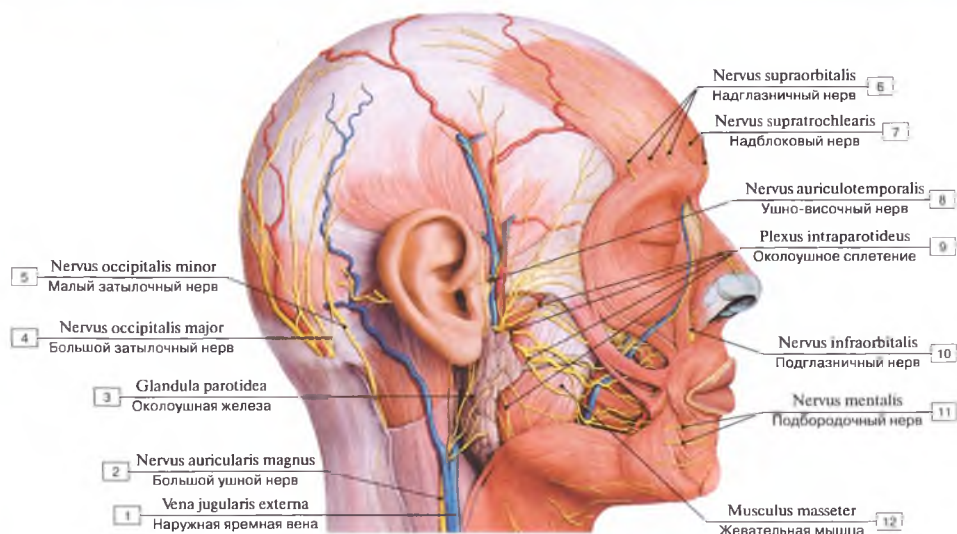


Рис. 202. Лицевой нерв и его ветви:

1 – External jugular vein; 2 – Great auricular nerve; 3 – Parotid gland; 4 – Greater occipital nerve; 5 – Lesser occipital nerve; 6 – Supra-orbital nerve; 7 – Supratrochlear nerve; 8 – Auriculotemporal nerve; 9 – Parotid plexus; 10 – Infra-orbital nerve; 11 – Mental nerve; 12 – Masseter

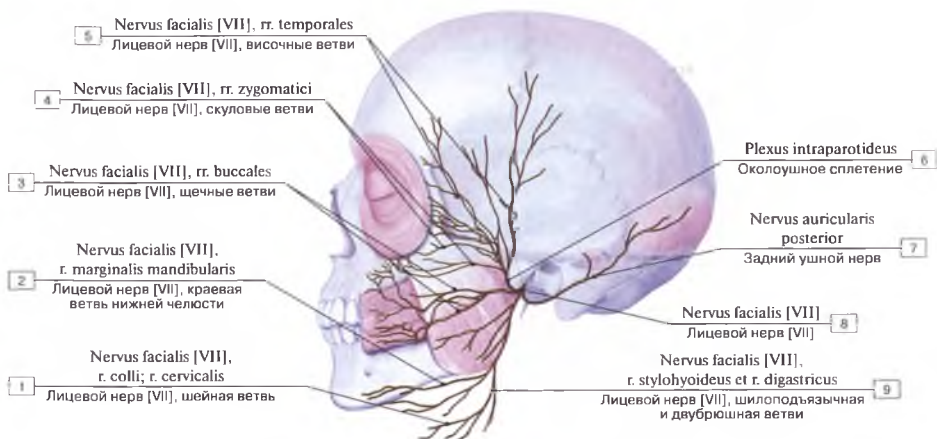


Рис. 203. Мышечные ветви лицевого нерва, вид сбоку и слева:

1 – Facial nerve [VII], cervical branch; 2 – Facial nerve [VII], marginal mandibular branch; 3 – Facial nerve [VII], buccal branches; 4 – Facial nerve [VII], zygomatic branches; 5 – Facial nerve [VII], temporal branches; 6 – Parotid plexus; 7 – Posterior auricular nerve; 8 – Facial nerve [VII]; 9 – Facial nerve [VII], stylohyoid and digastric branches

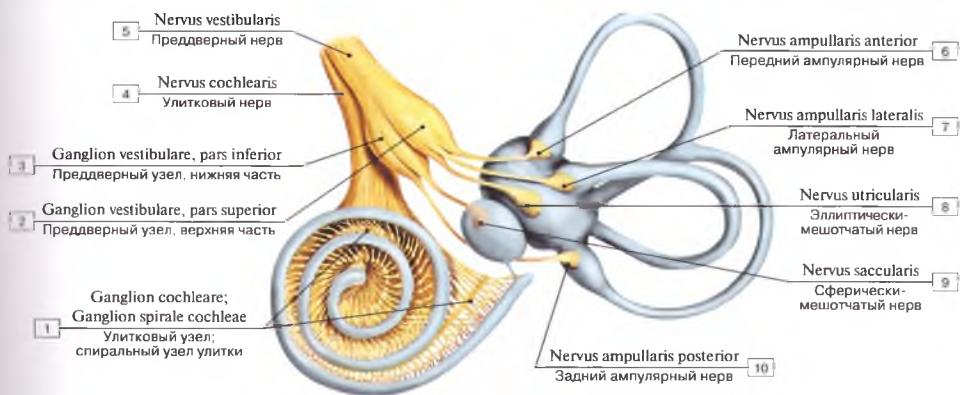


Рис. 204. Преддверный узел и улитковый узел (спиральный узел улитки):

1 – Cochlear ganglion; Spiral ganglion; 2 – Vestibular ganglion, superior part; 3 – Vestibular ganglion, inferior part; 4 – Cochlear nerve; 5 – Vestibular nerve; 6 – Anterior ampullary nerve; 7 – Lateral ampullary nerve; 8 – Utricular nerve; 9 – Saccular nerve; 10 – Posterior ampullary nerve

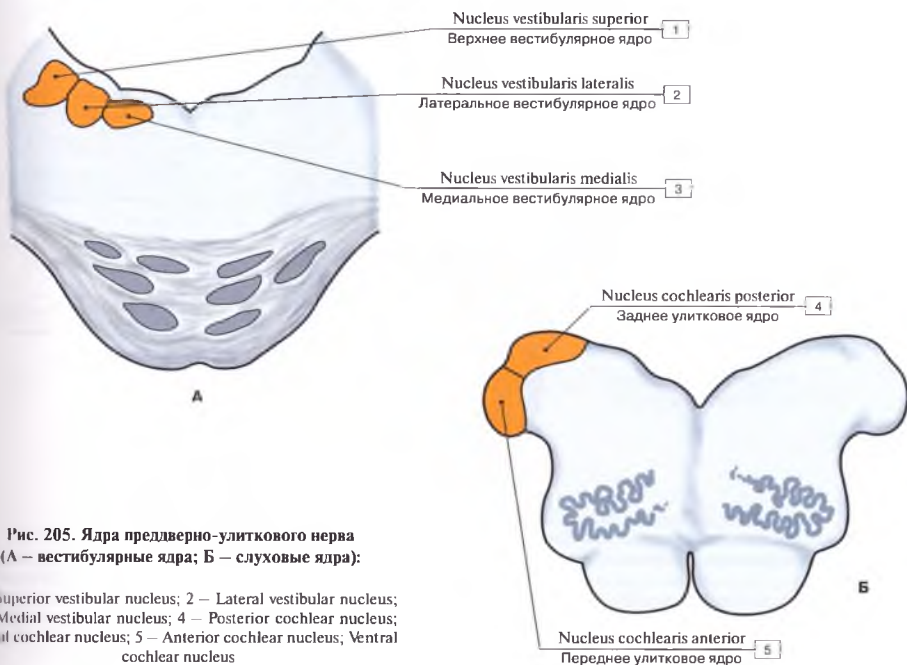


Рис. 205. Ядра преддверно-улиткового нерва  
(А – вестибулярные ядра; Б – слуховые ядра):

1 – Superior vestibular nucleus; 2 – Lateral vestibular nucleus;  
3 – Medial vestibular nucleus; 4 – Posterior cochlear nucleus;  
5 – Anterior cochlear nucleus; 5 – Ventral cochlear nucleus

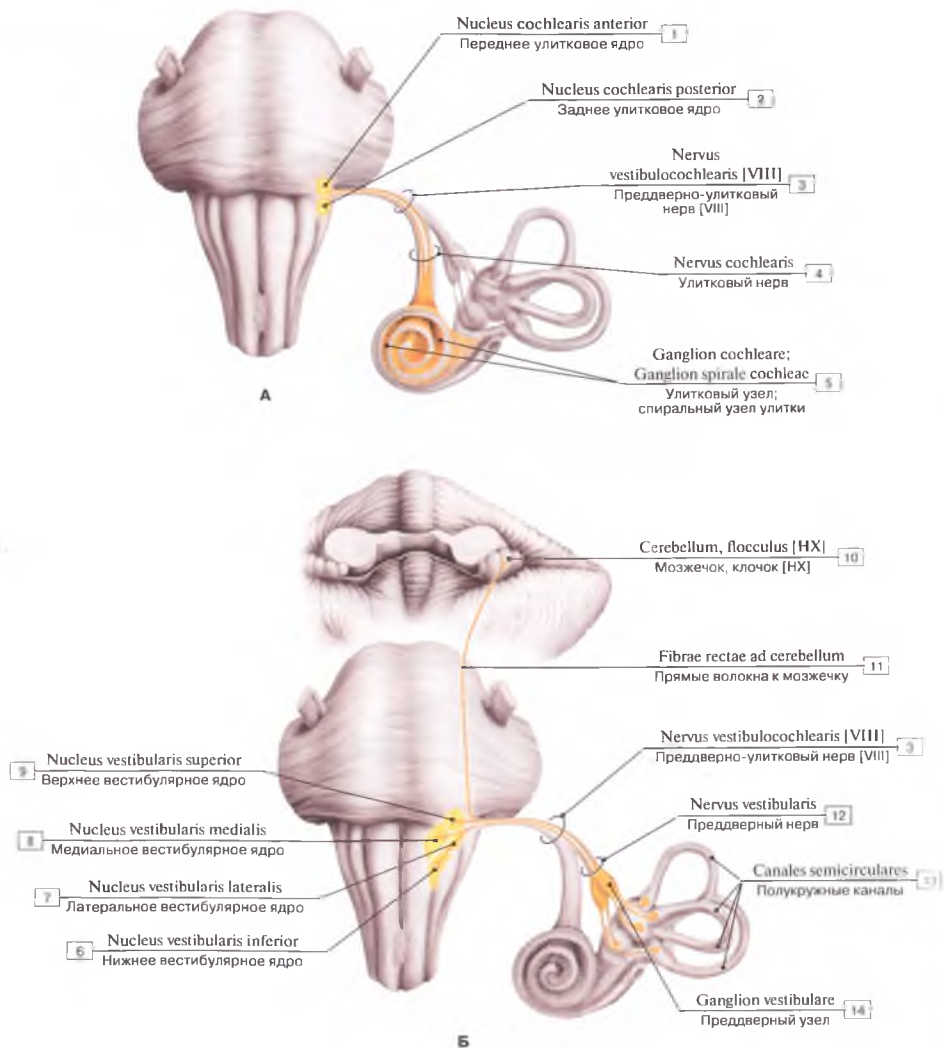
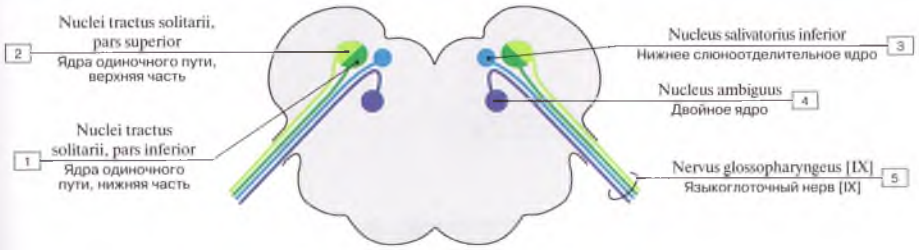


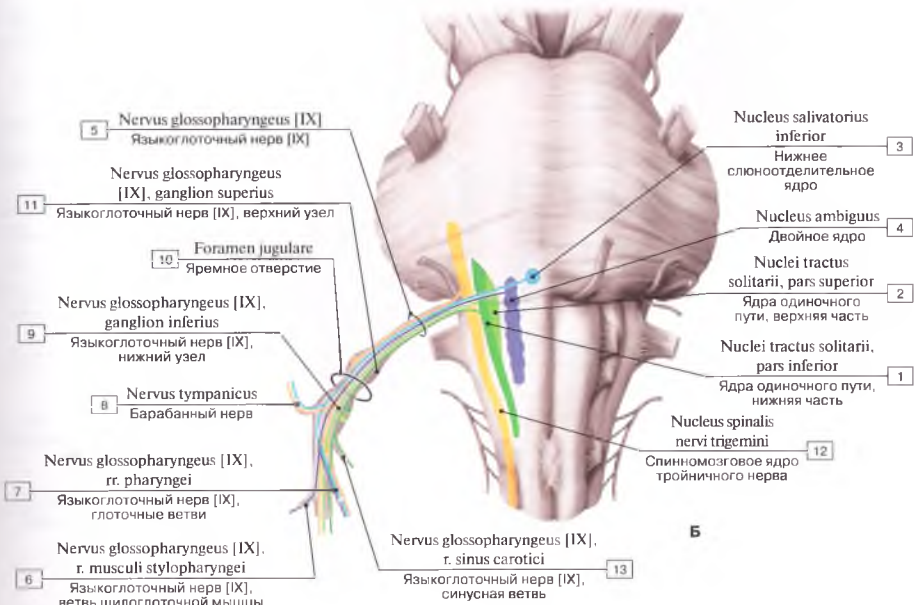
Рис. 206. Ядра преддверно-улиткового нерва в стволе мозга (А – улитковая часть; Б – вестибулярная часть) (схема):

1 – Anterior cochlear nucleus; 2 – Posterior cochlear nucleus; 3 – Vestibulocochlear nerve [VIII]; 4 – Cochlear nerve; 5 – Cochlear ganglion; 6 – Inferior vestibular nucleus; 7 – Lateral vestibular nucleus; 8 – Medial vestibular nucleus; 9 – Superior vestibular nucleus; 10 – Cerebellum, flocculus [HX]; 11 – Direct fibres to cerebellum; 12 – Vestibular nerve; 13 – Semicircular canals; 14 – Vestibular ganglion





А



Б

Рис. 207. Ядра языкоглоточного нерва (А – поперечный срез продолговатого мозга на уровне выхода языкоглоточного нерва; Б – продолговатый мозг, вид спереди) (схемы):

1 – Nuclei of solitary tract; Solitary nuclei, inferior part; 2 – Nuclei of solitary tract; Solitary nuclei, superior part; 3 – Inferior salivatory nucleus; 4 – Nucleus ambiguus; 5 – Glossopharyngeal nerve [IX]; 6 – Glossopharyngeal nerve [IX], stylopharyngeal branch; 7 – Glossopharyngeal nerve [IX], pharyngeal branches; 8 – Tympanic nerve; 9 – Glossopharyngeal nerve [IX], inferior ganglion; 10 – Jugular foramen; 11 – Glossopharyngeal nerve [IX], superior ganglion; 12 – Spinal nucleus of trigeminal nerve; 13 – Glossopharyngeal nerve [IX], carotid branch

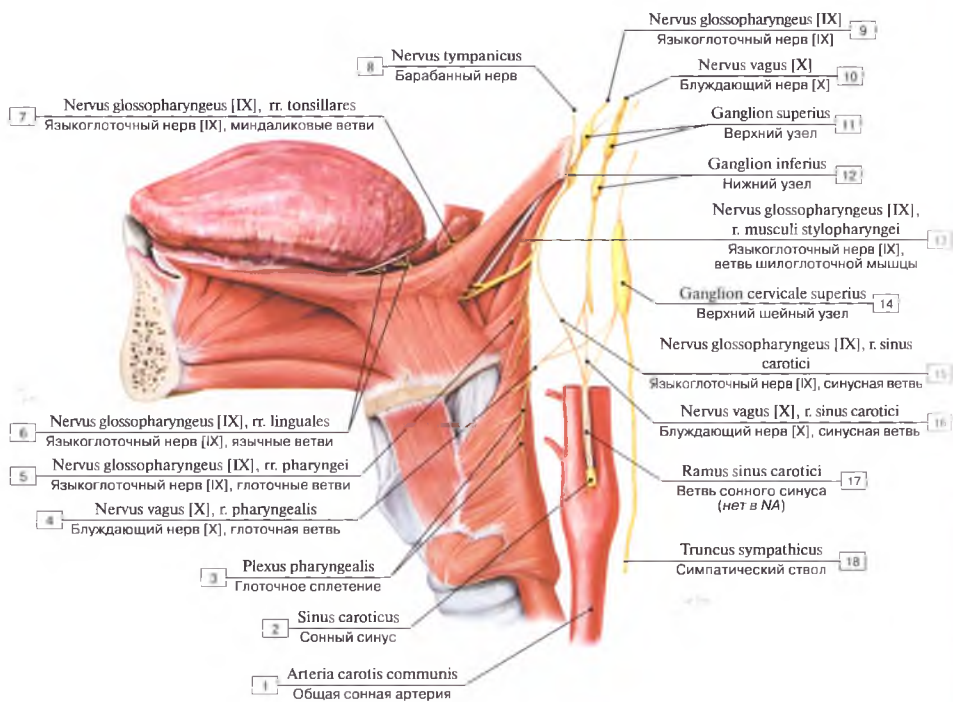


Рис. 208. Ветви языкоглоточного нерва за пределами основания черепа, вид слева:

1 – Common carotid artery; 2 – Carotid sinus; 3 – Pharyngeal plexus; 4 – Vagus nerve [X], pharyngeal branch; 5 – Glossopharyngeal nerve [IX], pharyngeal branches; 6 – Glossopharyngeal nerve [IX], lingual branches; 7 – Glossopharyngeal nerve [IX], tonsillar branches; 8 – Tympanic nerve; 9 – Glossopharyngeal nerve [IX]; 10 – Vagus nerve [X]; 11 – Superior ganglion; 12 – Inferior ganglion; 13 – Glossopharyngeal nerve [IX], stylopharyngeal branch; 14 – Superior cervical ganglion; 15 – Glossopharyngeal nerve [IX], carotid branch; 16 – Vagus nerve [X], carotid branch; 17 – Carotid branch; 18 – Sympathetic trunk

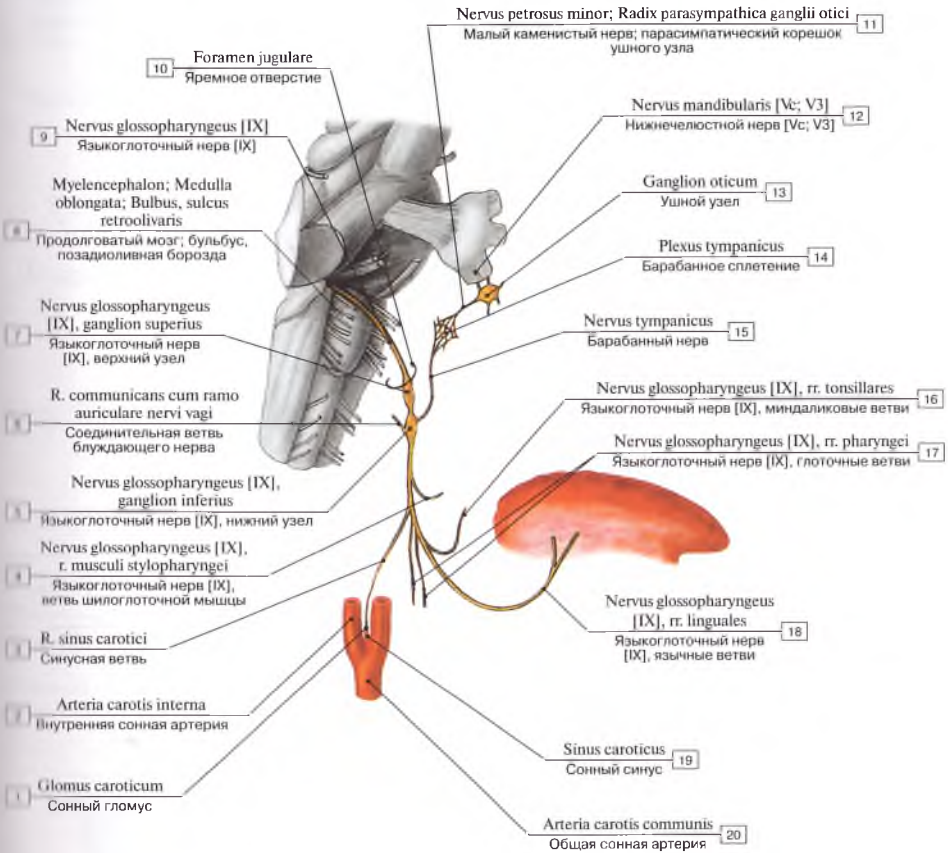


Рис. 209. Языкоглоточный нерв, вид справа:

1 – Carotid body; 2 – Internal carotid artery; 3 – Carotid branch; 4 – Glossopharyngeal nerve [IX], stylopharyngeal branch; 5 – Glossopharyngeal nerve [IX], inferior ganglion; 6 – Communicating branch with auricular branch of vagus nerve; 7 – Glossopharyngeal nerve [IX], superior ganglion; 8 – Myelencephalon; Medulla oblongata; Bulb, retro-olivary groove; 9 – Glossopharyngeal nerve [IX]; 10 – Jugular foramen; 11 – Lesser petrosal nerve; Parasympathetic root of otic ganglion; 12 – Mandibular nerve; Mandibular division [V; V3]; 13 – Otic ganglion; 14 – Tympanic plexus; 15 – Tympanic nerve; 16 – Glossopharyngeal nerve [IX], tonsillar branches; 17 – Glossopharyngeal nerve [IX], pharyngeal branches; 18 – Glossopharyngeal nerve [IX], lingual branches; 19 – Carotid sinus; 20 – Common carotid artery

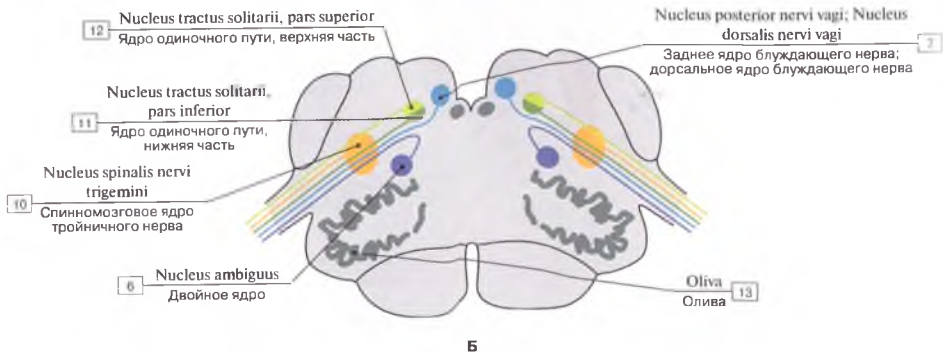
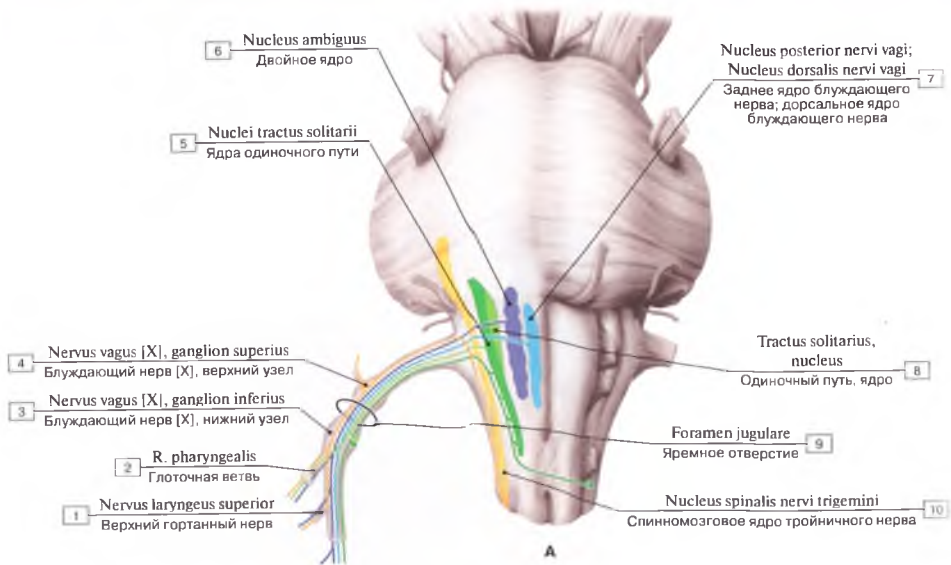


Рис. 210. Ядро блуждающего нерва (А — продолговатый мозг, вид спереди, показано место выхода блуждающего нерва; Б — поперечный срез продолговатого мозга на уровне верхней оливы):

1 — Superior laryngeal nerve; 2 — Pharyngeal branch; 3 — Vagus nerve [X], inferior ganglion; 4 — Vagus nerve [X], superior ganglion; 5 — Nuclei of solitary tract; Solitary nuclei; 6 — Nucleus ambiguus; 7 — Posterior nucleus of vagus nerve; Dorsal nucleus of vagus nerve; 8 — Solitary tract, nucleus; 9 — Jugular foramen; 10 — Spinal nucleus of trigeminal nerve; 11 — Nucleus of solitary tract; Solitary nucleus, inferior part; 12 — Nucleus of solitary tract; Solitary nucleus, superior part; 13 — Inferior olive

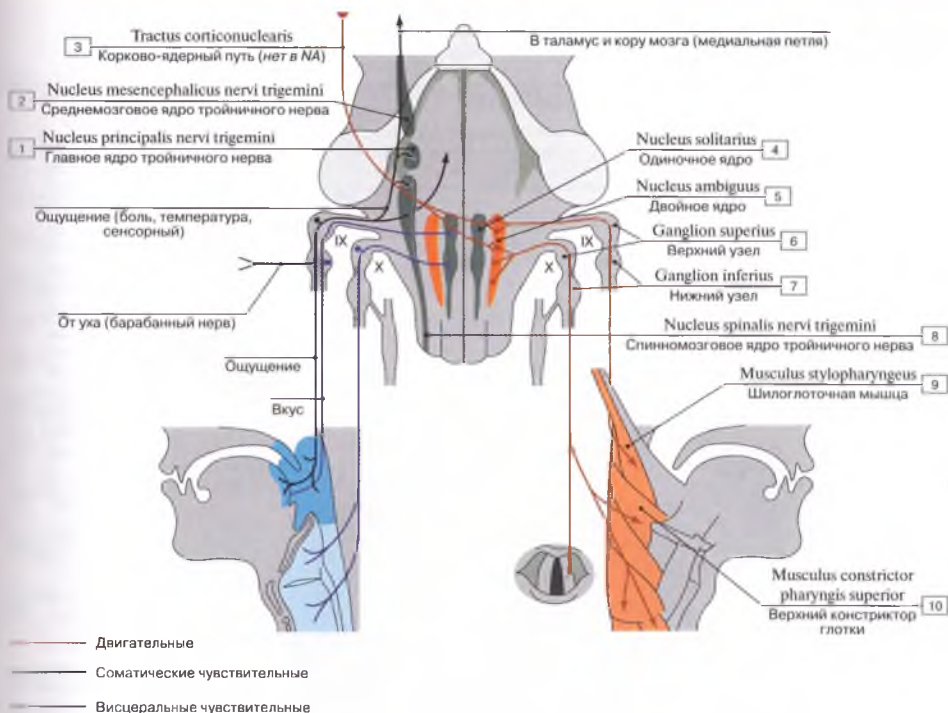


Рис. 211. Блуждающий нерв и языкоглоточный нерв: их периферическое распространение и ядра в продолговатом мозге, вид сзади:

1 – Principal sensory nucleus of trigeminal nerve; 2 – Mesencephalic nucleus of trigeminal nerve; 3 – Corticonuclear tract; 4 – Solitary nucleus; 5 – Nucleus ambiguus; 6 – Superior ganglion; 7 – Inferior ganglion; 8 – Spinal nucleus of trigeminal nerve; 9 – Stylopharyngeus; 10 – Superior constrictor

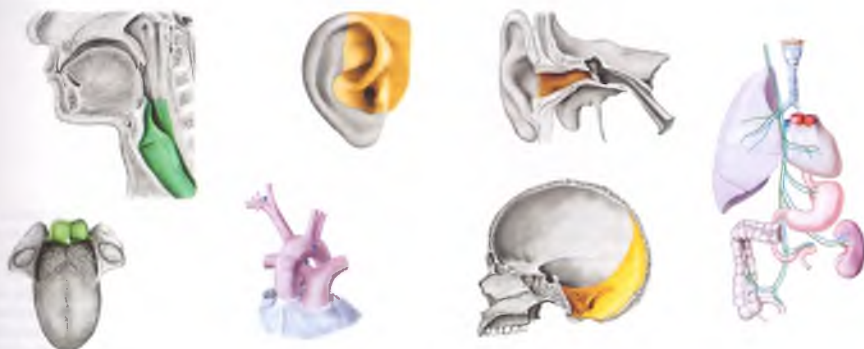

Рис. 212. Зоны чувствительной иннервации блуждающего нерва (схема)

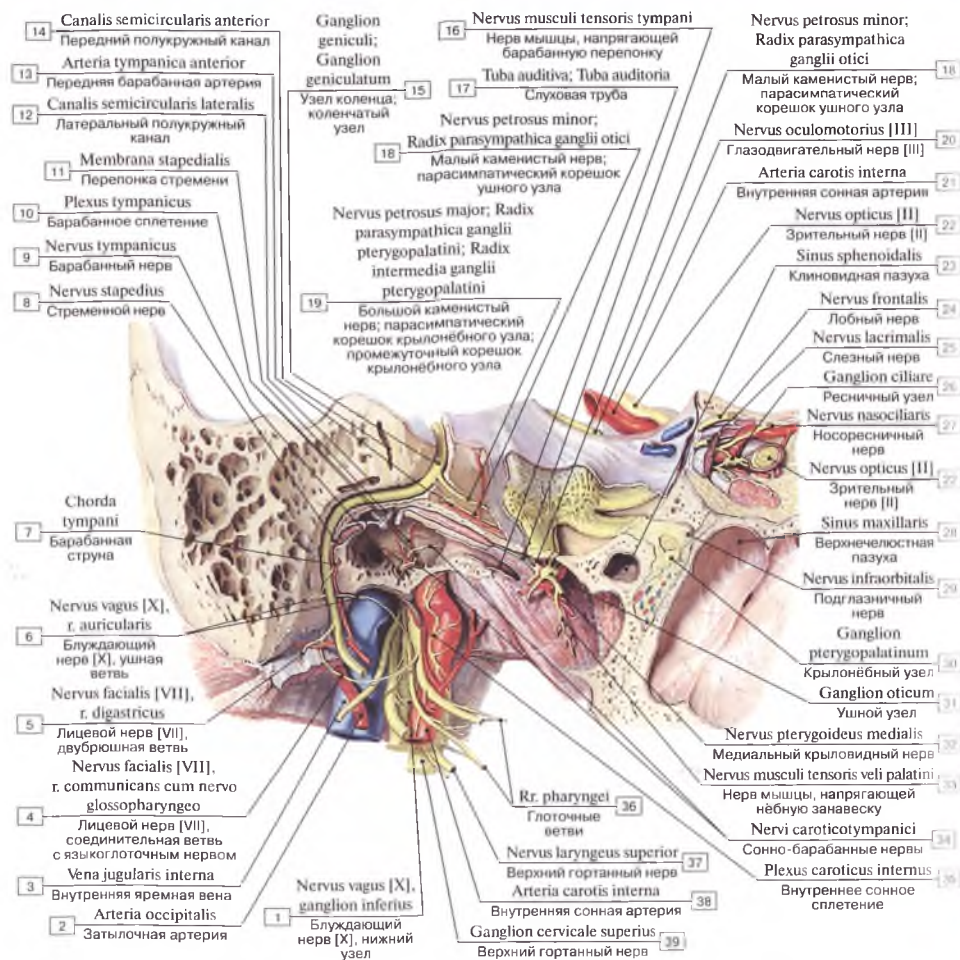


Рис. 213. Выход нервов из зygomatic отверстия:

1 — Vagus nerve [X], inferior ganglion; 2 — Occipital artery; 3 — Internal jugular vein; 4 — Facial nerve [VII], communicating branch with glossopharyngeal nerve; 5 — Facial nerve [VII], digastric branch; 6 — Vagus nerve [X], auricular branch; 7 — Chorda tympani; 8 — Nerve to stapedius; 9 — Tympanic nerve; 10 — Tympanic plexus; 11 — Stapedial membrane; 12 — Lateral semicircular canal; 13 — Anterior tympanic artery; 14 — Anterior semicircular canal; 15 — Geniculate ganglion; 16 — Nerve to tensor tympani; 17 — Pharyngotympanic tube; Auditory tube; 18 — Lesser petrosal nerve; Parasympathetic root of otic ganglion; 19 — Greater petrosal nerve; Parasympathetic root of pterygopalatine ganglion; 20 — Oculomotor nerve [III]; 21 — Internal carotid artery; 22 — Optic nerve [III]; 23 — Sphenoidal sinus; 24 — Frontal nerve; 25 — Lacrimal nerve; 26 — Ciliary ganglion; 27 — Nasociliary nerve; 28 — Maxillary sinus; 29 — Infra-orbital nerve; 30 — Pterygopalatine ganglion; 31 — Otic ganglion; 32 — Nerve to medial pterygoid; 33 — Nerve to tensor veli palatini; 34 — Caroticotympanic nerves; 35 — Internal carotid plexus; 36 — Pharyngeal branches; 37 — Superior laryngeal nerve; 38 — Internal carotid artery; 39 — Superior laryngeal nerve.

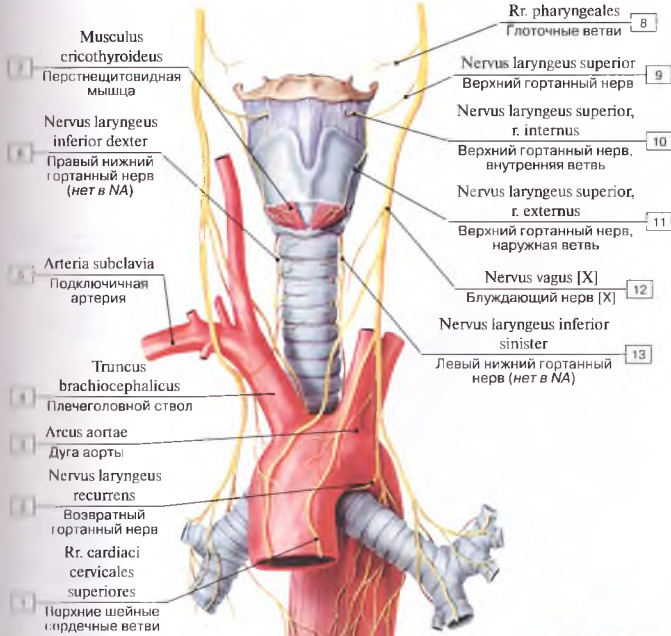


Рис. 214. Ветви блуждающего нерва на шею:

1 – Superior cervical cardiac branches; 2 – Recurrent laryngeal nerve; 3 – Arch of aorta; Aortic arch; 4 – Brachiocephalic trunk; 5 – Subclavian artery; 6 – Right inferior laryngeal nerve; 7 – Cricothyroid; 8 – Pharyngeal branches; 9 – Superior laryngeal nerve; 10 – Superior laryngeal nerve, internal branch; 11 – Superior laryngeal nerve, external branch; 12 – Vagus nerve [X]; 13 – Left inferior laryngeal nerve

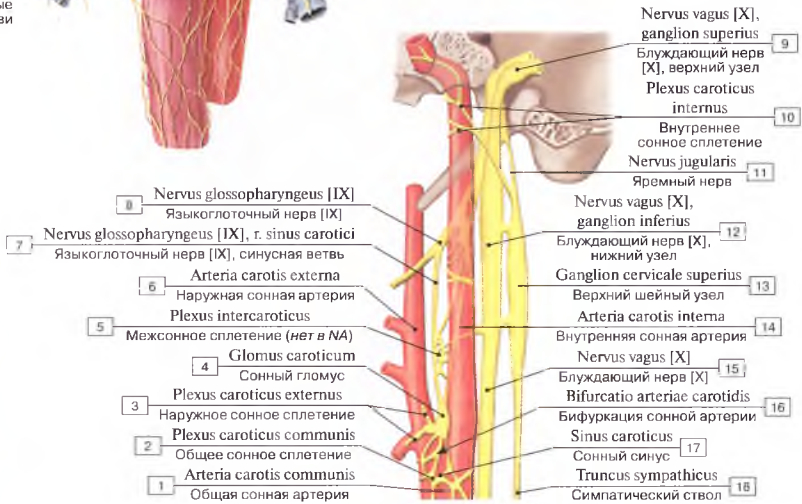


Рис. 215. Формирование блуждающего нерва:

1 – Common carotid artery; 2 – Common carotid plexus; 3 – External carotid plexus; 4 – Carotid body; 5 – Intercarotid plexus; 6 – External carotid artery; 7 – Glossopharyngeal nerve [IX], carotid branch; 8 – Glossopharyngeal nerve [IX]; 9 – Vagus nerve [X], superior ganglion; 10 – Internal carotid artery; 11 – Jugular nerve; 12 – Vagus nerve [X], inferior ganglion; 13 – Superior cervical ganglion; 14 – Internal carotid artery; 15 – Vagus nerve [X]; 16 – Carotid bifurcation; 17 – Carotid sinus; 18 – Sympathetic trunk

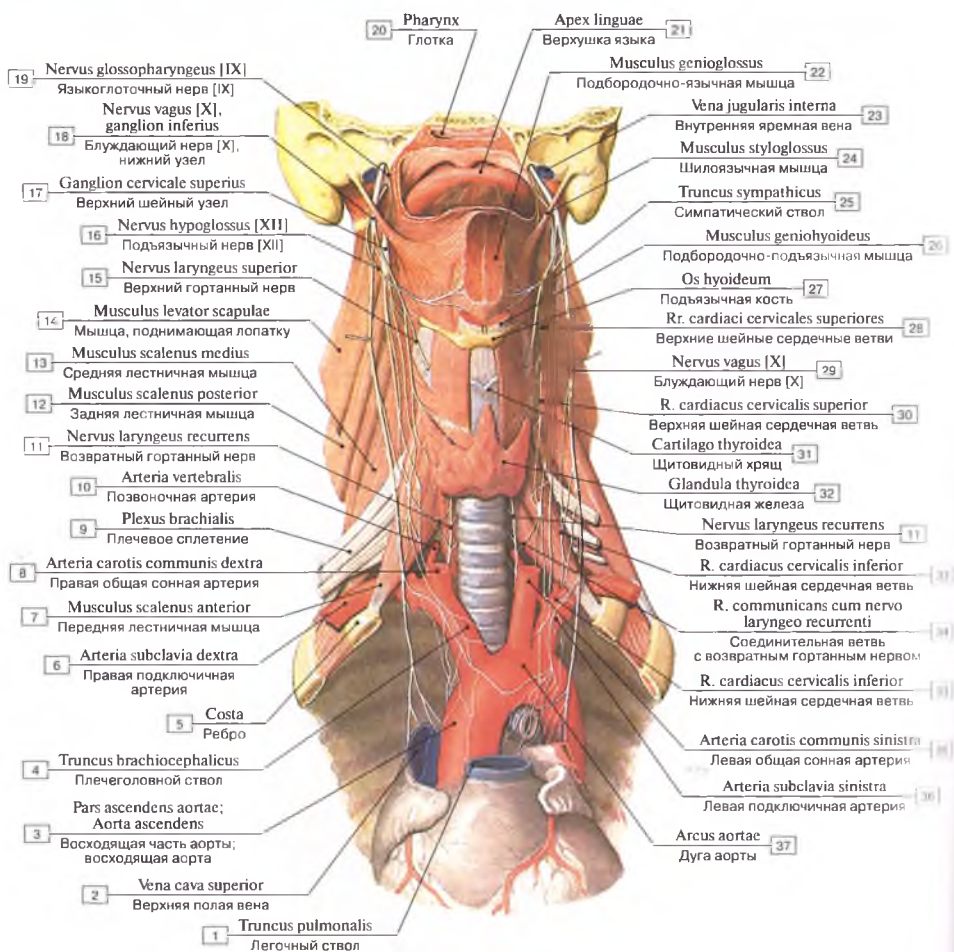


Рис. 216. Блуждающие нервы и другие нервы шеи, вид спереди (верхняя полая вена и легочная артерия удалены; на передней поверхности дуги аорты видна соединительная ветвь между правым и левым блуждающими нервами):

1 – Pulmonary trunk; 2 – Superior vena cava; 3 – Ascending aorta; 4 – Brachiocephalic trunk; 5 – Rib; 6 – Right subclavian artery; 7 – Scalenus anterior; Anterior scalene; 8 – Right common carotid artery; 9 – Brachial plexus; 10 – Vertebral artery; 11 – Recurrent laryngeal nerve; 12 – Scalenus posterior; Posterior scalene; 13 – Scalenus medius; Middle scalene; 14 – Levator scapulae; 15 – Superior laryngeal nerve; 16 – Hypoglossal nerve [XII]; 17 – Superior cervical ganglion; 18 – Vagus nerve [X], inferior ganglion; 19 – Glossopharyngeal nerve [IX]; 20 – Pharynx; 21 – Apex of tongue; Tip of tongue; 22 – Genioglossus; 23 – Internal jugular vein; 24 – Styloglossus; 25 – Sympathetic trunk; 26 – Geniohyoid; 27 – Hyoid bone; 28 – Superior cervical cardiac branches; 29 – Vagus nerve [X]; 30 – Superior cervical cardiac branch; 31 – Thyroid cartilage; 32 – Thyroid gland; 33 – Inferior cervical cardiac branch; 34 – Communicating branch with recurrent laryngeal nerve; 35 – Left common carotid artery; 36 – Left subclavian artery; 37 – Arch of aorta; Aortic arch



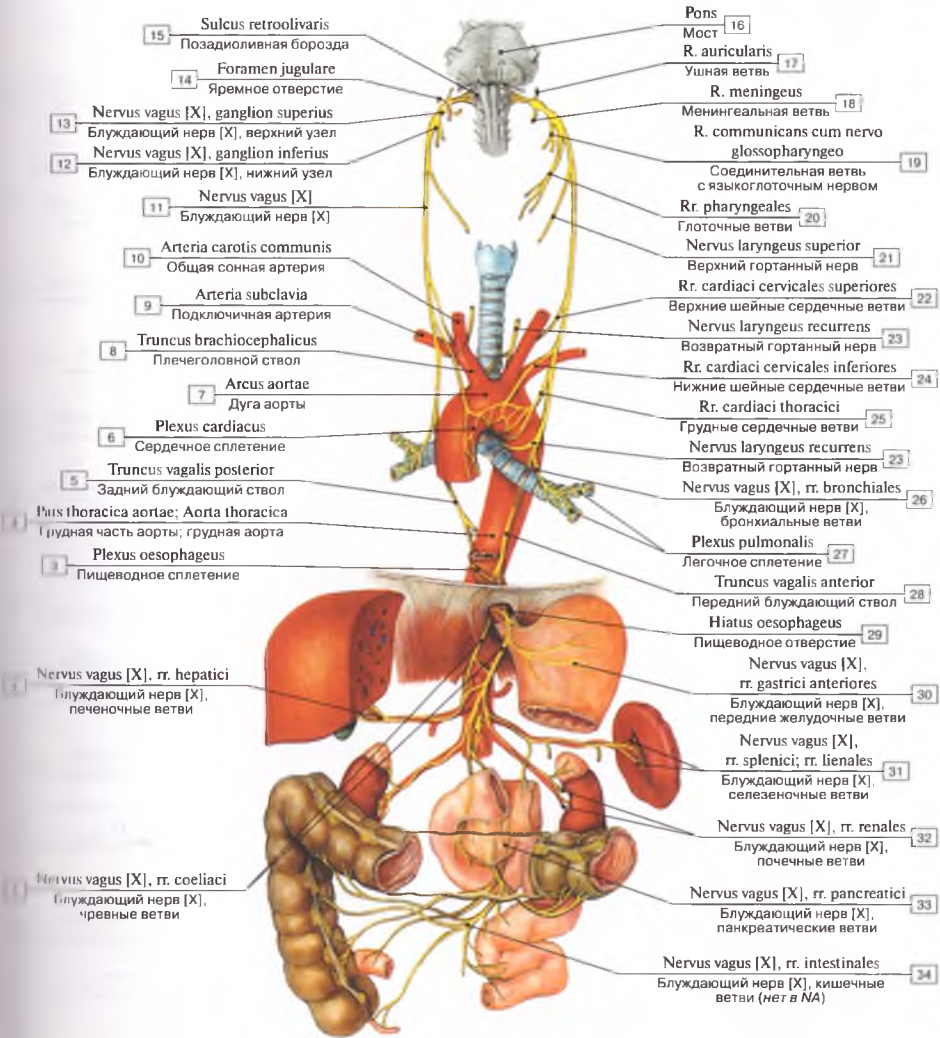


Рис. 217. Блуждающие нервы и их ветви, вид спереди (схема):

- 1 – Nervus vagus [X], coeliac branches; 2 – Vagus nerve [X], hepatic branches; 3 – Oesophageal plexus; 4 – Thoracic aorta; 5 – Posterior vagal trunk; 6 – Cardiac plexus; 7 – Arch of aorta; Aortic arch; 8 – Brachiocephalic trunk; 9 – Subclavian artery; 10 – Common carotid artery; 11 – Vagus nerve [X]; 12 – Vagus nerve [X], inferior ganglion; 13 – Vagus nerve [X], superior ganglion; 14 – Jugular foramen; 15 – Retro-olivary groove; 16 – Pons; 17 – Auricular branch; 18 – Meningeal branch; 19 – Communicating branch with glossopharyngeal nerve; 20 – Pharyngeal branches; 21 – Superior laryngeal nerve; 22 – Superior cervical cardiac branches; 23 – Recurrent laryngeal nerve; 24 – Inferior cervical cardiac branches; 25 – Thoracic cardiac branches; 26 – Vagus nerve [X], bronchial branches; 27 – Pulmonary plexus; 28 – Anterior vagal trunk; 29 – Oesophageal hiatus; 30 – Vagus nerve [X], anterior gastric branches; 31 – Vagus nerve [X], splenic branches; 32 – Vagus nerve [X], renal branches; 33 – Vagus nerve [X], pancreatic branches; 34 – Vagus nerve [X], intestinal branches

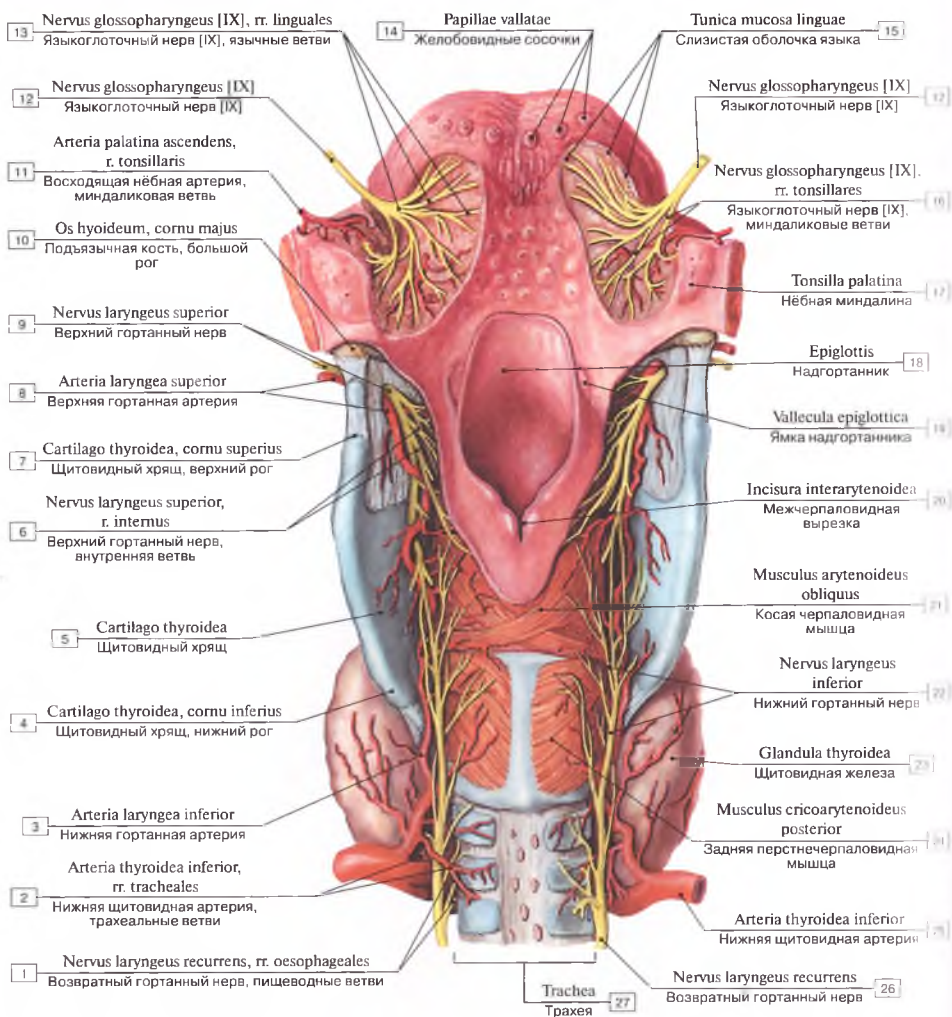


Рис. 218. Гортанные и другие нервы шеи, вид спереди:

1 – Recurrent laryngeal nerve, oesophageal branches; 2 – Inferior thyroid artery, tracheal branches; 3 – Inferior laryngeal artery; 4 – Thyroid cartilage, inferior horn; 5 – Thyroid cartilage; 6 – Superior laryngeal nerve, internal branch; 7 – Thyroid cartilage, superior horn; 8 – Superior laryngeal artery; 9 – Superior laryngeal nerve; 10 – Hyoid bone, greater horn; 11 – Ascending palatine artery, tonsillar branch; 12 – Glossopharyngeal nerve [IX]; 13 – Glossopharyngeal nerve [IX], lingual branches; 14 – Vallate papillae; 15 – Mucous membrane of tongue; 16 – Glossopharyngeal nerve [IX], tonsillar branches; 17 – Palatine tonsil; 18 – Epiglottis; 19 – Epiglottic vallecula; 20 – Interarytenoid notch; 21 – Oblique arytenoid; 22 – Inferior laryngeal nerve; 23 – Thyroid gland; 24 – Posterior crico-arytenoid; 25 – Inferior thyroid artery; 26 – Recurrent laryngeal nerve; 27 – Trachea

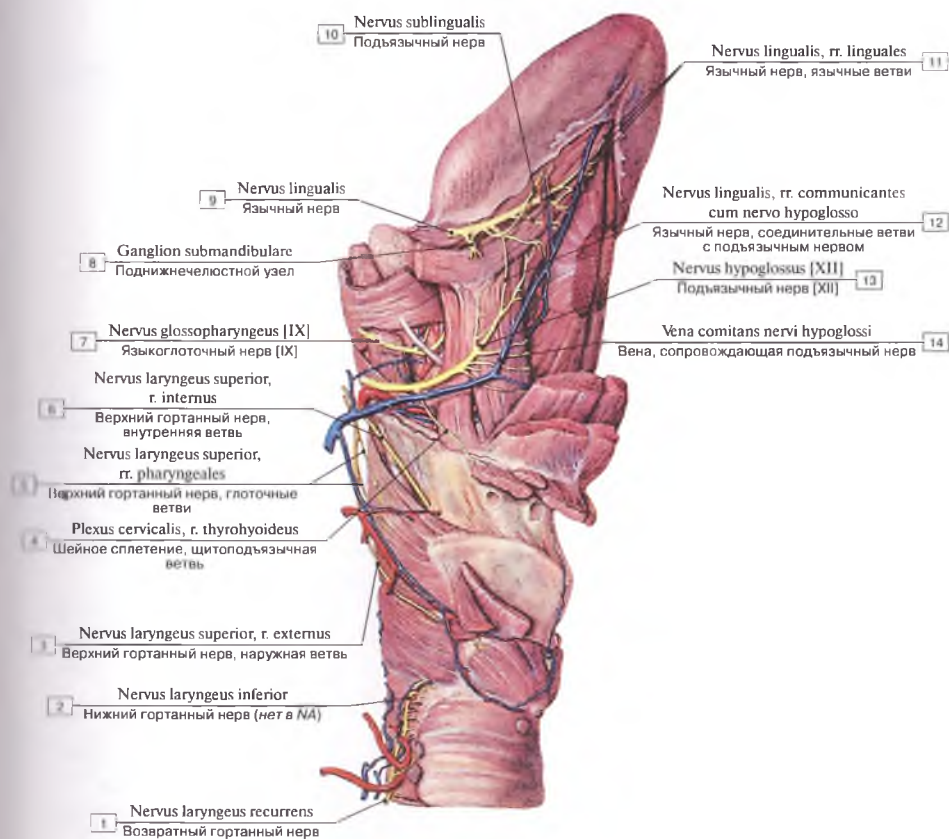


Рис. 219. Нервы языка, вид слева:

1 – Recurrent laryngeal nerve; 2 – Inferior laryngeal nerve; 3 – Superior laryngeal nerve, external branch; 4 – Cervical plexus, thyrohyoid branch; 5 – Superior laryngeal nerve, pharyngeal branches; 6 – Superior laryngeal nerve, internal branch; 7 – Glossopharyngeal nerve [IX]; 8 – Submandibular ganglion; 9 – Lingual nerve; 10 – Sublingual nerve; 11 – Lingual nerve, lingual branches; 12 – Lingual nerve, communicating branches with hypoglossal nerve; 13 – Hypoglossal nerve [XII]; 14 – Vena comitans of hypoglossal nerve

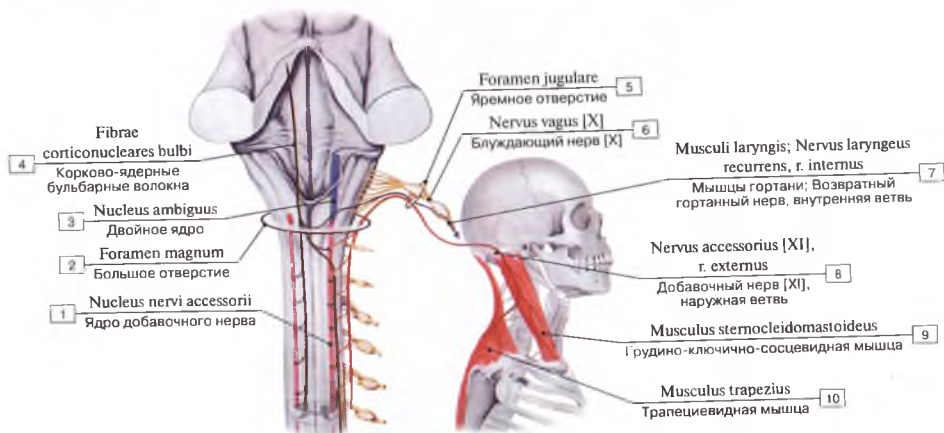


Рис. 223. Добавочный нерв (ядра и ход):

1 – Nucleus of accessory nerve; 2 – Foramen magnum; 3 – Nucleus ambiguus; 4 – Bulbar corticonuclear fibres; 5 – Jugular foramen; 6 – Vagus nerve [X]; 7 – Laryngeal muscles; Recurrent laryngeal nerve, internal branch; 8 – Accessory nerve [XI], external branch; 9 – Sternocleidomastoid; 10 – Trapezius

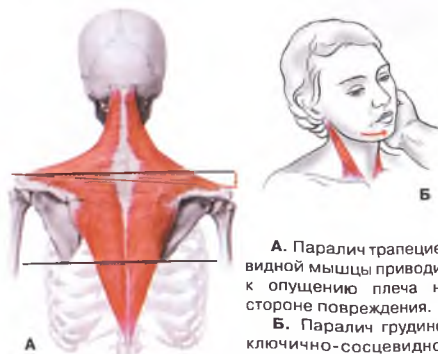


Рис. 224. Повреждения правого добавочного нерва (А – вид сзади; Б – вид справа спереди и сбоку)

А. Паралич трапециевидной мышцы приводит к опущению плеча на стороне повреждения.  
Б. Паралич грудно-ключично-сосцевидной мышцы приводит к невозможности повернуть голову в сторону, противоположную стороне повреждения.

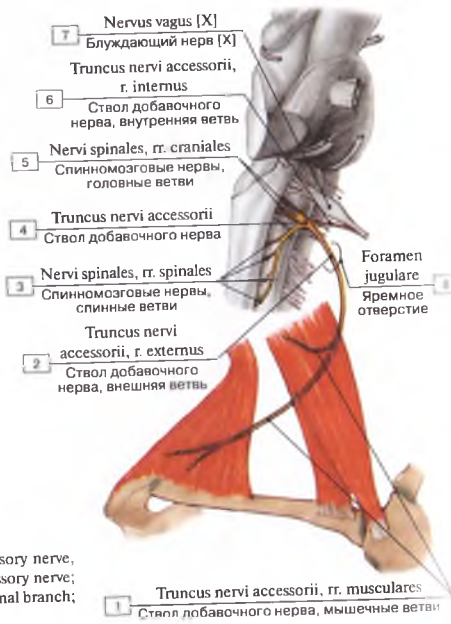

Рис. 225. Добавочный нерв:

1 – Trunk of accessory nerve, muscular branches; 2 – Trunk of accessory nerve, external branch; 3 – Spinal nerves, spinal branches; 4 – Trunk of accessory nerve; 5 – Spinal nerves, cranial branches; 6 – Trunk of accessory nerve, internal branch; 7 – Vagus nerve [X]; 8 – Jugular foramen

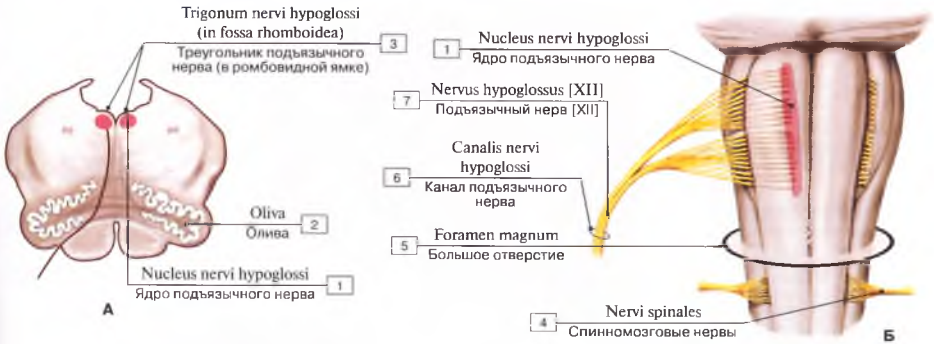


Рис. 226. Ядра подъязычного нерва (А – поперечный срез продолговатого мозга на уровне оливы; Б – продольный мозг, вид спереди):

1 – Nucleus of hypoglossal nerve; 2 – Inferior olive; 3 – Hypoglossal trigone; Trigonum of hypoglossal nerve (in rhomboid fossa; Floor of fourth ventricle); 4 – Spinal nerves; 5 – Foramen magnum; 6 – Hypoglossal canal; 7 – Hypoglossal nerve [XII]

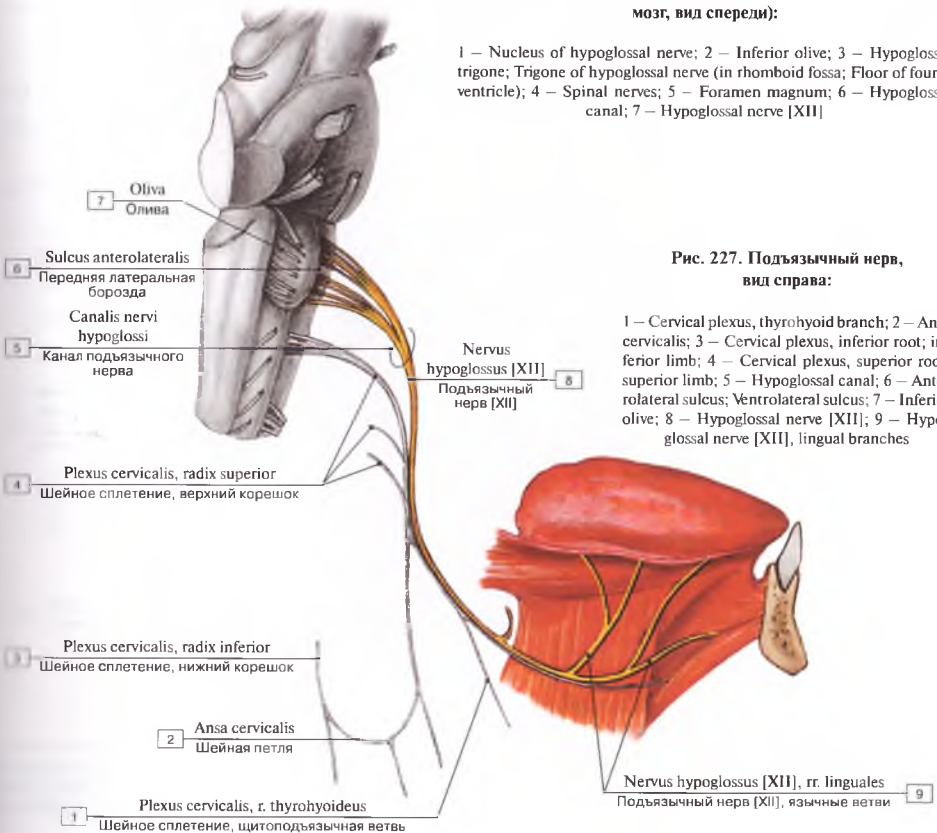


Рис. 227. Подъязычный нерв, вид справа:

1 – Cervical plexus, thyrothyoid branch; 2 – Ansa cervicalis; 3 – Cervical plexus, inferior root; inferior limb; 4 – Cervical plexus, superior root; superior limb; 5 – Hypoglossal canal; 6 – Anterolateral sulcus; Ventrolateral sulcus; 7 – Inferior olive; 8 – Hypoglossal nerve [XII]; 9 – Hypoglossal nerve [XII], lingual branches

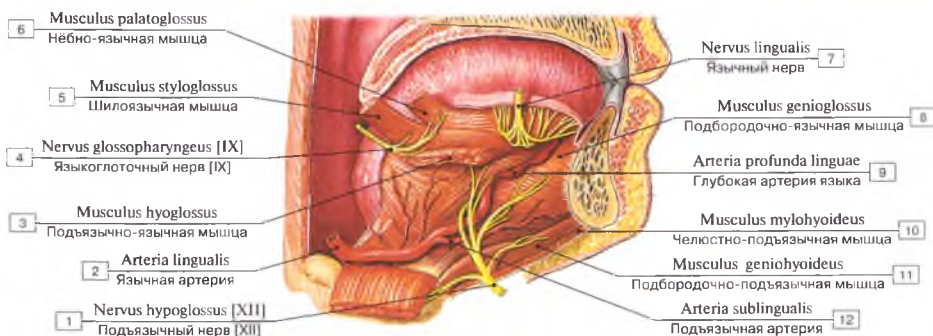


Рис. 228. Подъязычный нерв:

1 – Hypoglossal nerve [XII]; 2 – Lingual artery; 3 – Hyoglossus; 4 – Glossopharyngeal nerve [IX]; 5 – Styloglossus; 6 – Palatoglossus; 7 – Lingual nerve; 8 – Genioglossus; 9 – Deep lingual artery; 10 – Mylohyoid; 11 – Geniohyoid; 12 – Sublingual artery

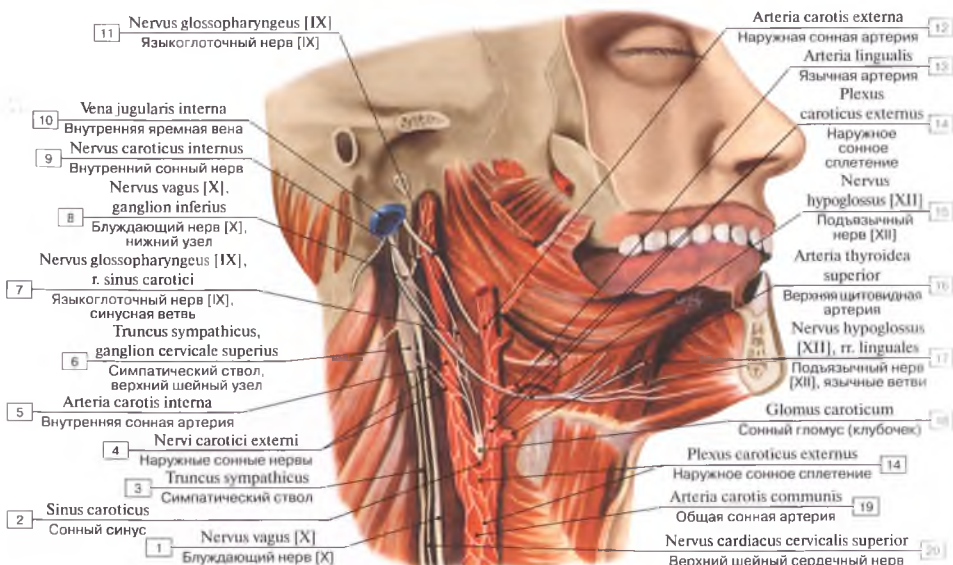


Рис. 229. Языкоглоточный и подъязычный нервы:

1 – Vagus nerve [X]; 2 – Carotid sinus; 3 – Sympathetic trunk; 4 – External carotid nerves; 5 – Internal carotid artery; 6 – Sympathetic trunk, superior cervical ganglion; 7 – Glossopharyngeal nerve [IX], carotid branch; 8 – Vagus nerve [X], inferior ganglion; 9 – Internal carotid nerve; 10 – Internal jugular vein; 11 – Glossopharyngeal nerve [IX]; 12 – External carotid artery; 13 – Lingual artery; 14 – External carotid plexus; 15 – Hypoglossal nerve [XII]; 16 – Superior thyroid artery; 17 – Hypoglossal nerve [XII], lingual branches; 18 – Carotid body; 19 – Common carotid artery; 20 – Superior cervical cardiac nerve

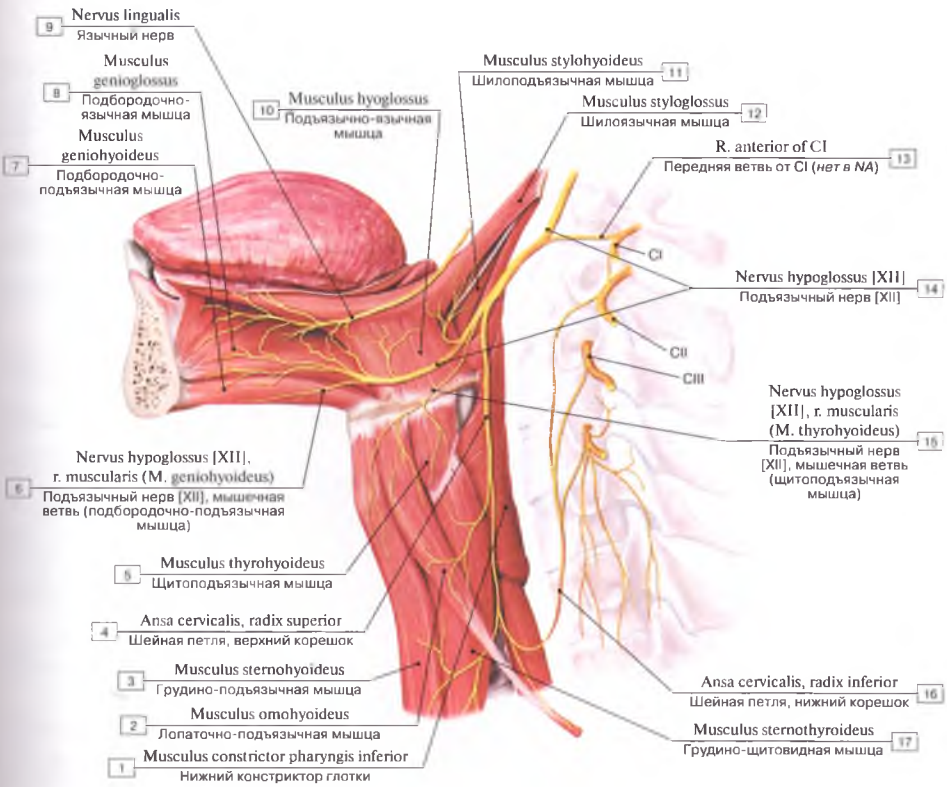


Рис. 230. Подъязычный нерв и шейная петля, вид сбоку слева:

1 – Inferior constrictor; 2 – Omohyoid; 3 – Sternohyoid; 4 – Ansa cervicalis, superior root; superior limb; 5 – Thyrohyoid; 6 – Hypoglossal nerve [XII], muscular branch (Geniohyoid); 7 – Geniohyoid; 8 – Genioglossus; 9 – Lingual nerve; 10 – Hyoglossus; 11 – Stylohyoid; 12 – Styloglossus; 13 – Anterior branch of CI; 14 – Hypoglossal nerve [XII]; 15 – Hypoglossal nerve [XII], muscular branch (Thyrohyoid); 16 – Ansa cervicalis, inferior root; inferior limb; 17 – Sternothyroid

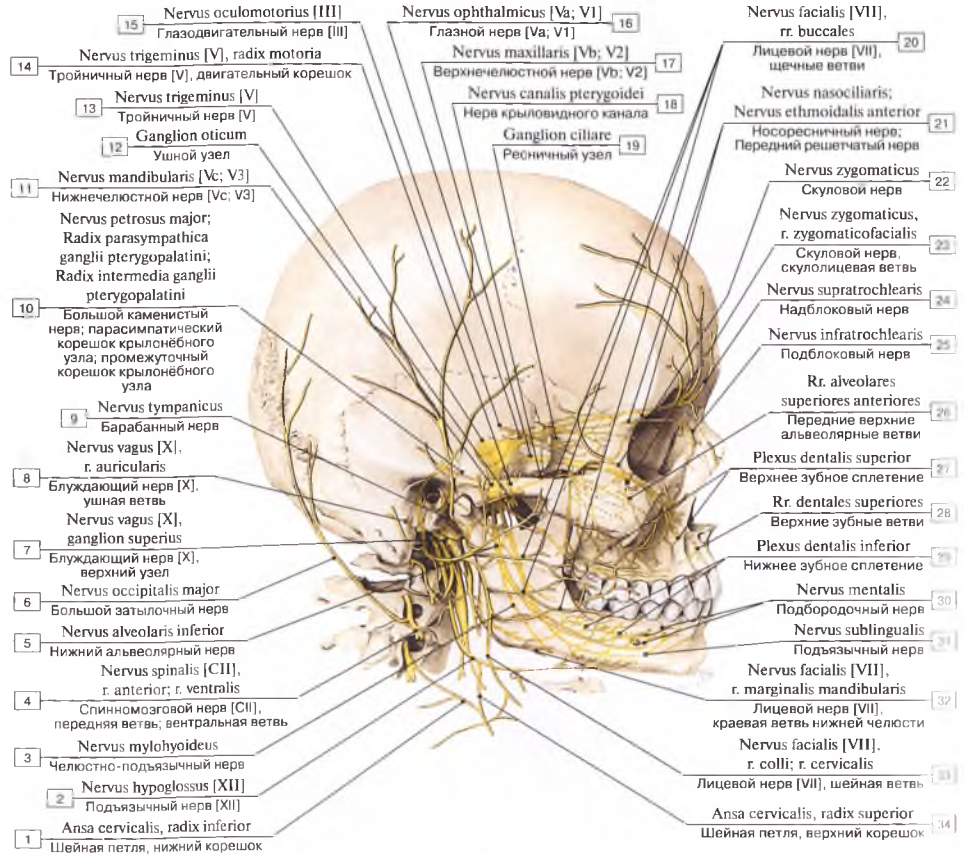
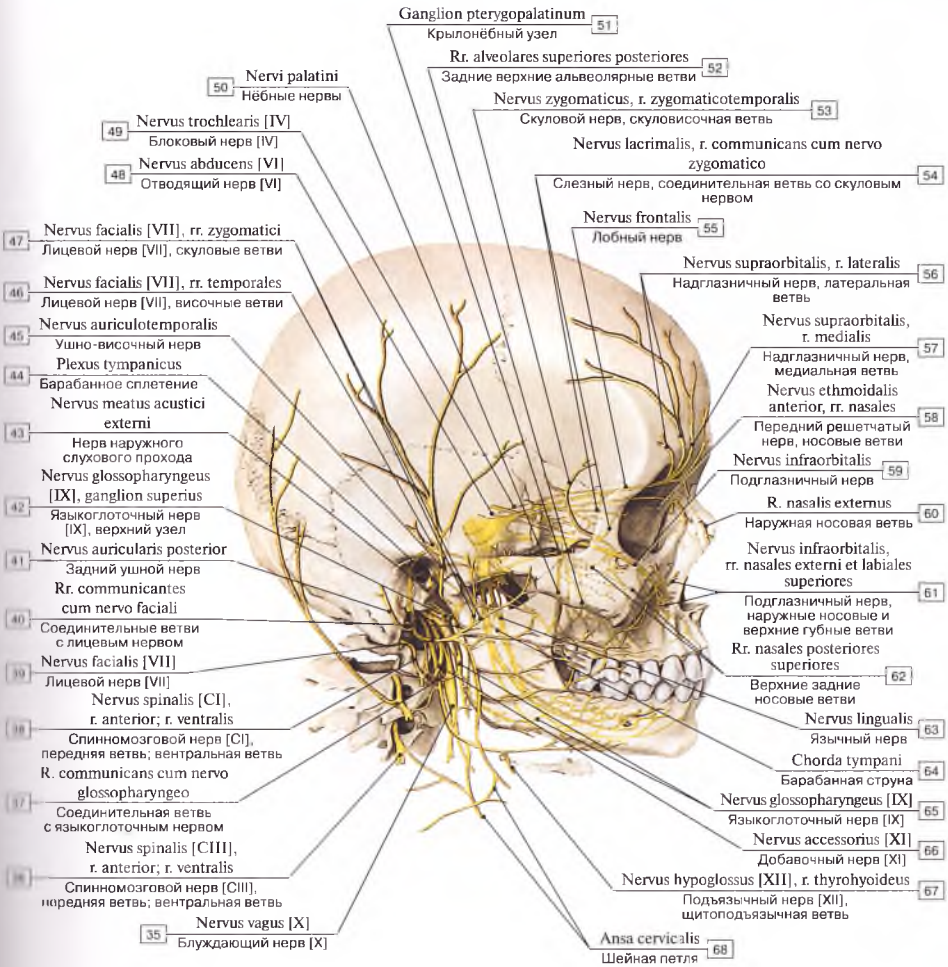


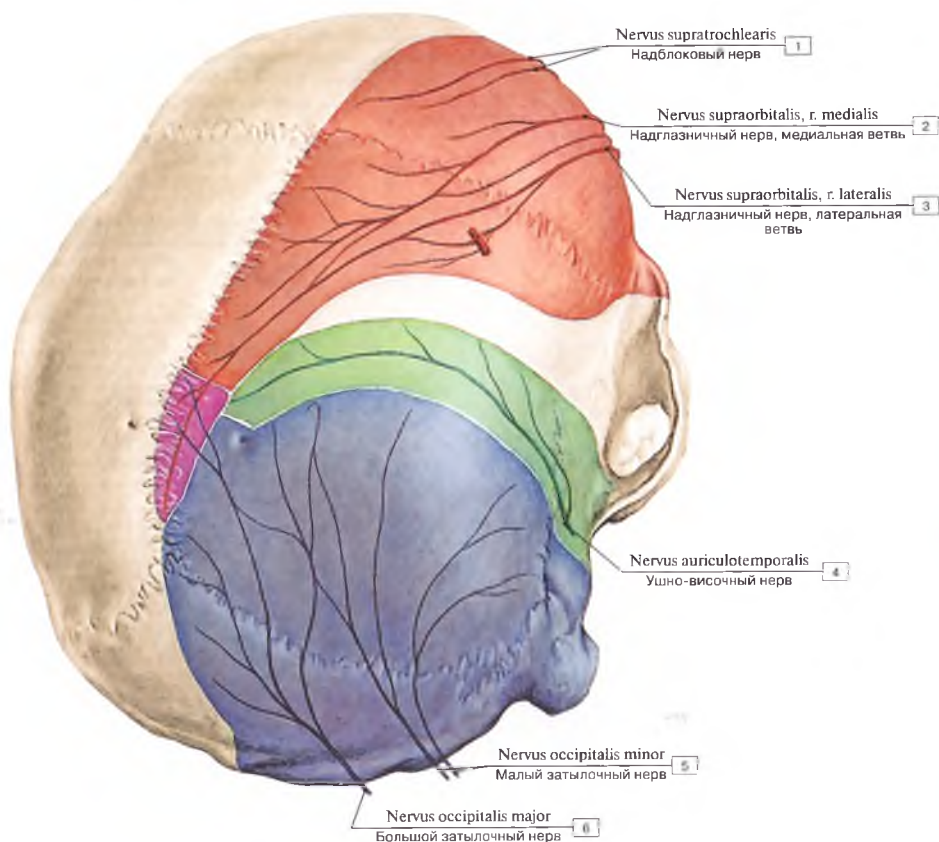
Рис. 231. Нервы головы:

1 – Ansa cervicalis, inferior root; inferior limb; 2 – Hypoglossal nerve [XII]; 3 – Nerve to mylohyoid; 4 – Spinal nerve [CII], anterior branch ventral branch; 5 – Inferior alveolar nerve; 6 – Greater occipital nerve; 7 – Vagus nerve [X], superior ganglion; 8 – Vagus nerve [X], auricular branch; 9 – Tympanic nerve; 10 – Greater petrosal nerve; Parasympathetic root of pterygopalatine ganglion; 11 – Mandibular nerve; Mandibular division [Vc; V3]; 12 – Otic ganglion; 13 – Trigeminal nerve [V]; 14 – Trigeminal nerve [V], motor root; 15 – Oculomotor nerve [III]; 16 – Ophthalmic nerve; Ophthalmic division [Va; V1]; 17 – Maxillary nerve; Maxillary division [Vb; V2]; 18 – Nerve of pterygoid canal; 19 – Ciliary ganglion; 20 – Facial nerve [VII], buccal branches; 21 – Nasociliary nerve; Anterior ethmoidal nerve; 22 – Zygomatic nerve; 23 – Zygomatic nerve, zygomaticofacial branch; 24 – Supratrochlear nerve; 25 – Infraorbital nerve; 26 – Anterior superior alveolar branches; 27 – Superior dental plexus; 28 – Superior dental branches; 29 – Inferior dental plexus; 30 – Mental nerve; 31 – Sublingual nerve;





32 – Facial nerve [VII], marginal mandibular branch; 33 – Facial nerve [VII], cervical branch; 34 – Ansa cervicalis, superior root; superior limb; 35 – Vagus nerve [X]; 36 – Spinal nerve [CIII], anterior branch; ventral branch; 37 – Communicating branch with glossopharyngeal nerve; 38 – Spinal nerve [CI], anterior branch; ventral branch; 39 – Facial nerve [VII]; 40 – Communicating branches with facial nerve; 41 – Posterior auricular nerve; 42 – Glossopharyngeal nerve [IX], superior ganglion; 43 – Nerve to external acoustic meatus; 44 – Tympanic plexus; 45 – Auriculotemporal nerve; 46 – Facial nerve [VII], temporal branches; 47 – Facial nerve [VII], zygomatic branches; 48 – Abducens nerve [VI]; 49 – Trochlear nerve [IV]; 50 – Palatine nerves; 51 – Pterygopalatine ganglion; 52 – Posterior superior alveolar branches; 53 – Zygomatic nerve, zygomaticotemporal branch; 54 – Lacrimal nerve, communicating branch with zygomatic nerve; 55 – Frontal nerve; 56 – Supra-orbital nerve, lateral branch; 57 – Supra-orbital nerve, medial branch; 58 – Anterior ethmoidal nerve, nasal branches; 59 – Infra-orbital nerve; 60 – External nasal branch; 61 – Infra-orbital nerve, external and internal nasal branches; 62 – Posterior superior nasal branches; 63 – Lingual nerve; 64 – Chorda tympani; 65 – Glossopharyngeal nerve [IX]; 66 – Accessory nerve [XI]; 67 – Hypoglossal nerve [XII], thyrohyoid branch; 68 – Ansa cervicalis



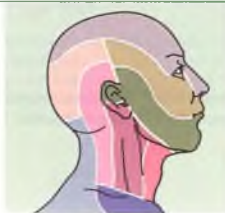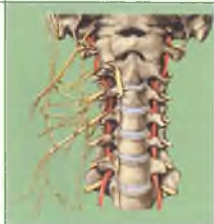
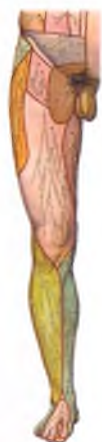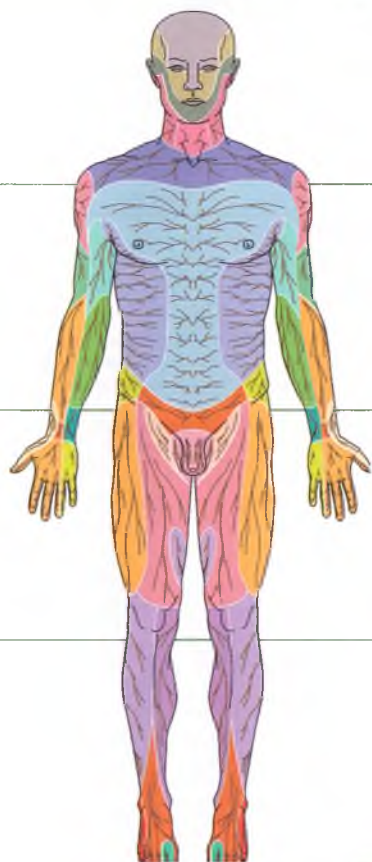
- область, иннервируемая глазным нервом (ветвь тройничного)
- область, иннервируемая верхнечелюстным нервом
- область, иннервируемая нижнечелюстным нервом
- область, иннервируемая вторым шейным сегментом (С.М.Н.)
- область иннервации обоими нервами: глазным и вторым шейным сегментом

Рис. 232. Чувствительная иннервация скальпа крыши черепа:

- 1 – Supratrochlear nerve; 2 – Supra-orbital nerve, medial branch; 3 – Supra-orbital nerve, lateral branch; 4 – Auriculotemporal nerve;  
5 – Lesser occipital nerve; 6 – Greater occipital nerve

# ПЕРИФЕРИЧЕСКАЯ НЕРВНАЯ СИСТЕМА

## Спинномозговые нервы



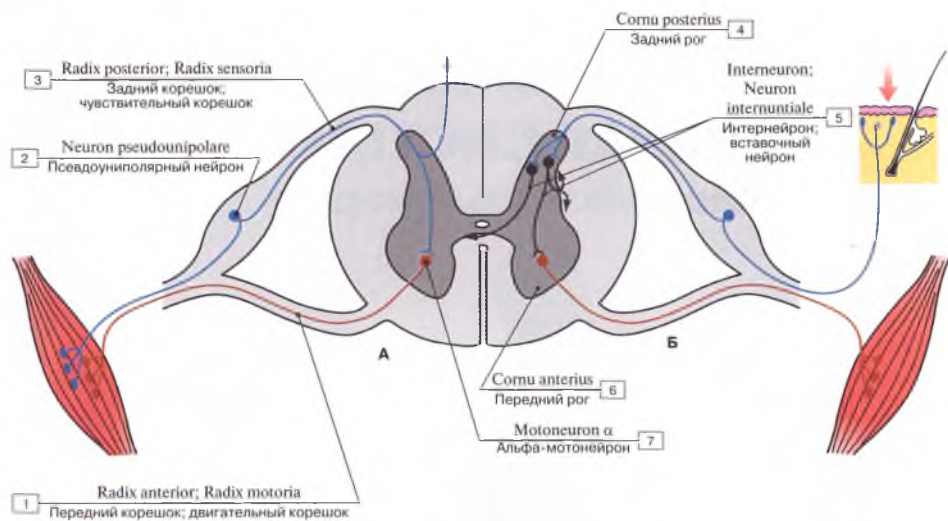


Рис. 233. Рефлекторная дуга соматического рефлекса (А – моносинаптическая; Б – полисинаптическая) (афферентные нервы показаны синим цветом, эфферентные нервы – красным, черным цветом показаны нейроны спинного рефлекса цепи) (схема):

1 – Anterior root; Motor root; Ventral root; 2 – Pseudounipolar cell body in spinal ganglion; 3 – Posterior root; Sensory root; Dorsal root; 4 – Posterior horn; Dorsal horn; 5 – Interneuron; Internuncial neuron; 6 – Anterior horn; Ventral horn; 7 – Alpha motor neuron

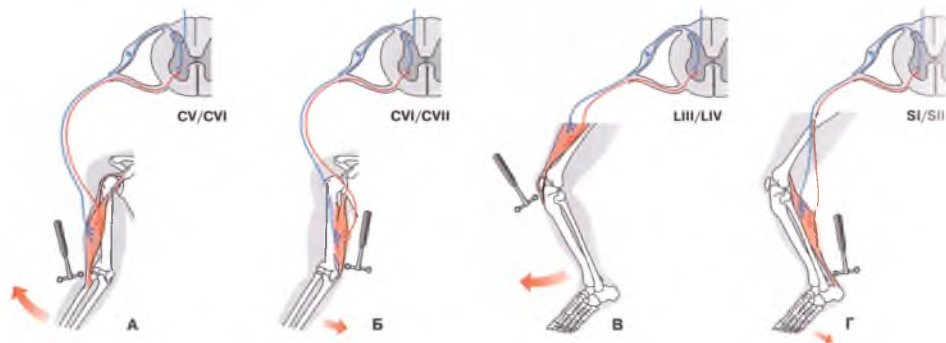


Рис. 234. Клинически важные моносинаптические рефлексы (схема) (А – сгибательный рефлекс предплечья; Б – разгибательный рефлекс предплечья; В – коленный рефлекс (четырёхглавый рефлекс); Г – ахиллов рефлекс)

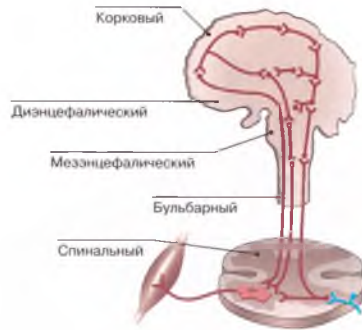

Рис. 235. Уровни полисинаптической рефлексорной дуги

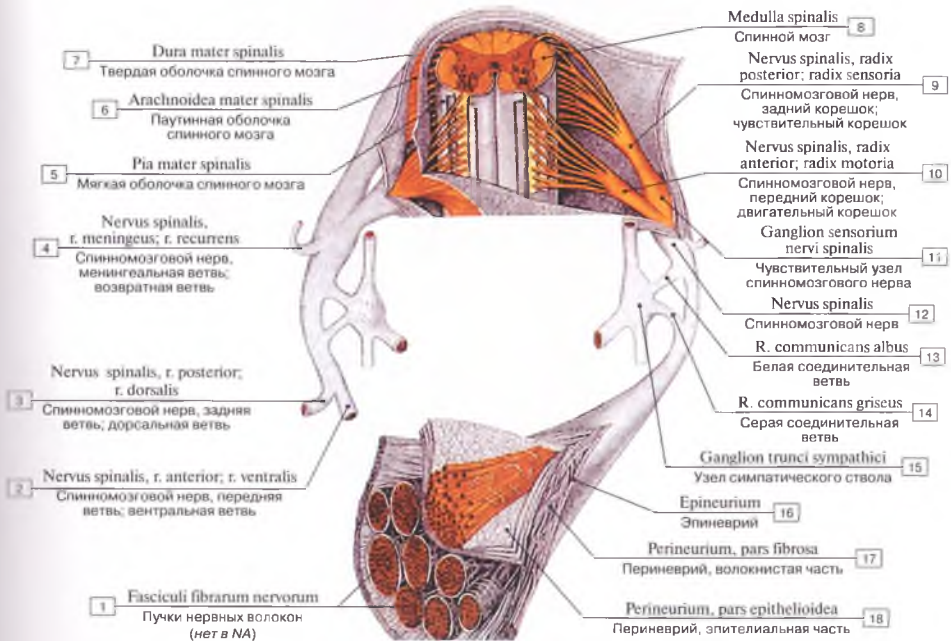


Рис. 236. Спинномозговой нерв:

1 - Fascicles of neurofibres; 2 - Spinal nerve, anterior branch; ventral branch; 3 - Spinal nerve, posterior branch; dorsal branch; 4 - Spinal nerve, meningeal branch; recurrent branch; 5 - Spinal pia mater; 6 - Spinal arachnoid mater; 7 - Spinal dura mater; 8 - Spinal cord; 9 - Spinal nerve, posterior root; sensory root; dorsal root; 10 - Spinal nerve, anterior root; motor root; ventral root; 11 - Spinal ganglion; Dorsal root ganglion; 12 - Spinal nerve; 13 - White communicating branch; 14 - Grey communicating branch; 15 - Ganglion of sympathetic trunk; 16 - Epineurium; 17 - Perineurium, fibrous part; 18 - Perineurium, epithelioid part

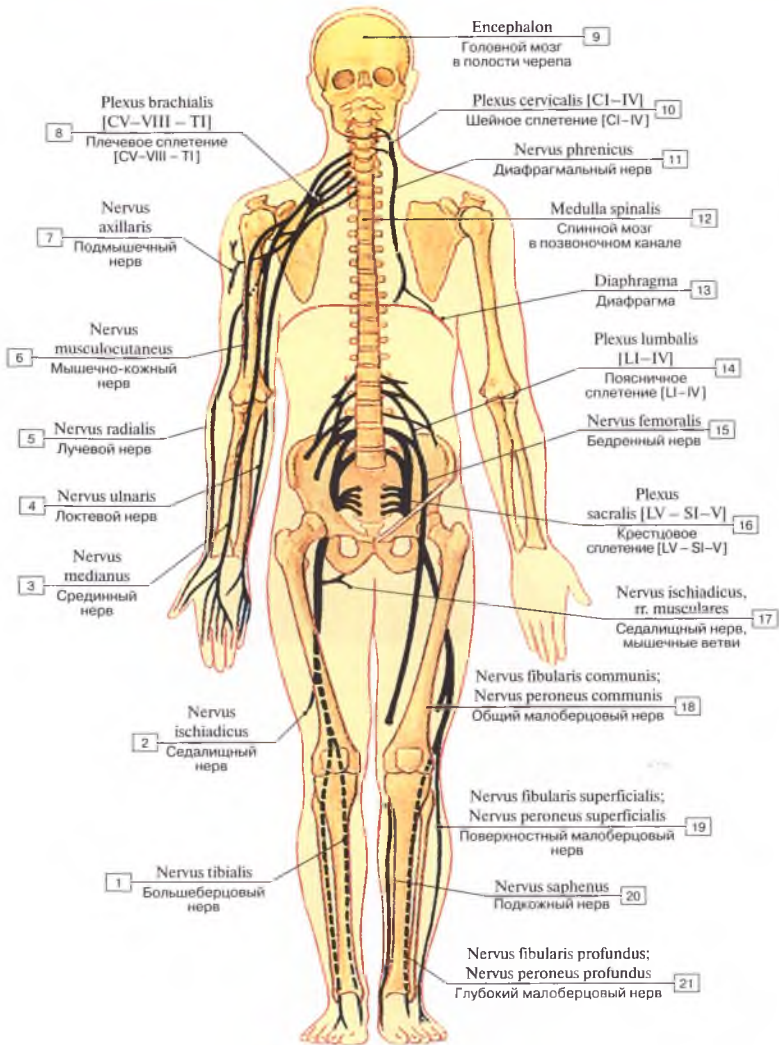


Рис. 237. Передние ветви спинномозговых нервов (сплетения) (схема):

1 - Tibial nerve; 2 - Sciatic nerve; 3 - Median nerve; 4 - Ulnar nerve; 5 - Radial nerve; 6 - Musculocutaneous nerve; 7 - Axillary nerve; 8 - Brachial plexus [CV-VIII - T1]; 9 - Brain; 10 - Cervical plexus [C1-IV]; 11 - Phrenic nerve; 12 - Spinal cord; 13 - Diaphragm; 14 - Lumbar plexus [L1-IV]; 15 - Femoral nerve; 16 - Sacral plexus [LV-SI-V]; 17 - Sciatic nerve, muscular branches; 18 - Common fibular nerve; Common peroneal nerve; 19 - Superficial fibular nerve; Superficial peroneal nerve; 20 - Saphenous nerve; 21 - Deep fibular nerve; Deep peroneal nerve

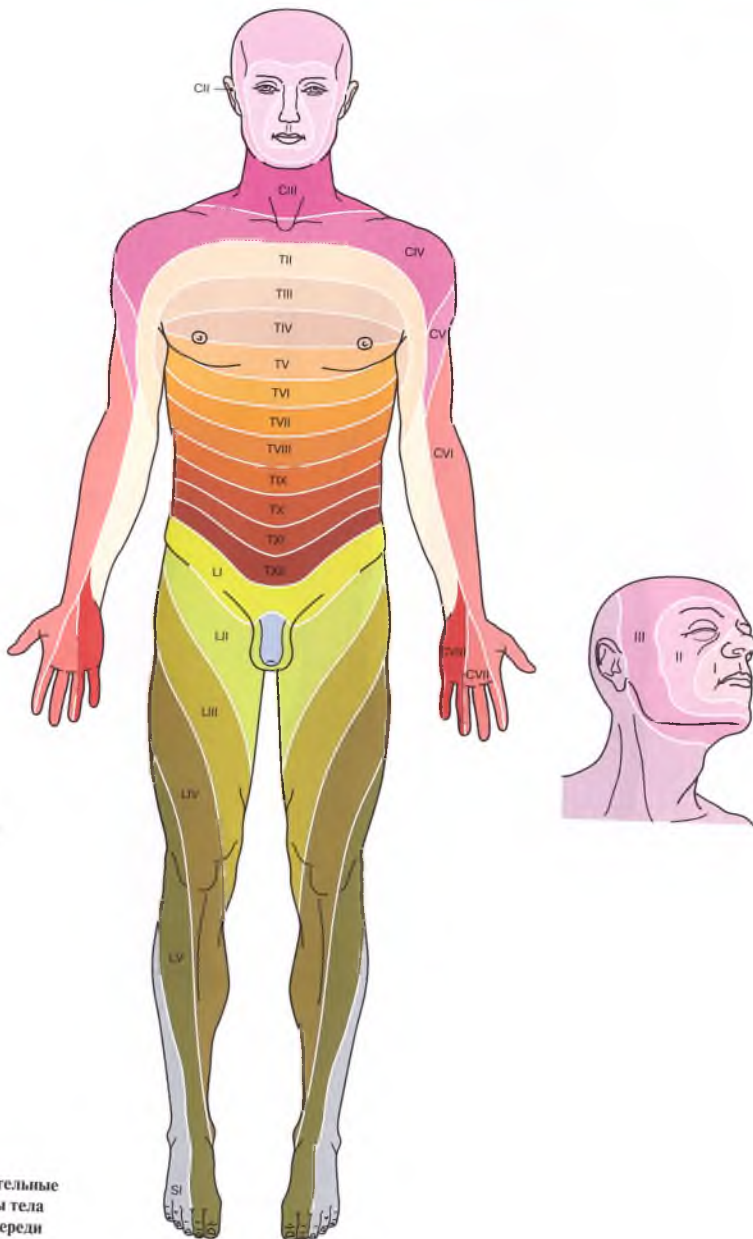


Рис. 238. Чувствительные корешковые зоны тела мужчины, вид спереди

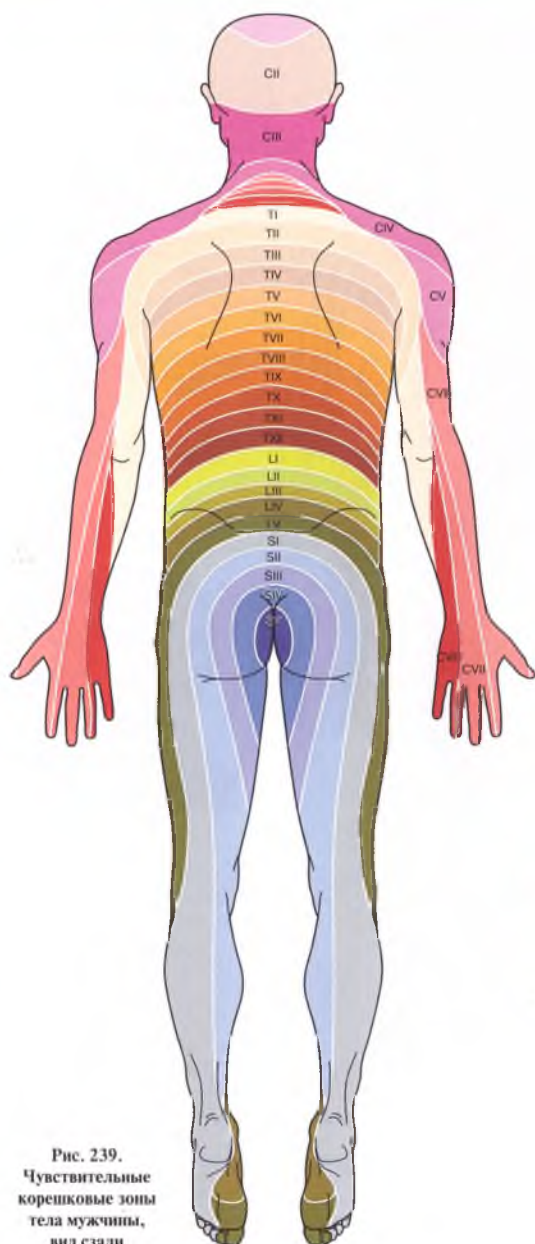


Рис. 239.  
Чувствительные  
корешковые зоны  
тела мужчины,  
вид сзади

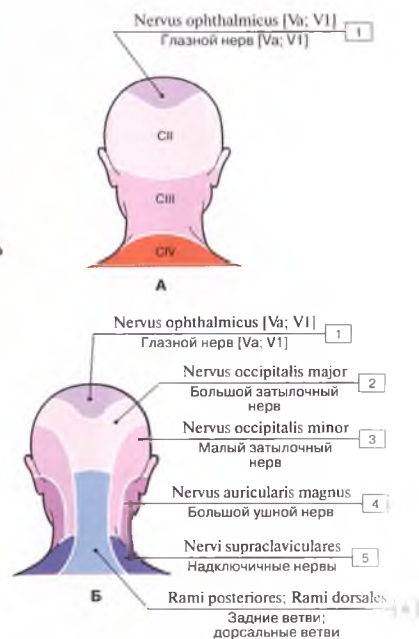


Рис. 240. Чувствительная иннервация задней  
поверхности головы и шеи  
(А – области иннервации; Б – нервы):

- 1 – Ophthalmic nerve; Ophthalmic division [Va; VI]  
2 – Greater occipital nerve; 3 – Lesser occipital nerve  
4 – Great auricular nerve; 5 – Supraclavicular nerves  
6 – Posterior branches; Dorsal branches



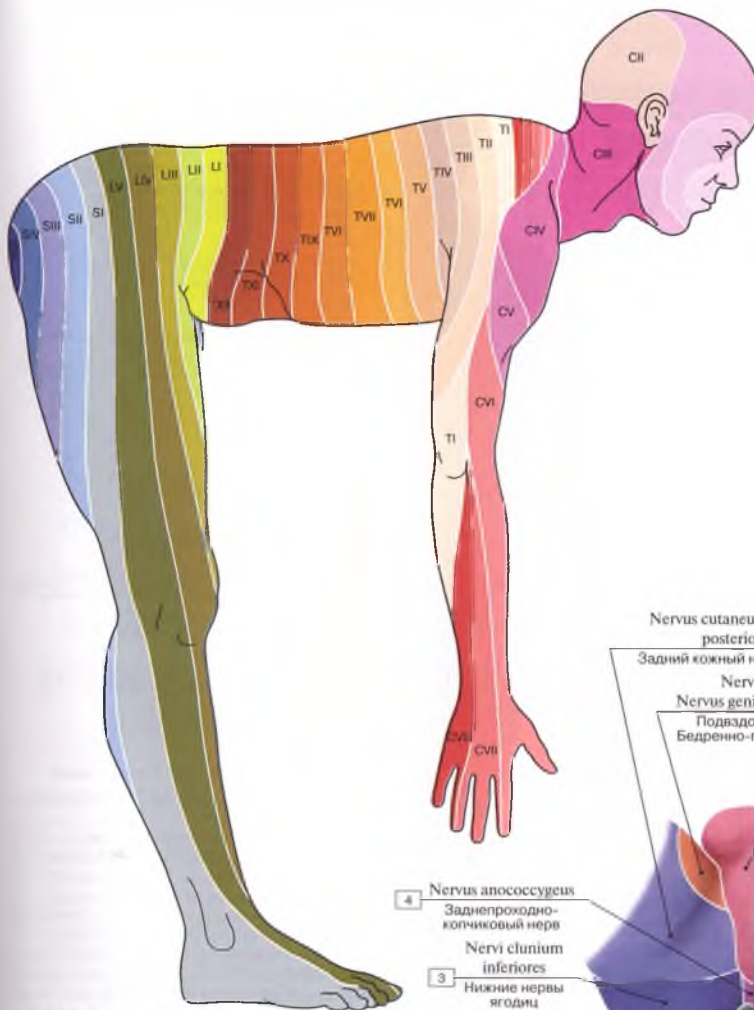


Рис. 241. Чувствительные корешковые зоны тела мужчины, вид сбоку, справа

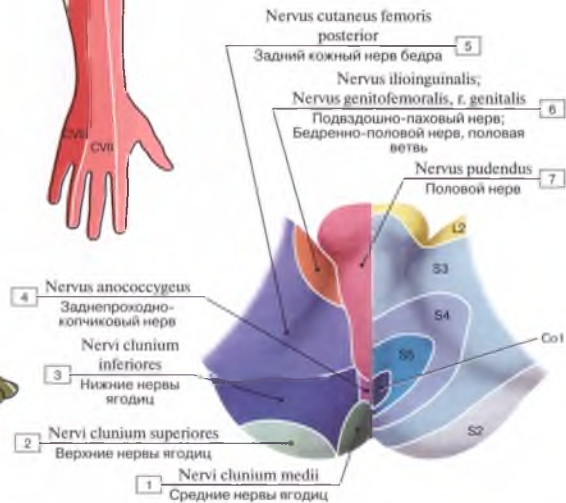
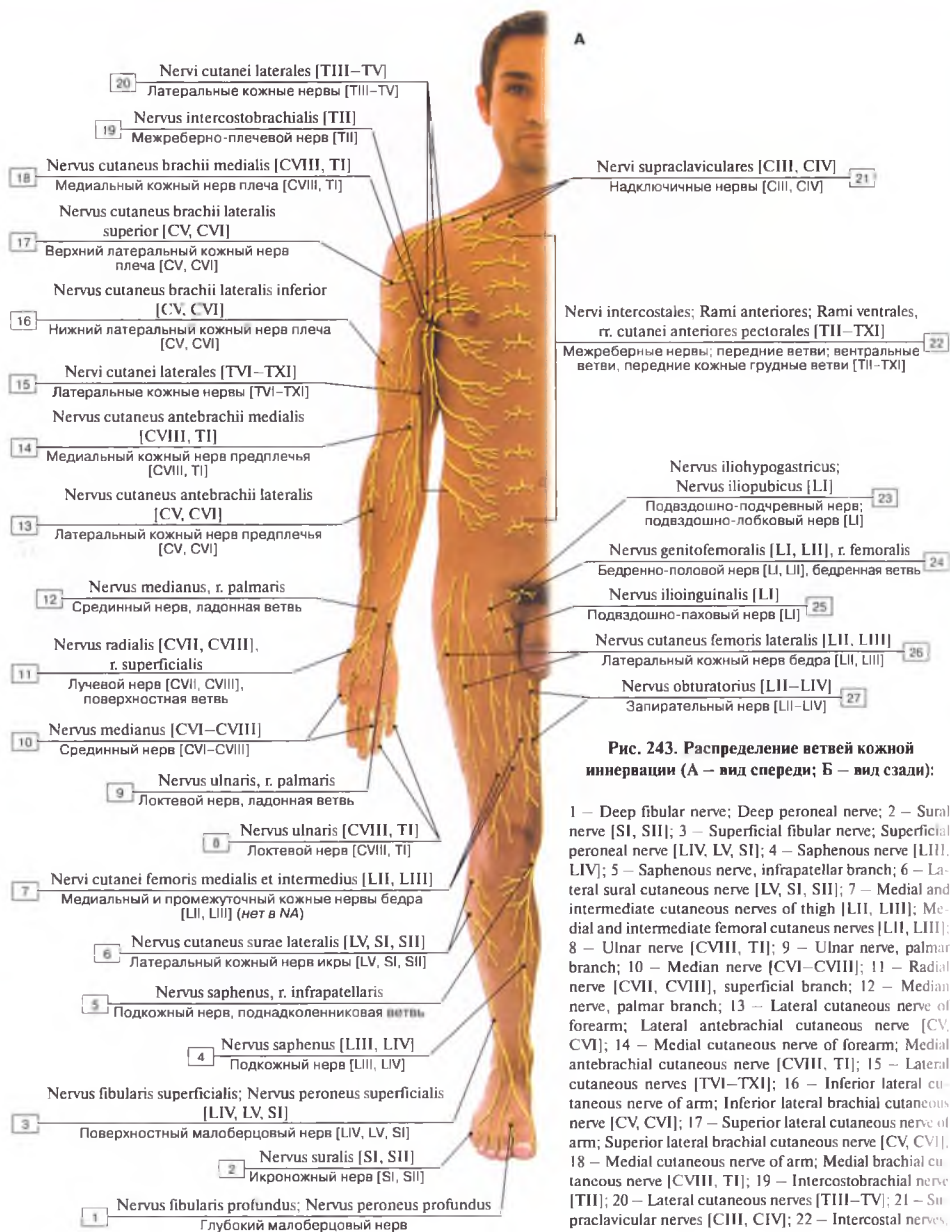


Рис. 242. Сегментарная и периферическая иннервация промежности мужчины:

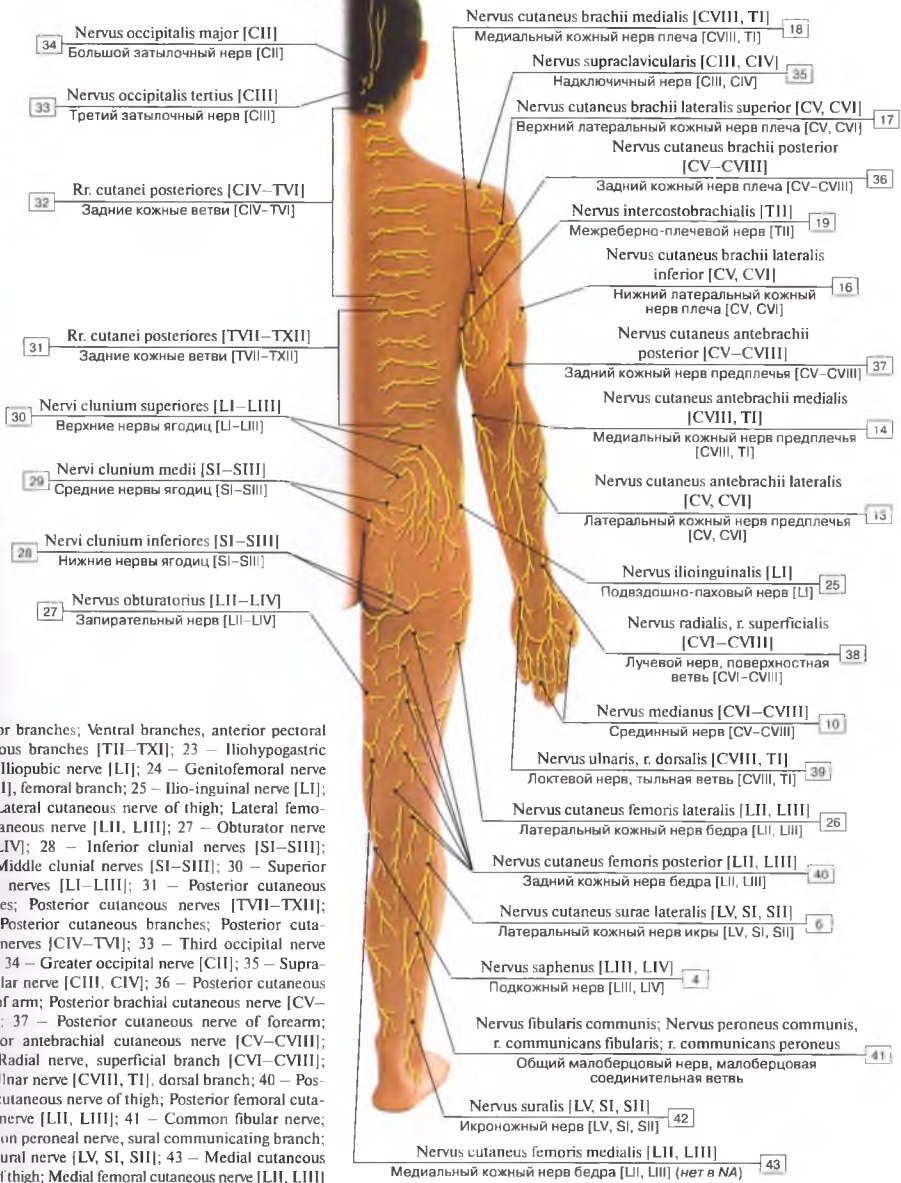
- 1 – Medial clunial nerves; 2 – Superior clunial nerves; 3 – Inferior clunial nerves;
- 4 – Anococcygeal nerve; 5 – Posterior cutaneous nerve of thigh; Posterior femoral cutaneous nerve;
- 6 – Ilio-inguinal nerve; Genitofemoral nerve, genital branch;
- 7 – Pudendal nerve



**Рис. 243. Распределение ветвей кожной иннервации (А – вид спереди; Б – вид сзади):**

1 – Deep fibular nerve; Deep peroneal nerve; 2 – Sural nerve [SI, SII]; 3 – Superficial fibular nerve; Superficial peroneal nerve [LIV, LV, SI]; 4 – Saphenous nerve [LIII, LIV]; 5 – Saphenous nerve, infrapatellar branch; 6 – Lateral sural cutaneous nerve [LV, SI, SII]; 7 – Medial and intermediate cutaneous nerves of thigh [LII, LIII]; Medial and intermediate femoral cutaneous nerves [LII, LIII]; 8 – Ulnar nerve [CVIII, TI]; 9 – Ulnar nerve, palmar branch; 10 – Median nerve [CVI–CVIII]; 11 – Radial nerve [CVII, CVIII], superficial branch; 12 – Median nerve, palmar branch; 13 – Lateral cutaneous nerve of forearm; Lateral antebrachial cutaneous nerve [CV, CVI]; 14 – Medial cutaneous nerve of forearm; Medial antebrachial cutaneous nerve [CVIII, TI]; 15 – Lateral cutaneous nerves [TVI–TXI]; 16 – Inferior lateral cutaneous nerve of arm; Inferior lateral brachial cutaneous nerve [CV, CVI]; 17 – Superior lateral cutaneous nerve of arm; Superior lateral brachial cutaneous nerve [CV, CVI]; 18 – Medial cutaneous nerve of arm; Medial brachial cutaneous nerve [CVIII, TI]; 19 – Intercostobrachial nerve [TII]; 20 – Lateral cutaneous nerves [TIII–TV]; 21 – Supraclavicular nerves [CIII, CIV]; 22 – Intercostal nerves;

Б



Anterior branches; Ventral branches, anterior pectoral cutaneous branches [TII–TXII]; 23 – Iliohypogastric nerve; Iliopubic nerve [LI]; 24 – Genitofemoral nerve [LI, LII], femoral branch; 25 – Ilio-inguinal nerve [LI]; 26 – Lateral cutaneous nerve of thigh; Lateral femoral cutaneous nerve [LII, LIII]; 27 – Obturator nerve [LII–LIV]; 28 – Inferior clunial nerves [SI–SIII]; 29 – Middle clunial nerves [SI–SIII]; 30 – Superior clunial nerves [LI–LIII]; 31 – Posterior cutaneous branches; Posterior cutaneous nerves [TVII–TXII]; 32 – Posterior cutaneous branches; Posterior cutaneous nerves [CIV–TVI]; 33 – Third occipital nerve [CIII]; 34 – Greater occipital nerve [CII]; 35 – Supraclavicular nerve [CIII, CIV]; 36 – Posterior cutaneous nerve of arm; Posterior brachial cutaneous nerve [CV–CVIII]; 37 – Posterior cutaneous nerve of forearm; Posterior antebrachial cutaneous nerve [CV–CVIII]; 38 – Radial nerve, superficial branch [CVI–CVIII]; 39 – Ulnar nerve [CVIII, TI], dorsal branch; 40 – Posterior cutaneous nerve of thigh; Posterior femoral cutaneous nerve [LII, LIII]; 41 – Common fibular nerve; Common peroneal nerve, sural communicating branch; 42 – Sural nerve [LV, SI, SII]; 43 – Medial cutaneous nerve of thigh; Medial femoral cutaneous nerve [LII, LIII]

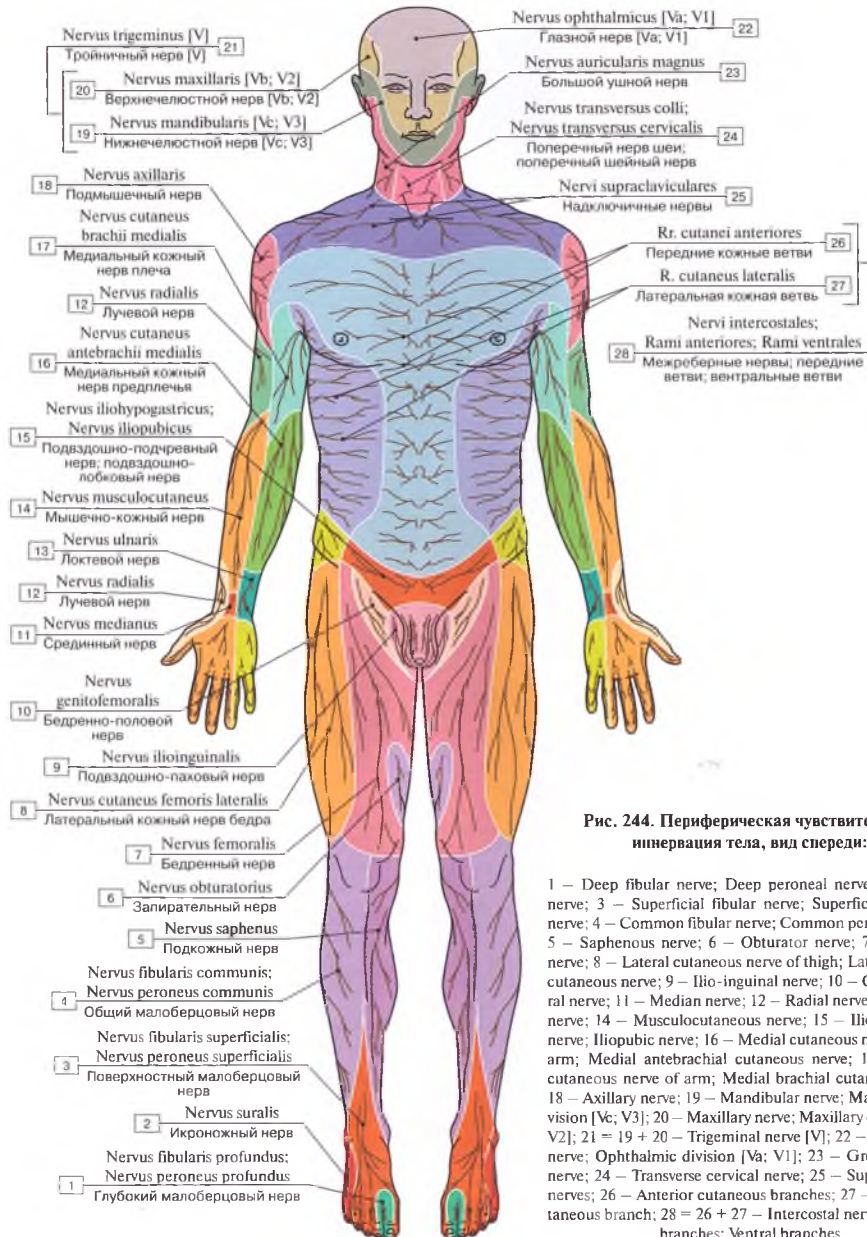
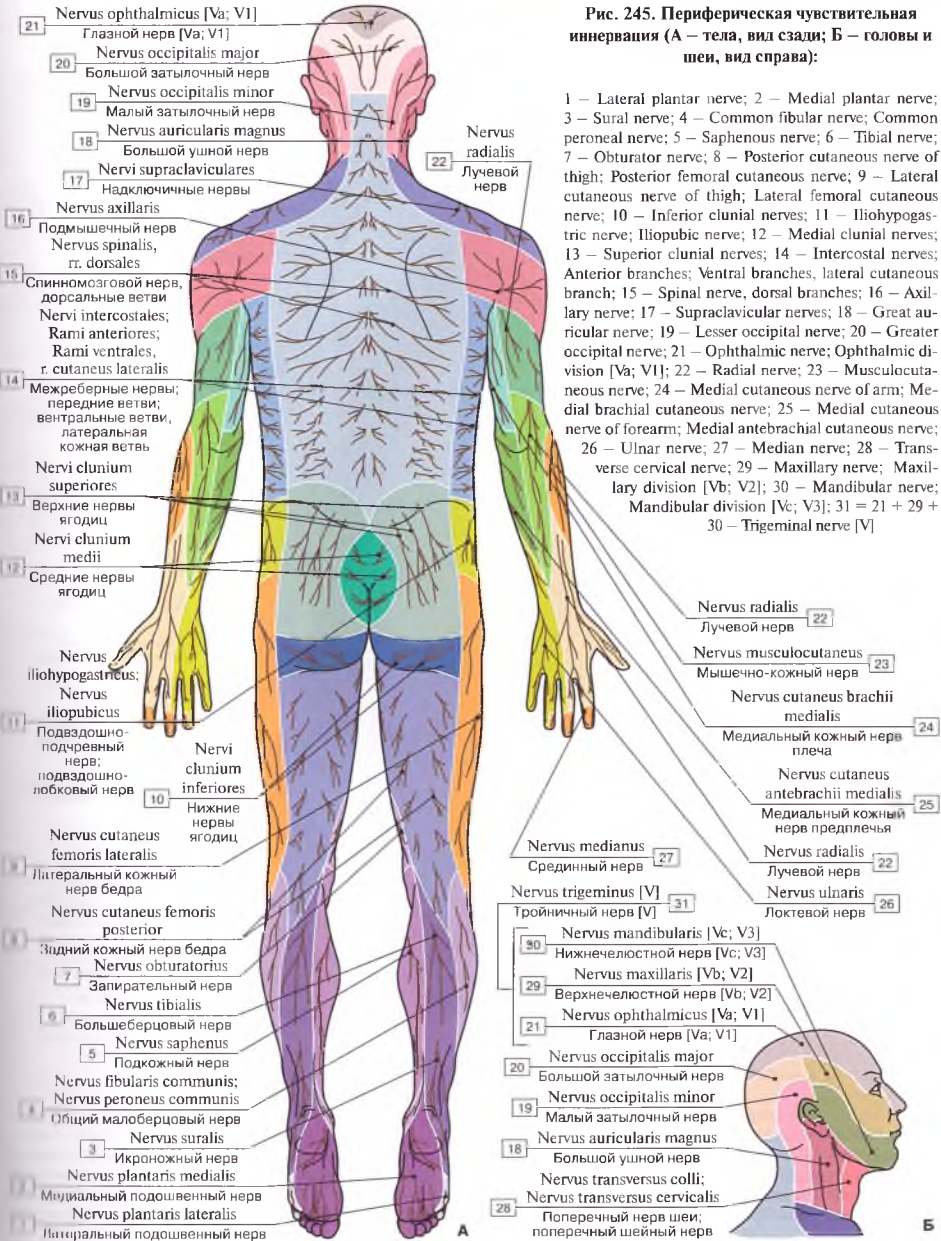


Рис. 244. Периферическая чувствительная иннервация тела, вид спереди:

1 — Deep fibular nerve; Deep peroneal nerve; 2 — Sural nerve; 3 — Superficial fibular nerve; Superficial peroneal nerve; 4 — Common fibular nerve; Common peroneal nerve; 5 — Saphenous nerve; 6 — Obturator nerve; 7 — Femoral nerve; 8 — Lateral cutaneous nerve of thigh; Lateral femoral cutaneous nerve; 9 — Ilio-inguinal nerve; 10 — Genitofemoral nerve; 11 — Median nerve; 12 — Radial nerve; 13 — Ulnar nerve; 14 — Musculocutaneous nerve; 15 — Iliohypogastric nerve; Iliopubic nerve; 16 — Medial cutaneous nerve of forearm; Medial antebrachial cutaneous nerve; 17 — Medial cutaneous nerve of arm; Medial brachial cutaneous nerve; 18 — Axillary nerve; 19 — Mandibular nerve; Mandibular division [Vc; V3]; 20 — Maxillary nerve; Maxillary division [Vb; V2]; 21 = 19 + 20 — Trigeminal nerve [V]; 22 — Ophthalmic nerve; Ophthalmic division [Va; V1]; 23 — Great auricular nerve; 24 — Transverse cervical nerve; 25 — Supraclavicular nerves; 26 — Anterior cutaneous branches; 27 — Lateral cutaneous branch; 28 = 26 + 27 — Intercostal nerves; Anterior branches; Ventral branches



1 – Lateral plantar nerve; 2 – Medial plantar nerve; 3 – Sural nerve; 4 – Common fibular nerve; Common peroneal nerve; 5 – Saphenous nerve; 6 – Tibial nerve; 7 – Obturator nerve; 8 – Posterior cutaneous nerve of thigh; 9 – Lateral cutaneous nerve of thigh; Lateral femoral cutaneous nerve; 10 – Inferior clunial nerves; 11 – Iliohypogastric nerve; Iliopubic nerve; 12 – Medial clunial nerves; 13 – Superior clunial nerves; 14 – Intercostal nerves; Anterior branches; Ventral branches; lateral cutaneous branch; 15 – Spinal nerve, dorsal branches; 16 – Axillary nerve; 17 – Supraclavicular nerves; 18 – Great auricular nerve; 19 – Lesser occipital nerve; 20 – Greater occipital nerve; 21 – Ophthalmic nerve; Ophthalmic division [Va; V1]; 22 – Radial nerve; 23 – Musculocutaneous nerve; 24 – Medial cutaneous nerve of arm; Medial brachial cutaneous nerve; 25 – Medial cutaneous nerve of forearm; Medial antebrachial cutaneous nerve; 26 – Ulnar nerve; 27 – Median nerve; 28 – Transverse cervical nerve; 29 – Maxillary nerve; Maxillary division [Vb; V2]; 30 – Mandibular nerve; Mandibular division [Vc; V3]; 31 = 21 + 29 + 30 – Trigeminal nerve [V]

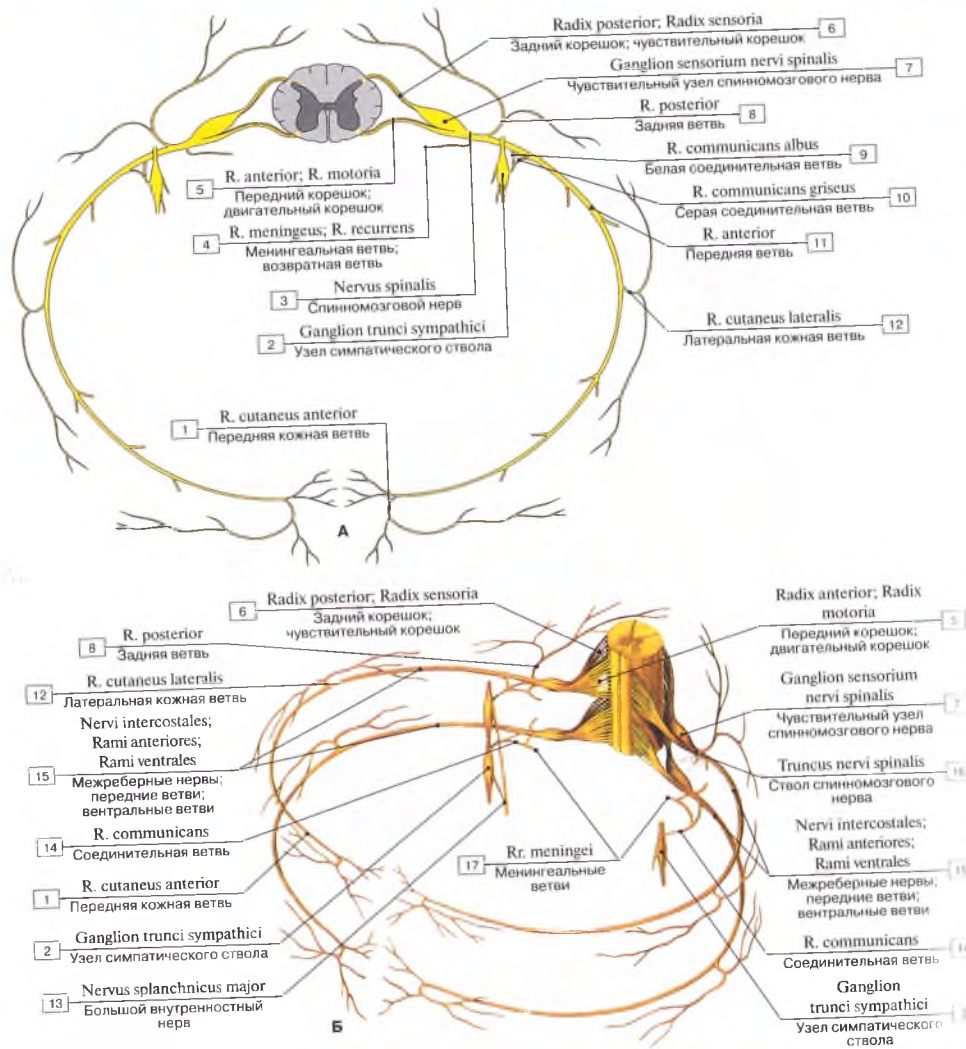


Рис. 246. Формирование спинномозгового нерва  
(А – сегмент спинного мозга; Б – реконструкция двух сегментов спинного мозга) (схема):

1 – Anterior cutaneous branch; 2 – Ganglion of sympathetic trunk; 3 – Spinal nerve; 4 – Meningeal branch; Recurrent branch; 5 – Anterior root; Motor root; Ventral root; 6 – Posterior root; Sensory root; Dorsal root; 7 – Spinal ganglion; Dorsal root ganglion; 8 – Posterior branch root; 9 – White communicating branch; 10 – Grey communicating branch; 11 – Anterior branch; 12 – Lateral cutaneous branch; 13 – Greater splanchnic nerve; 14 – Communicating branch; 15 – Intercostal nerves; Anterior branches; Ventral branches; 16 – Trunk of spinal nerve; 17 – Meningeal branches

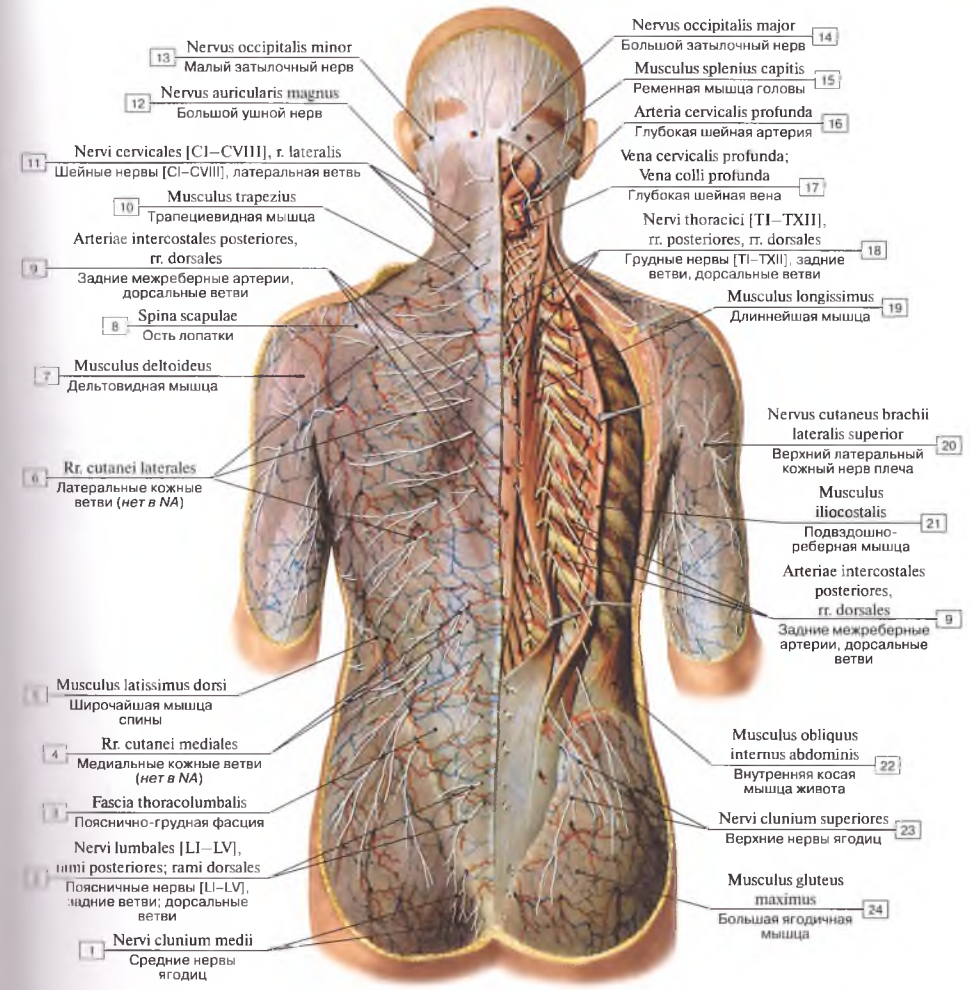


Рис. 247. Распределение задних ветвей спинномозговых нервов в области спины и затылка  
(слева показаны кожные ветви, справа – мышечные ветви):

1 – Middle clunial nerves; 2 – Lumbar nerves [LI–LV], posterior branches; dorsal branches; 3 – Thoracolumbar fascia; 4 – Medial cutaneous branches; 5 – Latissimus dorsi; 6 – Lateral cutaneous branches; 7 – Deltoid; 8 – Spine of scapula; 9 – Posterior intercostal arteries, dorsal branches; 10 – Trapezius; 11 – Cervical nerves [CI–CVIII], lateral branch; 12 – Great auricular nerve; 13 – Lesser occipital nerve; 14 – Greater occipital nerve; 15 – Splenius capitis; 16 – Deep cervical artery; 17 – Deep cervical vein; 18 – Thoracic nerves [TI–TXII], posterior branches; dorsal branches; 19 – Longissimus; 20 – Superior lateral cutaneous nerve of arm; Superior lateral brachial cutaneous nerve; 21 – Iliocostalis; 22 – Internal oblique; 23 – Superior clunial nerves; 24 – Gluteus maximus

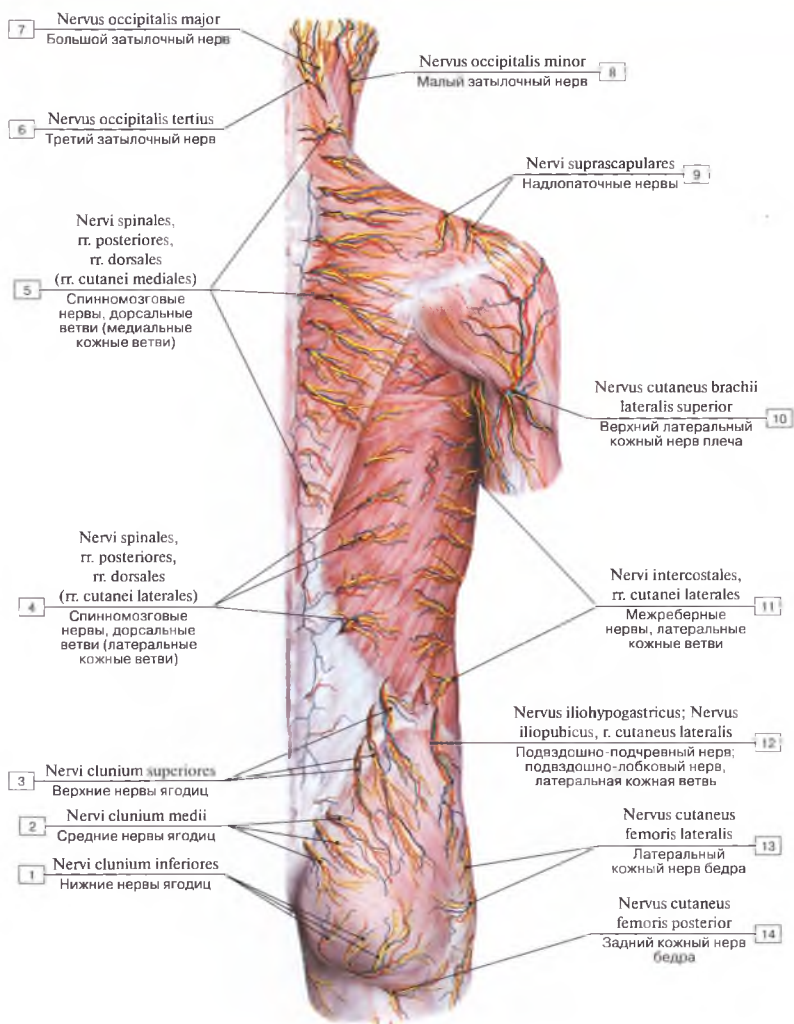


Рис. 248. Поверхностные нервы и сосуды туловища, вид сзади:

1 – Inferior clunial nerves; 2 – Middle clunial nerves; 3 – Superior clunial nerves; 4 – Spinal nerves, posterior branches, dorsal branches (lateral cutaneous branches); 5 – Spinal nerves, posterior branches, dorsal branches (medial cutaneous branches); 6 – Third occipital nerve; 7 – Greater occipital nerve; 8 – Lesser occipital nerve; 9 – Suprascapular nerves; 10 – Superior lateral cutaneous nerve of arm; Superior lateral brachial cutaneous nerve; 11 – Intercostal nerves, lateral cutaneous branches; 12 – Iliohypogastric nerve; Iliopubic nerve, lateral cutaneous branch; 13 – Lateral cutaneous nerve of thigh; Lateral femoral cutaneous nerve; 14 – Posterior cutaneous nerve of thigh; Posterior femoral cutaneous nerve

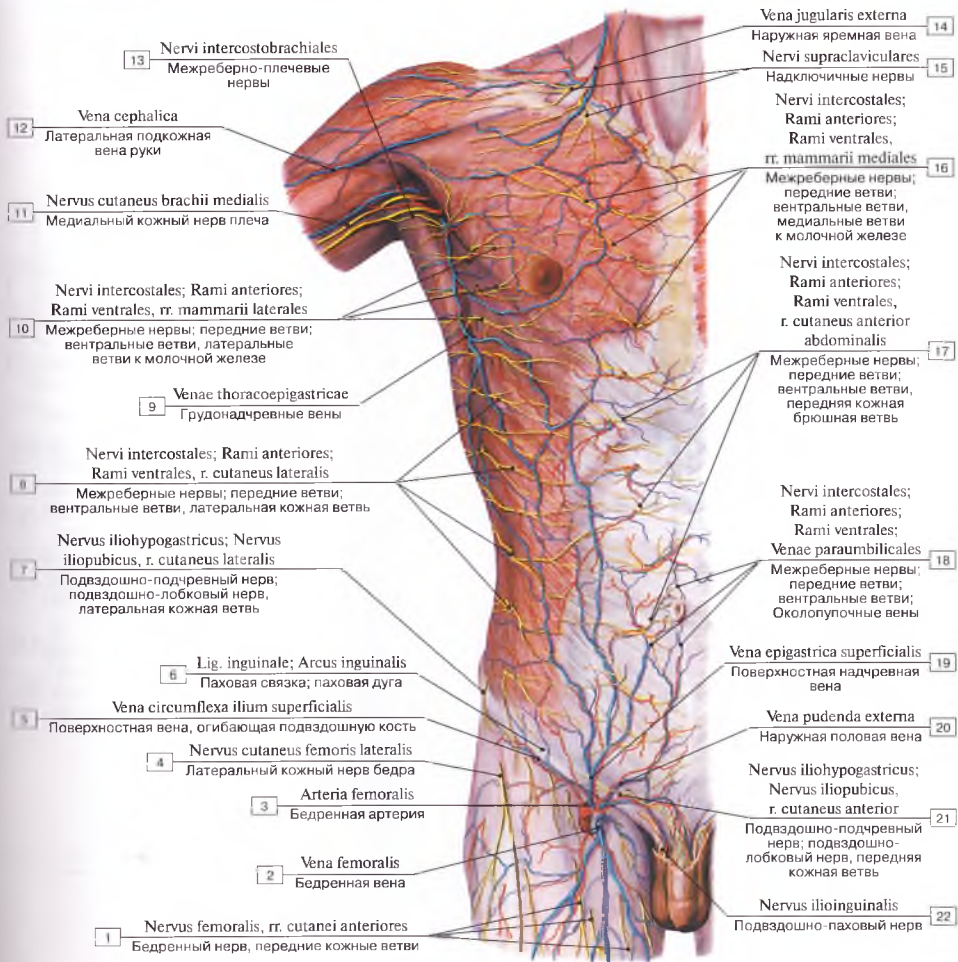


Рис. 249. Поверхностные нервы и сосуды туловища, вид спереди:

1 – Femoral nerve, anterior cutaneous branches; 2 – Femoral vein; 3 – Femoral artery; 4 – Lateral cutaneous nerve of thigh; Lateral femoral cutaneous nerve; 5 – Superficial circumflex iliac vein; 6 – Inguinal ligament; 7 – Iliohypogastric nerve; Iliopubic nerve, lateral cutaneous branch; 8 – Intercostal nerves; Anterior branches; Ventral branches, lateral abdominal cutaneous branch; 9 – Thoraco-epigastric veins; 10 – Intercostal nerves; Anterior branches; Ventral branches, lateral mammary branches; 11 – Medial cutaneous nerve of arm; Medial brachial cutaneous nerve; 12 – Cephalic vein; 13 – Intercostobrachial nerves; 14 – External jugular vein; 15 – Supraclavicular nerves; 16 – Intercostal nerves; Anterior branches; Ventral branches, medial mammary branches; 17 – Intercostal nerves; Anterior branches; Ventral branches, anterior abdominal cutaneous branch; 18 – Intercostal nerves; Anterior branches; Ventral branches; Para-umbilical veins; 19 – Superficial epigastric vein; 20 – External pudendal vein; 21 – Iliohypogastric nerve; Iliopubic nerve, anterior cutaneous branch; 22 – Ilio-inguinal nerve



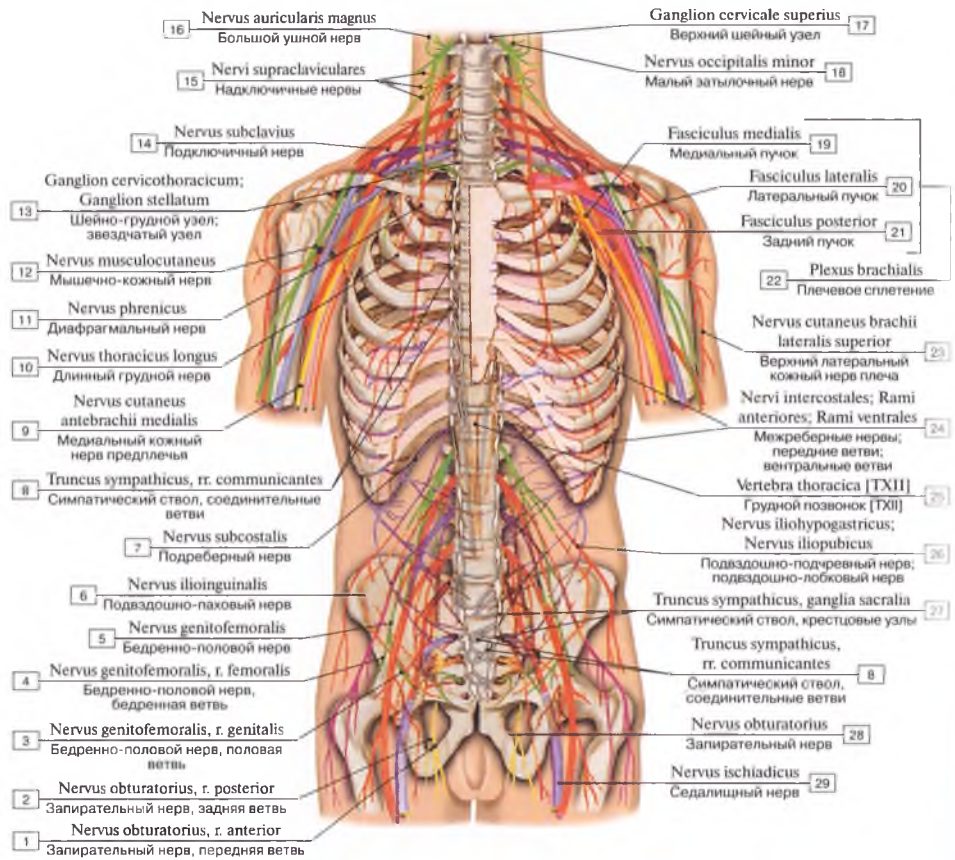
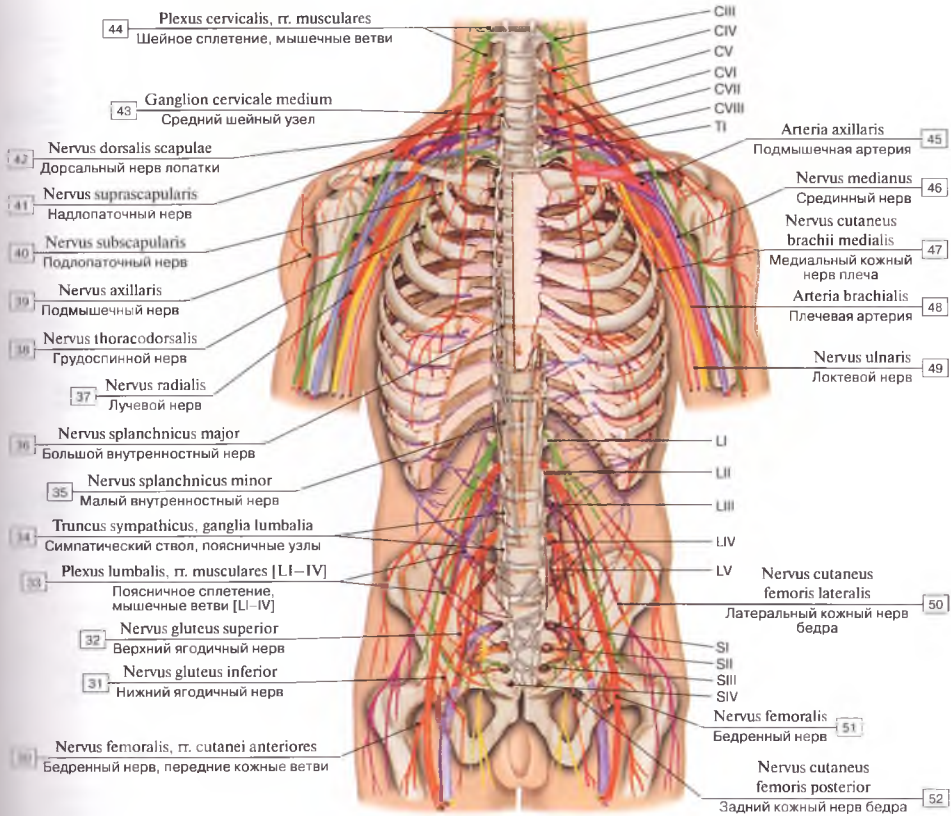


Рис. 250. Передние ветви спинномозговых нервов, вид спереди (образование сплетений) (схема):

1 – Obturator nerve, anterior branch; 2 – Obturator nerve, posterior branch; 3 – Genitofemoral nerve, genital branch; 4 – Genitofemoral nerve, femoral branch; 5 – Genitofemoral nerve; 6 – Ilio-inguinal nerve; 7 – Subcostal nerve; 8 – Sympathetic trunk, communicating branches; 9 – Medial cutaneous nerve of forearm; Medial antebrachial cutaneous nerve; 10 – Long thoracic nerve; 11 – Phrenic nerve; 12 – Musculocutaneous nerve; 13 – Cervicothoracic ganglion; Stellate ganglion; 14 – Subclavian nerve; 15 – Supraclavicular nerves; 16 – Great auricular nerve; 17 – Superior cervical ganglion; 18 – Lesser occipital nerve; 19 – Medial fascicle; 20 – Lateral fascicle; 21 – Posterior fascicle; 22 = 19 + 20 + 21 – Brachial plexus; 23 – Superior lateral cutaneous nerve of arm; Superior lateral brachial cutaneous nerve



44 – Intercostal nerves; Anterior branches; Ventral branches; 25 – Thoracic vertebra [TXII]; 26 – Iliohypogastric nerve; Iliopubic nerve; 27 – Sympathetic trunk, sacral ganglia; 28 – Obturator nerve; 29 – Sciatic nerve; 30 – Femoral nerve, anterior cutaneous branches; 31 – Inferior gluteal nerve; 32 – Superior gluteal nerve; 33 – Lumbar plexus, muscular branches [LI-IV]; 34 – Sympathetic trunk, lumbar ganglia; 35 – Lesser splanchnic nerve; 36 – Greater splanchnic nerve; 37 – Radial nerve; 38 – Thoracodorsal nerve; 39 – Axillary nerve; 40 – Subscapular nerve; 41 – Suprascapular nerve; 42 – Dorsal scapular nerve; 43 – Middle cervical ganglion; 44 – Cervical plexus, muscular branches; 45 – Axillary artery; 46 – Median nerve; 47 – Medial cutaneous nerve of arm; Medial brachial cutaneous nerve; 48 – Brachial artery; 49 – Ulnar nerve; 50 – Lateral cutaneous nerve of thigh; Lateral femoral cutaneous nerve; 51 – Femoral nerve; 52 – Posterior cutaneous nerve of thigh; Posterior femoral cutaneous nerve

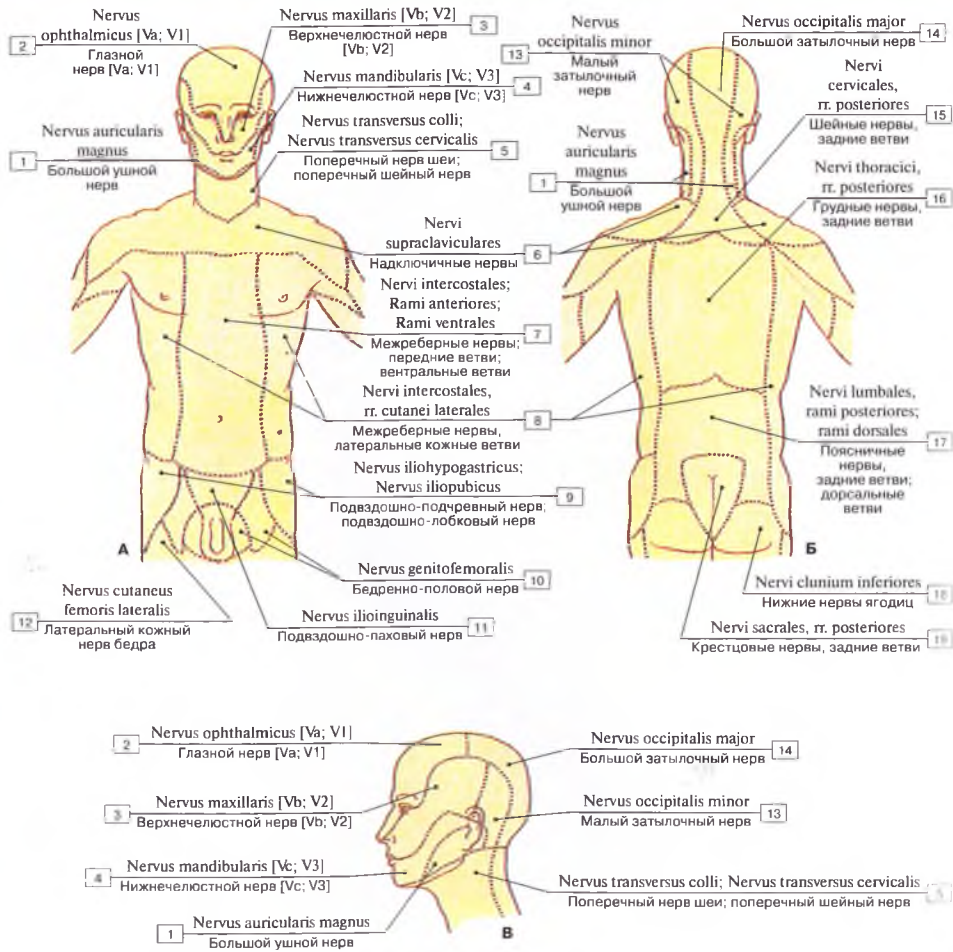


Рис. 251. Зоны чувствительной иннервации кожи передней (А) и задней (Б) поверхностей головы, шеи и туловища (В – боковая поверхность головы):

- 1 – Great auricular nerve; 2 – Ophthalmic nerve; Ophthalmic division [Va; V1]; 3 – Maxillary nerve; Maxillary division [Vb; V2]; 4 – Mandibular nerve; Mandibular division [Vc; V3]; 5 – Transverse cervical nerve; 6 – Supraclavicular nerves; 7 – Intercostal nerves; Anterior branches; Ventral branches; 8 – Intercostal nerves, lateral cutaneous branches; 9 – Iliohypogastric nerve; Iliopubic nerve; 10 – Genitofemoral nerve; 11 – Ilio-inguinal nerve; 12 – Lateral cutaneous nerve of thigh; Lateral femoral cutaneous nerve; 13 – Lesser occipital nerve; 14 – Greater occipital nerve; 15 – Cervical nerves, posterior branches; 16 – Thoracic nerves, posterior branches; 17 – Lumbar nerves, posterior branches; dorsal branches; 18 – Inferior clunial nerves; 19 – Sacral nerves, posterior branches

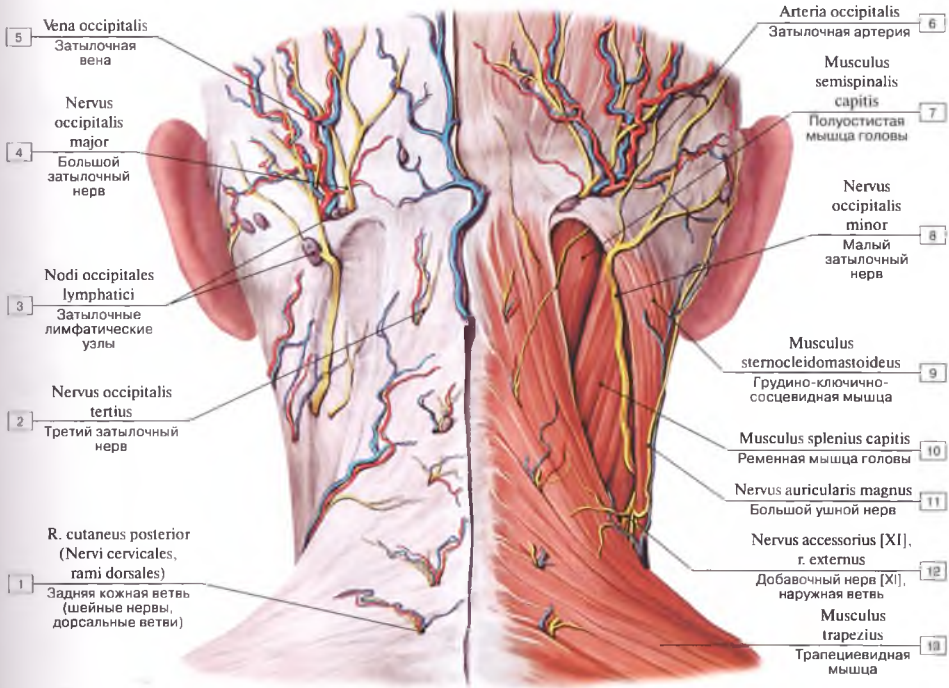


Рис. 252. Нервы задней поверхности шеи:

1 — Posterior cutaneous branch (Cervical nerves, dorsal branches); 2 — Third occipital nerve; 3 — Occipital lymph nodes; 4 — Greater occipital nerve; 5 — Occipital vein; 6 — Occipital artery; 7 — Semispinalis capitis; 8 — Lesser occipital nerve; 9 — Sternocleidomastoid; 10 — Splenius capitis; 11 — Great auricular nerve; 12 — Accessory nerve, external branch [XI]; 13 — Trapezius

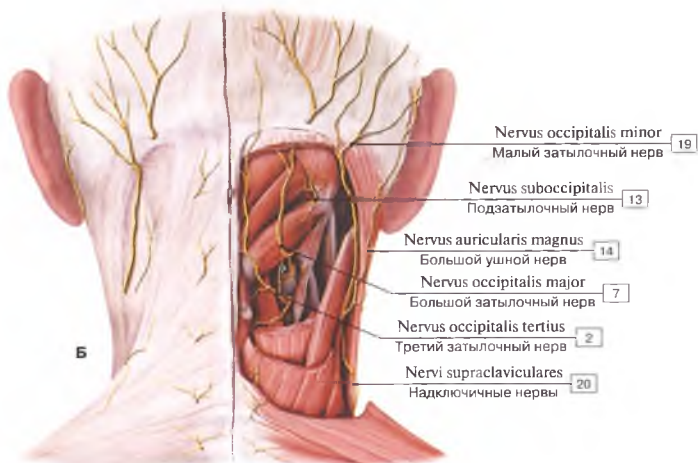
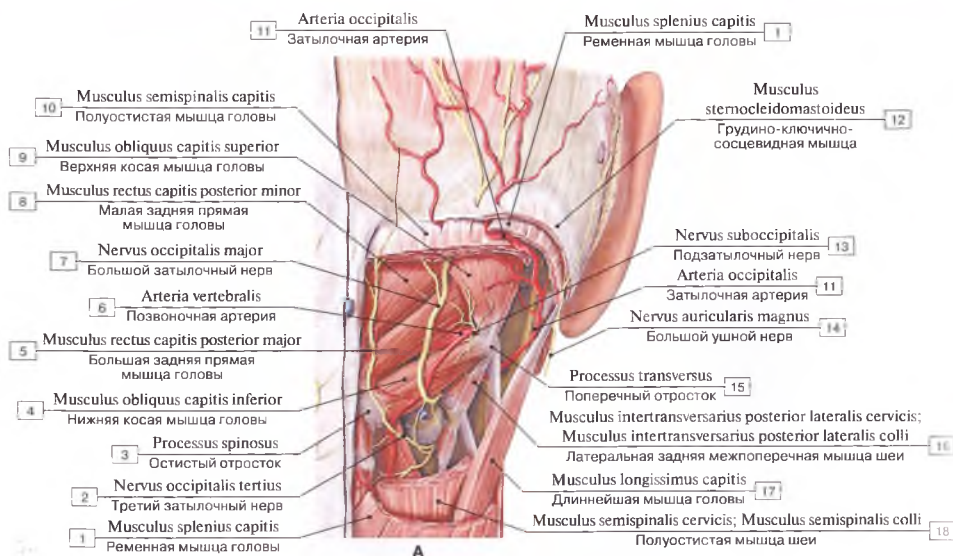


Рис. 253. Нервы задней области шеи (А – поверхностные, Б – глубокие):

1 – Splenius capitis; 2 – Third occipital nerve; 3 – Spinous process; 4 – Obliquus capitis inferior; 5 – Rectus capitis posterior major; 6 – Vertebral artery; 7 – Greater occipital nerve; 8 – Rectus capitis posterior minor; 9 – Obliquus capitis superior; 10 – Semispinalis capitis; 11 – Occipital artery; 12 – Sternocleidomastoid; 13 – Suboccipital nerve; 14 – Great auricular nerve; 15 – Transverse process; 16 – Lateral posterior cervical intertransversarius; 17 – Longissimus capitis; 18 – Semispinalis cervicis; 19 – Lesser occipital nerve; 20 – Supraclavicular nerve

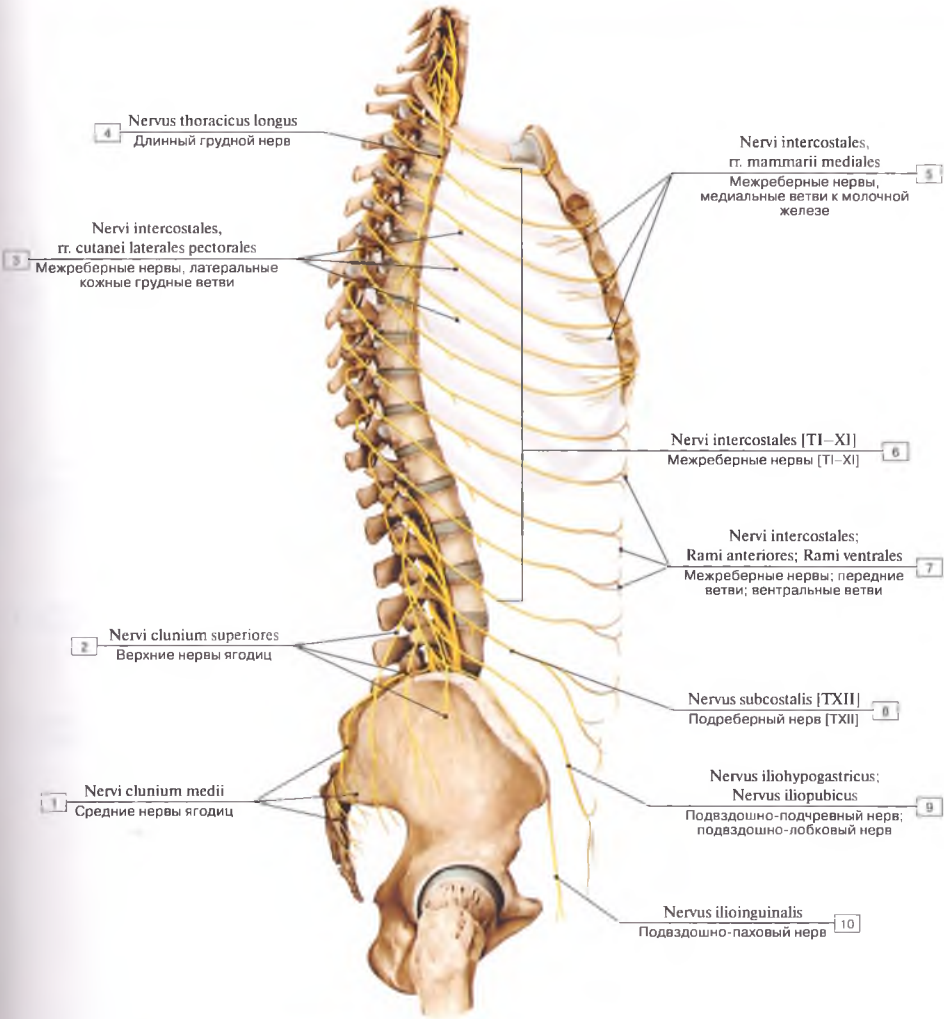


Рис. 254. Нервы боковой стенки туловища, вид справа:

- 1 – Medial clunial nerves; 2 – Superior clunial nerves; 3 – Intercostal nerves, lateral pectoral cutaneous branches; 4 – Long thoracic nerve;  
5 – Intercostal nerves, medial mammary branches; 6 – Intercostal nerves [T1–XI]; 7 – Intercostal nerves; Anterior branches; Ventral branches;  
8 – Subcostal nerve [TXII]; 9 – Iliohypogastric nerve; Iliopubic nerve; 10 – Ilio-inguinal nerve

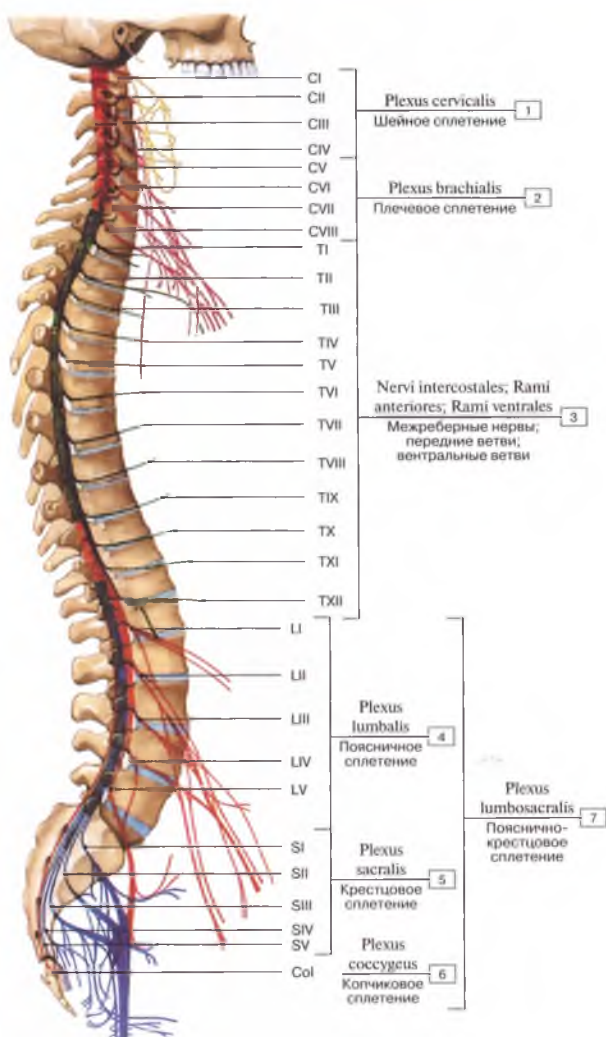


Рис. 255. Проекция спинномозговых нервов на позвоночный столб (схема):

1 – Cervical plexus; 2 – Brachial plexus; 3 – Intercostal nerves; Anterior branches; Ventral branches; 4 – Lumbar plexus; 5 – Sacral plexus; 6 – Coccygeal plexus; 7 = 4 + 5 + 6 – Lumbosacral plexus

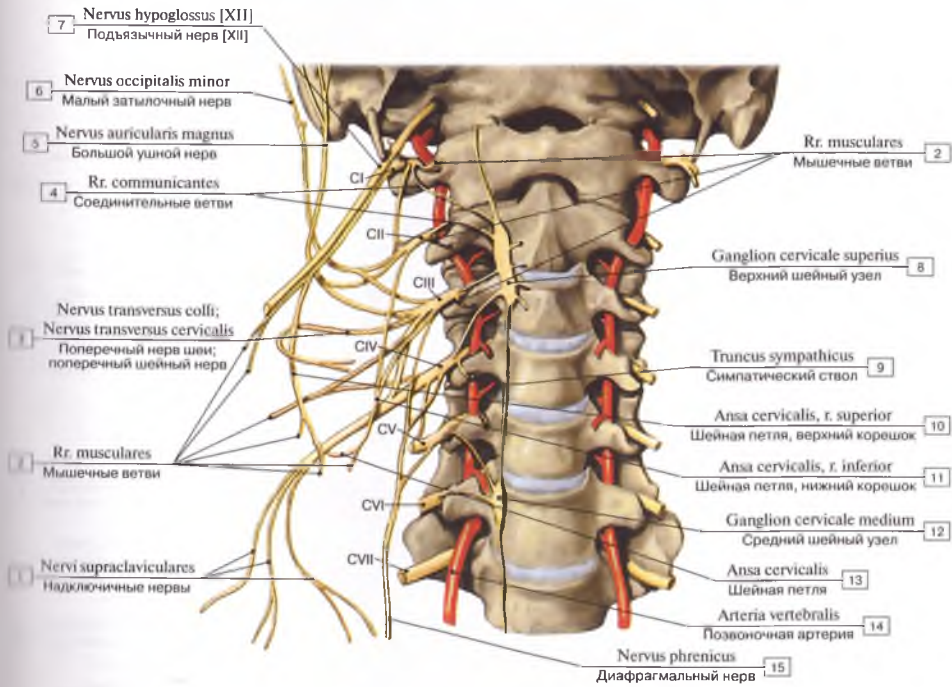


Рис. 256. Шейное сплетение, скелетотопия (схема):

1 – Clavicular nerves; 2 – Muscular branches; 3 – Transverse cervical nerve; 4 – Communicating branches; 5 – Great auricular nerve; 6 – Lesser occipital nerve; 7 – Hypoglossal nerve [XII]; 8 – Superior cervical ganglion; 9 – Sympathetic trunk; 10 – Ansa cervicalis, superior limb; 11 – Ansa cervicalis, inferior limb; 12 – Middle cervical ganglion; 13 – Ansa cervicalis; 14 – Vertebral artery; 15 – Phrenic nerve



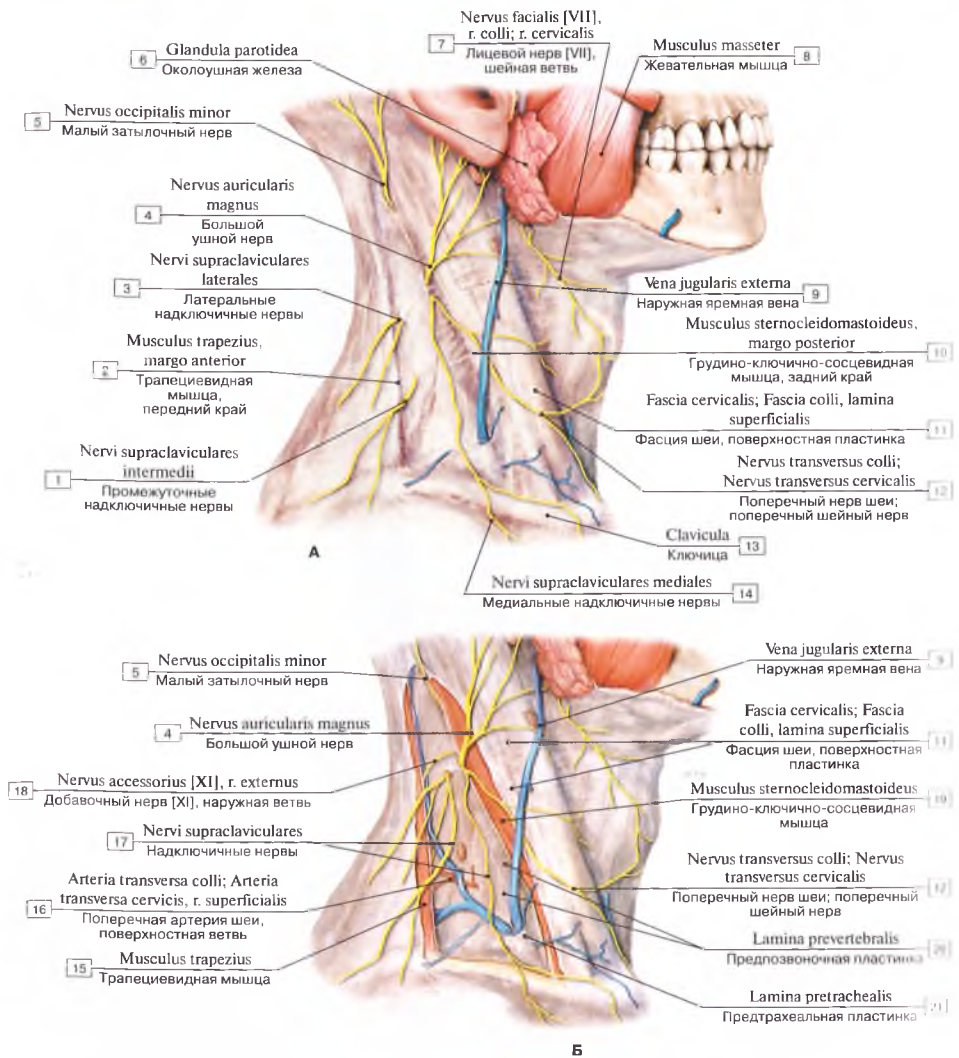
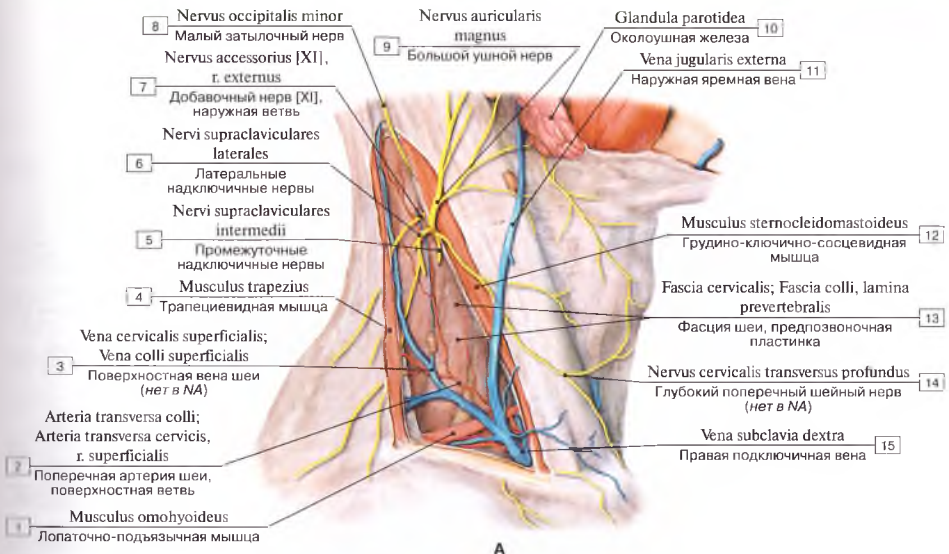
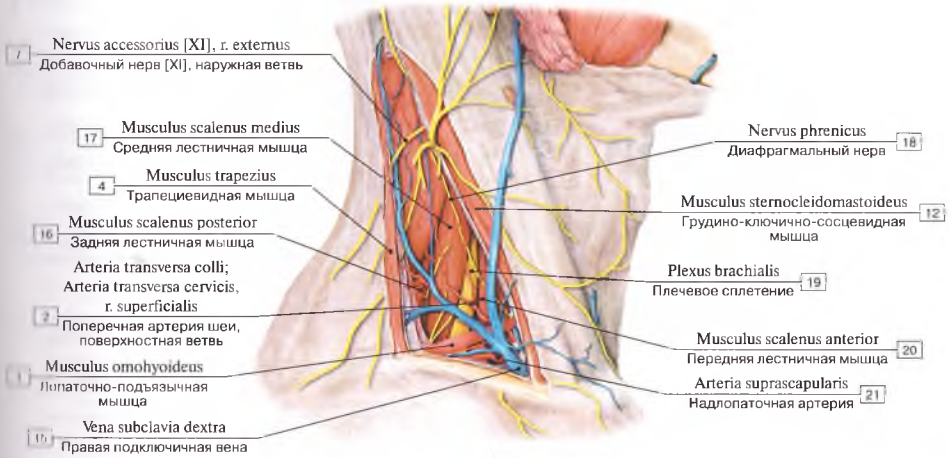


Рис. 257. Задний треугольник шеи, сосуды и нервы (А – подкожный слой; Б – субфасциальный слой):

1 – Intermediate supraclavicular nerves; 2 – Trapezius, anterior border; 3 – Lateral supraclavicular nerves; 4 – Great auricular nerve; 5 – Lesser occipital nerve; 6 – Parotid gland; 7 – Facial nerve [VII], cervical branch; 8 – Masseter; 9 – External jugular vein; 10 – Sternocleidomastoid, posterior border; 11 – Cervical fascia, investing layer; superficial layer; 12 – Transverse cervical nerve; 13 – Clavicle; 14 – Medial supraclavicular nerves; 15 – Trapezius; 16 – Transverse cervical artery, superficial branch; 17 – Supraclavicular nerves; 18 – Accessory nerve [XI], external branch; 19 – Sternocleidomastoid; 20 – Prevertebral layer; 21 – Pretracheal layer



А



Б

Рис. 258. Задний треугольник шеи, сосуды и нервы (А – глубокий слой; Б – глубокий слой, видно плечевое сплетение):

- 1 – Omohyoid; 2 – Transverse cervical vein; 3 – Superficial cervical vein; 4 – Trapezius; 5 – Intermediate supraclavicular nerves; 6 – Lateral supraclavicular nerves; 7 – Accessory nerve [XI], external branch; 8 – Lesser occipital nerve; 9 – Great auricular nerve; 10 – Parotid gland; 11 – External jugular vein; 12 – Sternocleidomastoid; 13 – Cervical fascia, prevertebral layer; 14 – Deep transverse cervical nerve; 15 – Right subclavian vein; 16 – Scalenus posterior; Posterior scalene; 17 – Scalenus medius; Middle scalene; 18 – Phrenic nerve; 19 – Brachial plexus; 20 – Scalenus anterior; Anterior scalene; 21 – Suprascapular artery

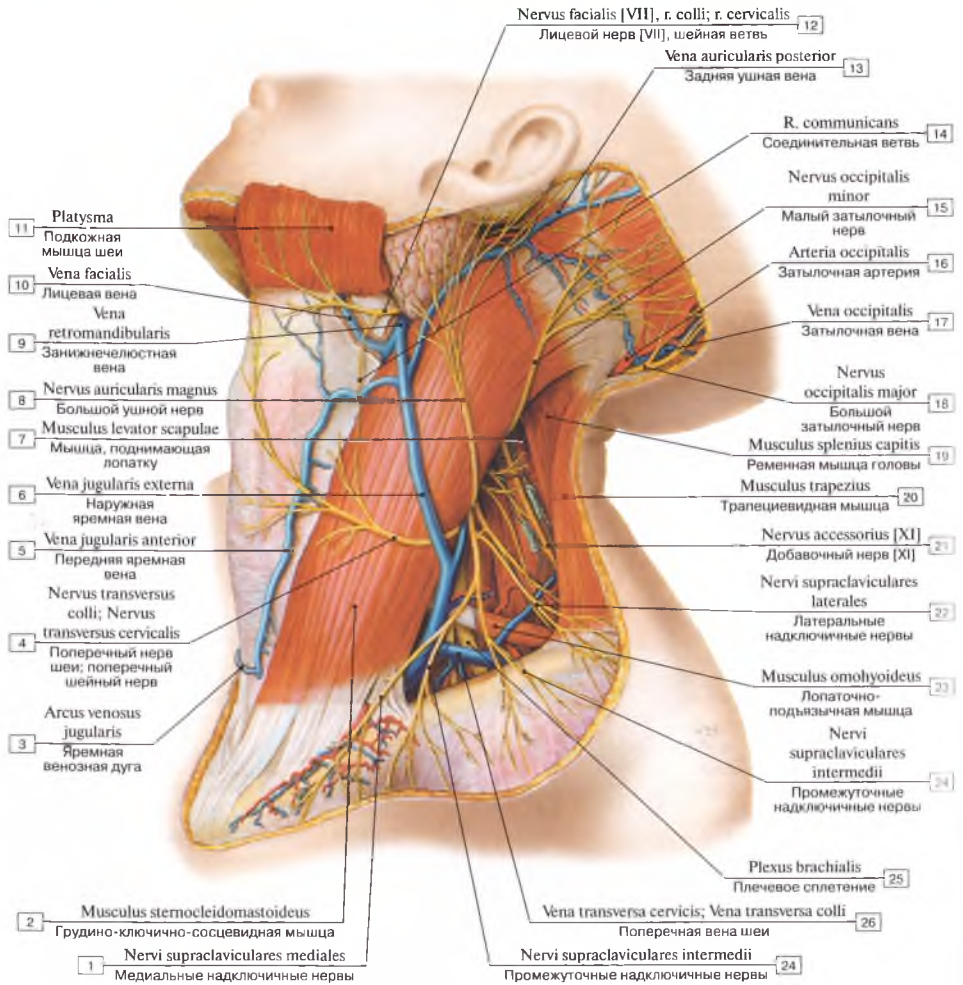


Рис. 259. Нервы шейного сплетения, вид слева:

1 – Medial supraclavicular nerves; 2 – Sternocleidomastoid; 3 – Jugular venous arch; 4 – Transverse cervical nerve; 5 – Anterior jugular vein; 6 – External jugular vein; 7 – Levator scapulae; 8 – Great auricular nerve; 9 – Retromandibular vein; 10 – Facial vein; 11 – Platysma; 12 – Facial nerve [VII], cervical branch; 13 – Posterior auricular vein; 14 – Communicating branch; 15 – Lesser occipital nerve; 16 – Occipital artery; 17 – Occipital vein; 18 – Greater occipital nerve; 19 – Splenius capitis; 20 – Trapezius; 21 – Accessory nerve [XI]; 22 – Lateral supraclavicular nerves; 23 – Omohyoid; 24 – Intermediate supraclavicular nerves; 25 – Brachial plexus; 26 – Transverse cervical vein.

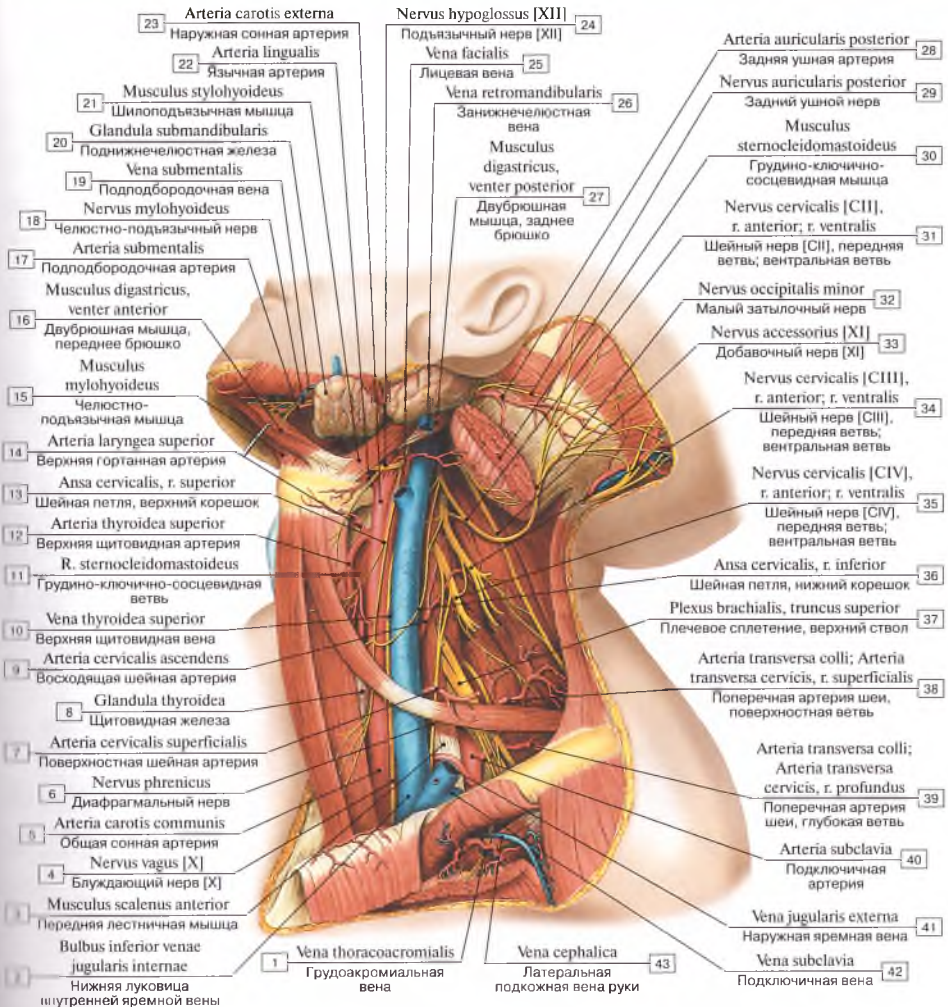


Рис. 260. Нервы и сосуды шеи, вид слева:

1 — Thoraco-acromial vein; 2 — Inferior bulb of internal jugular vein; 3 — Scalenus anterior; Anterior scalene; 4 — Vagus nerve [X]; 5 — Common carotid artery; 6 — Phrenic nerve; 7 — Superficial cervical artery; 8 — Thyroid gland; 9 — Ascending cervical artery; 10 — Superior thyroid vein; 11 — Sternocleidomastoid branch; 12 — Superior thyroid artery; 13 — Ansa cervicalis, superior root; superior limb; 14 — Superior jugular artery; 15 — Mylohyoid; 16 — Digastric, anterior belly; 17 — Submental artery; 18 — Nerve to mylohyoid; 19 — Submental vein; 20 — Submandibular gland; 21 — Stylohyoid; 22 — Lingual artery; 23 — External carotid artery; 24 — Hypoglossal nerve [XII]; 25 — Facial vein; 26 — Retromandibular vein; 27 — Digastric, posterior belly; 28 — Posterior auricular artery; 29 — Posterior auricular nerve; 30 — Sternocleidomastoid branch; 31 — Cervical nerve [CIII], anterior branch; ventral branch; 32 — Lesser occipital nerve; 33 — Accessory nerve [XI]; 34 — Cervical nerve [CIII], anterior branch; ventral branch; 35 — Cervical nerve [CIV], anterior branch; ventral branch; 36 — Ansa cervicalis, inferior root; inferior limb; 37 — Brachial plexus, superior trunk; Upper trunk; 38 — Transverse cervical artery, superficial branch; 39 — Transverse cervical artery, deep branch; 40 — Subclavian artery; 41 — External jugular vein; 42 — Subclavian vein; 43 — Cephalic vein

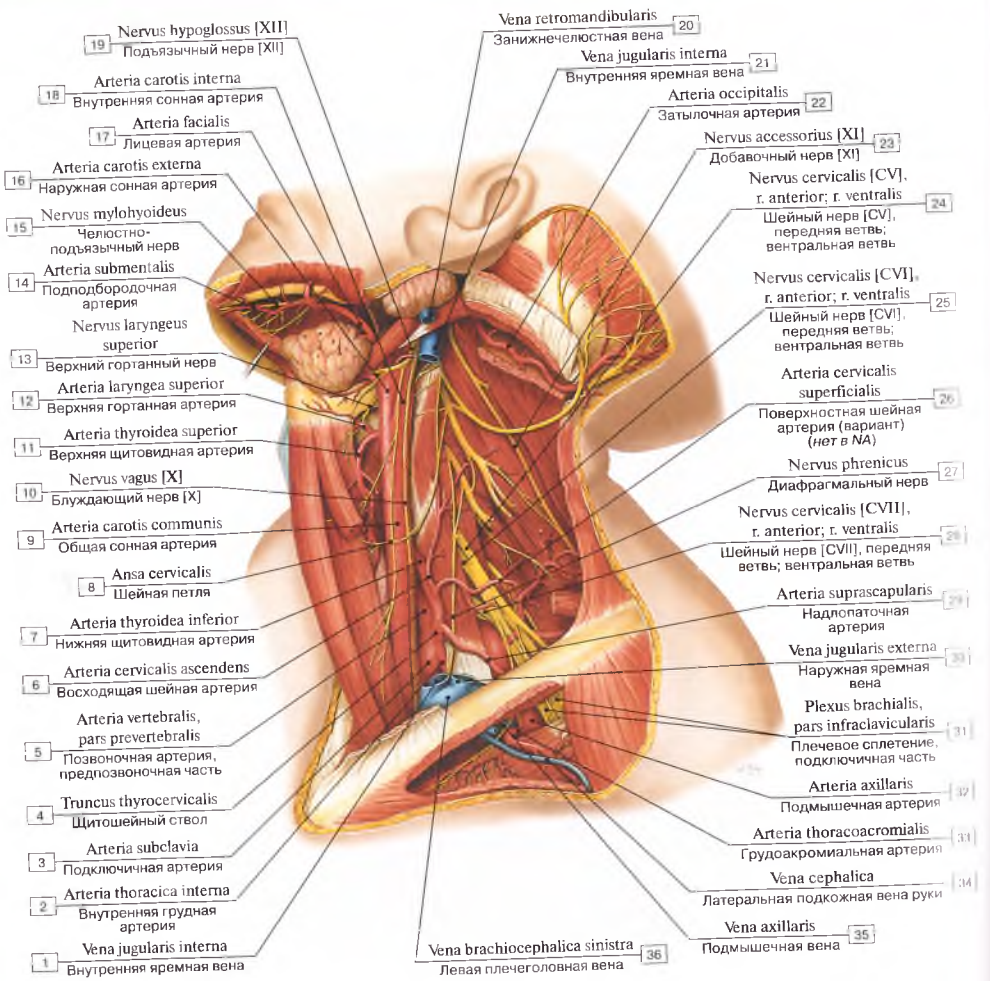


Рис. 261. Сосуды и нервы латеральной части шеи, глубокий слой:

- 1 – Internal jugular vein; 2 – Internal thoracic artery; 3 – Subclavian artery; 4 – Thyrocervical trunk; 5 – Vertebral artery, prevertebral part;
- 6 – Ascending cervical artery; 7 – Inferior thyroid artery; 8 – Ansa cervicalis; 9 – Common carotid artery; 10 – Vagus nerve [X]; 11 – Superior thyroid artery; 12 – Superior laryngeal artery; 13 – Superior laryngeal nerve; 14 – Submental artery; 15 – Nerve to mylohyoid; 16 – External carotid artery; 17 – Facial artery; 18 – Internal carotid artery; 19 – Hypoglossal nerve [XII]; 20 – Retromandibular vein; 21 – Internal jugular vein; 22 – Occipital artery; 23 – Accessory nerve [XII]; 24 – Cervical nerve [CV], anterior branch; ventral branch; 25 – Cervical nerve [CV], anterior branch; ventral branch; 26 – Superficial cervical artery; 27 – Phrenic nerve; 28 – Cervical nerve [CVII], anterior branch; ventral branch; 29 – Suprascapular artery; 30 – External jugular vein; 31 – Brachial plexus, infraclavicular part; 32 – Axillary artery; 33 – Thoracoacromial artery; 34 – Cephalic vein; 35 – Axillary vein; 36 – Left brachiocephalic vein

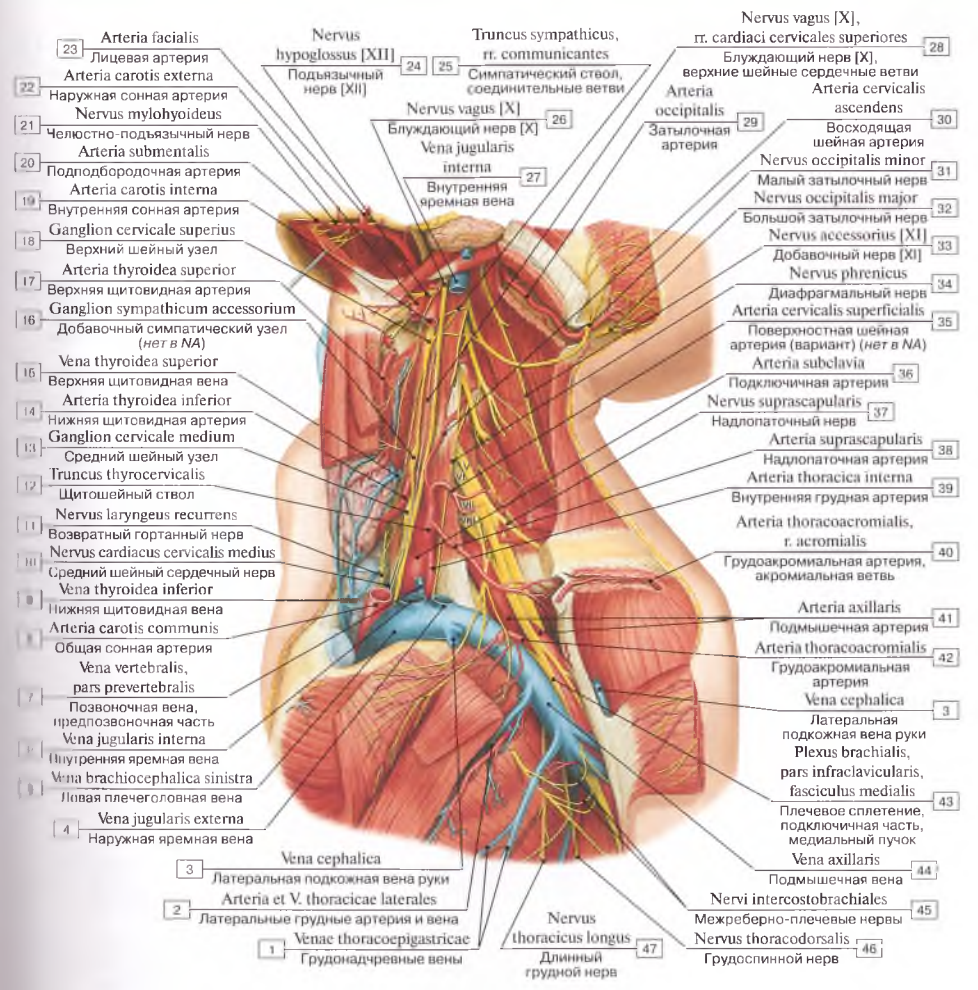


Рис. 262. Сосуды и нервы глубокой области шеи, вид слева:

- 1 – Thoraco-epigastric veins; 2 – Lateral thoracic artery and vein; 3 – Cephalic vein; 4 – External jugular vein; 5 – Left brachiocephalic vein; 6 – Internal jugular vein; 7 – Vertebral vein, prevertebral part; 8 – Common carotid artery; 9 – Inferior thyroid vein; 10 – Middle cervical cutaneous nerve; 11 – Recurrent laryngeal nerve; 12 – Thyrocervical trunk; 13 – Middle cervical ganglion; 14 – Inferior thyroid artery; 15 – Superior thyroid vein; 16 – Accessory sympathetic ganglion; 17 – Superior thyroid artery; 18 – Superior cervical ganglion; 19 – Internal carotid artery; 20 – Submental artery; 21 – Nerve to mylohyoid; 22 – External carotid artery; 23 – Facial artery; 24 – Hypoglossal nerve [XII]; 25 – Sympathetic trunk, communicating branches; 26 – Vagus nerve [X]; 27 – Internal jugular vein; 28 – Vagus nerve [X], superior cervical ganglion branches; 29 – Occipital artery; 30 – Ascending cervical artery; 31 – Lesser occipital nerve; 32 – Greater occipital nerve; 33 – Accessory nerve [XII]; 34 – Phrenic nerve; 35 – Superficial cervical artery; 36 – Subclavian artery; 37 – Suprascapular nerve; 38 – Suprascapular artery; 39 – Internal thoracic artery; 40 – Thoraco-acromial artery, acromial branch; 41 – Axillary artery; 42 – Thoraco-acromial artery; 43 – Brachial plexus, infraclavicular part, medial cord; 44 – Axillary vein; 45 – Intercostobrachial nerves; 46 – Thoracodorsal nerve; 47 – Long thoracic nerve

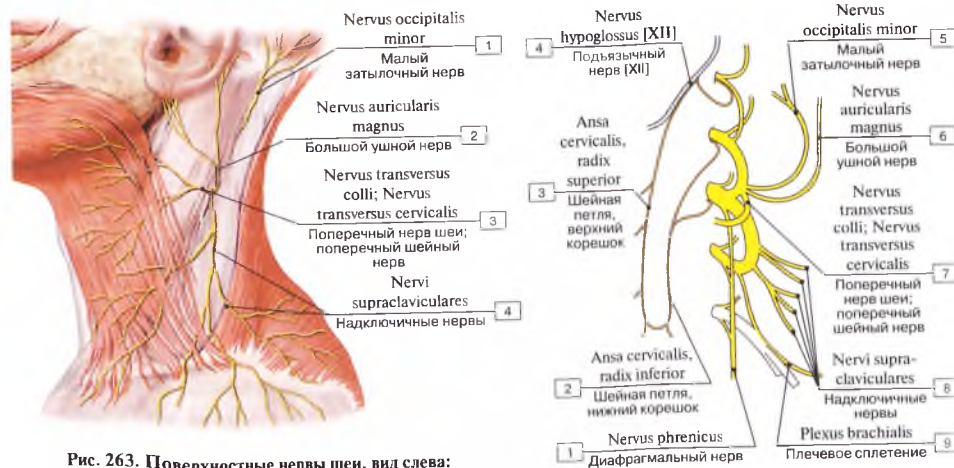


Рис. 263. Поверхностные нервы шеи, вид слева:

1 – Lesser occipital nerve; 2 – Great auricular nerve; 3 – Transverse cervical nerve; 4 – Supraclavicular nerves

Рис. 264. Ветви шейного сплетения, вид слева (схема):

1 – Phrenic nerve; 2 – Ansa cervicalis, inferior root; inferior limb; 3 – Ansa cervicalis, superior root; superior limb; 4 – Hypoglossal nerve [XII]; 5 – Lesser occipital nerve; 6 – Great auricular nerve; 7 – Transverse cervical nerve; 8 – Supraclavicular nerves; 9 – Brachial plexus

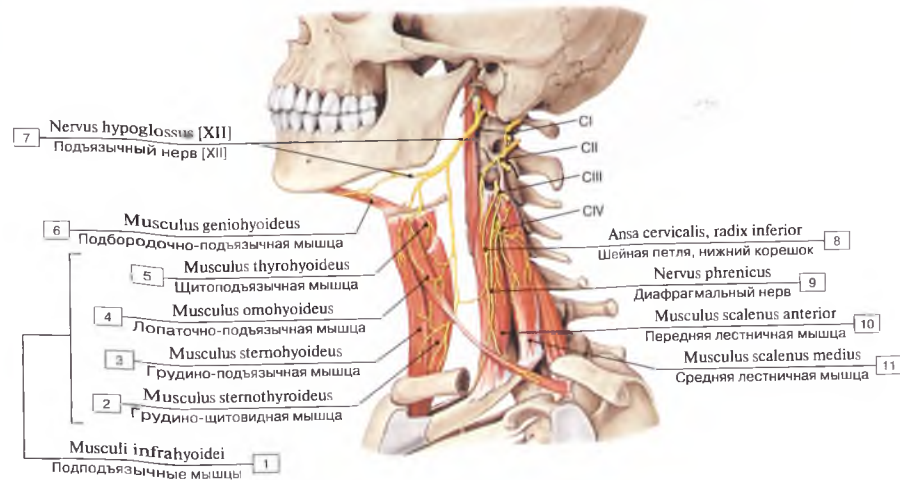


Рис. 265. Двигательные ветви шейного сплетения:

1 – Infrahyoid muscles; 2 – Sternothyroid; 3 – Sternohyoid; 4 – Omohyoid; 5 – Thyrohyoid; 6 – Geniohyoid; 7 – Hypoglossal nerve [XII]; 8 – Ansa cervicalis, inferior root; inferior limb; 9 – Phrenic nerve; 10 – Scalenus anterior; Anterior scalene; 11 – Scalenus medius; Middle scalene

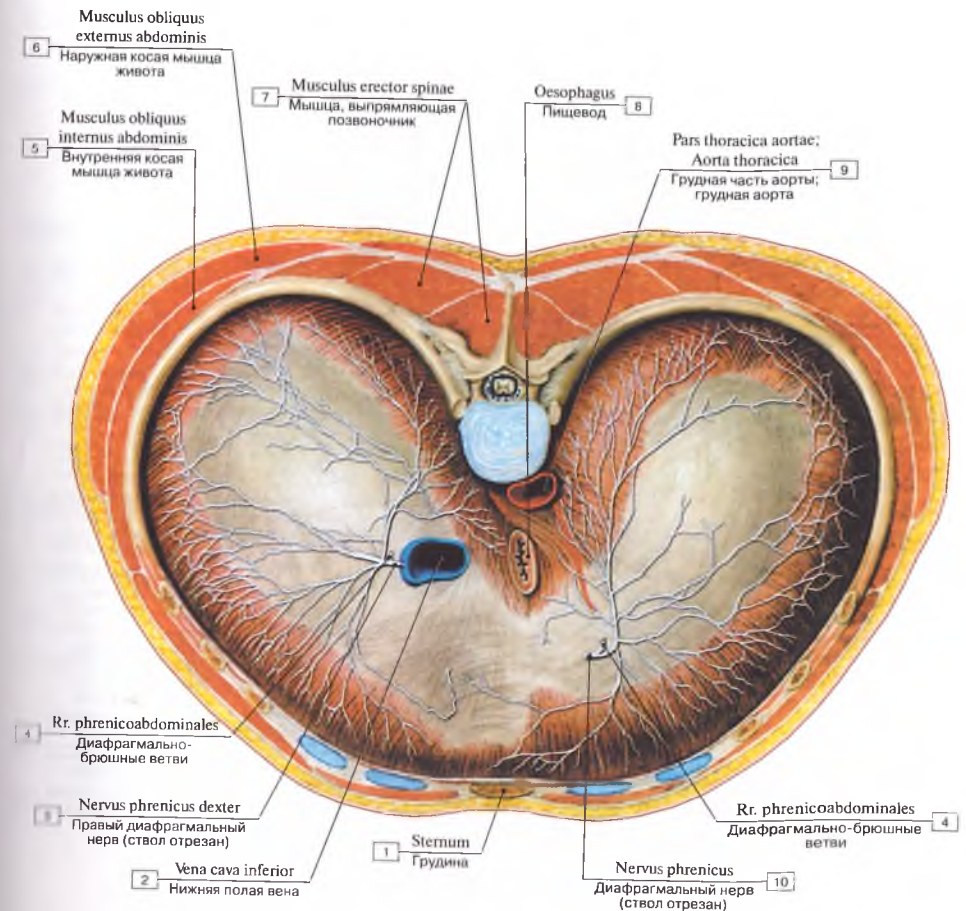


Рис. 266. Иннервация диафрагмы, вид сверху. Поперечный разрез туловища непосредственно над диафрагмой. Фасция, покрывающая диафрагму, удалена:

1 – Sternum; 2 – Inferior vena cava; 3 – Right phrenic nerve; 4 – Phrenico-abdominal branches; 5 – Internal oblique; 6 – External oblique; 7 – Erector spinae; 8 – Oesophagus; 9 – Thoracic aorta; 10 – Phrenic nerve

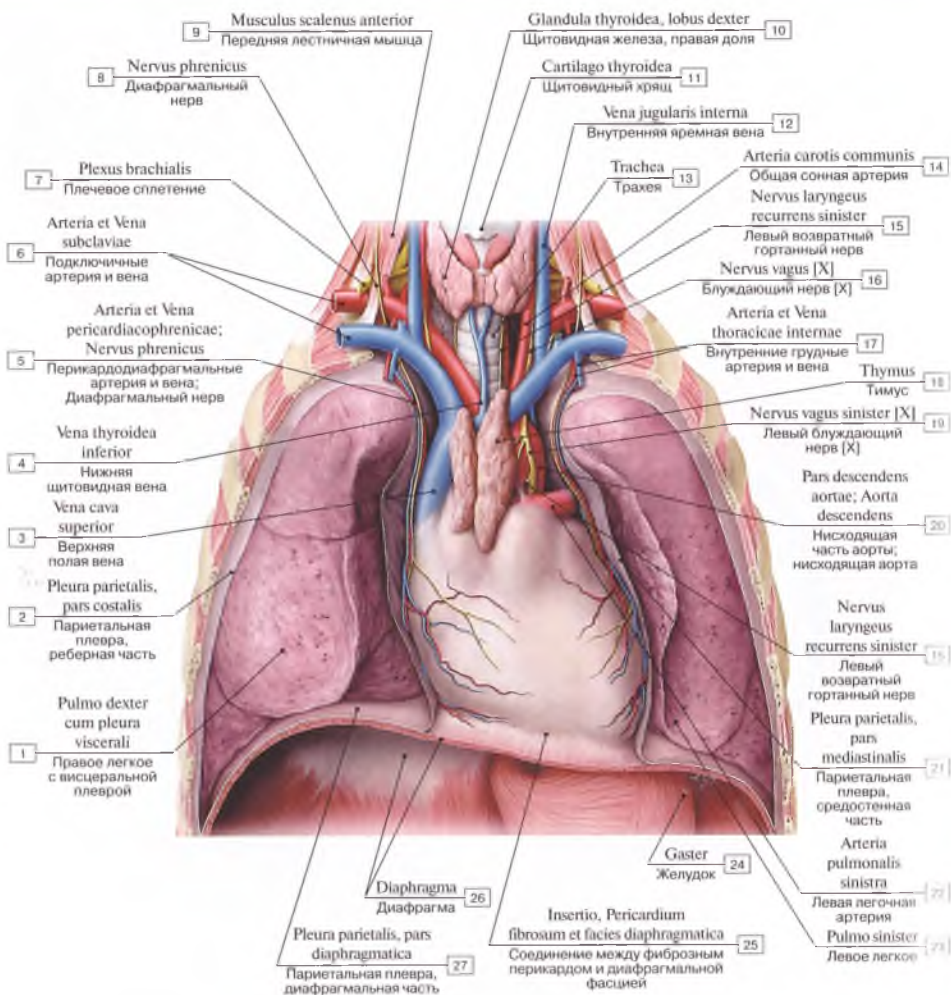


Рис. 267. Диафрагмальный нерв:

1 – Right lung with visceral pleura; 2 – Parietal pleura, costal part; 3 – Superior vena cava; 4 – Inferior thyroid vein; 5 – Pericardiophrenic artery and vein; Phrenic nerve; 6 – Subclavian artery and vein; 7 – Brachial plexus; 8 – Phrenic nerve; 9 – Scalenus anterior; Anterior scalene; 10 – Thyroid gland, right lobe; 11 – Thyroid cartilage; 12 – Internal jugular vein; 13 – Trachea; 14 – Common carotid artery; 15 – Left recurrent laryngeal nerve; 16 – Vagus nerve [X]; 17 – Internal thoracic artery and vein; 18 – Thymus; 19 – Left vagus nerve [X]; 20 – Aorta descending part; 21 – Parietal pleura, mediastinal part; 22 – Left pulmonary artery; 23 – Left lung; 24 – Stomach; 25 – Attachment between fibrous pericardium and diaphragmatic fascia; 26 – Diaphragm; 27 – Parietal pleura, diaphragmatic part

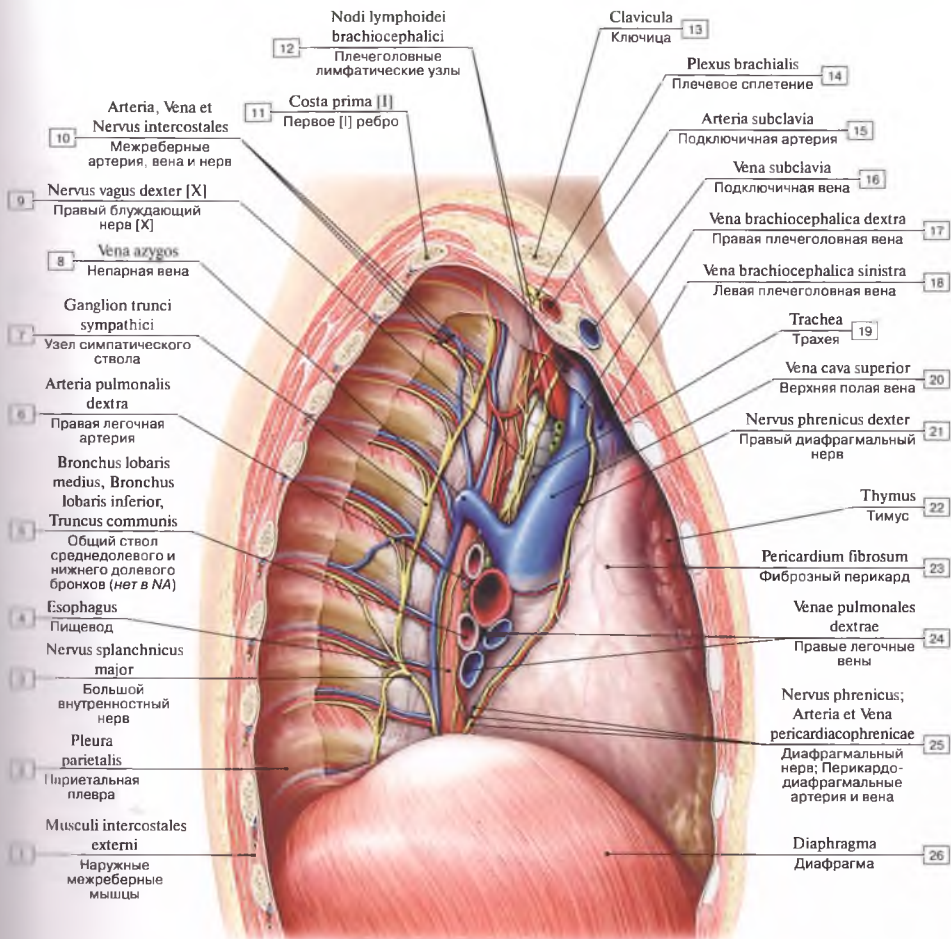


Рис. 268. Правый диафрагмальный нерв:

1 – External intercostal muscle; 2 – Parietal pleura; 3 – Greater splanchnic nerve; 4 – Esophagus; 5 – Common trunk of middle and lower lobes bronchi; 6 – Right pulmonary artery; 7 – Ganglion of sympathetic trunk; 8 – Azygos vein; 9 – Right vagus nerve [X]; 10 – Intercostal artery, vein and nerve; 11 – First rib [I]; 12 – Brachiocephalic lymph nodes; 13 – Clavicle; 14 – Brachial plexus; 15 – Subclavian artery; 16 – Subclavian vein; 17 – Right brachiocephalic vein; 18 – Left brachiocephalic vein; 19 – Trachea; 20 – Superior vena cava; 21 – Right phrenic nerve; 22 – Thymus; 23 – Fibrous pericardium; 24 – Right pulmonary veins; 25 – Phrenic nerve; Pericardiophrenic artery and vein; 26 – Diaphragm



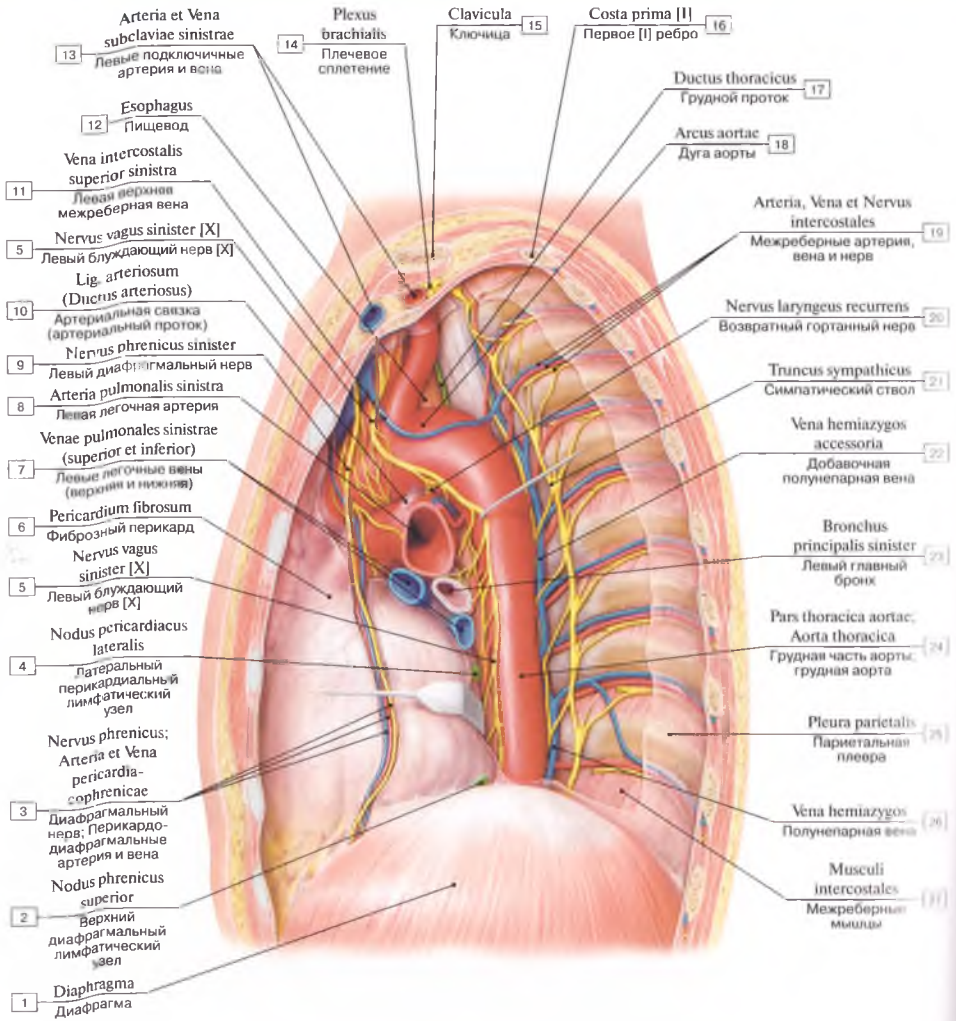


Рис. 269. Левый диафрагмальный нерв:

1 – Diaphragm; 2 – Superior diaphragmatic lymph node; 3 – Phrenic nerve; Pericardiacophrenic artery and vein; 4 – Lateral pericardial lymph node; 5 – Left vagus nerve [X]; 6 – Fibrous pericardium; 7 – Left pulmonary veins (superior and inferior); 8 – Left pulmonary artery; 9 – Left phrenic nerve; 10 – Ligamentum arteriosum (Ductus arteriosus); 11 – Left superior intercostal vein; 12 – Esophagus; 13 – Left subclavian artery and vein; 14 – Brachial plexus; 15 – Clavicle; 16 – First rib [I]; 17 – Thoracic duct; 18 – Arch of aorta; Aortic arch; 19 – Intercostal artery, vein and nerve; 20 – Recurrent laryngeal nerve; 21 – Sympathetic trunk; 22 – Accessory hemi-azygos vein; Superior hemi-azygos vein; 23 – Left main bronchus; 24 – Thoracic aorta; 25 – Parietal pleura; 26 – Hemi-azygos vein; Inferior hemi-azygos vein; 27 – Intercostal muscle

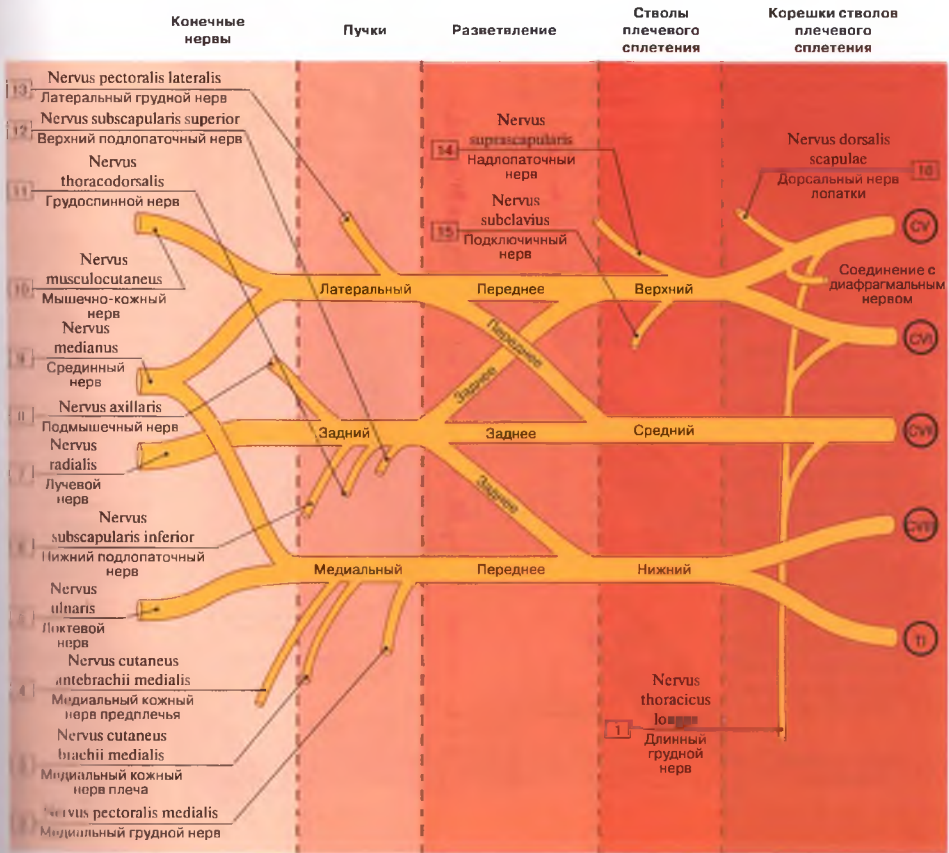


Рис. 270. Формирование плечевого сплетения (схема):

1 – Long thoracic nerve; 2 – Medial pectoral nerve; 3 – Medial cutaneous nerve of arm; Medial brachial cutaneous nerve; 4 – Medial cutaneous nerve of forearm; Medial antebrachial cutaneous nerve; 5 – Ulnar nerve; 6 – Inferior subscapular nerves; 7 – Radial nerve; 8 – Axillary nerve; 9 – Median nerve; 10 – Musculocutaneous nerve; 11 – Thoracodorsal nerve; 12 – Superior subscapular nerves; 13 – Lateral pectoral nerve; 14 – Suprascapular nerve; 15 – Subclavian nerve; 16 – Dorsal scapular nerve

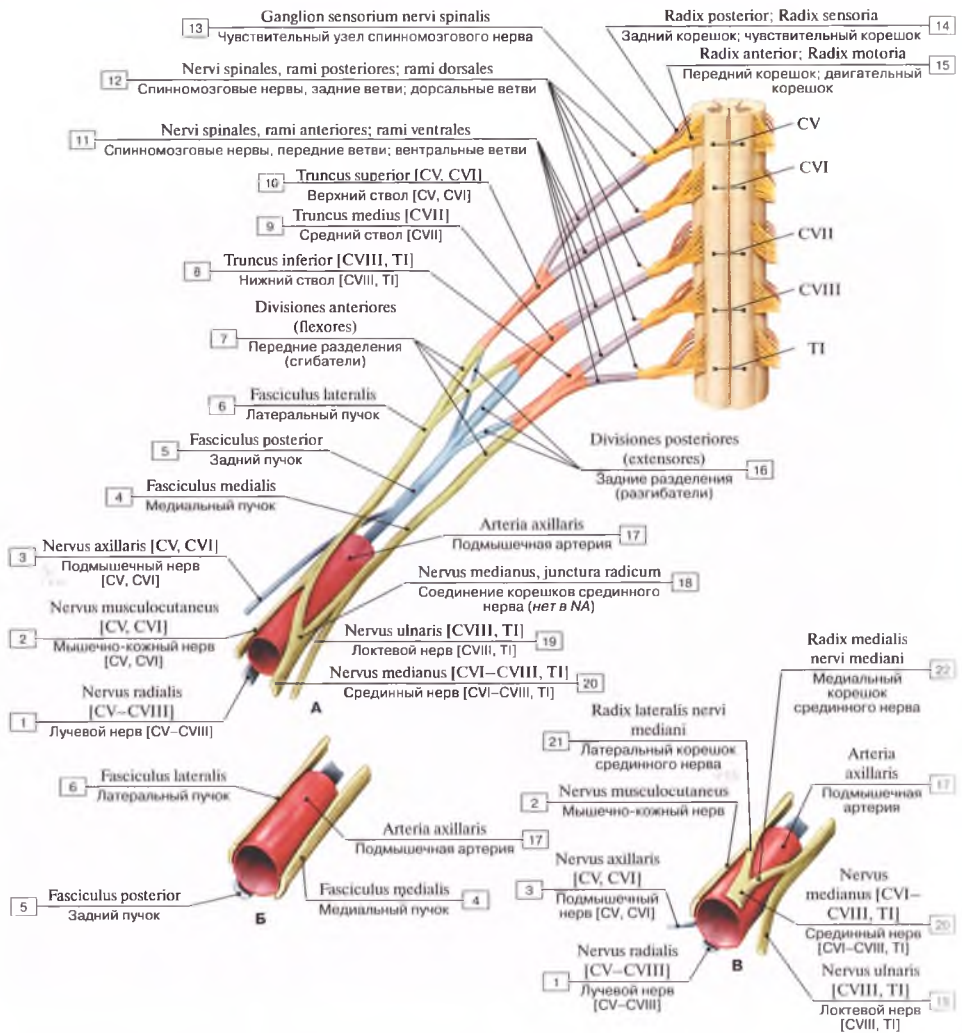


Рис. 271. Формирование плечевого сплетения (А – плечевое сплетение; Б – взаимоотношения пучков плечевого сплетения с подмышечной артерией; В – взаимоотношения нервов плечевого сплетения с подмышечной артерией):

1 – Radial nerve [CV–CVIII]; 2 – Musculocutaneous nerve [CV, CVI]; 3 – Axillary nerve [CV, CVI]; 4 – Medial cord; 5 – Posterior cord; 6 – Lateral cord; 7 – Anterior divisions (flexors); 8 – Lower trunk [CVIII, TI]; 9 – Middle trunk [CVII]; 10 – Upper trunk [CV, CVI]; 11 – Spinal nerves, anterior branches; ventral branches; 12 – Spinal nerves, posterior branches; dorsal branches; 13 – Spinal ganglion; Dorsal root ganglion; 14 – Posterior root; Sensory root; Dorsal root; 15 – Anterior root; Motor root; Ventral root; 16 – Posterior divisions (extensors); 17 – Axillary artery; 18 – Union of roots of median nerve; 19 – Ulnar nerve [CVIII, TI]; 20 – Median nerve [CVI–CVIII, TI]; 21 – Lateral root of median nerve; 22 – Medial root of median nerve

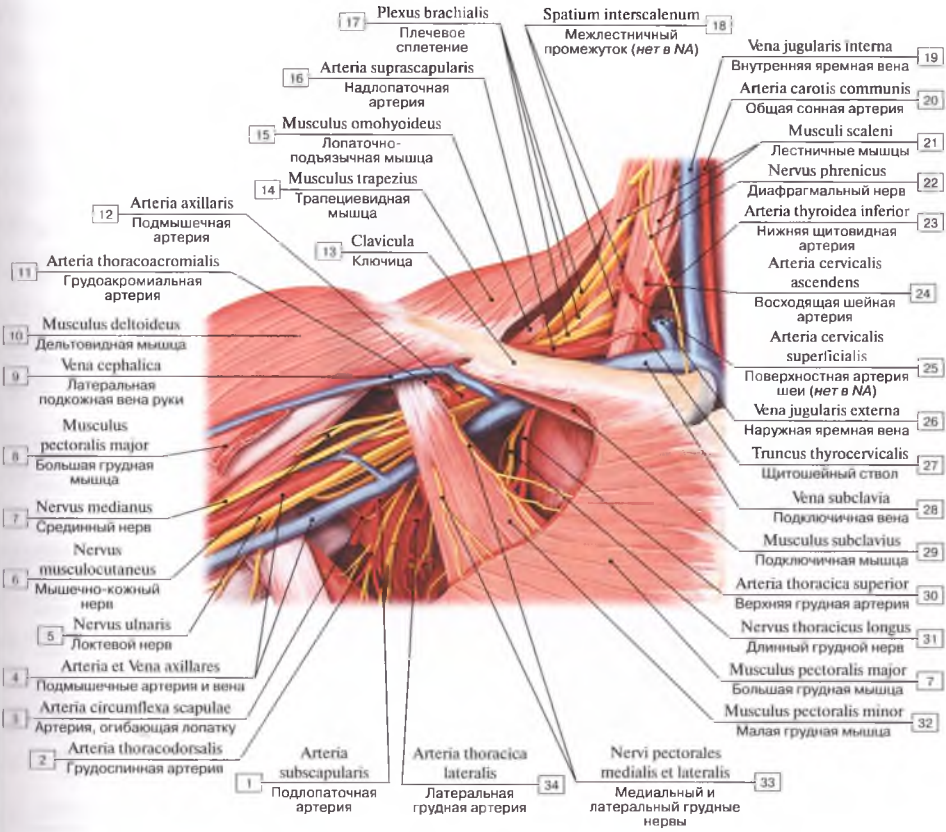


Рис. 272. Плечевое сплетение, над- и подключичная части:

- 1 – Subscapular artery; 2 – Thoracodorsal artery; 3 – Circumflex scapular artery; 4 – Axillary artery and vein; 5 – Ulnar nerve; 6 – Musculocutaneous nerve; 7 – Median nerve; 8 – Pectoralis major; 9 – Cephalic vein; 10 – Deltoid; 11 – Thoraco-acromial artery; 12 – Axillary artery; 13 – Clavicle; 14 – Trapezius; 15 – Omoxyoid; 16 – Suprascapular artery; 17 – Brachial plexus; 18 – Interscalene space; 19 – Internal jugular vein; 20 – Common carotid artery; 21 – Scalene muscles; 22 – Phrenic nerve; 23 – Inferior thyroid artery; 24 – Ascending cervical artery; 25 – Superficial cervical artery; 26 – External jugular vein; 27 – Thyrocervical trunk; 28 – Subclavian vein; 29 – Subclavius; 30 – Superior thoracic artery; 31 – Long thoracic nerve; 32 – Pectoralis major; 32 – Pectoralis minor; 33 – Medial and lateral pectoral nerves; 34 – Lateral thoracic artery

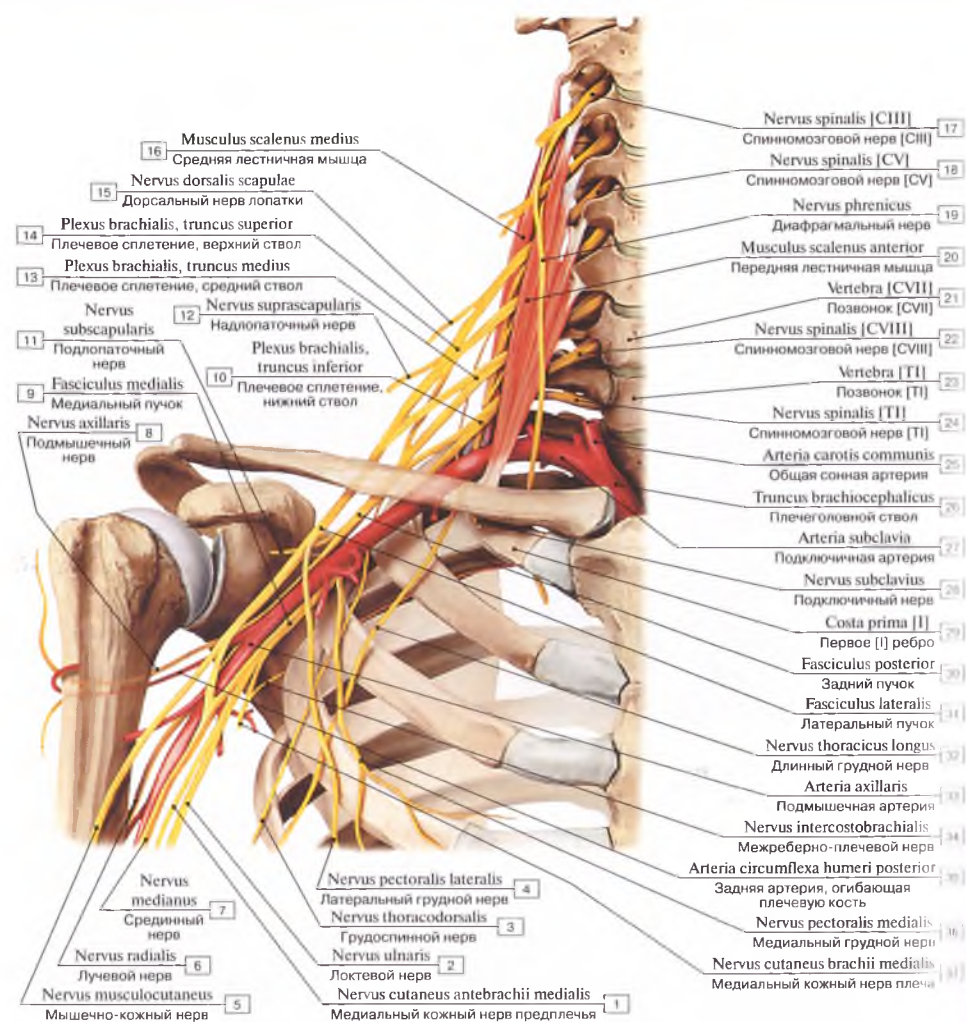


Рис. 273. Распространение нервов плечевого сплетения, правая сторона, вид спереди:

1 – Medial cutaneous nerve of forearm; Medial antebrachial cutaneous nerve; 2 – Ulnar nerve; 3 – Thoracodorsal nerve; 4 – Lateral pectoral nerve; 5 – Musculocutaneous nerve; 6 – Radial nerve; 7 – Median nerve; 8 – Axillary nerve; 9 – Medial cord; 10 – Brachial plexus, inferior trunk; lower trunk; 11 – Subscapular nerve; 12 – Suprascapular nerve; 13 – Brachial plexus, middle trunk; 14 – Brachial plexus, superior trunk; upper trunk; 15 – Dorsal scapular nerve; 16 – Scalenus medius; Middle scalene; 17 – Spinal nerve [CIII]; 18 – Spinal nerve [CV]; 19 – Phrenic nerve; 20 – Scalenus anterior; Anterior scalene; 21 – Vertebra [CVII]; 22 – Spinal nerve [CVIII]; 23 – Vertebra [TI]; 24 – Spinal nerve [TI]; 25 – Common carotid artery; 26 – Brachiocephalic trunk; 27 – Subclavian artery; 28 – Subclavian nerve; 29 – First rib [I]; 30 – Posterior cord; 31 – Lateral cord; 32 – Long thoracic nerve; 33 – Axillary artery; 34 – Intercostobrachial nerve; 35 – Posterior circumflex humeral artery; 36 – Medial pectoral nerve; 37 – Medial cutaneous nerve of arm; Medial brachial cutaneous nerve

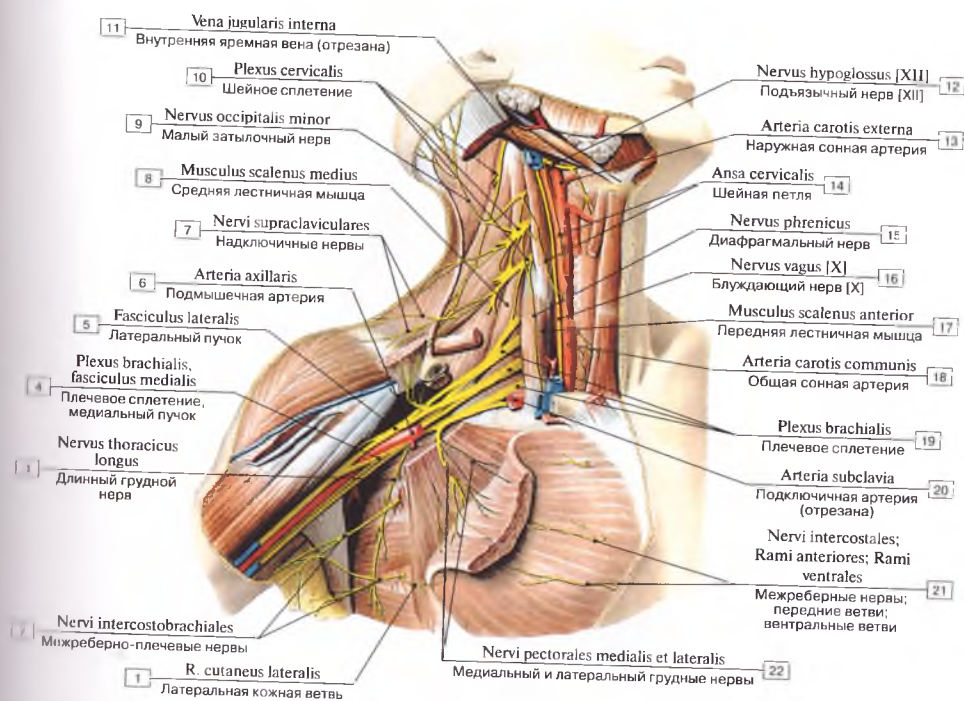


Рис. 274. Шейное и плечевое сплетения и их ветви, вид справа (средняя часть ключицы, подключичные артерия и вена, верхнее брюшко лопаточно-подъязычной мышцы удалены, большая грудная мышца разрезана и отвернута вниз):

1 – Lateral cutaneous branch; 2 – Intercostobrachial nerves; 3 – Long thoracic nerve; 4 – Brachial plexus, medial cord; 5 – Lateral cord; 6 – Axillary artery; 7 – Supraclavicular nerves; 8 – Scalenus medius; Middle scalene; 9 – Lesser occipital nerve; 10 – Cervical plexus; 11 – Internal jugular vein; 12 – Hypoglossal nerve [XII]; 13 – External carotid artery; 14 – Ansa cervicalis; 15 – Phrenic nerve; 16 – Vagus nerve [X]; 17 – Scalenus anterior; Anterior scalene; 18 – Common carotid artery; 19 – Brachial plexus; 20 – Subclavian artery; 21 – Intercostal nerves; Anterior branches; Ventral branches; 22 – Medial and lateral pectoral nerves

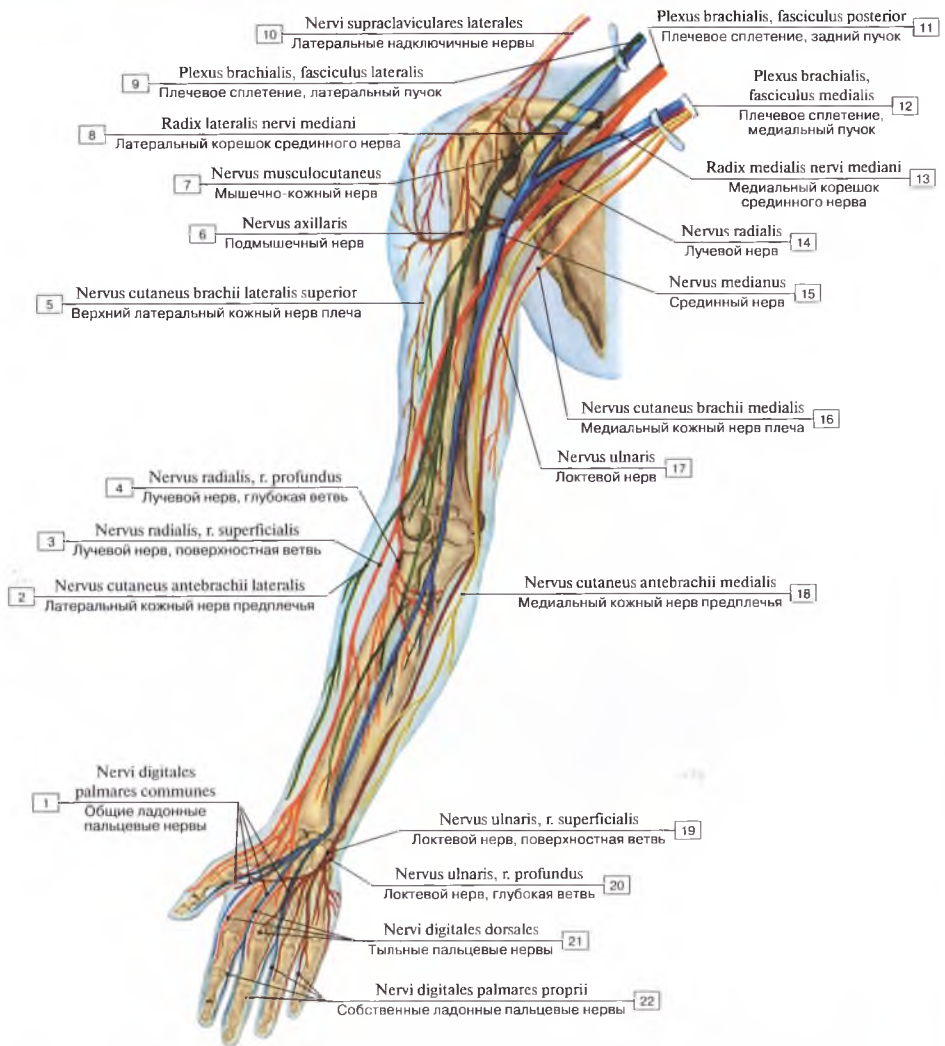
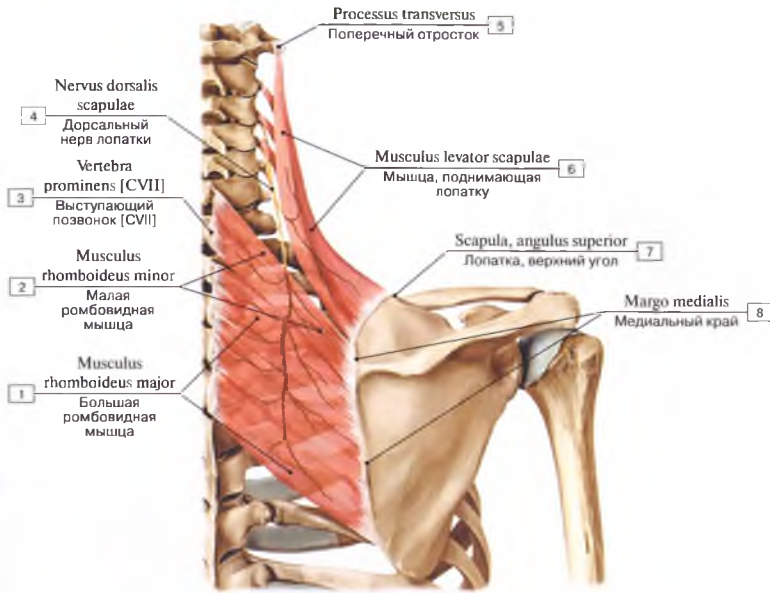
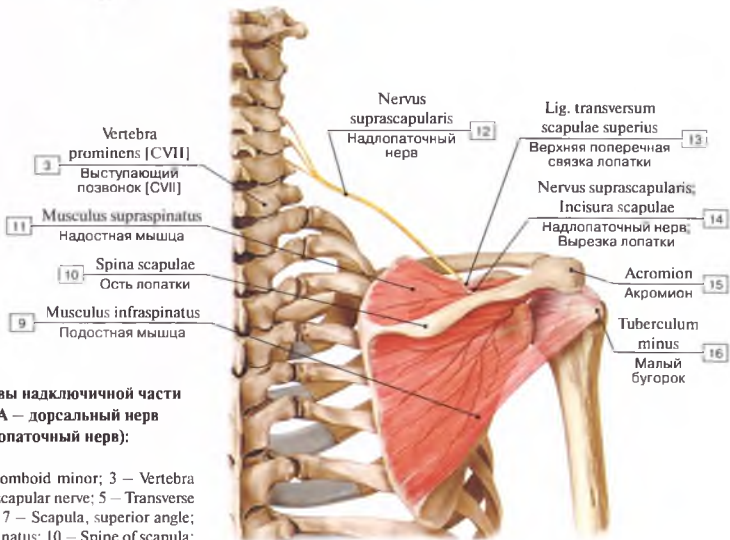


Рис. 275. Иннервация верхней конечности (схема):

1 – Common palmar digital nerves; 2 – Lateral cutaneous nerve of forearm; Lateral antebrachial cutaneous nerve; 3 – Radial nerve, superficial branch; 4 – Radial nerve, deep branch; 5 – Superior lateral cutaneous nerve of arm; Superior lateral brachial cutaneous nerve; 6 – Axillary nerve; 7 – Musculocutaneous nerve; 8 – Lateral root of median nerve; 9 – Brachial plexus, lateral cord; 10 – Lateral supraclavicular nerves; 11 – Brachial plexus, posterior cord; 12 – Brachial plexus, medial cord; 13 – Medial root of median nerve; 14 – Radial nerve; 15 – Median nerve; 16 – Medial cutaneous nerve of arm; Medial brachial cutaneous nerve; 17 – Ulnar nerve; 18 – Medial cutaneous nerve of forearm; Medial antebrachial cutaneous nerve; 19 – Ulnar nerve, superficial branch; 20 – Ulnar nerve, deep branch; 21 – Dorsal digital nerves; 22 – Proper palmar digital nerves



A



B

Рис. 276. Некоторые нервы надключичной части плечевого сплетения (А – дорсальный нерв лопатки; Б – надлопаточный нерв):

1 – Rhomboid major; 2 – Rhomboid minor; 3 – Vertebra prominens [CVII]; 4 – Dorsal scapular nerve; 5 – Transverse process; 6 – Levator scapulae; 7 – Scapula, superior angle; 8 – Medial border; 9 – Infraspinatus; 10 – Spine of scapula; 11 – Supraspinatus; 12 – Suprascapular nerve; 13 – Superior transverse scapular ligament; 14 – Suprascapular nerve; Suprascapular notch; 15 – Acromion; 16 – Lesser tubercle

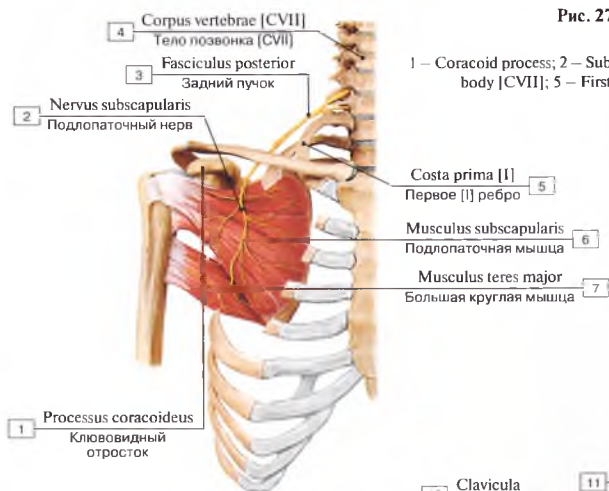


Рис. 277. Подлопаточный нерв:

1 – Coracoid process; 2 – Subscapular nerve; 3 – Posterior fascicle; 4 – Vertebral body [CVII]; 5 – First rib [I]; 6 – Subscapularis; 7 – Teres major

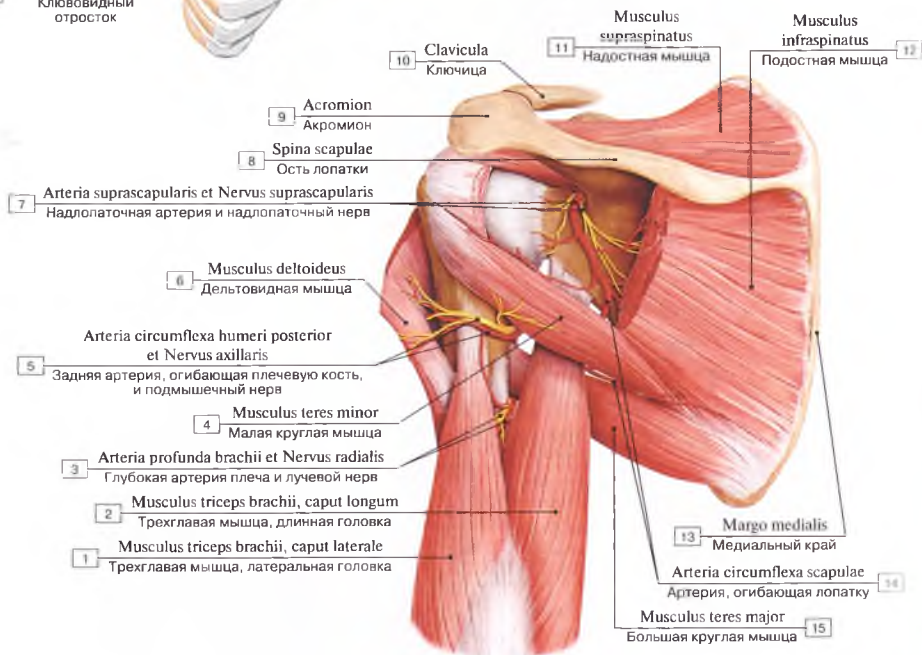


Рис. 278. Подмышечный и надлопаточный нервы:

1 – Triceps brachii, lateral head; 2 – Triceps brachii, long head; 3 – Profunda brachii artery; Deep artery of arm and Radial nerve; 4 – Teres minor; 5 – Posterior circumflex humeral artery and Axillary nerve; 6 – Deltoid; 7 – Suprascapular artery and Suprascapular nerve; 8 – Spine of scapula; 9 – Acromion; 10 – Clavicle; 11 – Supraspinatus; 12 – Infraspinatus; 13 – Medial border; 14 – Circumflex scapular artery; 15 – Teres major



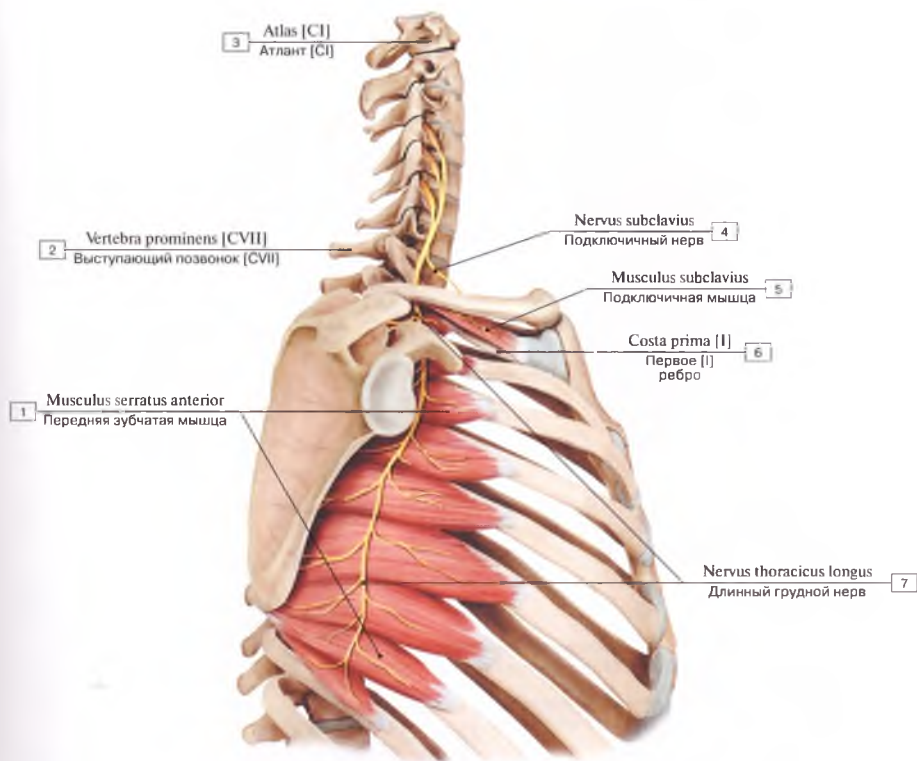


Рис. 279. Длинный грудной и подключичный нервы:

1 – Serratus anterior; 2 – Vertebra prominens [CVII]; 3 – Atlas [C1]; 4 – Subclavian nerve; 5 – Subclavius; 6 – First rib [I]; 7 – Long thoracic nerve

Рис. 280. Грудоспинайный нерв:

- 1 – Thoracolumbar fascia; 2 – Spinous process [TXII]; 3 – Spinous process [TVII];  
 4 – Thoracodorsal nerve; 5 – Latissimus dorsi; 6 – Sacrum [sacral vertebrae SI–SV];  
 7 – Iliac crest

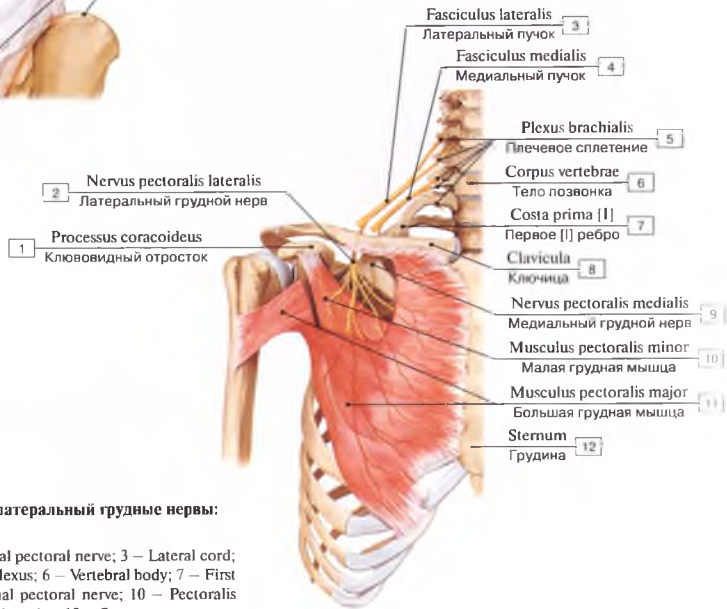
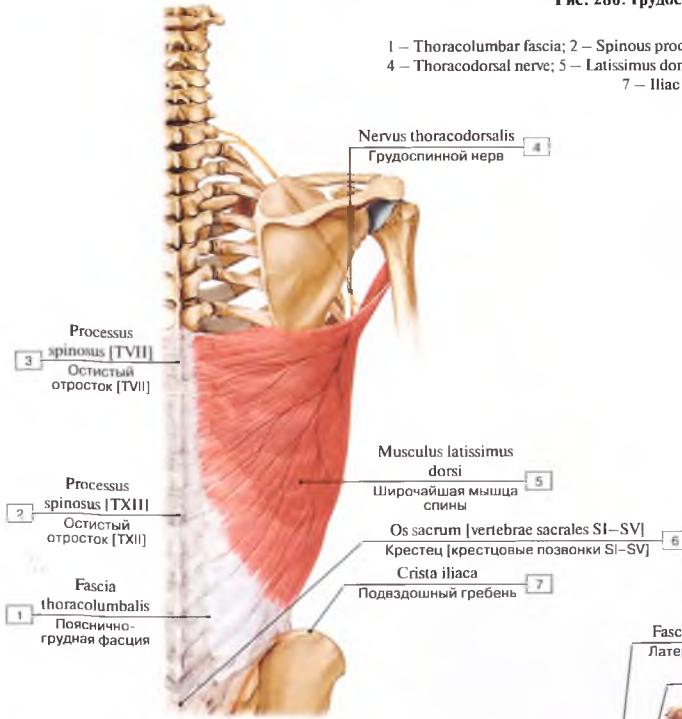


Рис. 281. Медиальный и латеральный грудные нервы:

- 1 – Coracoid process; 2 – Lateral pectoral nerve; 3 – Lateral cord;  
 4 – Medial cord; 5 – Brachial plexus; 6 – Vertebral body; 7 – First  
 rib [I]; 8 – Clavicle; 9 – Medial pectoral nerve; 10 – Pectoralis  
 minor; 11 – Pectoralis major; 12 – Sternum

Рис. 282. Подмышечный нерв:

1 – Axillary nerve; 2 – Deltoid; 3 – Teres major; 4 – Superior lateral cutaneous nerve of arm; Superior lateral brachial cutaneous nerve; 5 – Radial nerve

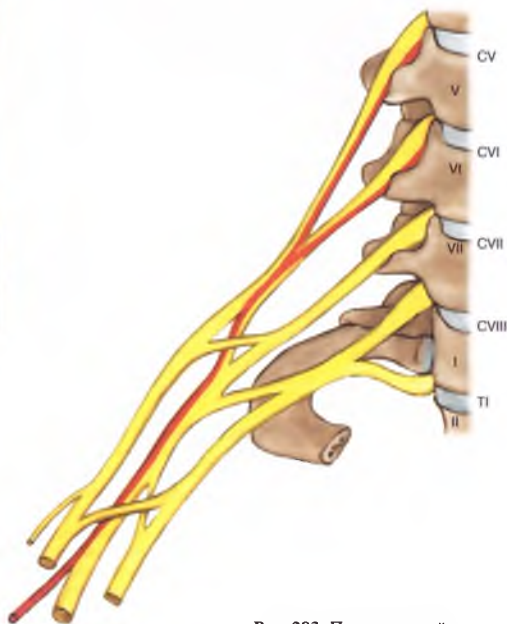
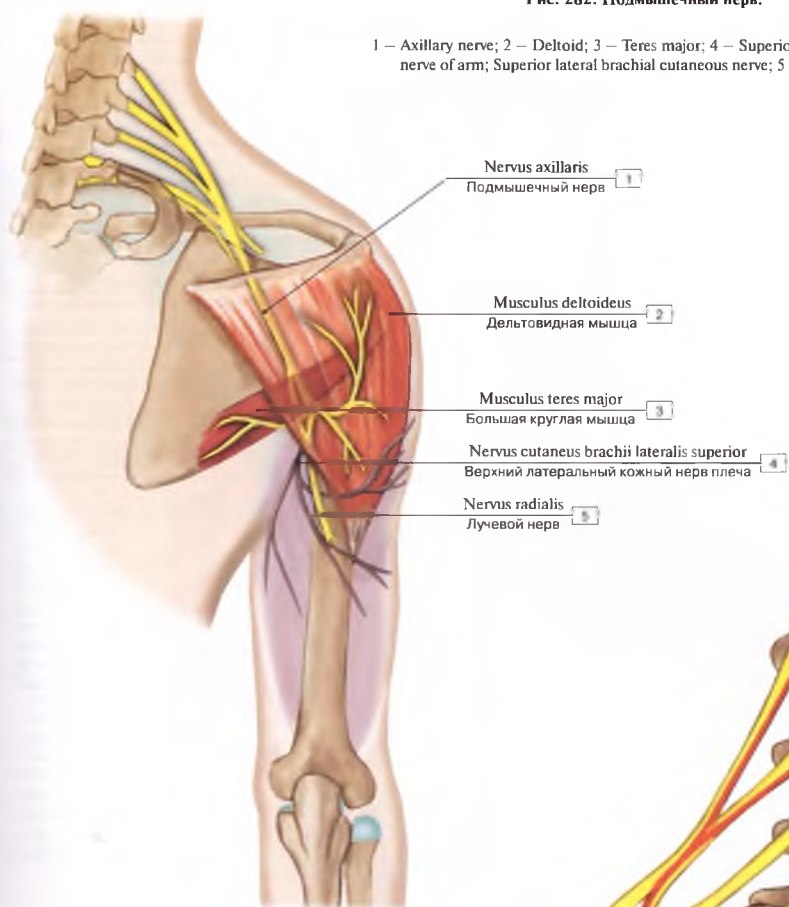


Рис. 283. Подмышечный нерв, сегментарная организация (схема)

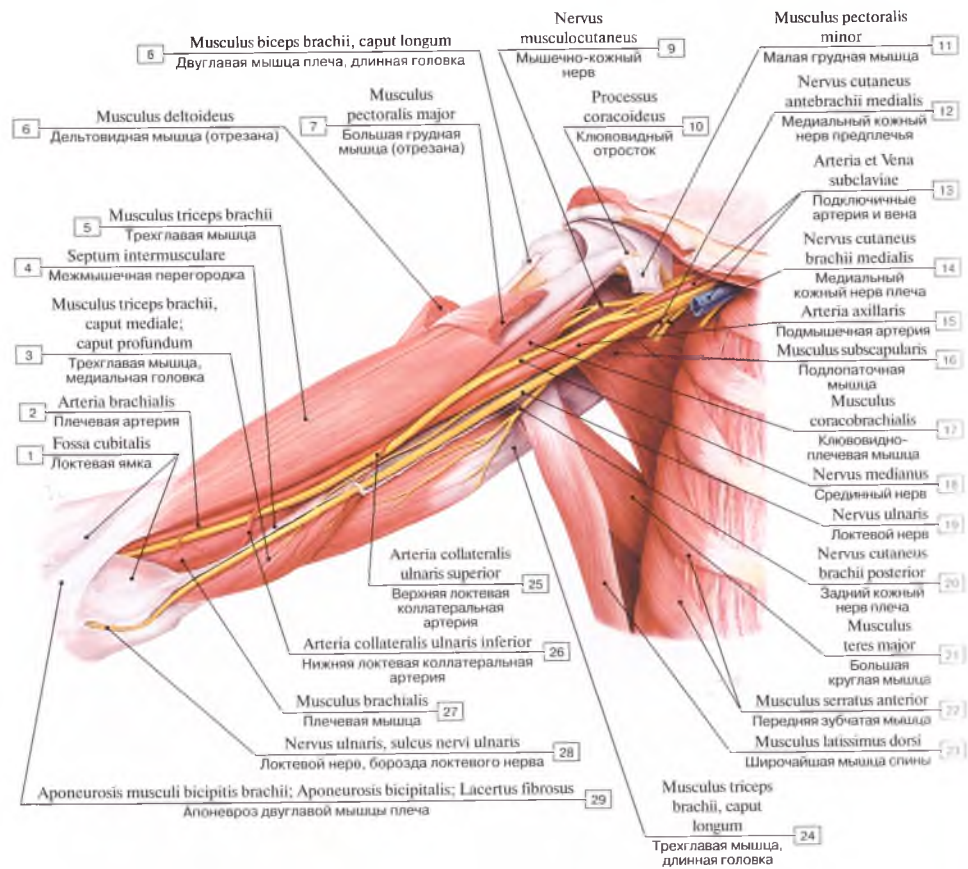


Рис. 284. Длинные ветви плечевого сплетения:

1 – Cubital fossa; 2 – Brachial artery; 3 – Triceps brachii, medial head; deep head; 4 – Intermuscular septum; 5 – Triceps brachii, short head; 6 – Deltoid; 7 – Pectoralis major; 8 – Biceps brachii, long head; 9 – Musculocutaneous nerve; 10 – Coracoid process; 11 – Pectoralis minor; 12 – Medial cutaneous nerve of forearm; Medial antebrachial cutaneous nerve; 13 – Subclavian artery and vein; 14 – Medial nerve; 15 – Ulnar nerve; 16 – Subscapularis; 17 – Coracobrachialis; 18 – Median nerve; 19 – Ulnar nerve; 20 – Posterior cutaneous nerve of arm; Posterior brachial cutaneous nerve; 21 – Teres major; 22 – Serratus anterior; 23 – Latissimus dorsi; 24 – Triceps brachii, long head; 25 – Superior ulnar collateral artery; 26 – Inferior ulnar collateral artery; 27 – Brachialis; 28 – Ulnar nerve, groove for ulnar nerve; 29 – Bicipital aponeurosis

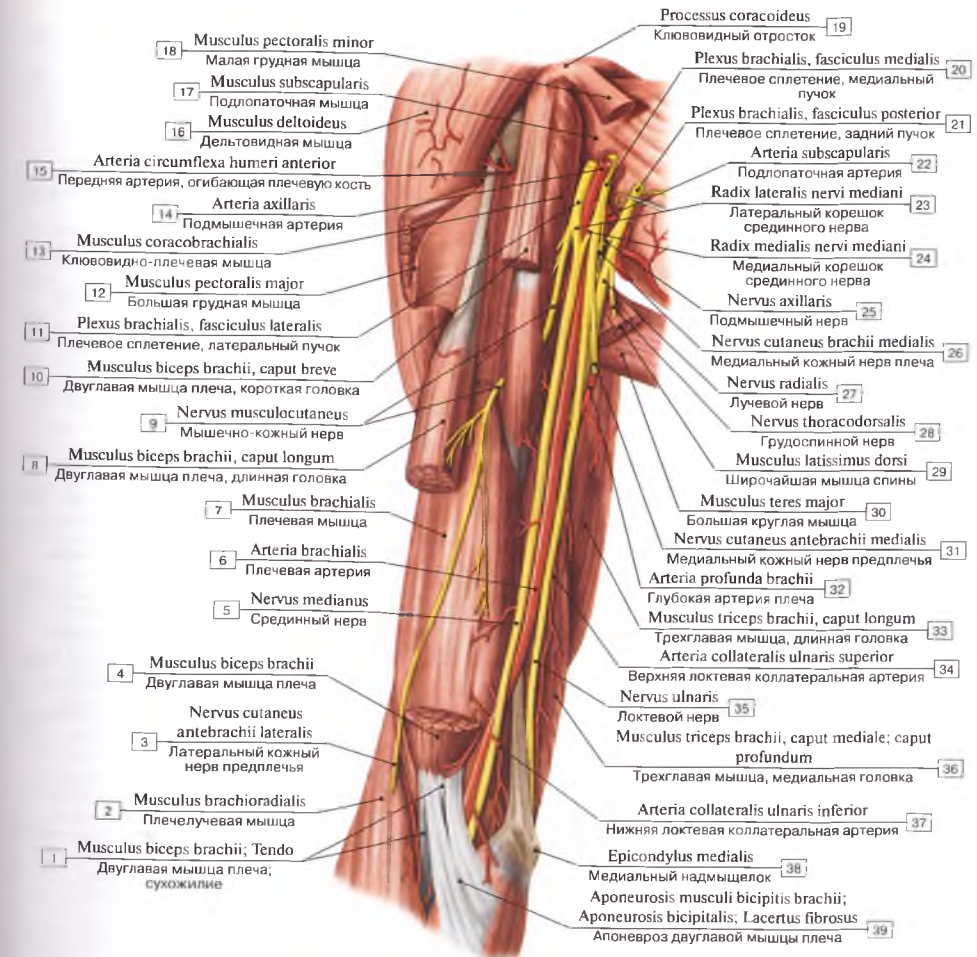
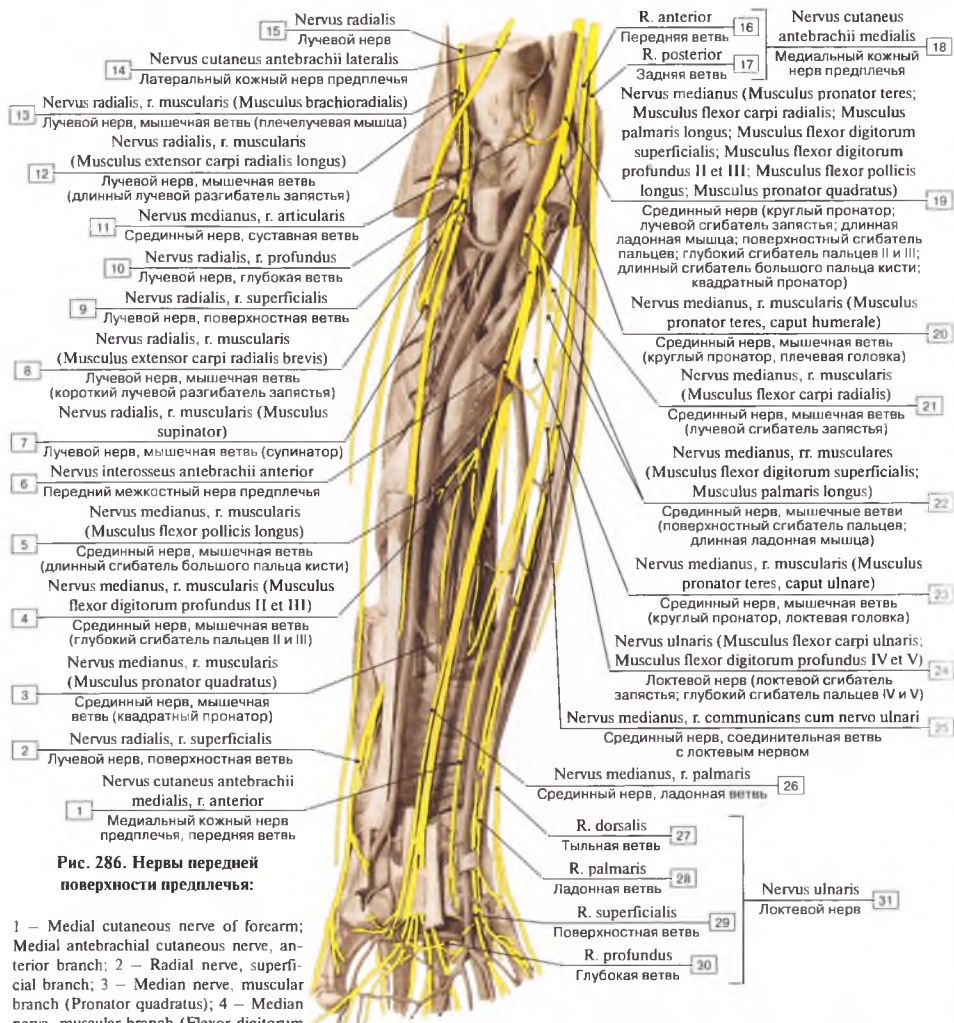


Рис. 285. Мышечно-кожный нерв и другие длинные нервы плечевого сплетения, вид спереди (двуглавая мышца плеча частично удалена):

1 – Biceps brachii; Tendon; 2 – Brachioradialis; 3 – Lateral cutaneous nerve of forearm; Lateral antebrachial cutaneous nerve; 4 – Biceps brachii, short head; 5 – Median nerve; 6 – Brachial artery; 7 – Brachialis; 8 – Biceps brachii, long head; 9 – Musculocutaneous nerve; 10 – Biceps brachii, long head; 11 – Brachial plexus, lateral cord; 12 – Pectoralis major; 13 – Coracobrachialis; 14 – Axillary artery; 15 – Anterior circumflex humeral artery; 16 – Deltoid; 17 – Subscapularis; 18 – Pectoralis minor; 19 – Coracoid process; 20 – Brachial plexus, medial cord; 21 – Brachial plexus, posterior cord; 22 – Subscapular artery; 23 – Lateral root of median nerve; 24 – Medial root of median nerve; 25 – Axillary nerve; 26 – Medial cutaneous nerve of arm; Medial brachial cutaneous nerve; 27 – Radial nerve; 28 – Thoracodorsal nerve; 29 – Latissimus dorsi; 30 – Teres major; 31 – Medial cutaneous nerve of forearm; Medial antebrachial cutaneous nerve; 32 – Profunda brachii artery; Deep artery of arm; 33 – Triceps brachii, long head; 34 – Superior ulnar collateral artery; 35 – Ulnar nerve; 36 – Triceps brachii, medial head; deep head; 37 – Inferior ulnar collateral artery; 38 – Medial epicondyle; 39 – Bicipital aponeurosis



**Рис. 286. Нервы передней поверхности предплечья:**

1 – Medial cutaneous nerve of forearm; Medial antebrachial cutaneous nerve, anterior branch; 2 – Radial nerve, superficial branch; 3 – Median nerve, muscular branch (Pronator quadratus); 4 – Median nerve, muscular branch (Flexor digitorum profundus II and III); 5 – Median nerve, muscular branch (Flexor pollicis longus); 6 – Anterior interosseous nerve; 7 – Radial nerve, muscular branch (Supinator); 8 – Radial nerve, muscular branch (Extensor carpi radialis brevis); 9 – Radial nerve, superficial branch; 10 – Radial nerve, deep branch; 11 – Median nerve, articular branch; 12 – Radial nerve, muscular branch (Extensor carpi radialis longus); 13 – Radial nerve, muscular branch (Brachioradialis); 14 – Lateral cutaneous nerve of forearm; Lateral antebrachial cutaneous nerve; 15 – Radial nerve, muscular branch (Brachioradialis); 16 – Anterior branch; 17 – Posterior branch; 18 = 16 + 17 – Medial cutaneous nerve of forearm; Medial antebrachial cutaneous nerve; 19 – Median nerve (Pronator teres; Flexor carpi radialis; Palmaris longus; Flexor digitorum superficialis; Flexor digitorum profundus II and III; Flexor pollicis longus; Pronator quadratus); 20 – Median nerve, muscular branches (Pronator teres, humeral head); 21 – Median nerve, muscular branch (Flexor carpi radialis); 22 – Median nerve, muscular branches (Flexor digitorum superficialis; Palmaris longus); 23 – Median nerve, muscular branch (Pronator teres, ulnar head); 24 – Ulnar nerve (Flexor carpi ulnaris; Flexor digitorum profundus IV and V); 25 – Median nerve, communicating branch with ulnar nerve; 26 – Median nerve, palmar branch; 27 – Dorsal branch; 28 – Palmar branch; 29 – Superficial branch; 30 – Deep branch; 31 = 27 + 28 + 29 + 30 – Ulnar nerve

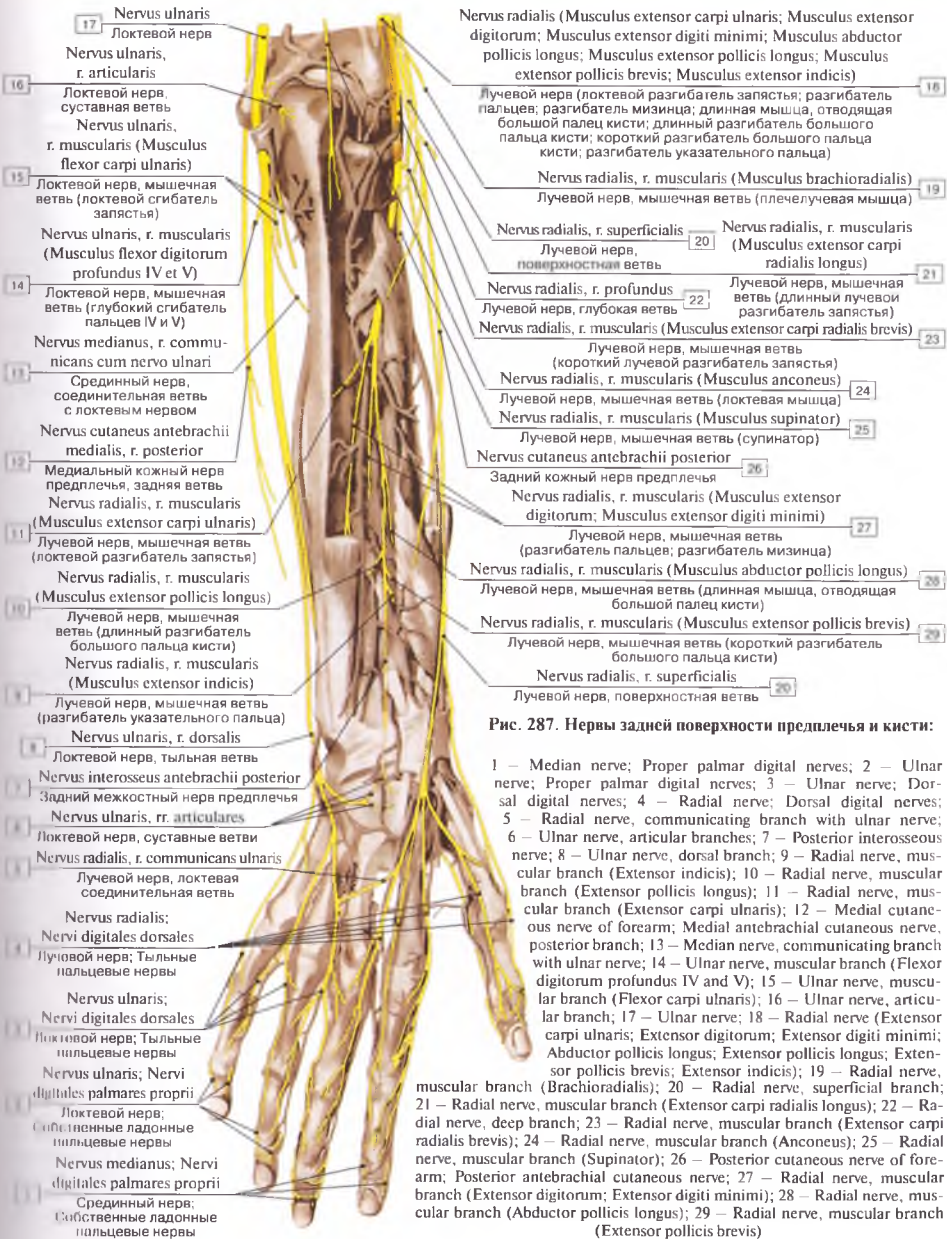


Рис. 287. Нервы задней поверхности предплечья и кисти:

1 – Median nerve; Proper palmar digital nerves; 2 – Ulnar nerve; Proper palmar digital nerves; 3 – Ulnar nerve; Dorsal digital nerves; 4 – Radial nerve; Dorsal digital nerves; 5 – Radial nerve, communicating branch with ulnar nerve; 6 – Ulnar nerve, articular branches; 7 – Posterior interosseous nerve; 8 – Ulnar nerve, dorsal branch; 9 – Radial nerve, muscular branch (Extensor indicis); 10 – Radial nerve, muscular branch (Extensor pollicis longus); 11 – Radial nerve, muscular branch (Extensor carpi ulnaris); 12 – Medial cutaneous nerve of forearm; 13 – Median nerve, communicating branch with ulnar nerve; 14 – Ulnar nerve, muscular branch (Flexor digitorum profundus IV and V); 15 – Ulnar nerve, muscular branch (Flexor carpi ulnaris); 16 – Ulnar nerve, articular branch; 17 – Ulnar nerve; 18 – Radial nerve (Extensor carpi ulnaris; Extensor digitorum; Extensor digiti minimi; Abductor pollicis longus; Extensor pollicis longus; Extensor pollicis brevis; Extensor indicis); 19 – Radial nerve, muscular branch (Brachioradialis); 20 – Radial nerve, superficial branch (Extensor carpi radialis longus); 21 – Radial nerve, muscular branch (Extensor carpi radialis longus); 22 – Radial nerve, deep branch (Extensor carpi radialis brevis); 23 – Radial nerve, muscular branch (Extensor carpi radialis brevis); 24 – Radial nerve, muscular branch (Anconeus); 25 – Radial nerve, muscular branch (Supinator); 26 – Posterior cutaneous nerve of forearm; 27 – Radial nerve, muscular branch (Extensor digitorum; Extensor digiti minimi); 28 – Radial nerve, muscular branch (Abductor pollicis longus); 29 – Radial nerve, muscular branch (Extensor pollicis longus); 30 – Radial nerve, superficial branch (Extensor pollicis brevis)

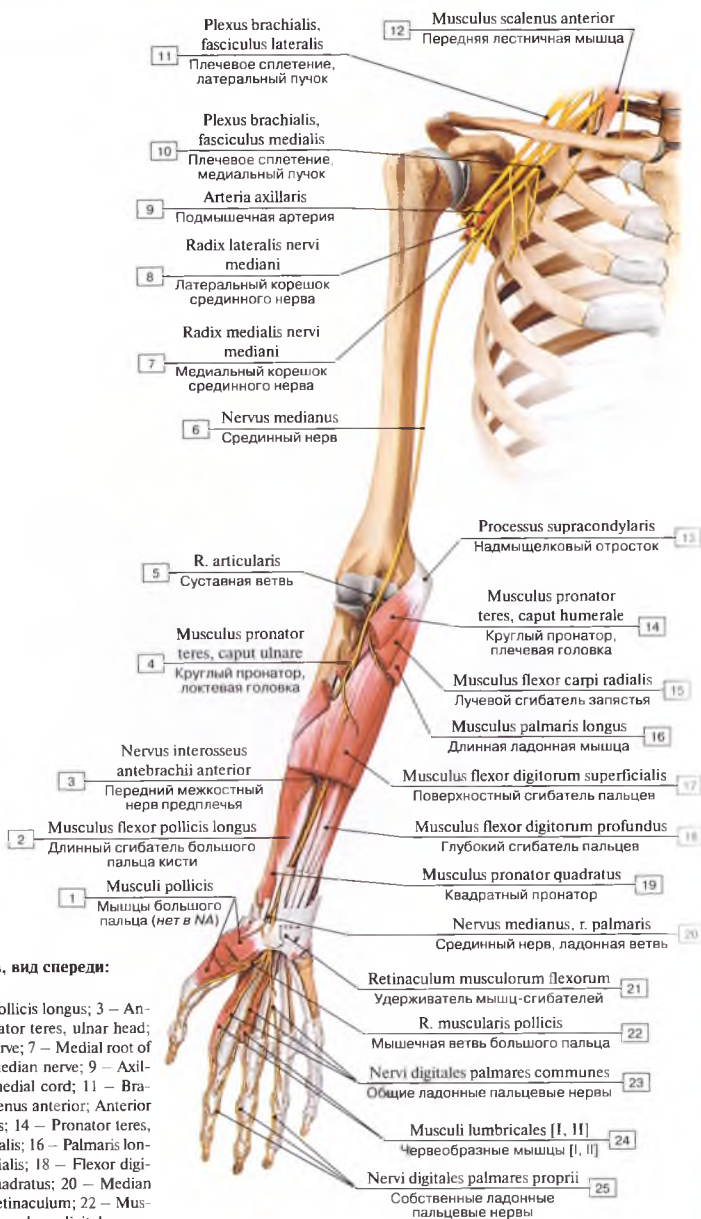


Рис. 288. Срединный нерв, вид спереди:

1 – Muscles of pollex; 2 – Flexor pollicis longus; 3 – Anterior interosseous nerve; 4 – Pronator teres, ulnar head; 5 – Articular branch; 6 – Median nerve; 7 – Medial root of median nerve; 8 – Lateral root of median nerve; 9 – Axillary artery; 10 – Brachial plexus, medial cord; 11 – Brachial plexus, lateral cord; 12 – Scalenus anterior; Anterior scalene; 13 – Supracondylar process; 14 – Pronator teres, humeral head; 15 – Flexor carpi radialis; 16 – Palmaris longus; 17 – Flexor digitorum superficialis; 18 – Flexor digitorum profundus; 19 – Pronator quadratus; 20 – Median nerve, palmar branch; 21 – Flexor retinaculum; 22 – Muscular branch of pollex; 23 – Common palmar digital nerves; 24 – Lumbricals [I, II]; 25 – Proper palmar digital nerves

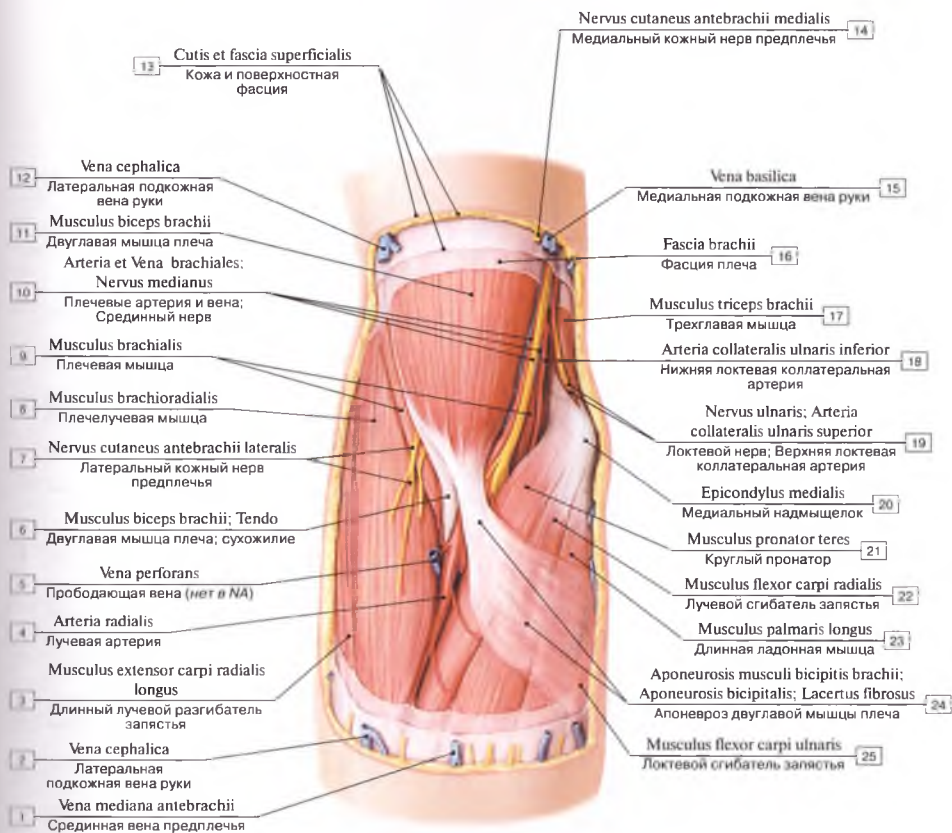


Рис. 289. Ход срединного нерва в локтевой ямке:

1 — Median antebrachial vein; Median vein of forearm; 2 — Cephalic vein; 3 — Extensor carpi radialis longus; 4 — Radial artery; 5 — Perforating vein; 6 — Biceps brachii; Tendon; 7 — Lateral cutaneous nerve of forearm; Lateral antebrachial cutaneous nerve; 8 — Brachioradialis; 9 — Brachialis; 10 — Brachial artery and vein; Median nerve; 11 — Biceps brachii; 12 — Cephalic vein; 13 — Skin and Superficial fascia; 14 — Medial cutaneous nerve of forearm; Medial antebrachial cutaneous nerve; 15 — Basilic vein; 16 — Brachial fascia; 17 — Triceps brachii; 18 — Inferior ulnar collateral artery; 19 — Ulnar nerve; Superior ulnar collateral artery; 20 — Medial epicondyle; 21 — Pronator teres; 22 — Flexor carpi radialis; 23 — Palmaris longus; 24 — Bicipital aponeurosis; 25 — Flexor carpi ulnaris



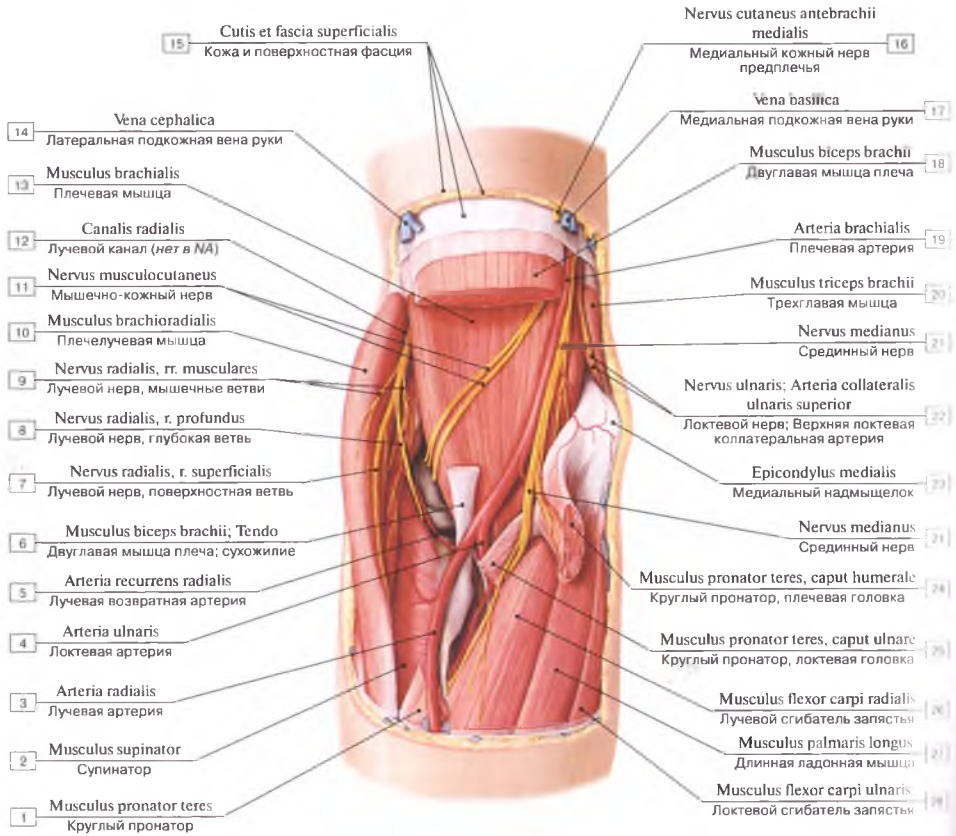


Рис. 290. Ход срединного нерва в локтевой ямке:

1 – Pronator teres; 2 – Supinator; 3 – Radial artery; 4 – Ulnar artery; 5 – Radial recurrent artery; 6 – Biceps brachii; Tendon; 7 – Radial nerve, superficial branch; 8 – Radial nerve, deep branch; 9 – Radial nerve, muscular branches; 10 – Brachioradialis; 11 – Musculocutaneous nerve; 12 – Radial tunnel; 13 – Brachialis; 14 – Cephalic vein; 15 – Skin and Superficial fascia; 16 – Medial cutaneous nerve of forearm; Medial antebrachial cutaneous nerve; 17 – Basilic vein; 18 – Biceps brachii; 19 – Brachial artery; 20 – Triceps brachii; 21 – Median nerve; 22 – Ulnar nerve; Superior ulnar collateral artery; 23 – Medial epicondyle; 24 – Pronator teres, humeral head; 25 – Pronator teres, ulnar head; 26 – Flexor carpi radialis; 27 – Palmaris longus; 28 – Flexor carpi ulnaris

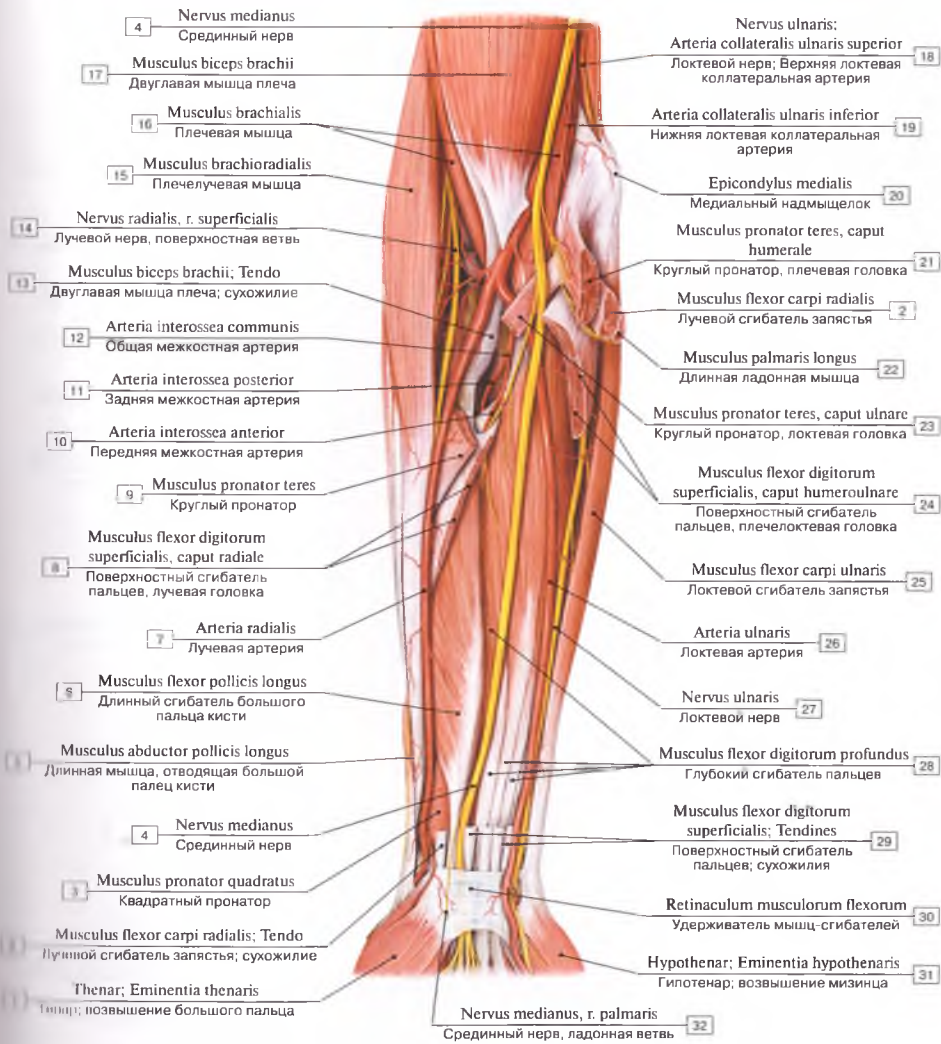


Рис. 291. Ход срединного нерва в локтевой ямке и на предплечье:

- 1 — Thenar eminence; 2 — Flexor carpi radialis; Tendon; 3 — Pronator quadratus; 4 — Median nerve; 5 — Abductor pollicis longus; 6 — Flexor pollicis longus; 7 — Radial artery; 8 — Flexor digitorum superficialis, radial head; 9 — Pronator teres; 10 — Anterior interosseous artery; 11 — Posterior interosseous artery; 12 — Common interosseous artery; 13 — Biceps brachii; Tendon; 14 — Radial nerve, superficial branch; 15 — Brachioradialis; 16 — Brachialis; 17 — Biceps brachii; 18 — Ulnar nerve; Superior ulnar collateral artery; 19 — Inferior ulnar collateral artery; 20 — Medial epicondyle; 21 — Pronator teres, humeral head; 22 — Palmaris longus; 23 — Pronator teres, ulnar head; 24 — Flexor digitorum superficialis, humero-ulnar head; 25 — Flexor carpi ulnaris; 26 — Ulnar artery; 27 — Ulnar nerve; 28 — Flexor digitorum profundus; 29 — Flexor digitorum superficialis; Tendons; 30 — Flexor retinaculum; 31 — Hypothenar eminence; 32 — Median nerve, palmar branch

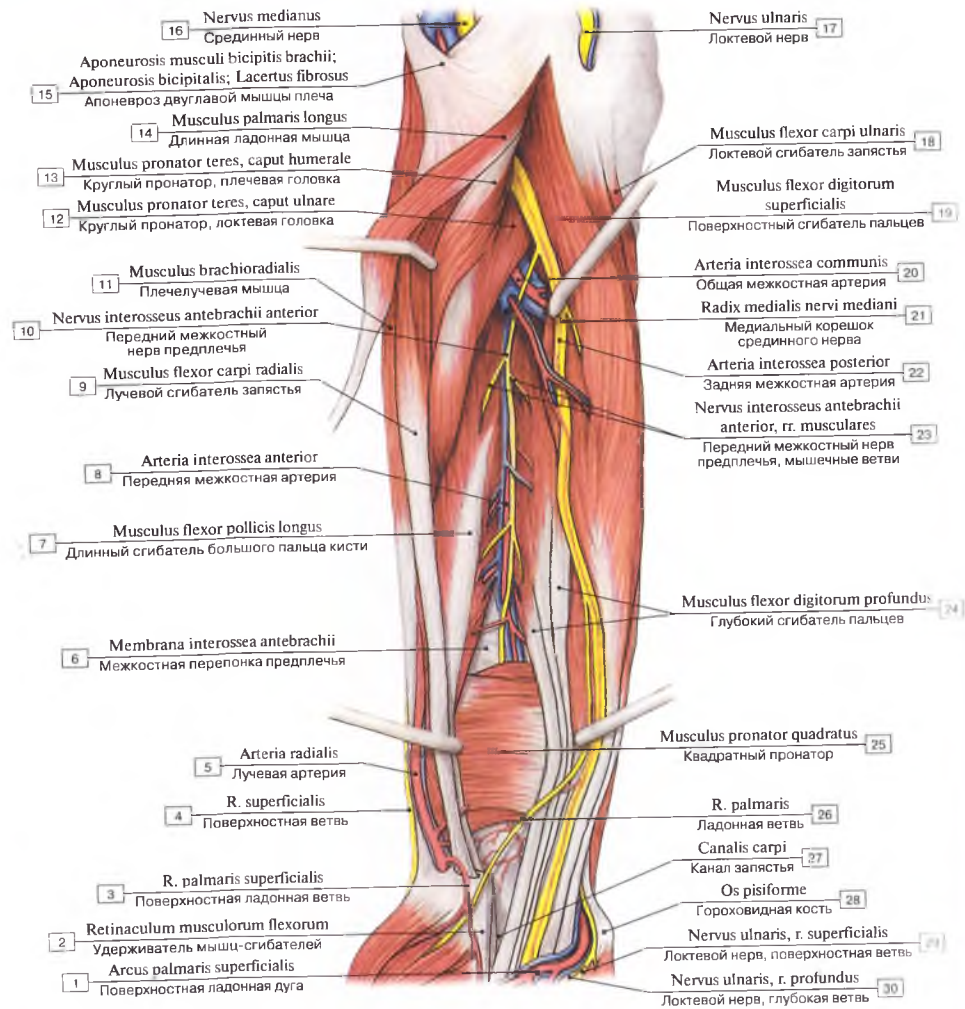


Рис. 292. Срединный и передний межкостные нервы предплечья:

1 – Superficial palmar arch; 2 – Flexor retinaculum; 3 – Superficial palmar branch; 4 – Superficial branch; 5 – Radial artery; 6 – Interosseous membrane of forearm; 7 – Flexor pollicis longus; 8 – Anterior interosseous artery; 9 – Flexor carpi radialis; 10 – Anterior interosseous nerve; 11 – Brachioradialis; 12 – Pronator teres, humeral head; 13 – Pronator teres, ulnar head; 14 – Palmaris longus; 15 – Bicipital aponeurosis; 16 – Median nerve; 17 – Ulnar nerve; 18 – Flexor carpi ulnaris; 19 – Flexor digitorum superficialis; 20 – Common interosseous artery; 21 – Medial root of median nerve; 22 – Posterior interosseous artery; 23 – Anterior interosseous nerve, muscular branches; 24 – Flexor digitorum profundus; 25 – Pronator quadratus; 26 – Palmar branch; 27 – Carpal tunnel; 28 – Pisiform; 29 – Ulnar nerve, superficial branch; 30 – Ulnar nerve, deep branch

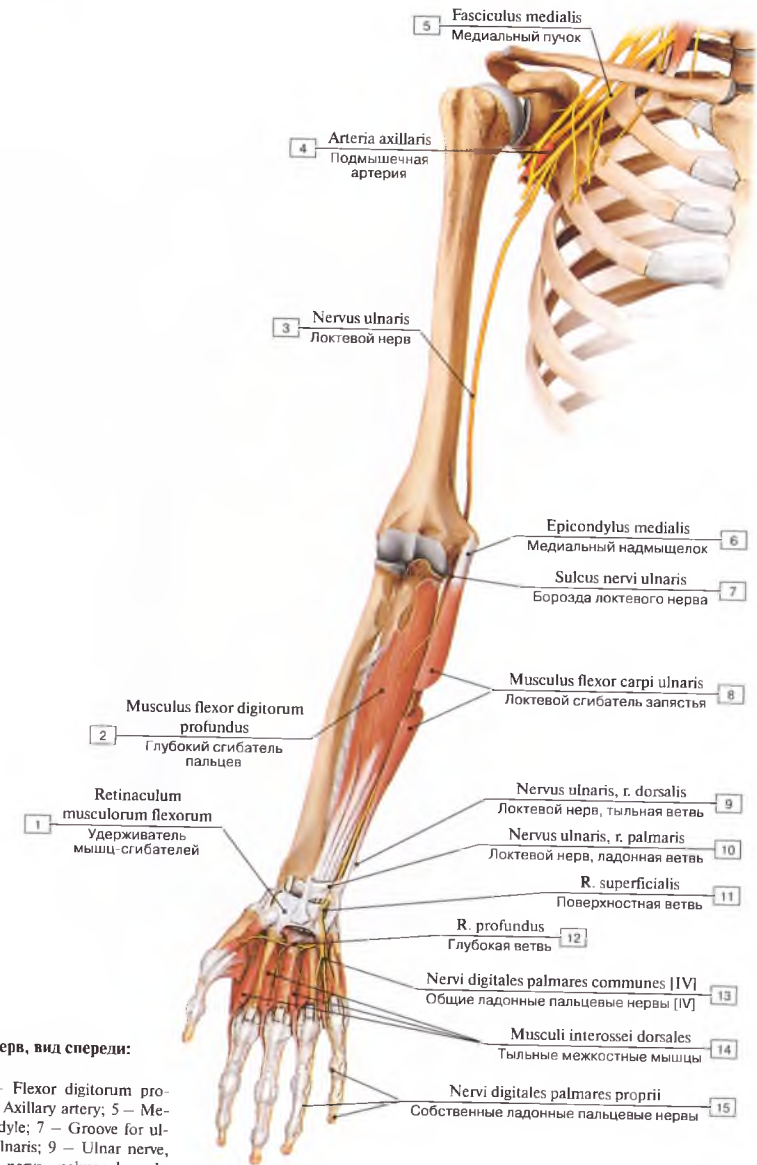


Рис. 293. Локтевой нерв, вид спереди:

1 – Flexor retinaculum; 2 – Flexor digitorum profundus; 3 – Ulnar nerve; 4 – Axillary artery; 5 – Medial cord; 6 – Medial epicondyle; 7 – Groove for ulnar nerve; 8 – Flexor carpi ulnaris; 9 – Ulnar nerve, dorsal branch; 10 – Ulnar nerve, palmar branch; 11 – Superficial branch; 12 – Deep branch; 13 – Common palmar digital nerves [IV]; 14 – Dorsal interossei; 15 – Proper palmar digital nerves



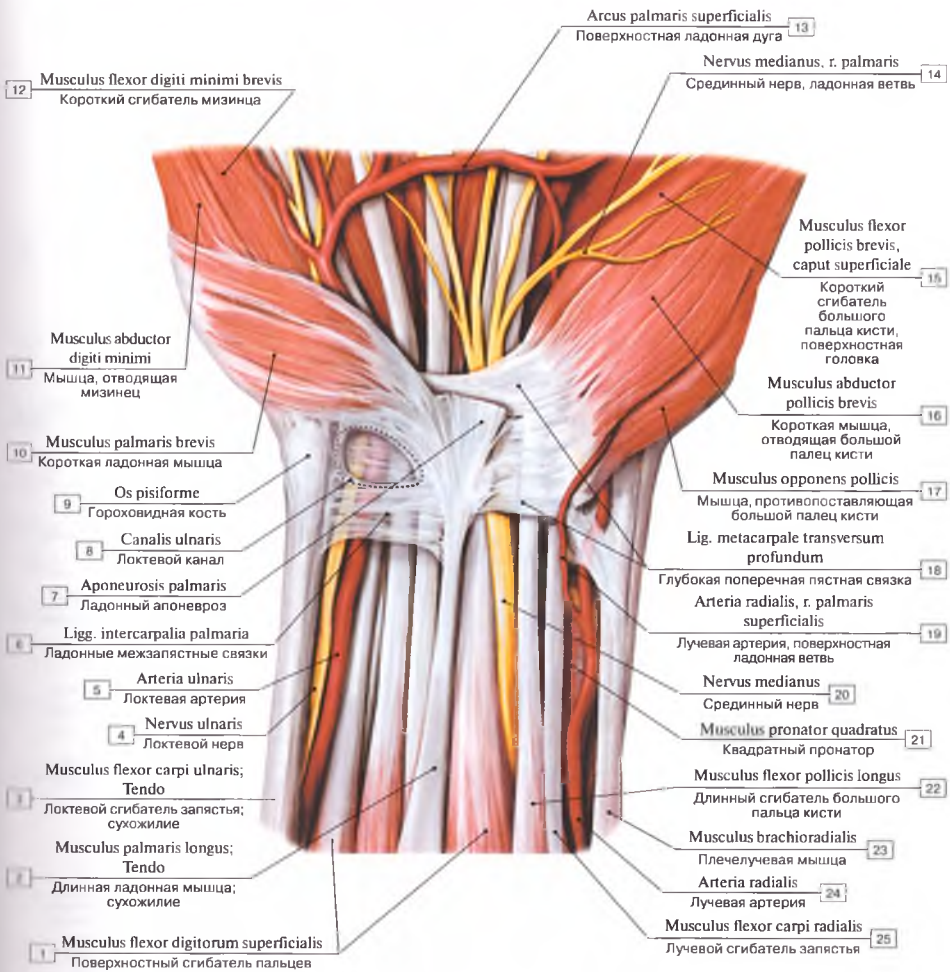


Рис. 295. Ход срединного нерва в канале запястья, правого:

- 1 – Flexor digitorum superficialis; 2 – Palmaris longus; Tendon; 3 – Flexor carpi ulnaris; Tendon; 4 – Ulnar nerve; 5 – Ulnar artery; 6 – Palmar intercarpal ligaments; 7 – Palmar aponeurosis; 8 – Ulnar canal; 9 – Pisiform; 10 – Palmaris brevis; 11 – Abductor digiti minimi; 12 – Flexor digiti minimi brevis; 13 – Superficial palmar arch; 14 – Median nerve, palmar branch; 15 – Flexor pollicis brevis, superficial head; 16 – Abductor pollicis brevis; 17 – Opponens pollicis; 18 – Deep transverse metacarpal ligament; 19 – Radial artery, superficial palmar branch; 20 – Median nerve; 21 – Pronator quadratus; 22 – Flexor pollicis longus; 23 – Brachioradialis; 24 – Radialis artery; 25 – Flexor carpi radialis

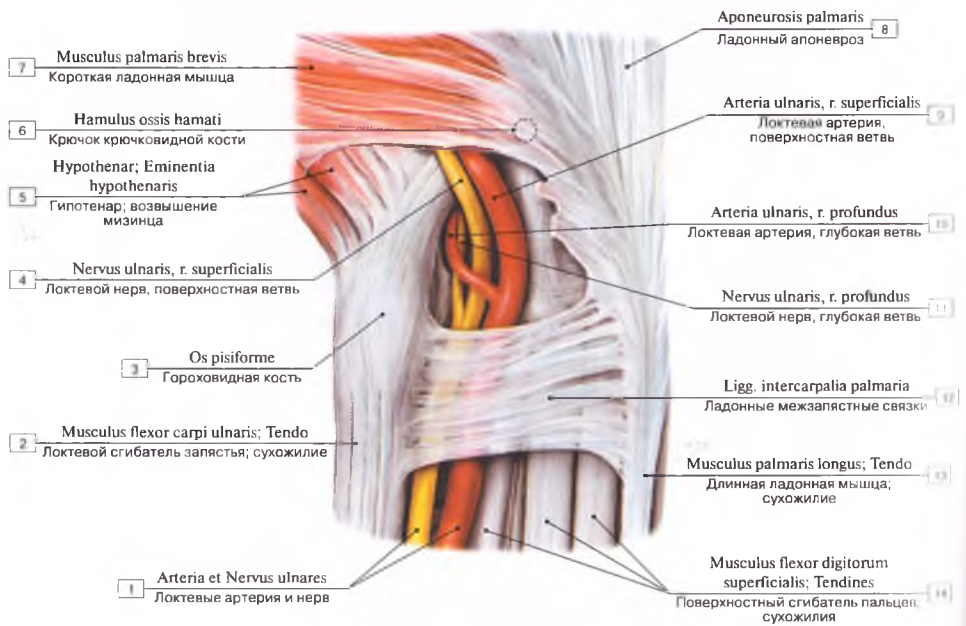


Рис. 296. Ход локтевого нерва и локтевой артерии в области лучезапястного сустава:

1 – Ulnar artery and nerve; 2 – Flexor carpi ulnaris; Tendon; 3 – Pisiform; 4 – Ulnar nerve, superficial branch; 5 – Hypothenar eminence; 6 – Hook of hamate; 7 – Palmaris brevis; 8 – Palmar aponeurosis; 9 – Ulnar artery, superficial branch; 10 – Ulnar artery, deep branch; 11 – Ulnar nerve, deep branch; 12 – Palmar intercarpal ligaments; 13 – Palmaris longus; Tendon; 14 – Flexor digitorum superficialis; Tendons

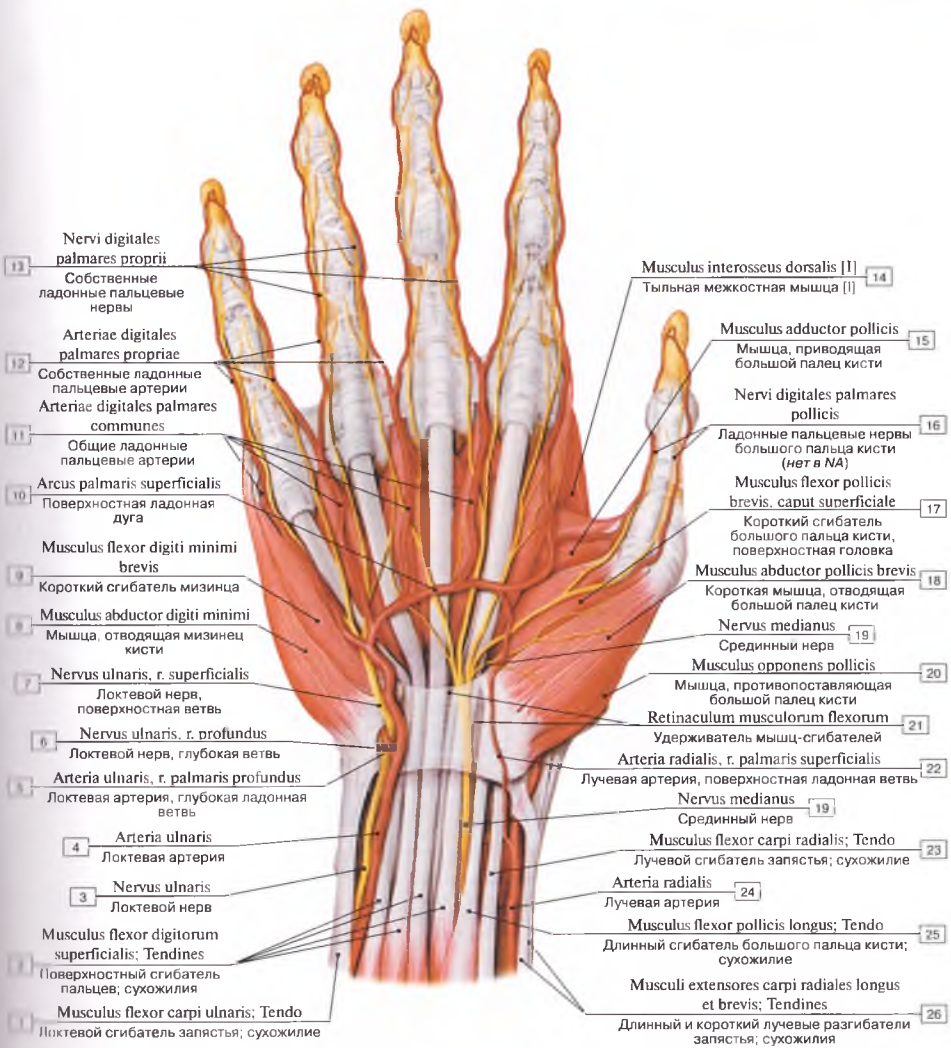


Рис. 297. Нервы и артерии ладонной поверхности кисти:

1 – Flexor carpi ulnaris; Tendon; 2 – Flexor digitorum superficialis; Tendons; 3 – Ulnar nerve; 4 – Ulnar artery; 5 – Ulnar artery, deep branch; 6 – Ulnar nerve, deep branch; 7 – Ulnar nerve, superficial branch; 8 – Abductor digiti minimi; 9 – Flexor digiti minimi brevis; 10 – Superficial palmar arch; 11 – Common palmar digital arteries; 12 – Proper palmar digital arteries; 13 – Proper palmar digital nerves; 14 – Dorsal interosseus I; 15 – Adductor pollicis; 16 – Palmar digital nerves of pollex; 17 – Flexor pollicis brevis, superficial head; 18 – Abductor pollicis brevis; 19 – Median nerve; 20 – Opponens pollicis; 21 – Flexor retinaculum; 22 – Radial artery, superficial palmar branch; 23 – Flexor carpi radialis; 24 – Radial artery; 25 – Flexor pollicis longus; Tendon; 26 – Extensor carpi radialis longus and brevis; Tendons

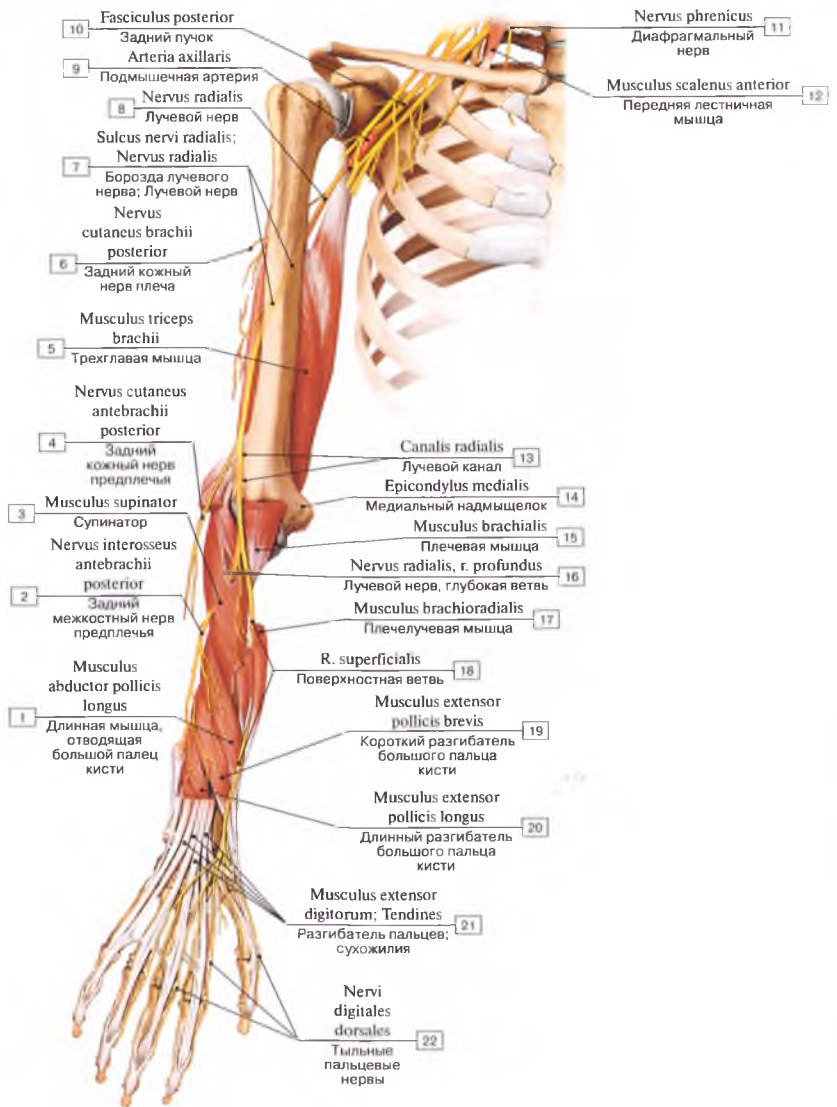


Рис. 298. Лучевой нерв, вид спереди:

1 — Abductor pollicis longus; 2 — Posterior interosseous nerve; 3 — Supinator; 4 — Posterior cutaneous nerve of forearm; Posterior antebrachial cutaneous nerve; 5 — Triceps brachii; 6 — Posterior cutaneous nerve of arm; Posterior brachial cutaneous nerve; 7 — Radial groove; Groove for radial nerve; Radial nerve; 8 — Radial nerve; 9 — Axillary artery; 10 — Posterior cord; 11 — Phrenic nerve; 12 — Scalenus anterior; Anterior scalene; 13 — Radial tunnel; 14 — Medial epicondyle; 15 — Brachialis; 16 — Radial nerve, deep branch; 17 — Brachioradialis; 18 — Superficial branch; 19 — Extensor pollicis brevis; 20 — Extensor pollicis longus; 21 — v; 22 — Dorsal digital branches



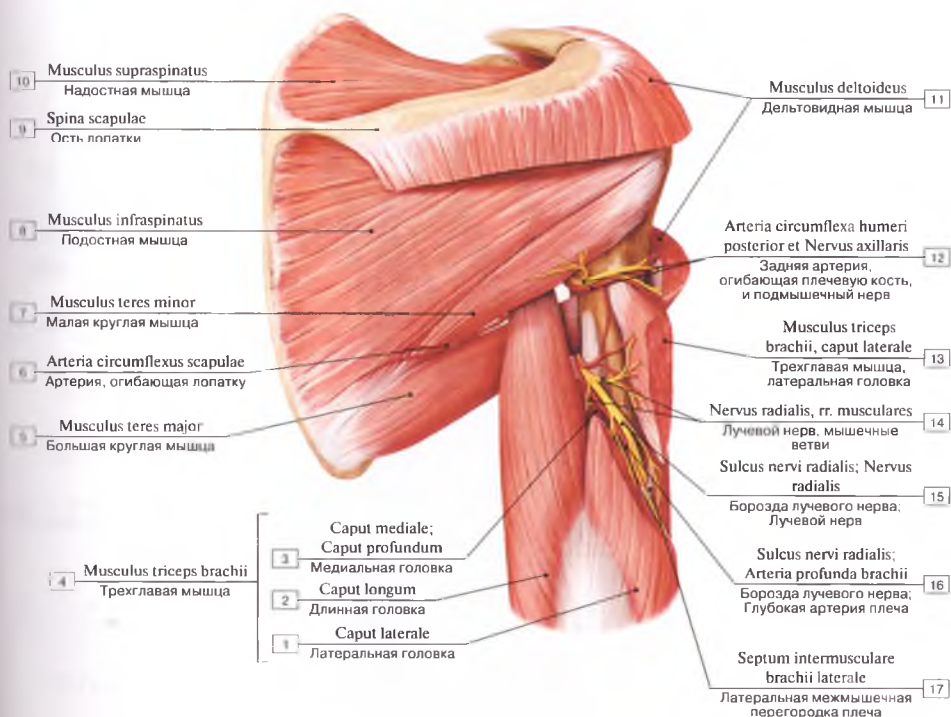


Рис. 299. Расположение лучевого нерва в одноименном канале, вид сзади:

1 – Lateral head; 2 – Long head; 3 – Medial head; Deep head; 4 = 1 + 2 + 3 – Triceps brachii; 5 – Teres major; 6 – Circumflex scapular artery; 7 – Teres minor; 8 – Infraspinatus; 9 – Spine of scapula; 10 – Supraspinatus; 11 – Deltoid; 12 – Posterior circumflex humeral artery and Axillary nerve; 13 – Triceps brachii, lateral head; 14 – Radial nerve, muscular branches; 15 – Radial groove; Groove for radial nerve; Radial nerve; 16 – Radial groove; Groove for radial nerve; Profunda brachii artery; Deep artery of arm; 17 – Lateral intermuscular septum of arm

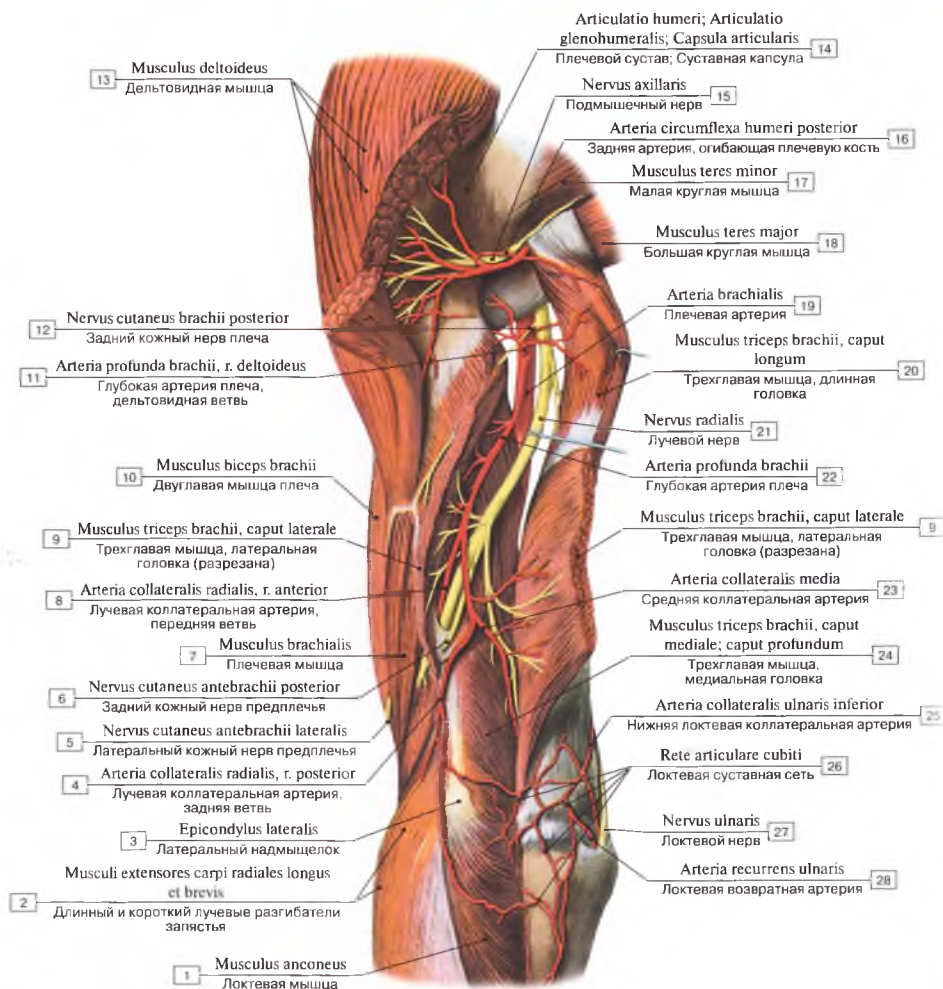


Рис. 300. Лучевой нерв и его взаимоотношение с плечевой артерией:

1 – Anconeus; 2 – Extensor carpi radialis longus and brevis; 3 – Lateral epicondyle; 4 – Radial collateral artery, posterior branch; 5 – Lateral cutaneous nerve of forearm; Lateral antebrachial cutaneous nerve; 6 – Posterior cutaneous nerve of forearm; Posterior antebrachial cutaneous nerve; 7 – Brachialis; 8 – Radial collateral artery, anterior branch; 9 – Triceps brachii, lateral head; 10 – Biceps brachii; 11 – Profunda brachii artery; Deep artery of arm, deltoid branch; 12 – Posterior cutaneous nerve of arm; Posterior brachial cutaneous nerve; 13 – Deltoid; 14 – Glenohumeral joint; Shoulder joint; Joint capsule; Articular capsule; 15 – Axillary nerve; 16 – Posterior circumflex humeral artery; 17 – Teres minor; 18 – Teres major; 19 – Brachial artery; 20 – Triceps brachii, long head; 21 – Radial nerve; 22 – Profunda brachii artery; Deep artery of arm; 23 – Medial collateral artery; 24 – Triceps brachii, medial head; deep head; 25 – Inferior ulnar collateral artery; 26 – Cubital anastomosis; 27 – Ulnar nerve; 28 – Ulnar recurrent artery

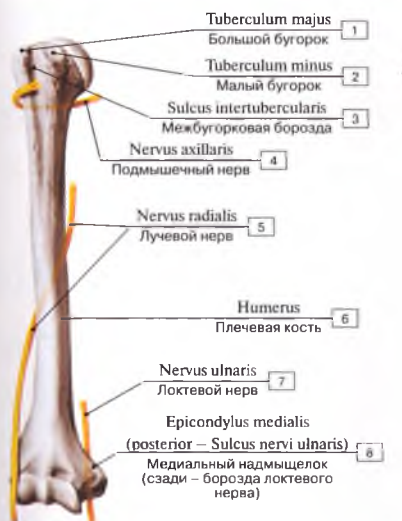


Рис. 301. Взаимоотношения подмышечного лучевого и локтевого нервов с плечевой костью (схема):

1 – Greater tubercle; 2 – Lesser tubercle; 3 – Intertubercular sulcus; Bicipital groove; 4 – Axillary nerve; 5 – Radial nerve; 6 – Humerus; 7 – Ulnar nerve; 8 – Medial epicondyle (posterior – Groove for radial nerve)

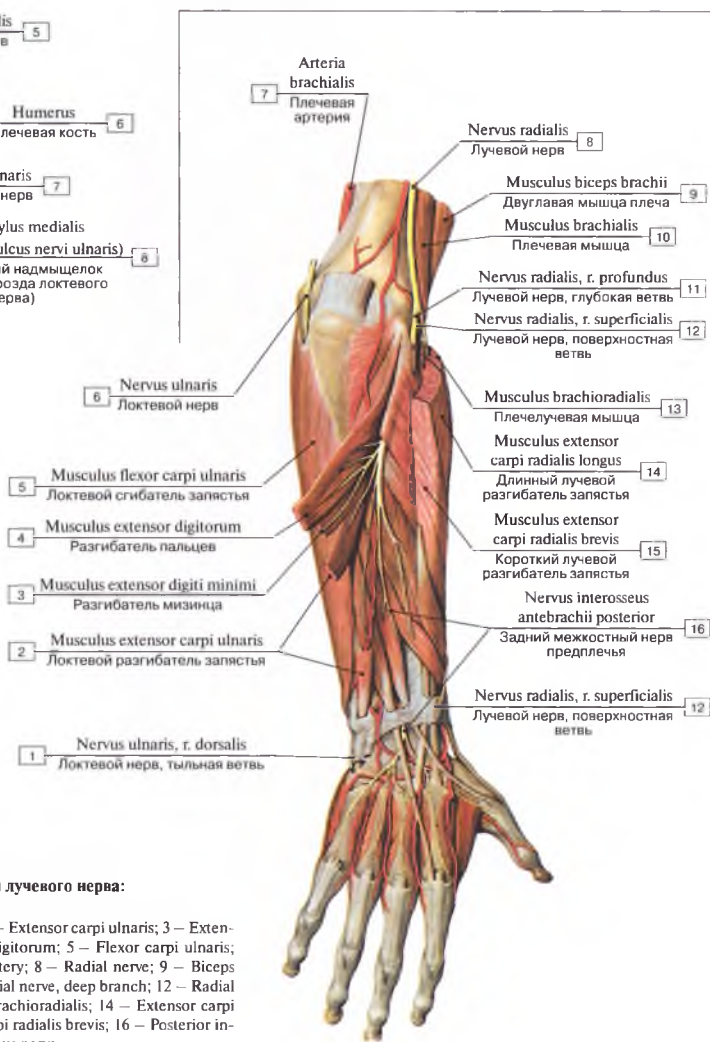


Рис. 302. Ветви лучевого нерва:

1 – Ulnar nerve, dorsal branch; 2 – Extensor carpi ulnaris; 3 – Extensor digiti minimi; 4 – Extensor digitorum; 5 – Flexor carpi ulnaris; 6 – Ulnar nerve; 7 – Brachial artery; 8 – Radial nerve; 9 – Biceps brachii; 10 – Brachialis; 11 – Radial nerve, deep branch; 12 – Radial nerve, superficial branch; 13 – Brachioradialis; 14 – Extensor carpi radialis longus; 15 – Extensor carpi radialis brevis; 16 – Posterior interosseous nerve

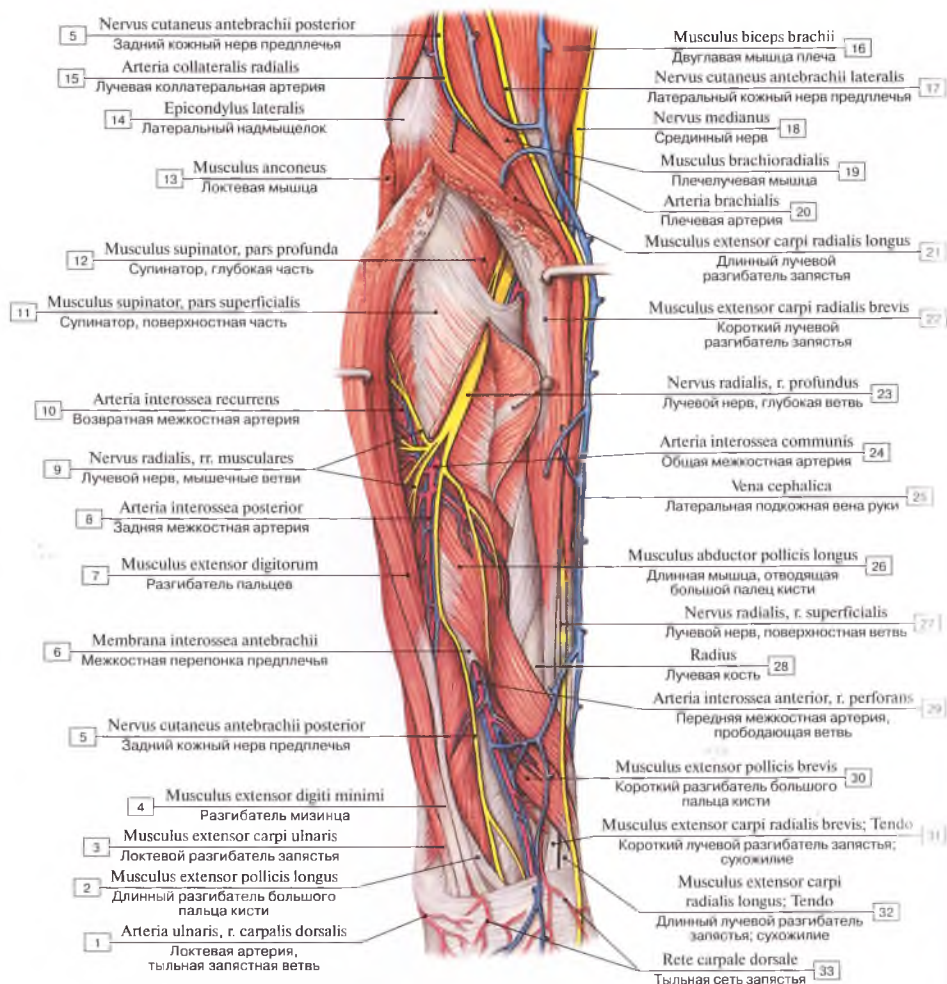


Рис. 303. Глубокая ветвь лучевого нерва:

1 – Ulnar artery, dorsal carpal branch; 2 – Extensor pollicis longus; 3 – Extensor carpi ulnaris; 4 – Extensor digiti minimi; 5 – Posterior cutaneous nerve of forearm; Posterior antebrachial cutaneous nerve; 6 – Interosseous membrane of forearm; 7 – Extensor digitorum; 8 – Posterior interosseous artery; 9 – Radial nerve, muscular branches; 10 – Recurrent interosseous artery; 11 – Supinator, superficial part; 12 – Supinator, deep part; 13 – Anconeus; 14 – Lateral epicondyle; 15 – Radial collateral artery; 16 – Biceps brachii; 17 – Lateral cutaneous nerve of forearm; Lateral antebrachial cutaneous nerve; 18 – Median nerve; 19 – Brachioradialis; 20 – Brachial artery; 21 – Extensor carpi radialis longus; 22 – Extensor carpi radialis brevis; 23 – Radial nerve, deep branch; 24 – Common interosseous artery; 25 – Cephalic vein; 26 – Abductor pollicis longus; 27 – Radial nerve, superficial branch; 28 – Radius; 29 – Anterior interosseous artery, perforating branch; 30 – Extensor pollicis brevis; 31 – Extensor carpi radialis brevis; Tendon; 32 – Extensor carpi radialis longus; Tendon; 33 – Dorsal carpal arch

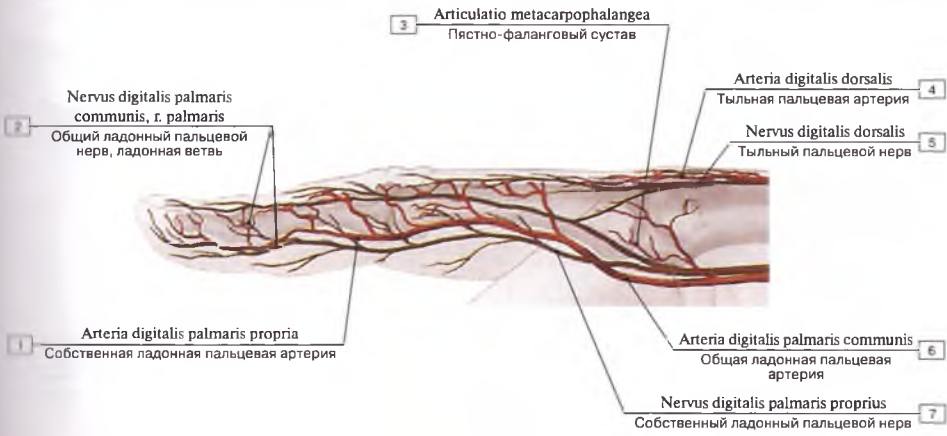


Рис. 304. Кровоснабжение и иннервация среднего пальца кисти:

1 – Proper palmar digital artery; 2 – Common palmar digital nerve, palmar branch; 3 – Metacarpophalangeal joint; 4 – Dorsal digital artery; 5 – Dorsal digital nerve; 6 – Common palmar digital artery; 7 – Proper palmar digital nerve

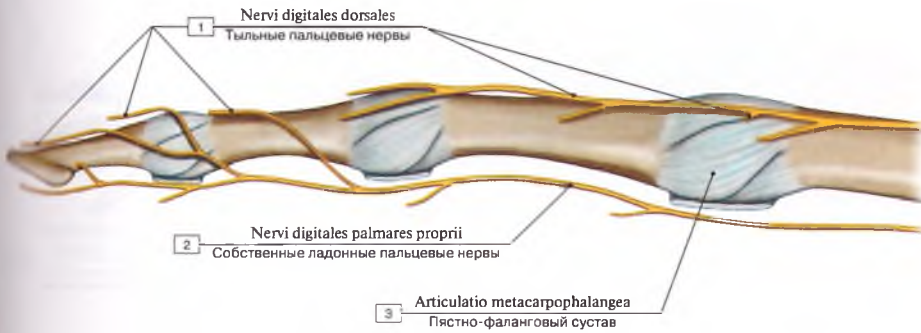


Рис. 305. Иннервация среднего пальца:

1 – Dorsal digital nerves; 2 – Proper palmar digital nerves; 3 – Metacarpophalangeal joint

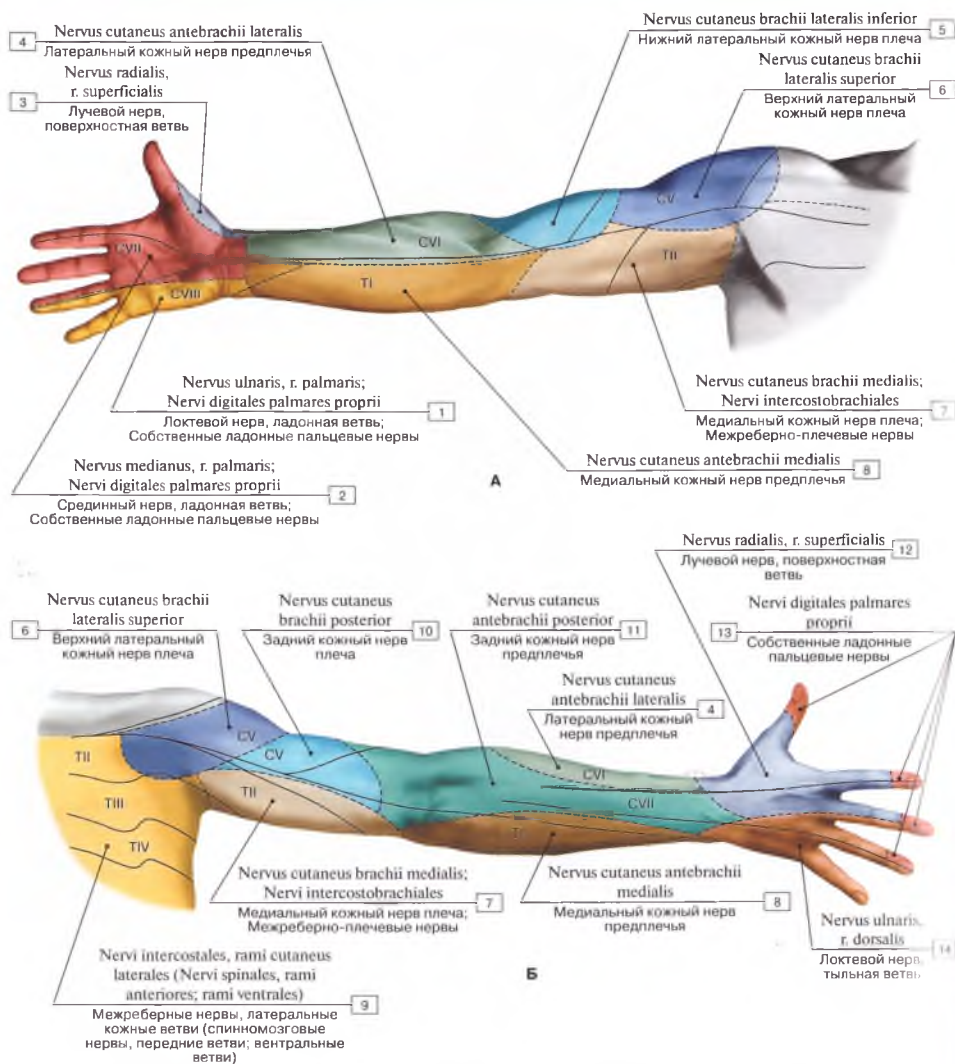


Рис. 306. Кожная иннервация верхней конечности (А – вид спереди; Б – вид сзади):

1 – Ulnar nerve, palmar branch; Proper palmar digital nerves; 2 – Median nerve, palmar branch; Proper palmar digital nerves; 3 – Radial nerve, superficial branch; 4 – Lateral cutaneous nerve of forearm; Lateral antebrachial cutaneous nerve; 5 – Inferior lateral cutaneous nerve of arm; Inferior lateral brachial cutaneous nerve; 6 – Superior lateral cutaneous nerve of arm; Superior lateral brachial cutaneous nerve; 7 – Medial cutaneous nerve of arm; Medial brachial cutaneous nerve; Intercostobrachial nerves; 8 – Medial cutaneous nerve of forearm; Medial antebrachial cutaneous nerve; 9 – Intercostal nerves, lateral cutaneous branches (Spinal nerves, anterior branches; ventral branches); 10 – Posterior cutaneous nerve of arm; Posterior brachial cutaneous nerve; 11 – Posterior cutaneous nerve of forearm; Posterior antebrachial cutaneous nerve; 12 – Radial nerve, superficial branch; 13 – Proper palmar digital nerves; 14 – Ulnar nerve, dorsal branch

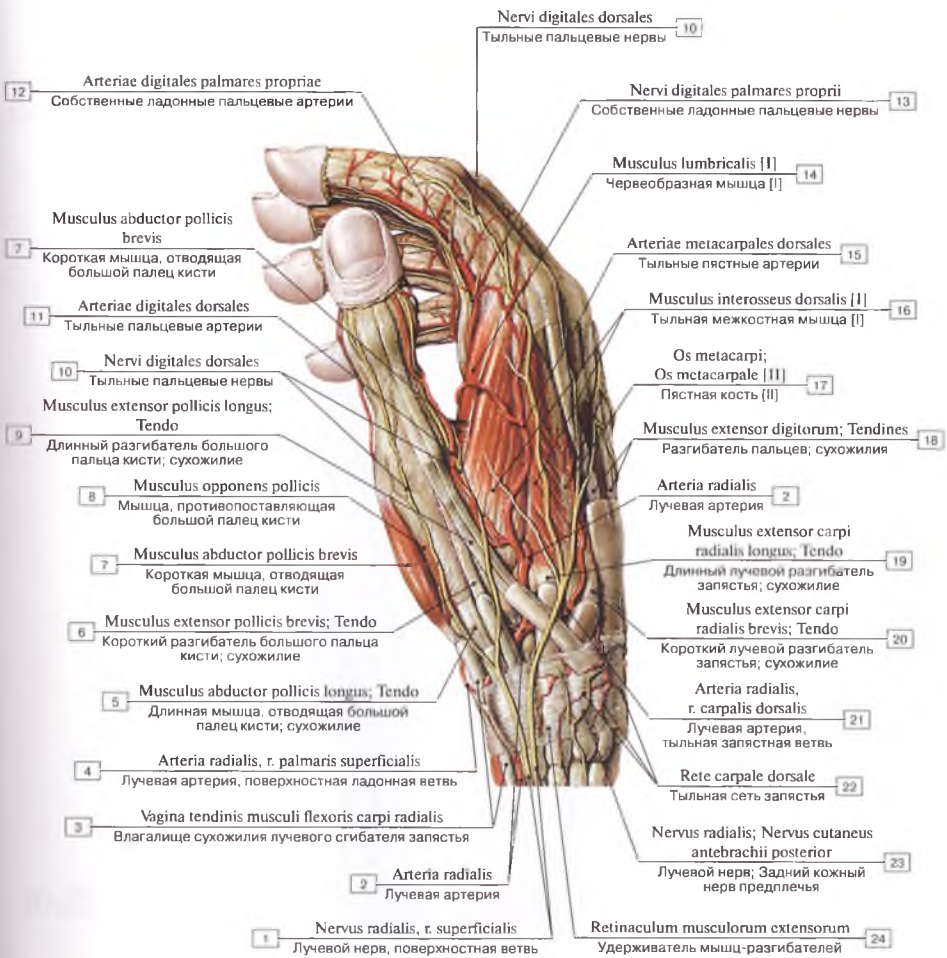


Рис. 307. Нервы и артерии кисти, вид с медиальной стороны:

- 1 — Radial nerve, superficial branch; 2 — Radial artery; 3 — Tendinous sheath of flexor carpi radialis; 4 — Radial artery, superficial palmar branch; 5 — Abductor pollicis longus; Tendon; 6 — Extensor pollicis brevis; Tendon; 7 — Abductor pollicis brevis; 8 — Opponens pollicis; 9 — Extensor pollicis longus; Tendon; 10 — Dorsal digital nerves; 11 — Dorsal digital arteries; 12 — Proper palmar digital arteries; 13 — Proper radial digital nerves; 14 — Lumbrical [I]; 15 — Dorsal metacarpal arteries; 16 — Dorsal interosseus [I]; 17 — Metacarpal [II]; 18 — Extensor digitorum; Tendons; 19 — Extensor carpi radialis longus; Tendon; 20 — Extensor carpi radialis brevis; Tendon; 21 — Radial artery, dorsal carpal branch; 22 — Dorsal carpal arch; 23 — Radial nerve; Posterior cutaneous nerve of forearm; Posterior antebrachial cutaneous nerve; 24 — Extensor retinaculum

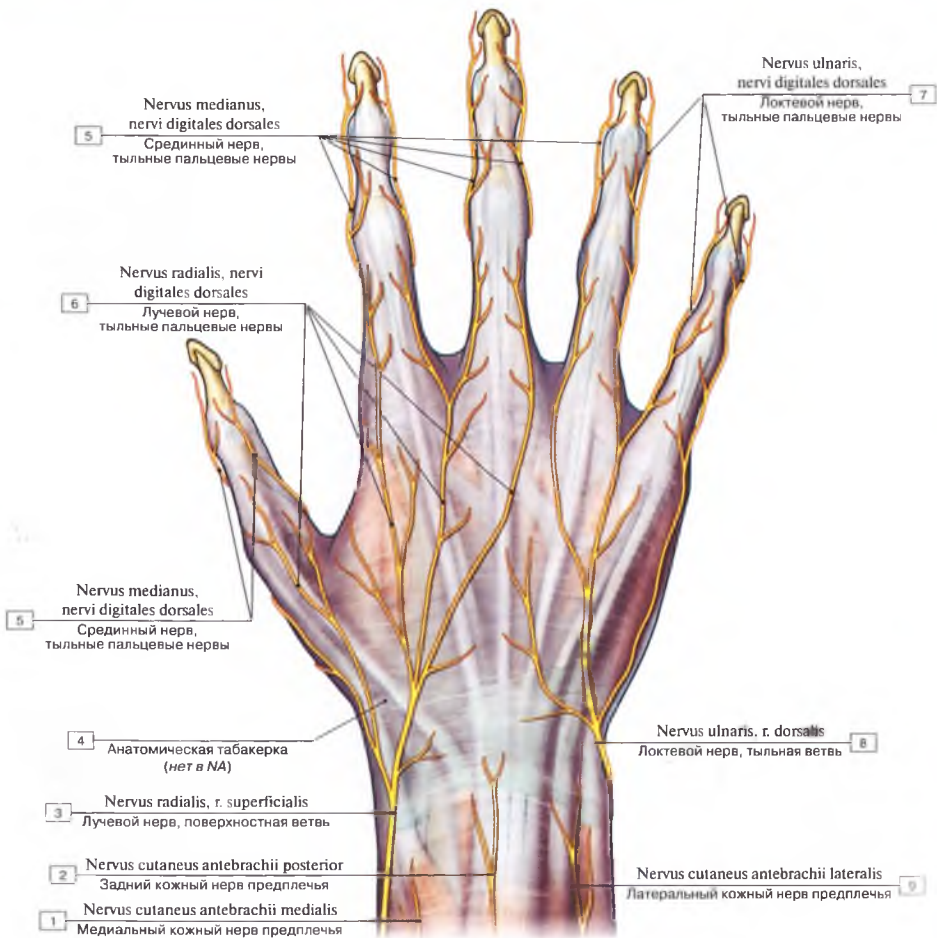


Рис. 308. Нервы тыла кисти, правой:

1 – Medial cutaneous nerve of forearm; Medial antebrachial cutaneous nerve; 2 – Posterior cutaneous nerve of forearm; Posterior antebrachial cutaneous nerve; 3 – Radial nerve, superficial branch; 4 – Anatomical snuffbox; 5 – Median nerve, dorsal digital nerves; 6 – Radial nerve, dorsal digital nerves; 7 – Ulnar nerve, dorsal digital nerves; 8 – Ulnar nerve, dorsal branch; 9 – Lateral cutaneous nerve of forearm; Lateral antebrachial cutaneous nerve



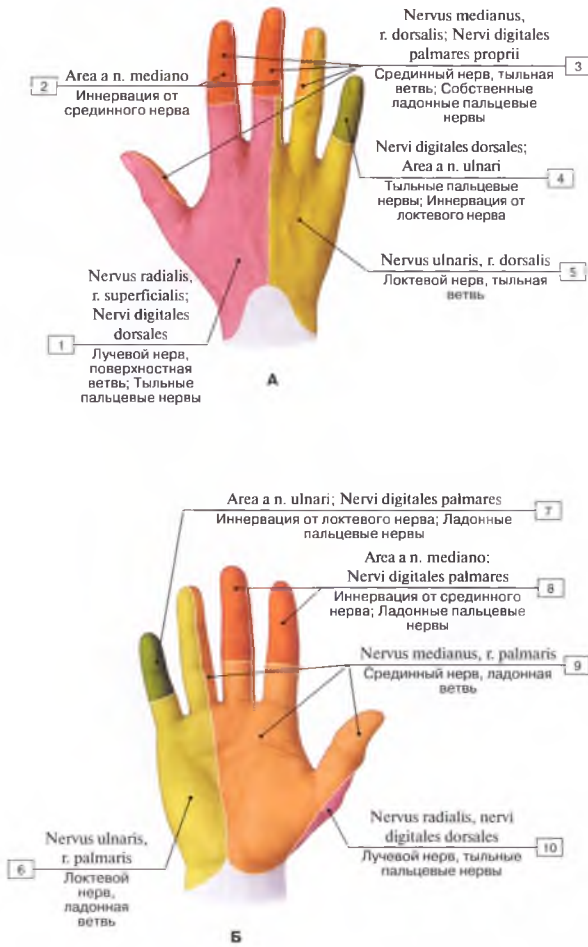


Рис. 309. Области кожной иннервации кисти (А – тыльная поверхность; Б – ладонная поверхность) (схема):

1 – Radial nerve, superficial branch, dorsal digital nerves; 2 – Median nerve, exclusive area; 3 – Median nerve, dorsal branch, proper palmar digital nerves; 4 – Dorsal digital nerves, exclusive area; 5 – Ulnar nerve, dorsal branch; 6 – Ulnar nerve, palmar branch; 7 – Ulnar nerve, exclusive area, palmar digital nerves; 8 – Median nerve, exclusive area, palmar digital nerves; 9 – Median nerve, palmar branch; 10 – Radial nerve, dorsal digital nerves

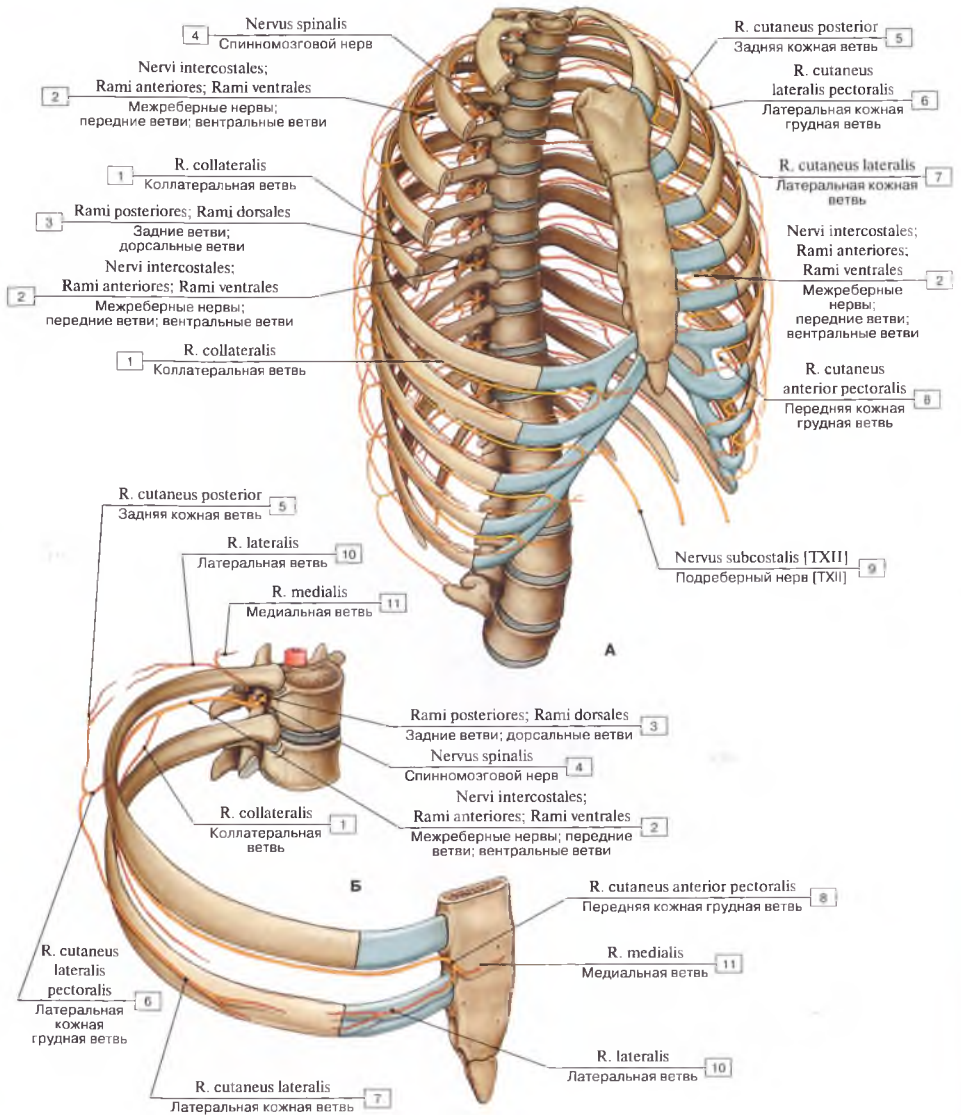


Рис. 310. Межреберные нервы (А – схема; Б – ход нервов в межреберном промежутке):

1 – Collateral branch; 2 – Intercostal nerves; Anterior branches; Ventral branches; 3 – Posterior branches; Dorsal branches; 4 – Spinal nerve; 5 – Posterior cutaneous branch; 6 – Lateral pectoral cutaneous branch; 7 – Lateral cutaneous branch; 8 – Anterior pectoral cutaneous branch; 9 – Subcostal nerve [TXII]; 10 – Lateral branch; 11 – Medial branch

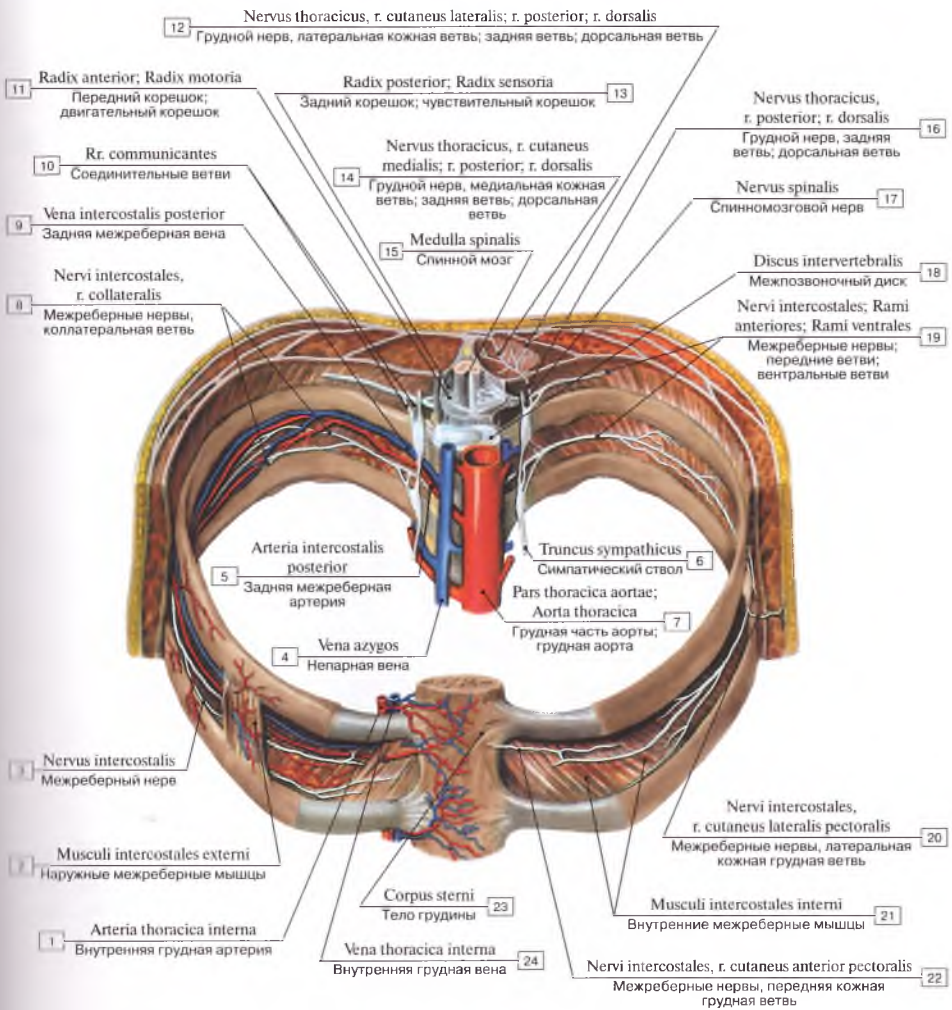


Рис. 311. Сосуды и нервы стенок грудной полости (фрагмент):

- 1 – Internal thoracic artery; 2 – External intercostal muscles; 3 – Intercostal nerve; 4 – Azygos vein; 5 – Posterior intercostal artery; 6 – Sympathetic trunk; 7 – Thoracic aorta; 8 – Intercostal nerves, collateral branch; 9 – Posterior intercostal vein; 10 – Communicating branches; 11 – Anterior root; Motor root; Ventral root; 12 – Thoracic nerve, lateral cutaneous branch; posterior branch; dorsal branch; 13 – Posterior root; Sensory root; Dorsal root; 14 – Thoracic nerve, medial cutaneous branch; posterior branch; dorsal branch; 15 – Spinal cord; 16 – Thoracic nerve, posterior branch; dorsal branch; 17 – Spinal nerve; 18 – Intervertebral disc; 19 – Intercostal nerves; Anterior branches; Ventral branches; 20 – Intercostal nerves, lateral pectoral cutaneous branch; 21 – Internal intercostal muscles; 22 – Intercostal nerves, anterior pectoral cutaneous branch; 23 – Body of sternum; 24 – Internal thoracic vein

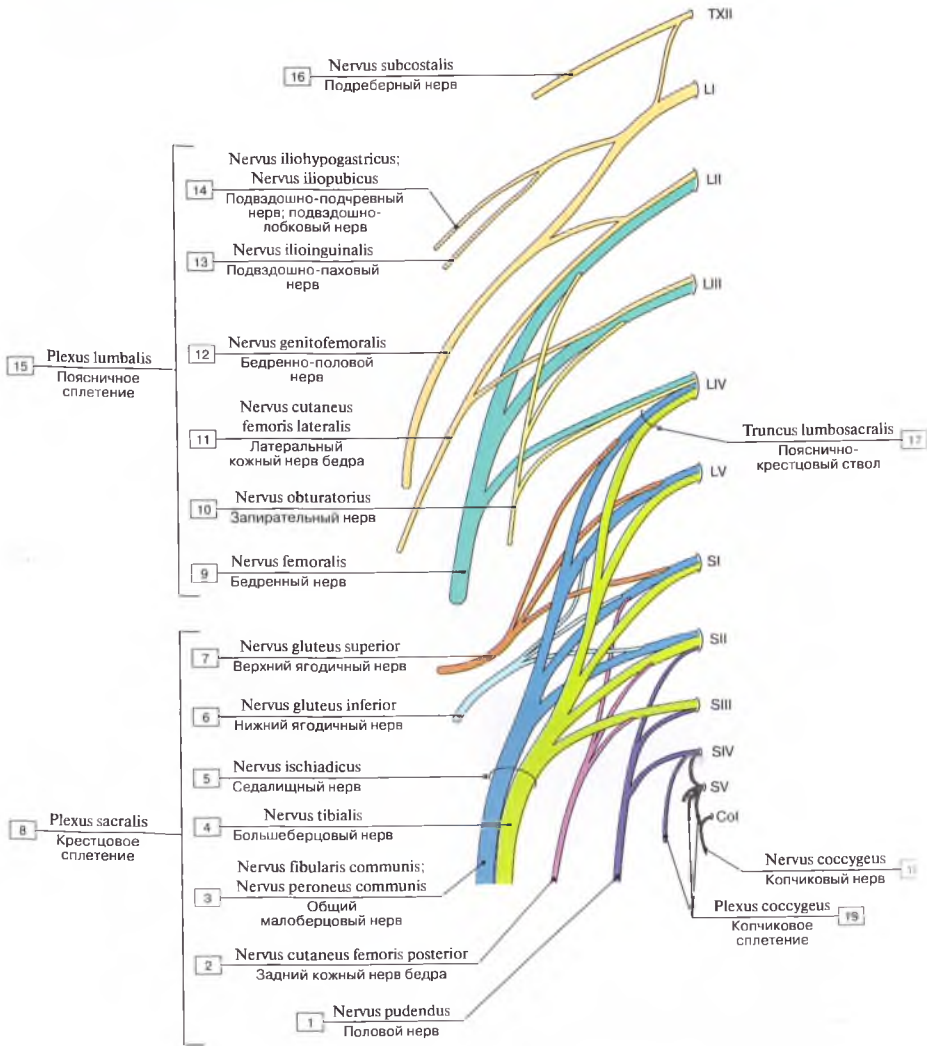


Рис. 312. Поясничное, крестцовое и копчиковое сплетения (схема):

1 – Pudendal nerve; 2 – Posterior cutaneous nerve of thigh; Posterior femoral cutaneous nerve; 3 – Common fibular nerve; Common peroneal nerve; 4 – Tibial nerve; 5 – Sciatic nerve; 6 – Inferior gluteal nerve; 7 – Superior gluteal nerve; 8 – Sacral plexus; 9 – Femoral nerve; 10 – Obturator nerve; 11 – Lateral cutaneous nerve of thigh; Lateral femoral cutaneous nerve; 12 – Genitofemoral nerve; 13 – Ilio-inguinal nerve; 14 – Iliohypogastric nerve; Iliopubic nerve; 15 – Lumbar plexus; 16 – Subcostal nerve; 17 – Lumbosacral trunk; 18 – Coccygeal plexus; 19 – Coccygeal plexus

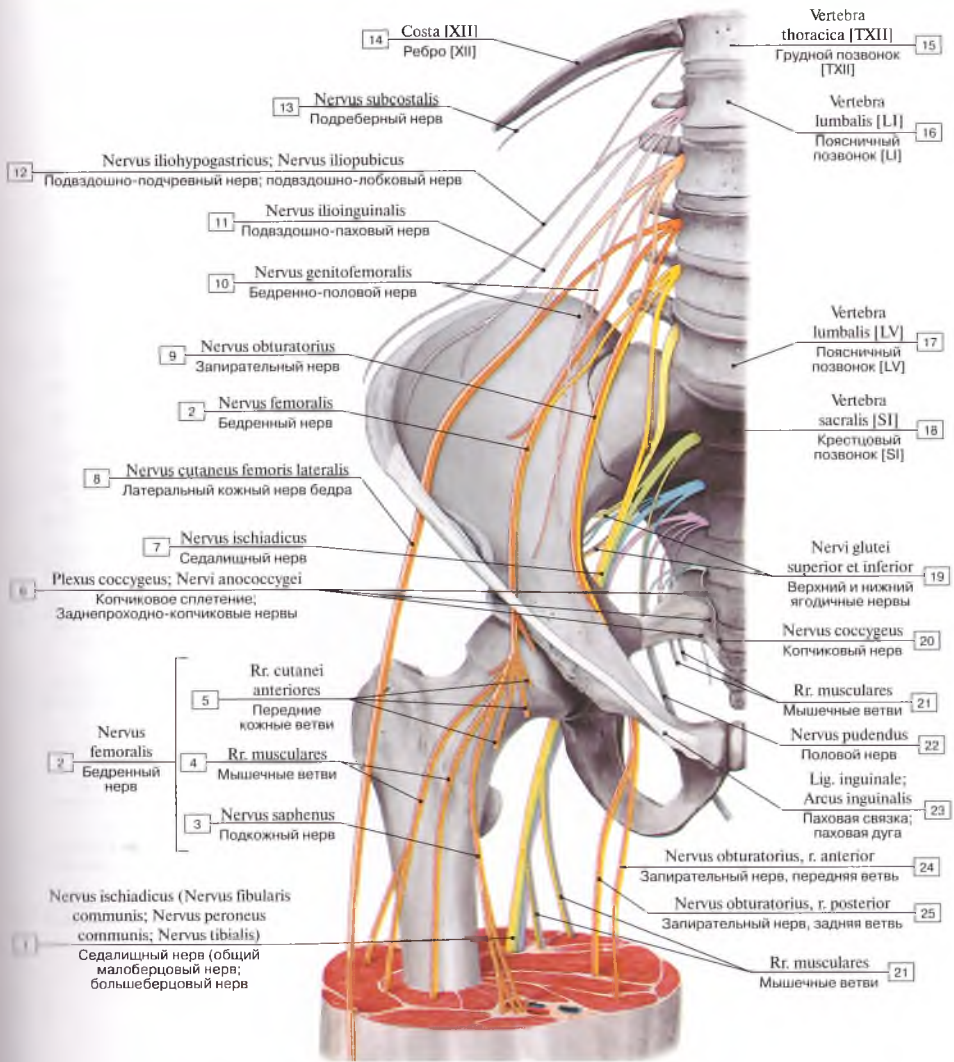


Рис. 313. Поясничное, крестцовое и копчиковое сплетения, вид спереди (схема):

1 – Sciatic nerve (Common fibular nerve; Common peroneal nerve; Tibial nerve); 2 = 3 + 4 + 5 – Femoral nerve; 3 – Saphenous nerve; 4 – Muscular branches; 5 – Anterior cutaneous branches; 6 – Coccygeal plexus, anococcygeal nerves; 7 – Sciatic nerve; 8 – Lateral cutaneous nerve of thigh; Lateral femoral cutaneous nerve; 9 – Obturator nerve; 10 – Genitofemoral nerve; 11 – Ilio-inguinal nerve; 12 – Iliohypogastric nerve; Iliopubic nerve; 13 – Subcostal nerve; 14 – Rib [XII]; 15 – Thoracic vertebra [TXII]; 16 – Lumbar vertebra [LI]; 17 – Lumbar vertebra [LV]; 18 – Sacrum vertebra [SI]; 19 – Superior and inferior gluteal nerves; 20 – Coccygeal nerve; 21 – Muscular branches; 22 – Pudendal nerve; 23 – Inguinal ligament; 24 – Obturator nerve, anterior branch; 25 – Obturator nerve, posterior branch

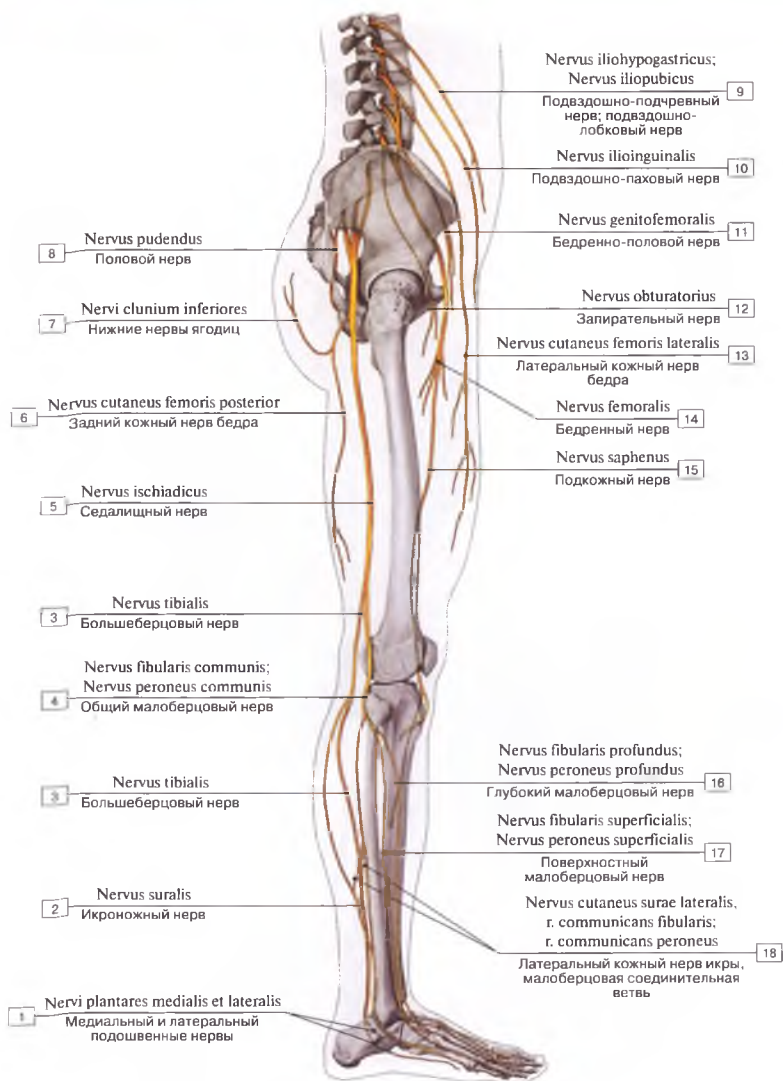


Рис. 314. Ветви поясничного и крестцового сплетений, вид сбоку (схема):

1 – Medial and lateral plantar nerves; 2 – Sural nerve; 3 – Tibial nerve; 4 – Common fibular nerve; Common peroneal nerve; 5 – Sciatic nerve; 6 – Posterior cutaneous nerve of thigh; Posterior femoral cutaneous nerve; 7 – Inferior clunial nerves; 8 – Pudendal nerve; 9 – Iliohypogastric nerve; Iliopubic nerve; 10 – Ilio-inguinal nerve; 11 – Genitofemoral nerve; 12 – Obturator nerve; 13 – Lateral cutaneous nerve of thigh; Lateral femoral cutaneous nerve; 14 – Femoral nerve; 15 – Saphenous nerve; 16 – Deep fibular nerve; Deep peroneal nerve; 17 – Superficial fibular nerve; Superficial peroneal nerve; 18 – Lateral sural cutaneous nerve, sural communicating branch

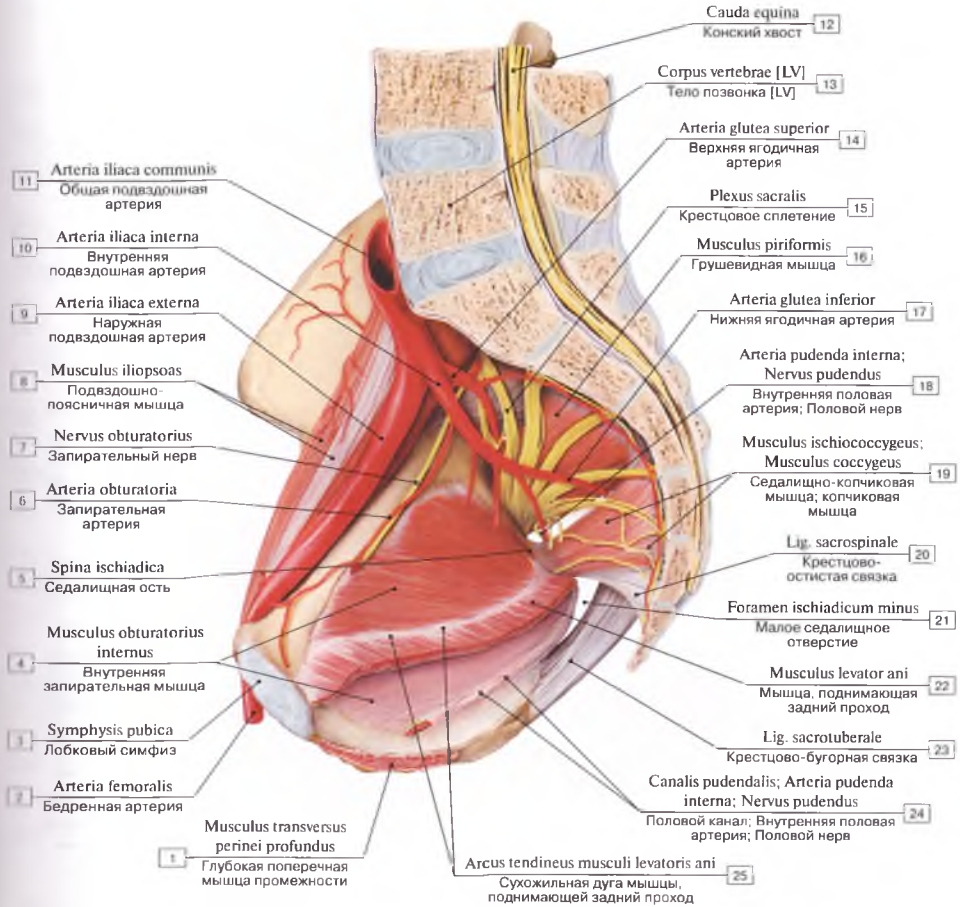


Рис. 315. Крестцовое сплетение, вид изнутри:

1 – Deep transverse perineal muscle; 2 – Femoral artery; 3 – Pubic symphysis; 4 – Obturator internus; 5 – Ischial spine; 6 – Obturator artery; 7 – Obturator nerve; 8 – Iliopsoas; 9 – External iliac artery; 10 – Internal iliac artery; 11 – Common iliac artery; 12 – Cauda equina; 13 – Vertebral body [LV]; 14 – Superior gluteal artery; 15 – Sacral plexus; 16 – Piriformis; 17 – Inferior gluteal artery; 18 – Internal pudendal artery; Pudendal nerve; 19 – Ischiococcygeus; Coccygeus; 20 – Sacrospinous ligament; 21 – Lesser sciatic foramen; 22 – Levator ani; 23 – Sacrotuberous ligament; 24 – Pudendal canal; Internal pudendal artery; Pudendal nerve; 25 – Tendinous arch of levator ani

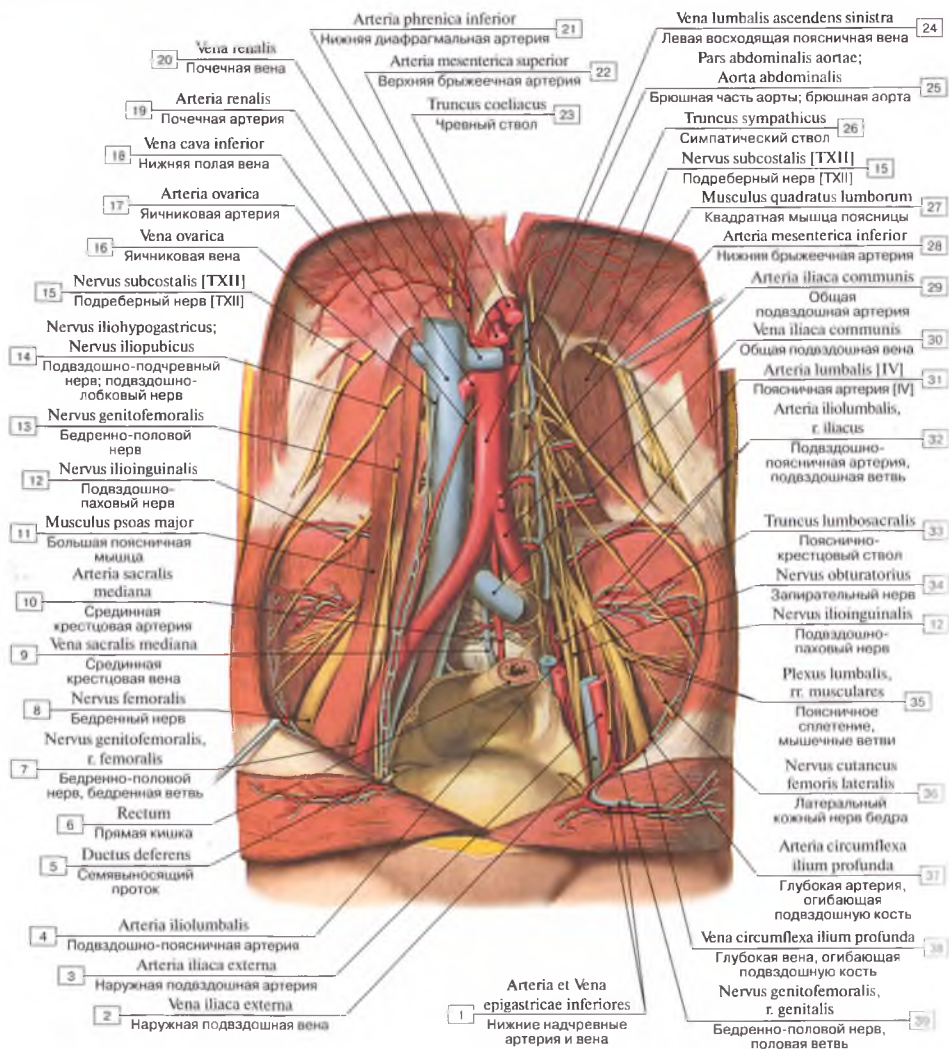


Рис. 316. Нервы поясничного сплетения:

1 – Inferior epigastric vein and artery; 2 – External iliac vein; 3 – External iliac artery; 4 – Iliolumbar artery; 5 – Ductus deferens; V. deferens; 6 – Rectum; 7 – Genitofemoral nerve, femoral branch; 8 – Femoral nerve; 9 – Median sacral artery; 10 – Median sacral artery; 11 – Psoas major; 12 – Ilio-inguinal nerve; 13 – Genitofemoral nerve; 14 – Iliohypogastric nerve; Iliopubic nerve; 15 – Subcostal nerve [TXII]; 16 – Ovarian vein; 17 – Ovarian artery; 18 – Inferior vena cava; 19 – Renal artery; 20 – Renal vein; 21 – Inferior phrenic artery; 22 – Superior mesenteric artery; 23 – Coeliac trunk; 24 – Left ascending lumbar vein; 25 – Abdominal aorta; 26 – Sympathetic trunk; 27 – Quadratus lumborum; 28 – Inferior mesenteric artery; 29 – Common iliac artery; 30 – Common iliac vein; 31 – Lumbar artery [IV]; 32 – Iliolumbar artery; iliacus branch; 33 – Lumbosacral trunk; 34 – Obturator nerve; 35 – Lumbar plexus, muscular branches; 36 – Lateral cutaneous nerve of thigh; Lateral femoral cutaneous nerve; 37 – Deep circumflex iliac artery; 38 – Deep circumflex iliac vein; 39 – Genitofemoral nerve, genital branch



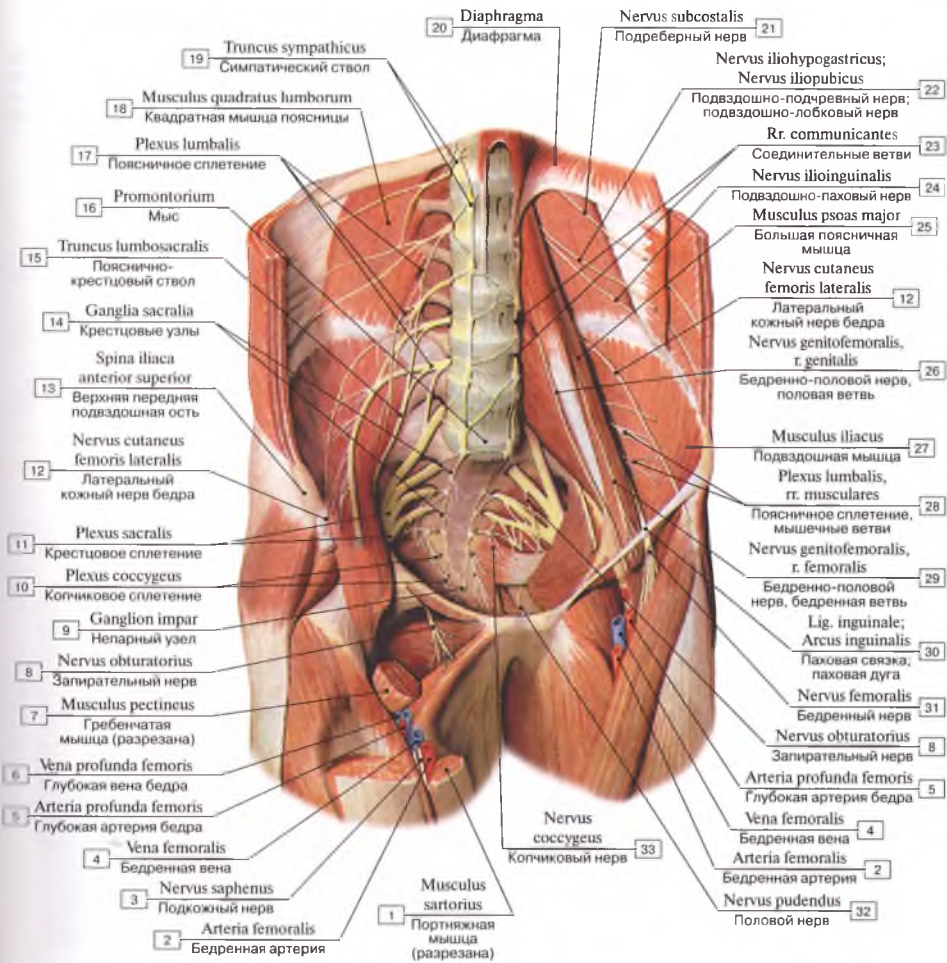


Рис. 317. Поясничное и крестцовое сплетения:

1 – Sartorius; 2 – Femoral artery; 3 – Saphenous nerve; 4 – Femoral vein; 5 – Deep artery of thigh; 6 – Profunda femoris vein; Deep vein of thigh; 7 – Pectineus; 8 – Obturator nerve; 9 – Ganglion impar; 10 – Coccygeal plexus; 11 – Sacral plexus; 12 – Lateral cutaneous nerve of thigh; Lateral femoral cutaneous nerve; 13 – Anterior superior iliac spine; 14 – Sacral ganglia; 15 – Lumbosacral trunk; 16 – Promontory; 17 – Lumbar plexus; 18 – Quadratus lumborum; 19 – Sympathetic trunk; 20 – Diaphragm; 21 – Subcostal nerve; 22 – Iliohypogastric nerve; Iliopubic nerve; 23 – Communicating branches; 24 – Ilio-inguinal nerve; 25 – Psoas major; 26 – Genitofemoral nerve, genital branch; 27 – Iliacus; 28 – Lumbar plexus, muscular branches; 29 – Genitofemoral nerve, femoral branch; 30 – Inguinal ligament; 31 – Femoral nerve; 32 – Pudendal nerve; 33 – Coccygeal nerve

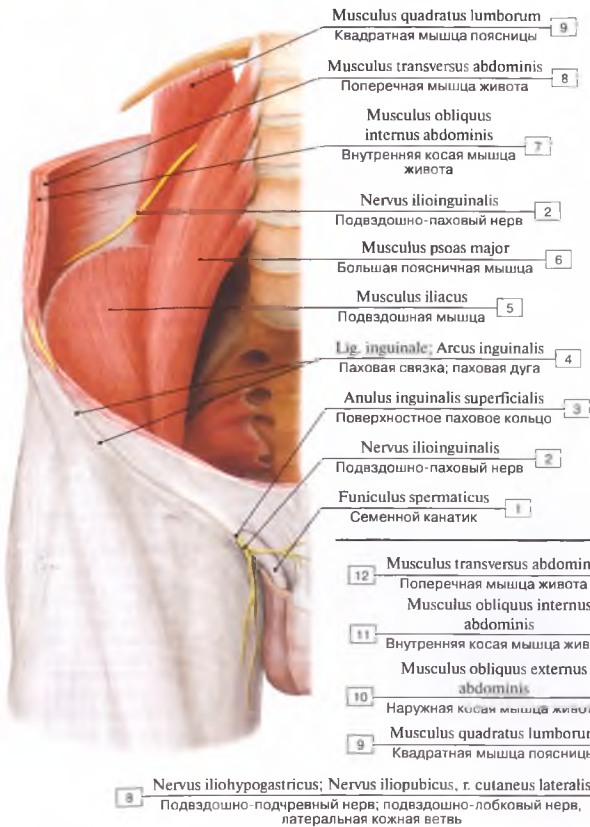


Рис. 318. Подвздошно-паховый нерв:

1 – Spermatic cord; 2 – Ilio-inguinal nerve; 3 – Superficial inguinal ring; 4 – Inguinal ligament; 5 – Iliacus; 6 – Psoas major; 7 – Internal oblique; 8 – Transversus abdominis; Transverse abdominalis; 9 – Quadratus lumborum

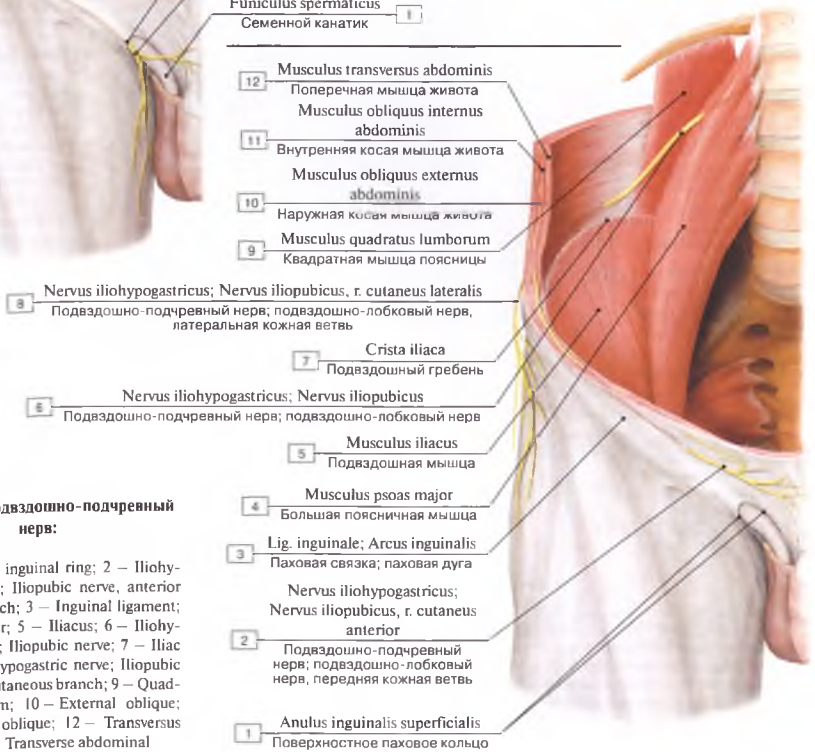


Рис. 319. Подвздошно-подчревный нерв:

1 – Superficial inguinal ring; 2 – Iliohypogastric nerve; Iliopubic nerve, anterior cutaneous branch; 3 – Inguinal ligament; 4 – Psoas major; 5 – Iliacus; 6 – Iliohypogastric nerve; Iliopubic nerve, lateral cutaneous branch; 7 – Iliac crest; 8 – Iliohypogastric nerve; Iliopubic nerve, lateral cutaneous branch; 9 – Quadratus lumborum; 10 – External oblique; 11 – Internal oblique; 12 – Transversus abdominis; Transverse abdominal

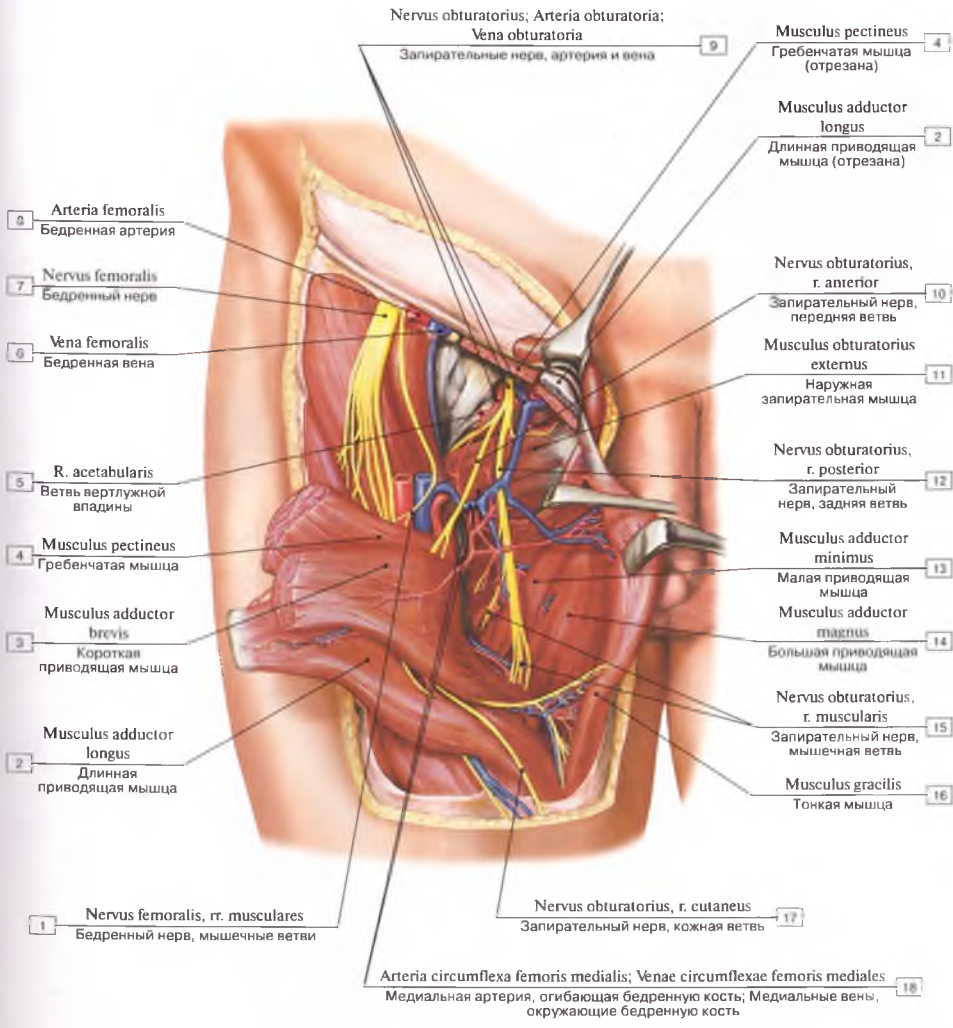


Рис. 320. Запирательный и бедренный нервы:

1 – Femoral nerve, muscular branches; 2 – Adductor longus; 3 – Adductor brevis; 4 – Pectineus; 5 – Acetabular branch; 6 – Femoral vein; 7 – Femoral nerve; 8 – Femoral artery; 9 – Obturator nerve; Obturator artery; Obturator vein; 10 – Obturator nerve, anterior branch; 11 – Obturator externus; 12 – Obturator nerve, posterior branch; 13 – Adductor minimus; 14 – Adductor magnus; 15 – Obturator nerve, muscular branch; 16 – Gracilis; 17 – Obturator nerve, cutaneous branch; 18 – Medial circumflex femoral artery; Medial circumflex femoral veins

Рис. 321. Бедренно-половой нерв:

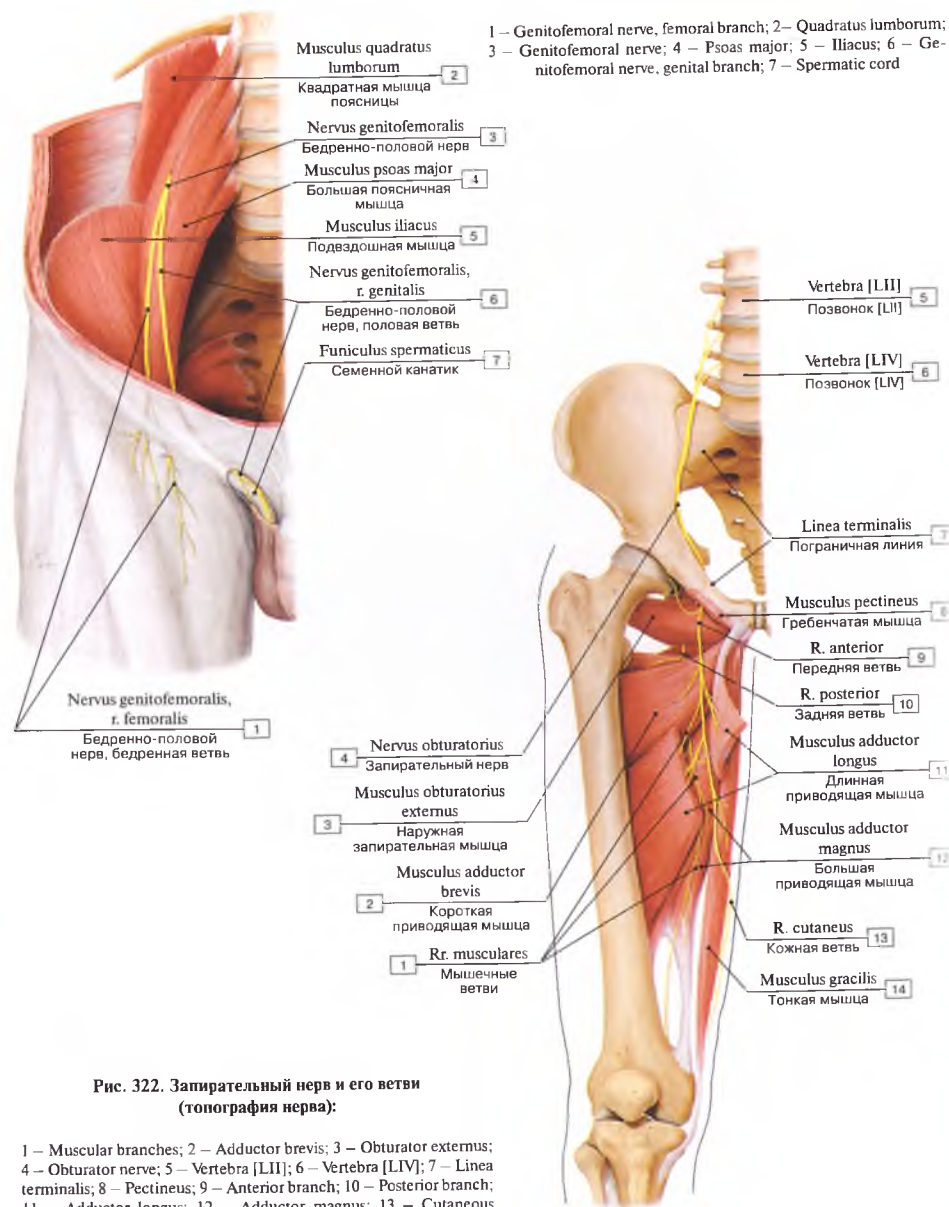


Рис. 322. Запирательный нерв и его ветви (топография нерва):

1 – Muscular branches; 2 – Adductor brevis; 3 – Obturator externus; 4 – Obturator nerve; 5 – Vertebra [LII]; 6 – Vertebra [LIV]; 7 – Linea terminalis; 8 – Pectineus; 9 – Anterior branch; 10 – Posterior branch; 11 – Adductor longus; 12 – Adductor magnus; 13 – Cutaneous branch; 14 – Gracilis

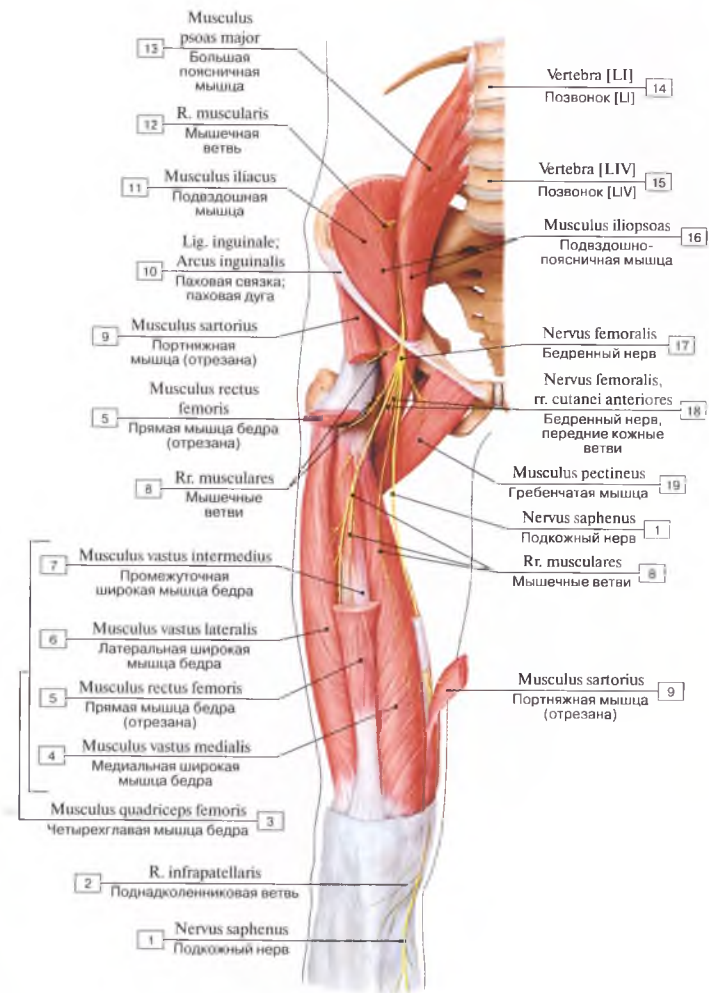


Рис. 323. Бедренный нерв и его ветви (топография нерва):

1 – Saphenous nerve; 2 – Infrapatellar branch; 3 = 4 + 5 + 6 + 7 – Quadriceps femoris; 4 – Vastus medialis; 5 – Rectus femoris; 6 – Vastus lateralis; 7 – Vastus intermedius; 8 – Muscular branches; 9 – Sartorius; 10 – Inguinal ligament; 11 – Iliacus; 12 – Muscular branch; 13 – Psoas major; 14 – Vertebra [LI]; 15 – Vertebra [LIV]; 16 – Iliopsoas; 17 – Femoral nerve; 18 – Femoral nerve, anterior cutaneous branches; 19 – Pectineus

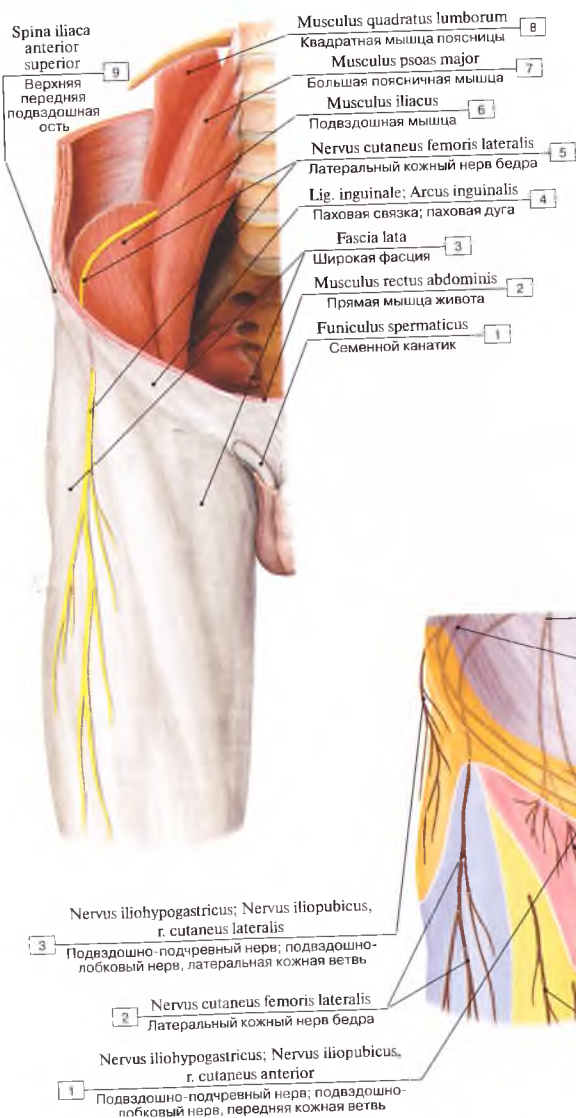


Рис. 324. Латеральный кожный нерв бедра, ход нерва:

1 – Spermatic cord; 2 – Rectus abdominis; 3 – Fascia lata; 4 – Inguinal ligament; 5 – Lateral cutaneous nerve of thigh; 6 – Iliacus; 7 – Psoas major; 8 – Quadratus lumborum; 9 – Anterior superior iliac spine

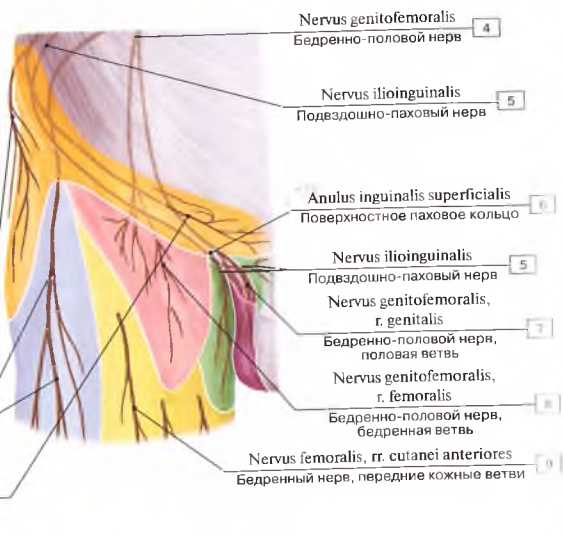


Рис. 325. Чувствительная иннервация паховой области (схема):

1 – Iliohypogastric nerve; Iliopubic nerve, anterior cutaneous branch; 2 – Lateral cutaneous nerve of thigh; Lateral femoral cutaneous nerve; 3 – Iliohypogastric nerve; Iliopubic nerve, lateral cutaneous branch; 4 – Genitofemoral nerve; 5 – Ilio-inguinal nerve; 6 – Superficial inguinal ring; 7 – Genitofemoral nerve, genital branch; 8 – Genitofemoral nerve, femoral branch; 9 – Femoral nerve, anterior cutaneous branches

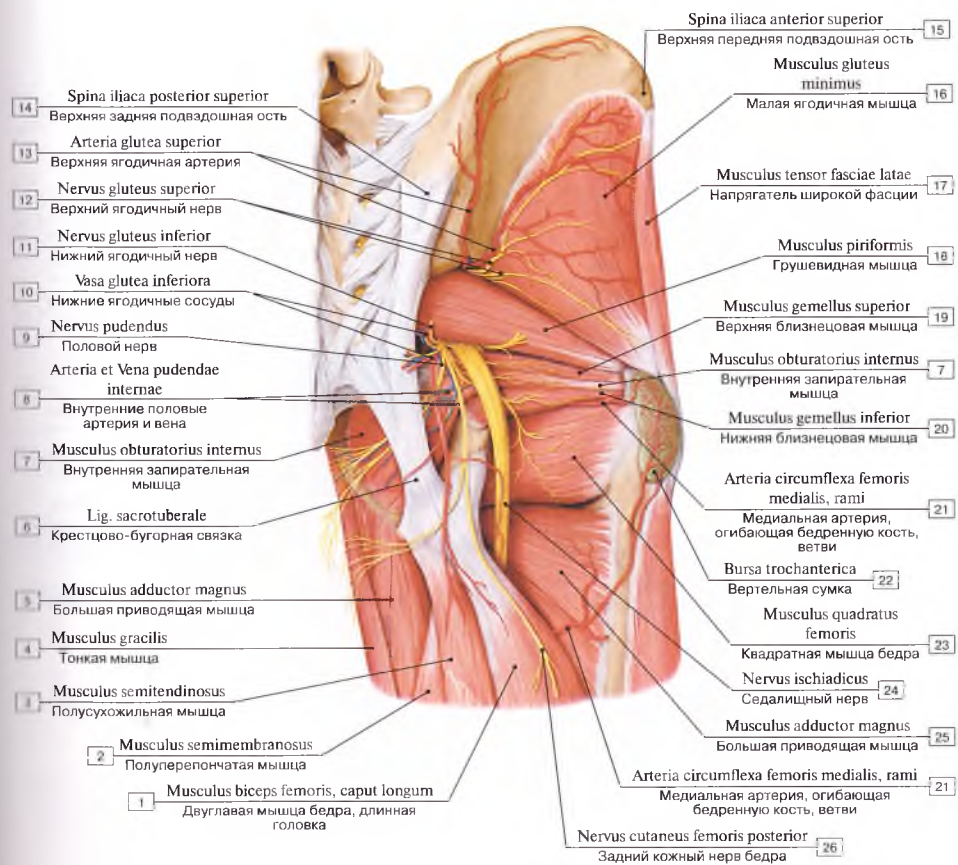


Рис. 326. Короткие ветви крестцового сплетения:

1 – Biceps femoris, long head; 2 – Semimembranosus; 3 – Semitendinosus; 4 – Gracilis; 5 – Adductor magnus; 6 – Sacrotuberous ligament; 7 – Obturator internus; 8 – Internal pudendal artery and vein; 9 – Pudendal nerve; 10 – Inferior gluteal vessels; 11 – Inferior gluteal nerve; 12 – Superior gluteal nerve; 13 – Superior gluteal artery; 14 – Posterior superior iliac spine; 15 – Anterior superior iliac spine; 16 – Gluteus minimus; 17 – Tensor fasciae latae; 18 – Piriformis; 19 – Gemellus superior; Superior gemellus; 20 – Gemellus inferior; Inferior gemellus; 21 – Medial circumflex femoral artery, branches; 22 – Trochanteric bursae; 23 – Quadratus femoris; 24 – Sciatic nerve; 25 – Adductor magnus; 26 – Posterior cutaneous nerve of thigh; Posterior femoral cutaneous nerve

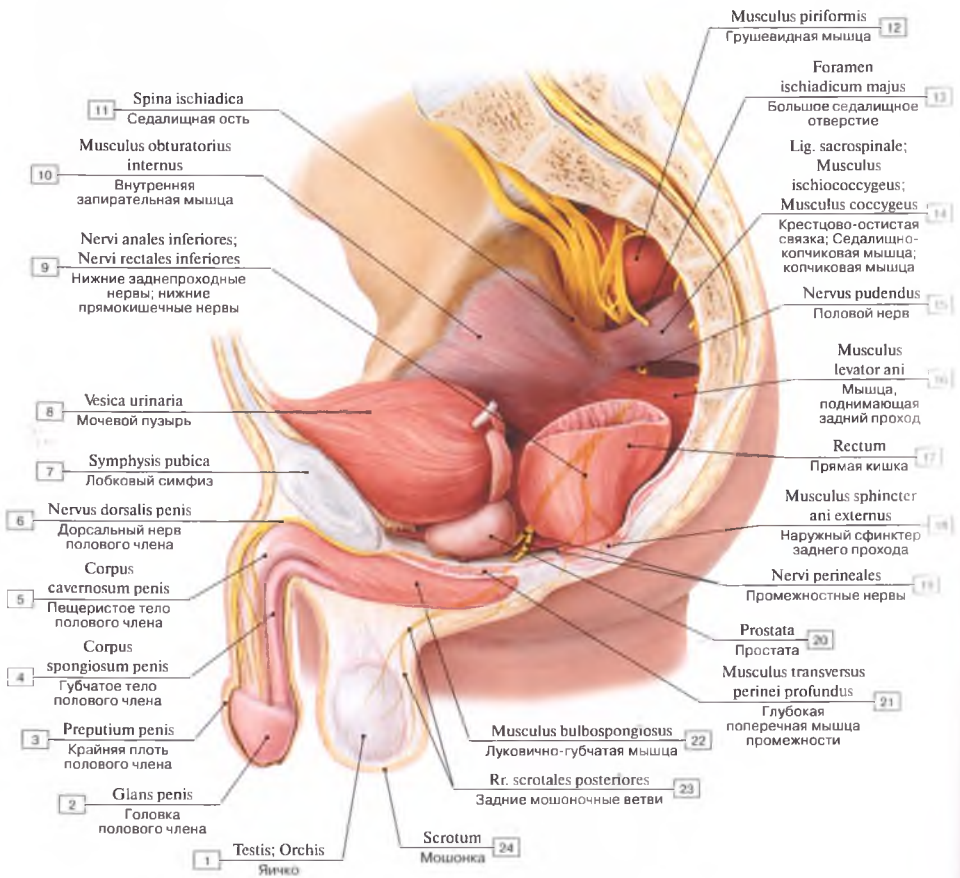


Рис. 327. Половой нерв мужчины:

1 – Testis; 2 – Glans penis; 3 – Prepuce; Foreskin; 4 – Corpus spongiosum penis; 5 – Corpus cavernosum penis; 6 – Dorsal nerve of penis; 7 – Pubic symphysis; 8 – Urinary bladder; 9 – Inferior anal nerves; Inferior rectal nerves; 10 – Obturator internus; 11 – Ischial spine; 12 – Piriformis; 13 – Greater sciatic foramen; 14 – Sacrospinous ligament; Ischiococcygeus; Coccygeus; 15 – Pudendal nerve; 16 – Levator ani; 17 – Rectum; 18 – External anal sphincter; 19 – Perineal nerves; 20 – Prostate; 21 – Deep transverse perineal muscle; 22 – Bulbospongiosus; 23 – Posterior scrotal nerves; 24 – Scrotum

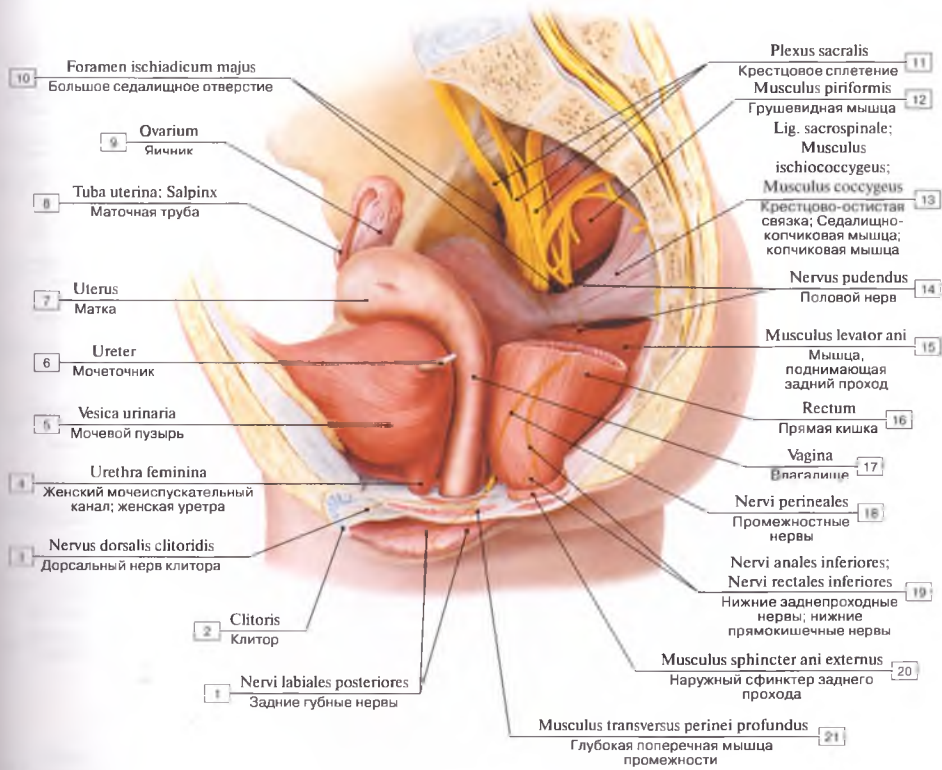


Рис. 328. Половой нерв женщины:

1 – Posterior labial nerves; 2 – Clitoris; 3 – Dorsal nerve of clitoris; 4 – Female urethra; 5 – Urinary bladder; 6 – Ureter; 7 – Uterus; 8 – Uterine tube; 9 – Ovary; 10 – Greater sciatic foramen; 11 – Sacral plexus; 12 – Piriformis; 13 – Sacrospinous ligament; Ischiococcygeus; Ischiococcygeus; 14 – Pudendal nerve; 15 – Levator ani; 16 – Rectum; 17 – Vagina; 18 – Perineal nerves; 19 – Inferior anal nerves; Inferior rectal nerves; 20 – External anal sphincter; 21 – Deep transverse perineal muscle

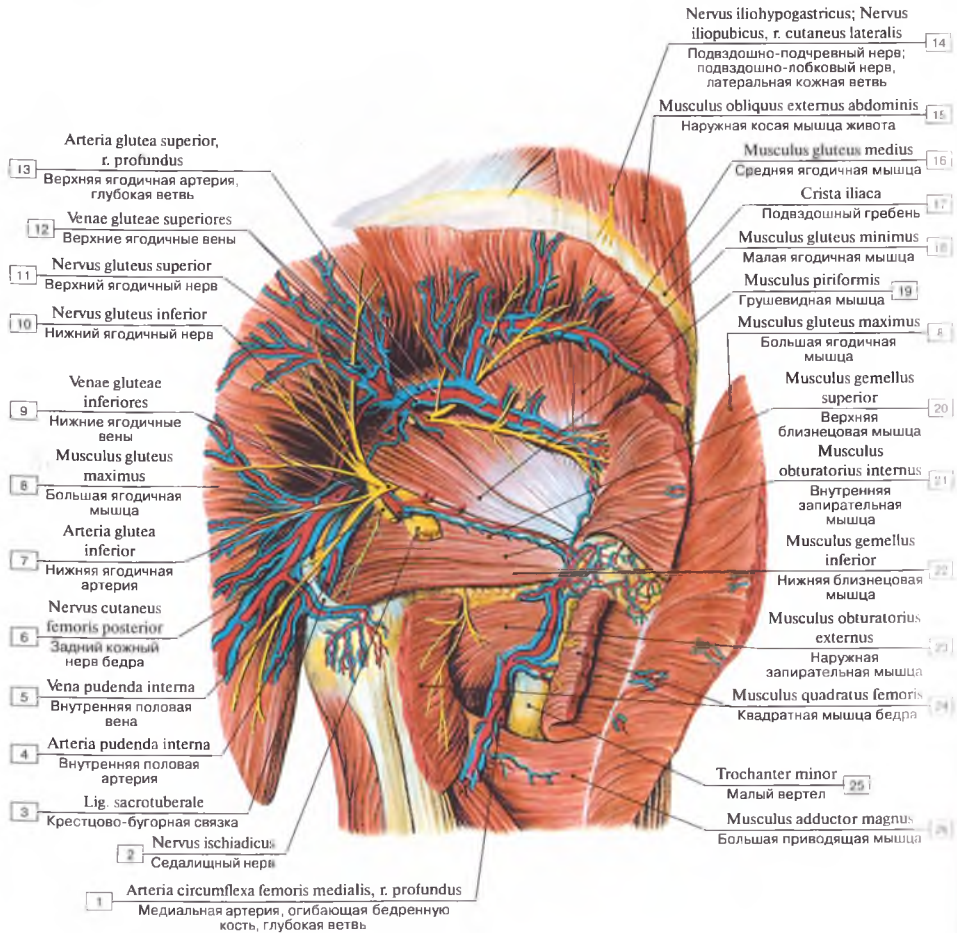


Рис. 329. Сосуды и нервы ягодичной области:

1 – Medial circumflex femoral artery, deep branch; 2 – Sciatic nerve; 3 – Sacrotuberous ligament; 4 – Internal pudendal artery; 5 – Internal pudendal vein; 6 – Posterior cutaneous nerve of thigh; Posterior femoral cutaneous nerve; 7 – Inferior gluteal artery; 8 – Gluteus maximus; 9 – Inferior gluteal veins; 10 – Inferior gluteal nerve; 11 – Superior gluteal nerve; 12 – Superior gluteal veins; 13 – Superior gluteal artery, deep branch; 14 – Iliohypogastric nerve; Iliopubic nerve, lateral cutaneous branch; 15 – External oblique; 16 – Gluteus medius; 17 – Iliac crest; 18 – Gluteus minimus; 19 – Piriformis; 20 – Gemellus superior; Superior gemellus; 21 – Obturator internus; 22 – Gemellus inferior; Inferior gemellus; 23 – Obturator externus; 24 – Quadratus femoris; 25 – Lesser trochanter; 26 – Adductor magnus



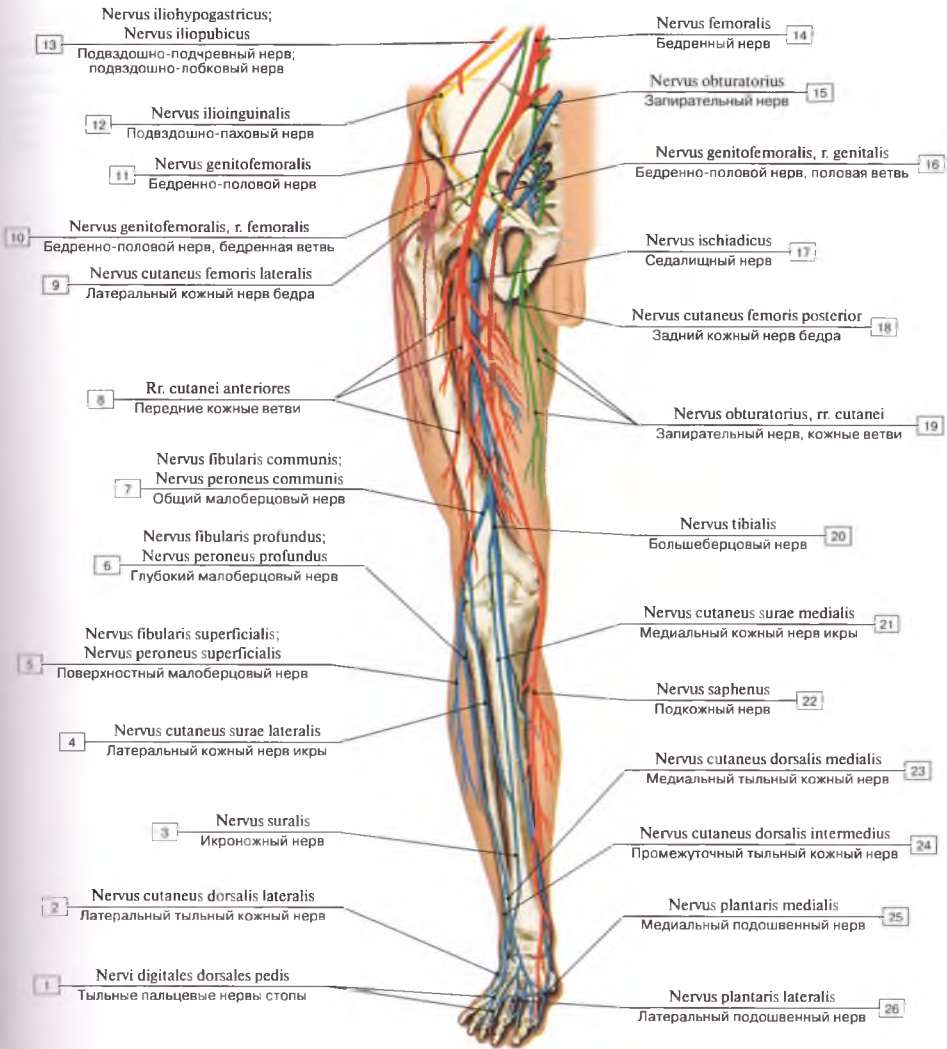
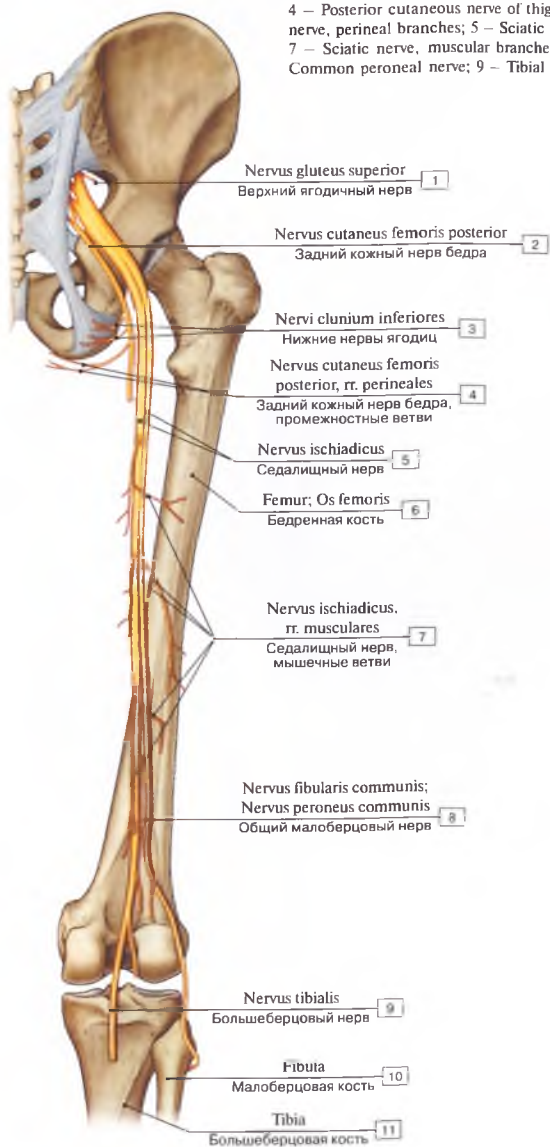


Рис. 330. Нервы нижней конечности:

1 – Dorsal digital nerves of foot; 2 – Lateral dorsal cutaneous nerve; 3 – Sural nerve; 4 – Lateral sural cutaneous nerve; 5 – Superficial fibular nerve; Superficial peroneal nerve; 6 – Deep fibular nerve; Deep peroneal nerve; 7 – Common fibular nerve; Common peroneal nerve; 8 – Anterior cutaneous branches; 9 – Lateral cutaneous nerve of thigh; Lateral femoral cutaneous nerve; 10 – Genitofemoral nerve, femoral branch; 11 – Genitofemoral nerve; 12 – Ilio-inguinal nerve; 13 – Iliohypogastric nerve; Iliopubic nerve; 14 – Femoral nerve; 15 – Obturator nerve; 16 – Genitofemoral nerve, genital branch; 17 – Sciatic nerve; 18 – Posterior cutaneous nerve of thigh; Posterior femoral cutaneous nerve; 19 – Obturator nerve, cutaneous branches; 20 – Tibial nerve; 21 – Medial sural cutaneous nerve; 22 – Saphenous nerve; 23 – Medial dorsal cutaneous nerve; 24 – Intermediate dorsal cutaneous nerve; 25 – Medial plantar nerve; 26 – Lateral plantar nerve

Рис. 331. Нервы нижней конечности, вид сзади:

1 – Superior gluteal nerve; 2 – Posterior cutaneous nerve of thigh; Posterior femoral cutaneous nerve; 3 – Inferior clunial nerves; 4 – Posterior cutaneous nerve of thigh; Posterior femoral cutaneous nerve, perineal branches; 5 – Sciatic nerve; 6 – Femur; Thigh bone; 7 – Sciatic nerve, muscular branches; 8 – Common fibular nerve; Common peroneal nerve; 9 – Tibial nerve; 10 – Fibula; 11 – Tibia



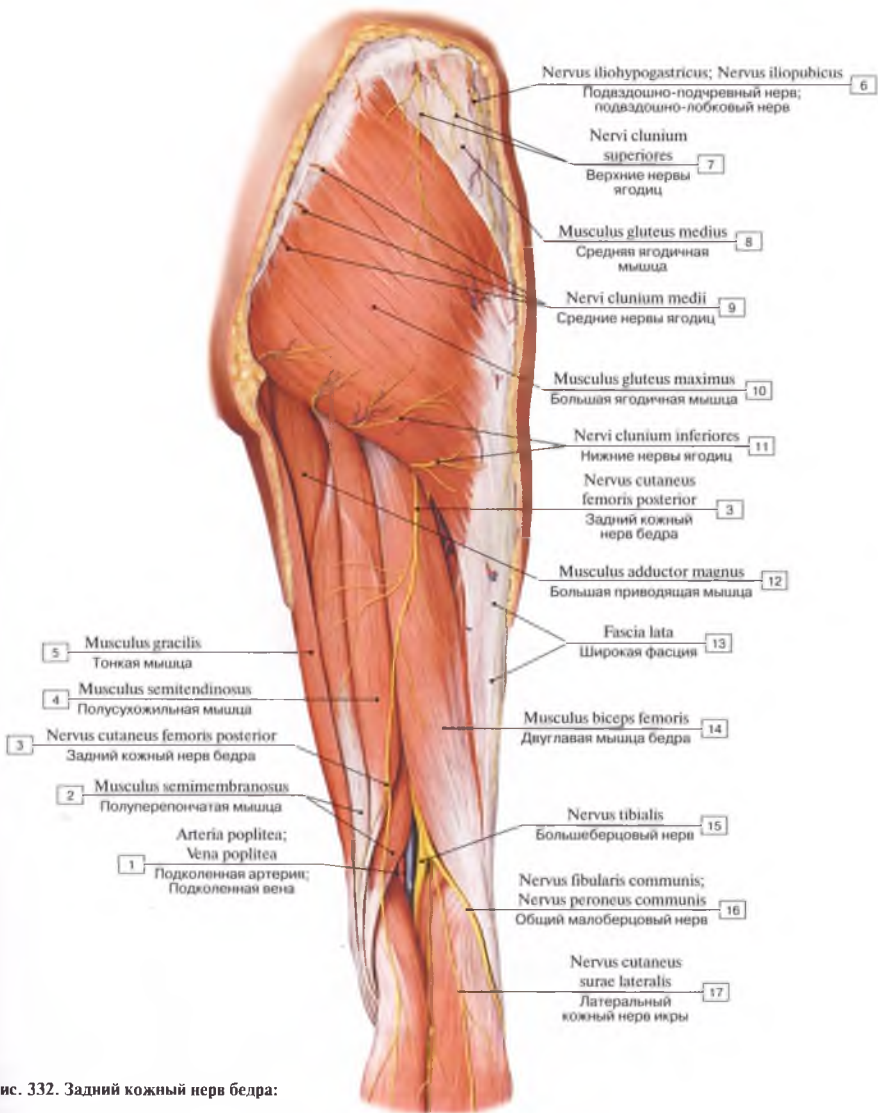


Рис. 332. Задний кожный нерв бедра:

1 — Popliteal artery; Popliteal vein; 2 — Semimembranosus;

3 — Posterior cutaneous nerve of thigh; Posterior femoral

cutaneous nerve; 4 — Semitendinosus; 5 — Gracilis; 6 — Iliohypogastric nerve; Iliopubic nerve; 7 — Superior clunial nerves; 8 — Gluteus

medius; 9 — Middle clunial nerves; 10 — Gluteus maximus; 11 — Inferior clunial nerves; 12 — Adductor magnus; 13 — Fascia lata; 14 — Biceps

femoris; 15 — Tibial nerve; 16 — Common fibular nerve; Common peroneal nerve; 17 — Lateral sural cutaneous nerve

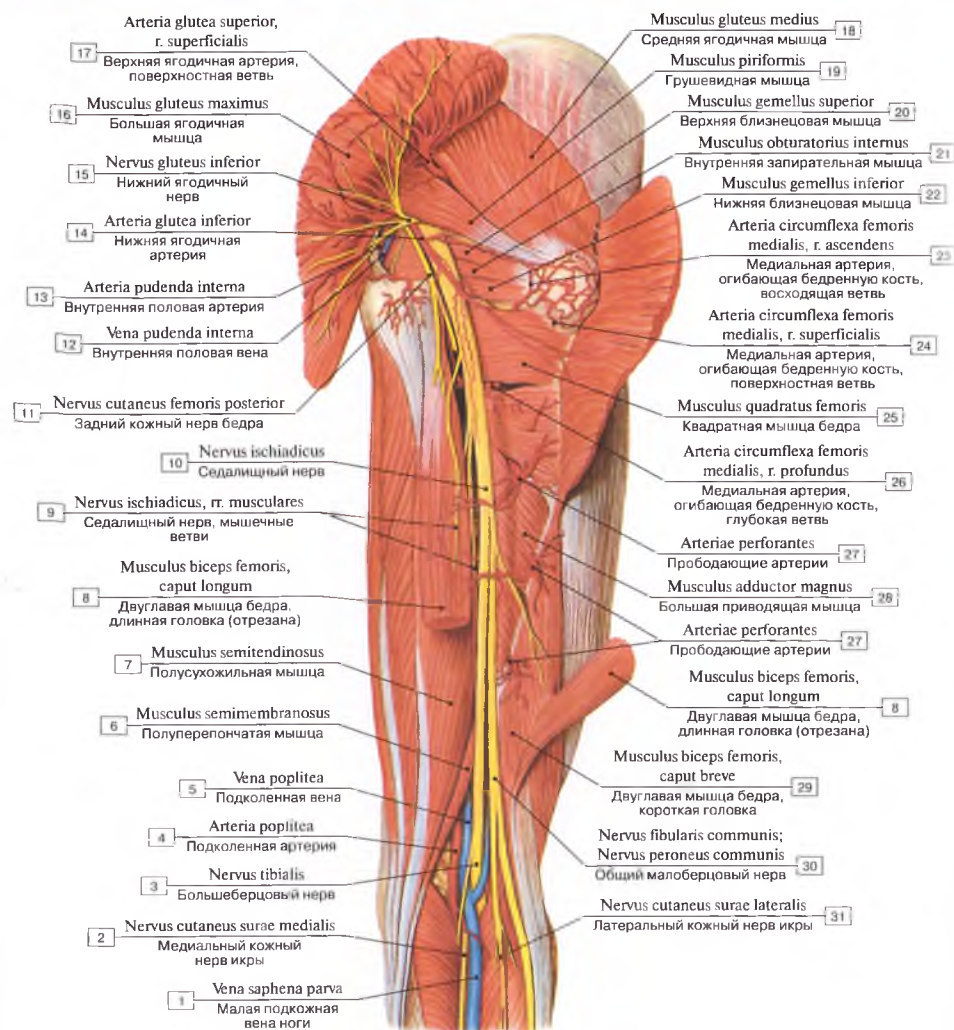
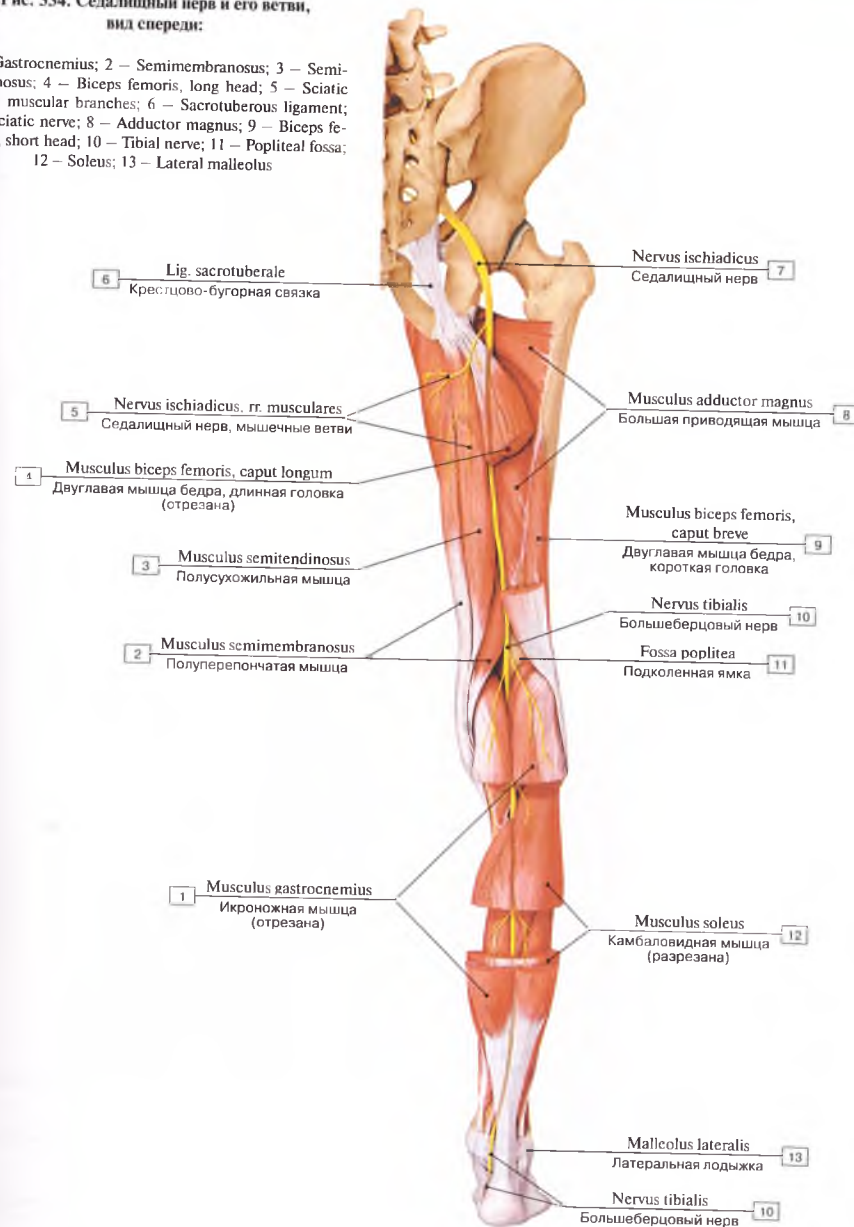


Рис. 333. Седлищный нерв:

1 – Small saphenous vein; Short saphenous vein; 2 – Medial sural cutaneous nerve; 3 – Tibial nerve; 4 – Popliteal artery; 5 – Popliteal vein; 6 – Semimembranosus; 7 – Semitendinosus; 8 – Biceps femoris, long head; 9 – Sciatic nerve, muscular branches; 10 – Sciatic nerve; 11 – Posterior cutaneous nerve of thigh; Posterior femoral cutaneous nerve; 12 – Internal pudendal vein; 13 – Internal pudendal artery; 14 – Inferior gluteal artery; 15 – Inferior gluteal nerve; 16 – Gluteus maximus; 17 – Superior gluteal artery, superficial branch; 18 – Gluteus medius; 19 – Piriformis; 20 – Gemellus superior; Superior gemellus; 21 – Obturator internus; 22 – Gemellus inferior; Inferior gemellus; 23 – Medial circumflex femoral artery, ascending branch; 24 – Medial circumflex femoral artery, superficial branch; 25 – Quadratus femoris; 26 – Medial circumflex femoral artery, deep branch; 27 – Perforating arteries; 28 – Adductor magnus; 29 – Biceps femoris, short head; 30 – Common fibular nerve; Common peroneal nerve; 31 – Lateral sural cutaneous nerve

Рис. 334. Седлищный нерв и его ветви, вид спереди:

1 – Gastrocnemius; 2 – Semimembranosus; 3 – Semitendinosus; 4 – Biceps femoris, long head; 5 – Sciatic nerve, muscular branches; 6 – Sacrotuberous ligament; 7 – Sciatic nerve; 8 – Adductor magnus; 9 – Biceps femoris, short head; 10 – Tibial nerve; 11 – Popliteal fossa; 12 – Soleus; 13 – Lateral malleolus



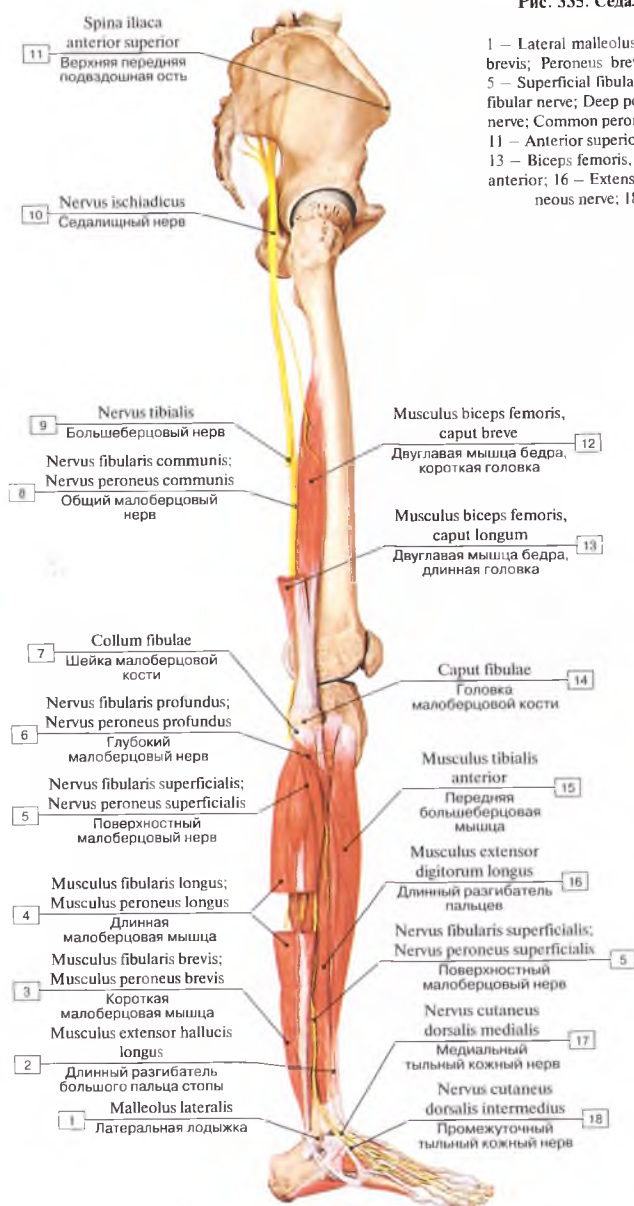


Рис. 335. Седалищный нерв и его ветви, вид сбоку:

1 – Lateral malleolus; 2 – Extensor hallucis longus; 3 – Fibularis brevis; Peroneus brevis; 4 – Fibularis longus; Peroneus longus; 5 – Superficial fibular nerve; Superficial peroneal nerve; 6 – Deep fibular nerve; Deep peroneal nerve; 7 – Neck; 8 – Common fibular nerve; Common peroneal nerve; 9 – Tibial nerve; 10 – Sciatic nerve; 11 – Anterior superior iliac spine; 12 – Biceps femoris, short head; 13 – Biceps femoris, long head; 14 – Head of fibula; 15 – Tibialis anterior; 16 – Extensor digitorum longus; 17 – Medial dorsal cutaneous nerve; 18 – Intermediate dorsal cutaneous nerve

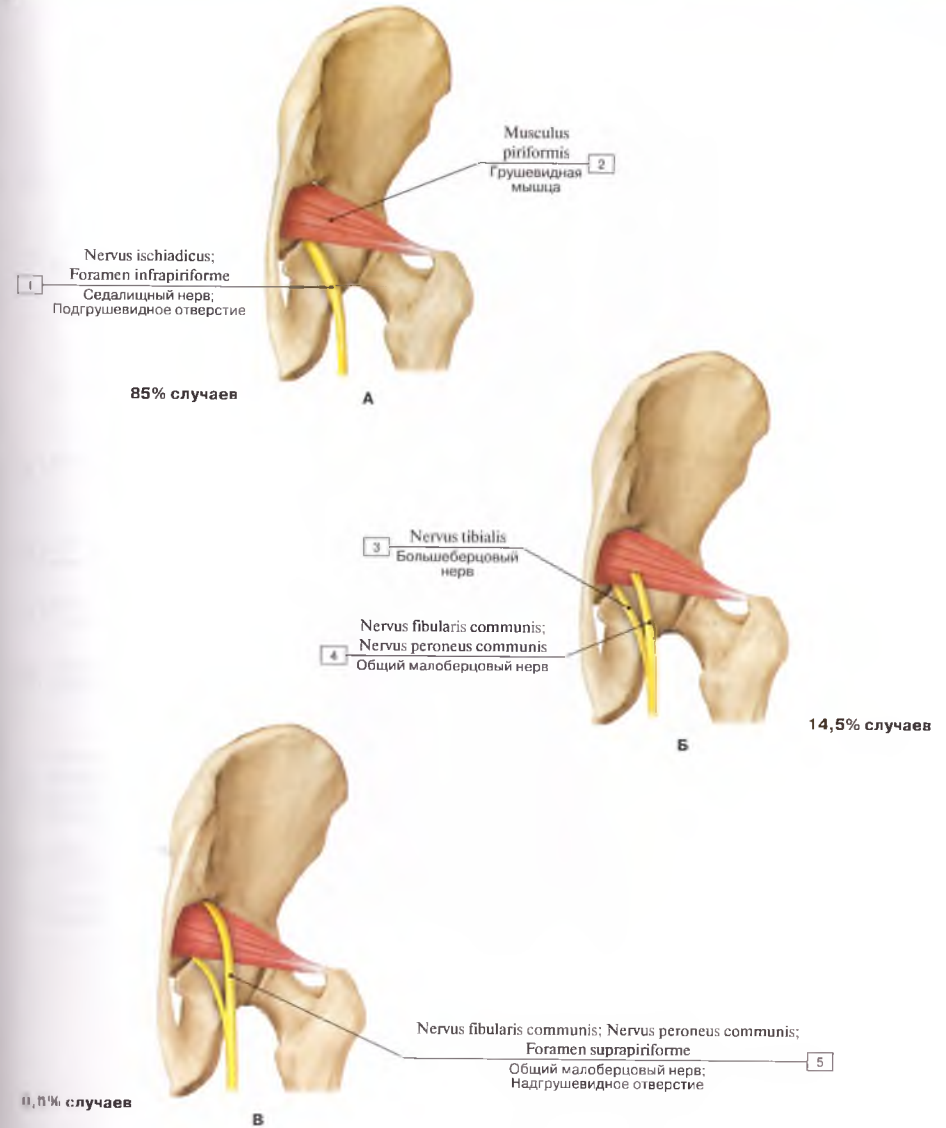


Рис. 336. Варианты выхода седалищного нерва (А – через подгрушевидное отверстие; Б – через подгрушевидное отверстие и грушевидную мышцу; В – через над- и подгрушевидные отверстия:

1 – Ischialtic nerve; Infrapiriform foramen; 2 – Piriformis; 3 – Tibial nerve; 4 – Common fibular nerve; Common peroneal nerve; 5 – Common fibular nerve; Suprapiriform foramen

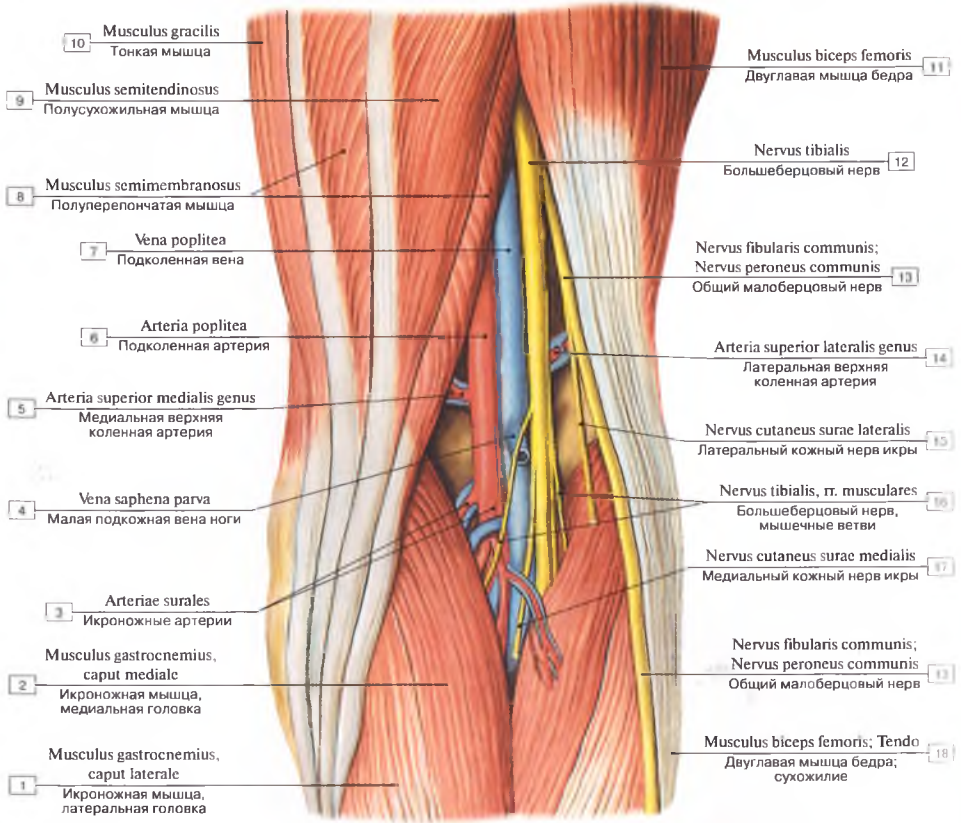


Рис. 337. Сосуды и нервы подколенной ямки:

1 – Gastrocnemius, lateral head; 2 – Gastrocnemius, medial head; 3 – Sural arteries; 4 – Small saphenous vein; Short saphenous vein; 5 – Superior medial genicular artery; 6 – Popliteal artery; 7 – Popliteal vein; 8 – Semimembranosus; 9 – Semitendinosus; 10 – Gracilis; 11 – Biceps femoris; 12 – Tibial nerve; 13 – Common fibular nerve; Common peroneal nerve; 14 – Superior lateral genicular artery; 15 – Lateral sural cutaneous nerve; 16 – Tibial nerve, muscular branches; 17 – Medial sural cutaneous nerve; 18 – Biceps femoris; Tendon

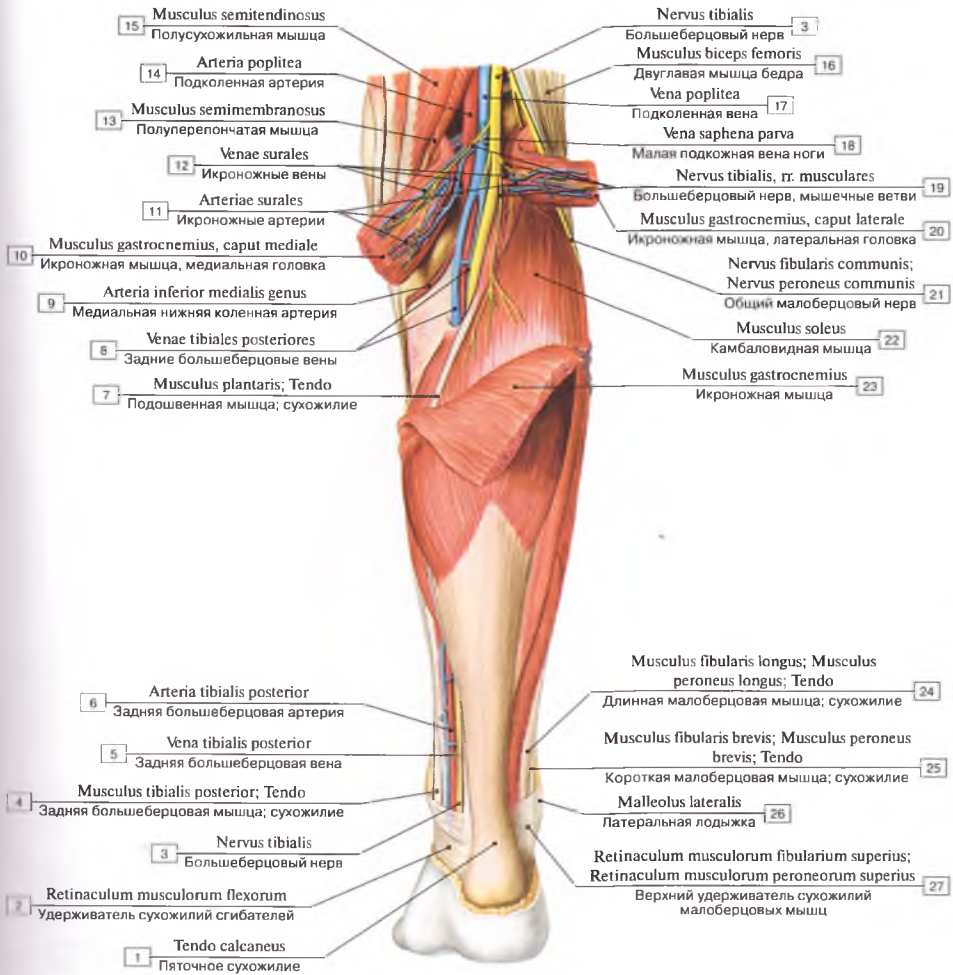


Рис. 338. Сосуды и нервы голени:

1 – Calcaneal tendon; 2 – Flexor retinaculum; 3 – Tibial nerve; 4 – Tibialis posterior; Tendon; 5 – Posterior tibial vein; 6 – Posterior tibial artery; 7 – Plantaris; Tendon; 8 – Posterior tibial veins; 9 – Inferior medial genicular artery; 10 – Gastrocnemius, medial head; 11 – Sural arteries; 12 – Sural veins; 13 – Semimembranosus; 14 – Popliteal artery; 15 – Semitendinosus; 16 – Biceps femoris; 17 – Popliteal vein; 18 – Small saphenous vein; Short saphenous vein; 19 – Tibial nerve, muscular branches; 20 – Gastrocnemius, lateral head; 21 – Common tibular nerve; Common peroneal nerve; 22 – Soleus; 23 – Gastrocnemius; 24 – Fibularis longus; Peroneus longus; Tendon; 25 – Fibularis brevis; Peroneus brevis; Tendon; 26 – Lateral malleolus; 27 – Superior fibular retinaculum; Superior peroneal retinaculum

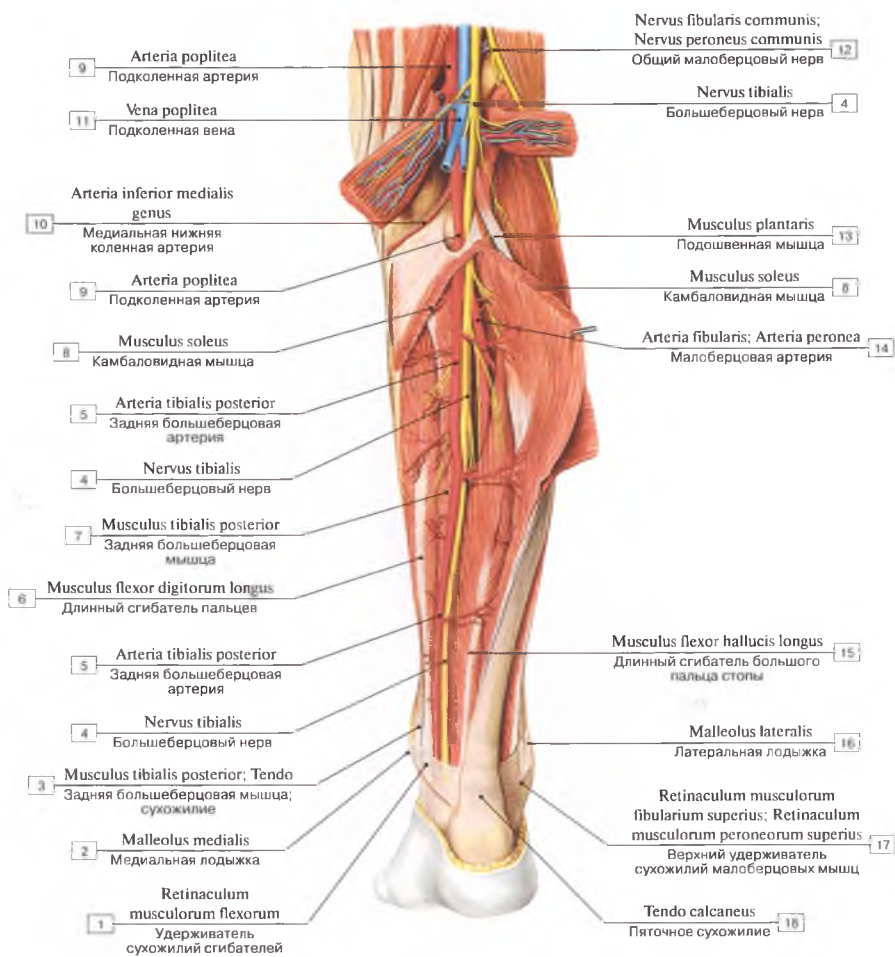


Рис. 339. Большеберцовый нерв, вид сзади:

1 – Flexor retinaculum; 2 – Medial malleolus; 3 – Tibialis posterior; Tendon; 4 – Tibial nerve; 5 – Posterior tibial artery; 6 – Flexor digitorum longus; 7 – Tibialis posterior; 8 – Soleus; 9 – Popliteal artery; 10 – Inferior medial genicular artery; 11 – Popliteal vein; 12 – Common fibular nerve; Common peroneal nerve; 13 – Plantaris; 14 – Fibular artery; Peroneal artery; 15 – Flexor hallucis longus; 16 – Latral malleolus; 17 – Superior fibular retinaculum; Superior peroneal retinaculum; 18 – Calcaneal tendon



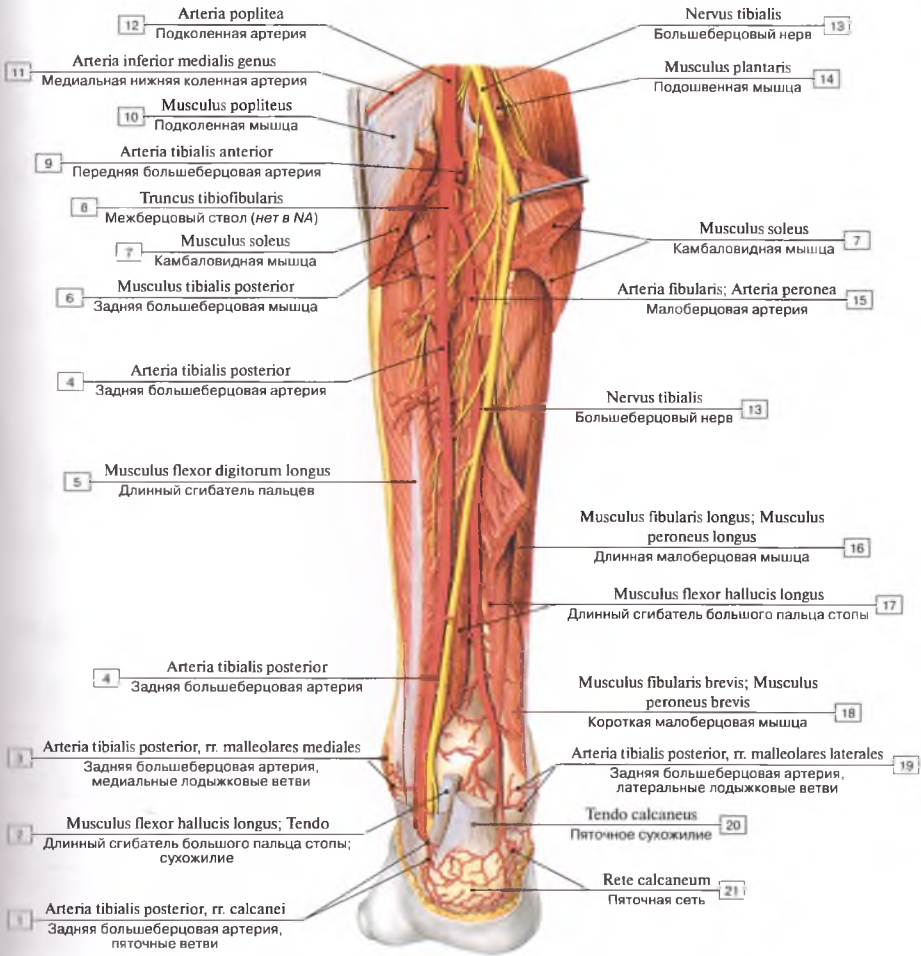


Рис. 340. Большеберцовые нерв и артерия:

- 1 — Posterior tibial artery, calcaneal branches; 2 — Flexor hallucis longus; Tendon; 3 — Posterior tibial artery, medial malleolar branches; 4 — Posterior tibial artery; 5 — Flexor digitorum longus; 6 — Tibialis posterior; 7 — Soleus; 8 — Tibiofibular trunk; 9 — Anterior tibial artery; 10 — Popliteus; 11 — Inferior medial genicular artery; 12 — Popliteal artery; 13 — Tibial nerve; 14 — Plantaris; 15 — Fibular artery; Peroneal artery; 16 — Fibularis longus; Peroneus longus; 17 — Flexor hallucis longus; 18 — Fibularis brevis; Peroneus brevis; 19 — Posterior tibial artery, lateral malleolar branches; 20 — Calcaneal tendon; 21 — Calcaneal anastomosis

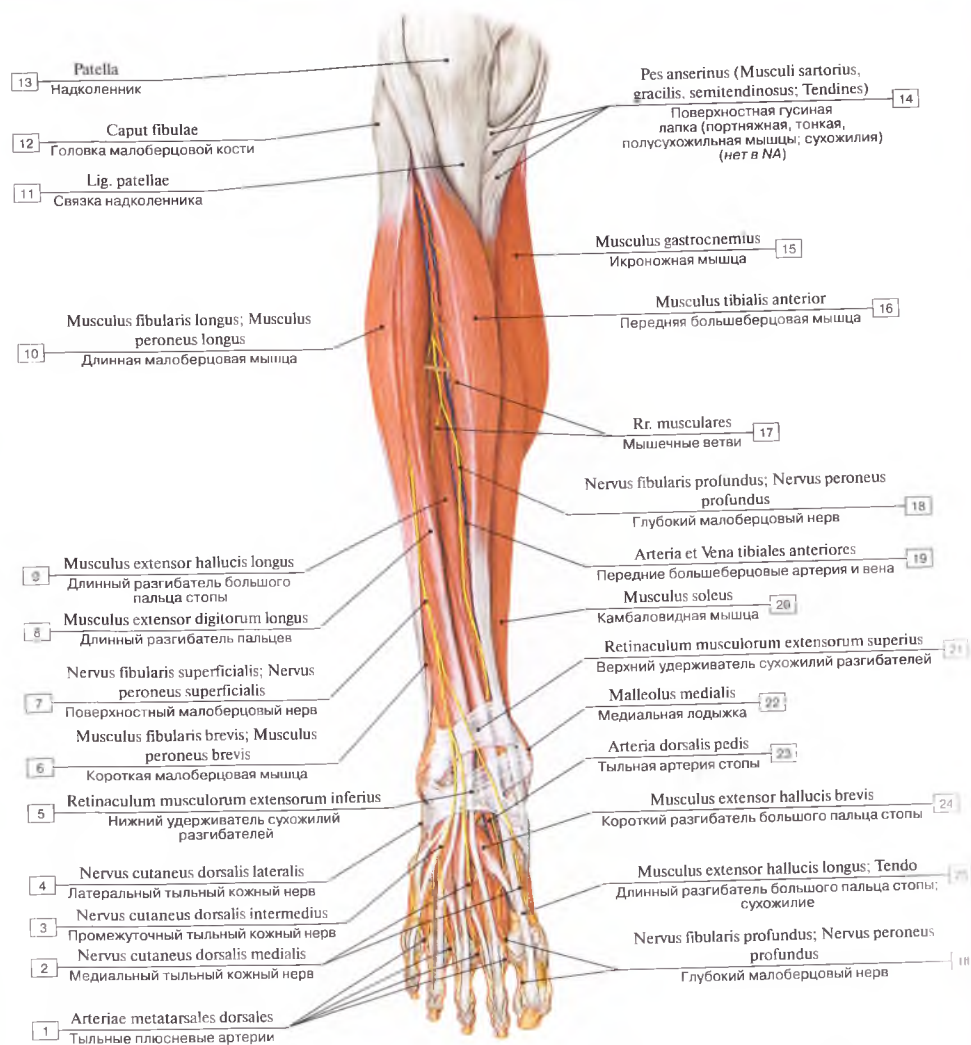


Рис. 341. Малоберцовый нерв:

1 - Dorsal metatarsal arteries; 2 - Medial dorsal cutaneous nerve; 3 - Intermediate dorsal cutaneous nerve; 4 - Lateral dorsal cutaneous nerve; 5 - Inferior extensor retinaculum; 6 - Fibularis brevis; Peroneus brevis; 7 - Superficial fibular nerve; Superficial peroneal nerve; 8 - Extensor digitorum longus; 9 - Extensor hallucis longus; 10 - Fibularis longus; Peroneus longus; 11 - Patellar ligament; 12 - Head of fibula; 13 - Patella; 14 - Pes anserinus (Sartorius, Gracilis, Semitendinosus; Tendons); 15 - Gastrocnemius; 16 - Tibialis anterior; 17 - Muscular branches; 18 - Deep fibular nerve; Deep peroneal nerve; 19 - Anterior tibial artery and vein; 20 - Soleus; 21 - Superior extensor retinaculum; 22 - Medial malleolus; 23 - Dorsal pedis artery; Dorsal artery of foot; 24 - Extensor hallucis brevis; 25 - Extensor hallucis longus; Tendon

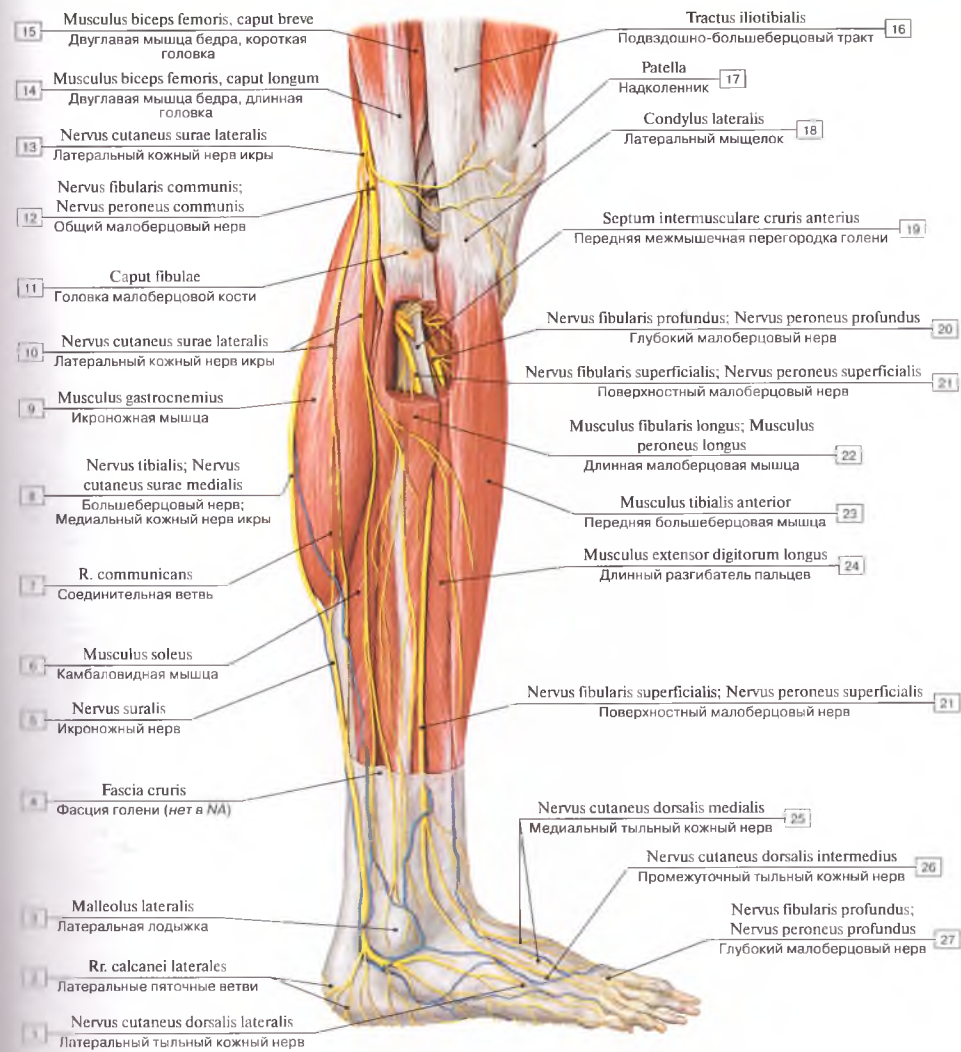


Рис. 342. Малоберцовый нерв, вид сбоку:

1 - Lateral dorsal cutaneous nerve; 2 - Lateral calcaneal branches; 3 - Lateral malleolus; 4 - Fascia of leg; 5 - Sural nerve; 6 - Soleus; 7 - Communicating branch; 8 - Tibial nerve; Medial sural cutaneous nerve; 9 - Gastrocnemius; 10 - Lateral sural cutaneous nerve; 11 - Head of fibula; 12 - Common fibular nerve; Common peroneal nerve; 13 - Lateral sural cutaneous nerve; 14 - Biceps femoris, long head; 15 - Biceps femoris, short head; 16 - Iliotibial tract; 17 - Patella; 18 - Lateral condyle; 19 - Anterior intermuscular septum of leg; 20 - Deep fibular nerve; Deep peroneal nerve; 21 - Superficial fibular nerve; Superficial peroneal nerve; 22 - Fibularis longus; Peroneus longus; 23 - Tibialis anterior; 24 - Extensor digitorum longus; 25 - Medial dorsal cutaneous nerve; 26 - Intermediate dorsal cutaneous nerve; 27 - Deep fibular nerve; Deep peroneal nerve

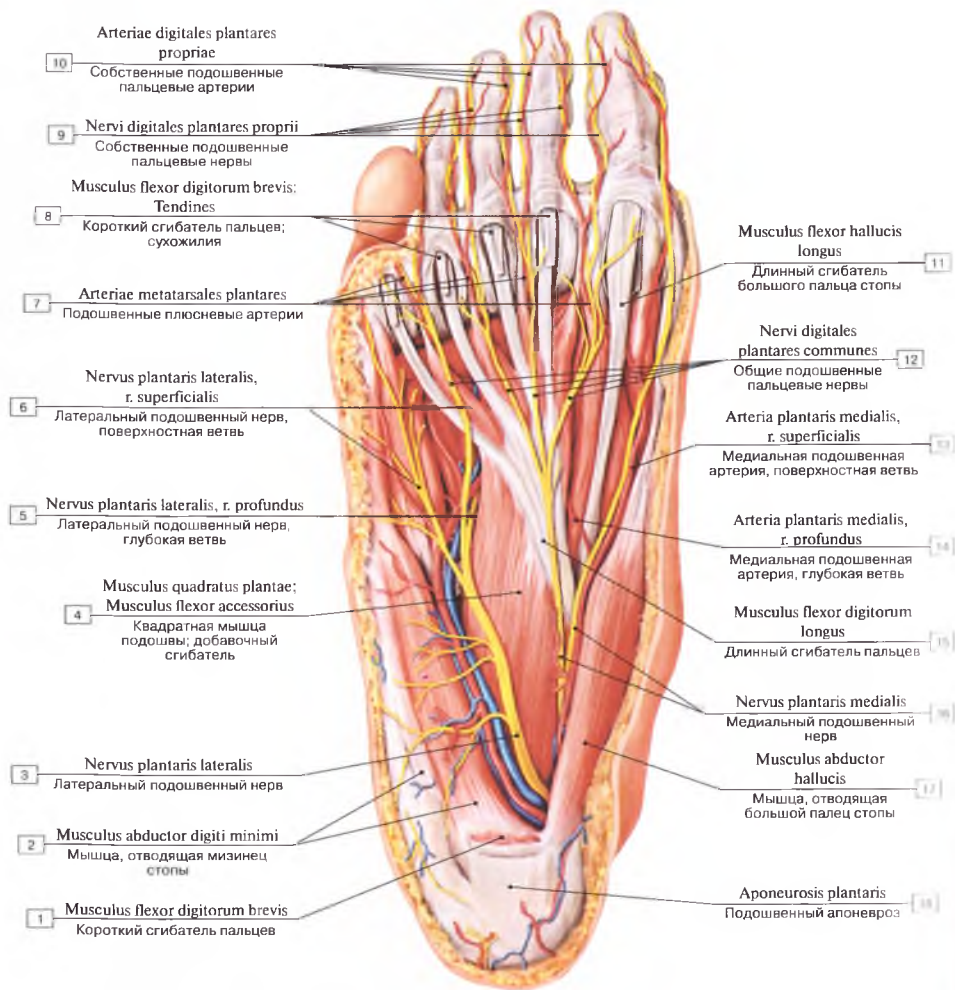


Рис. 343. Сосуды и нервы стопы (подошвенная поверхность):

1 – Flexor digitorum brevis; 2 – Abductor digiti minimi; 3 – Lateral plantar nerve; 4 – Quadratus plantae; Flexor accessorius; 5 – Lateral plantar nerve, deep branch; 6 – Lateral plantar nerve, superficial branch; 7 – Plantar metatarsal arteries; 8 – Flexor digitorum brevis; Tendines; 9 – Proper plantar digital nerves; 10 – Proper plantar digital arteries; 11 – Flexor hallucis longus; 12 – Common plantar digital nerves; 13 – Medial plantar artery, superficial branch; 14 – Medial plantar artery, deep branch; 15 – Flexor digitorum longus; 16 – Medial plantar nerve; 17 – Abductor hallucis; 18 – Plantar aponeurosis

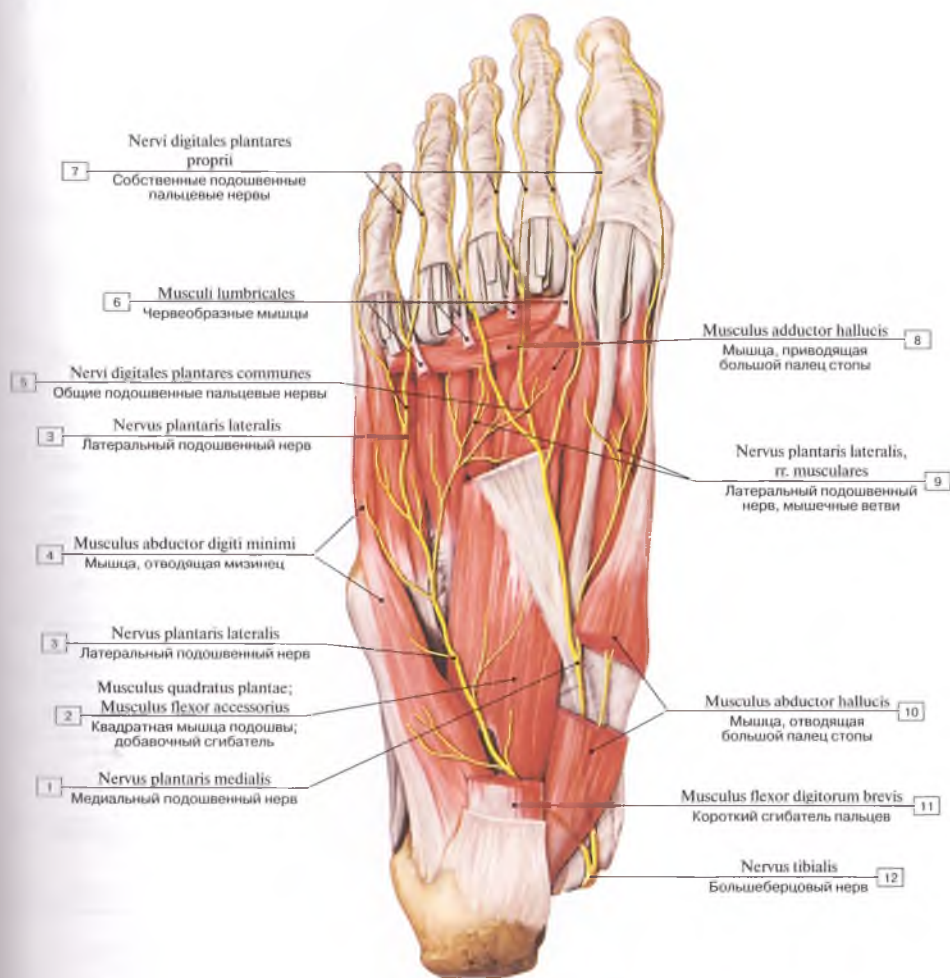


Рис. 344. Нервы стопы (подошвенная поверхность):

1 — Medial plantar nerve; 2 — Quadratus plantae; Flexor accessorius; 3 — Lateral plantar nerve; 4 — Abductor digiti minimi; 5 — Common plantar digital nerves; 6 — Lumbricals; 7 — Proper plantar digital nerves; 8 — Adductor hallucis; 9 — Lateral plantar nerve, muscular branches; 10 — Abductor hallucis; 11 — Flexor digitorum brevis; 12 — Tibial nerve

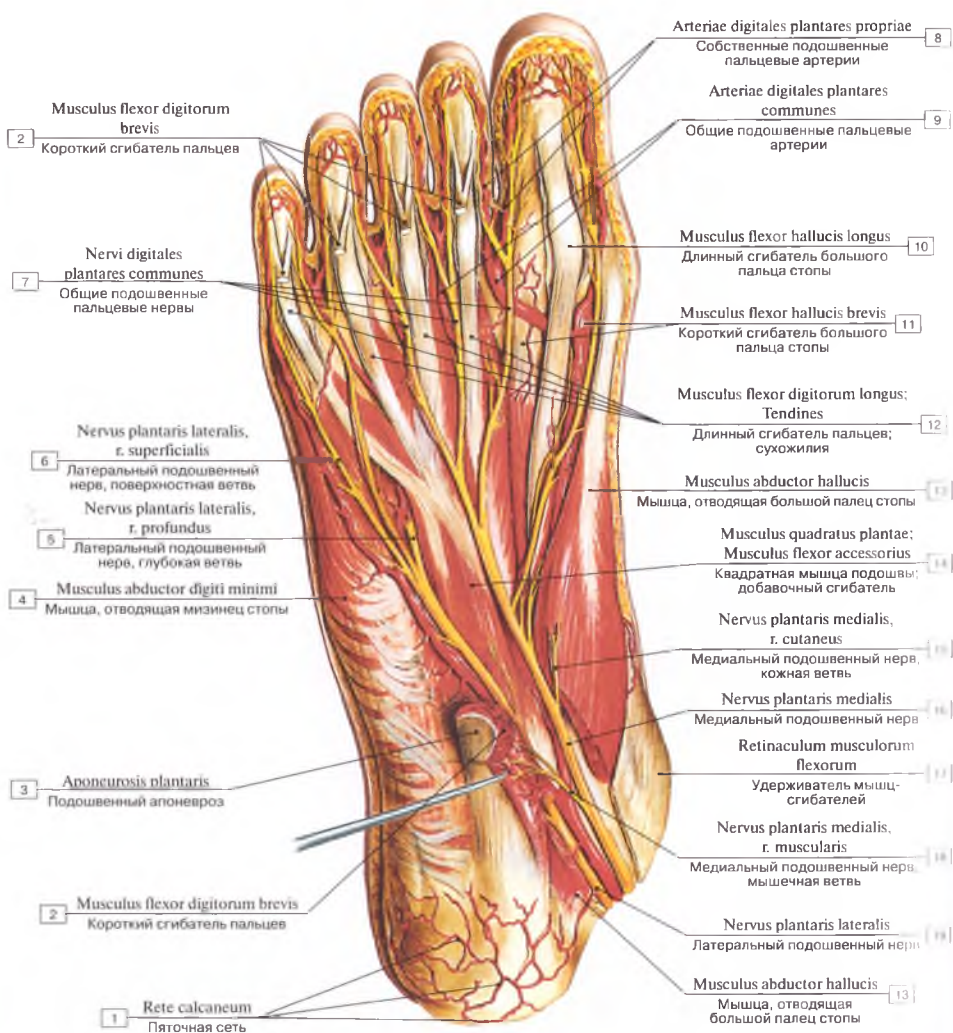


Рис. 345. Нервы стопы (подошвенная поверхность):

1 – Calcaneal anastomosis; 2 – Flexor digitorum brevis; 3 – Plantar aponeurosis; 4 – Abductor digiti minimi; 5 – Lateral plantar nerve, deep branch; 6 – Lateral plantar nerve, superficial branch; 7 – Common plantar digital nerves; 8 – Proper plantar digital arteries; 9 – Common plantar digital arteries; 10 – Flexor hallucis longus; 11 – Flexor hallucis brevis; 12 – Flexor digitorum longus; Tendons; 13 – Abductor hallucis; 14 – Quadratus plantae; Flexor accessorius; 15 – Medial plantar nerve, cutaneous branch; 16 – Medial plantar nerve; 17 – Flexor digitorum longus; 18 – Medial plantar nerve, muscular branch; 19 – Lateral plantar nerve

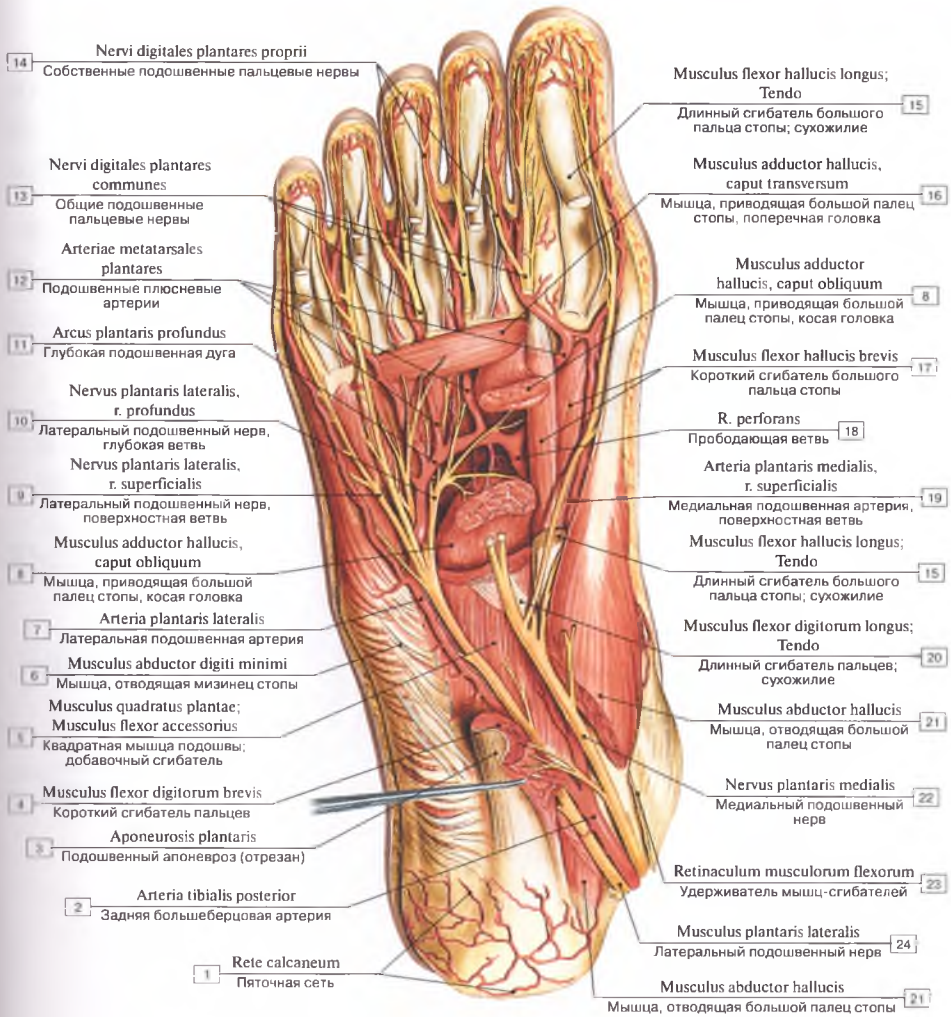


Рис. 346. Нервы стопы (подошвенная поверхность):

1 — Calcaneal anastomosis; 2 — Posterior tibial artery; 3 — Plantar aponeurosis; 4 — Flexor digitorum brevis; 5 — Quadratus plantae; Flexor accessorius; 6 — Abductor digiti minimi; 7 — Lateral plantar artery; 8 — Adductor hallucis, oblique head; 9 — Lateral plantar nerve, superficial branch; 10 — Lateral plantar nerve, deep branch; 11 — Deep plantar arch; 12 — Plantar metatarsal arteries; 13 — Common plantar digital nerves; 14 — Proper plantar digital nerves; 15 — Flexor hallucis longus; Tendon; 16 — Adductor hallucis, transverse head; 17 — Flexor hallucis brevis; 18 — Perforating branch; 19 — Medial plantar artery, superficial branch; 20 — Flexor digitorum longus; Tendon; 21 — Abductor hallucis; 22 — Medial plantar nerve; 23 — Flexor retinaculum; 24 — Lateral plantar nerve

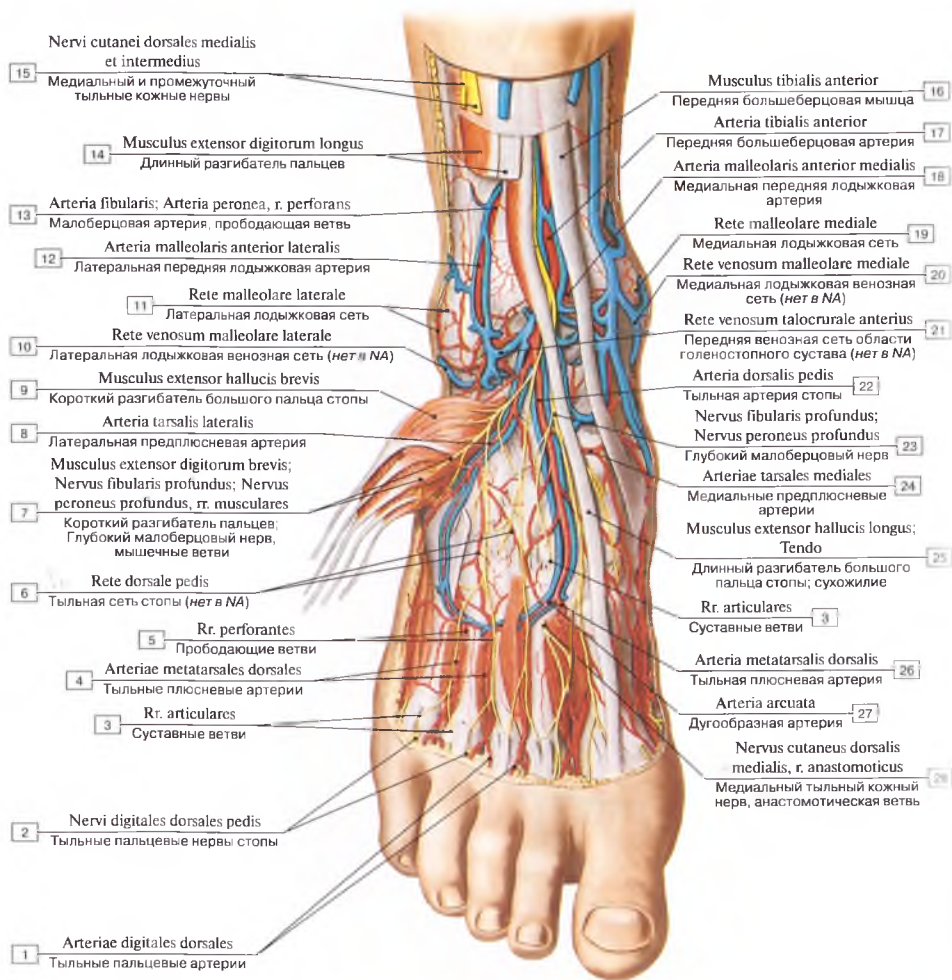


Рис. 347. Сосуды и нервы стопы (тыльная поверхность):

1 – Dorsal digital arteries; 2 – Dorsal digital nerves of foot; 3 – Articular branches; 4 – Dorsal metatarsal arteries; 5 – Perforating branches; 6 – Dorsal network of foot; 7 – Extensor digitorum brevis; Deep fibular nerve; Deep peroneal nerve, muscular branches; 8 – Lateral tarsal artery; 9 – Extensor hallucis brevis; 10 – Lateral malleolar venous network; 11 – Lateral malleolar network; 12 – Anterior lateral malleolar artery; 13 – Fibular artery; Peroneal artery, perforating branch; 14 – Extensor digitorum longus; 15 – Medial and intermediate dorsal cutaneous nerves; 16 – Tibialis anterior; 17 – Anterior tibial artery; 18 – Anterior medial malleolar artery; 19 – Medial malleolar network; 20 – Medial malleolar venous network; 21 – Anterior talocrural venous network; 22 – Dorsal pedis artery; Dorsal artery of foot; 23 – Deep fibular nerve; Deep peroneal nerve; 24 – Medial tarsal arteries; 25 – Extensor hallucis longus; Tendon; 26 – Dorsal metatarsal artery; 27 – Arcuate artery; 28 – Medial dorsal cutaneous nerve, anastomotic branch

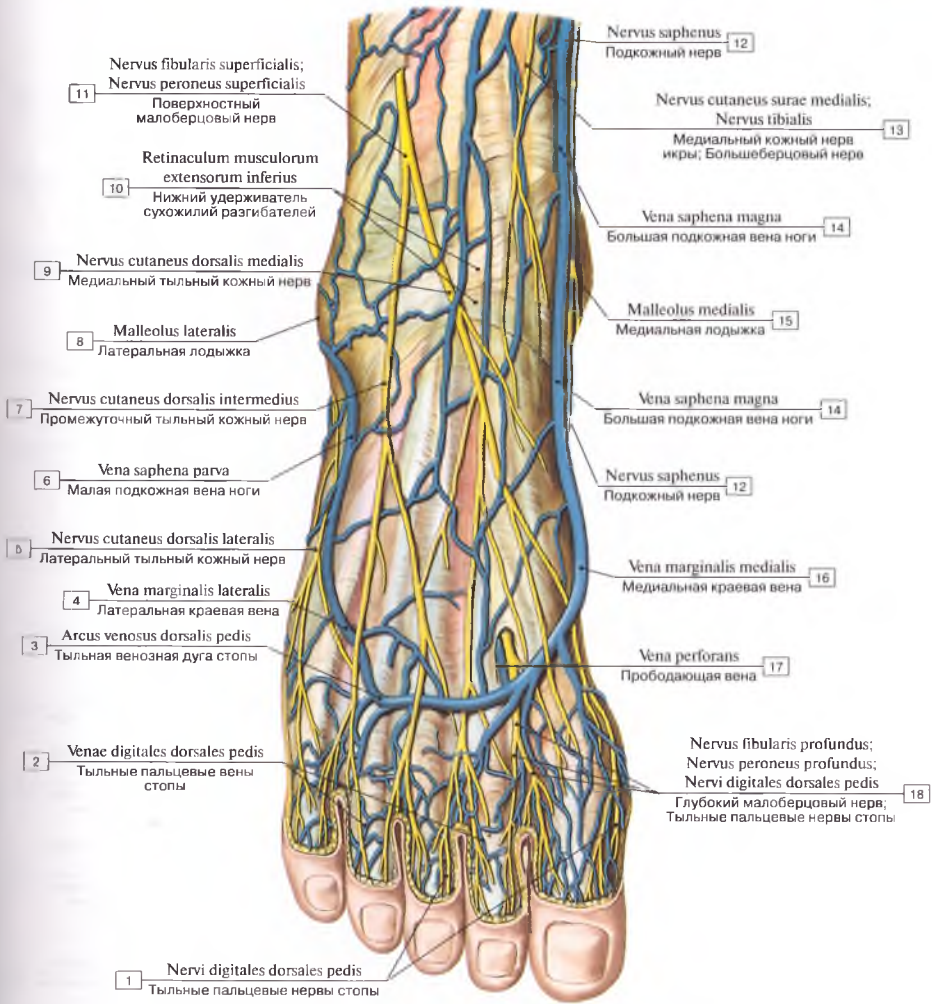


Рис. 348. Нервы и вены стопы (тыльная поверхность):

1 — Dorsal digital nerves of foot; 2 — Dorsal digital veins; 3 — Dorsal venous arch of foot; 4 — Lateral dorsal cutaneous nerve; 5 — Small saphenous vein; 6 — Small saphenous vein; Short saphenous vein; 7 — Intermediate dorsal cutaneous nerve; 8 — Lateral malleolus; 9 — Medial dorsal cutaneous nerve; 10 — Inferior extensor retinaculum; 11 — Superficial fibular nerve; Superficial peroneal nerve; 12 — Saphenous nerve; 13 — Medial sural cutaneous nerve; Tibial nerve; 14 — Great saphenous vein; Long saphenous vein; 15 — Medial malleolus; 16 — Medial marginal vein; 17 — Perforating vein; 18 — Deep fibular nerve; Deep peroneal nerve; Dorsal digital nerves of foot



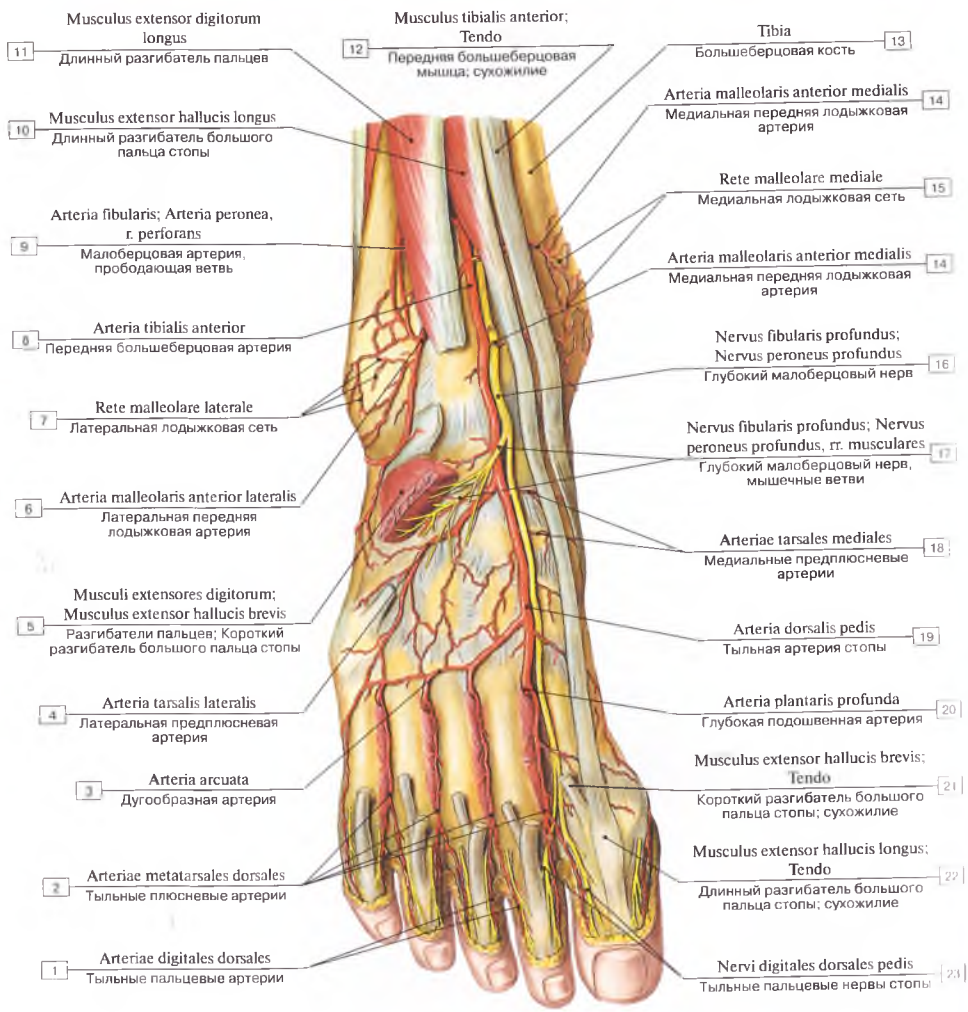


Рис. 349. Глубокий малоберцовый нерв и его ветви:

1 – Dorsal digital arteries; 2 – Dorsal metatarsal arteries; 3 – Arcuate artery; 4 – Lateral tarsal artery; 5 – Extensor digitorum; Extensor hallucis brevis; 6 – Anterior lateral malleolar artery; 7 – Lateral malleolar network; 8 – Anterior tibial artery; 9 – Fibular artery; Peroneal artery, perforating branch; 10 – Extensor hallucis longus; 11 – Extensor digitorum longus; 12 – Tibialis anterior; Tendon; 13 – Tibia; 14 – Anterior medial malleolar artery; 15 – Medial malleolar network; 16 – Deep fibular nerve; Deep peroneal nerve; 17 – Deep fibular nerve; Deep peroneal nerve, muscular branches; 18 – Medial tarsal arteries; 19 – Dorsal artery of foot; 20 – Deep plantar artery; 21 – Extensor hallucis brevis; Tendon; 22 – Extensor hallucis longus; Tendon; 23 – Dorsal digital nerves of foot

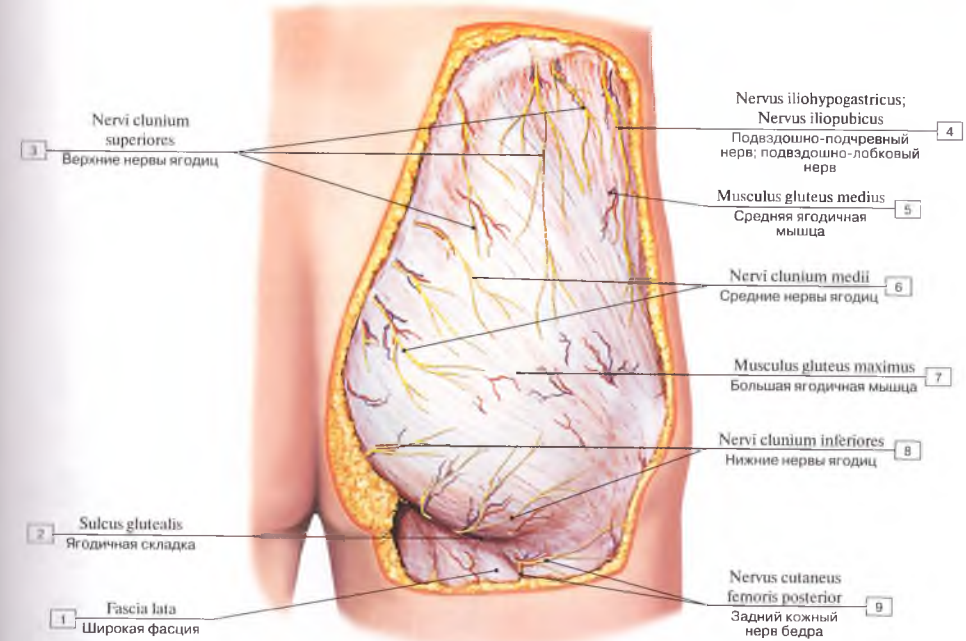


Рис. 350. Поверхностные нервы ягодичной области:

1 – Fascia lata; 2 – Gluteal fold; 3 – Superior clunial nerves; 4 – Iliohypogastric nerve; Iliopubic nerve; 5 – Gluteus medius; 6 – Middle clunial nerves; 7 – Gluteus maximus; 8 – Inferior clunial nerves; 9 – Posterior cutaneous nerve of thigh; Posterior femoral cutaneous nerve

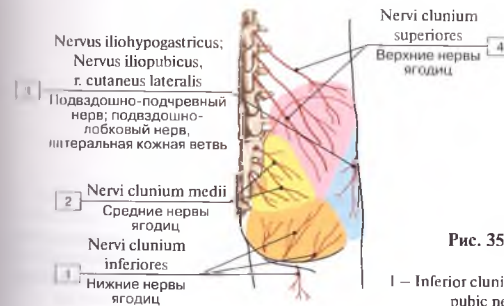


Рис. 351. Кожная иннервация ягодичной области (схема):

1 – Inferior clunial nerves; 2 – Medial clunial nerves; 3 – Iliohypogastric nerve; Iliopubic nerve, lateral cutaneous branch; 4 – Superior clunial nerves

- Половой нерв
- Подвздошно-паховый нерв и бедренно-половой нерв, половая ветвь
- Задний кожный нерв бедра
- Нижний ягодичный нерв
- Верхний ягодичный нерв
- Средний ягодичный нерв
- Заднепреходно-копчиковый нерв

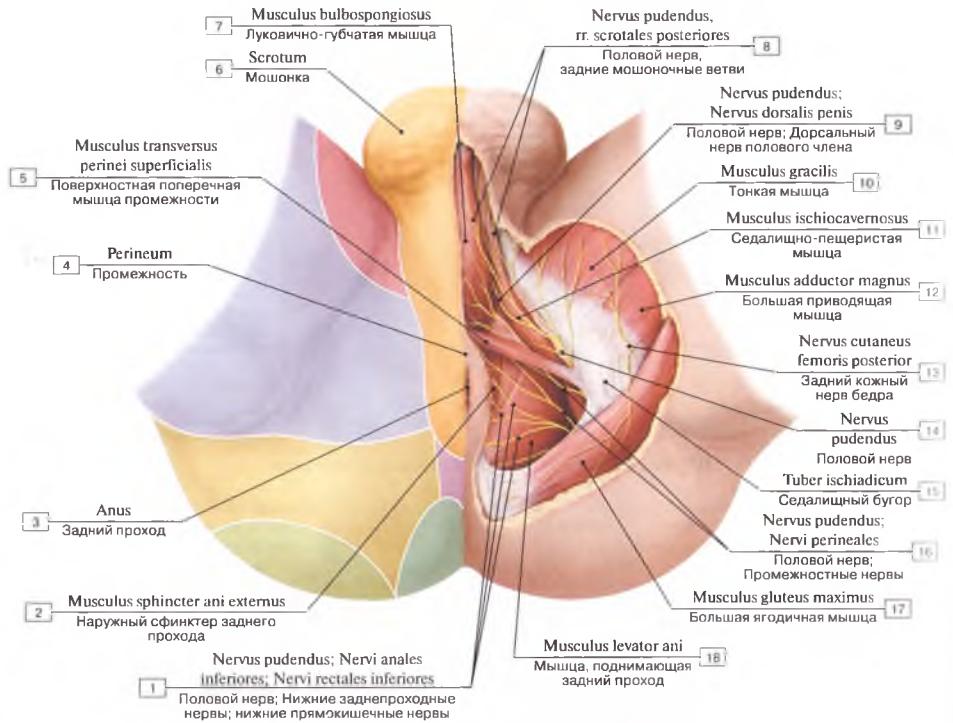


Рис. 352. Иннервация кожи мужской промежности:

1 – Pudendal nerve; Inferior anal nerves; Inferior rectal nerves; 2 – External anal sphincter; 3 – Anus; 4 – Perineum; 5 – Superficial transverse perineal muscle; 6 – Scrotum; 7 – Bulbospongiosus; 8 – Pudendal nerve; posterior scrotal branches; 9 – Pudendal nerve; Dorsal nerve of penis; 10 – Gracilis; 11 – Ischiocavernosus; 12 – Adductor magnus; 13 – Posterior cutaneous nerve of thigh; Posterior femoral cutaneous nerve; 14 – Pudendal nerve; 15 – Ischial tuber; 16 – Pudendal nerve; Perineal nerves; 17 – Gluteus maximus; 18 – Levator ani

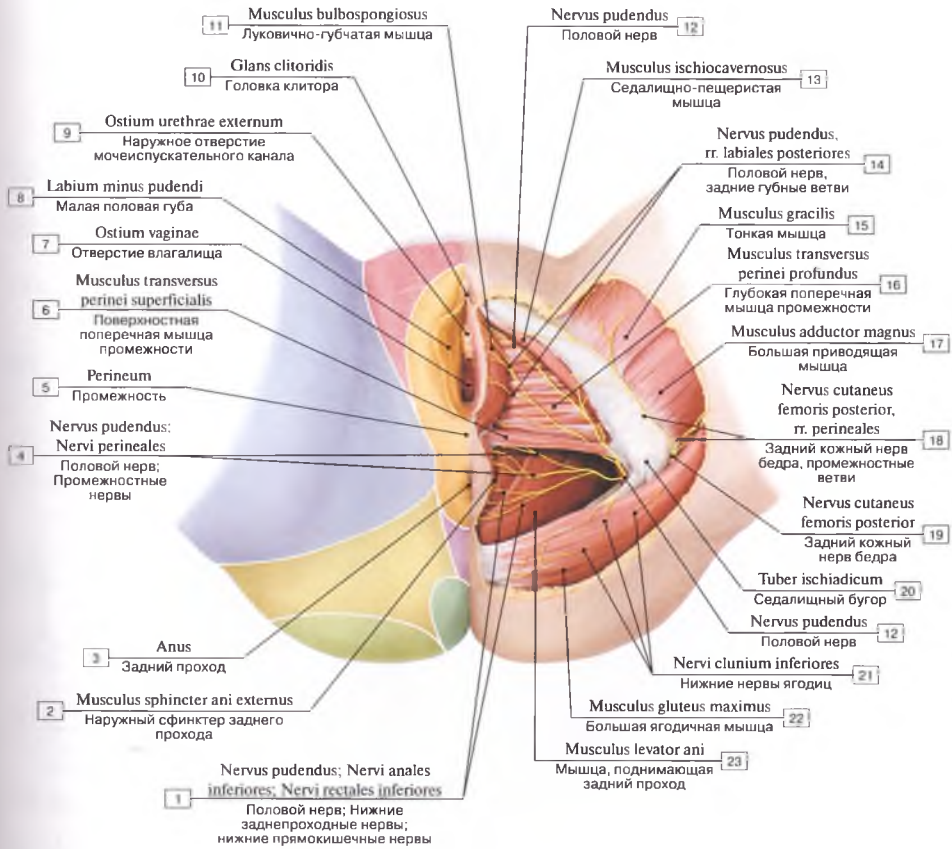


Рис. 353. Иннервация кожи женской промежности:

1 — Pudendal nerve, inferior anal nerves; inferior rectal nerves; 2 — External anal sphincter; 3 — Anus; 4 — Pudendal nerve; Perineal nerves; 5 — Perineum; 6 — Superficial transverse perineal muscle; 7 — Vaginal orifice; 8 — Labium minus; 9 — External urethral orifice; External urinary meatus; 10 — Glans of clitoris; 11 — Bulbospongiosus; 12 — Pudendal nerve; 13 — Ischio cavernosus; 14 — Pudendal nerve, posterior labial branches; 15 — Gracilis; 16 — Deep transverse perineal muscle; 17 — Adductor magnus; 18 — Posterior cutaneous of thigh; Posterior femoral cutaneous nerve, perineal branches; 19 — Posterior cutaneous of thigh; Posterior femoral cutaneous nerve; 20 — Ischial tuber; 21 — Inferior clunial nerves; 22 — Gluteus maximus; 23 — Levator ani

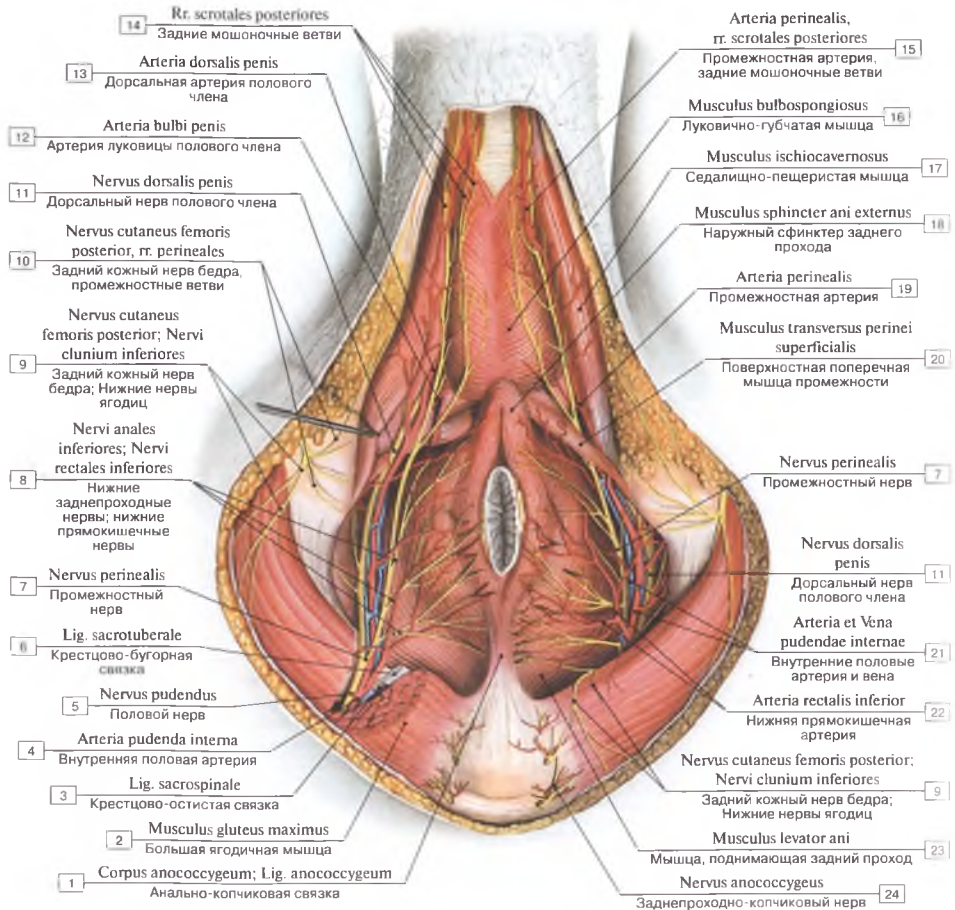


Рис. 354. Сосуды и нервы мужской промежности:

1 – Anococcygeal body; Anococcygeal ligament; 2 – Gluteus maximus; 3 – Sacrospinous ligament; 4 – Internal pudendal artery; 5 – Pudendal nerve; 6 – Sacrotuberous ligament; 7 – Perineal nerve; 8 – Inferior anal nerves; Inferior rectal nerves; 9 – Posterior cutaneous nerve of thigh; Posterior femoral cutaneous nerve; Inferior clunial nerves; 10 – Posterior cutaneous nerve of thigh; Posterior femoral cutaneous nerve, perineal branches; 11 – Dorsal nerve of penis; 12 – Artery of bulb of penis; 13 – Dorsal artery of penis; 14 – Posterior scrotal nerves; 15 – Perineal artery, posterior scrotal branches; 16 – Bulbospongiosus; 17 – Ischioavernosus; 18 – External anal sphincter; 19 – Perineal artery; 20 – Superficial transverse perineal muscle; 21 – Internal pudendal artery and vein; 22 – Inferior rectal artery; 23 – Levator ani; 24 – Anococcygeal nerve

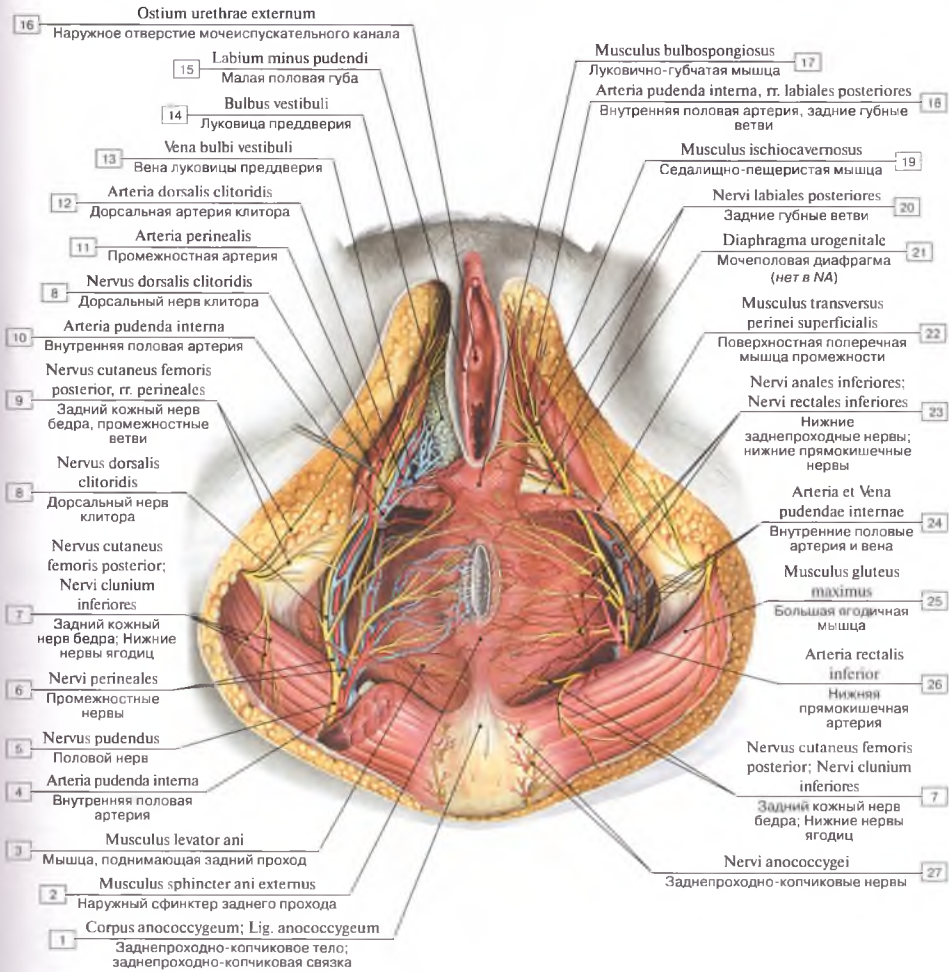


Рис. 355. Сосуды и нервы женской промежности:

1 — Anococcygeal body; Anococcygeal ligament; 2 — External anal sphincter; 3 — Levator ani; 4 — Internal pudendal artery; 5 — Pudendal nerve; 6 — Perineal nerves; 7 — Posterior cutaneous nerve of thigh; Posterior femoral cutaneous nerve, inferior clunial nerves; 8 — Dorsal nerve of clitoris; 9 — Posterior cutaneous nerve of thigh; Posterior femoral cutaneous nerve, perineal branches; 10 — Internal pudendal artery; 11 — Perineal artery; 12 — Dorsal artery of clitoris; 13 — Vein of bulb of vestibule; 14 — Bulb of vestibule; 15 — Labium minus; 16 — External urethral orifice; External urinary meatus; 17 — Bulbospongiosus; 18 — Internal pudendal artery, posterior labial branches; 19 — Ischioavernosus; 20 — Posterior labial nerves; 21 — Urogenital diaphragm; 22 — Superficial transverse perineal muscle; 23 — Inferior anal nerves; Inferior rectal nerves; 24 — Internal pudendal artery and vein; 25 — Gluteus maximus; 26 — Inferior rectal artery; 27 — Anococcygeal nerves

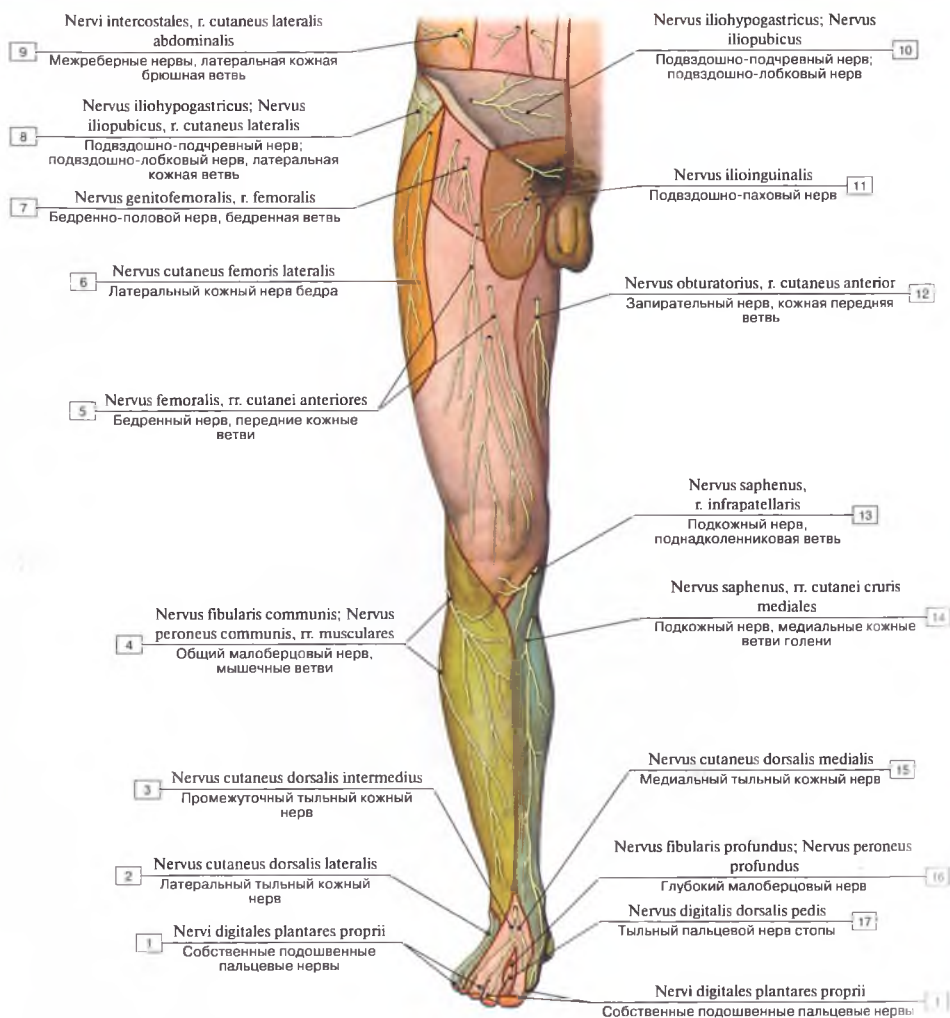


Рис. 356. Кожные ветви поясничного и крестцового сплетений и области их распространения на передней стороне брюшной стенки и на нижней конечности, вид спереди (схема):

1 — Proper plantar digital nerves; 2 — Lateral dorsal cutaneous nerve; 3 — Intermediate dorsal cutaneous nerve; 4 — Common fibular nerve; Common peroneal nerve, muscular branches; 5 — Femoral nerve, anterior cutaneous branches; 6 — Lateral cutaneous nerve of thigh; Lateral femoral cutaneous nerve; 7 — Genitofemoral nerve, femoral branch; 8 — Iliohypogastric nerve; Iliopubic nerve, lateral cutaneous branch; 9 — Intercostal nerves, lateral abdominal cutaneous branch; 10 — Iliohypogastric nerve; Iliopubic nerve; 11 — Ilio-inguinal nerve; 12 — Obturator nerve, cutaneous anterior branch; 13 — Saphenous nerve, infrapatellar branch; 14 — Saphenous nerve, medial cutaneous branches of leg; medial crural cutaneous branches; 15 — Medial dorsal cutaneous nerve; 16 — Deep fibular nerve; Deep peroneal nerve; 17 — Dorsal digital nerve of foot

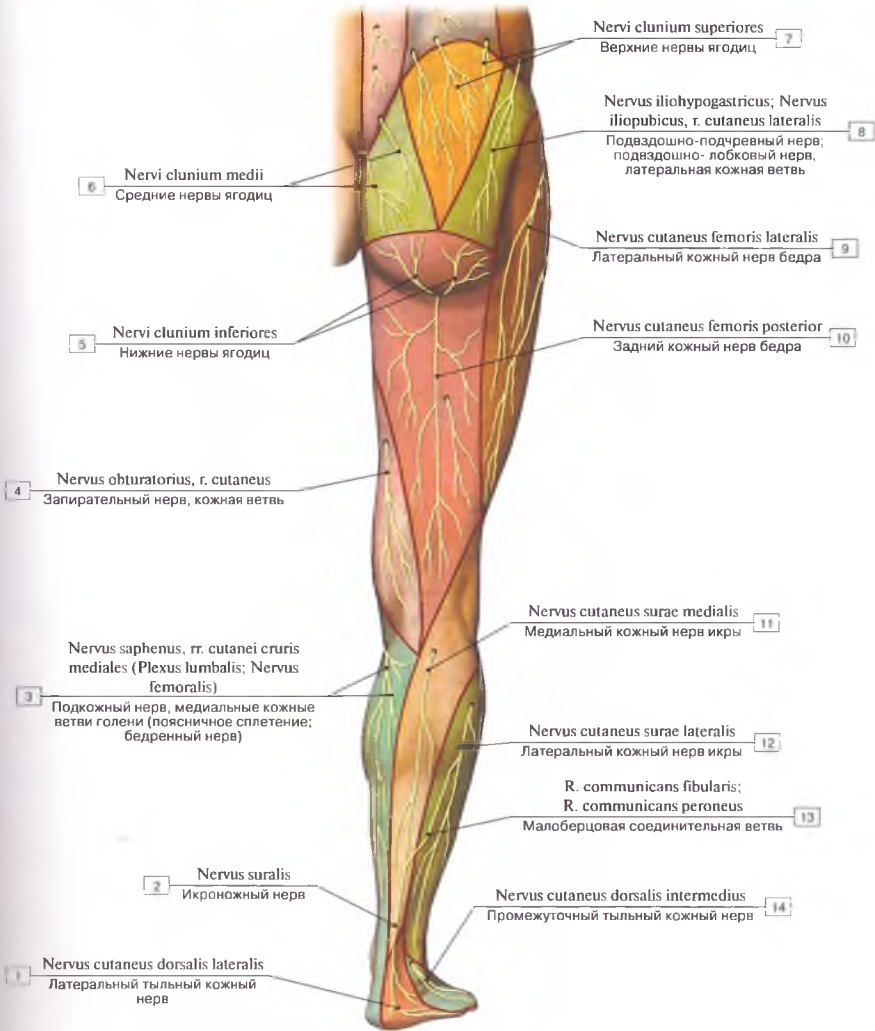


Рис. 357. Задний кожный нерв бедра и другие кожные нервы задней стороны нижней конечности, вид сзади:

1 – Lateral dorsal cutaneous nerve; 2 – Sural nerve; 3 – Saphenous nerve, medial cutaneous branches of leg; medial crural cutaneous branches (lumbar plexus, Femoral nerve); 4 – Obturator nerve, cutaneous branch; 5 – Inferior clunial nerves; 6 – Middle clunial nerves; 7 – Superior clunial nerves; 8 – Iliohypogastric nerve; Iliopubic nerve, lateral cutaneous branch; 9 – Lateral cutaneous nerve of thigh; Lateral femoral cutaneous nerve; 10 – Posterior cutaneous nerve of thigh; Posterior femoral cutaneous nerve; 11 – Medial sural cutaneous nerve; 12 – Lateral sural cutaneous nerve; 13 – Sural communicating branch; 14 – Intermediate dorsal cutaneous nerve

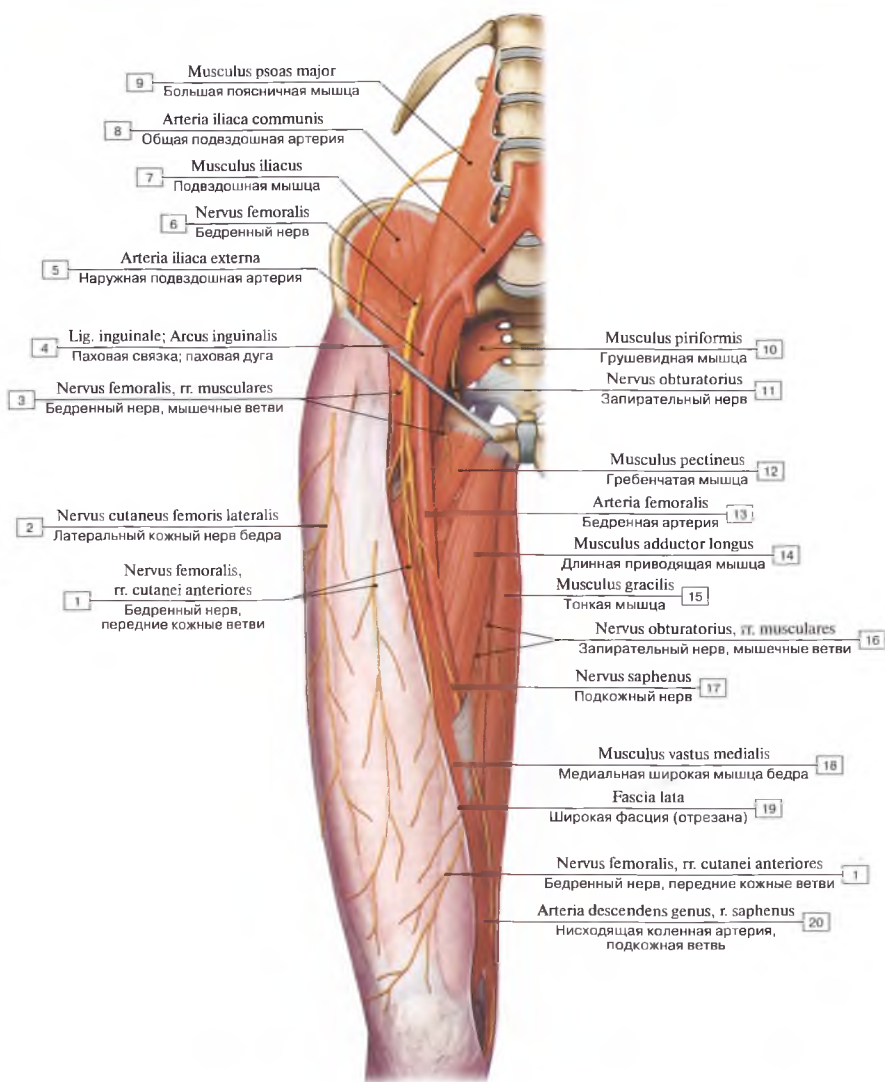


Рис. 358. Кожные нервы бедра, вид спереди:

1 – Femoral nerve, anterior cutaneous branches; 2 – Lateral cutaneous nerve of thigh; Lateral femoral cutaneous nerve; 3 – Femoral nerve, muscular branches; 4 – Inguinal ligament; 5 – External iliac artery; 6 – Femoral nerve; 7 – Iliacus; 8 – Common iliac artery; 9 – Psoas major; 10 – Piriformis; 11 – Obturator nerve; 12 – Pectineus; 13 – Femoral artery; 14 – Adductor longus; 15 – Gracilis; 16 – Obturator nerve, muscular branches; 17 – Saphenous nerve; 18 – Vastus medialis; 19 – Fascia lata; 20 – Descending genicular artery, saphenous branch



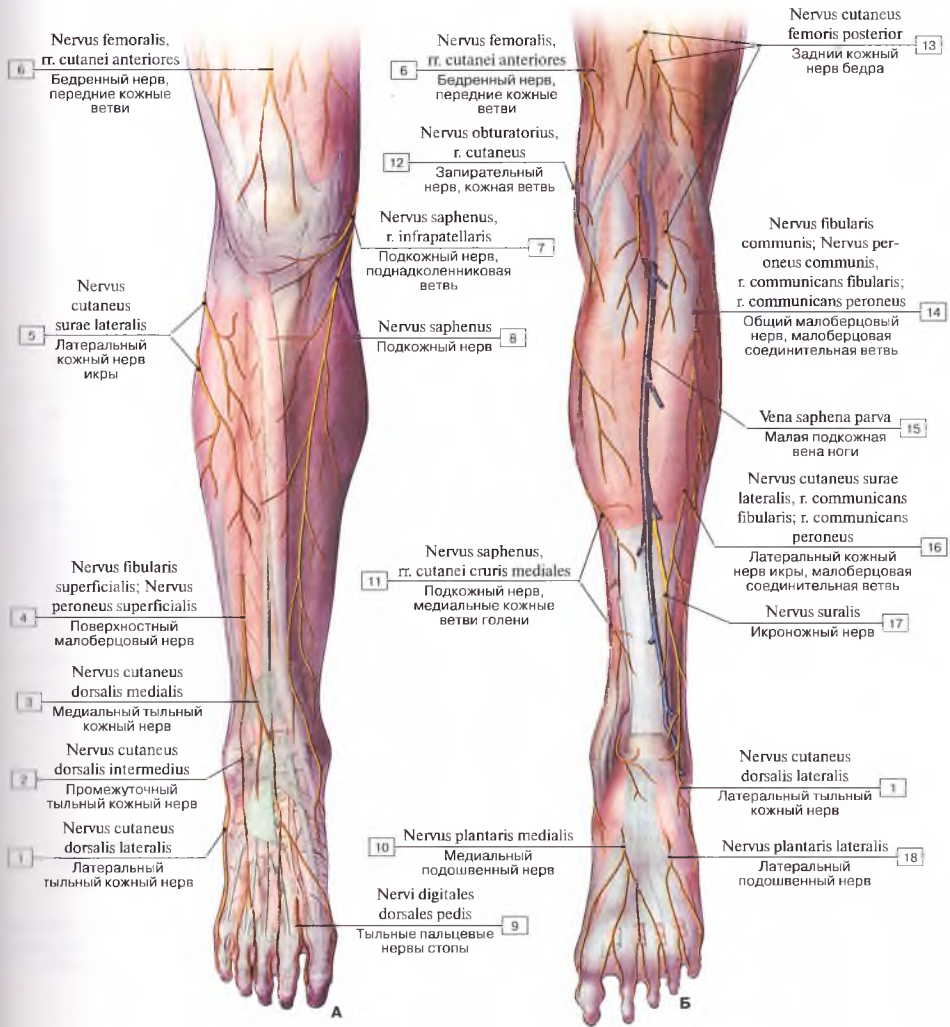


Рис. 359. Кожные нервы голени (А – вид спереди; Б – вид сзади):

1 – Lateral dorsal cutaneous nerve; 2 – Intermediate dorsal cutaneous nerve; 3 – Medial dorsal cutaneous nerve; 4 – Superficial fibular nerve; 5 – Superficial peroneal nerve; 5 – Lateral sural cutaneous nerve; 6 – Femoral nerve, anterior cutaneous branches; 7 – Saphenous nerve, infrapatellar branch; 8 – Saphenous nerve; 9 – Dorsal digital nerves of foot; 10 – Medial plantar nerve; 11 – Saphenous nerve, medial cutaneous branches of leg, medial crural cutaneous branches; 12 – Obturator nerve, cutaneous branch; 13 – Posterior cutaneous nerve of thigh; 14 – Common fibular nerve; 14 – Common fibular nerve; Common peroneal nerve, sural communicating branch; 15 – Small saphenous vein; Short saphenous vein; 16 – Lateral sural cutaneous nerve, sural communicating branch; 17 – Sural nerve; 18 – Lateral plantar nerve

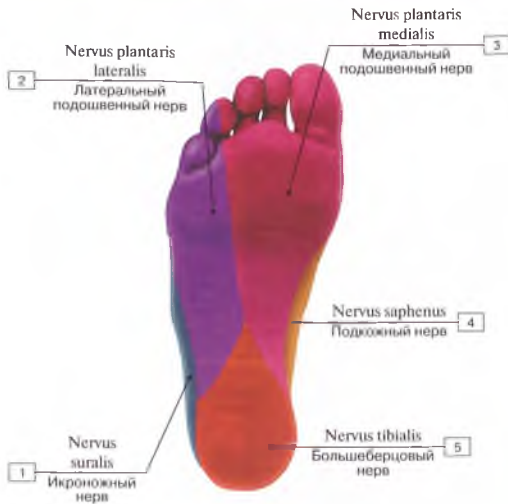

Рис. 360. Области кожной иннервации подошвенной поверхности стопы, правой:

1 – Sural nerve; 2 – Lateral plantar nerve; 3 – Medial plantar nerve; 4 – Saphenous nerve; 5 – Tibial nerve

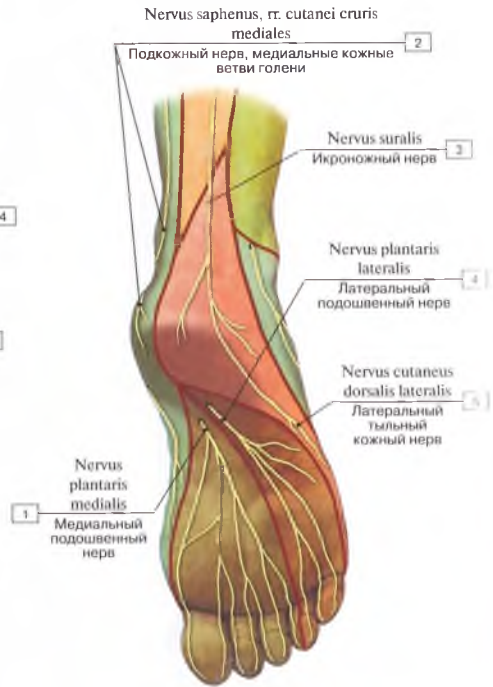


Рис. 361. Области распространения ветвей медиального и латерального подошвенных нервов в коже подошвенной поверхности стопы:

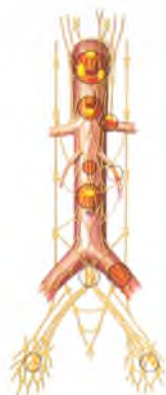
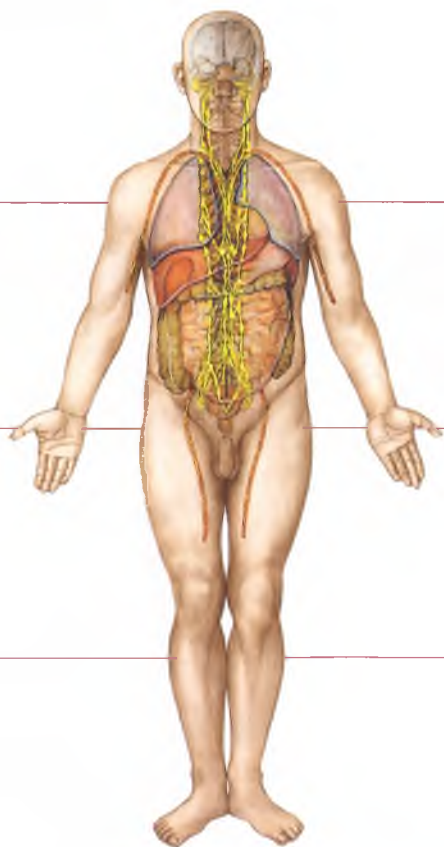
1 – Medial plantar nerve; 2 – Saphenous nerve, medial cutaneous branches of leg; medial crural cutaneous branches; 3 – Sural nerve; 4 – Lateral plantar nerve; 5 – Lateral dorsal cutaneous nerve

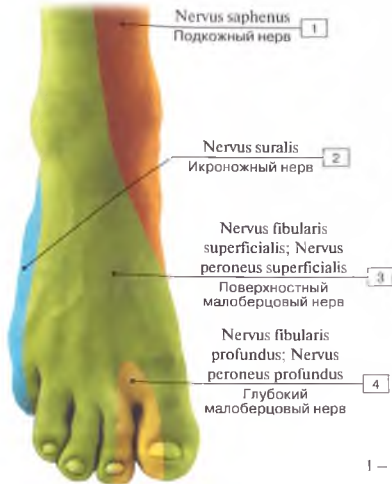
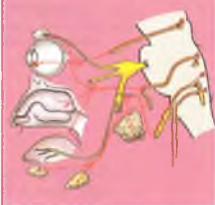
Рис. 362. Кожная иннервация стопы, тыльная поверхность:

1 – Saphenous nerve; 2 – Sural nerve; 3 – Superficial fibular nerve; Superficial peroneal nerve; 4 – Deep fibular nerve; Deep peroneal nerve

# ВЕГЕТАТИВНАЯ НЕРВНАЯ СИСТЕМА



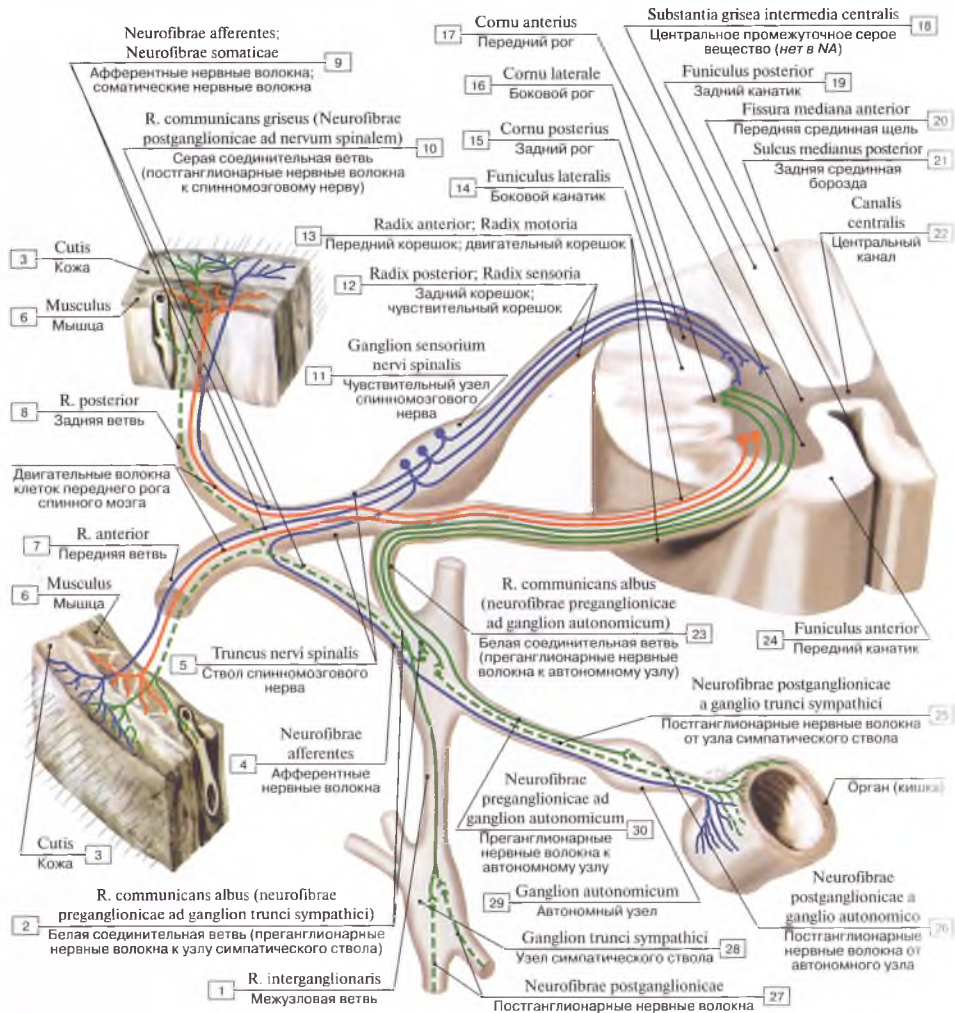


Рис. 363. Вегетативный рефлекс (схема):

1 – Interganglionic branch; 2 – White communicating branch (Preganglionic nerve fibres to ganglion of sympathetic trunk); 3 – Skin; 4 – Afferent nerve fibres; 5 – Trunk of spinal nerve; 6 – Muscle; 7 – Anterior branch; 8 – Posterior branch; 9 – Afferent nerve fibres; Somatic nerve fibres; 10 – Grey communicating branch (Postganglionic nerve fibres to spinal nerve); 11 – Spinal ganglion; Dorsal root ganglion; 12 – Posterior root; Sensory root; Dorsal root; 13 – Anterior root; Motor root; Ventral root; 14 – Lateral funiculus; 15 – Posterior horn; Dorsal horn; 16 – Lateral horn; 17 – Anterior horn; Ventral horn; 18 – Central intermediate grey substance; 19 – Posterior funiculus; Dorsal funiculus; 20 – Anterior median fissure; Ventral median fissure; 21 – Posterior median sulcus; Dorsal median sulcus; 22 – Central canal; 23 – White communicating branch (Preganglionic nerve fibres to autonomic ganglion); 24 – Anterior funiculus; Ventral funiculus; 25 – Postganglionic nerve fibres from ganglion of sympathetic trunk; 26 – Postganglionic nerve fibres from autonomic ganglion; 27 – Postganglionic nerve fibres; 28 – Ganglion of sympathetic trunk; 29 – Autonomic ganglion; 30 – Preganglionic nerve fibres to autonomic ganglion

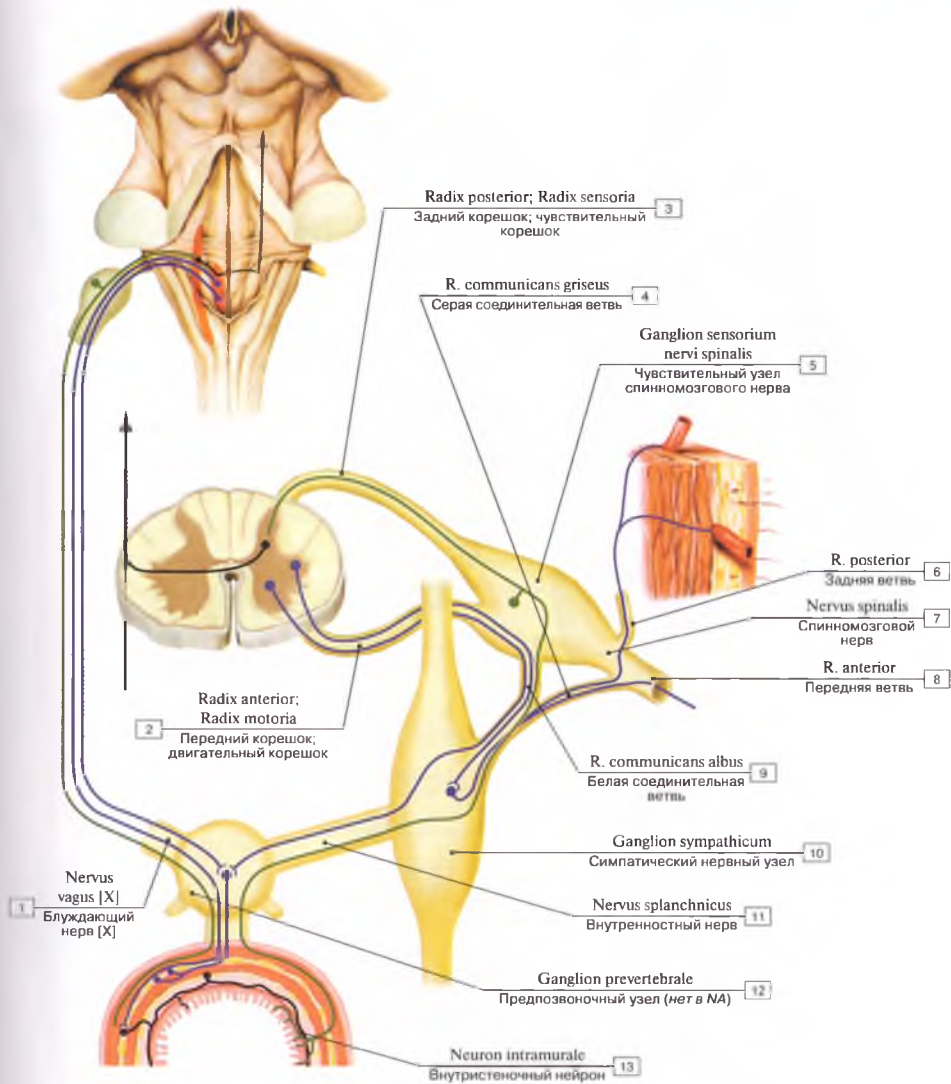


Рис. 364. Вегетативные рефлекторные дуги ВНС (схема):

1 – Vagus nerve [X]; 2 – Anterior root; Motor root; Ventral root; 3 – Posterior root; Sensory root; Dorsal root; 4 – Grey communicating branch; 5 – Spinal ganglion; Dorsal root ganglion; 6 – Posterior branch; 7 – Spinal nerve; 8 – Anterior branch; 9 – White communicating branch; 10 – Sympathetic ganglion; 11 – Splanchnic nerve; 12 – Prevertebral ganglion; 13 – Intramural neuron

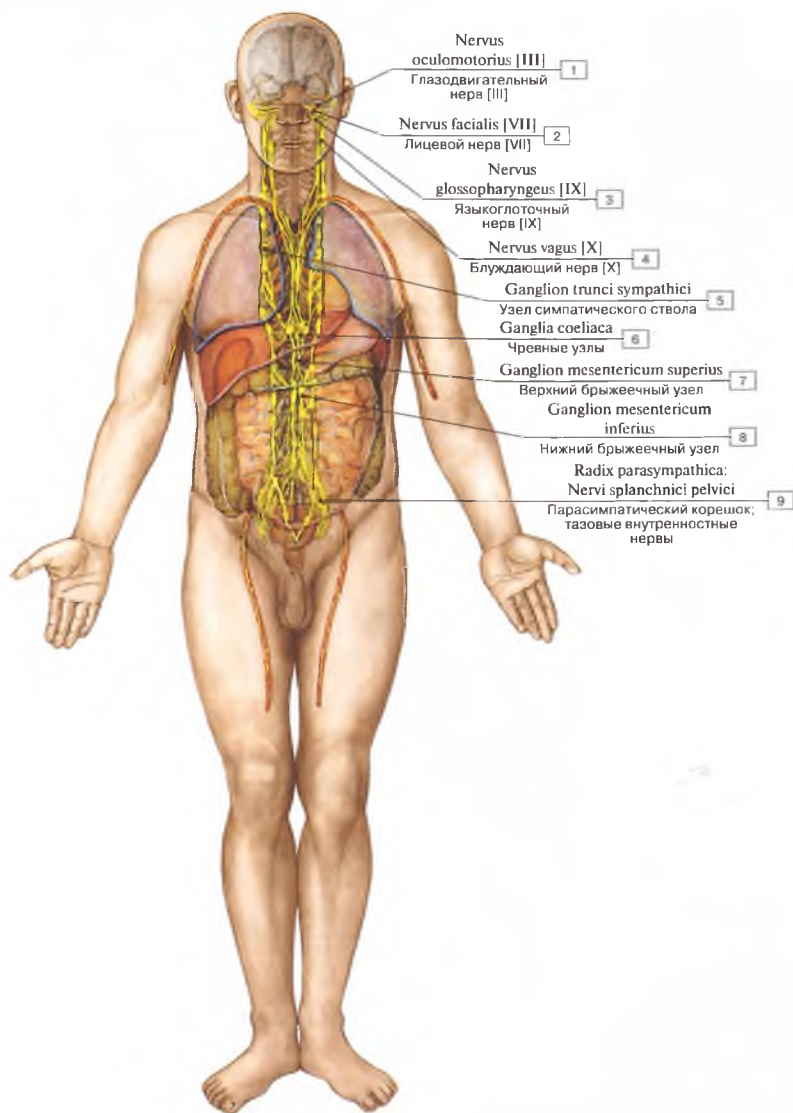


Рис. 365. Структура вегетативной нервной системы:

1 – Oculomotor nerve [III]; 2 – Facial nerve [VII]; 3 – Glossopharyngeal nerve [IX]; 4 – Vagus nerve [X]; 5 – Ganglion of sympathetic trunk; 6 – Coeliac ganglion; 7 – Superior mesenteric ganglion; 8 – Inferior mesenteric ganglion; 9 – Parasympathetic root; Pelvic splanchnic nerves

Симпатическая нервная система

Парасимпатическая нервная система

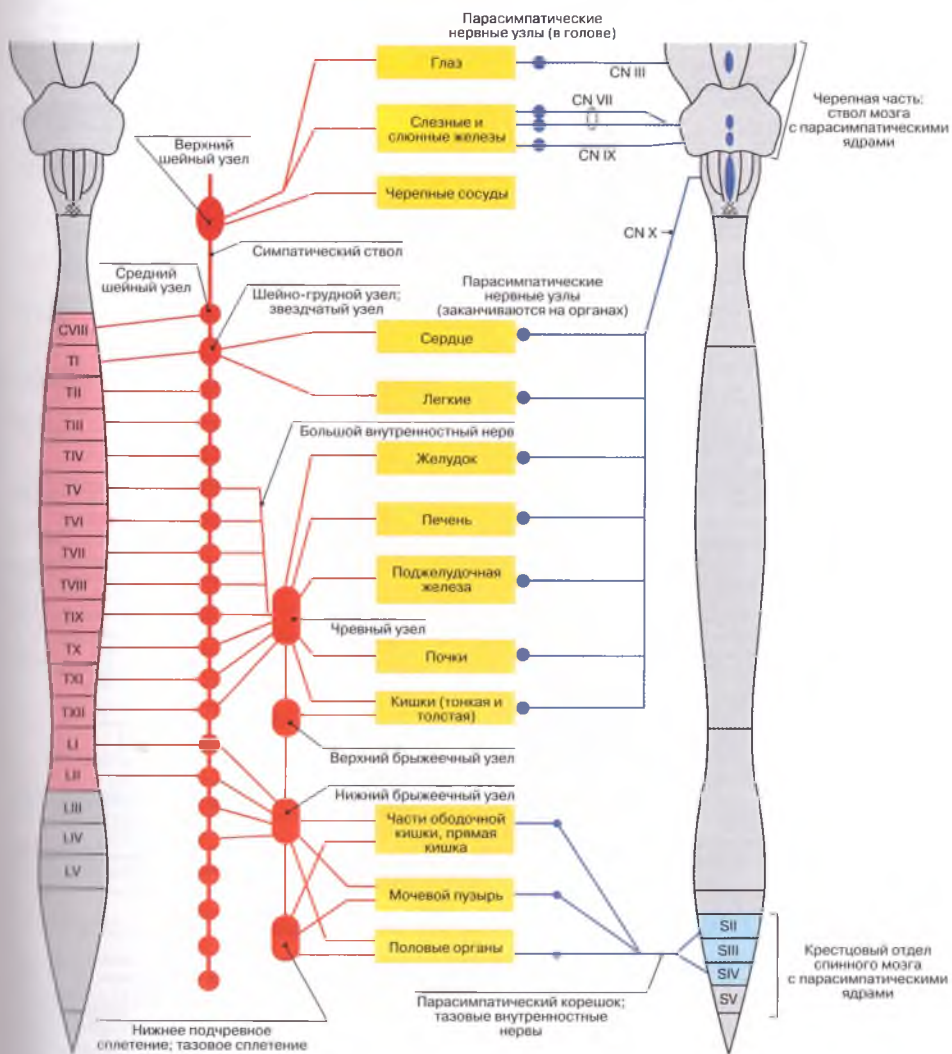


Рис. 366. Вегетативная нервная система (схема)

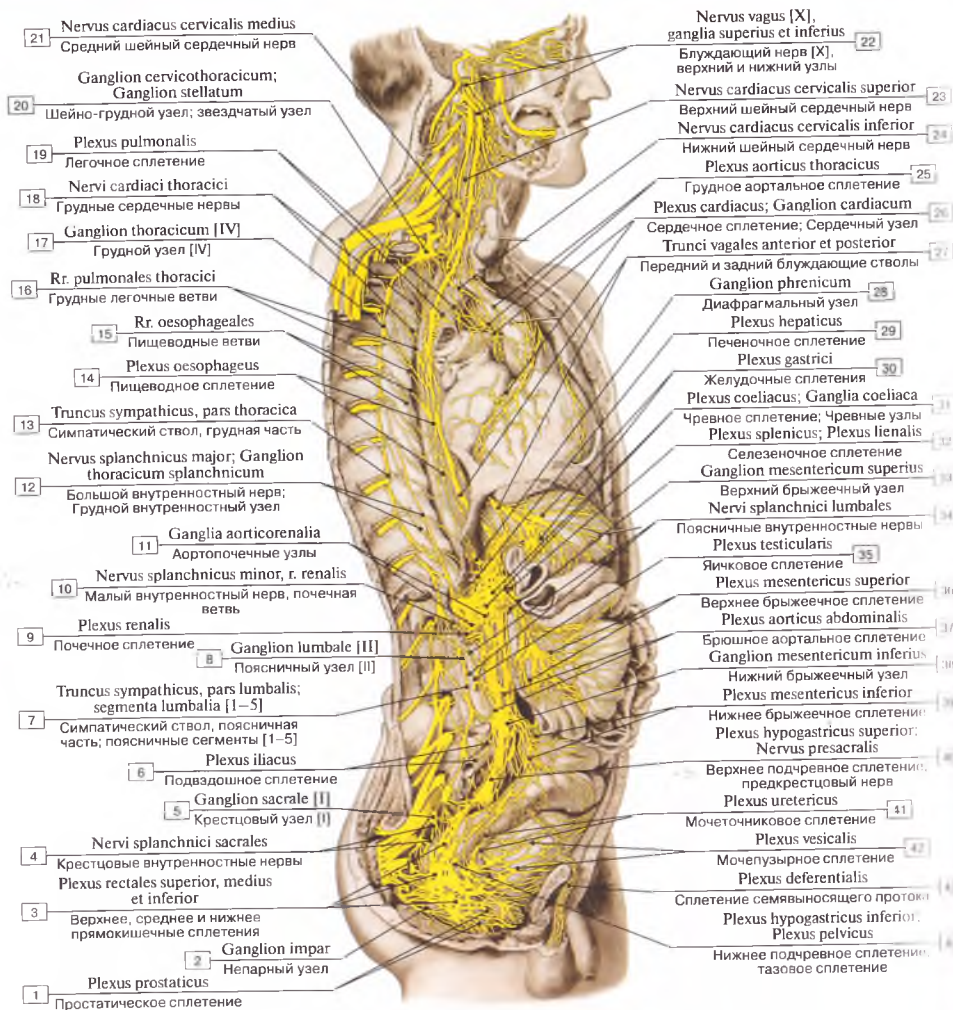


Рис. 367. Автономная часть периферической нервной системы:

1 – Prostatic plexus; 2 – Ganglion impar; 3 – Superior, middle and inferior rectal plexuses; 4 – Sacral splanchnic nerves; 5 – Sacral ganglion [I]; 6 – Iliac plexus; 7 – Sympathetic trunk, lumbar part; 8 – Lumbar ganglion [II]; 9 – Renal plexus; 10 – Lesser splanchnic nerve, renal branch; 11 – Aorticorenal ganglion; 12 – Greater splanchnic nerve; 13 – Sympathetic trunk, thoracic part; 14 – Oesophageal ganglion; 15 – Oesophageal branches; 16 – Thoracic splanchnic nerves; 17 – Thoracic ganglion [IV]; 18 – Thoracic cardiac nerves; 19 – Pulmonary plexus; 20 – Cervicothoracic ganglion; 21 – Middle cervical cardiac nerve; 22 – Vagus nerve [X], superior and inferior ganglia; 23 – Superior cervical cardiac nerve; 24 – Inferior cervical cardiac nerve; 25 – Thoracic aortic plexus; 26 – Cardiac plexus; 27 – Anterior and posterior vagal trunks; 28 – Phrenic ganglion; 29 – Hepatic plexus; 30 – Gastric plexuses; 31 – Coeliac plexus; 32 – Splenic plexus; 33 – Superior mesenteric ganglion; 34 – Lumbar splanchnic nerves; 35 – Testicular plexus; 36 – Superior mesenteric plexus; 37 – Abdominal aortic plexus; 38 – Inferior mesenteric ganglion; 39 – Inferior mesenteric plexus; 40 – Superior hypogastric plexus; 41 – Ureteric nerve; 42 – Vesical plexus; 43 – Deferential plexus; 44 – Inferior hypogastric plexus; Pelvic plexus

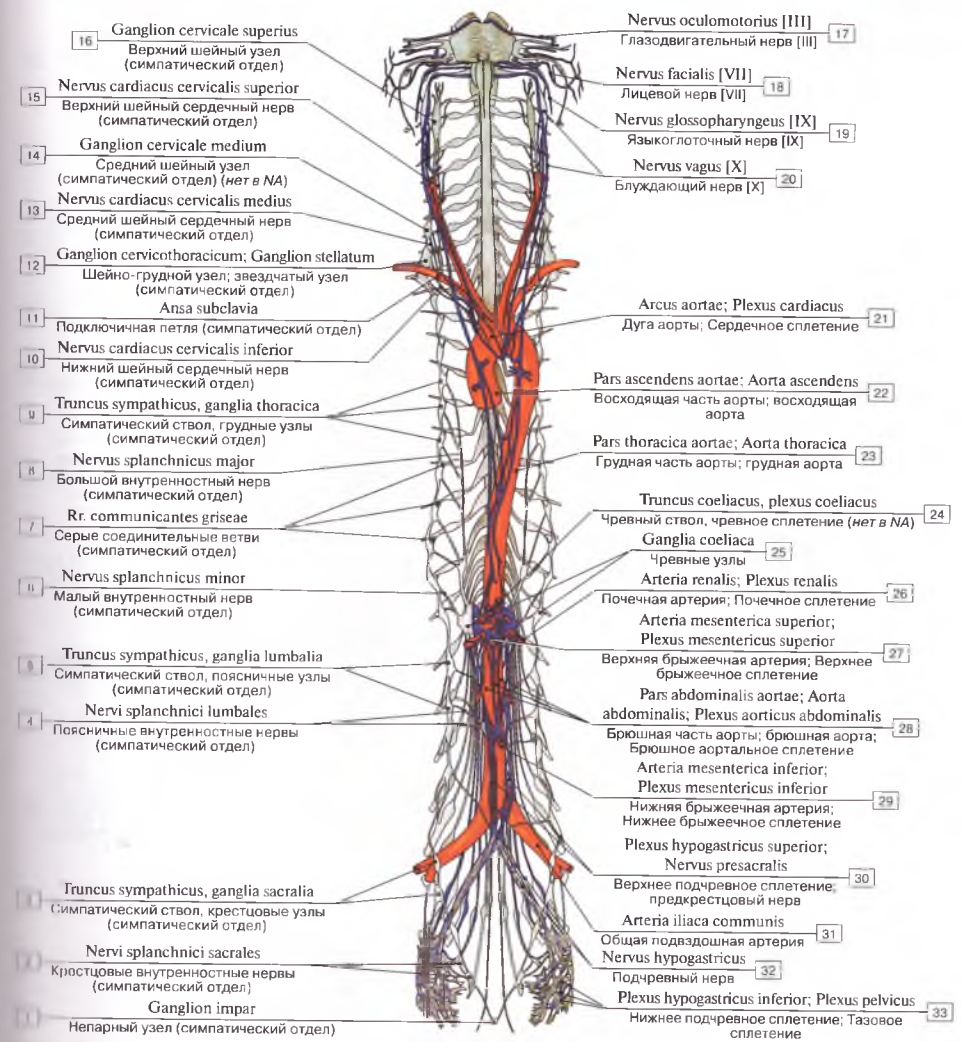


Рис. 368. Парасимпатическая часть вегетативной нервной системы (схема):

1 – Ganglion impar; 2 – Sacral splanchnic nerves; 3 – Sympathetic trunk, sacral ganglia; 4 – Lumbar splanchnic nerves; 5 – Sympathetic trunk, lumbar ganglia; 6 – Lesser splanchnic nerve; 7 – Grey communicating branches; 8 – Greater splanchnic nerve; 9 – Sympathetic trunk, thoracic ganglia; 10 – Inferior cervical cardiac nerve; 11 – Ansa subclavia; 12 – Cervicothoracic ganglion; 13 – Middle cervical cardiac nerve; 14 – Middle cervical ganglion; 15 – Superior cervical cardiac nerve; 16 – Superior cervical ganglion; 17 – Oculomotor nerve [III]; 18 – Facial nerve [VII]; 19 – Glossopharyngeal nerve [IX]; 20 – Vagus nerve [X]; 21 – Arch of aorta; 22 – Ascending aorta; 23 – Thoracic aorta; 24 – Coeliac trunk, plexus coeliac; 25 – Coeliac ganglia; 26 – Renal artery; 27 – Superior mesenteric artery; 28 – Abdominal aorta; 29 – Inferior mesenteric artery; 30 – Superior hypogastric plexus; 31 – Common iliac artery; 32 – Hypogastric nerve; 33 – Inferior hypogastric plexus; Pelvic plexus



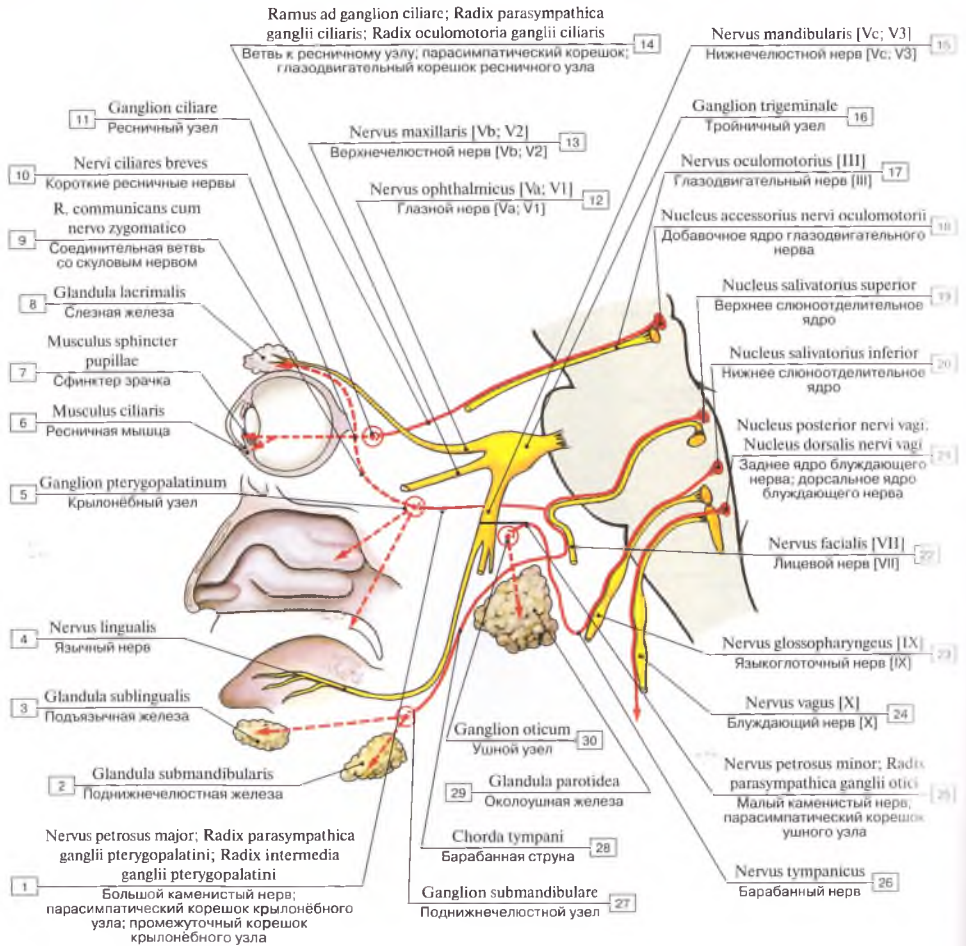


Рис. 369. Парасимпатические центры ствола мозга и иннервируемые ими отделы (схема):

1 — Greater petrosal nerve; Parasympathetic root of pterygopalatine ganglion; 2 — Submandibular gland; 3 — Sublingual gland; 4 — Lingual nerve; 5 — Pterygopalatine ganglion; 6 — Ciliary muscle; 7 — Sphincter pupillae; 8 — Lacrimal gland; 9 — Communicating branch with zygomatic nerve; 10 — Short ciliary nerves; 11 — Ciliary ganglion; 12 — Ophthalmic nerve; Ophthalmic division [Va; V1]; 13 — Maxillary nerve; Maxillary division [Vb; V2]; 14 — Branch to ciliary ganglion; Parasympathetic root of ciliary ganglion; Oculomotor root of ciliary ganglion; 15 — Mandibular nerve; Mandibular division [Vc; V3]; 16 — Trigeminal ganglion; 17 — Oculomotor nerve [III]; 18 — Accessory nucleus of oculomotor nerve; 19 — Superior salivatory nucleus; 20 — Inferior salivatory nucleus; 21 — Posterior nucleus of vagus nerve; Dorsal nucleus of vagus nerve; 22 — Facial nerve [VII]; 23 — Glossopharyngeal nerve [IX]; 24 — Vagus nerve [X]; 25 — Lesser petrosal nerve; Parasympathetic root of otic ganglion; 26 — Tympanic nerve; 27 — Submandibular ganglion; 28 — Chorda tympani; 29 — Parotid gland; 30 — Otic ganglion

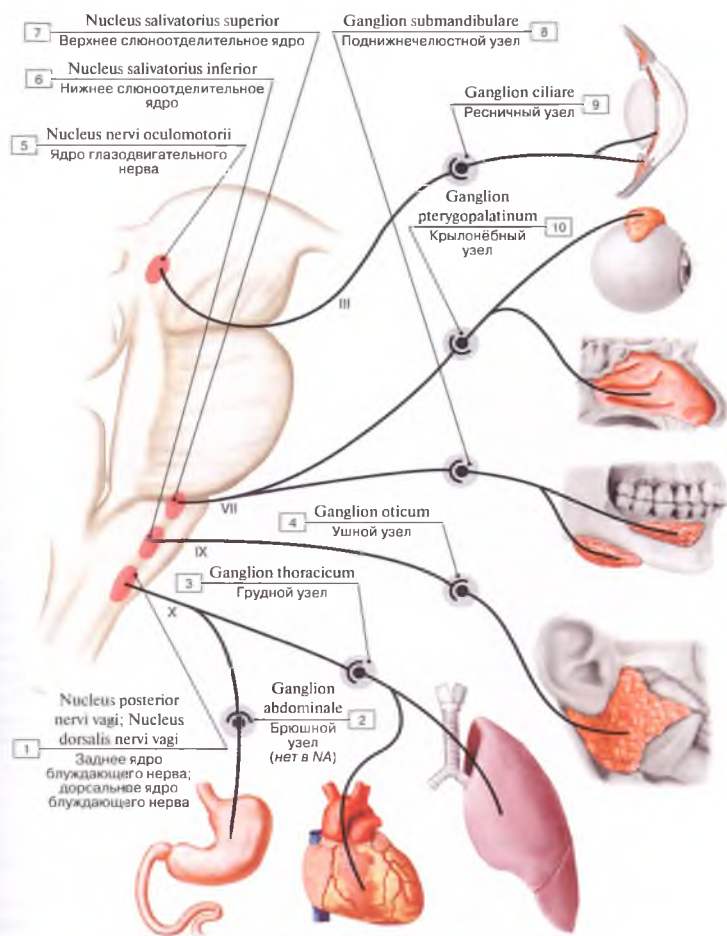


Рис. 370. Парасимпатические центры ствола мозга и иннервируемые ими органы:

1 – Posterior nucleus of vagus nerve; Dorsal nucleus of vagus nerve; 2 – Abdominal ganglion; 3 – Thoracic ganglion; 4 – Otic ganglion; 5 – Nucleus of oculomotor nerve; 6 – Inferior salivatory nucleus; 7 – Superior salivatory nucleus; 8 – Submandibular ganglion; 9 – Ciliary ganglion; 10 – Pterygopalatine ganglion

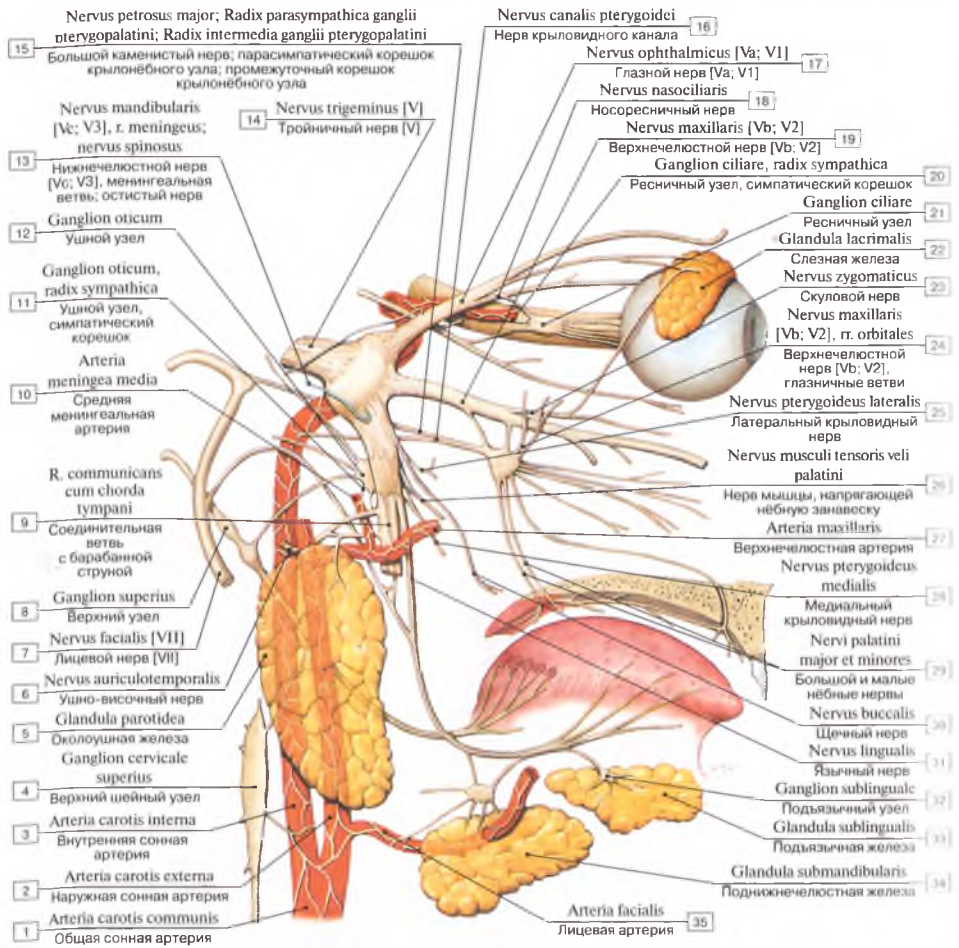
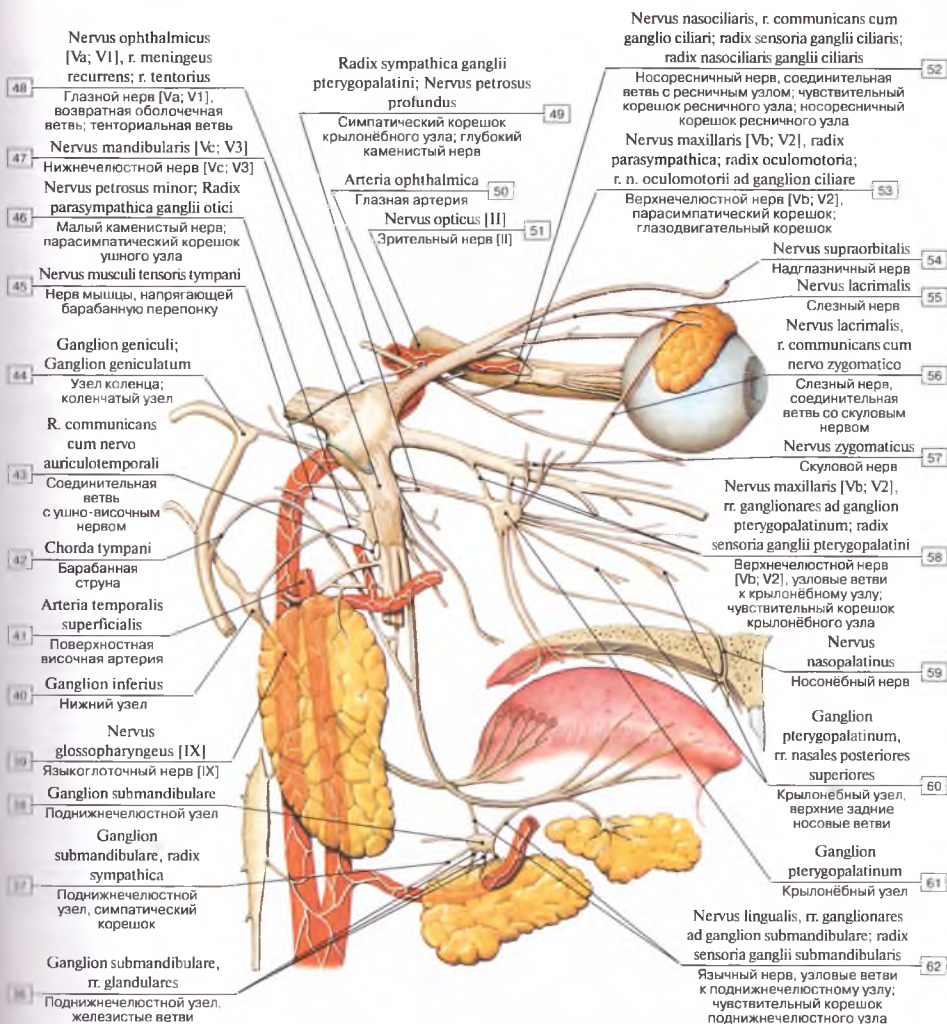


Рис. 371. Расположение парасимпатических узлов и отходящих от них нервов в области головного отдела вегетативной нервной системы (схема):

1 — Common carotid artery; 2 — External carotid artery; 3 — Internal carotid artery; 4 — Superior cervical ganglion; 5 — Parotid gland; 6 — Auriculotemporal nerve; 7 — Facial nerve [VII]; 8 — Superior ganglion; 9 — Communicating branch with chorda tympani; 10 — Middle meningeal artery; 11 — Otic ganglion, sympathetic root; 12 — Otic ganglion; 13 — Mandibular nerve; Mandibular division [Vc; V3], meningeal branch; 14 — Trigeminal nerve [V]; 15 — Greater petrosal nerve; Parasympathetic root of pterygopalatine ganglion; 16 — Nerve of pterygoid canal; 17 — Ophthalmic nerve; Ophthalmic division [Va; V1]; 18 — Nasociliary nerve; 19 — Maxillary nerve; Maxillary division [Vb; V2]; 20 — Ciliary ganglion, sympathetic root; 21 — Ciliary ganglion; 22 — Lacrimal gland; 23 — Zygomatic nerve; 24 — Maxillary nerve; Maxillary division [Vb; V2], orbital branches; 25 — Nerve to lateral pterygoid; 26 — Nerve to tensor veli palatini; 27 — Maxillary artery; 28 — Nerve to medial pterygoid; 29 — Greater and lesser palatine nerves; 30 — Buccal nerve; 31 — Lingual nerve; 32 — Sublingual ganglion; 33 — Sublingual gland; 34 — Submandibular gland; 35 — Facial artery; 36 — Submandibular ganglion, glandular branches; 37 — Submandibular ganglion, Sympathetic root; 38 — Submandibular ganglion; 39 — Glossopharyngeal nerve [IX]; 40 — Inferior ganglion; 41 — Superficial temporal artery.



- 42 – Chorda tympani; 43 – Communicating branch with auriculotemporal nerve; 44 – Geniculate ganglion; 45 – Nerve to tensor tympani; 46 – Lesser petrosal nerve; Parasympathetic root of otic ganglion; 47 – Mandibular nerve; Mandibular division [Vc; V3]; 48 – Ophthalmic nerve; Ophthalmic division [Va; V1], tentorial branch; 49 – Sympathetic root; Deep petrosal nerve; 50 – Ophthalmic artery; 51 – Optic nerve [II]; 52 – Nasociliary nerve, communicating branch with ciliary ganglion; sensory root of ciliary ganglion; nasociliary root of ciliary ganglion; 53 – Maxillary nerve; Maxillary division [Vb; V2], parasympathetic root; branch of oculomotor nerve to ciliary ganglion; 54 – Supra-orbital nerve; 55 – Lacrimal nerve; 56 – Lacrimal nerve, communicating branch with zygomatic nerve; 57 – Zygomatic nerve; 58 – Maxillary nerve; Maxillary division [Vb; V2], ganglionic branches to pterygopalatine ganglion; sensory root of pterygopalatine ganglion; 59 – Nasopalatine nerve; 60 – Pterygopalatine ganglion, posterior superior nasal branches; 61 – Pterygopalatine ganglion; 62 – Lingual nerve, ganglionic branches to submandibular ganglion; sensory root of submandibular ganglion

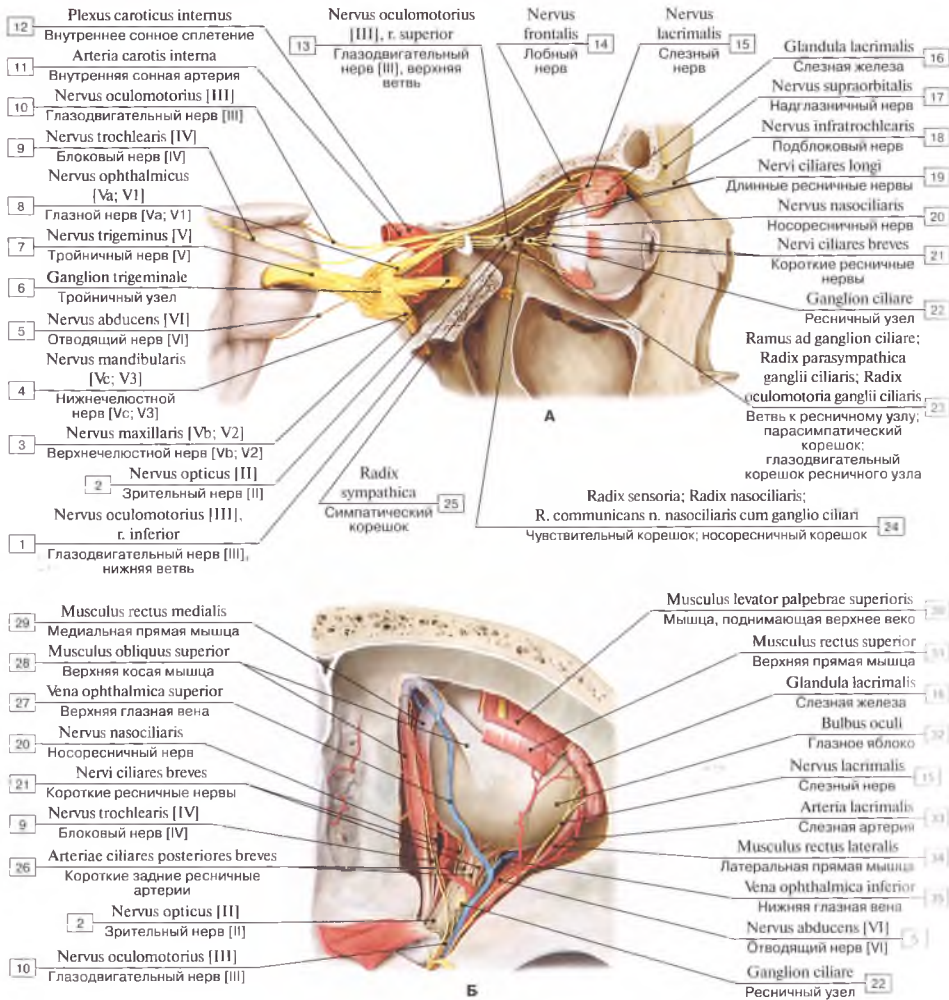


Рис. 372. Ресничный узел:

1 – Oculomotor nerve [III], inferior branch; 2 – Optic nerve [II]; 3 – Maxillary nerve: Maxillary division [Vb; V2]; 4 – Mandibular nerve: Mandibular division [Vc; V3]; 5 – Abducent nerve: Abducent nerve [VI]; 6 – Trigeminal ganglion; 7 – Trigeminal nerve [VI]; 8 – Ophthalmic nerve; Ophthalmic division [Va; V1]; 9 – Trochlear nerve [IV]; 10 – Oculomotor nerve [III]; 11 – Internal carotid artery; 12 – Internal carotid plexus; 13 – Oculomotor nerve [III], superior branch; 14 – Frontal nerve; 15 – Lacrimal nerve; 16 – Lacrimal gland; 17 – Supra-orbital nerve; 18 – Infratrochlear nerve; 19 – Long ciliary nerves; 20 – Nasociliary nerve; 21 – Short ciliary nerves; 22 – Ciliary ganglion; 23 – Branch to ciliary ganglion; Parasympathetic root of ciliary ganglion; Oculomotor root of ciliary ganglion; 24 – Sensory root; Nasociliary root; Communicating branch of nasociliary nerve with ciliary ganglion; 25 – Sympathetic root; 26 – Short posterior ciliary arteries; 27 – Superior ophthalmic vein; 28 – Superior oblique; 29 – Medial rectus; 30 – Levator palpebrae superioris; 31 – Superior rectus; 32 – Eyeball; 33 – Lacrimal artery; 34 – Lateral rectus; 35 – Inferior ophthalmic vein

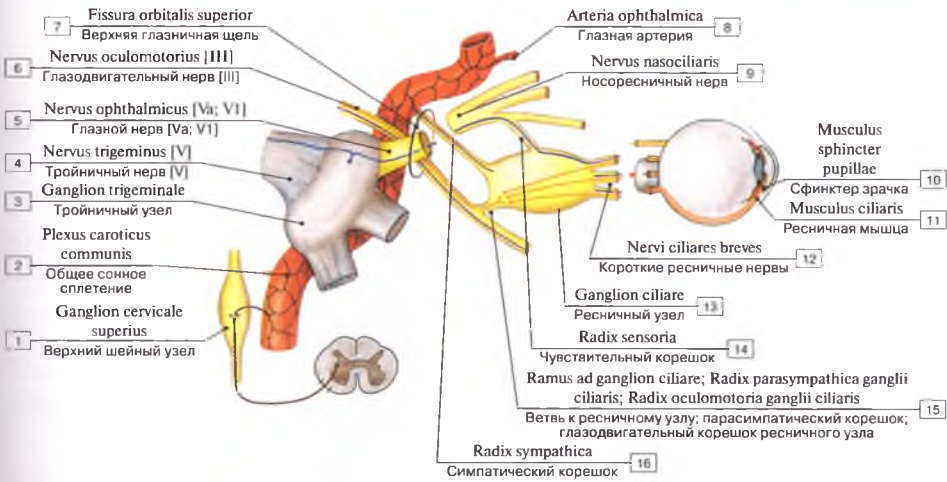


Рис. 373. Ресничный узел (схема):

1 – Superior cervical ganglion; 2 – Common carotid plexus; 3 – Trigeminal ganglion; 4 – Trigeminal nerve [V]; 5 – Ophthalmic nerve; Ophthalmic division [Va; VI]; 6 – Oculomotor nerve [III]; 7 – Superior orbital fissure; 8 – Ophthalmic artery; 9 – Nasociliary nerve; 10 – Sphincter pupillae; 11 – Ciliary muscle; 12 – Short ciliary nerves; 13 – Ciliary ganglion; 14 – Sensory root; 15 – Branch to ciliary ganglion; Parasympathetic root of ciliary ganglion; Oculomotor root of ciliary ganglion; 16 – Sympathetic root

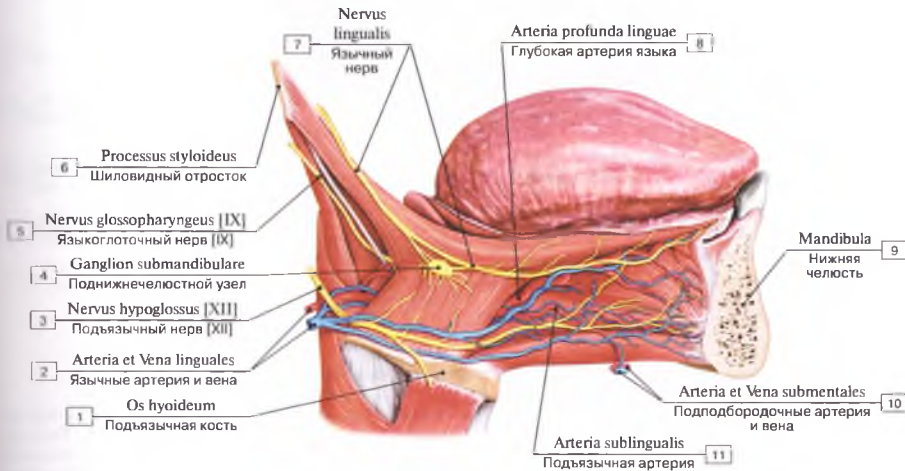


Рис. 374. Поднижнечелюстной узел:

1 – Hyoid bone; 2 – Lingual artery and vein; 3 – Hypoglossal nerve [XII]; 4 – Submandibular ganglion; 5 – Glossopharyngeal nerve [IX]; 6 – Styloid process; 7 – Lingual nerve; 8 – Deep lingual artery; 9 – Mandible; 10 – Submental artery and vein; 11 – Sublingual artery

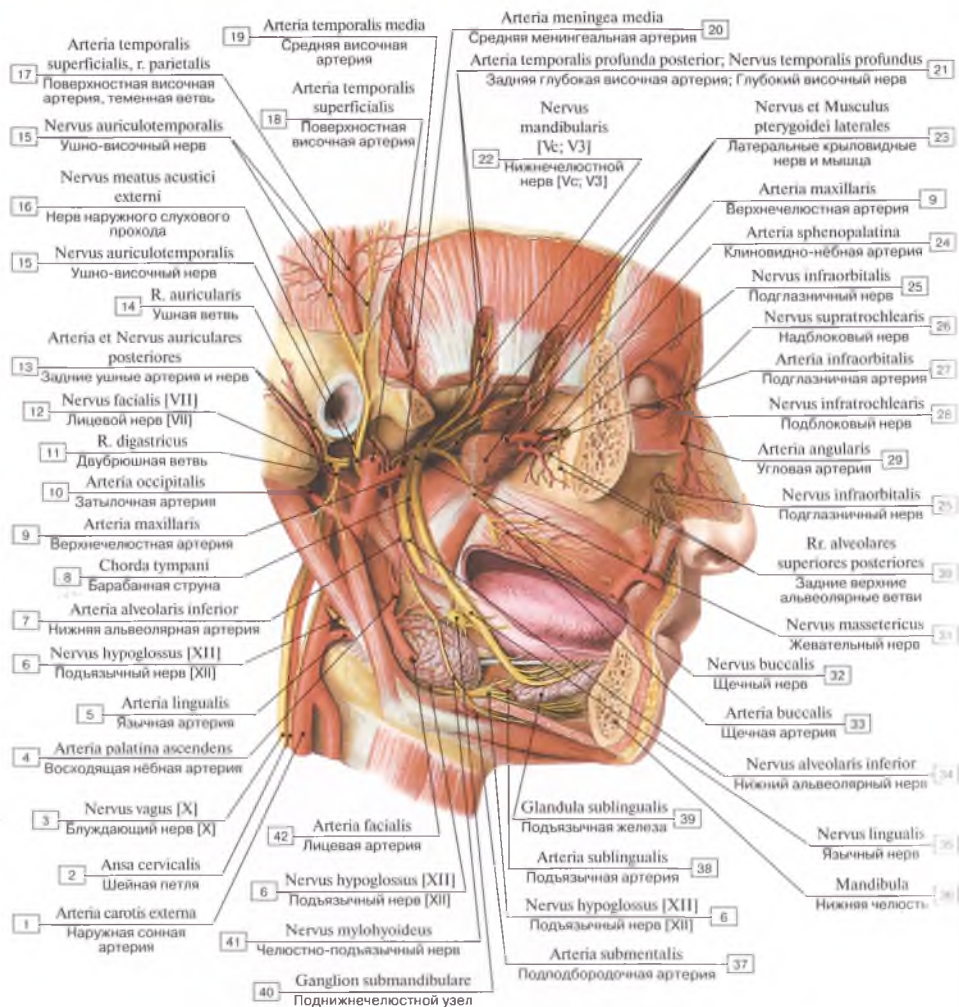


Рис. 375. Сосуды и нервы головы, поднижнечелюстной узел:

1 – External carotid artery; 2 – Ansa cervicalis; 3 – Vagus nerve [X]; 4 – Ascending palatine artery; 5 – Lingual artery; 6 – Hypoglossal nerve [XII]; 7 – Inferior alveolar artery; 8 – Chorda tympani; 9 – Maxillary artery; 10 – Occipital artery; 11 – Digastric branch; 12 – Facial nerve [VII]; 13 – Posterior auricular artery and nerve; 14 – Auricular branch; 15 – Auriculotemporal nerve; 16 – Nerve to external acoustic meatus; 17 – Superficial temporal artery, parietal branch; 18 – Superficial temporal artery; 19 – Middle temporal artery; 20 – Middle meningeal artery; 21 – Posterior deep temporal artery; Deep temporal nerve; 22 – Mandibular nerve; Mandibular division [Vc; V3]; 23 – Nerve to lateral pterygoid; Lateral pterygoid; 24 – Sphenopalatine artery; 25 – Infra-orbital nerve; 26 – Supratrochlear nerve; 27 – Infra-orbital artery; 28 – Infratrochlear nerve; 29 – Angular artery; 30 – Posterior superior alveolar branches; 31 – Masseteric nerve; 32 – Buccal nerve; 33 – Buccal artery; 34 – Inferior alveolar nerve; 35 – Lingual nerve; 36 – Mandible; 37 – Submental artery; 38 – Sublingual artery; 39 – Sublingual gland; 40 – Submandibular ganglion; 41 – Nerve to mylohyoid; 42 – Facial artery

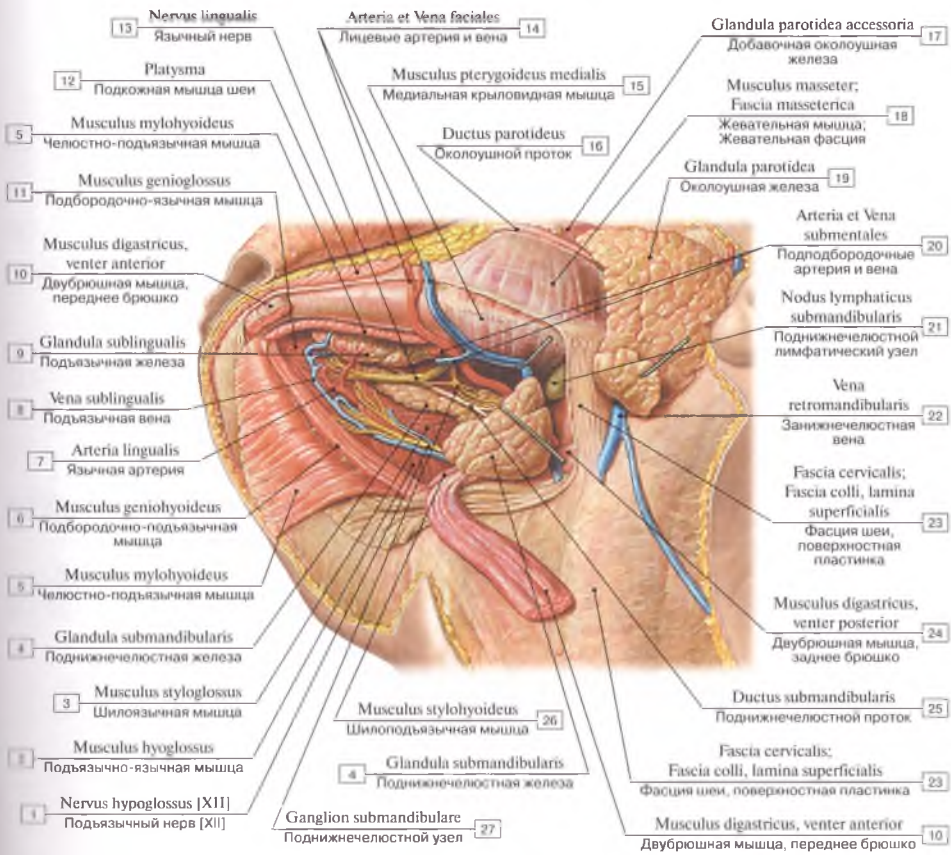


Рис. 376. Сосуды и нервы диафрагмы рта, поднижнечелюстной узел:

1 — Hypoglossal nerve [XII]; 2 — Hyoglossus; 3 — Styloglossus; 4 — Submandibular gland; 5 — Mylohyoid; 6 — Geniohyoid; 7 — Lingual artery; 8 — Sublingual vein; 9 — Sublingual gland; 10 — Digastric, anterior belly; 11 — Genioglossus; 12 — Platysma; 13 — Lingual nerve; 14 — Facial artery and vein; 15 — Medial pterygoid; 16 — Parotid duct; 17 — Accessory parotid gland; 18 — Masseter; Masseteric fascia; 19 — Parotid gland; 20 — Submental artery and vein; 21 — Submandibular lymph node; 22 — Retromandibular vein; 23 — Cervical fascia, investing layer; superficial layer; 24 — Digastric, posterior belly; 25 — Submandibular duct; 26 — Stylohyoid; 27 — Submandibular ganglion



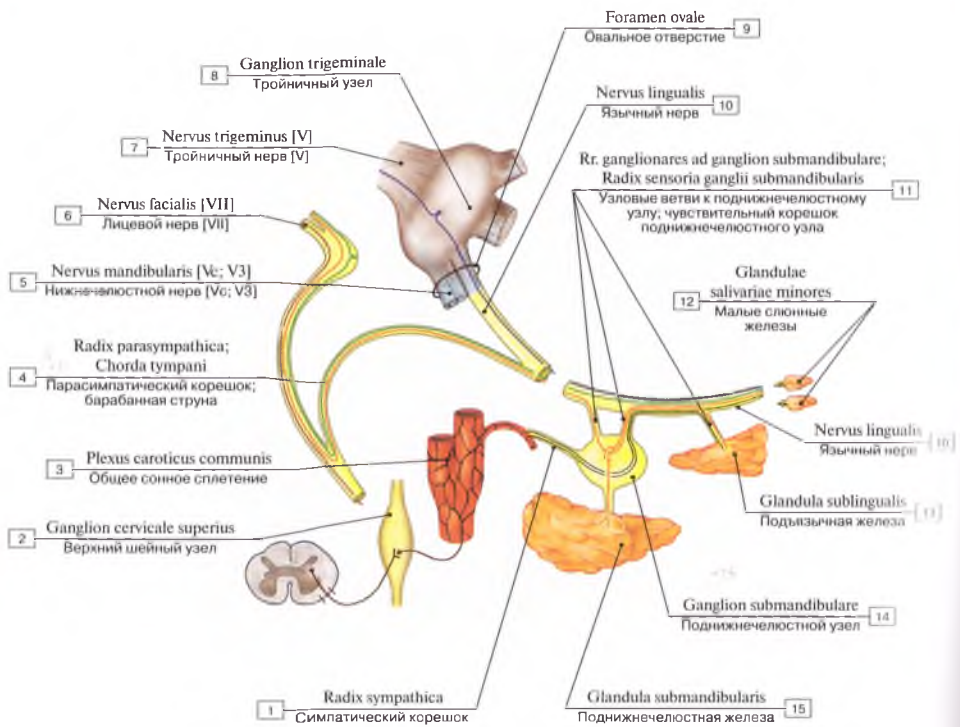


Рис. 377. Поднижечелюстной узел и его ветви (схема):

1 — Sympathetic root; 2 — Superior cervical ganglion; 3 — Common carotid plexus; 4 — Parasympathetic root; Chorda tympani; 5 — Mandibular nerve; Mandibular division [Vc; V3]; 6 — Facial nerve [VII]; 7 — Trigeminal nerve [V]; 8 — Trigeminal ganglion; 9 — Foramen ovale; 10 — Lingual nerve; 11 — Ganglionic branches to submandibular ganglion; Sensory root of submandibular ganglion; 12 — Minor salivary glands; 13 — Sublingual gland; 14 — Submandibular ganglion; 15 — Submandibular gland

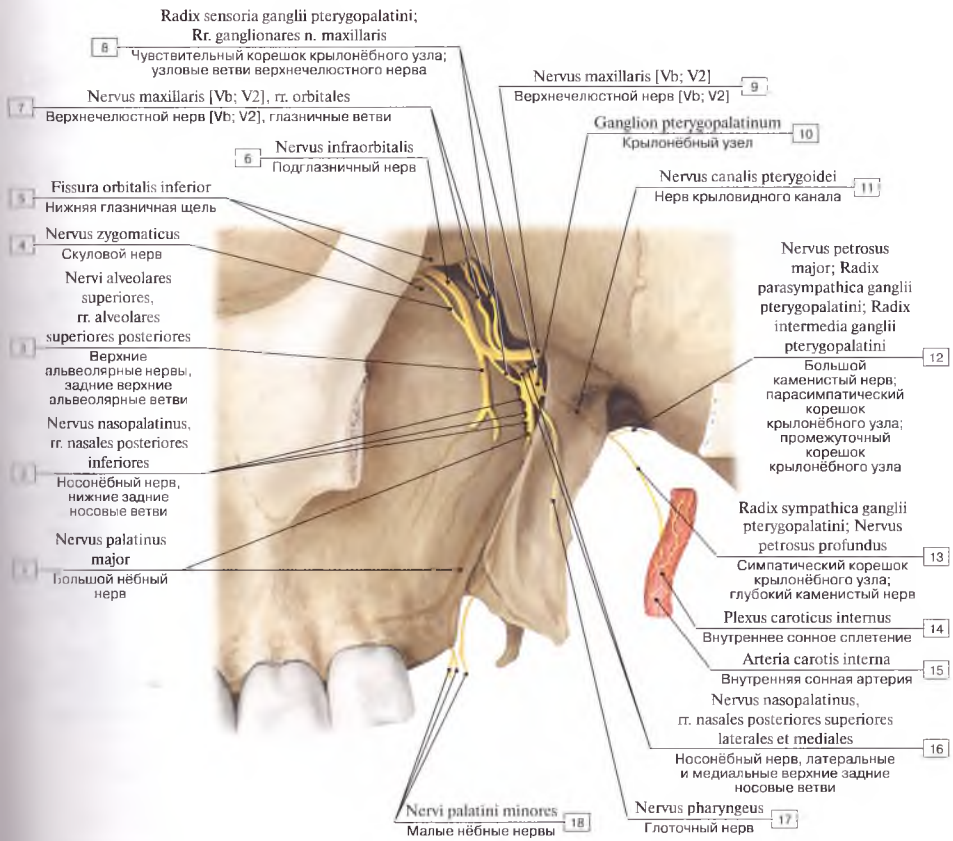


Рис. 378. Крылонёбный узел:

1 – Greater palatine nerve; 2 – Nasopalatine nerve, posterior inferior nasal nerves; 3 – Superior alveolar nerves, posterior superior alveolar nerves; 4 – Zygomatic nerve; 5 – Inferior orbital fissure; 6 – Infra-orbital nerve; 7 – Maxillary nerve; Maxillary division [Vb; V2], orbital branches; 8 – Sensory root; Ganglionic branches of maxillary nerve; 9 – Maxillary nerve; Maxillary division [Vb; V2]; 10 – Pterygopalatine ganglion; 11 – Nerve of pterygoid canal; 12 – Greater petrosal nerve; Parasympathetic root of pterygopalatine ganglion; 13 – Sympathetic root of pterygopalatine ganglion; Deep petrosal nerve; 14 – Internal carotid plexus; 15 – Internal carotid artery; 16 – Nasopalatine nerve, posterior superior lateral and medial nasal branches; 17 – Pharyngeal nerve; 18 – Lesser palatine nerves

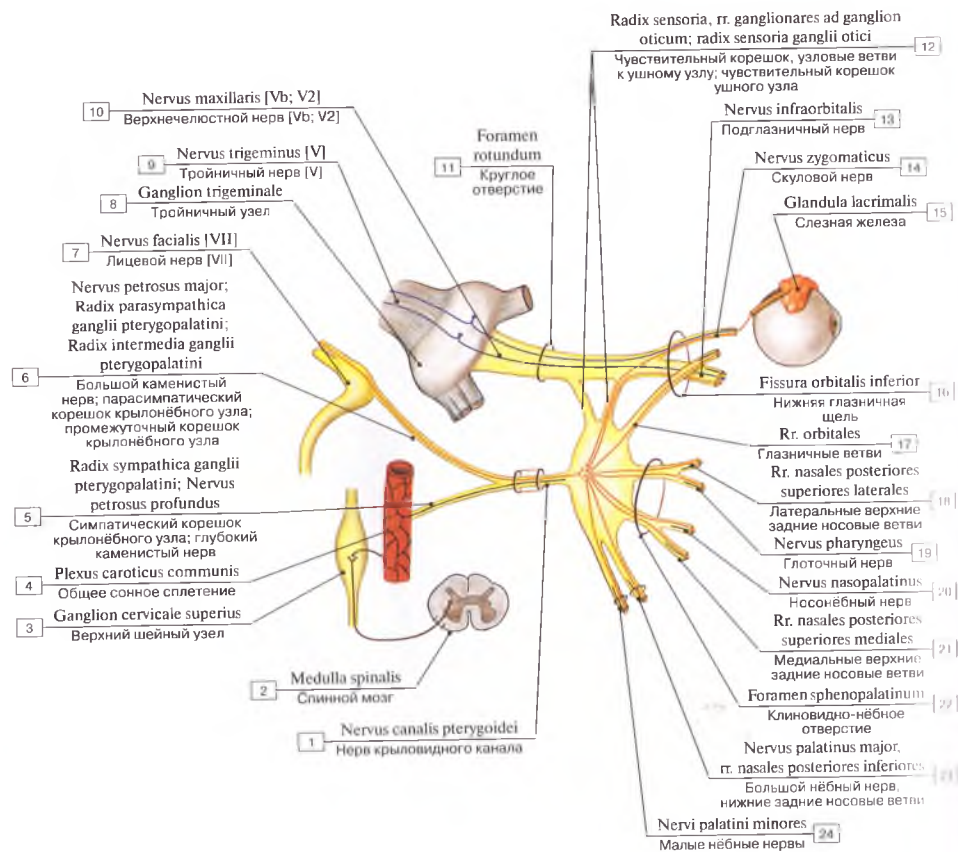


Рис. 379. Крылонёбный узел (схема):

1 – Nerve of pterygoid canal; 2 – Spinal cord; 3 – Superior cervical ganglion; 4 – Common carotid plexus; 5 – Sympathetic root of pterygopalatine ganglion; 6 – Greater petrosal nerve; 7 – Facial nerve [VII]; 8 – Trigeminal ganglion; 9 – Trigeminal nerve [V]; 10 – Maxillary nerve; Maxillary division [Vb; V2]; 11 – Foramen rotundum; 12 – Sensory root, ganglionic branches to otic ganglion; 13 – Infra-orbital nerve; 14 – Zygomatic nerve; 15 – Lacrimal gland; 16 – Inferior orbital fissure; 17 – Orbital branches; 18 – Posterior superior lateral nasal branches; 19 – Pharyngeal nerve; 20 – Nasopalatine nerve; 21 – Posterior superior medial nasal branches; 22 – Sphenopalatine foramen; 23 – Greater palatine nerve; posterior inferior nasal branches; 24 – Lesser palatine nerves

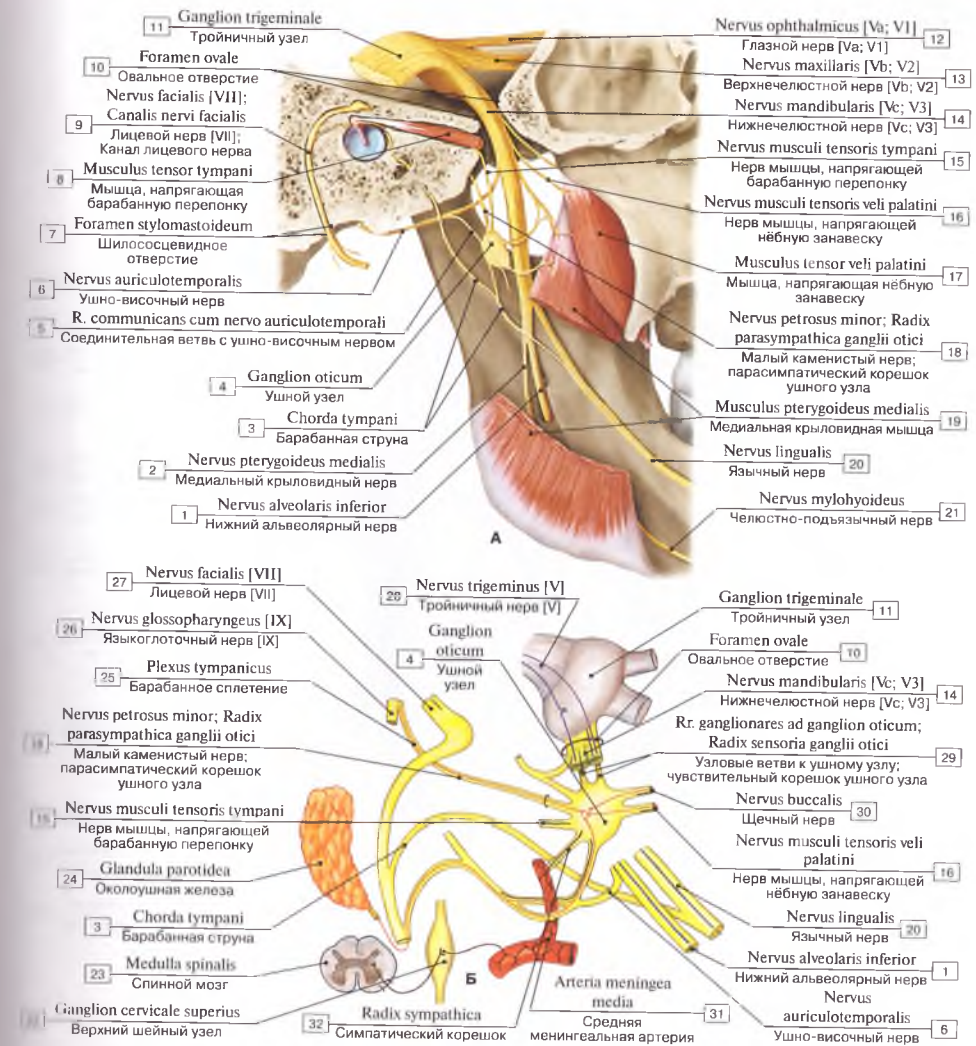


Рис. 380. Ушной узел (А – расположение ушного узла, медиальная крыловидная мышца отсечена; Б – схема):

1 – Inferior alveolar nerve; 2 – Nerve to medial pterygoid; 3 – Chorda tympani; 4 – Otic ganglion; 5 – Communicating branch with auriculotemporal nerve; 6 – Auriculotemporal nerve; 7 – Stylomastoid foramen; 8 – Tensor tympani; 9 – Facial nerve [VII]; Facial canal; 10 – Foramen ovale; 11 – Trigeminal ganglion; 12 – Ophthalmic nerve; Ophthalmic division [Va; V1]; 13 – Maxillary nerve; Maxillary division [Vb; V2]; 14 – Mandibular nerve; Mandibular division [Vc; V3]; 15 – Nerve to tensor tympani; 16 – Nerve to tensor veli palatini; 17 – Tensor veli palatini; 18 – Lesser petrosal nerve; Parasympathetic root of otic ganglion; 19 – Medial pterygoid; 20 – Lingual nerve; 21 – Nerve to mylohyoid; 22 – Superior cervical ganglion; 23 – Spinal cord; 24 – Parotid gland; 25 – Tympanic plexus; 26 – Glossopharyngeal nerve [IX]; 27 – Facial nerve [VII]; 28 – Trigeminal nerve [V]; 29 – Branches to otic ganglion; Sensory root of otic ganglion; 30 – Buccal nerve; 31 – Middle meningeal artery; 32 – Sympathetic root

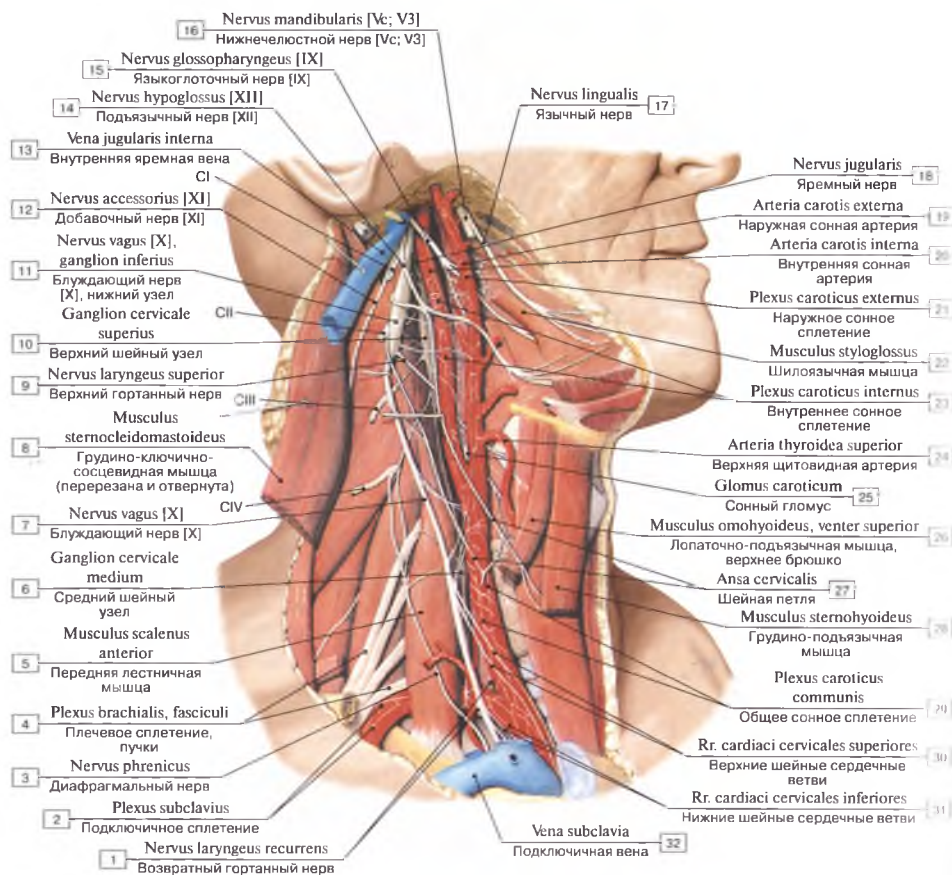


Рис. 381. Связи блуждающего и языкоглоточного нервов с симпатическим стволом:

1 — Recurrent laryngeal nerve; 2 — Subclavian plexus; 3 — Phrenic nerve; 4 — Brachial plexus, cords; 5 — Scalenus anterior; Anterior scaleni; 6 — Middle cervical ganglion; 7 — Vagus nerve [X]; 8 — Sternocleidomastoid; 9 — Superior laryngeal nerve; 10 — Superior cervical ganglion; 11 — Vagus nerve [X], inferior ganglion; 12 — Accessory nerve [XI]; 13 — Internal jugular vein; 14 — Hypoglossal nerve [XII]; 15 — Glossopharyngeal nerve [IX]; 16 — Mandibular nerve; Mandibular division [Vc; V3]; 17 — Lingual nerve; 18 — Jugular nerve; 19 — External carotid artery; 20 — Internal carotid artery; 21 — External carotid plexus; 22 — Styloglossus; 23 — Internal carotid plexus; 24 — Superior thyroid artery; 25 — Carotid body; 26 — Omohyoid, superior belly; 27 — Ansa cervicalis; 28 — Sternohyoid; 29 — Common carotid plexus; 30 — Superior cervical cardiac branches; 31 — Inferior cervical cardiac branches; 32 — Subclavian vein

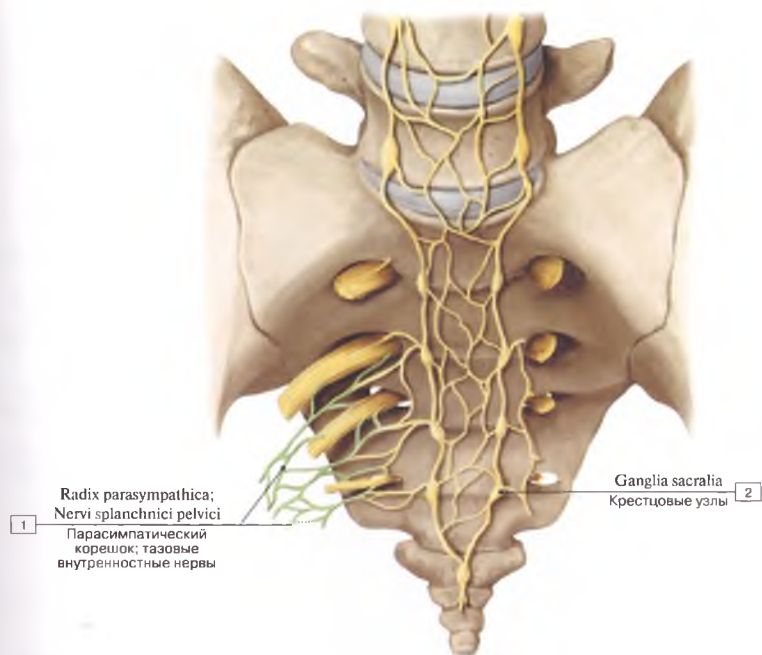


Рис. 382. Крестцовая часть парасимпатического отдела вегетативной нервной системы:

1 – Parasympathetic root; Pelvic splanchnic nerves; 2 – Sacral nodes

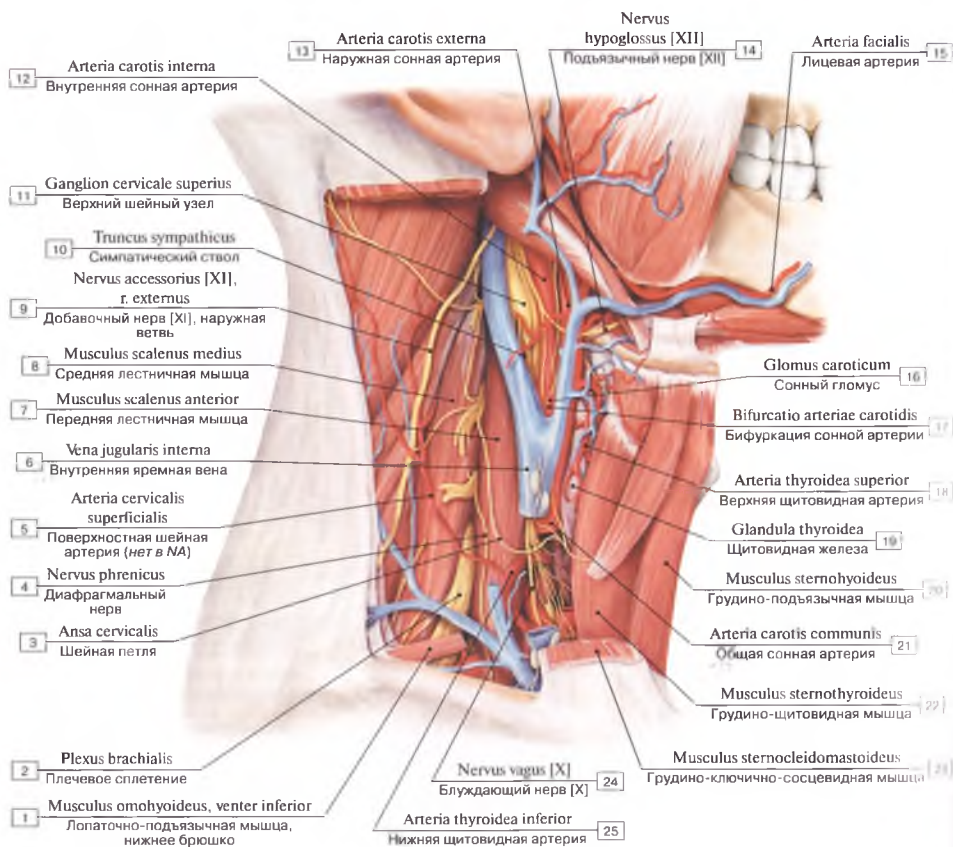


Рис. 385. Верхний шейный узел:

1 – Omohyoid, inferior belly; 2 – Brachial plexus; 3 – Ansa cervicalis; 4 – Phrenic nerve; 5 – Superficial cervical artery; 6 – Internal jugular vein; 7 – Scalenus anterior; Anterior scalene; 8 – Scalenus medius; Middle scalene; 9 – Accessory nerve [XI], external branch; 10 – Sympathetic trunk; 11 – Superior cervical ganglion; 12 – Internal carotid artery; 13 – External carotid artery; 14 – Hypoglossal nerve [XII]; 15 – Facial artery; 16 – Carotid body; 17 – Carotid bifurcation; 18 – Superior thyroid artery; 19 – Thyroid gland; 20 – Sternohyoid; 21 – Common carotid artery; 22 – Sternothyroid; 23 – Sternocleidomastoid; 24 – Vagus nerve [X]; 25 – Inferior thyroid artery.

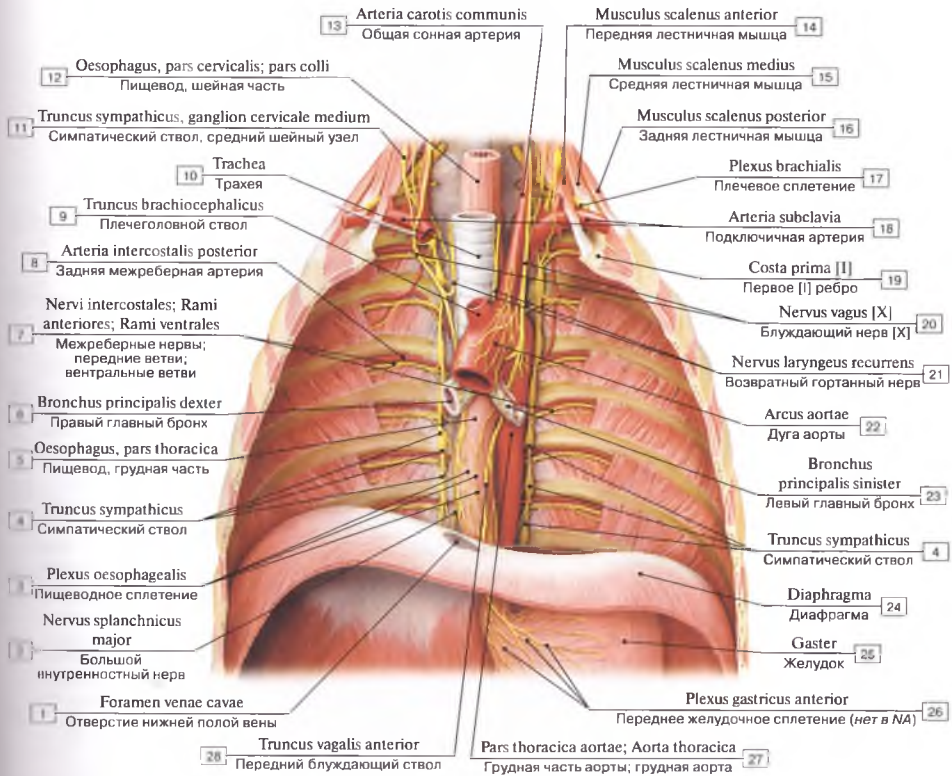


Рис. 386. Симпатический ствол, грудной отдел:

1 – Caval opening; 2 – Greater splanchnic nerve; 3 – Oesophageal plexus; 4 – Sympathetic trunk; 5 – Oesophagus, thoracic part; 6 – Right main bronchus; 7 – Intercostal nerves; Anterior branches; Ventral branches; 8 – Posterior intercostal artery; 9 – Brachiocephalic trunk; 10 – Trachea; 11 – Sympathetic trunk, middle cervical ganglion; 12 – Oesophagus, cervical part; 13 – Common carotid artery; 14 – Scalenus anterior; Anterior scalene; 15 – Scalenus medius; Middle scalene; 16 – Scalenus posterior; Posterior scalene; 17 – Brachial plexus; 18 – Subclavian artery; 19 – First rib [I]; 20 – Vagus nerve [X]; 21 – Recurrent laryngeal nerve; 22 – Arch of aorta; Aortic arch; 23 – Left main bronchus; 24 – Diaphragm; 25 – Stomach; 26 – Anterior gastric plexus; 27 – Thoracic aorta; 28 – Anterior vagal trunk

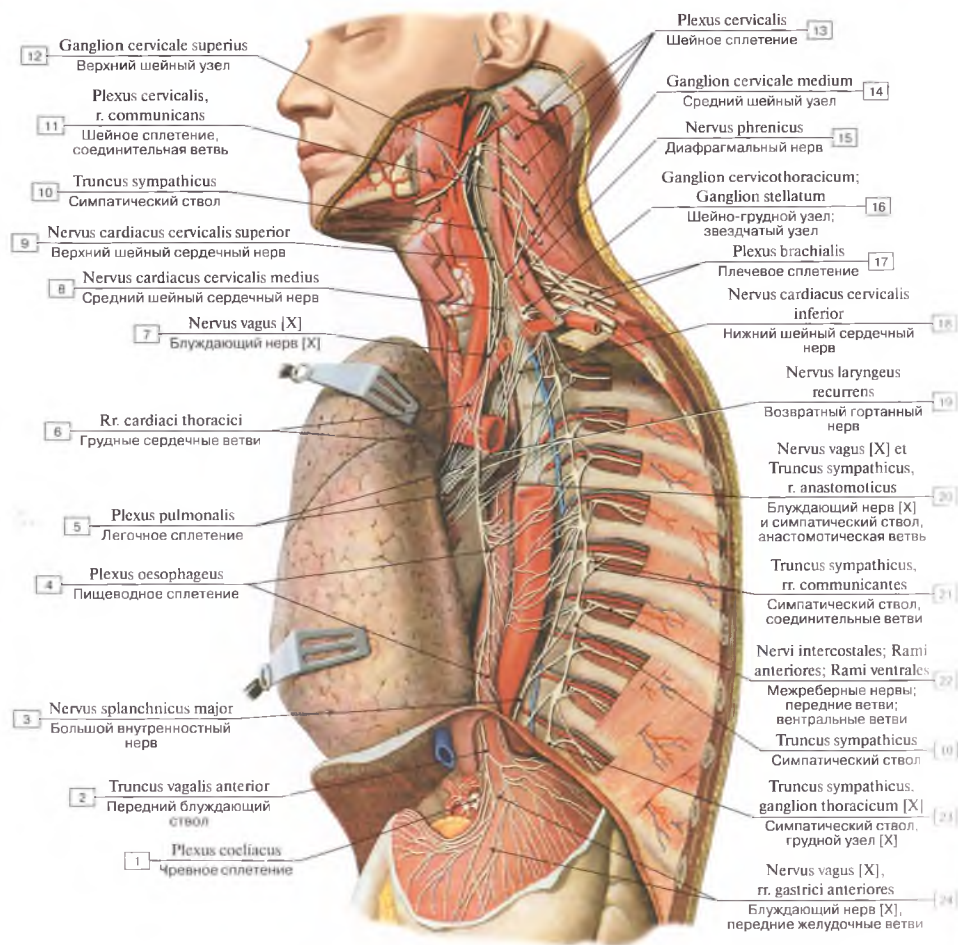
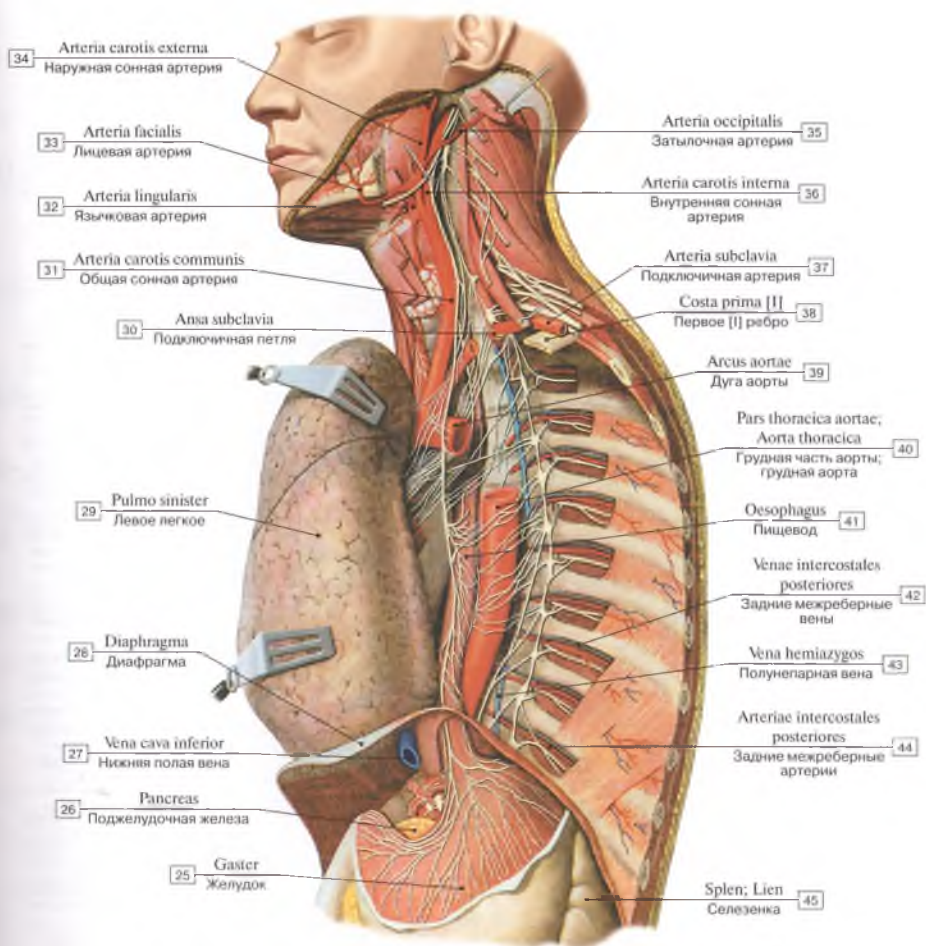


Рис. 387. Нервы и сплетения органов грудной полости, вид слева  
(пристеночный листок брюшины и внутригрудная фасция удалены; левое легкое отведено вправо):

1 – Coeliac plexus; 2 – Anterior vagal trunk; 3 – Greater splanchnic nerve; 4 – Oesophageal plexus; 5 – Pulmonary plexus; 6 – Thoracic cardiac branches; 7 – Vagus nerve [X]; 8 – Middle cervical cardiac nerve; 9 – Superior cervical cardiac nerve; 10 – Sympathetic trunk; 11 – Cervical plexus, communicating branch; 12 – Superior cervical ganglion; 13 – Cervical plexus; 14 – Middle cervical ganglion; 15 – Phrenic nerve; 16 – Cervicothoracic ganglion; 17 – Brachial plexus; 18 – Inferior cervical cardiac nerve; 19 – Recurrent laryngeal nerve; 20 – Vagus nerve [X] and Sympathetic trunk, anastomotic branch; 21 – Sympathetic trunk, communicating branch; 22 – Intercostal nerves; 23 – Sympathetic trunk, ganglion thoracicum [X]; 24 – Vagus nerve [X], anterior gastric branches.





31 – Intercostal nerves; Anterior branches; Ventral branches; 23 – Sympathetic trunk, thoracic ganglion [X]; 24 – Vagus nerve [X], anterior branches; 25 – Stomach; 26 – Pancreas; 27 – Inferior vena cava; 28 – Diaphragm; 29 – Left lung; 30 – Ansa subclavia; 31 – Common carotid artery; 32 – Lingular artery; 33 – Facial artery; 34 – External carotid artery; 35 – Occipital artery; 36 – Internal carotid artery; 37 – Subclavian artery; 38 – First rib [I]; 39 – Arch of aorta; Aortic arch; 40 – Thoracic aorta; 41 – Oesophagus; 42 – Posterior intercostal veins; 43 – Hemi-azygos vein; Inferior hemi-azygos vein; 44 – Posterior intercostal arteries; 45 – Spleen

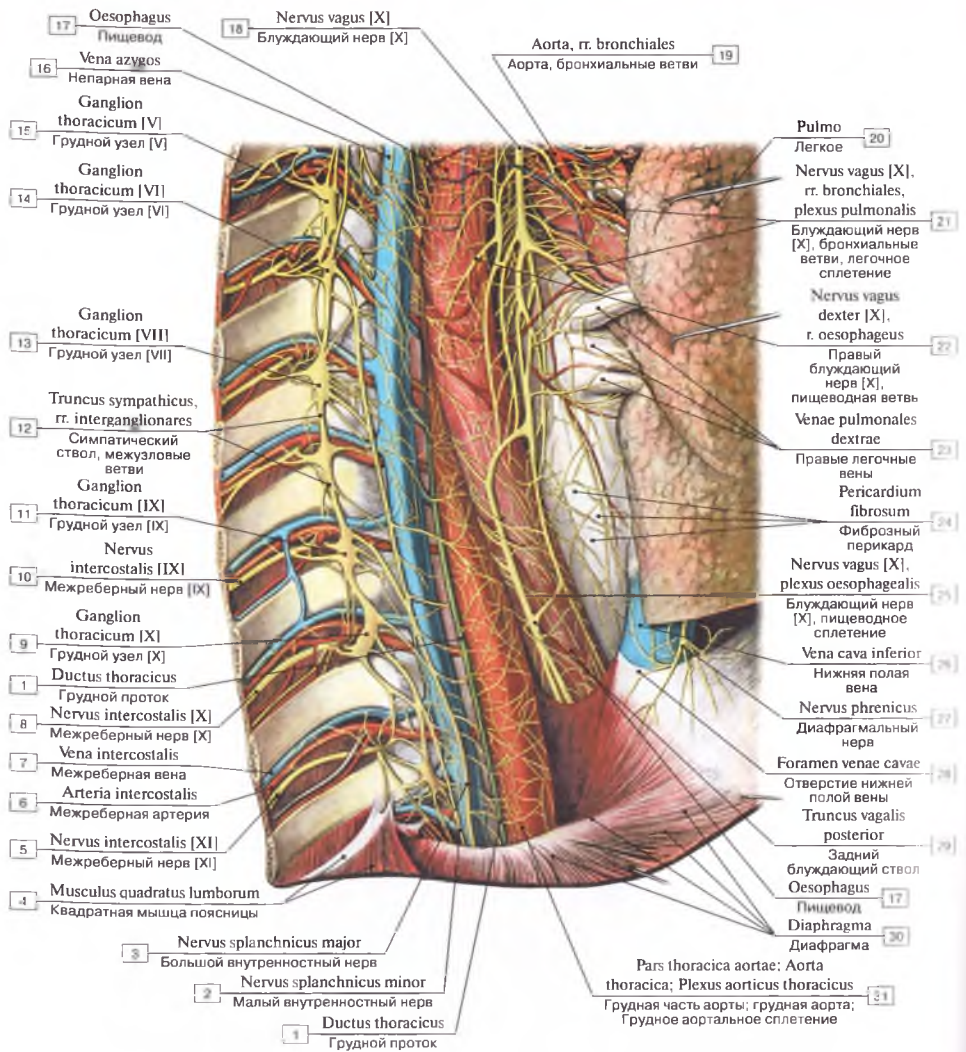


Рис. 388. Нервы, отходящие от симпатического ствола в грудном отделе, вид спереди:

1 — Thoracic duct; 2 — Lesser splanchnic nerve; 3 — Greater splanchnic nerve; 4 — Quadratus lumborum; 5 — Intercostal nerves; 6 — Intercostal artery; 7 — Intercostal vein; 8 — Intercostal nerves [X]; 9 — Thoracic ganglion [X]; 10 — Intercostal nerves [IX]; 11 — Thoracic ganglion [IX]; 12 — Sympathetic trunk, interganglionic branches; 13 — Thoracic ganglion [VII]; 14 — Thoracic ganglion [VI]; 15 — Thoracic ganglion [V]; 16 — Azygos vein; 17 — Oesophagus; 18 — Vagus nerve [X]; 19 — Aorta, bronchial branches; 20 — Lung; 21 — Vagus nerve [X], bronchial branches, pulmonary plexus; 22 — Right vagus nerve [X]; 23 — Right pulmonary veins; 24 — Fibrous pericardium; 25 — Vagus nerve [X], oesophageal plexus; 26 — Inferior vena cava; 27 — Phrenic nerve; 28 — Caval opening; 29 — Posterior vagal trunk; 30 — Diaphragm; 31 — Thoracic aorta; Thoracic aortic plexus

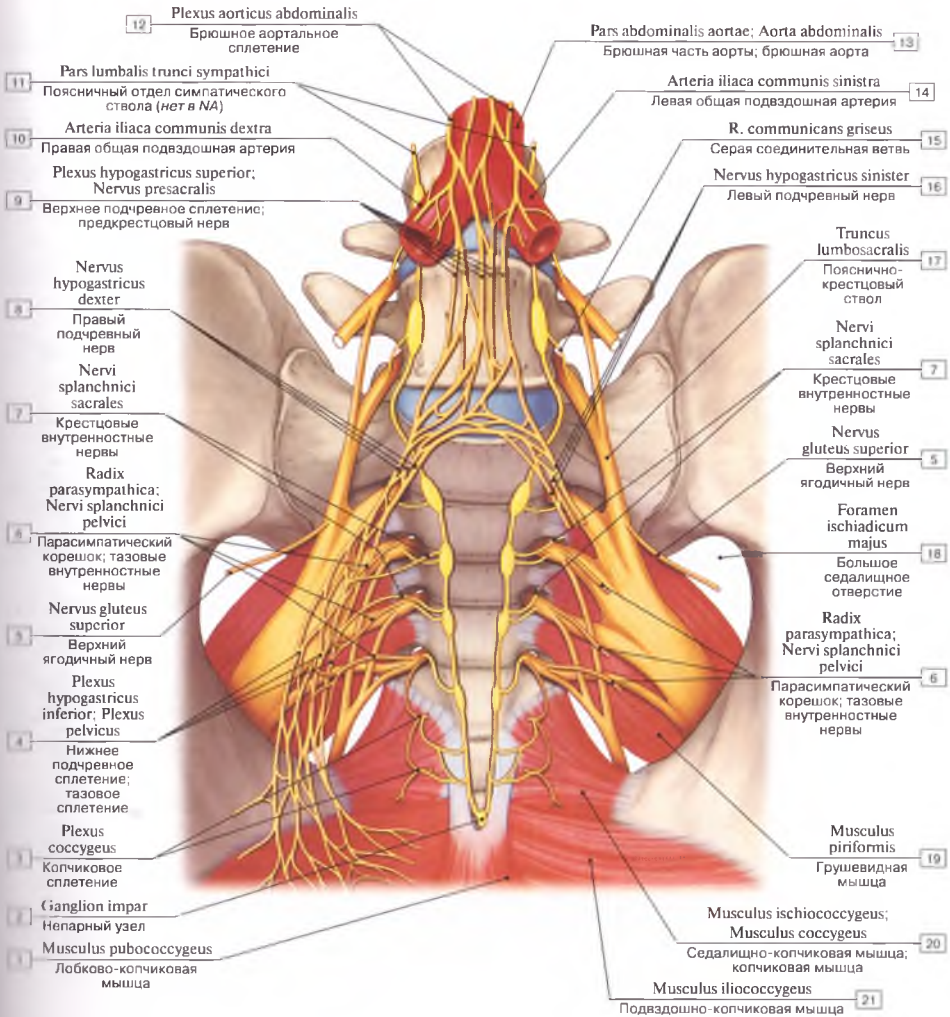


Рис. 389. Симпатический ствол, тазовый отдел:

- 1 – Pihococcygeus; 2 – Ganglion impar; 3 – Coccygeal plexus; 4 – Inferior hypogastric plexus; Pelvic plexus; 5 – Superior gluteal nerve; 6 – Parasympathetic root; Pelvic splanchnic nerves; 7 – Sacral splanchnic nerves; 8 – Right hypogastric nerve; 9 – Superior hypogastric plexus; Inferior hypogastric plexus; 10 – Right common iliac artery; 11 – Lumbar part of sympathetic trunk; 12 – Abdominal aortic plexus; 13 – Abdominal aortic plexus; 14 – Left common iliac artery; 15 – Grey communicating branch; 16 – Left hypogastric nerve; 17 – Lumbosacral trunk; 18 – Greater sciatic foramen; 19 – Piriformis; 20 – Ischiococcygeus; Coccygeus; 21 – Iliococcygeus

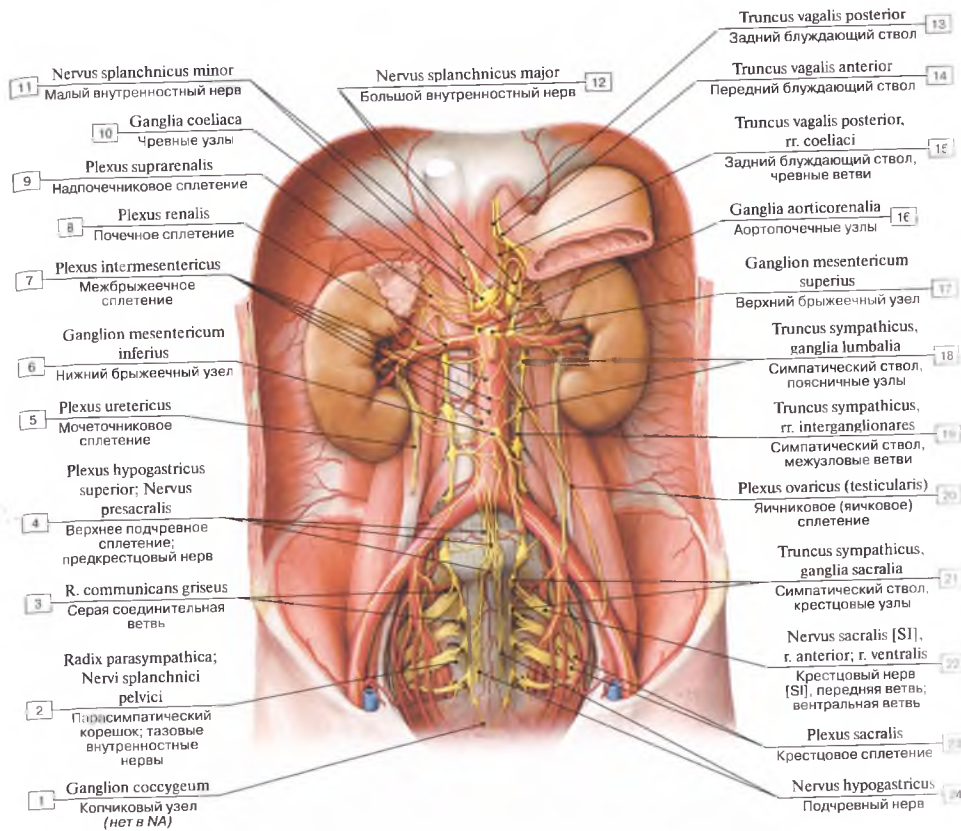


Рис. 390. Симпатические узлы и сплетения в брюшной полости и малом тазу:

1 — Coccygeal ganglion; 2 — Parasympathetic root; Pelvic splanchnic nerves; 3 — Grey communicating branch; 4 — Superior hypogastric plexus; Presacral nerve; 5 — Ureteric plexus; 6 — Inferior mesenteric ganglion; 7 — Intermesenteric plexus; 8 — Renal plexus; 9 — Suprarenal plexus; 10 — Coeliac ganglia; 11 — Lesser splanchnic nerve; 12 — Greater splanchnic nerve; 13 — Posterior vagal trunk; 14 — Anterior vagal trunk; 15 — Posterior vagal trunk, coeliac branches; 16 — Aorticorenal ganglia; 17 — Superior mesenteric ganglion; 18 — Sympathetic trunk lumbar ganglia; 19 — Sympathetic trunk, interganglionic branches; 20 — Ovarian (testicular) plexus; 21 — Sympathetic trunk, sacral ganglia; 22 — Sacral nerve [SI], anterior branch; ventral branch; 23 — Sacral plexus; 24 — Hypogastric nerve

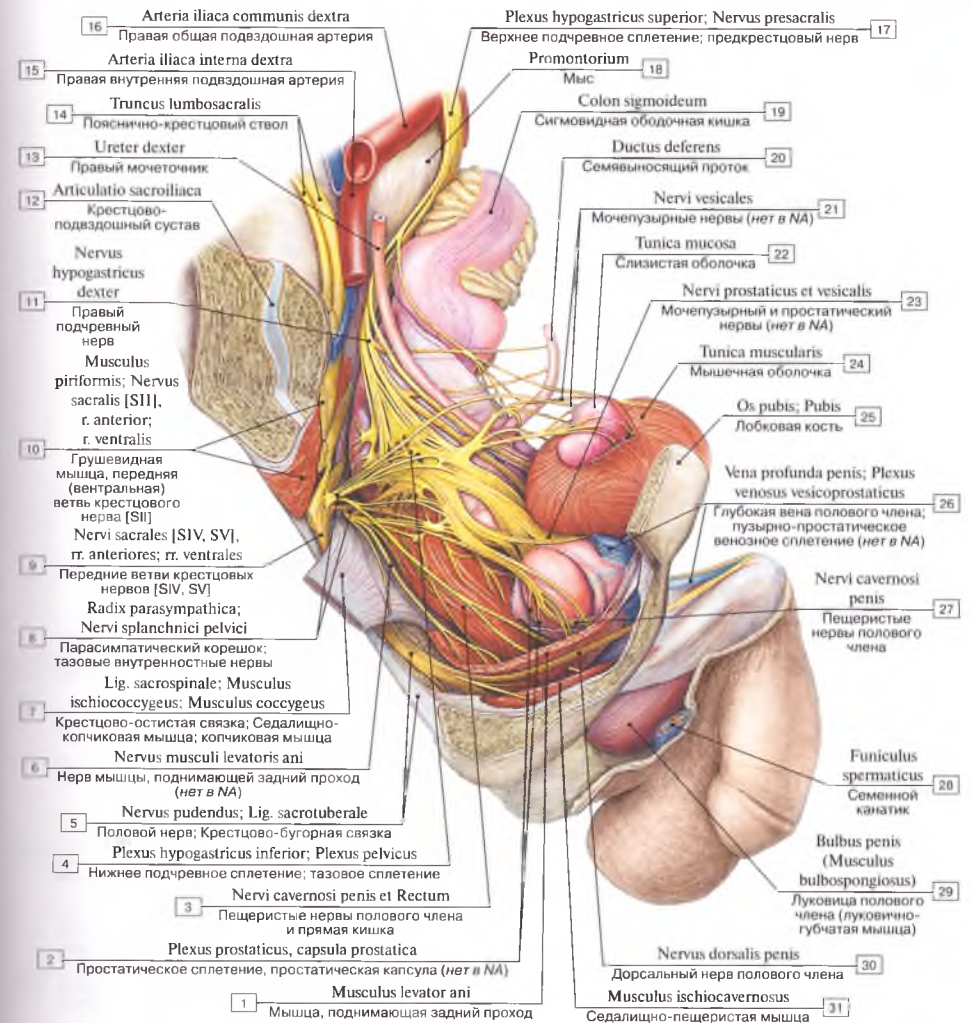


Рис. 391. Тазовые сплетения мужского таза:

1 — Levator ani; 2 — Prostatic plexus and capsula; 3 — Cavemous nerves of penis and Rectum; 4 — Inferior hypogastric plexus; Pelvic plexus; 5 — Pudendal nerve; Sacrotuberous ligament; 6 — Nerve of levator ani; 7 — Sacrospinous ligament; Ischiococcygeus; Coccygeus; 8 — Parasympathetic root; Pelvic splanchnic nerves; 9 — Sacral nerves [SIV, SV], anterior branches; ventral branches; 10 — Piriformis and Sacral nerve [SI], anterior branch; ventral branch; 11 — Right hypogastric nerve; 12 — Sacro-iliac joint; 13 — Right ureter; 14 — Lumbo-sacral trunk; 15 — Right internal iliac artery; 16 — Right common iliac artery; 17 — Superior hypogastric plexus; Presacral nerve; 18 — Promontory; 19 — Sigmoid colon; 20 — Ductus deferens; Vas deferens; 21 — Vesical nerves; 22 — Mucosa; Mucous membrane; 23 — Vesical and prostatic nerves; 24 — Muscular layer; Muscular coat; 25 — Pubis; 26 — Deep vein of penis; Vesicoprostatic venous plexus; 27 — Cavemous nerves of penis; 28 — Spermatic cord; 29 — Bulb of penis (Bulbospongiosus); 30 — Dorsal nerve of penis; 31 — Ischio-cavernosus

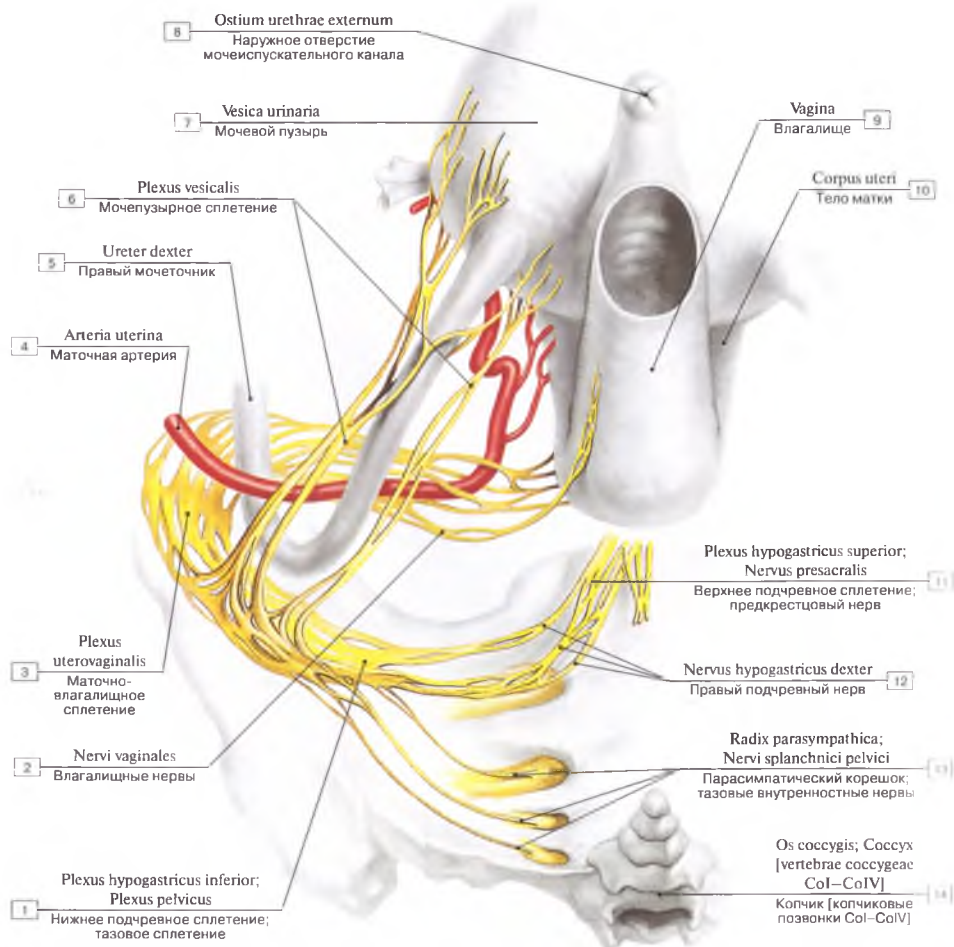


Рис. 392. Тазовые сплетения женского таза:

1 – Inferior hypogastric plexus; Pelvic plexus; 2 – Vaginal nerves; 3 – Uterovaginal plexus; 4 – Uterine artery; 5 – Right ureter; 6 – Vesical plexus; 7 – Urinary bladder; 8 – External urethral orifice; External urinary meatus; 9 – Vagina; 10 – Body of uterus; 11 – Superior hypogastric plexus; Presacral nerve; 12 – Right hypogastric nerve; 13 – Parasympathetic root; Pelvic splanchnic nerves; 14 – Coccyx [coccygeal vertebrae CoI–CoIV]

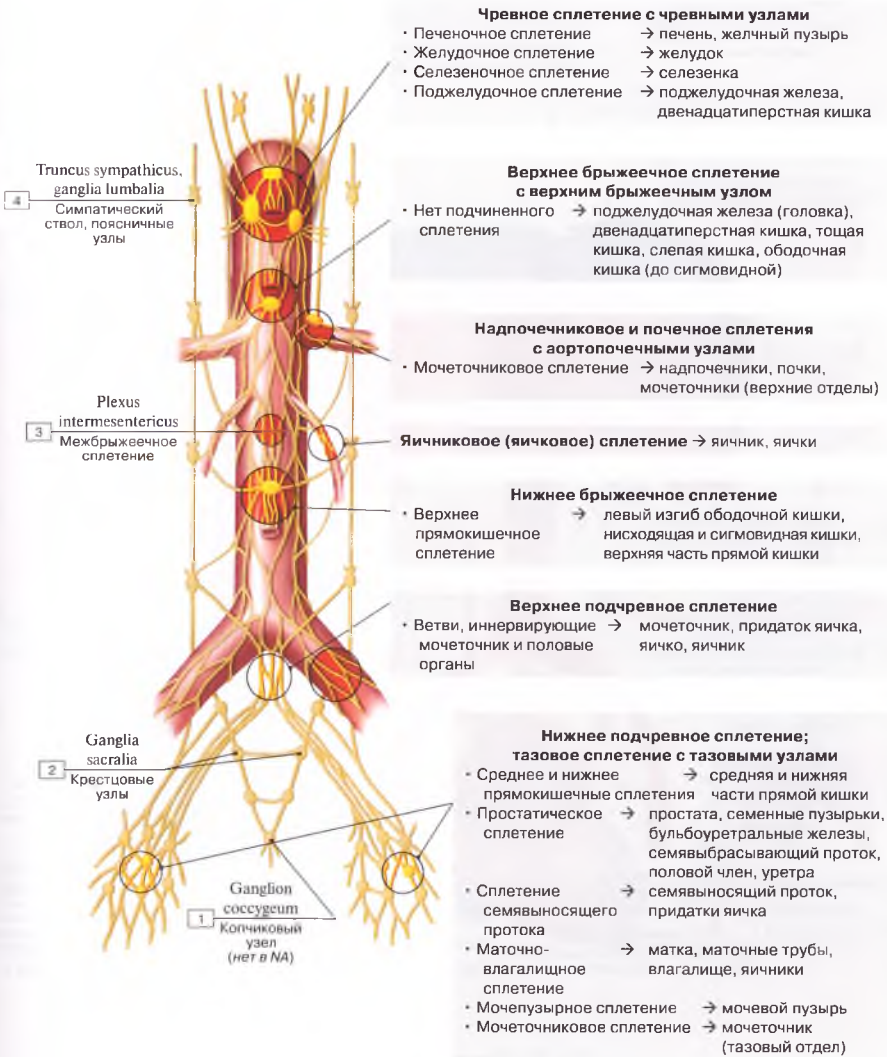


Рис. 393. Вегетативные сплетения брюшной полости и полости таза:

1 – Coccygeal ganglion; 2 – Sacral ganglia; 3 – Intermesenteric plexus; 4 – Sympathetic trunk, lumbar ganglia

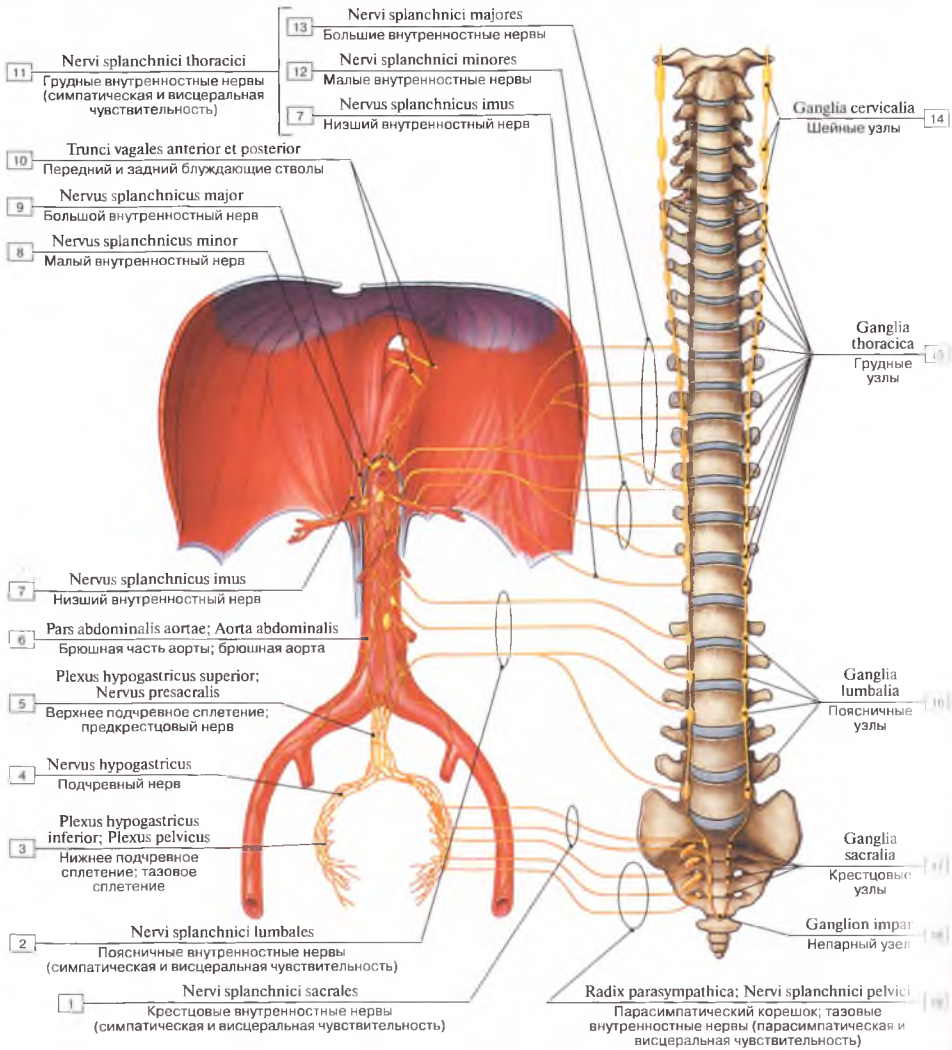


Рис. 394. Внутренностные нервы (схема):

1 — Sacral splanchnic nerves; 2 — Lumbar splanchnic nerves; 3 — Inferior hypogastric plexus; Pelvic plexus; 4 — Hypogastric nerve; 5 — Superior hypogastric plexus; Presacral nerve; 6 — Abdominal aorta; 7 — Least splanchnic nerve; Lowest splanchnic nerve; 8 — Lesser splanchnic nerve; 9 — Greater splanchnic nerve; 10 — Anterior and posterior vagal trunks; 11 — Thoracic splanchnic nerves; 12 — Lesser splanchnic nerves; 13 — Greater splanchnic nerves; 14 — Cervical ganglia; 15 — Thoracic ganglia; 16 — Lumbar ganglia; 17 — Sacral ganglia; 18 — Ganglion impar; 19 — Parasympathetic root; Pelvic splanchnic nerves

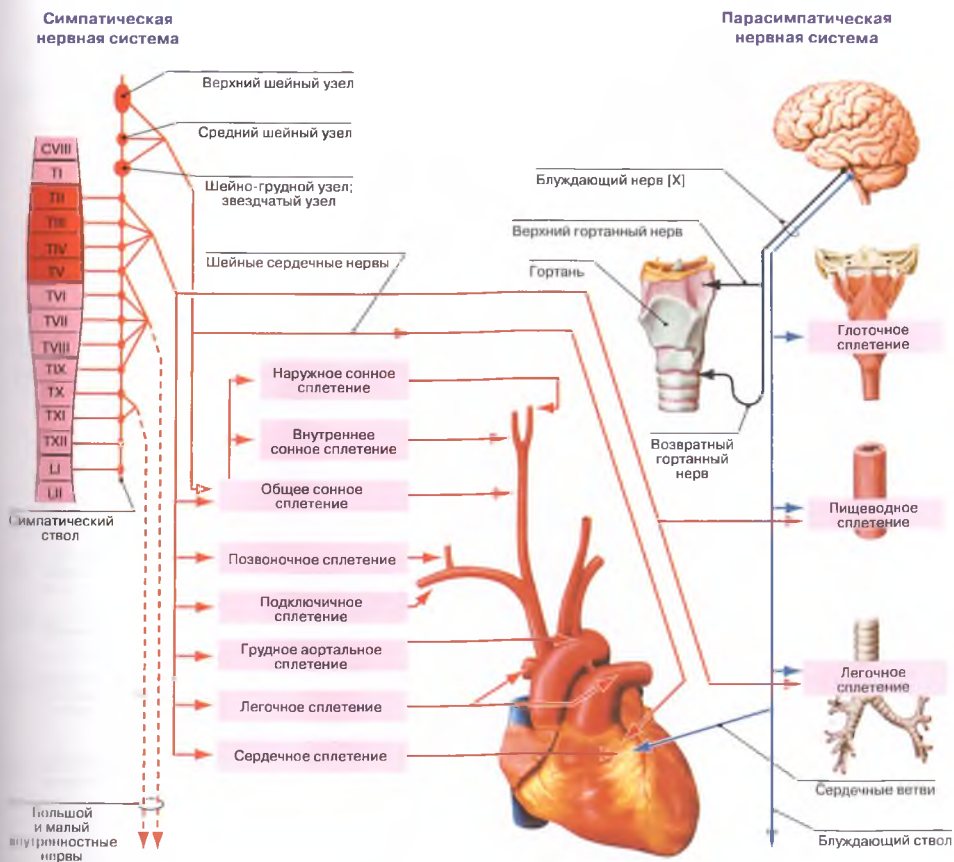


Рис. 395. Организация симпатической и парасимпатической нервной системы в шейном и грудном отделах (схема)



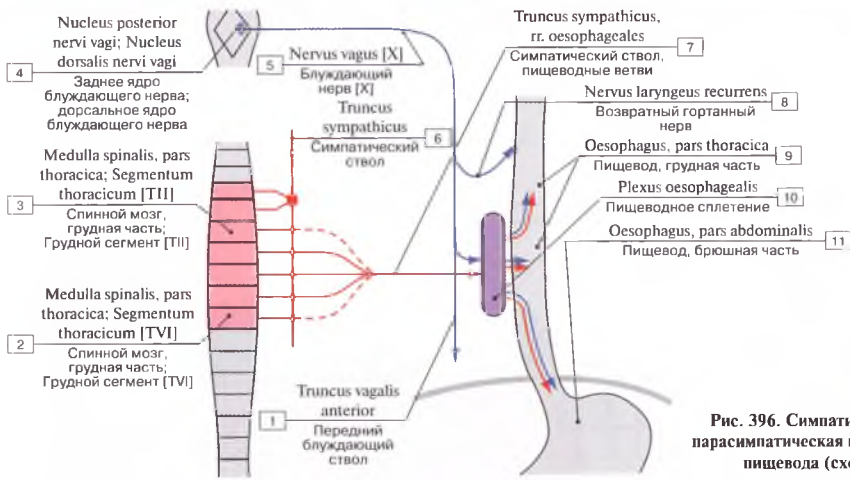


Рис. 396. Симпатическая и парасимпатическая иннервация пищевода (схема):

1 — Anterior vagal trunk; 2 — Spinal cord, thoracic part; Thoracic segment [TVI]; 3 — Spinal cord, thoracic part; Thoracic segment [TII]; 4 — Posterior nucleus of vagus nerve; Dorsal nucleus of vagus nerve; 5 — Vagus nerve [X]; 6 — Sympathetic trunk; 7 — Sympathetic trunk, oesophageal branches; 8 — Recurrent laryngeal nerve; 9 — Oesophagus, thoracic part; 10 — Oesophageal plexus; 11 — Oesophagus, abdominal part

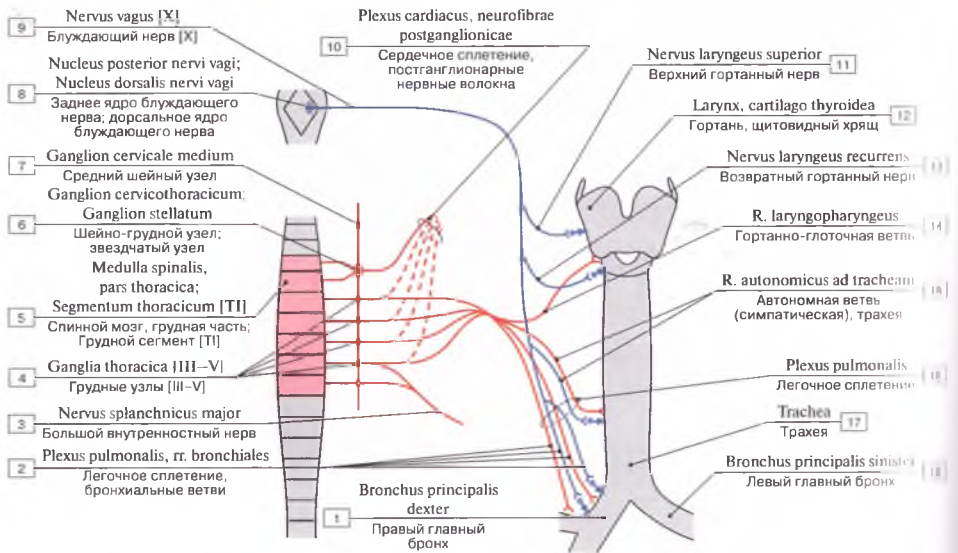


Рис. 397. Симпатическая и парасимпатическая иннервация гортани, трахеи и бронхов (схема):

1 — Right main bronchus; 2 — Pulmonary plexus, bronchial branches; 3 — Greater splanchnic nerve; 4 — Thoracic ganglia [III-V]; 5 — Spinal cord, thoracic part; Thoracic segment [TII]; 6 — Cervicothoracic ganglion; Stellate ganglion; 7 — Middle cervical ganglion; 8 — Dorsal nucleus of vagus nerve; Dorsal nucleus of vagus nerve; 9 — Vagus nerve [X]; 10 — Cardiac plexus, postganglionic nerve fibres; 11 — Superior laryngeal nerve; 12 — Larynx, thyroid cartilage; 13 — Recurrent laryngeal nerve; 14 — Laryngopharyngeal branch; 15 — Autonomic branch, trachea; 16 — Pulmonary plexus; 17 — Trachea; 18 — Left main bronchus

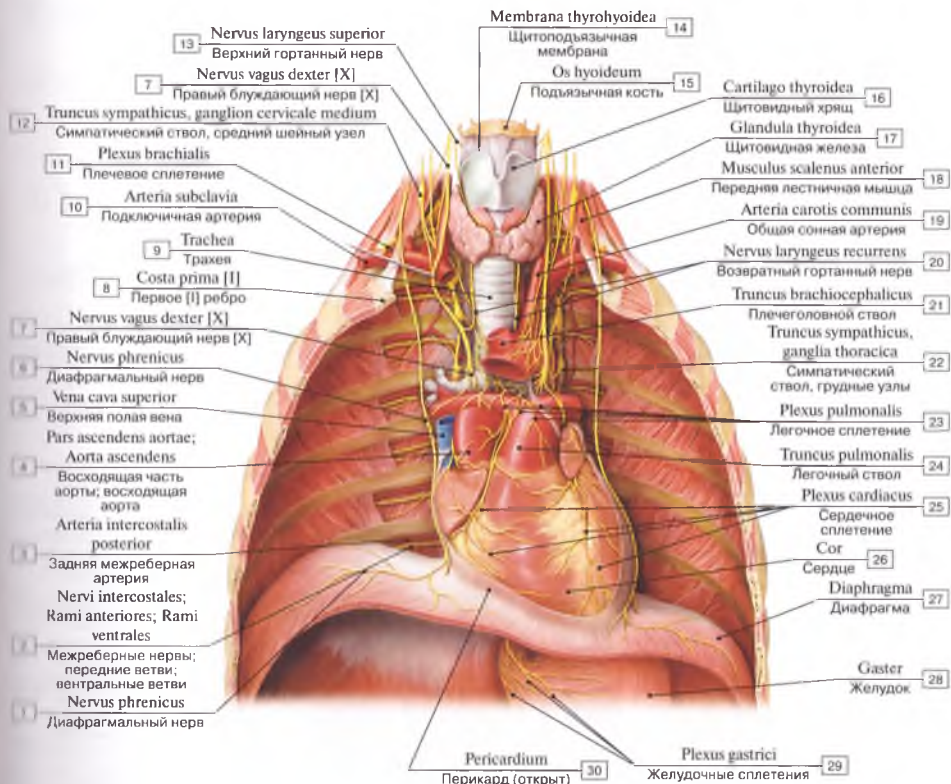


Рис. 398. Вегетативная (автономная) иннервация сердца:

1 – Phrenic nerve; 2 – Intercostal nerves; Anterior branches; Ventral branches; 3 – Posterior intercostal artery; 4 – Ascending aorta; 5 – Superior vena cava; 6 – Phrenic nerve; 7 – Right vagus nerve [X]; 8 – First rib [I]; 9 – Trachea; 10 – Subclavian artery; 11 – Brachial plexus; 12 – Sympathetic trunk; 13 – Superior laryngeal nerve; 14 – Thyrohyoid membrane; 15 – Hyoid bone; 16 – Thyroid cartilage; 17 – Thyroid gland; 18 – Scalenus anterior; Anterior scalene; 19 – Common carotid artery; 20 – Recurrent laryngeal nerve; 21 – Brachiocephalic trunk; 22 – Sympathetic trunk, thoracic ganglia; 23 – Pulmonary plexus; 24 – Pulmonary trunk; 25 – Cardiac plexus; 26 – Heart; 27 – Diaphragm; 28 – Stomach; 29 – Gastric plexuses; 30 – Pericardium

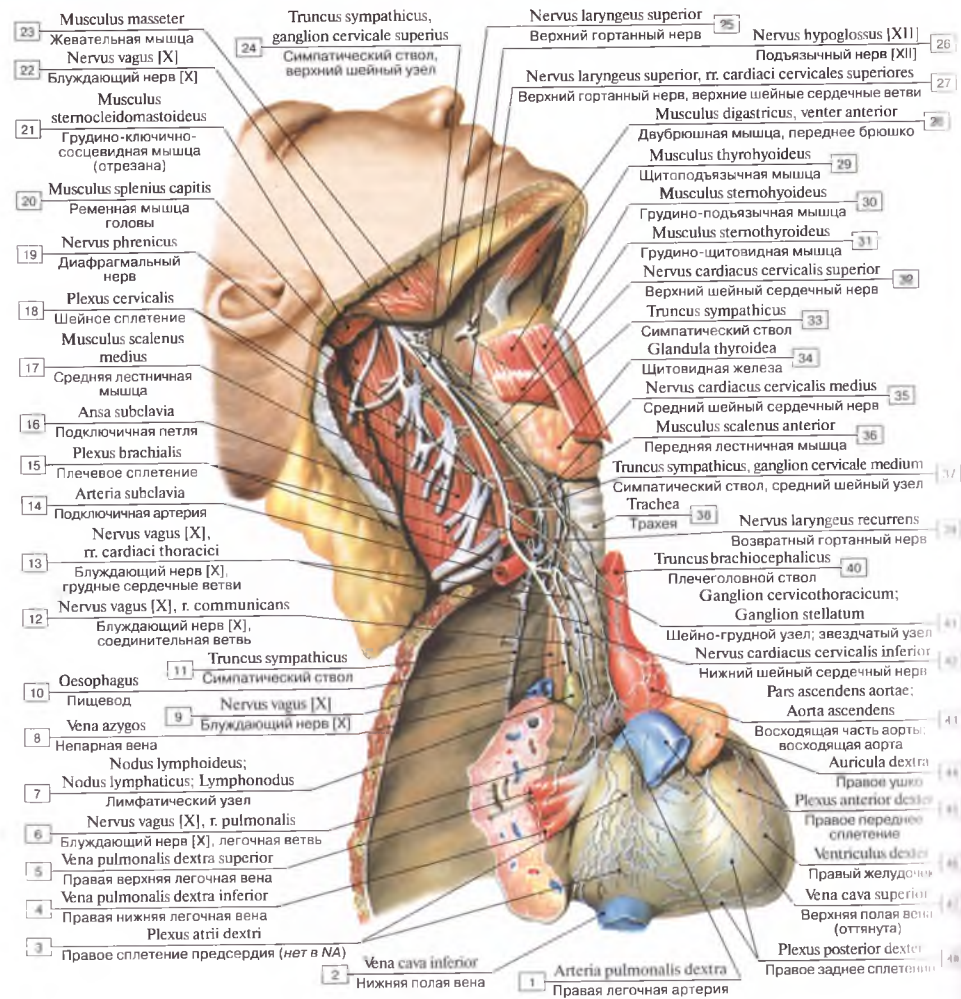


Рис. 399. Нервы сердца, вид справа:

- 1 – Right pulmonary artery; 2 – Inferior vena cava; 3 – Right atrium plexus; 4 – Right inferior pulmonary vein; 5 – Right superior pulmonary vein; 6 – Vagus nerve [X], pulmonary branch; 7 – Lymph node; 8 – Azygos vein; 9 – Vagus nerve [X]; 10 – Oesophagus; 11 – Sympathetic trunk; 12 – Vagus nerve [X], communicating branch; 13 – Vagus nerve [X], thoracic cardiac branches; 14 – Subclavian artery; 15 – Brachial plexus; 16 – Ansa subclavia; 17 – Scalenus medius; 18 – Cervical plexus; 19 – Phrenic nerve; 20 – Splenius capitis; 21 – Sternocleidomastoid; 22 – Vagus nerve [X]; 23 – Masseter; 24 – Sympathetic trunk, superior cervical ganglion; 25 – Superior laryngeal nerve; 26 – Hypoglossal nerve [XII]; 27 – Superior laryngeal nerve, superior cervical cardiac branches; 28 – Digastric anterior belly; 29 – Thyrohyoid; 30 – Sternohyoid; 31 – Sternothyroid; 32 – Superior cervical cardiac nerve; 33 – Sympathetic trunk; 34 – Thyroid gland; 35 – Middle cervical cardiac nerve; 36 – Scalenus anterior; Anterior scalene; 37 – Sympathetic trunk, middle cervical ganglion; 38 – Trachea; 39 – Recurrent laryngeal nerve; 40 – Brachiocephalic trunk; 41 – Cervicothoracic ganglion; Stellate ganglion; 42 – Inferior cervical cardiac nerve; 43 – Ascending aorta; 44 – Right auricle; 45 – Right anterior plexus; 46 – Right ventricle; 47 – Superior vena cava; 48 – Right posterior plexus

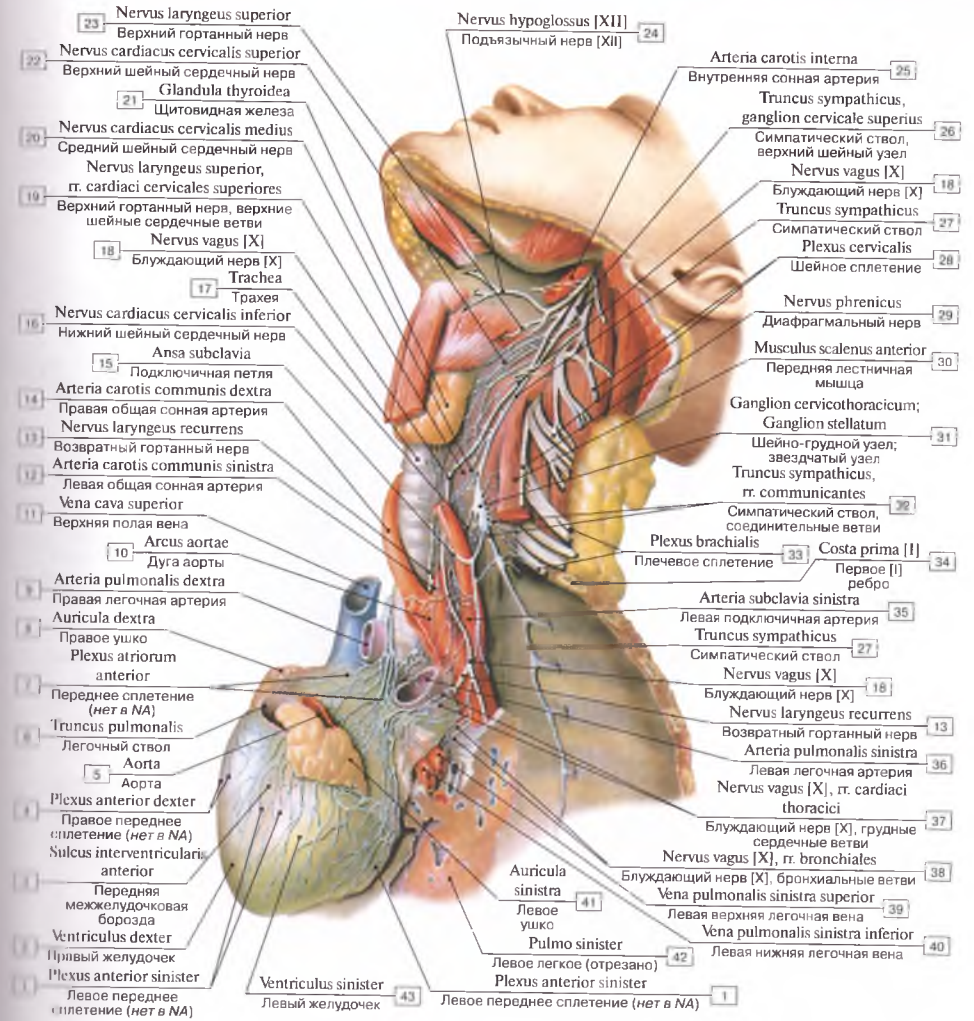


Рис. 400. Нервы сердца, вид слева:

- 1 – Left anterior plexus; 2 – Right ventricle; 3 – Anterior interventricular sulcus; 4 – Right anterior plexus; 5 – Aorta; 6 – Pulmonary trunk; 7 – Inferior plexus; 8 – Right auricle; 9 – Right pulmonary artery; 10 – Arch of aorta; Aortic arch; 11 – Superior vena cava; 12 – Left common carotid artery; 13 – Recurrent laryngeal nerve; 14 – Right common carotid artery; 15 – Ansa subclavia; 16 – Inferior cervical cardiac nerve; 17 – Trachea; 18 – Vagus nerve [X]; 19 – Superior laryngeal nerve, superior cervical cardiac branches; 20 – Middle cervical cardiac nerve; 21 – Thyroid gland; 22 – Superior cervical cardiac nerve; 23 – Superior laryngeal nerve; 24 – Hypoglossal nerve [XII]; 25 – Internal carotid artery; 26 – Sympathetic trunk, superior cervical ganglion; 27 – Sympathetic trunk; 28 – Cervical plexus; 29 – Phrenic nerve; 30 – Scalenus anterior; Anterior scalene; 31 – Cervicothoracic ganglion; Stellate ganglion; 32 – Sympathetic trunk, communicating branches; 33 – Brachial plexus; 34 – First rib [I]; 35 – Left subclavian artery; 36 – Left pulmonary artery; 37 – Vagus nerve [X], thoracic cardiac branches; 38 – Vagus nerve [X], bronchial branches; 39 – Left superior pulmonary vein; 40 – Left inferior pulmonary vein; 41 – Left auricle; 42 – Left lung; 43 – Left ventricle

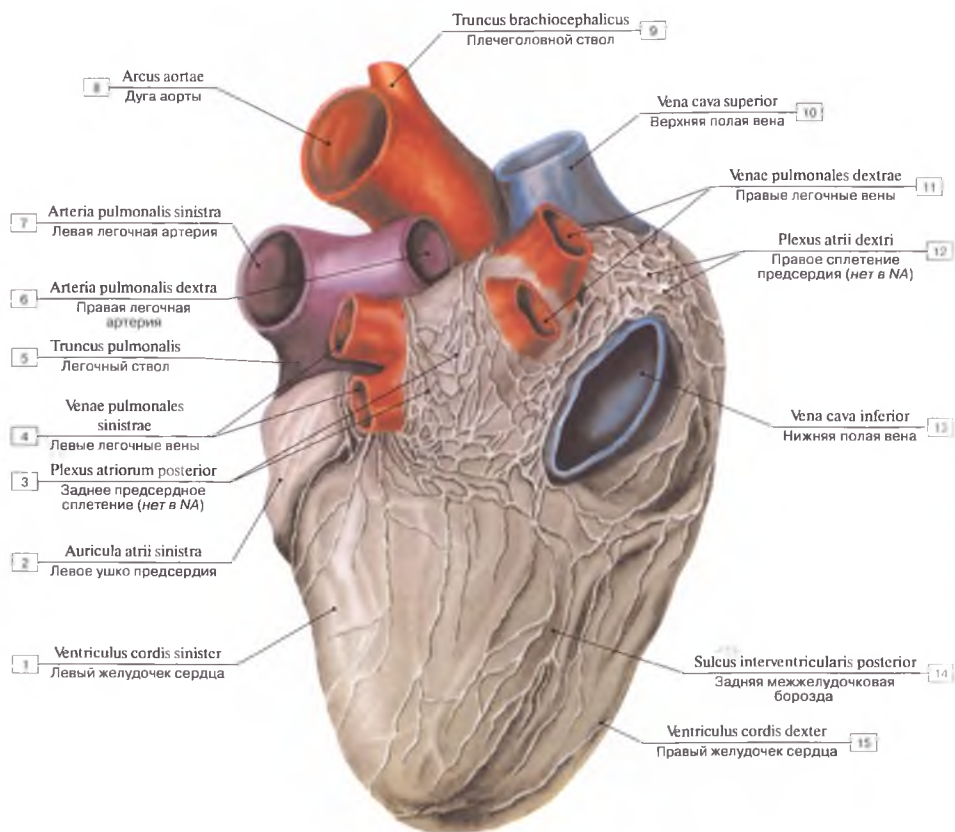


Рис. 401. Сердечные сплетения:

1 – Left ventricle; 2 – Left auricle; 3 – Posterior atrial plexus; 4 – Left pulmonary veins; 5 – Pulmonary trunk; 6 – Right pulmonary artery; 7 – Left pulmonary artery; 8 – Arch of aorta; Aortic arch; 9 – Brachiocephalic trunk; 10 – Superior vena cava; 11 – Right pulmonary vein; 12 – Right atrium plexus; 13 – Inferior vena cava; 14 – Posterior interventricular sulcus; 15 – Right ventricle

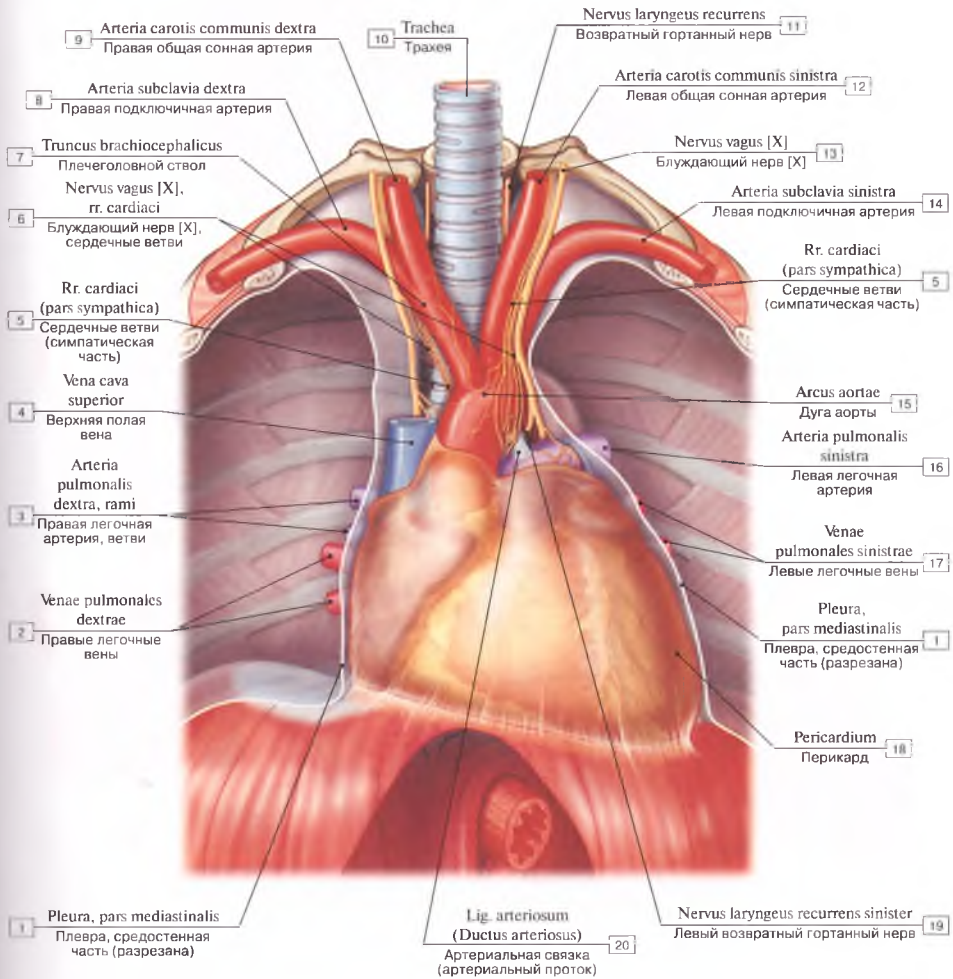


Рис. 402. Артерии и нервы средостения:

- 1 – Pleura, mediastinal part; 2 – Right pulmonary veins; 3 – Right pulmonary artery, branches; 4 – Superior vena cava; 5 – Cardiac branches (sympathetic part); 6 – Vagus nerve [X], cardiac branches; 7 – Brachiocephalic trunk; 8 – Right subclavian artery; 9 – Right common carotid artery; 10 – Trachea; 11 – Recurrent laryngeal nerve; 12 – Left common carotid artery; 13 – Vagus nerve [X]; 14 – Left subclavian artery; 15 – Arch of aorta; Aortic arch; 16 – Left pulmonary artery; 17 – Left pulmonary veins; 18 – Pericardium; 19 – Left recurrent laryngeal nerve; 20 – Ligamentum arteriosum (Ductus arteriosus)

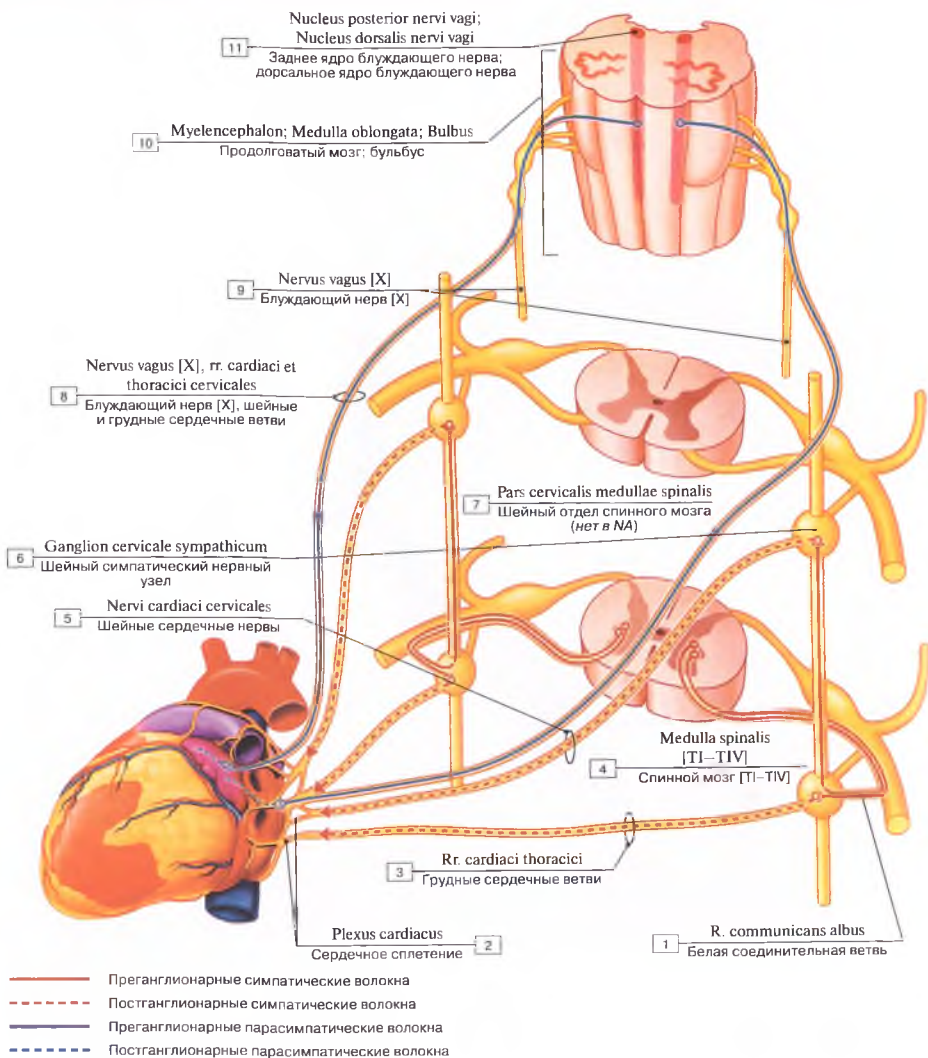


Рис. 403. Эфферентная иннервация сердца симпатическими и парасимпатическими волокнами (схема):

1 — White communicating branch; 2 — Cardiac plexus; 3 — Thoracic cardiac branches; 4 — Spinal cord [T1–TIV]; 5 — Cervical cardiac nerves; 6 — Sympathetic cervical ganglion; 7 — Cervical spinal cord; 8 — Vagus nerve [X], cervical and thoracic cardiac branches; 9 — Vagus nerve; 10 — Myelencephalon; Medulla oblongata; Bulb; 11 — Posterior nucleus of vagus nerve; Dorsal nucleus of vagus nerve

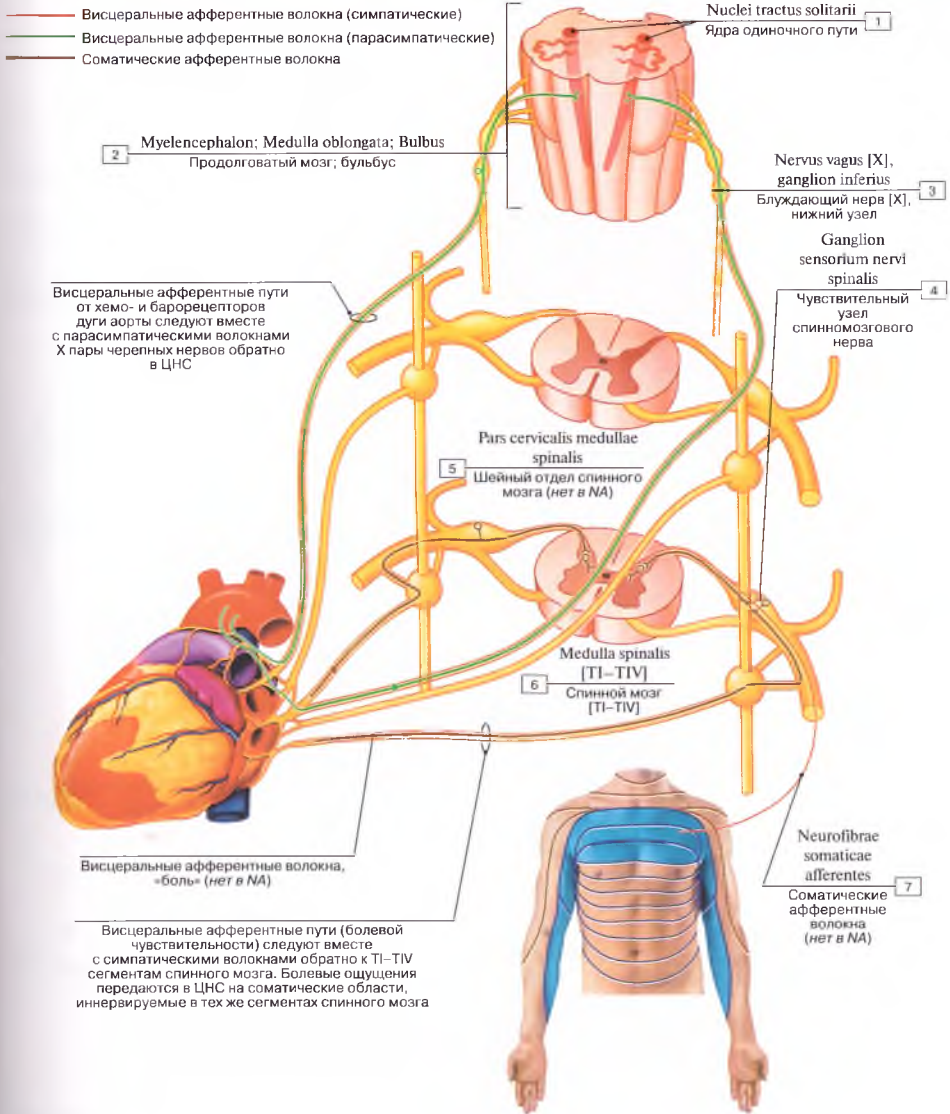


Рис. 404. Чувствительная иннервация сердца (схема):

1 — Nuclei of solitary tract; Solitary nuclei; 2 — Myelencephalon; Medulla oblongata; Bulb; 3 — Vagus nerve [X], inferior ganglion; 4 — Spinal ganglion; Dorsal root ganglion; 5 — Cervical spinal cord; 6 — Spinal cord [T1–TIV]; 7 — Somatic afferent fibres

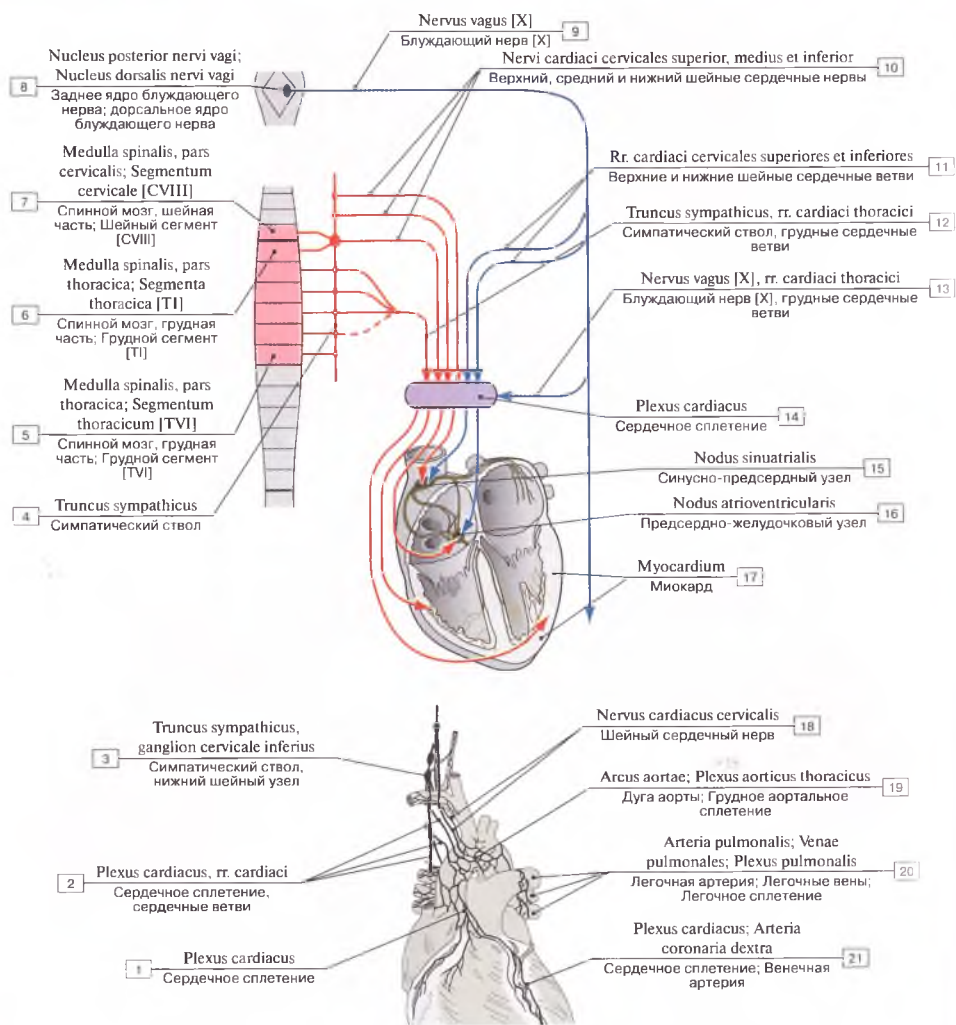


Рис. 405. Симпатическая и парасимпатическая иннервация сердца (схема):

1 – Cardiac plexus; 2 – Cardiac plexus, thoracic cardiac branches; 3 – Sympathetic trunk, inferior cervical ganglion; 4 – Sympathetic trunk; 5 – Spinal cord, thoracic part; Thoracic segment [TVI]; 6 – Spinal cord, thoracic part; Thoracic segment [T1]; 7 – Spinal cord, cervical part; Cervical segment [CVIII]; 8 – Posterior nucleus of vagus nerve; Dorsal nucleus of vagus nerve; 9 – Vagus nerve [X]; 10 – Superior, middle and inferior cervical cardiac nerves; 11 – Superior and inferior cervical cardiac branches; 12 – Sympathetic trunk, thoracic cardiac branches; 13 – Vagus nerve [X], thoracic cardiac branches; 14 – Cardiac plexus; 15 – Sinu-atrial node; 16 – Atrioventricular node; 17 – Myocardium; 18 – Cervical cardiac nerve; 19 – Arch of aorta; Thoracic aortic plexus; 20 – Pulmonary artery; Pulmonary veins; Pulmonary plexus; 21 – Cardiac plexus; Coronary artery



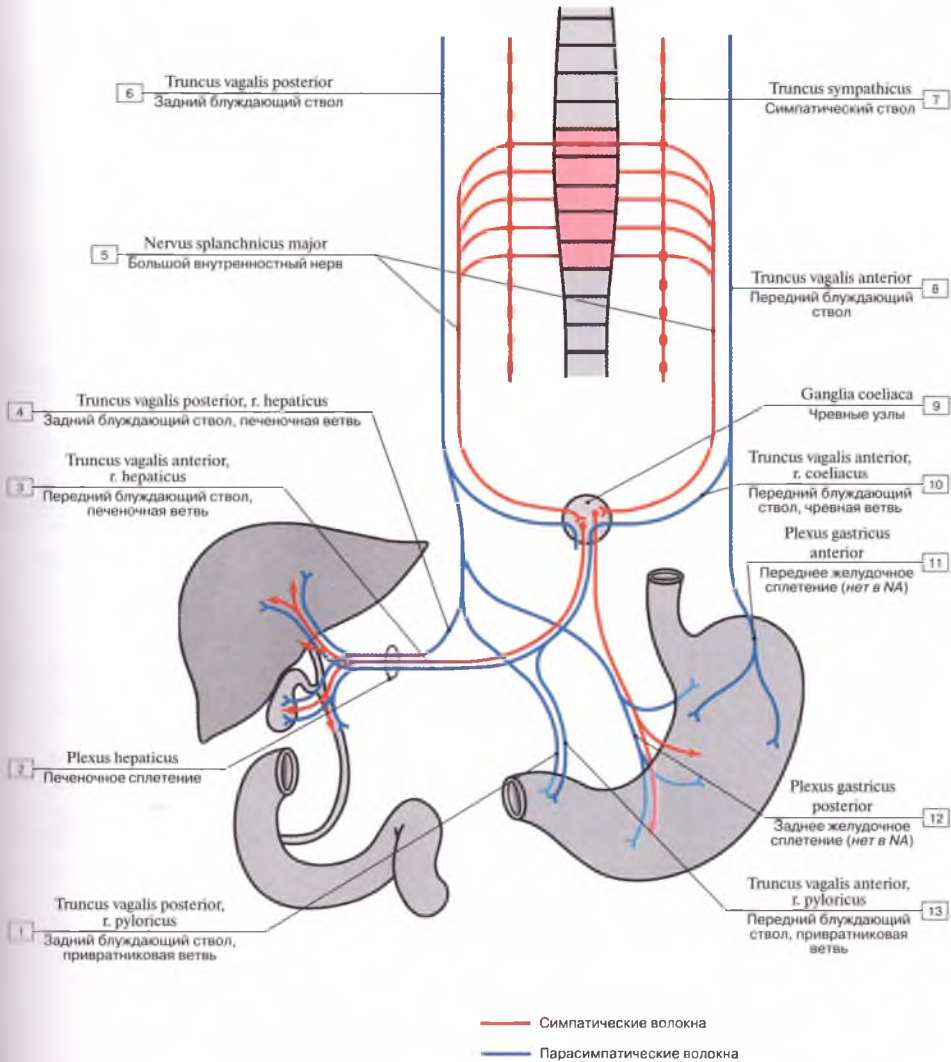


Рис. 406. Симпатическая и парасимпатическая иннервация печени, желчного пузыря, желудка, кишечника (схема):

1 - Posterior vagal trunk, pyloric branch; 2 - Hepatic plexus; 3 - Anterior vagal trunk, hepatic branch; 4 - Posterior vagal trunk, hepatic branch; 5 - Greater splanchnic nerve; 6 - Posterior vagal trunk; 7 - Sympathetic trunk; 8 - Anterior vagal trunk; 9 - Coeliac ganglia; 10 - Anterior vagal trunk, coeliac branch; 11 - Anterior gastric plexus; 12 - Posterior gastric plexus; 13 - Anterior vagal trunk, pyloric branch

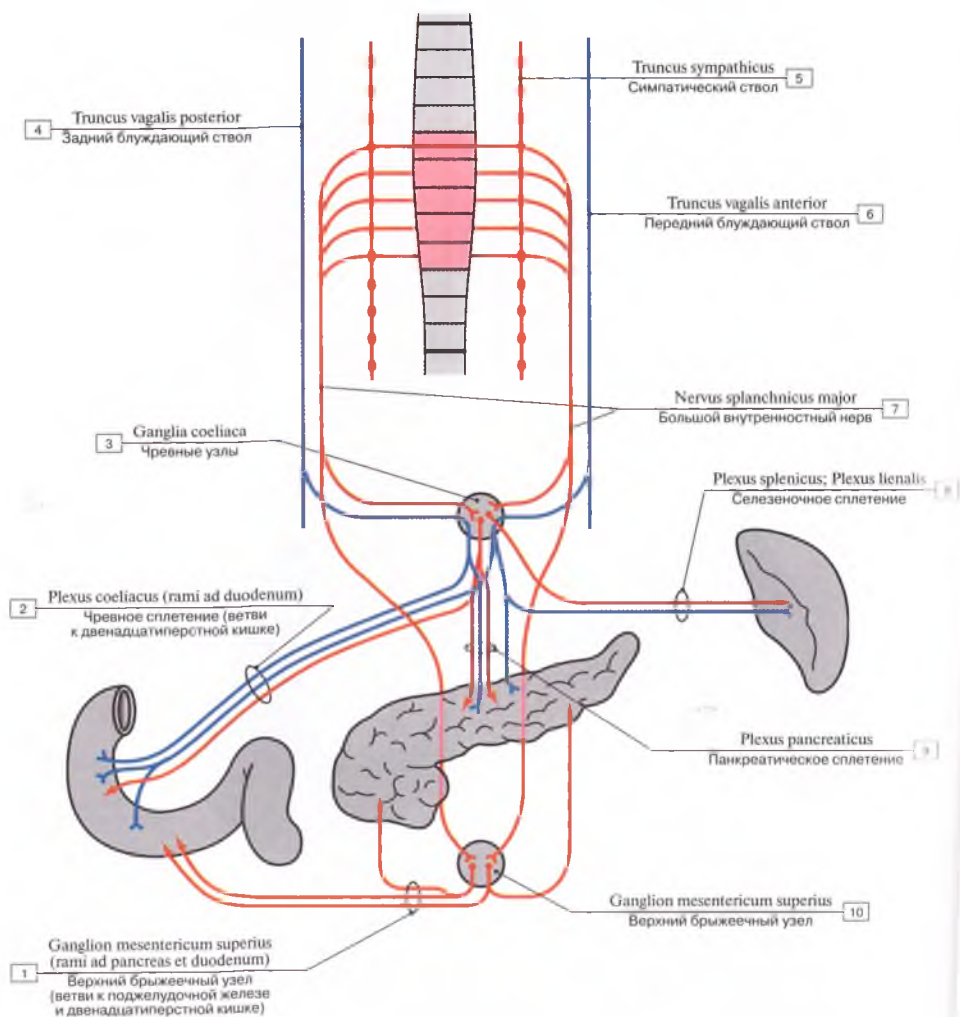


Рис. 407. Симпатическая и парасимпатическая иннервация поджелудочной железы, двенадцатиперстной кишки и селезенки (схема):

1 – Superior mesenteric ganglion (branches to pancreas and duodenum); 2 – Coeliac plexus (branches to duodenum); 3 – Coeliac ganglion; 4 – Posterior vagal trunk; 5 – Sympathetic trunk; 6 – Anterior vagal trunk; 7 – Greater splanchnic nerve; 8 – Splenic plexus; 9 – Pancreatic plexus; 10 – Superior mesenteric ganglion

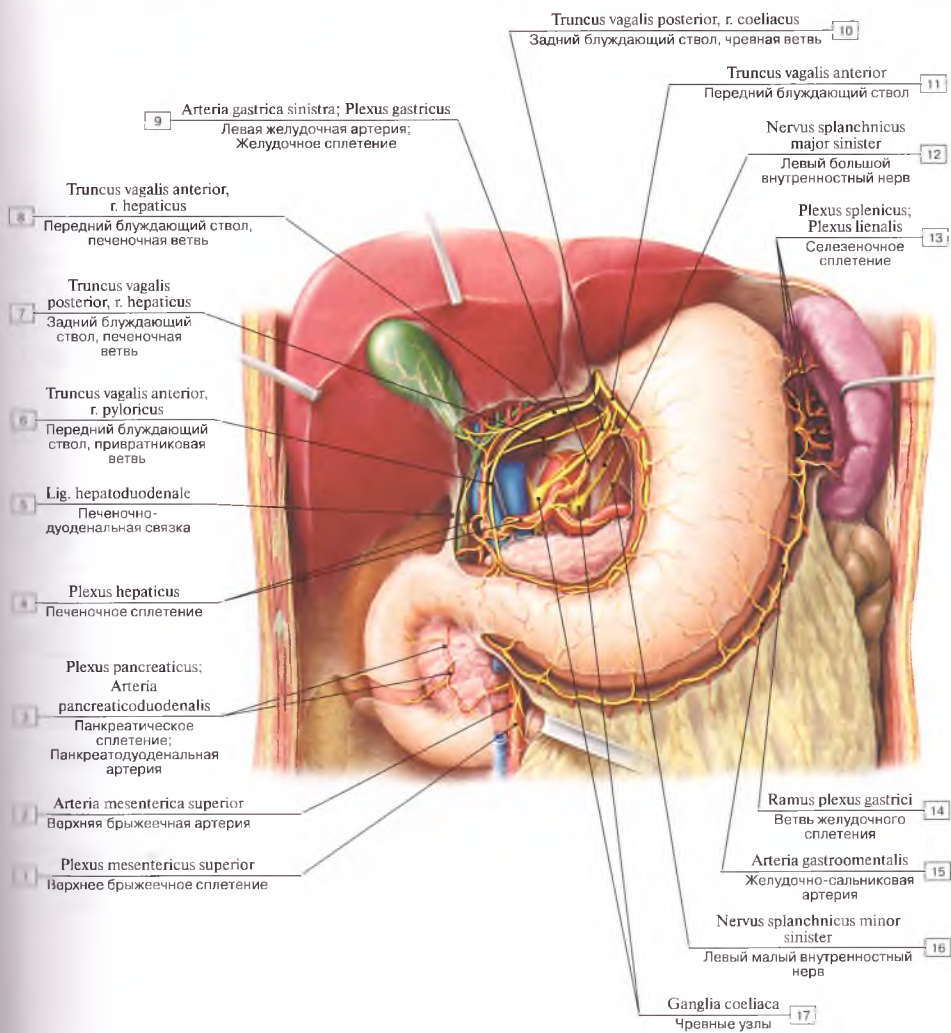


Рис. 408. Иннервация печени, желчного пузыря, желудка, двенадцатиперстной кишки, поджелудочной железы и селезенки, вид спереди:

1 – Superior mesenteric plexus; 2 – Superior mesenteric artery; 3 – Pancreatic plexus; Pancreaticoduodenal artery; 4 – Hepatic plexus; 5 – Hepatoduodenal ligament; 6 – Anterior vagal trunk, pyloric branch; 7 – Posterior vagal trunk, hepatic branch; 8 – Anterior vagal trunk, hepatic branch; 9 – Left gastric artery; Gastric plexus; 10 – Posterior vagal trunk, coeliac branch; 11 – Anterior vagal trunk, pyloric branch; 12 – Left greater splanchnic nerve; 13 – Splenic plexus; 14 – Branch of gastric plexus; 15 – Gastro-omental artery; Gastro-epiploic artery; 16 – Left lesser splanchnic nerve; 17 – Coeliac ganglia

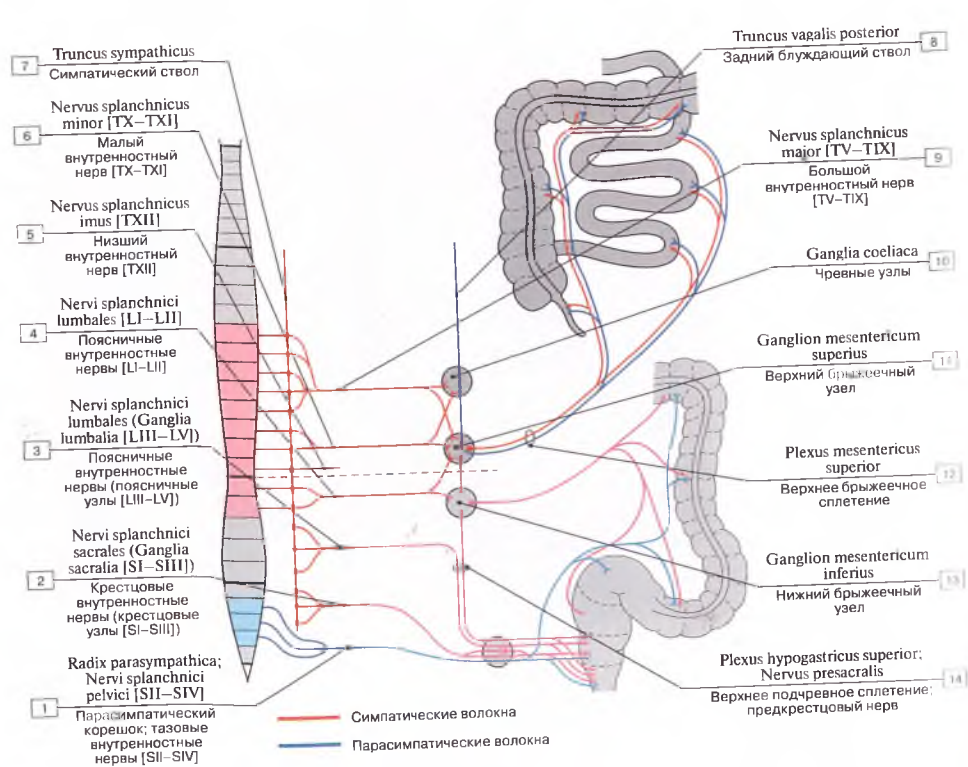


Рис. 409. Симпатическая и парасимпатическая иннервация кишечника ветвями верхнего и нижнего брыжеечного сплетений (схема):

1 – Parasympathetic root; Pelvic splanchnic nerves [SII–SIV]; 2 – Sacral splanchnic nerves (Sacral ganglia [SI–SIII]); 3 – Lumbar splanchnic nerves (Lumbar ganglia [LIII–LV]); 4 – Lumbar splanchnic nerves [LI–LII]; 5 – Least splanchnic nerve; Lowest splanchnic nerve [TXII]; 6 – Lesser splanchnic nerve [TX–TXI]; 7 – Sympathetic trunk; 8 – Posterior vagal trunk; 9 – Greater splanchnic nerve [TV–TIX]; 10 – Coeliac ganglia; 11 – Superior mesenteric ganglion; 12 – Superior mesenteric plexus; 13 – Inferior mesenteric ganglion; 14 – Superior hypogastric plexus; Presacral nerve

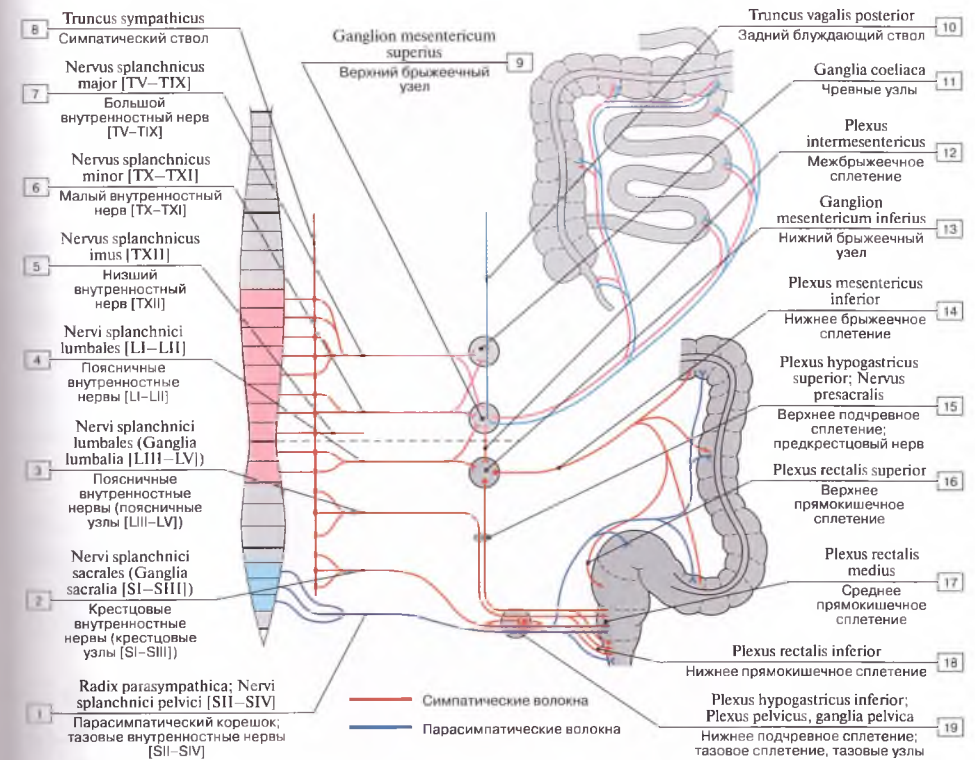


Рис. 410. Вегетативная иннервация кишечника ветвями верхнего и нижнего брыжеечного сплетений (схема):

1 – Parasympathetic root; Pelvic splanchnic nerves [SII–SIV]; 2 – Sacral splanchnic nerves (Sacral ganglia [SI–SIII]); 3 – Lumbar splanchnic nerves (Lumbar ganglia [LIII–LV]); 4 – Lumbar splanchnic nerves [LI–LII]; 5 – Least splanchnic nerve; Lowest splanchnic nerve [TXII]; 6 – Lesser splanchnic nerve [TX–TXI]; 7 – Greater splanchnic nerve [TV–TIX]; 8 – Sympathetic trunk; 9 – Superior mesenteric ganglion; 10 – Posterior vagal trunk; 11 – Coeliac ganglia; 12 – Intermesenteric plexus; 13 – Inferior mesenteric ganglion; 14 – Inferior mesenteric plexus; 15 – Superior hypogastric plexus; Presacral nerve; 16 – Superior rectal plexus; 17 – Middle rectal plexus; 18 – Inferior rectal plexus; 19 – Inferior hypogastric plexus; Pelvic plexus, pelvic ganglia

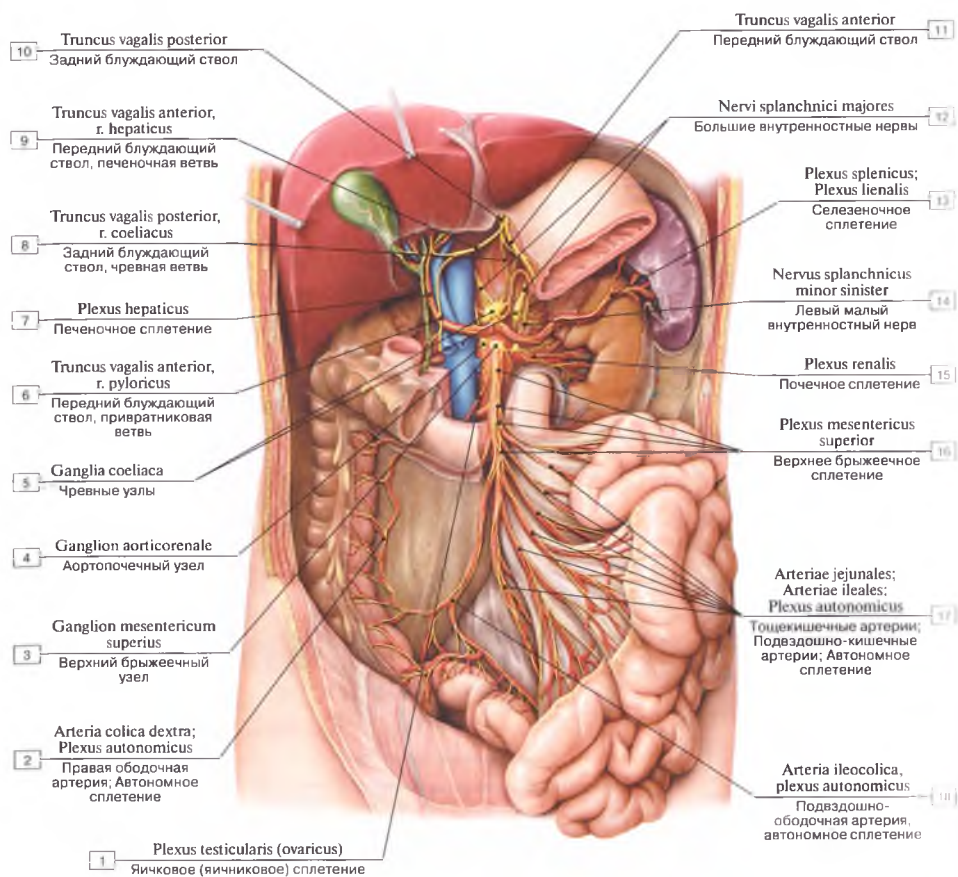


Рис. 411. Вегетативная иннервация кишечника ветвями верхнего и брыжеечного сплетений:

1 – Testicular (ovarian) plexus; 2 – Right colic artery, autonomic plexus; 3 – Superior mesenteric ganglion; 4 – Aorticorenal ganglion; 5 – Coeliac ganglia; 6 – Anterior vagal trunk; Pyloric branch; 7 – Hepatic plexus; 8 – Posterior vagal trunk, coeliac branch; 9 – Anterior vagal trunk, hepatic branch; 10 – Posterior vagal trunk; 11 – Anterior vagal trunk; 12 – Greater splanchnic nerves; 13 – Splenic plexus; 14 – Left lesser splanchnic nerve; 15 – Renal plexus; 16 – Superior mesenteric plexus; 17 – Jejunal arteries; Ileal arteries; Autonomic plexus; 18 – Ileocolic artery, autonomic plexus

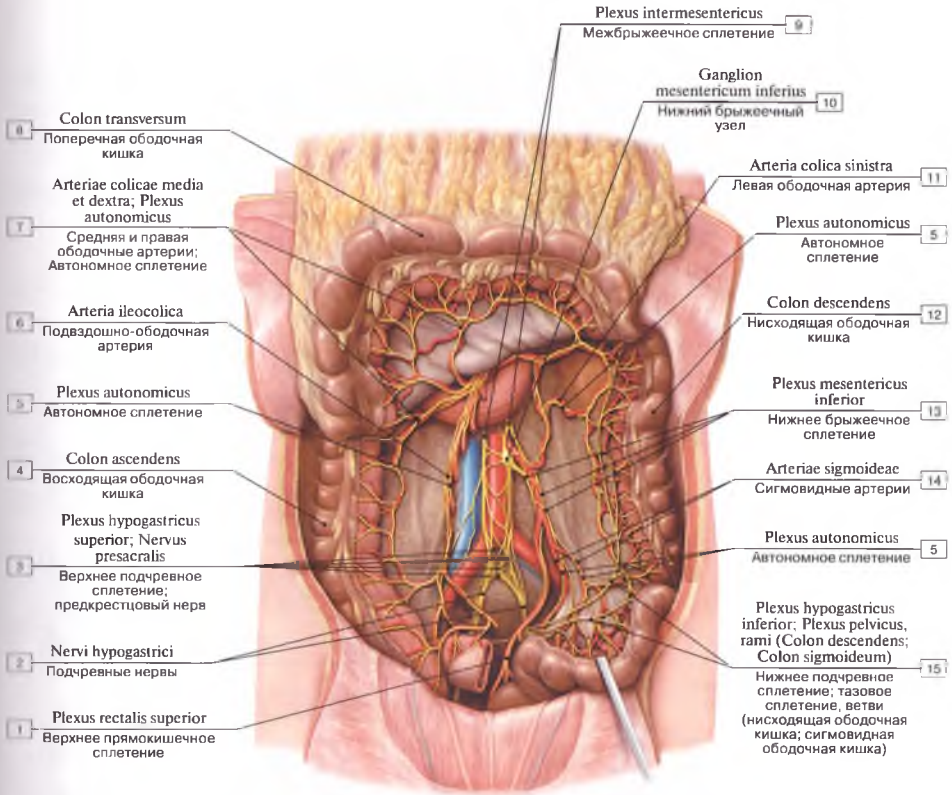


Рис. 412. Вегетативная иннервация толстой кишки ветвями верхнего и нижнего брыжеечного сплетений:

- 1 – Superior rectal plexus; 2 – Hypogastric nerves; 3 – Superior hypogastric plexus; Presacral nerve; 4 – Ascending colon; 5 – Autonomic plexus; 6 – Ileocolic artery; 7 – Middle and right colic arteries; Autonomic plexus; 8 – Transverse colon; 9 – Intermesenteric plexus; 10 – Inferior mesenteric ganglion; 11 – Left colic artery; 12 – Descending colon; 13 – Inferior mesenteric plexus; 14 – Sigmoid arteries; 15 – Inferior hypogastric plexus; Pelvic plexus, branches (Descending colon; Sigmoid colon)

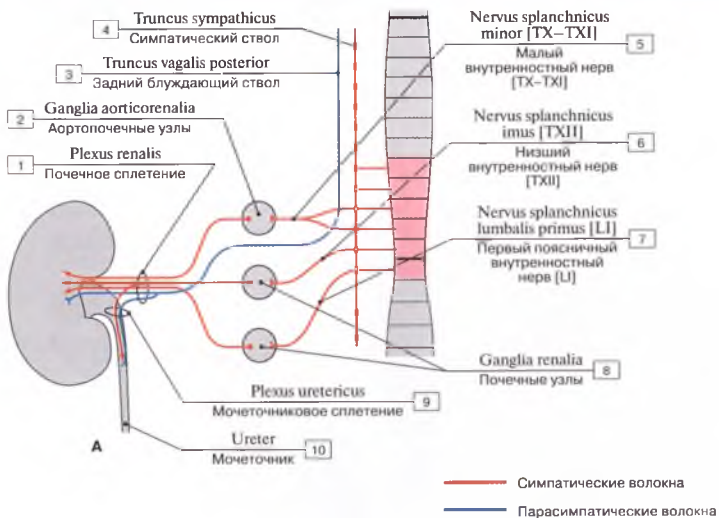
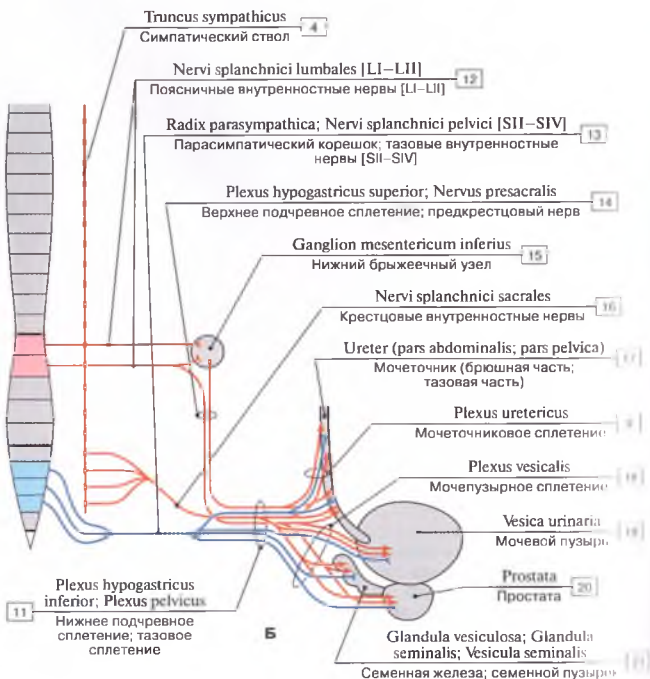


Рис. 413. Симпатическая и парасимпатическая иннервация почек (А), мочевого пузыря и мочеточников (Б) (схема):

1 – Renal plexus; 2 – Aorticorenal ganglia; 3 – Posterior vagal trunk; 4 – Sympathetic trunk; 5 – Lesser splanchnic nerve [TX–TXI]; 6 – Least splanchnic nerve; 7 – First lumbar splanchnic nerve [LI]; 8 – Renal ganglia; 9 – Ureteric plexus; 10 – Ureter; 11 – Inferior hypogastric plexus; Pelvic plexus; 12 – Lumbar splanchnic nerves [LI–LII]; 13 – Parasympathetic root; Pelvic splanchnic nerves [SII–SIV]; 14 – Superior hypogastric plexus; Presacral nerve; 15 – Inferior mesenteric ganglion; 16 – Sacral splanchnic nerves; 17 – Ureter (abdominal part; pelvic part); 18 – Vesical plexus; 19 – Urinary bladder; 20 – Prostate; 21 – Seminal gland; Seminal vesicle



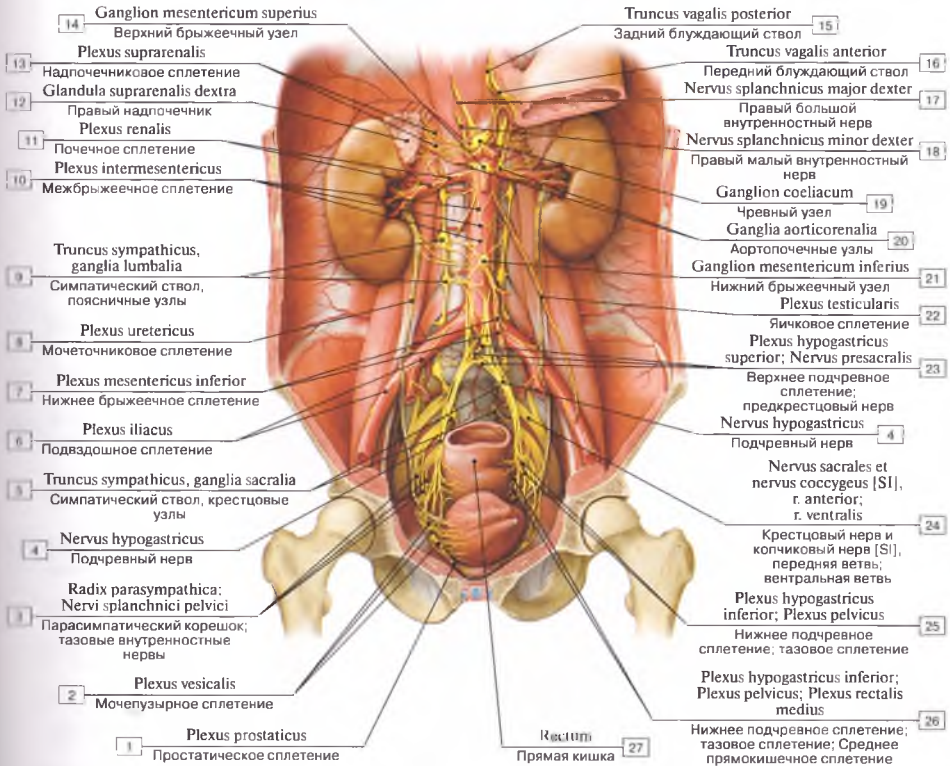


Рис. 414. Вегетативная иннервация мочевых органов и надпочечников мужчины, вид спереди:

1 – Prostatic plexus; 2 – Vesical plexus; 3 – Parasympathetic root; Pelvic splanchnic nerves; 4 – Hypogastric nerve; 5 – Sympathetic trunk, lumbar ganglia; 6 – Iliac plexus; 7 – Inferior mesenteric plexus; 8 – Ureteric plexus; 9 – Sympathetic trunk, lumbar ganglia; 10 – Intermesenteric plexus; 11 – Renal plexus; 12 – Right suprarenal gland; Right adrenal gland; 13 – Suprarenal plexus; 14 – Superior mesenteric ganglion; 15 – Posterior vagal trunk; 16 – Anterior vagal trunk; 17 – Right greater splanchnic nerve; 18 – Right lesser splanchnic nerve; 19 – Coeliac ganglion; 20 – Aorticorenal ganglia; 21 – Inferior mesenteric ganglion; 22 – Testicular plexus; 23 – Superior hypogastric plexus; Presacral plexus; 24 – Sacral nerve and coccygeal nerve [SI], anterior branch; ventral branch; 25 – Inferior hypogastric plexus; Pelvic plexus; Middle rectal plexus; 26 – Inferior hypogastric plexus; Pelvic plexus; Middle rectal plexus; 27 – Rectum



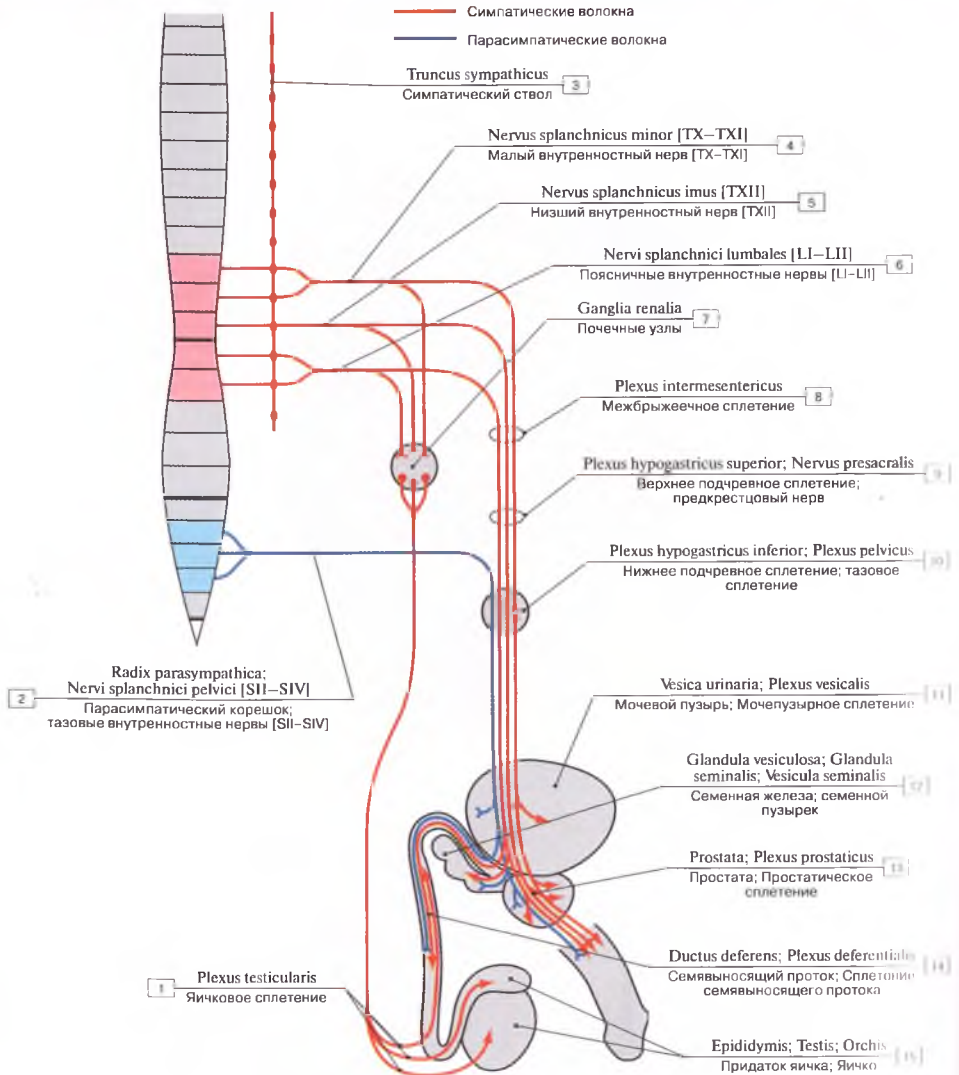


Рис. 415. Симпатическая и парасимпатическая иннервация мужских половых органов:

1 – Testicular plexus; 2 – Parasympathetic root; Pelvic splanchnic nerves [SII–SIV]; 3 – Sympathetic trunk; 4 – Lesser splanchnic nerve [TX–TXI]; 5 – Least splanchnic nerve; Lowest splanchnic nerve [TXII]; 6 – Lumbar splanchnic nerves [LI–LII]; 7 – Renal ganglia; 8 – Intermesenteric plexus; 9 – Superior hypogastric plexus; Presacral nerve; 10 – Inferior hypogastric plexus; Pelvic plexus; 11 – Urinary bladder; Vesical plexus; 12 – Seminal gland; Seminal vesicle; 13 – Prostate; Prostatic plexus; 14 – Ductus deferens; Vas deferens; Deferential plexus; 15 – Epididymis; Testis

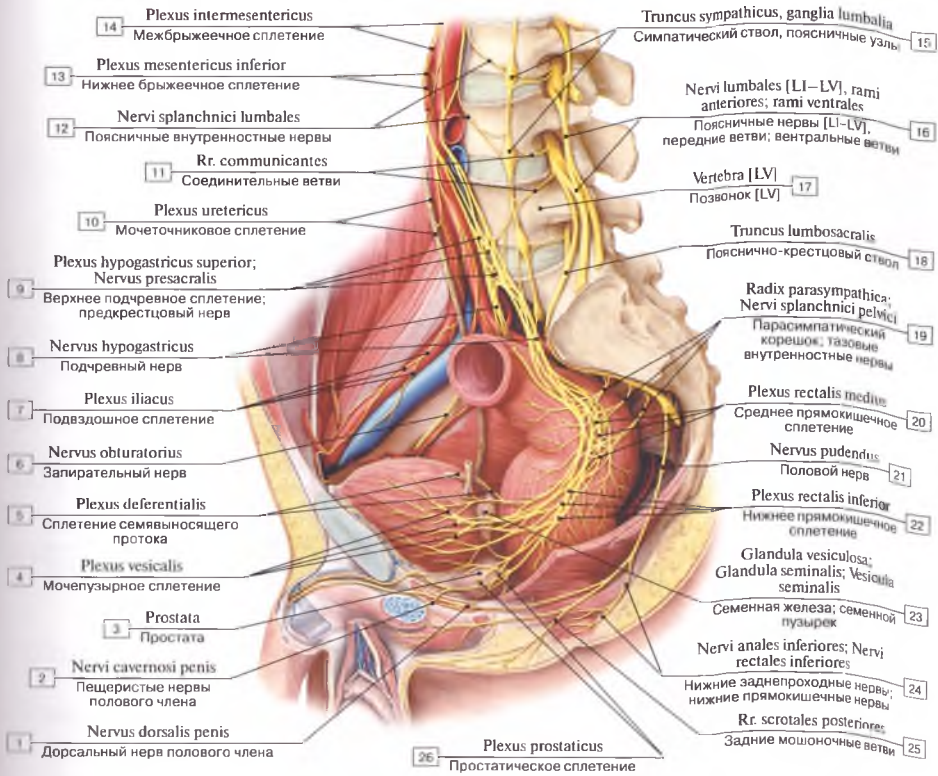


Рис. 416. Вегетативная иннервация мужских половых органов:

1 – Dorsal nerve of penis; 2 – Cavernous nerves of penis; 3 – Prostate; 4 – Vesical plexus; 5 – Deferential plexus; Plexus of ductus deferens; 6 – Obturator nerve; 7 – Iliac plexus; 8 – Hypogastric nerve; 9 – Superior hypogastric plexus; Presacral nerve; 10 – Ureteric plexus; 11 – Communicating branches; 12 – Lumbar splanchnic nerves; 13 – Inferior mesenteric plexus; 14 – Intermesenteric plexus; 15 – Sympathetic trunk, lumbar ganglia; 16 – Lumbar nerves [LI–LV], anterior branches; ventral branches; 17 – Vertebra [LV]; 18 – Lumbosacral trunk; 19 – Parasympathetic root; Pelvic splanchnic nerves; 20 – Middle rectal plexus; 21 – Pudendal nerve; 22 – Inferior rectal plexus; 23 – Seminal gland; Seminal vesicle; 24 – Inferior anal nerves; Inferior rectal nerves; 25 – Posterior scrotal nerves; 26 – Prostatic plexus

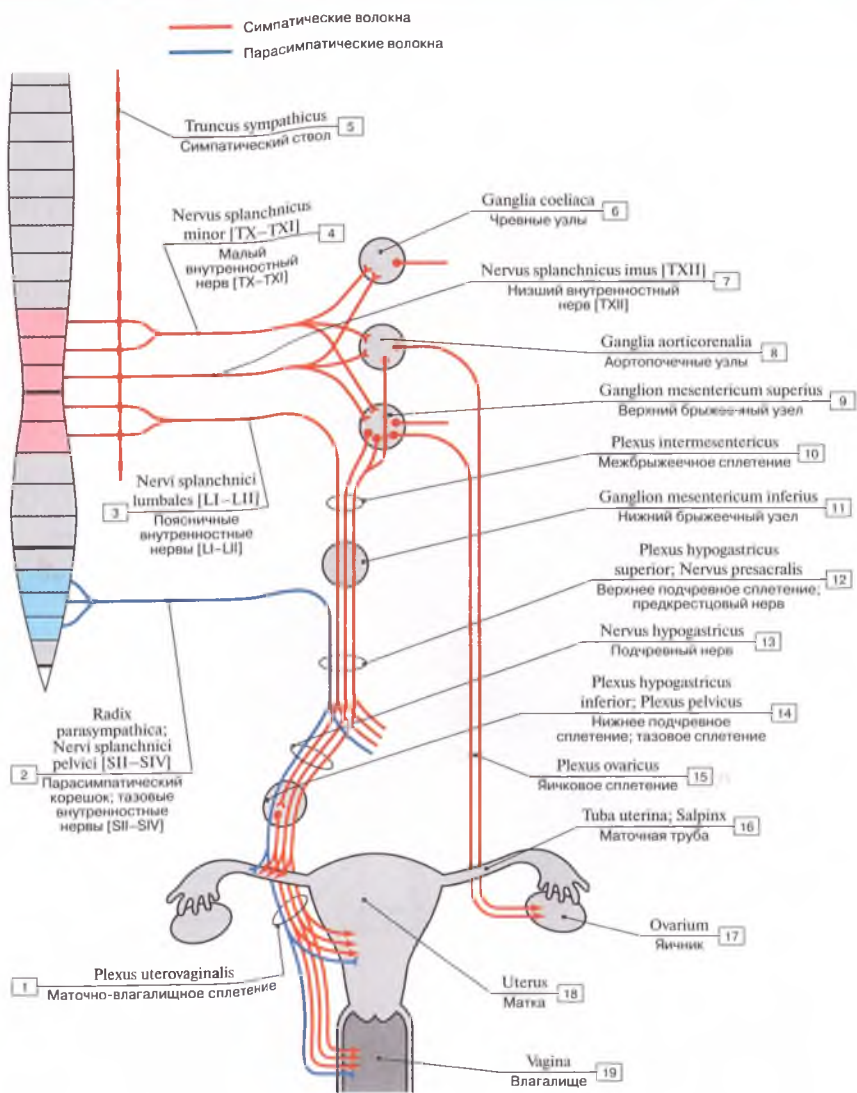


Рис. 417. Симпатическая и парасимпатическая иннервация женских половых органов (схема):

1 — Uterovaginal plexus; 2 — Parasympathetic root; Pelvic splanchnic nerves [SII–SIV]; 3 — Lumbar splanchnic nerves [LI–LII]; 4 — Least splanchnic nerve [TX–TXI]; 5 — Sympathetic trunk; 6 — Coeliac ganglia; 7 — Least splanchnic nerve; Lowest splanchnic nerve [TXII]; 8 — Aorticorenal ganglia; 9 — Superior mesenteric ganglion; 10 — Intermesenteric plexus; 11 — Inferior mesenteric ganglion; 12 — Superior hypogastric plexus; Presacral nerve; 13 — Hypogastric nerve; 14 — Inferior hypogastric plexus; Pelvic plexus; 15 — Ovarian plexus; 16 — Uterine tube; 17 — Ovary; 18 — Uterus; 19 — Vagina

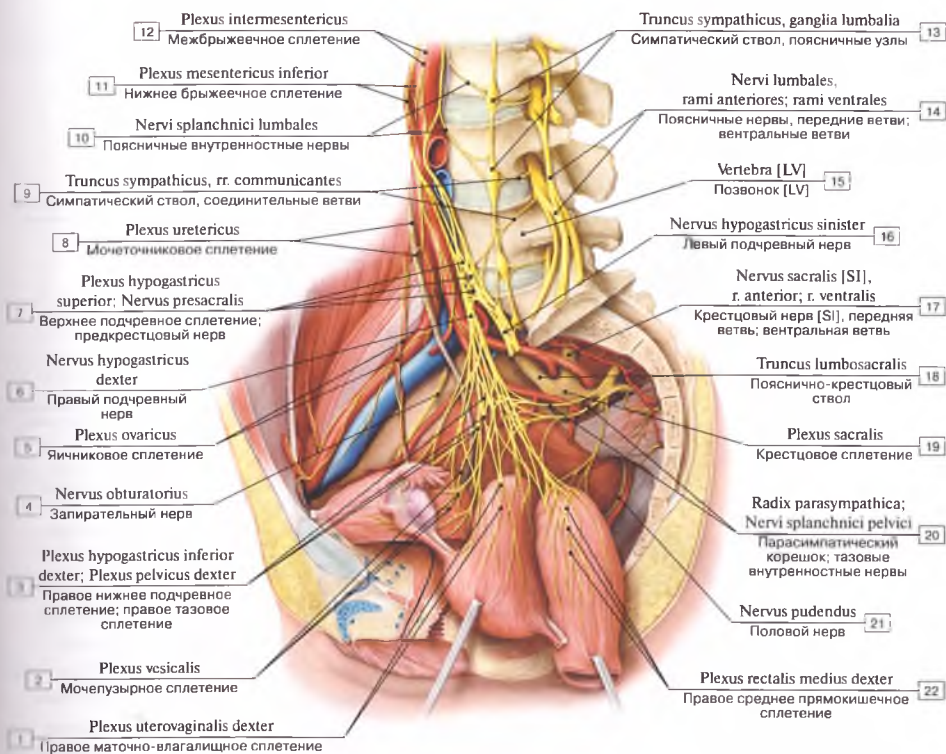


Рис. 418. Вегетативная иннервация женских половых органов:

1 – Right uterovaginal plexus; 2 – Vesical plexus; 3 – Right inferior hypogastric plexus; Right pelvic plexus; 4 – Obturator nerve; 5 – Ovarian plexus; 6 – Right hypogastric nerve; 7 – Superior hypogastric plexus; Presacral nerve; 8 – Ureteric plexus; 9 – Sympathetic trunk, communicating branches; 10 – Lumbar splanchnic nerves; 11 – Inferior mesenteric plexus; 12 – Intermesenteric plexus; 13 – Sympathetic trunk, lumbar ganglia; 14 – Lumbar nerves, anterior branches; ventral branches; 15 – Vertebra [LV]; 16 – Left hypogastric nerve; 17 – Sacral nerve [SI], anterior branch; ventral branch; 18 – Lumbosacral trunk; 19 – Sacral plexus; 20 – Parasympathetic root; Pelvic splanchnic nerves; 21 – Pudendal nerve; 22 – Right middle rectal plexus

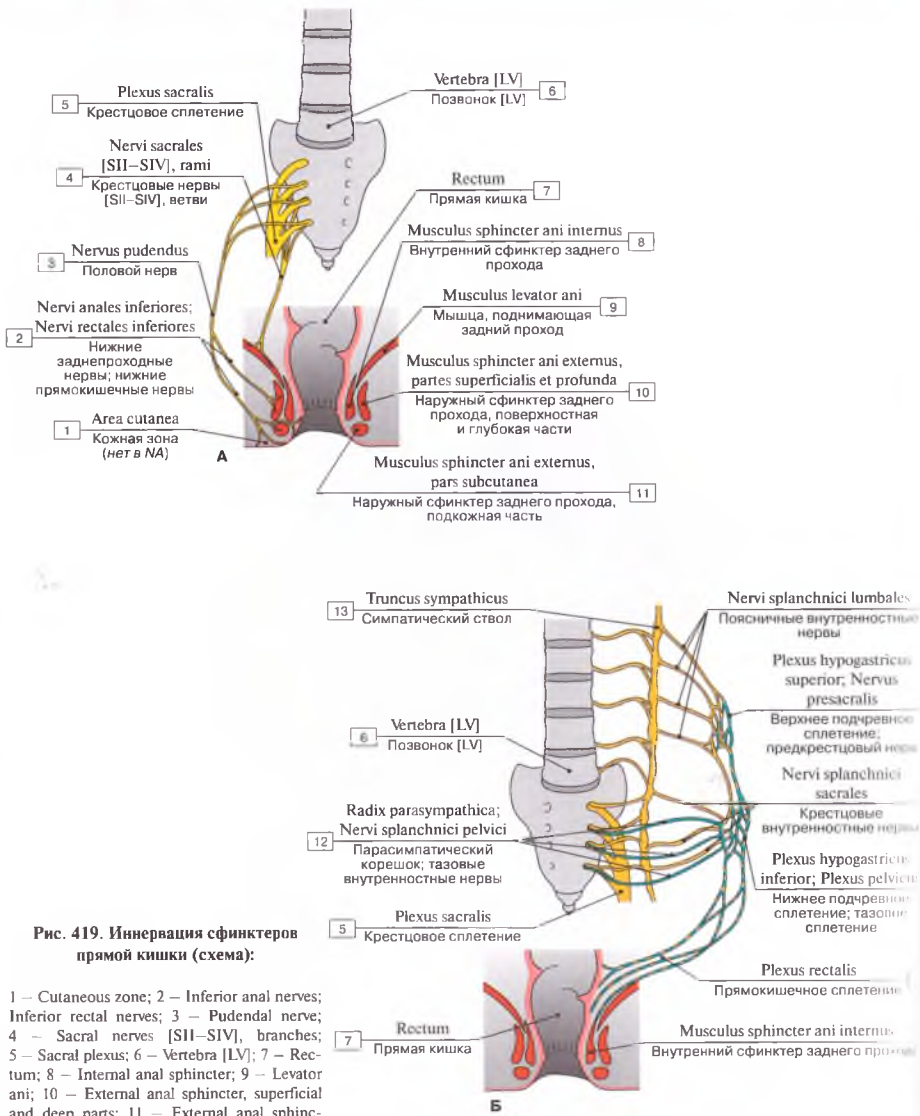


Рис. 419. Иннервация сфинктеров прямой кишки (схема):

1 – Cutaneous zone; 2 – Inferior anal nerves; Inferior rectal nerves; 3 – Pudendal nerve; 4 – Sacral nerves [SII–SIV], branches; 5 – Sacral plexus; 6 – Vertebra [LV]; 7 – Rectum; 8 – Internal anal sphincter; 9 – Levator ani; 10 – External anal sphincter, superficial and deep parts; 11 – External anal sphincter, subcutaneous part; 12 – Parasympathetic root; Pelvic splanchnic nerves; 13 – Sympathetic trunk; 14 – Lumbar splanchnic nerves; 15 – Superior hypogastric plexus; Presacral nerve; 16 – Sacral splanchnic nerves; 17 – Inferior hypogastric plexus; Pelvic plexus; 18 – Rectal plexus

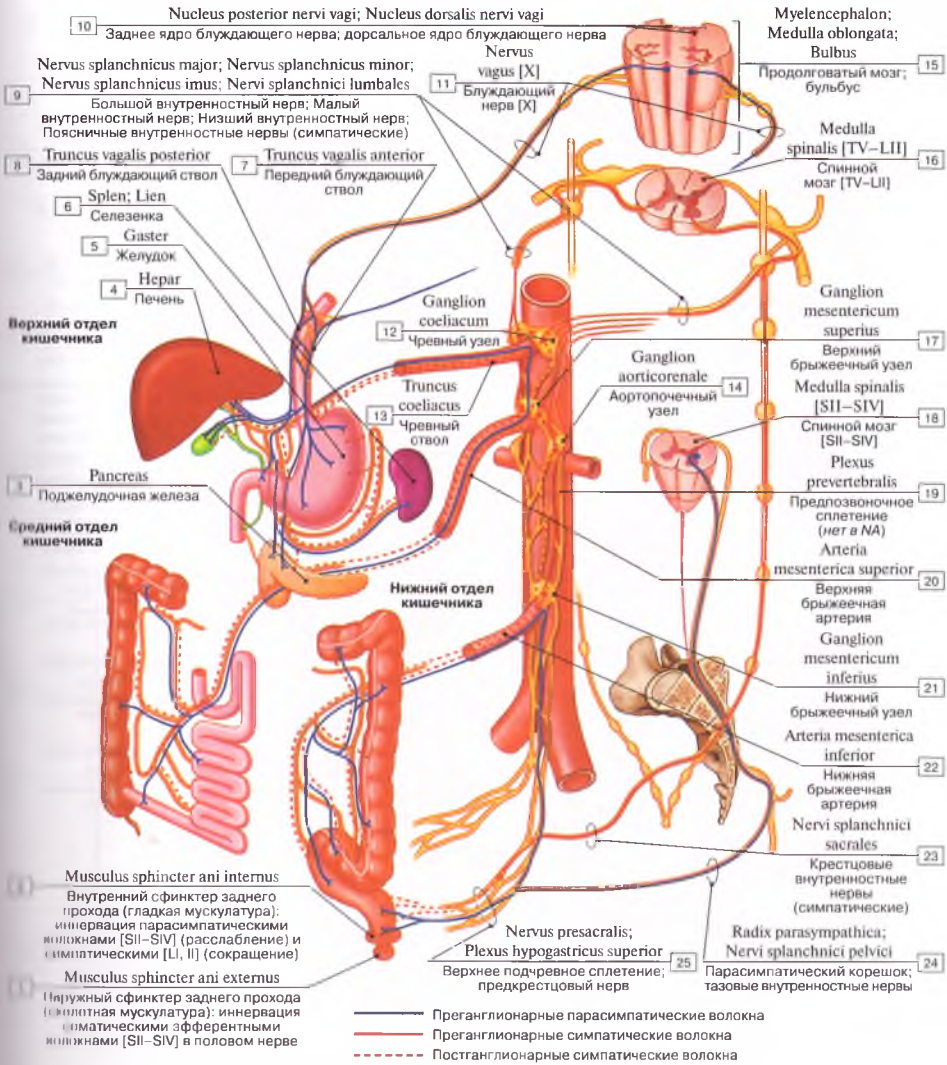


Рис. 420. Эфферентная иннервация органов брюшной полости:

1 — External anal sphincter; 2 — Internal anal sphincter; 3 — Pancreas; 4 — Liver; 5 — Stomach; 6 — Spleen; 7 — Anterior vagal trunk; 8 — Posterior vagal trunk; 9 — Greater splanchnic nerve; Lesser splanchnic nerve; Least splanchnic nerve; Lumbar splanchnic nerves; 10 — Posterior nucleus of vagal nerve; Dorsal nucleus of vagus nerve; 11 — Vagus nerve [X]; 12 — Coeliac ganglion; 13 — Coeliac trunk; 14 — Aorticorenal ganglion; 15 — Myelencephalon; Medulla oblongata; Bulb; 16 — Spinal cord [TV-LII]; 17 — Superior mesenteric ganglion; 18 — Spinal cord [SII-SIV]; 19 — Prevertebral plexus; 20 — Superior mesenteric artery; 21 — Inferior mesenteric ganglion; 22 — Inferior mesenteric artery; 23 — Sacral splanchnic nerves; 24 — Parasymphathetic root; Pelvic splanchnic nerves; 25 — Superior hypogastric plexus; Presacral nerve

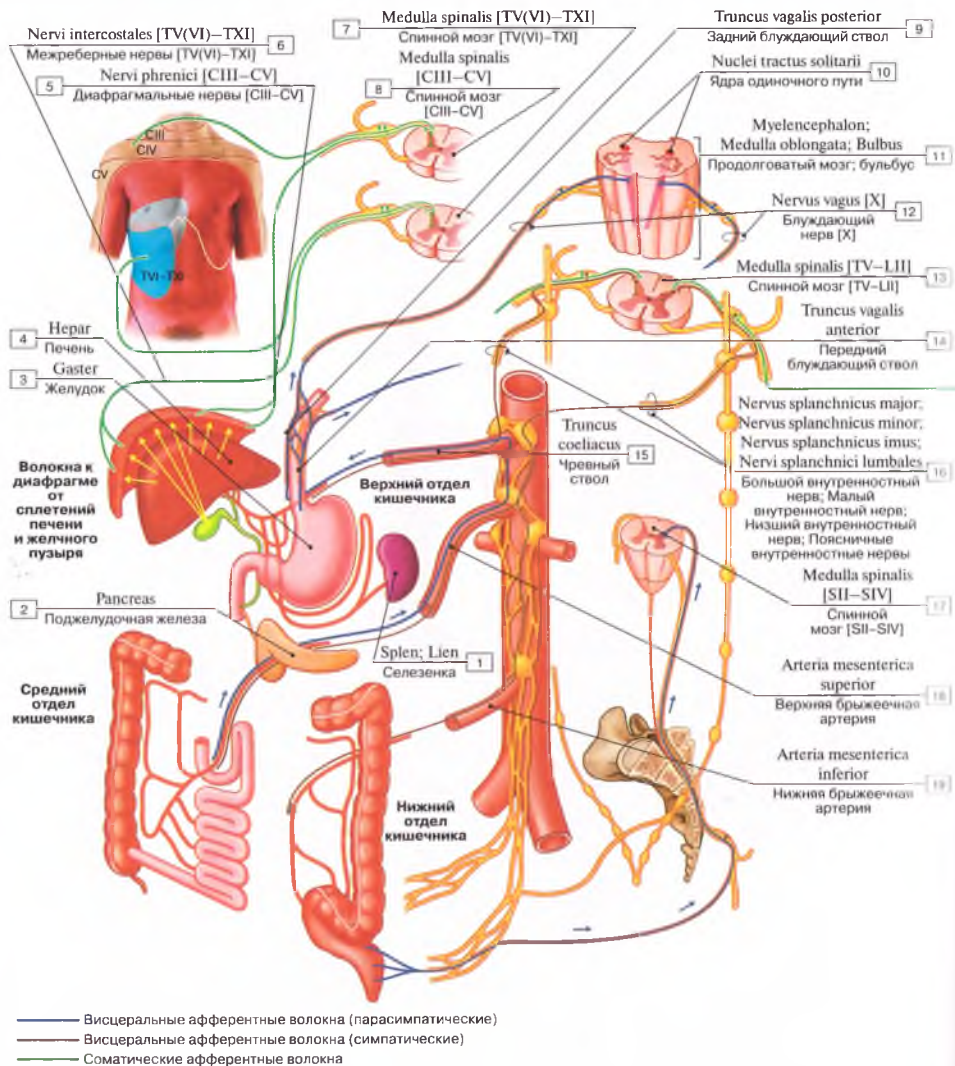
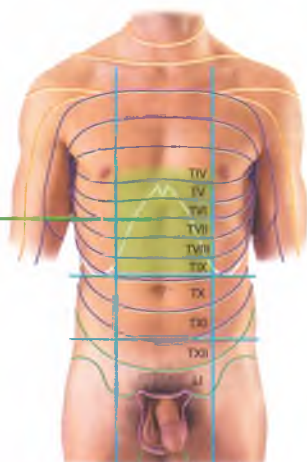
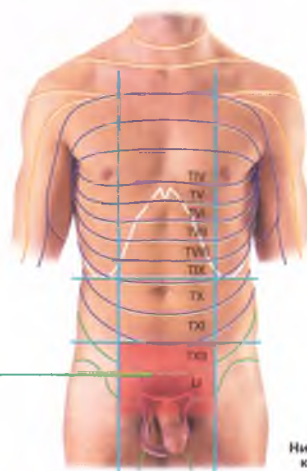


Рис. 421. Афферентная иннервация органов брюшной полости:

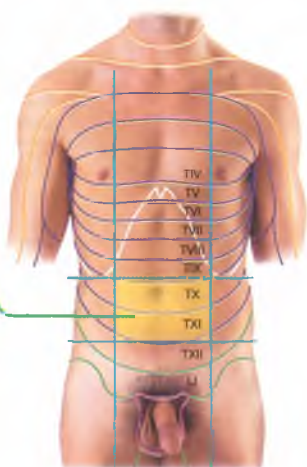
1 — Spleen; 2 — Pancreas; 3 — Stomach; 4 — Liver; 5 — Phrenic nerves [CIII–CV]; 6 — Intercostal nerves [TV(VI)–TXI]; 7 — Spinal cord [TV(VI)–TXI]; 8 — Spinal cord [CIII–CV]; 9 — Posterior vagal trunk; 10 — Nuclei of solitary tract; Solitary nuclei; 11 — Myelencephalon; Medulla oblongata; Bulb; 12 — Vagus nerve [X]; 13 — Spinal cord [TV–LII]; 14 — Anterior vagal trunk; 15 — Coeliac trunk; 16 — Greater splanchnic nerve; Lesser splanchnic nerve; Least splanchnic nerve; Lumbar splanchnic nerves; 17 — Spinal cord [SII–SIV]; 18 — Superior mesenteric artery; 19 — Inferior mesenteric artery



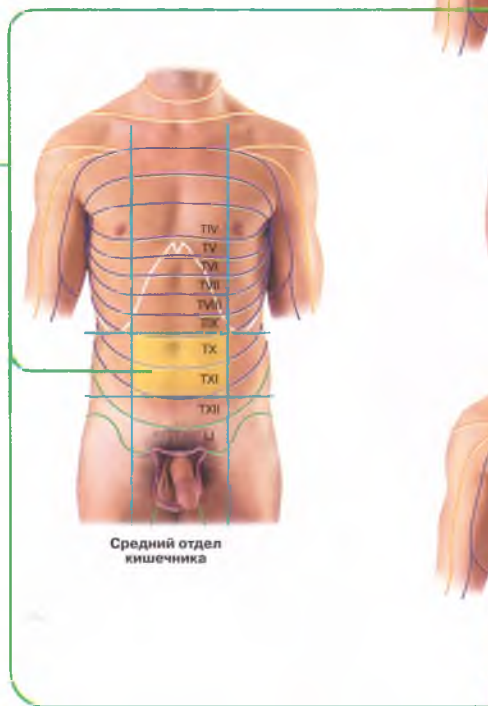
Верхний отдел  
кишечника



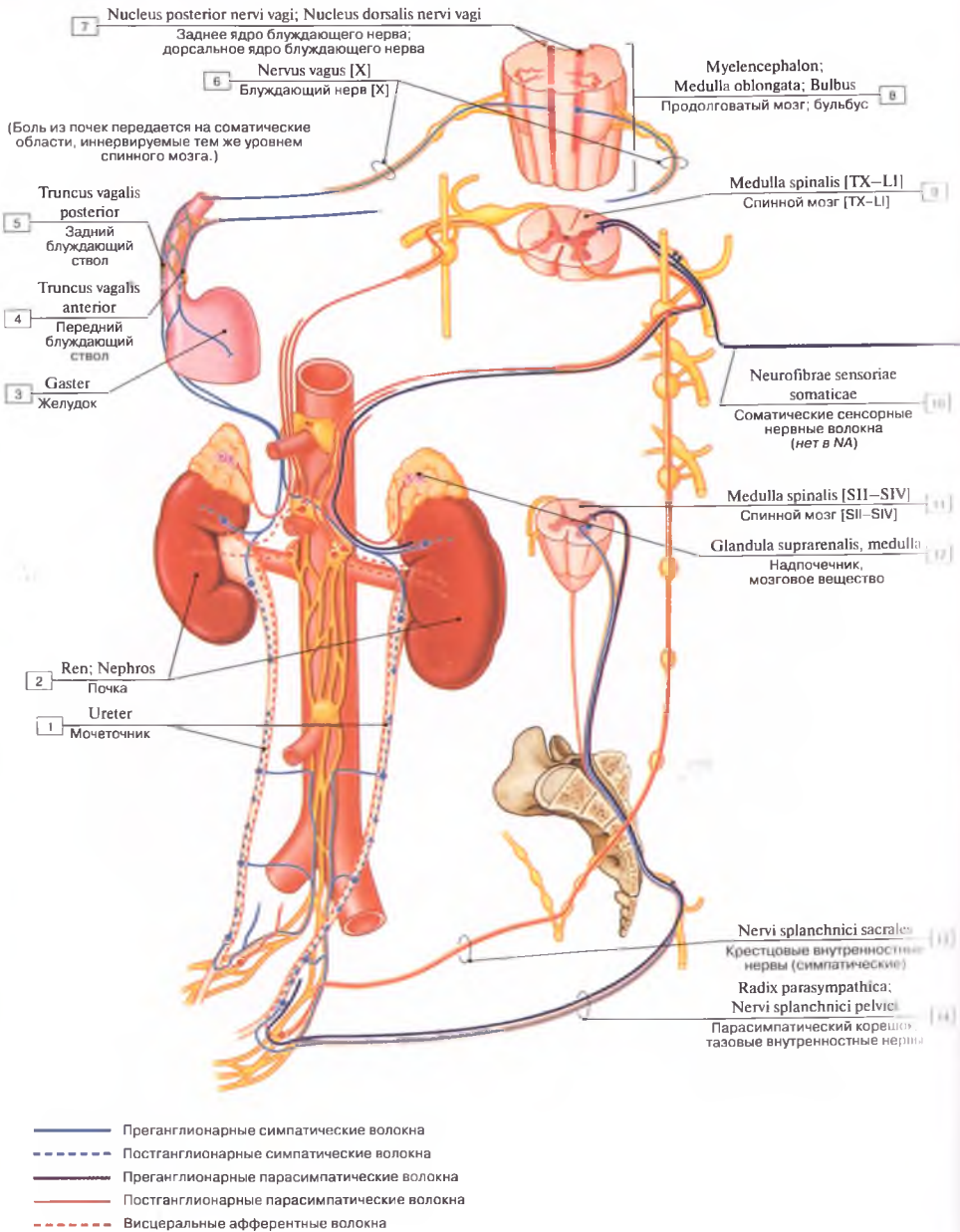
Нижний отдел  
кишечника

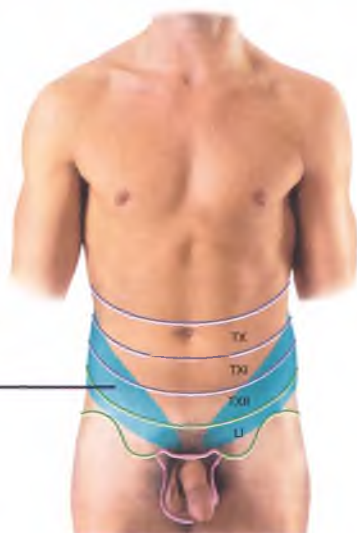

Средний отдел  
кишечника









Дерматомы  
TX-LI

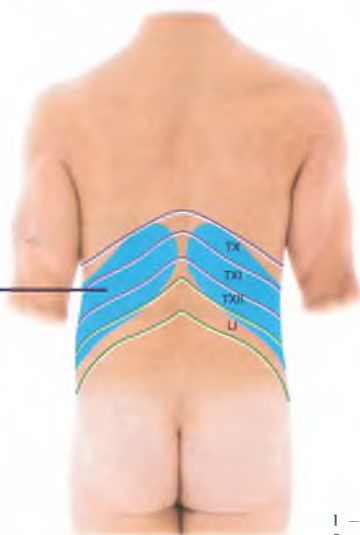

Рис. 422. Аfferентная иннервация внутренних органов:

- 1 – Ureter; 2 – Kidney; 3 – Stomach; 4 – Anterior vagal trunk;  
 5 – Posterior vagal trunk; 6 – Vagus nerve [X]; 7 – Posterior nucleus of  
 vagus nerve; Dorsal nucleus of vagus nerve; 8 – Myelencephalon; Medulla  
 oblongata; Bulb; 9 – Spinal cord [TX–LI]; 10 – Somatic sensory nerve  
 fibres; 11 – Spinal cord [SII–SIV]; 12 – Suprarenal gland; Adrenal gland,  
 medulla; 13 – Sacral splanchnic nerves; 14 – Parasympathetic root; Pelvic  
 splanchnic nerves

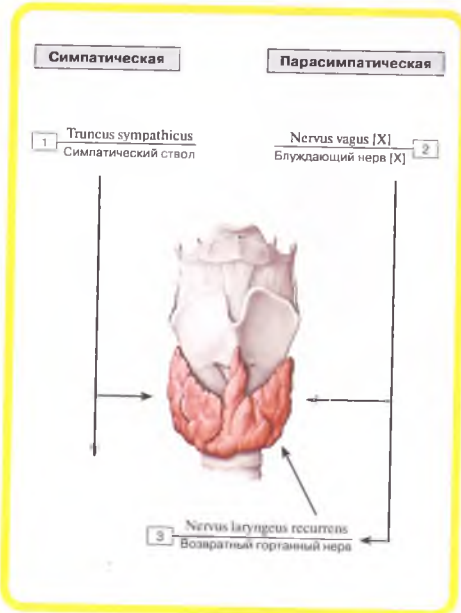
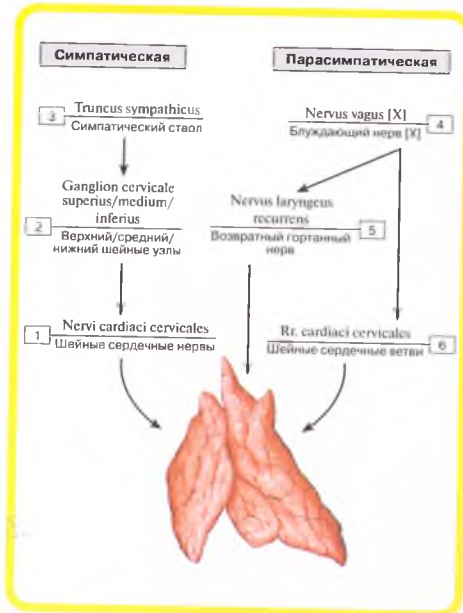


Рис. 423. Иннервация тимуса:

1 – Cervical cardiac nerves; 2 – Superior/middle/inferior cervical ganglia; 3 – Sympathetic trunk; 4 – Vagus nerve [X]; 5 – Recurrent laryngeal nerve; 6 – Cervical cardiac branches

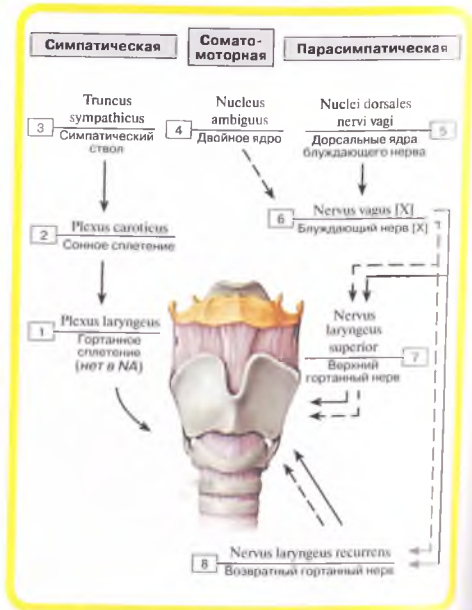


Рис. 424. Иннервация гортани:

1 – Laryngeal plexus; 2 – Carotid plexus; 3 – Sympathetic trunk; 4 – Nucleus ambiguus; 5 – Dorsal nuclei of vagus nerve; 6 – Vagus nerve [X]; 7 – Superior laryngeal nerve; 8 – Recurrent laryngeal nerve

Рис. 425. Иннервация щитовидной железы:

1 – Sympathetic trunk; 2 – Vagus nerve [X]; 3 – Recurrent laryngeal nerve

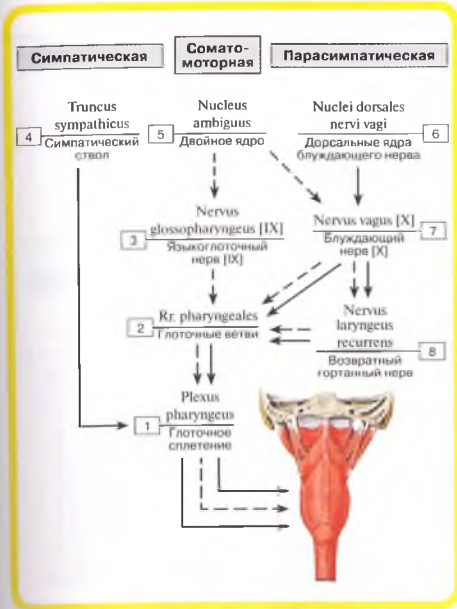


Рис. 426. Иннервация глотки:

1 – Pharyngeal plexus; 2 – Pharyngeal branches; 3 – Glossopharyngeal nerve [IX]; 4 – Sympathetic trunk; 5 – Nucleus ambiguus; 6 – Dorsal nuclei of vagus nerve; 7 – Vagus nerve [X]; 8 – Recurrent laryngeal nerve

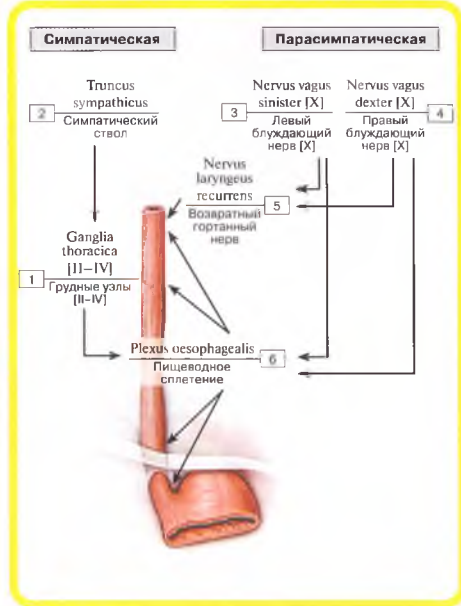
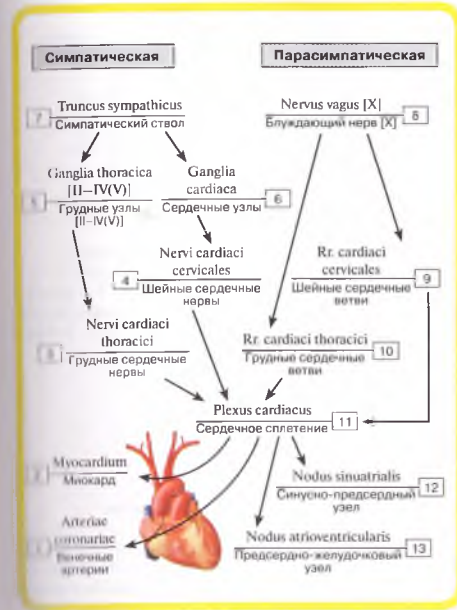
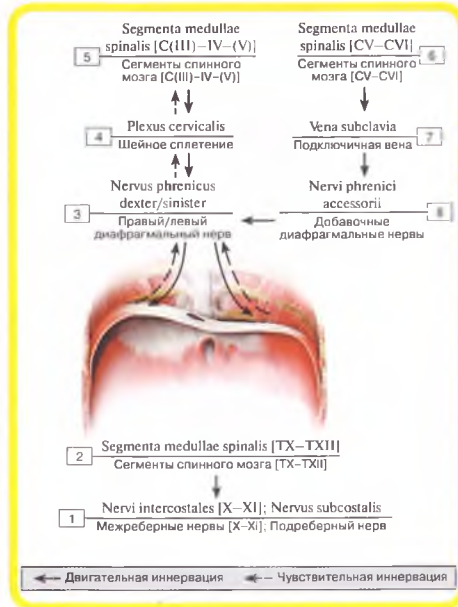
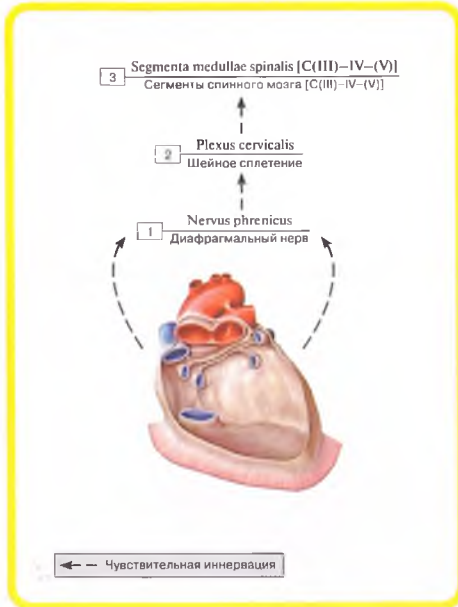


Рис. 427. Иннервация пищевода:

1 – Thoracic ganglia [II–IV]; 2 – Sympathetic trunk; 3 – Left vagus nerve [X]; 4 – Right vagus nerve [X]; 5 – Recurrent laryngeal nerve; 6 – Oesophageal plexus

Рис. 428. Иннервация сердца:

1 – Coronary arteries; 2 – Myocardium; 3 – Thoracic cardiac nerves; 4 – Cervical cardiac nerves; 5 – Thoracic ganglia [II–IV(V)]; 6 – Cardiac ganglia; 7 – Sympathetic trunk; 8 – Vagus nerve [X]; 9 – Cervical cardiac branches; 10 – Thoracic cardiac branches; 11 – Cardiac plexus; 12 – Sinu-atrial node; 13 – Atrioventricular node



← — Рис. 429. Иннервация перикарда:  
1 — Phrenic nerve; 2 — Cervical plexus; 3 — Spinal cord segments [C(III)–IV–(V)]

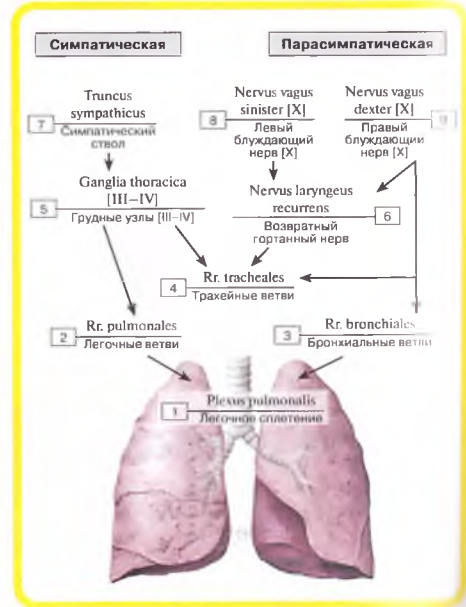
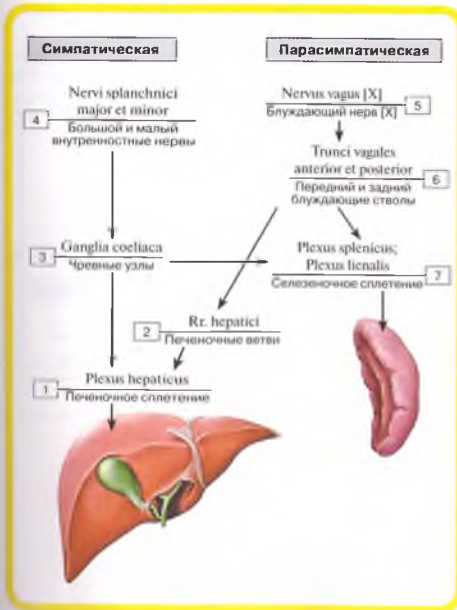


Рис. 430. Иннервация трахеи и легких:

1 — Pulmonary plexus; 2 — Pulmonary branches; 3 — Bronchial branches; 4 — Tracheal branches; 5 — Thoracic ganglia [III–IV]; 6 — Recurrent laryngeal nerve; 7 — Sympathetic trunk; 8 — Left vagus nerve [X]; 9 — Right vagus nerve [X]

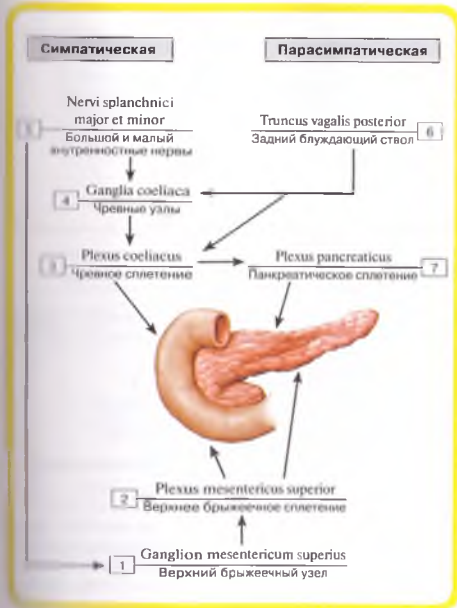
← — Рис. 431. Иннервация диафрагмы:

1 — Intercostal nerves [X–XI]; Subcostal nerve; 2 — Spinal cord segments [TX–TXII]; 3 — Right/left phrenic nerve; 4 — Cervical plexus; 5 — Spinal cord segments [C(III)–IV–(V)]; 6 — Spinal cord segments [CV–CVI]; 7 — Subclavian vein; 8 — Accessory phrenic nerve



← Рис. 432. Иннервация печени, желчного пузыря и селезенки:

- 1 – Hepatic plexus; 2 – Hepatic branches; 3 – Coeliac ganglia; 4 – Greater and lesser splanchnic nerves; 5 – Vagus nerve [X]; 6 – Anterior and posterior vagal trunks; 7 – Splenic plexus



← Рис. 434. Иннервация двенадцатиперстной кишки и поджелудочной железы:

- 1 – Superior mesenteric ganglion; 2 – Superior mesenteric plexus; 3 – Coeliac plexus; 4 – Coeliac ganglia; 5 – Greater and lesser splanchnic nerves; 6 – Posterior vagal trunk; 7 – Pancreatic plexus

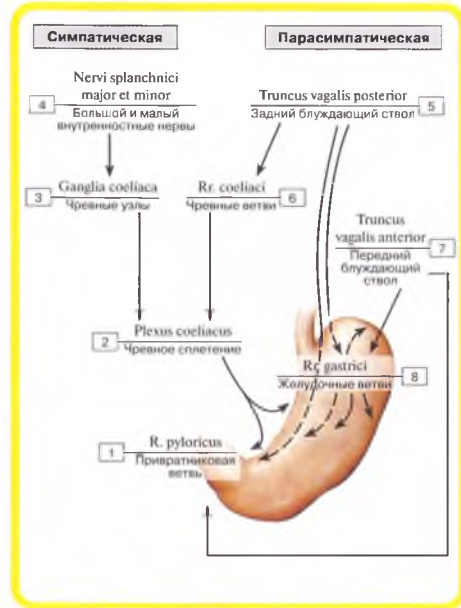
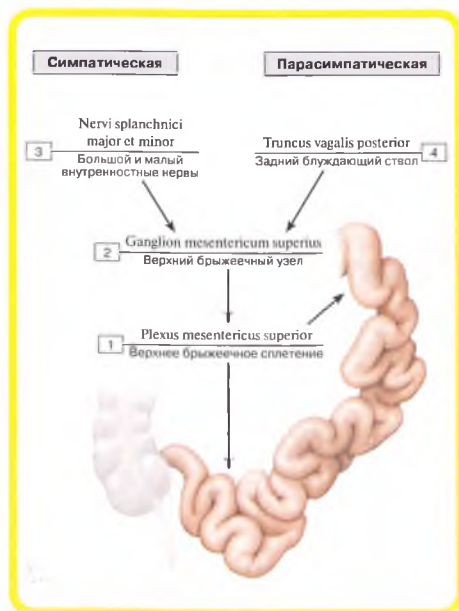


Рис. 433. Иннервация желудка:

- 1 – Pyloric branch; 2 – Coeliac plexus; 3 – Coeliac ganglia; 4 – Greater and lesser splanchnic nerves; 5 – Posterior vagal trunk; 6 – Coeliac branches; 7 – Anterior vagal trunk; 8 – Gastric branches



←Рис. 435. Иннервация тощей и подвздошной кишки:

1 – Superior mesenteric plexus; 2 – Superior mesenteric ganglion; 3 – Greater and lesser splanchnic nerves; 4 – Posterior vagal trunk

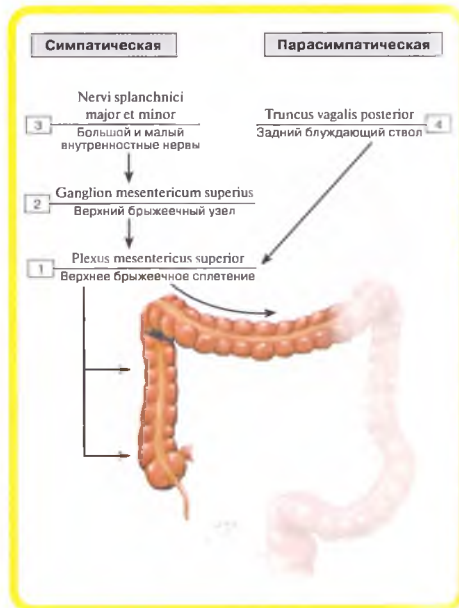
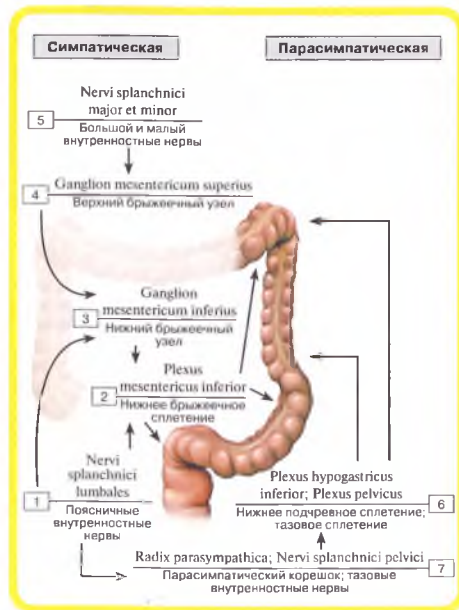
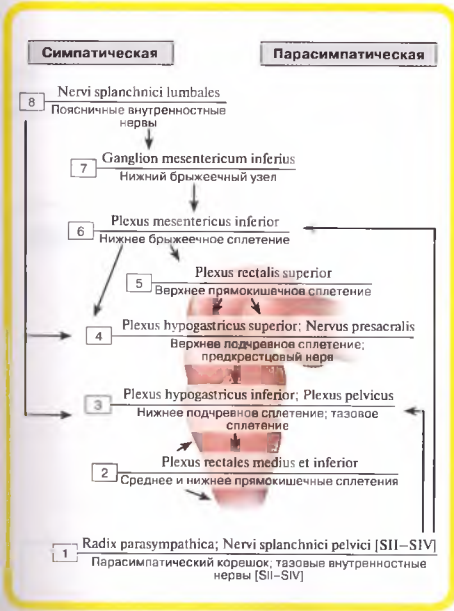


Рис. 436. Иннервация слепой кишки, аппендикса, восходящей и поперечной ободочных кишок:

1 – Superior mesenteric plexus; 2 – Superior mesenteric ganglion; 3 – Greater and lesser splanchnic nerves; 4 – Posterior vagal trunk

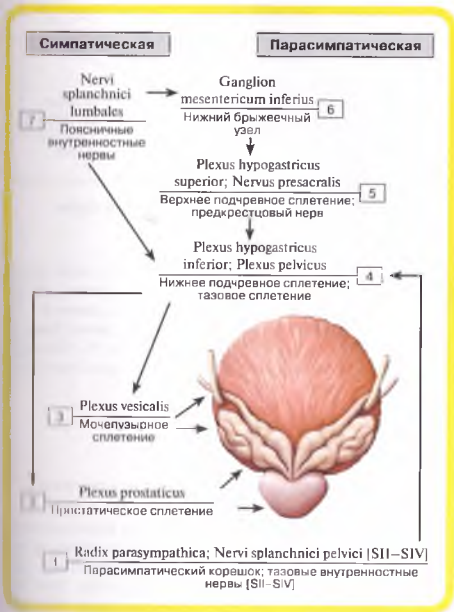
←Рис. 437. Иннервация нисходящей и сигмовидной ободочных кишок:

1 – Lumbar splanchnic nerves; 2 – Inferior mesenteric plexus; 3 – Inferior mesenteric ganglion; 4 – Superior mesenteric ganglion; 5 – Greater and lesser splanchnic nerves; 6 – Inferior hypogastric plexus; Pelvic plexus; 7 – Parasympathetic root; Pelvic splanchnic nerves



← Рис. 438. Иннервация прямой кишки:

- 1 – Parasympathetic root; Pelvic splanchnic nerves [SII–SIV];  
2 – Middle and inferior rectal plexuses; 3 – Inferior hypogastric plexus; Pelvic plexus; 4 – Superior hypogastric plexus; Presacral nerve; 5 – Superior rectal plexus; 6 – Inferior mesenteric plexus; 7 – Inferior mesenteric ganglion; 8 – Lumbar splanchnic nerves



← Рис. 440. Иннервация мочевого пузыря, простаты и семенных пузырьков:

- 1 – Parasympathetic root; Pelvic splanchnic nerves [SII–SIV];  
2 – Prostatic plexus; 3 – Vesical plexus; 4 – Inferior hypogastric plexus; Pelvic plexus; 5 – Superior hypogastric plexus; Presacral nerve; 6 – Inferior mesenteric ganglion; 7 – Lumbar splanchnic nerves

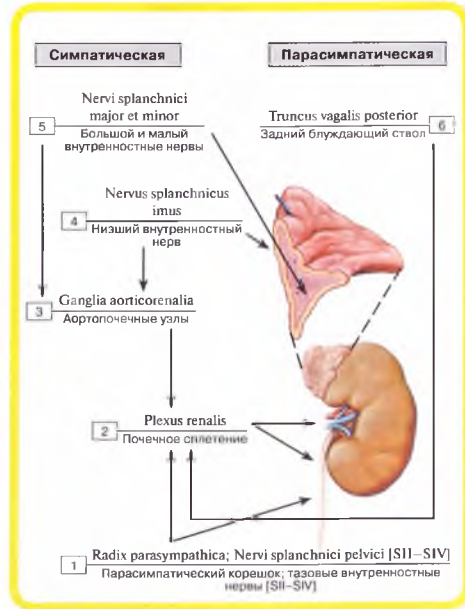
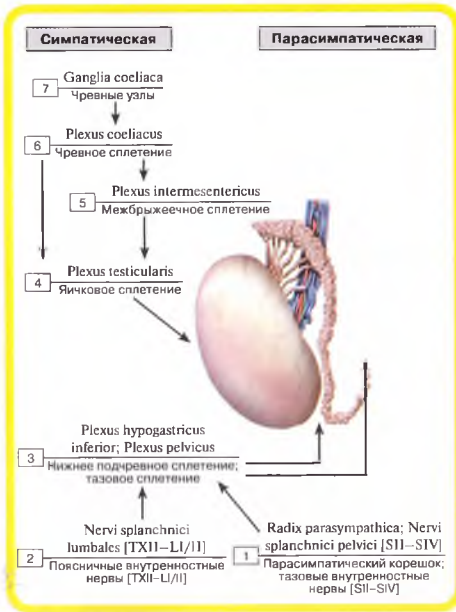


Рис. 439. Иннервация левой почки, мочеточника и надпочечника:

- 1 – Parasympathetic root; Pelvic splanchnic nerves [SII–SIV];  
2 – Renal plexus; 3 – Aorticorenal ganglia; 4 – Least splanchnic nerve; Lowest splanchnic nerve; 5 – Greater and lesser splanchnic nerves; 6 – Posterior vagal trunk





← Рис. 441. Иннервация яичка, придатка яичка и семявыносящего протока:

1 — Parasympathetic root; Pelvic splanchnic nerves [SII-SIV]; 2 — Lumbar splanchnic nerves [TXII-L/II]; 3 — Inferior hypogastric plexus; Pelvic plexus; 4 — Testicular plexus; 5 — Intermesenteric plexus; 6 — Coeliac plexus; 7 — Coeliac ganglia

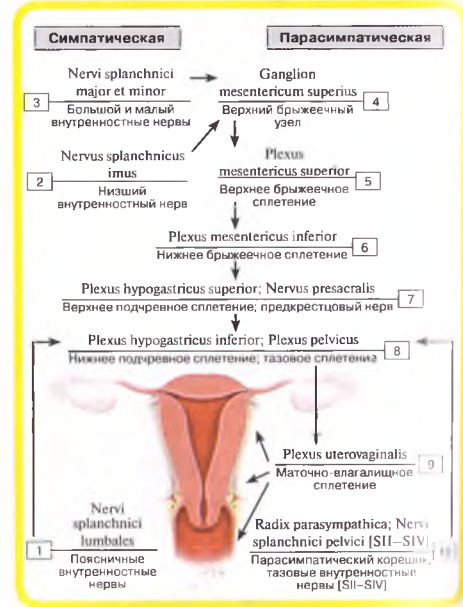
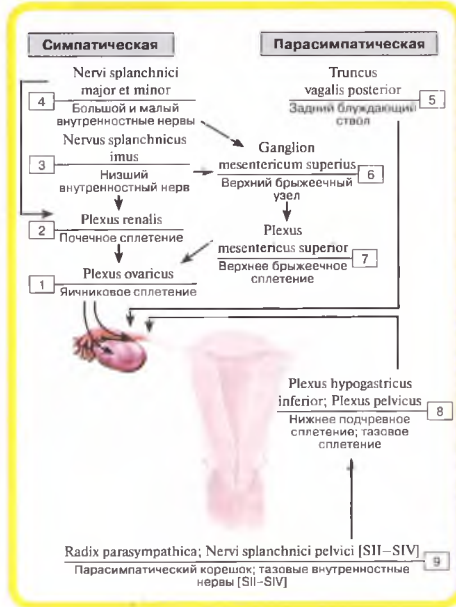


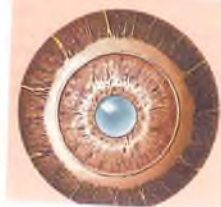
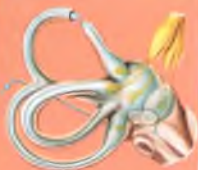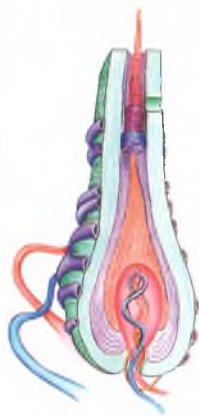Рис. 442. Иннервация матки, маточной трубы и влагалища:

1 — Lumbar splanchnic nerves; 2 — Least splanchnic nerve; 3 — Greater and lesser splanchnic nerves; 4 — Superior mesenteric ganglion; 5 — Superior mesenteric plexus; 6 — Inferior mesenteric plexus; 7 — Superior hypogastric plexus; 8 — Inferior hypogastric plexus; 9 — Uterovaginal plexus; 10 — Parasympathetic root; Pelvic splanchnic nerves [SII-SIV]

← Рис. 443. Иннервация маточной трубы и яичника:

1 — Ovarian plexus; 2 — Renal plexus; 3 — Least splanchnic nerve; 4 — Superior mesenteric ganglion; 5 — Posterior vagal trunk; 6 — Superior mesenteric ganglion; 7 — Superior mesenteric plexus; 8 — Inferior hypogastric plexus; 9 — Parasympathetic root; Pelvic splanchnic nerves [SII-SIV]

# ОРГАНЫ ЧУВСТВ



## ОРГАН ЗРЕНИЯ

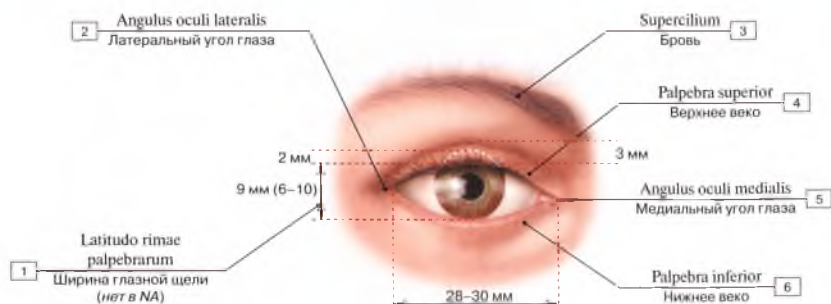


Рис. 444. Открытый глаз:

1 – Width of palpebral fissure; 2 – Lateral angle of eye; 3 – Eyebrow; 4 – Superior eyelid; Upper eyelid; 5 – Medial angle of eye; 6 – Inferior eyelid; Lower eyelid

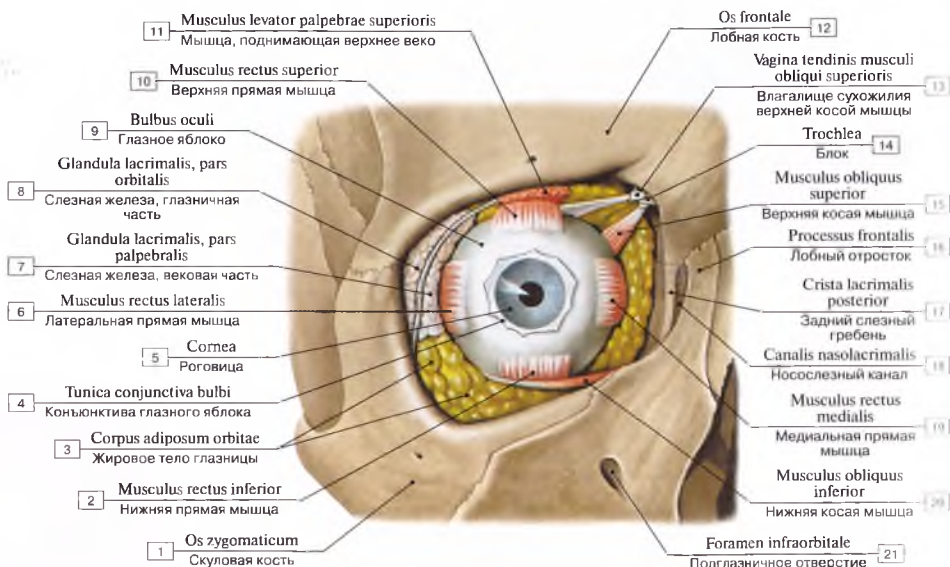


Рис. 445. Жировое тело глазницы:

1 – Zygomatic bone; 2 – Inferior rectus; 3 – Retrobulbar fat; 4 – Bulbar conjunctiva; 5 – Cornea; 6 – Lateral rectus; 7 – Lacrimal gland, palpebral part; 8 – Lacrimal gland, orbital part; 9 – Eyeball; 10 – Superior rectus; 11 – Levator palpebrae superioris; 12 – Frontal bone; 13 – Tendinous sheath of superior oblique; 14 – Trochlea; 15 – Superior oblique; 16 – Frontal process; 17 – Posterior lacrimal crest; 18 – Nasolacrimal canal; 19 – Medial rectus; 20 – Inferior oblique; 21 – Infra-orbital foramen

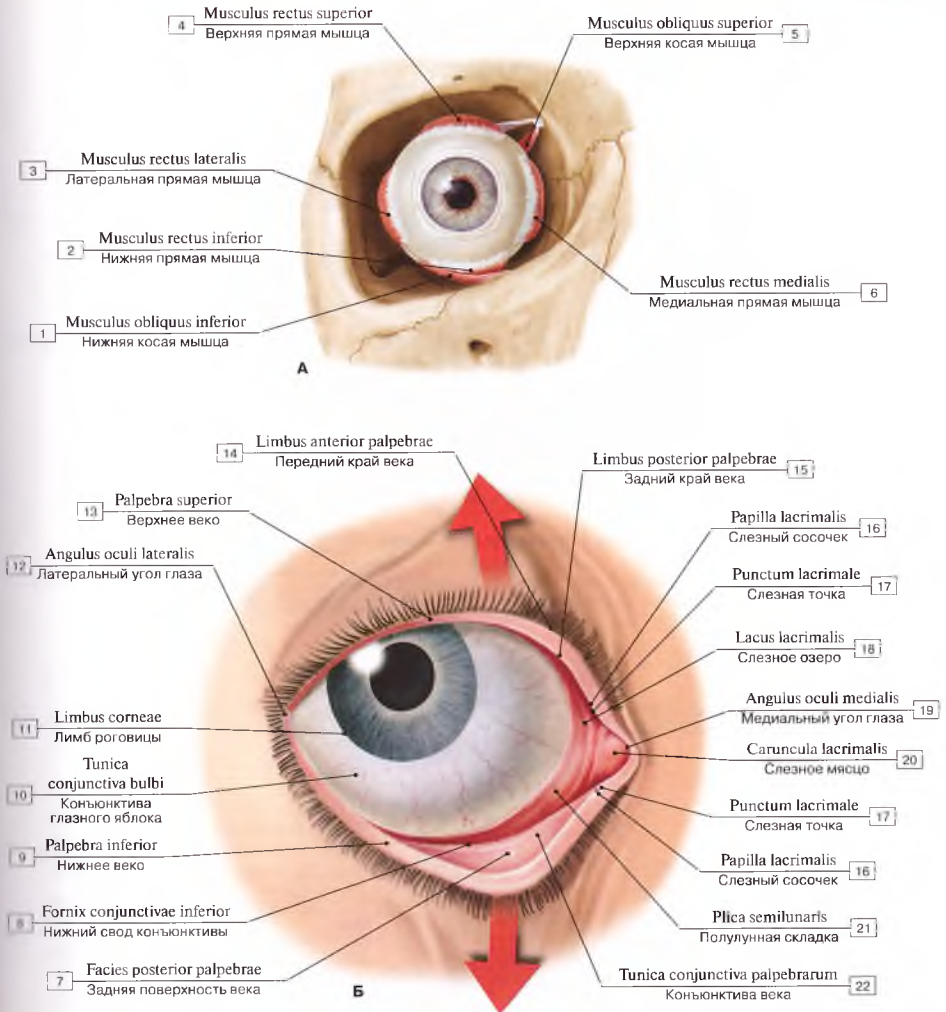


Рис. 446. Глазное яблоко (А – положение в глазнице, жировая ткань удалена; Б – конъюнктива):

1 – Inferior oblique; 2 – Inferior rectus; 3 – Lateral rectus; 4 – Superior rectus; 5 – Superior oblique; 6 – Medial rectus; 7 – Posterior surface of eyelid; 8 – Inferior conjunctival fornix; 9 – Inferior eyelid; Lower eyelid; 10 – Bulbar conjunctiva; 11 – Corneoscleral junction; Corneal limbus; 12 – Lateral angle of eye; 13 – Superior eyelid; Upper eyelid; 14 – Anterior palpebral margin; 15 – Posterior palpebral margin; 16 – Lacrimal papilla; 17 – Lacrimal punctum; 18 – Lacus lacrimalis; Lacrimal lake; 19 – Medial angle of eye; 20 – Lacrimal caruncle; 21 – Plica semilunaris; 22 – Palpebral conjunctiva

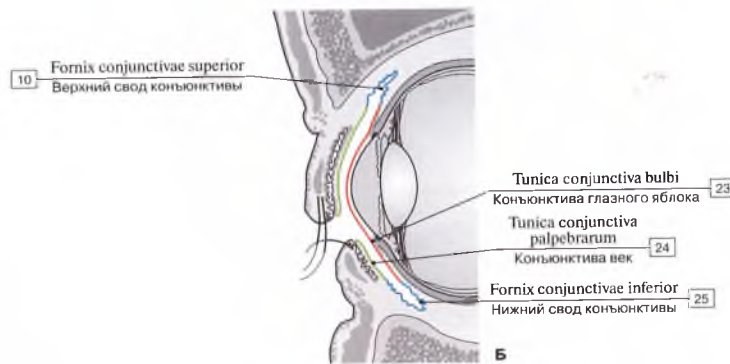
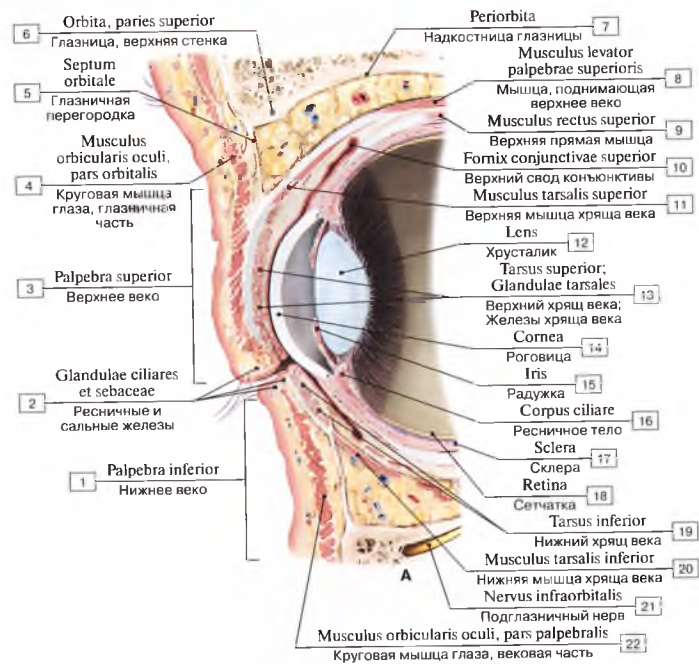


Рис. 447. Строение века и конъюнктивы (А – сагиттальный разрез передней полости глазницы; Б – анатомия конъюнктивы)

1 – Inferior eyelid; Lower eyelid; 2 – Ciliary and sebaceous glands; 3 – Superior eyelid; Upper eyelid; 4 – Orbicularis oculi, orbital part; 5 – Orbital septum; 6 – Orbit, roof; 7 – Periorbita; 8 – Levator palpebrae superioris; 9 – Superior rectus; 10 – Superior conjunctival fornix; 11 – Superior tarsal muscle; 12 – Lens; 13 – Superior tarsus; Tarsal glands; 14 – Cornea; 15 – Iris; 16 – Ciliary body; 17 – Sclera; 18 – Retina; 19 – Inferior tarsus; 20 – Inferior tarsal muscle; 21 – Infra-orbital nerve; 22 – Orbicularis oculi, palpebral part; 23 – Bulboconjunctiva; 24 – Palpebral conjunctiva; 25 – Inferior conjunctival fornix

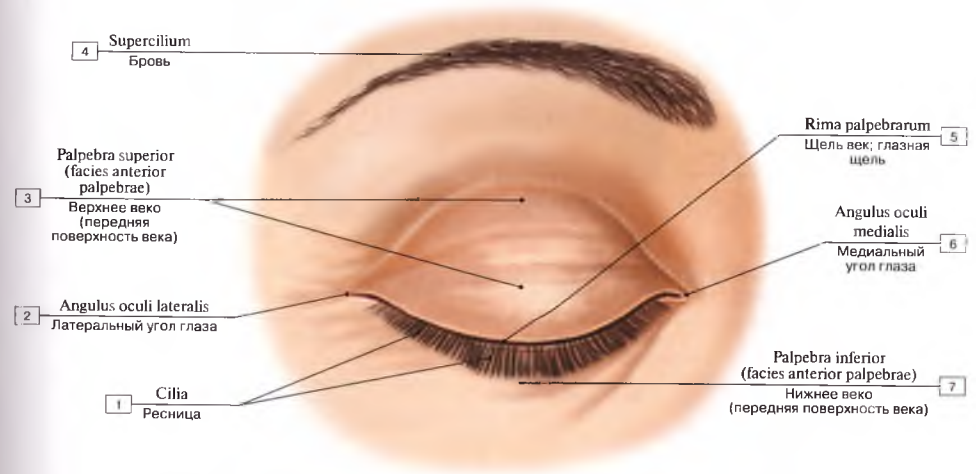


Рис. 448. Верхнее веко при закрытом глазе:

1 – Eyelash; 2 – Lateral angle of eye; 3 – Superior eyelid; Upper eyelid (anterior surface of eyelid); 4 – Eyebrow; 5 – Palpebral fissure; 6 – Medial angle of eye; 7 – Inferior eyelid; Lower eyelid (anterior surface of eyelid)

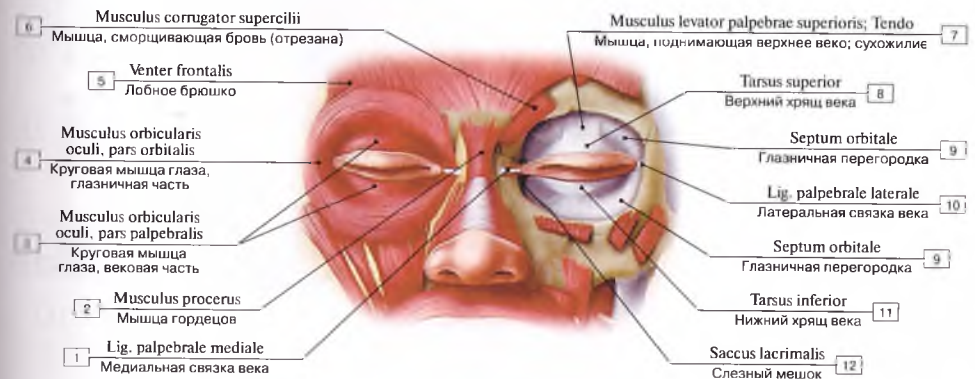


Рис. 449. Хрящи век:

1 – Medial palpebral ligament; 2 – Procerus; 3 – Orbicularis oculi, palpebral part; 4 – Orbicularis oculi, orbital part; 5 – Frontal belly; 6 – Corrugator supercilii; 7 – Levator palpebrae superioris; Tendon; 8 – Superior tarsus; 9 – Orbital septum; 10 – Lateral palpebral ligament; 11 – Inferior tarsus; 12 – Lacrimal sac

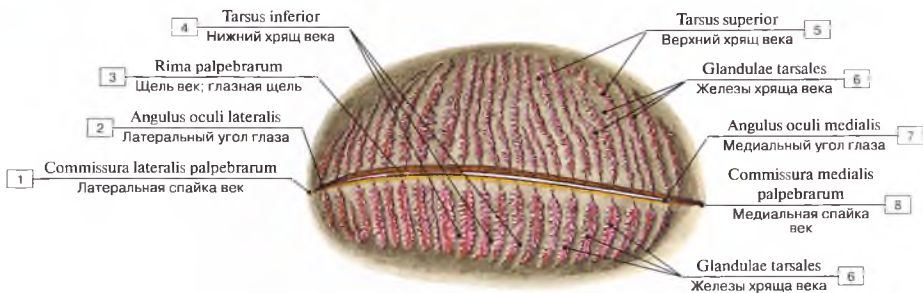


Рис. 450. Железы век:

1 – Lateral palpebral commissure; 2 – Lateral angle of eye; 3 – Palpebral fissure; 4 – Inferior tarsus; 5 – Superior tarsus; 6 – Tarsal glands; 7 – Medial angle of eye; 8 – Medial palpebral commissure

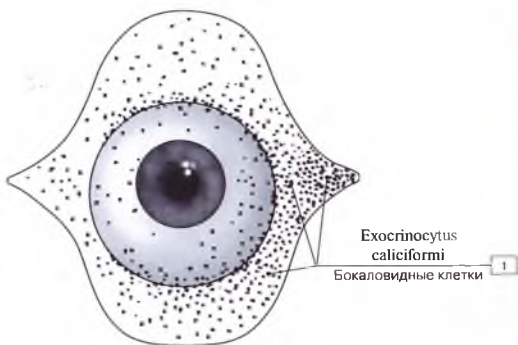


Рис. 451. Распределение бокаловидных клеток в конъюнктиве:

1 – Goblet cells

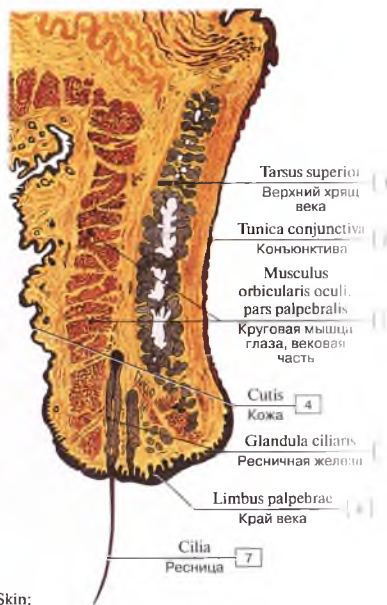


Рис. 452. Строение верхнего века, фронтальный разрез:

1 – Superior tarsus; 2 – Conjunctiva; 3 – Orbicularis oculi, palpebral part; 4 – Skin; 5 – Ciliary gland; 6 – Palpebral margin; 7 – Eyelash

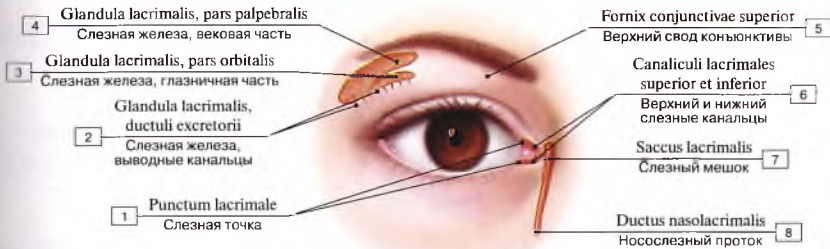


Рис. 453. Проекция слезных желез:

1 – Lacrimal punctum; 2 – Lacrimal gland, excretory ducts; 3 – Lacrimal gland, orbital part; 4 – Lacrimal gland, palpebral part; 5 – Superior conjunctival fornix; 6 – Superior and inferior lacrimal canaliculus; 7 – Lacrimal sac; 8 – Nasolacrimal duct

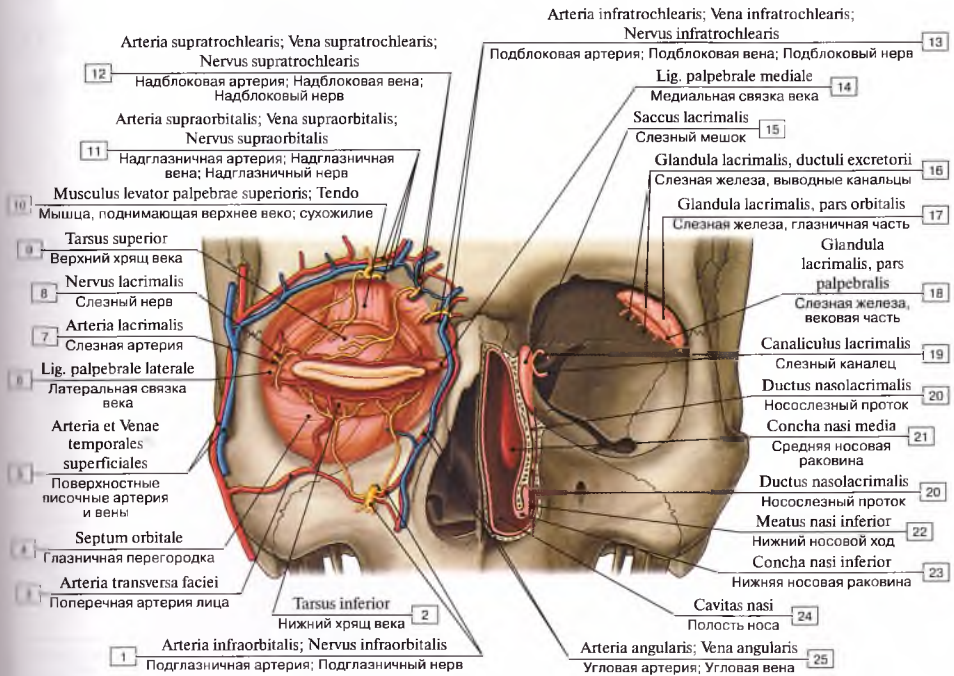


Рис. 454. Иннервация и кровоснабжение глаза:

1 – Infra-orbital artery and nerve; 2 – Inferior tarsus; 3 – Transverse facial artery; 4 – Orbital septum; 5 – Superficial temporal artery and vein; 6 – Lateral palpebral ligament; 7 – Lacrimal artery; 8 – Lacrimal nerve; 9 – Superior tarsus; 10 – Levator palpebrae superioris muscle; tendon; 11 – Supra-orbital artery, vein and nerve; 12 – Supratrochlear artery, vein and nerve; 13 – Infratrochlear artery, vein and nerve; 14 – Medial palpebral ligament; 15 – Lacrimal sac; 16 – Lacrimal gland, excretory ducts; 17 – Lacrimal gland, orbital part; 18 – Lacrimal gland, palpebral part; 19 – Lacrimal canaliculus; 20 – Nasolacrimal duct; 21 – Middle nasal concha; 22 – Inferior nasal meatus; 23 – Inferior nasal concha; 24 – Nasal cavity; 25 – Angular artery and vein

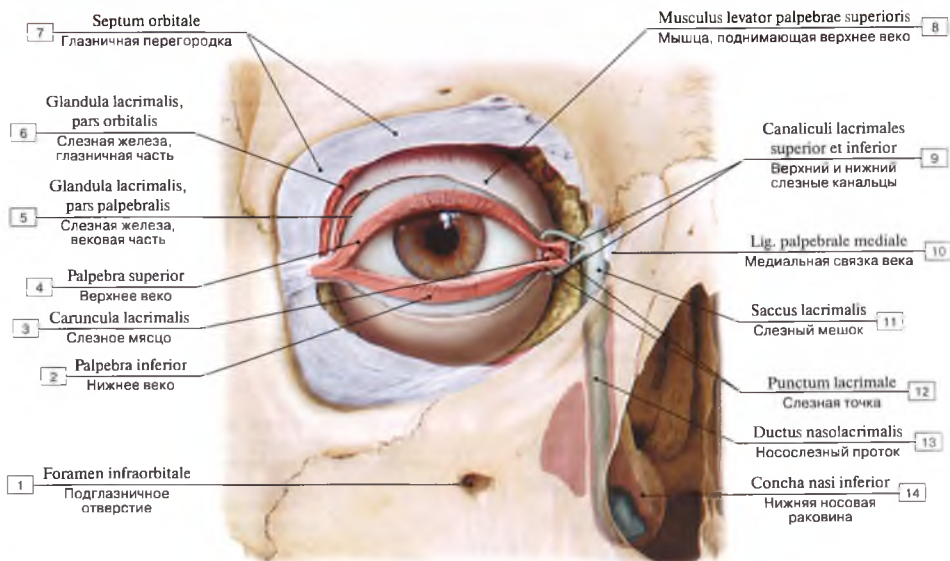


Рис. 455. Слезный аппарат, правый глаз, вид спереди:

1 – Infra-orbital foramen; 2 – Inferior eyelid; Lower eyelid; 3 – Lacrimal caruncle; 4 – Superior eyelid; Upper eyelid; 5 – Lacrimal gland, palpebral part; 6 – Lacrimal gland, orbital part; 7 – Orbital septum; 8 – Levator palpebrae superioris; 9 – Superior and inferior lacrimal canaliculus; 10 – Medial palpebral ligament; 11 – Lacrimal sac; 12 – Lacrimal punctum; 13 – Nasolacrimal duct; 14 – Inferior nasal concha

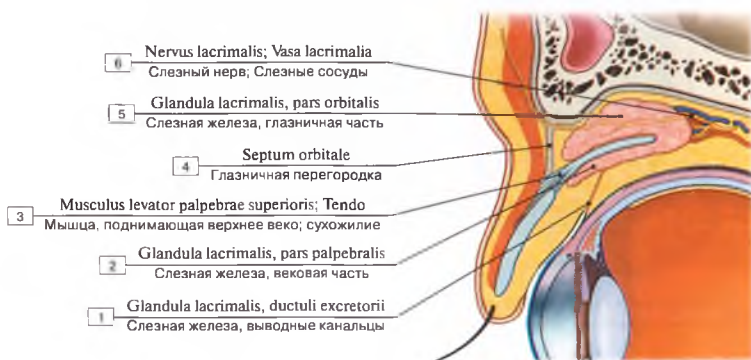


Рис. 456. Слезная железа, сагиттальный разрез:

1 – Lacrimal gland, excretory ducts; 2 – Lacrimal gland, palpebral part; 3 – Levator palpebrae superioris; Tendon; 4 – Orbital septum; 5 – Lacrimal gland, orbital part; 6 – Lacrimal nerve; Lacrimal vessels



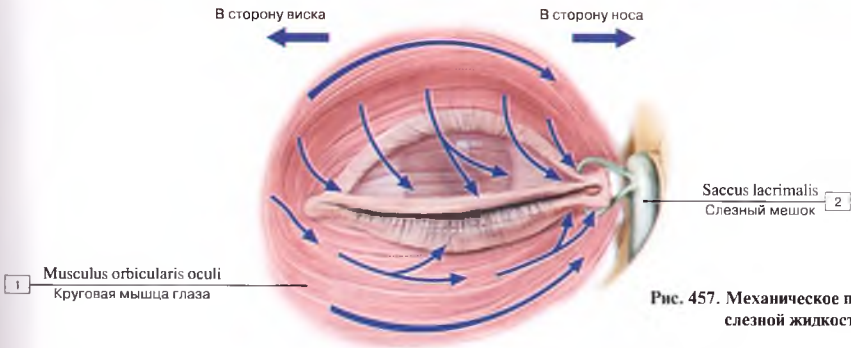


Рис. 457. Механическое продвижение слезной жидкости:

1 – Orbicularis oculi; 2 – Lacrimal sac

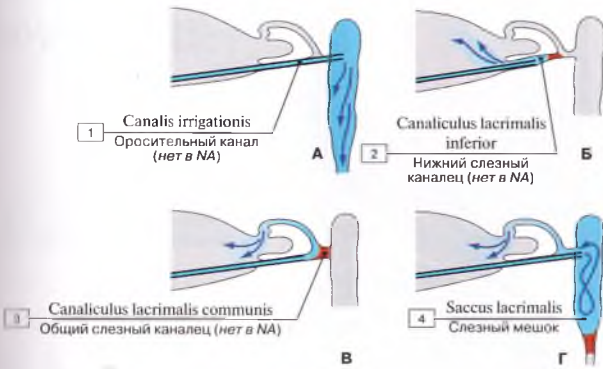


Рис. 458. Схемы оттока слезной жидкости (А–Г):

1 – Irrigation tube; 2 – Inferior lacrimal canaliculus; 3 – Common lacrimal canaliculus; 4 – Lacrimal sac

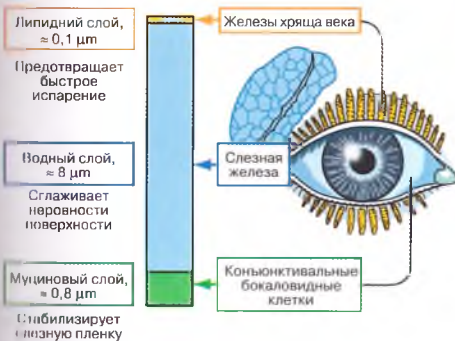


Рис. 459. Отток слезной жидкости (схема)

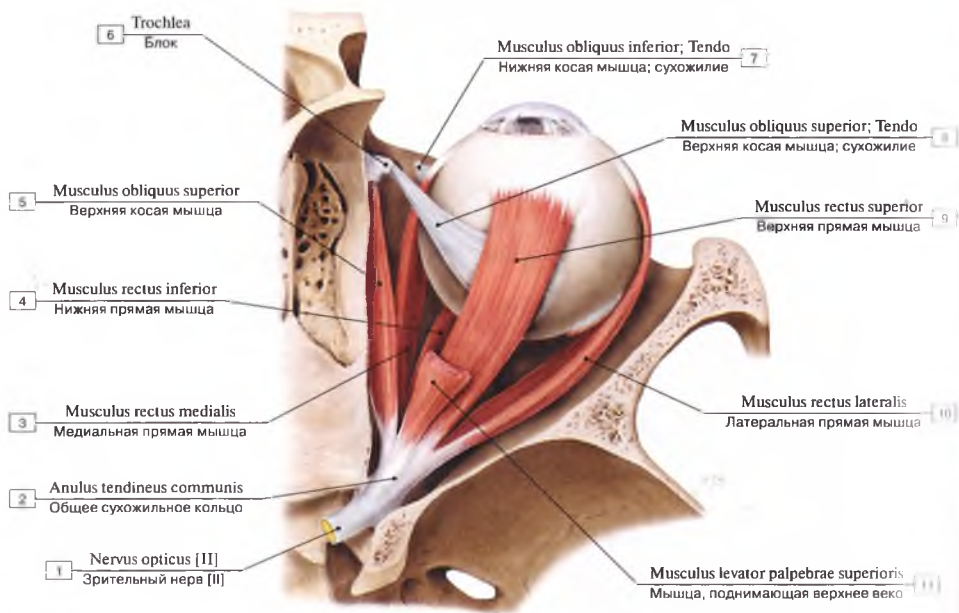


Рис. 460. Глазодвигательные мышцы, вид сверху:

1 – Optic nerve [II]; 2 – Common tendinous ring; 3 – Medial rectus; 4 – Inferior rectus; 5 – Superior oblique;  
6 – Trochlea; 7 – Inferior oblique; Tendon; 8 – Superior oblique; Tendon; 9 – Superior rectus; 10 – Lateral rectus; 11 – Levator  
palpebrae superioris

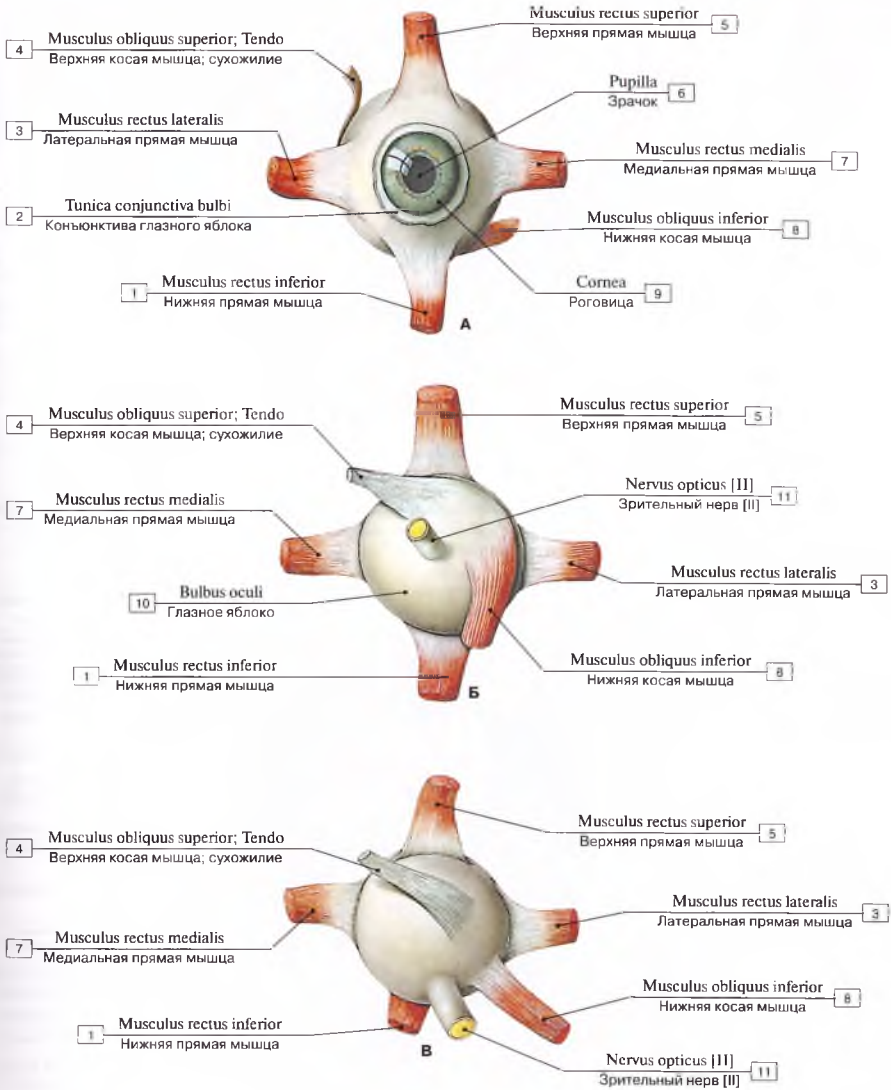


Рис. 461. Глазодвигательные мышцы (А – вид спереди; Б – вид сзади; В – вид сзади и сверху):

1 – Inferior rectus; 2 – Bulbar conjunctiva; 3 – Lateral rectus; 4 – Superior oblique; Tendon; 5 – Superior rectus; 6 – Pupil; 7 – Medial rectus; 8 – Inferior oblique; 9 – Cornea; 10 – Eyeball; 11 – Optic nerve [II]

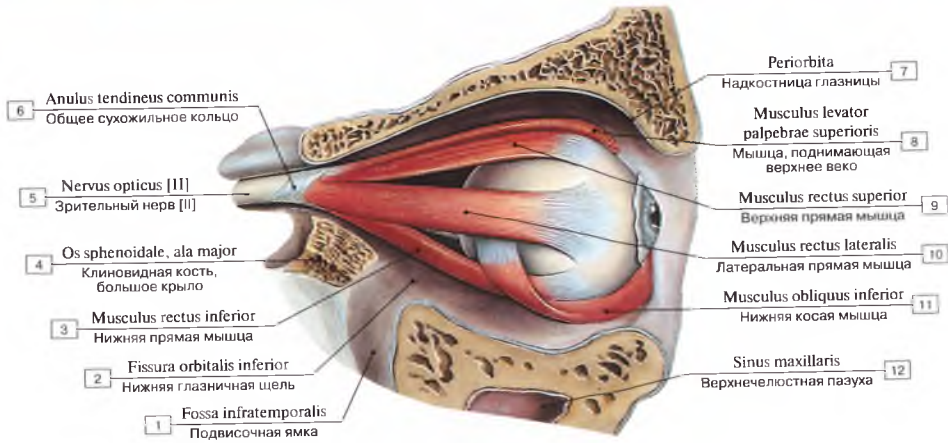


Рис. 462. Глазодвигательные мышцы с латеральной стороны:

1 – Infratemporal fossa; 2 – Inferior orbital fissure; 3 – Inferior rectus; 4 – Sphenoid; Sphenoidal bone, greater wing; 5 – Optic nerve [II]; 6 – Common tendinous ring; Common annular tendon; 7 – Periorbita; 8 – Levator palpebrae superioris; 9 – Superior rectus; 10 – Lateral rectus; 11 – Inferior oblique; 12 – Maxillary sinus

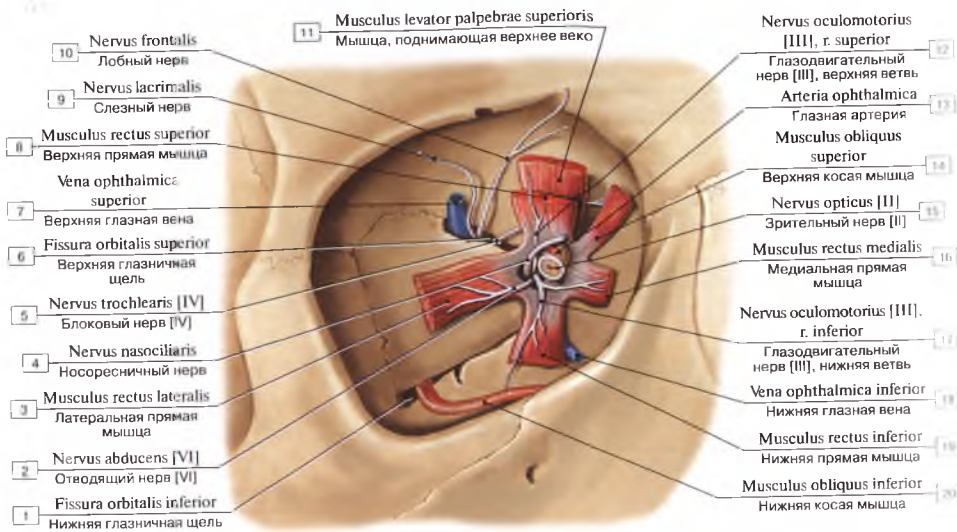


Рис. 463. Сухожильное кольцо:

1 – Inferior orbital fissure; 2 – Abducent nerve; Abducent nerve [VI]; 3 – Lateral rectus; 4 – Nasociliary nerve; 5 – Trochlear nerve [IV]; 6 – Superior orbital fissure; 7 – Superior ophthalmic vein; 8 – Superior rectus; 9 – Lacrimal nerve; 10 – Frontal nerve; 11 – Levator palpebrae superioris; 12 – Oculomotor nerve [III], superior branch; 13 – Ophthalmic artery; 14 – Superior oblique; 15 – Optic nerve [II]; 16 – Medial rectus; 17 – Oculomotor nerve [III], inferior branch; 18 – Inferior ophthalmic vein; 19 – Inferior rectus; 20 – Inferior oblique

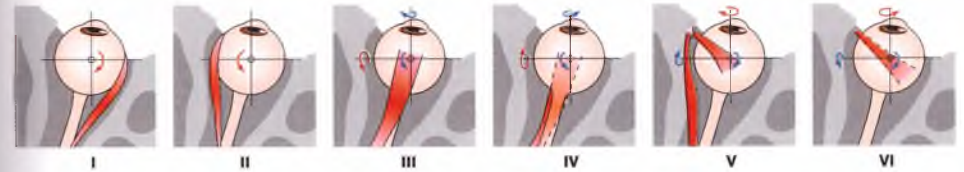


Рис. 464. Функции и иннервация глазодвигательных мышц

Правый глаз, вид сверху с удаленной верхней стенкой глазницы. Латеральная и медиальная прямые мышцы имеют только одно основное действие и одно направление тяги (I, II), в то время как другие мышцы имеют вторичное действие и направление тяги.

Мышца	Первичное действие	Вторичное действие	Иннервация
I Латеральная прямая мышца	Отведение	-	Отводящий нерв [CN VI]
II Медиальная прямая мышца	Приведение	-	Глазодвигательный нерв [CN III], нижняя ветвь
III Верхняя прямая мышца	Поднимание	Приведение и медиальное вращение	Глазодвигательный нерв [CN III], верхние ветви
IV Нижняя прямая мышца	Опускание	Приведение и боковое вращение	Глазодвигательный нерв [CN III], нижняя ветвь
V Верхняя косая мышца	Опускание и отведение	Медиальное вращение	Блоковый нерв [CN IV]
VI Нижняя косая мышца	Поднимание и отведение	Боковое вращение	Глазодвигательный нерв [CN III], нижняя ветвь

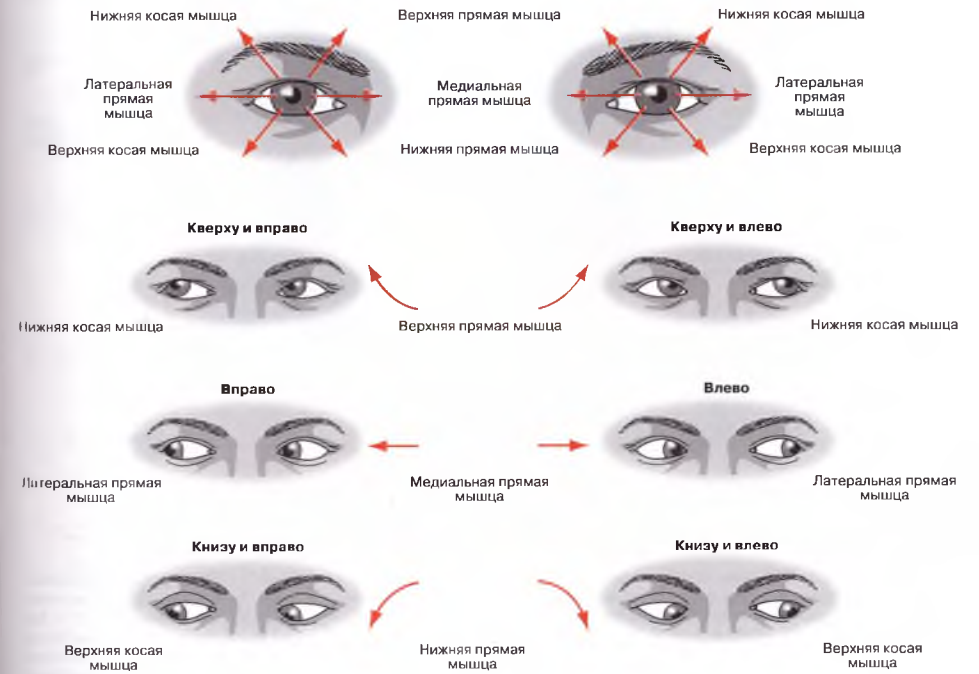


Рис. 465. Шесть основных направлений взгляда

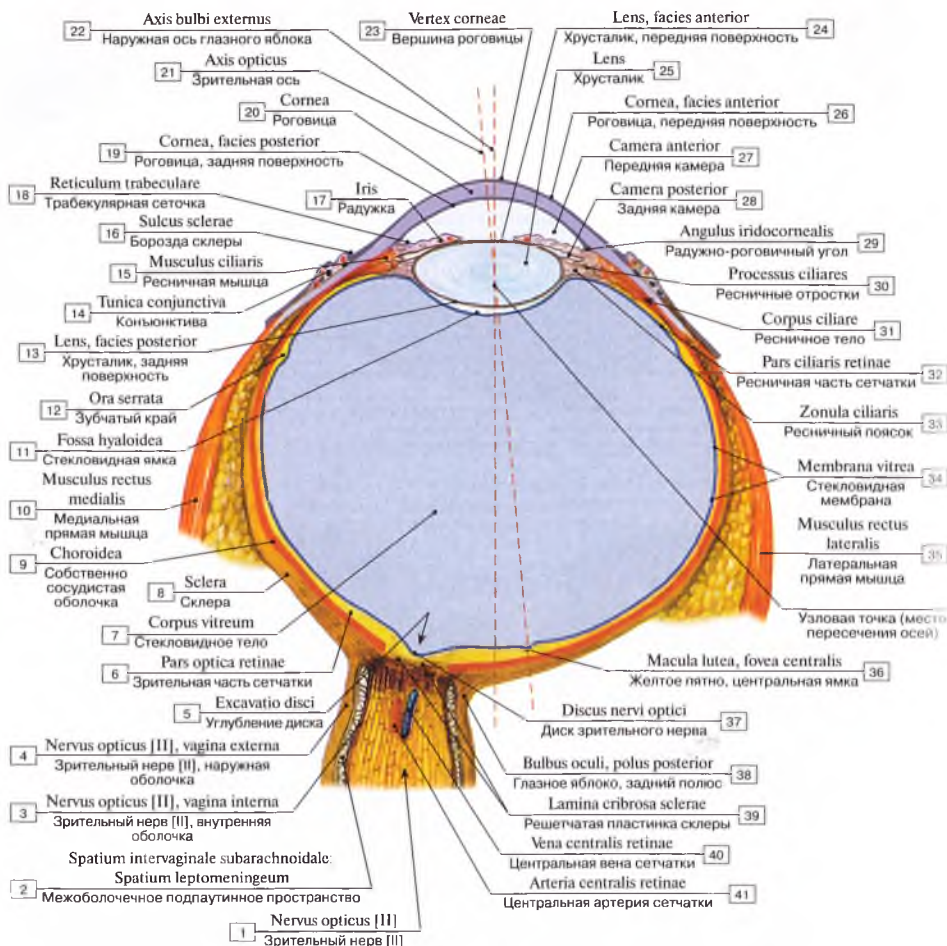


Рис. 466. Глаз, сагиттальный разрез:

1 – Optic nerve [III]; 2 – Subarachnoid space; Leptomeningeal space; 3 – Optic nerve [II], inner sheath; 4 – Optic nerve [II], outer sheath; 5 – Depression of optic disc; Physiological cup; 6 – Optic part of retina; 7 – Vitreous body; 8 – Sclera; 9 – Choroid; 10 – Medial rectus; 11 – Hyaloid fossa; 12 – Ora serrata; 13 – Lens, posterior surface; 14 – Conjunctiva; 15 – Ciliary muscle; 16 – Sulcus sclerae; 17 – Iris; 18 – Trabecular tissue; 19 – Cornea, posterior surface; 20 – Cornea; 21 – Optic axis; 22 – External axis of eyeball; 23 – Corneal vertex; 24 – Lens, anterior surface; 25 – Lens; 26 – Cornea, anterior surface; 27 – Anterior chamber; 28 – Posterior chamber; 29 – Iridocorneal angle; 30 – Ciliary processes; 31 – Ciliary body; 32 – Ciliary part of retina; 33 – Ciliary zonule; 34 – Vitreous membrane; 35 – Lateral rectus; 36 – Macula, fovea centralis; 37 – Optic disc; 38 – Eyeball, posterior pole; 39 – Lamina cribrosa of sclera; 40 – Central retinal vein; 41 – Central retinal artery

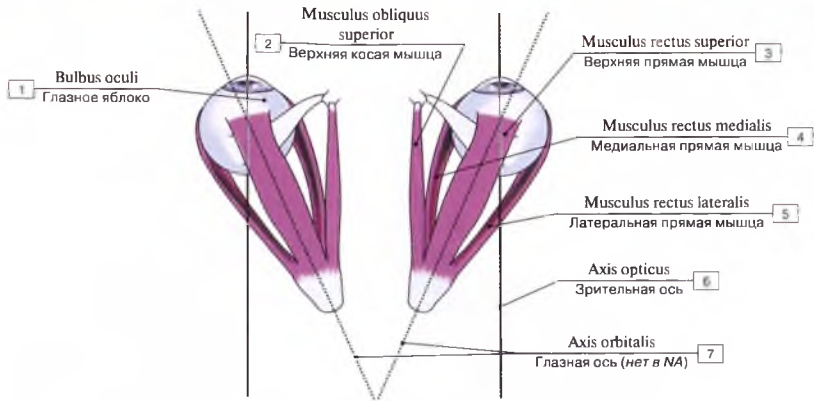


Рис. 467. Оптическая ось и оси глазницы (схема):

1 – Eyeball; 2 – Superior oblique; 3 – Superior rectus; 4 – Medial rectus; 5 – Lateral rectus; 6 – Optic axis; 7 – Orbital axis

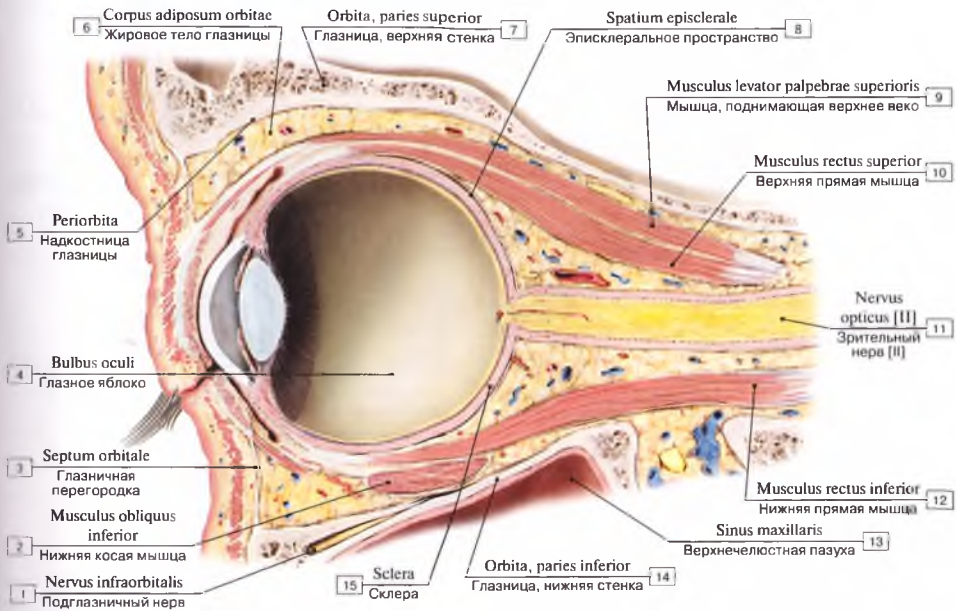


Рис. 468. Глаз в глазнице, сагиттальный разрез:

1 – Infra-orbital nerve; 2 – Inferior oblique; 3 – Orbital septum; 4 – Eyeball; 5 – Periorbita; 6 – Retrobulbar fat; 7 – Orbit, roof; 8 – Episcleral space; 9 – Levator palpebrae superioris; 10 – Superior rectus; 11 – Optic nerve [II]; 12 – Inferior rectus; 13 – Maxillary sinus; 14 – Orbit, floor; 15 – Sclera

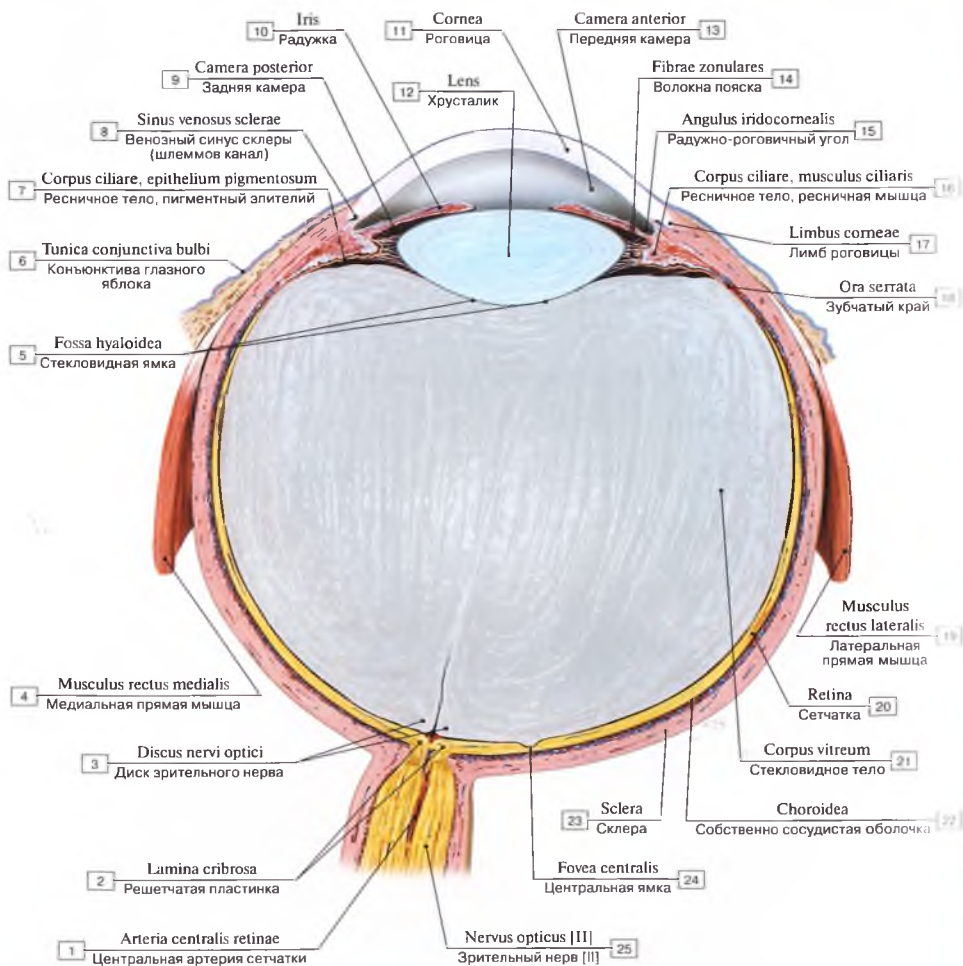


Рис. 469. Глаз, сагиттальный разрез:

1 – Central retinal artery; 2 – Cribriform plate; 3 – Optic disc; 4 – Medial rectus; 5 – Hyaloid fossa; 6 – Bulbar conjunctiva; 7 – Ciliary body, pigmented epithelium; 8 – Scleral venous sinus; 9 – Posterior chamber; 10 – Iris; 11 – Cornea; 12 – Lens; 13 – Anterior chamber; 14 – Zonular fibres; 15 – Iridocorneal angle; 16 – Ciliary body, ciliary muscle; 17 – Corneoscleral junction; 18 – Ora serrata; 19 – Lateral rectus; 20 – Retina; 21 – Vitreous body; 22 – Choroid; 23 – Sclera; 24 – Fovea centralis; 25 – Optic nerve [II]

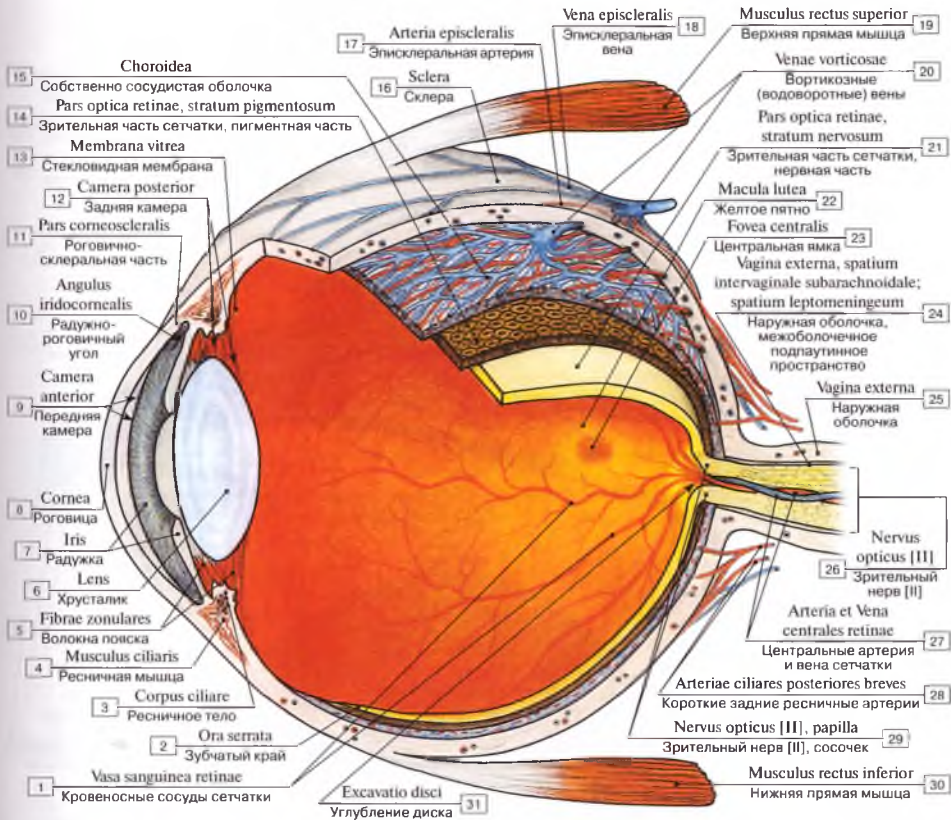


Рис. 470. Оболочки глаза:

1 — Retinal blood vessels; 2 — Ora serrata; 3 — Ciliary body; 4 — Ciliary muscle; 5 — Zonular fibres; 6 — Lens; 7 — Iris; 8 — Cornea; 9 — Anterior chamber; 10 — Iridocorneal angle; 11 — Corneoscleral part; 12 — Posterior chamber; 13 — Vitreous membrane; 14 — Optic part of retina, pigmented layer; 15 — Choroid; 16 — Sclera; 17 — Episcleral artery; 18 — Episcleral vein; 19 — Superior rectus; 20 — Vorticosae veins; 21 — Optic part of retina, neural layer; 22 — Macula; 23 — Fovea centralis; 24 — Outer sheath, subarachnoid space; leptomeningeal space; 25 — Outer sheath; 26 — Optic nerve [III]; 27 — Central retinal artery and vein; 28 — Short posterior ciliary arteries; 29 — Optic nerve [II], papillae; 30 — Inferior rectus; 31 — Depression of optic disc; Physiological cup



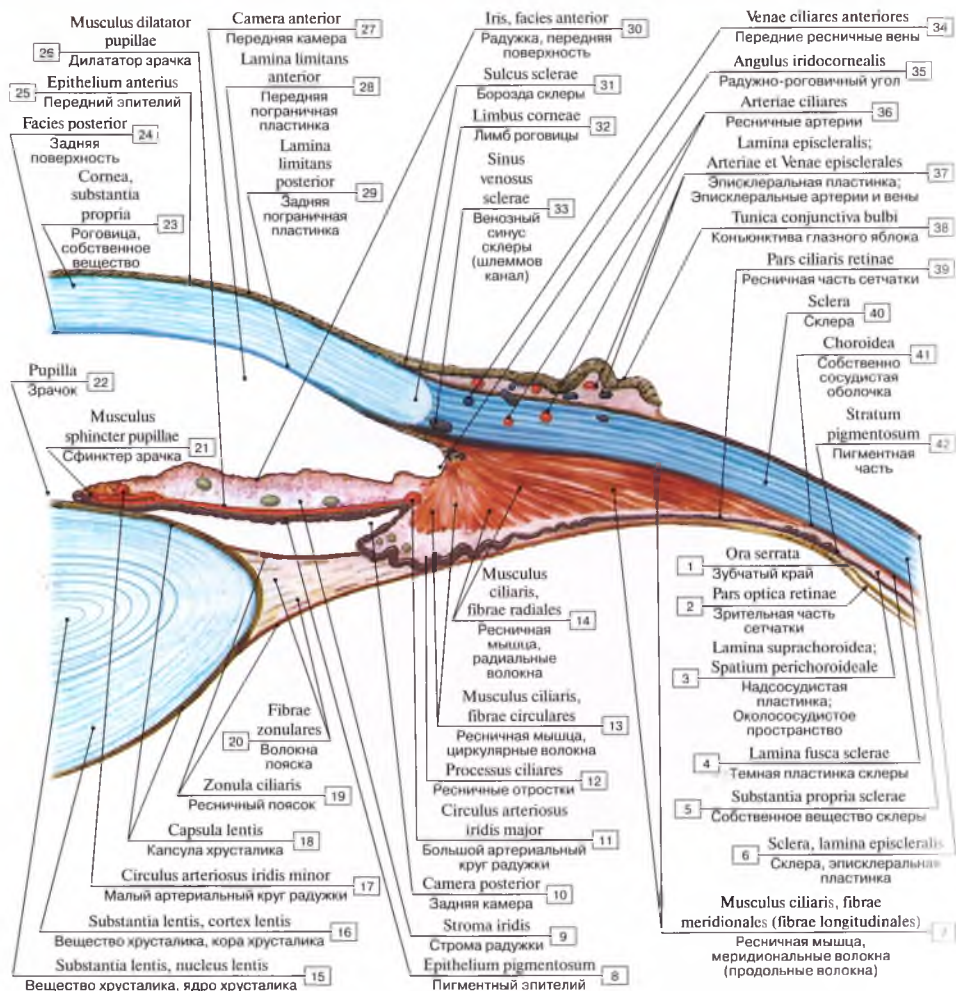


Рис. 471. Фиброзная и сосудистая оболочки глаза, хрусталик:

1 – Ora serrata; 2 – Optic part of retina; 3 – Suprachoroid lamina; Perichoroidal space; 4 – Dark lamina of sclera; 5 – Substantia propria; 6 – Sclera, episcleral layer; 7 – Ciliary muscle, meridional fibres (longitudinal fibres); 8 – Pigmented epithelium; 9 – Stroma of iris; 10 – Posterior chamber; 11 – Major circulus arteriosus of iris; 12 – Ciliary processes; 13 – Ciliary muscle, circular fibres; 14 – Ciliary muscle, radial fibres; 15 – Lens substance, nucleus of lens; 16 – Lens substance, cortex of lens; 17 – Minor circulus arteriosus of iris; 18 – Capsule of lens; 19 – Ciliary zonule; 20 – Zonular fibres; 21 – Sphincter pupillae; 22 – Pupil; 23 – Cornea, substantia propria; 24 – Posterior surface; 25 – Corneal epithelium; 26 – Dilator pupillae; 27 – Anterior chamber; 28 – Anterior limiting lamina; 29 – Posterior limiting lamina; 30 – Iris, anterior surface; 31 – Sulcus sclerae; 32 – Corneoscleral junction; Corneal limbus; 33 – Scleral venous sinus; 34 – Anterior ciliary veins; 35 – Iridocorneal angle; 36 – Ciliary arteries; 37 – Episcleral layer; Episcleral arteries and veins; 38 – Bulbar conjunctiva; 39 – Ciliary part of retina; 40 – Sclera; 41 – Choroid; 42 – Pigmented layer

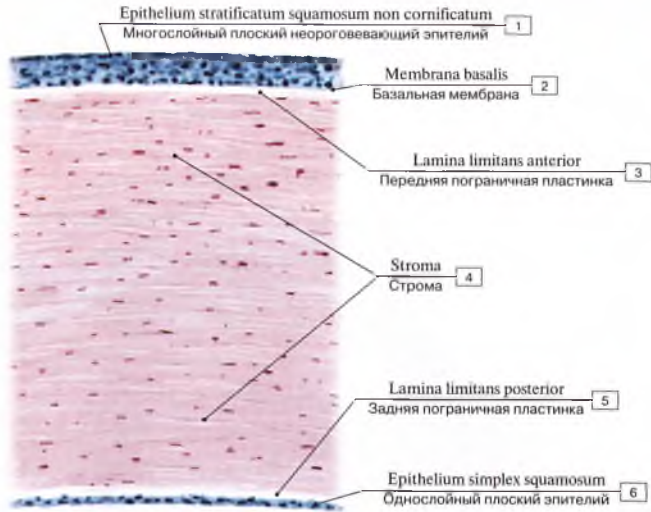


Рис. 472. Структура роговицы:

1 – Nonkeratinized stratified squamous; 2 – Basement membrane; 3 – Anterior limiting lamina; 4 – Stroma; 5 – Posterior limiting membrane; 6 – Simple squamous epithelium

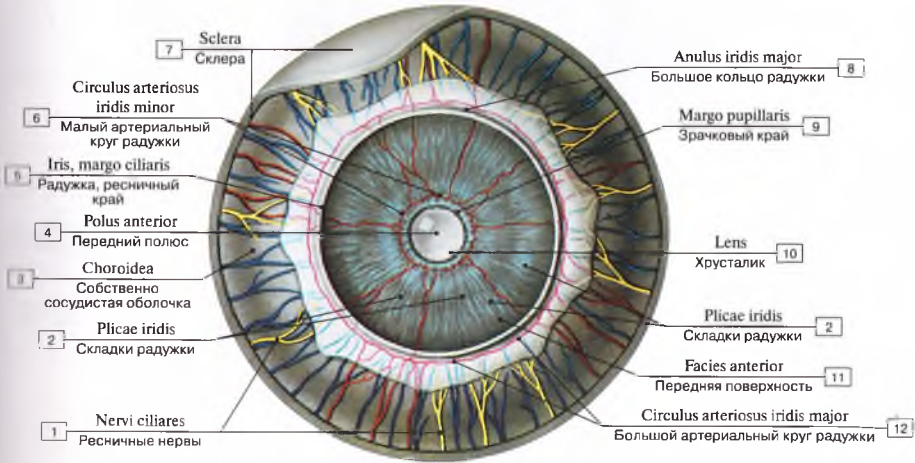


Рис. 473. Сосудистая оболочка глазного яблока:

1 – Ciliary nerves; 2 – Folds of iris; 3 – Choroid; 4 – Anterior pole; 5 – Iris, ciliary margin; 6 – Minor circulus arteriosus of iris; 7 – Sclera; 8 – Outer border of iris; 9 – Pupillary margin; 10 – Lens; 11 – Anterior surface; 12 – Major circulus arteriosus of iris

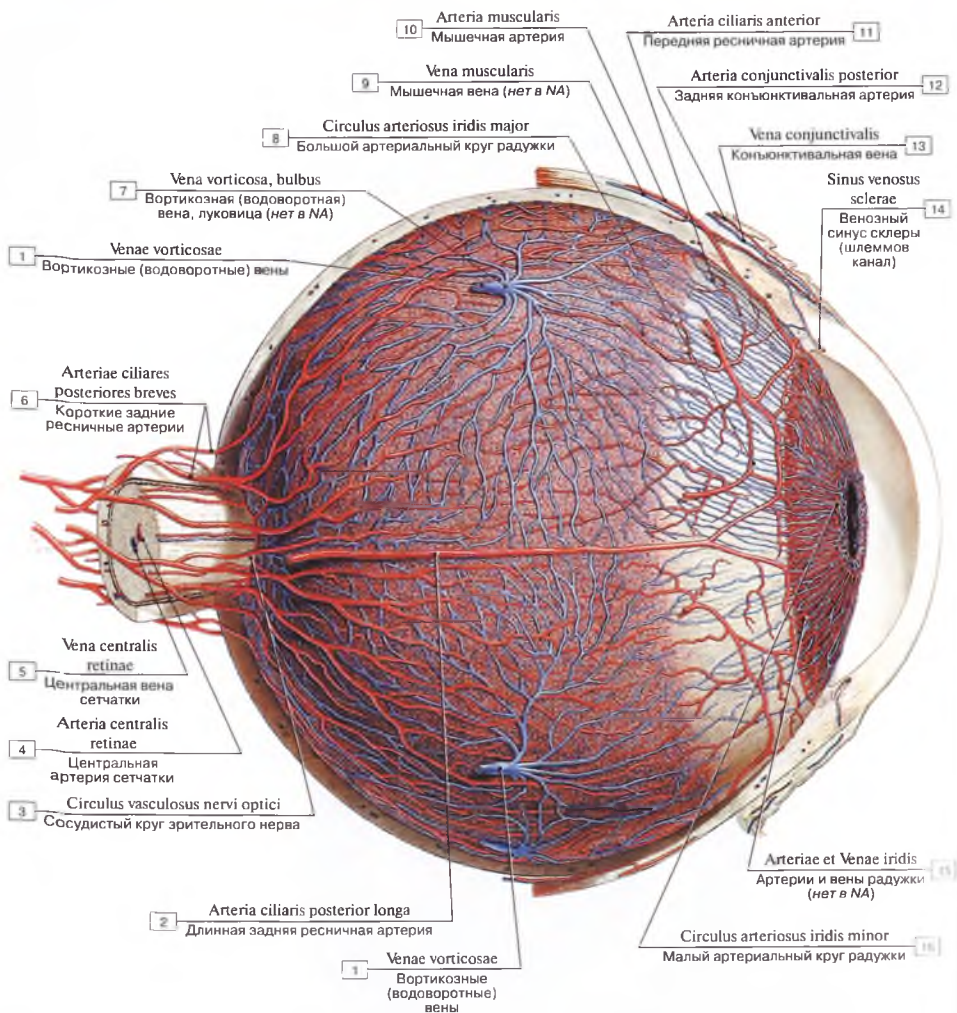


Рис. 474. Сосудистая оболочка глазного яблока, вид спереди:

- 1 – Vorticosae veins; 2 – Long posterior ciliary artery; 3 – Vascular circle of optic nerve; 4 – Central retinal artery; 5 – Central retinal vein; 6 – Short posterior ciliary arteries; 7 – Vorticosae vein, bulb; 8 – Major circulus arteriosus of iris; 9 – Muscular vein; 10 – Muscular artery; 11 – Anterior ciliary artery; 12 – Posterior conjunctival artery; 13 – Conjunctival vein; 14 – Scleral venous sinus; 15 – Iridial arteries and veins; 16 – Minor circulus arteriosus of iris

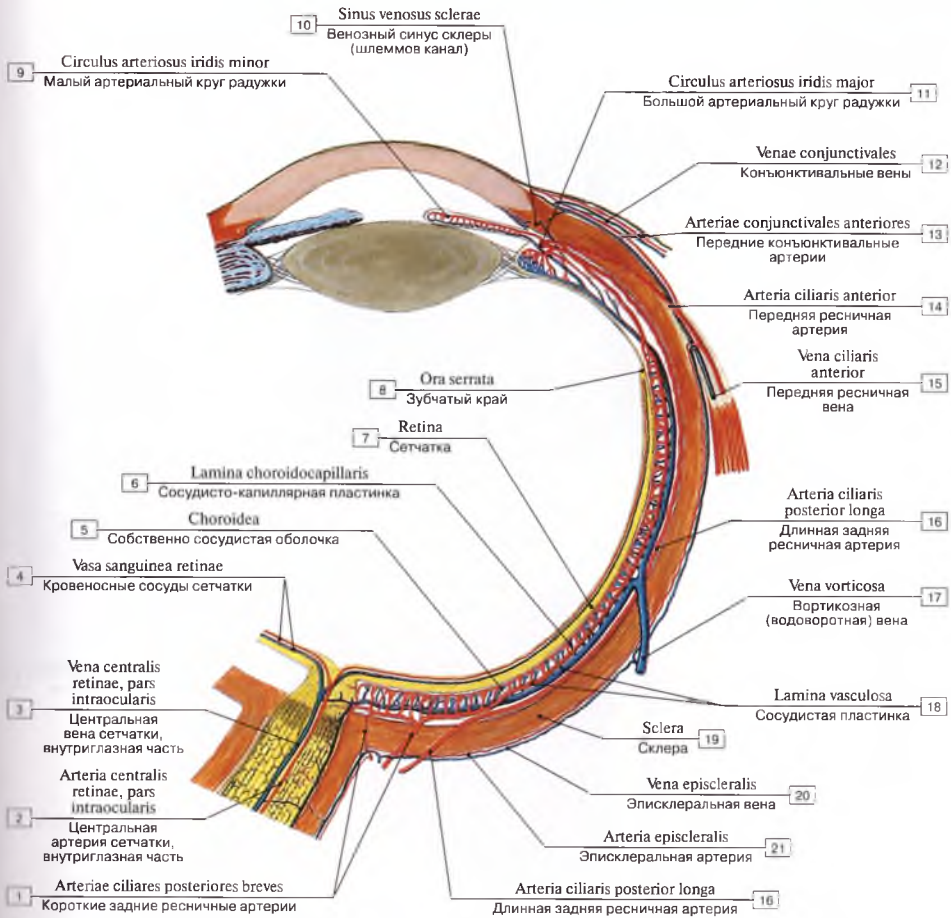


Рис. 475. Оболочки глаза:

1 — Short posterior ciliary arteries; 2 — Central retinal artery, intra-ocular part; 3 — Central retinal vein, intra-ocular part; 4 — Retinal blood vessels; 5 — Choroid; 6 — Capillary lamina; 7 — Retina; 8 — Ora serrata; 9 — Minor circulus arteriosus of iris; 10 — Scleral venous sinus; 11 — Major circulus arteriosus of iris; 12 — Conjunctival veins; 13 — Anterior conjunctival arteries; 14 — Anterior ciliary artery; 15 — Anterior ciliary vein; 16 — Long posterior ciliary artery; 17 — Vorticosose vein; 18 — Vascular lamina; 19 — Sclera; 20 — Episcleral vein; 21 — Episcleral artery

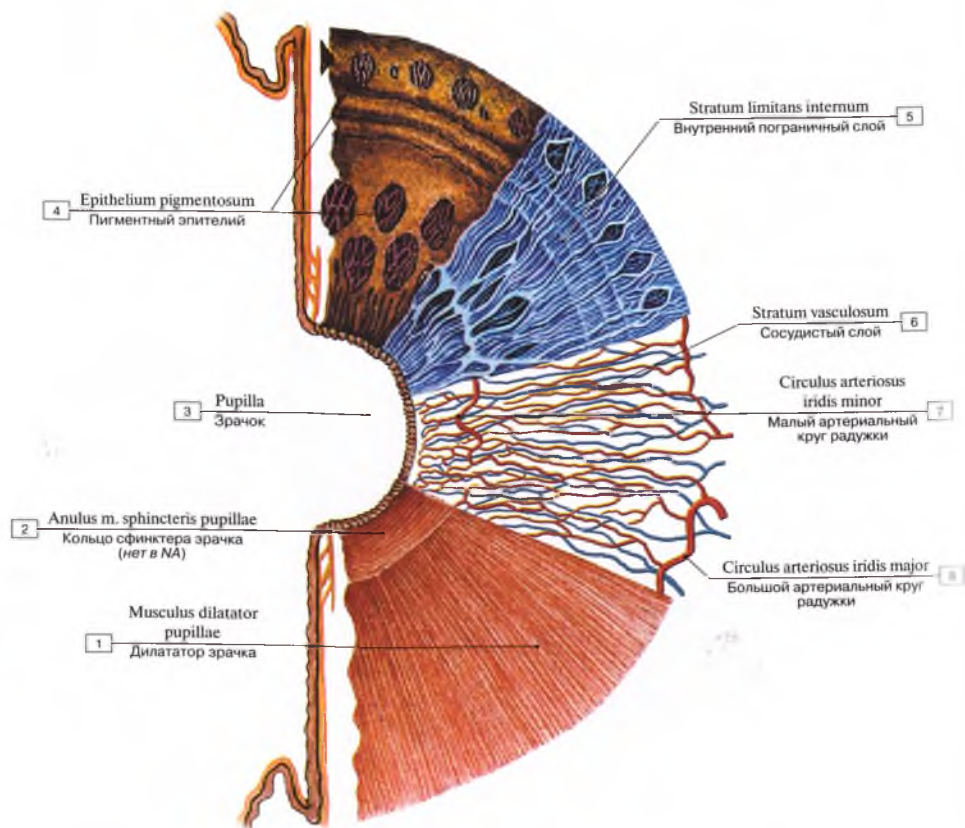


Рис. 476. Строение радужки глазного яблока (схема):

1 – Dilator pupillae; 2 – Anulus sphincter pupillae; 3 – Pupil; 4 – Pigmented epithelium; 5 – Inner limiting layer; 6 – Vascular layer;  
7 – Minor circulus arteriosus of iris; 8 – Major circulus arteriosus of iris

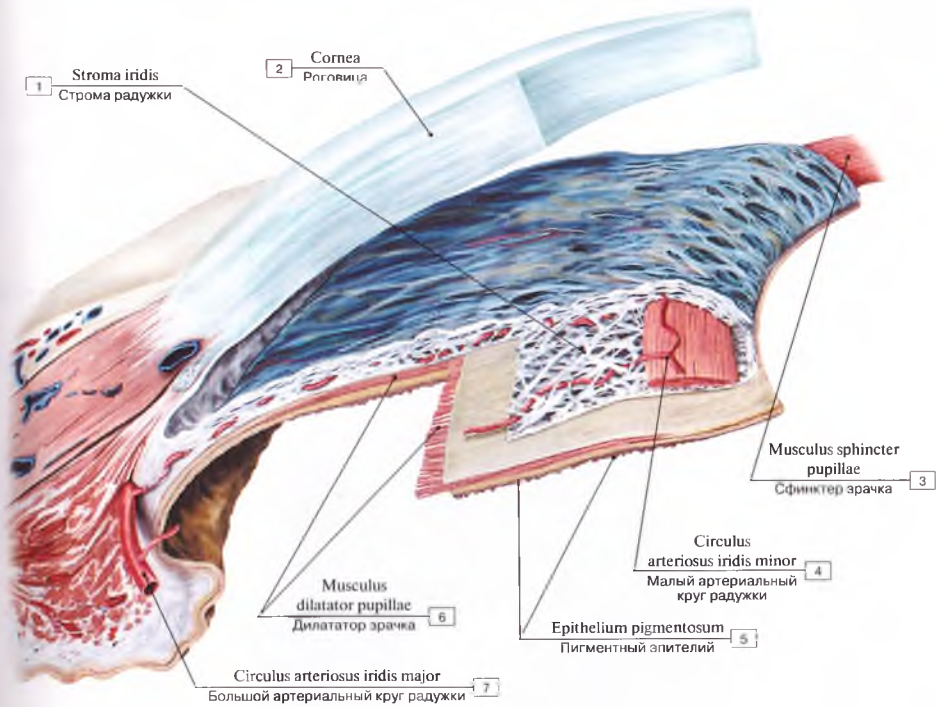


Рис. 477. Радужная оболочка:

1 – Stroma of iris; 2 – Cornea; 3 – Sphincter pupillae; 4 – Minor circulus arteriosus of iris; 5 – Pigmented epithelium; 6 – Dilator pupillae; 7 – Major circulus arteriosus of iris

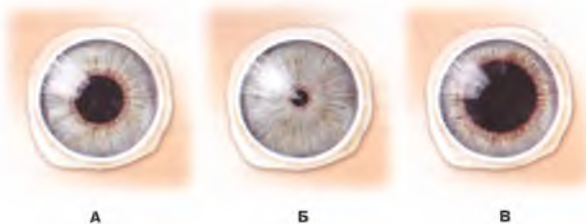

Рис. 478. Размеры зрачка (А – нормальный размер зрачка; Б – максимальная констрикция (миоз); В – максимальная дилатация (мидриаз))

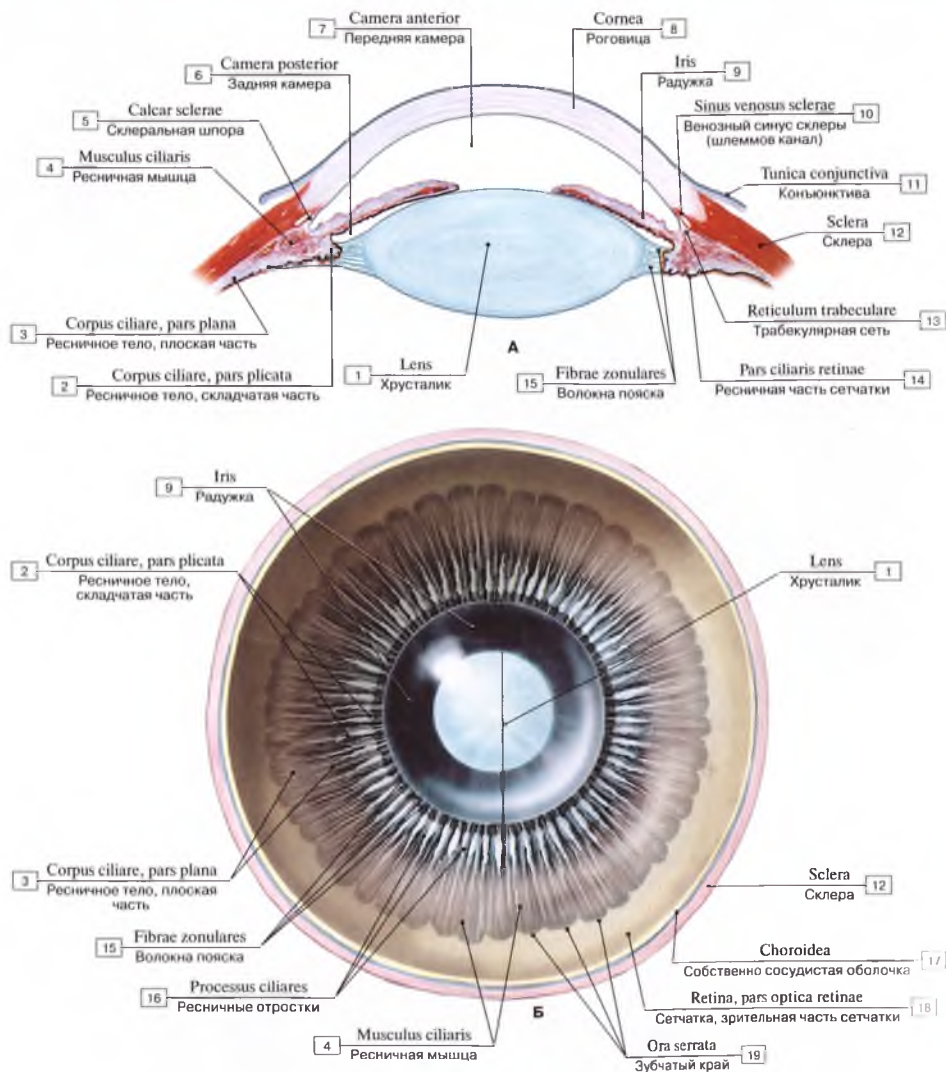


Рис. 479. Камеры глаза (А); ресничное тело, хрусталик (Б) (схемы):

1 – Lens; 2 – Ciliary body, plicate part; 3 – Ciliary body, planes part; 4 – Ciliary muscle; 5 – Scleral spur; 6 – Posterior chamber; 7 – Anterior chamber; 8 – Cornea; 9 – Iris; 10 – Scleral venous sinus; 11 – Conjunctiva; 12 – Sclera; 13 – Trabecular reticulum; 14 – Ciliary part of retina; 15 – Zonular fibres; 16 – Ciliary processes; 17 – Choroid; 18 – Retina, optic part of retina; 19 – Ora serrata

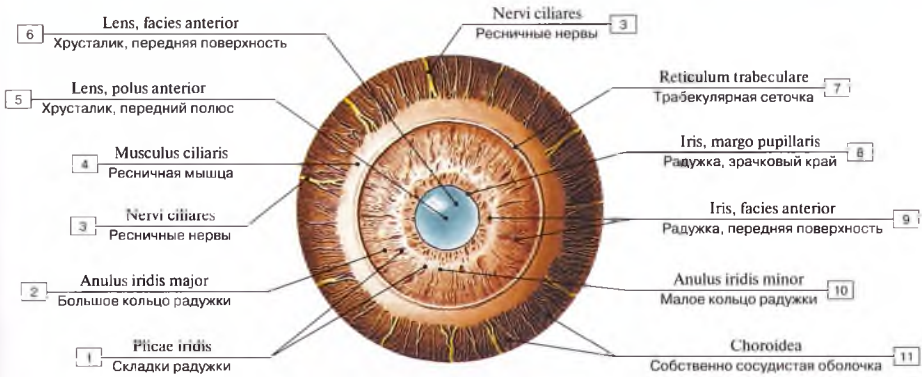


Рис. 480. Радужная оболочка, удалены склера и роговица, вид спереди:

1 – Folds of iris; 2 – Outer border of iris; 3 – Ciliary nerves; 4 – Ciliary muscle; 5 – Lens, anterior pole; 6 – Lens, anterior surface; 7 – Trabecular tissue; 8 – Iris, pupillary margin; 9 – Iris, anterior surface; 10 – Inner border of iris; 11 – Choroid

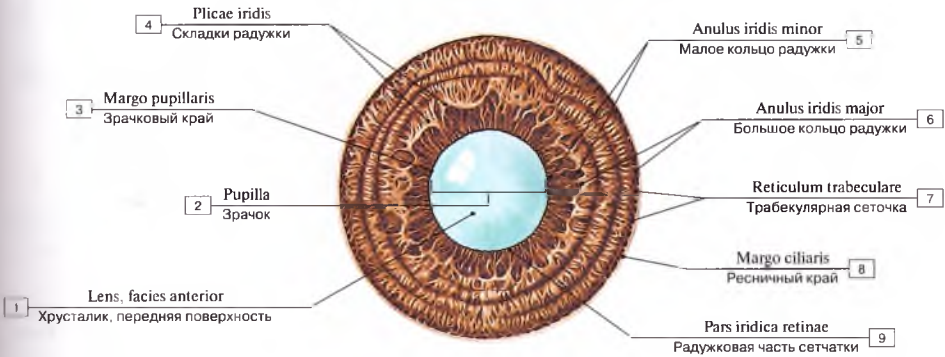


Рис. 481. Радужная оболочка, удалена склера, вид спереди:

1 – Lens, anterior surface; 2 – Pupil; 3 – Pupillary margin; 4 – Folds of iris; 5 – Inner border of iris; 6 – Outer border of iris; 7 – Trabecular tissue; 8 – Ciliary margin; 9 – Iridial part of retina



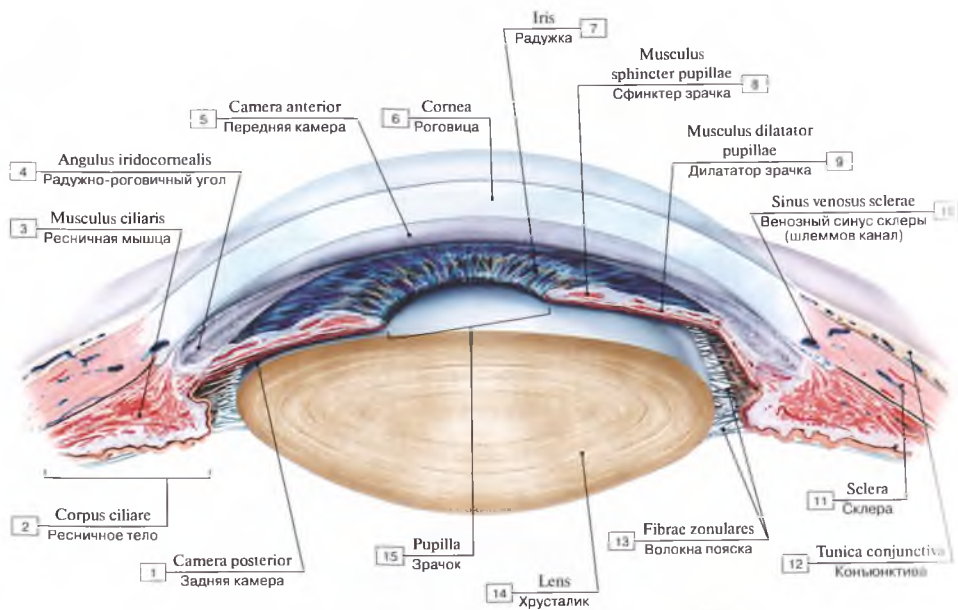


Рис. 482. Хрусталик (поперечное сечение через передний сегмент глаза, вид сверху):

1 – Posterior chamber; 2 – Ciliary body; 3 – Ciliary muscle; 4 – Iridocorneal angle; 5 – Anterior chamber; 6 – Cornea; 7 – Iris; 8 – Sphincter pupillae; 9 – Dilator pupillae; 10 – Scleral venous sinus; 11 – Sclera; 12 – Conjunctiva; 13 – Zonular fibres; 14 – Lens; 15 – Pupil

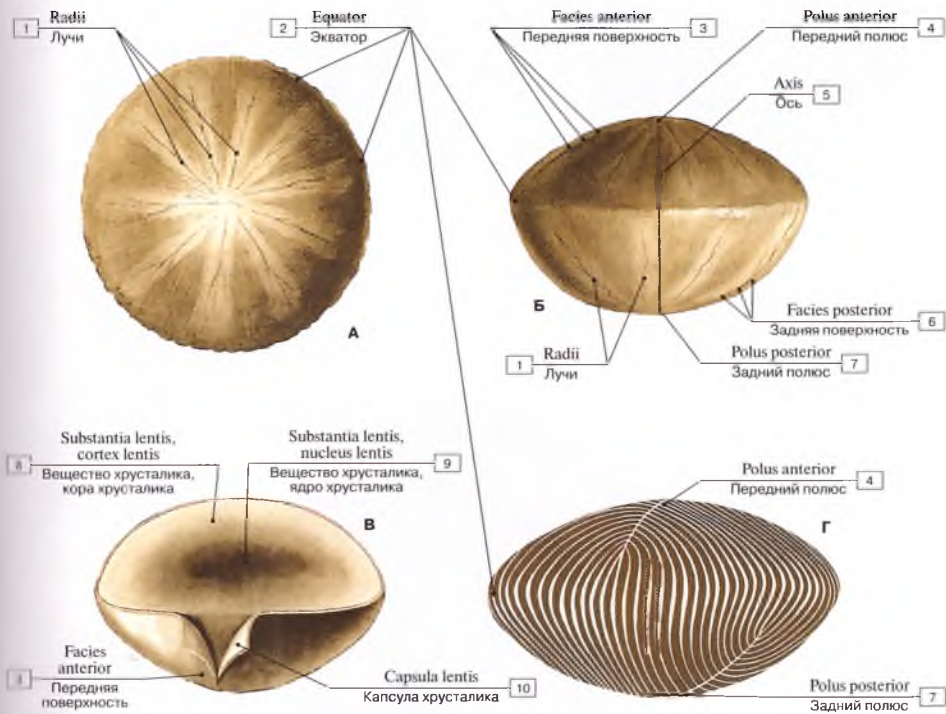


Рис. 483. Изолированный хрусталик (А – вид сверху; Б – вид сбоку; В – косой срез; Г – схема расположения волокон хрусталика у новорожденного);

1 – Radii; 2 – Equator; 3 – Anterior surface; 4 – Anterior pole; 5 – Axis; 6 – Posterior surface; 7 – Posterior pole; 8 – Lens substance, cortex of lens; 9 – Lens substance, nucleus of lens; 10 – Capsule of lens

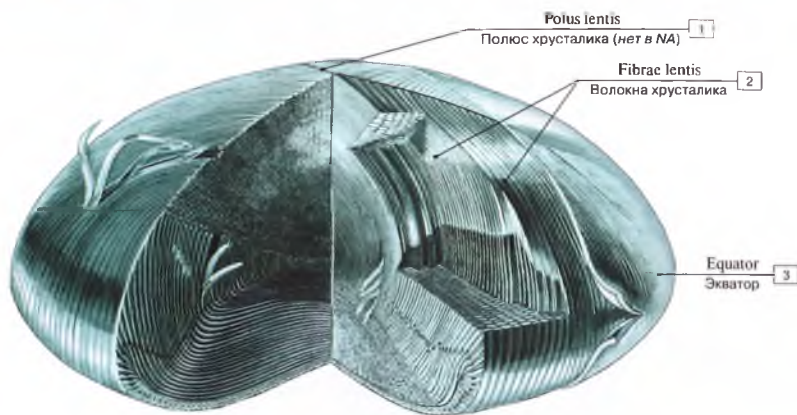


Рис. 484. Распространение волокон в хрусталике (объемная схема):

1 – Pole lens; 2 – Lens fibres; 3 – Equator

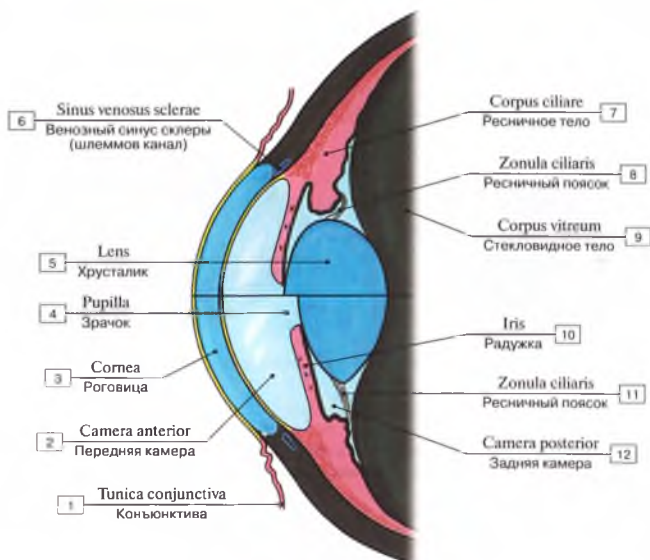
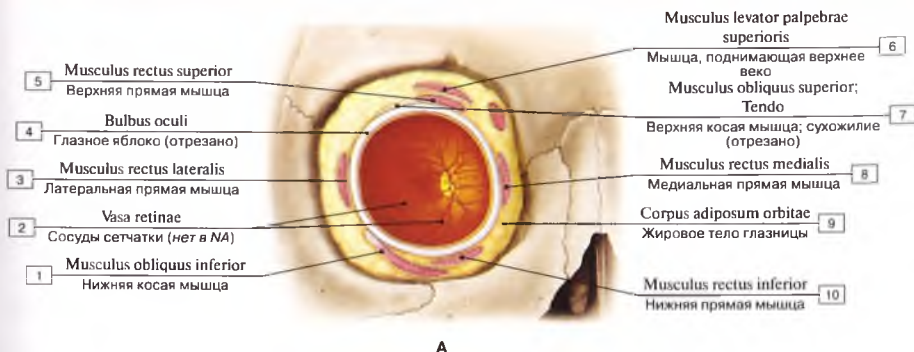
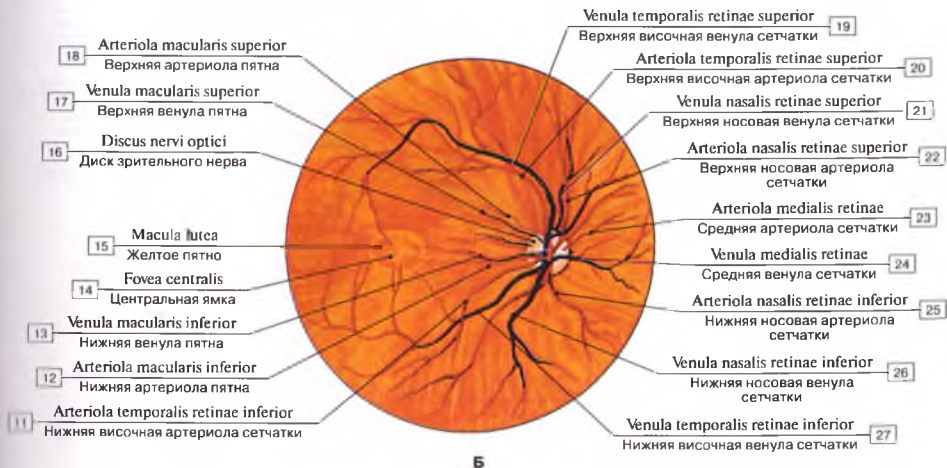


Рис. 485. Натянутый и ненатянутый хрусталик:

1 – Conjunctiva; 2 – Anterior chamber; 3 – Cornea; 4 – Pupil; 5 – Lens; 6 – Scleral venous sinus; 7 – Ciliary body; 8 – Cil  
9 – Vitreous body; 10 – Iris; 11 – Ciliary zonule; 12 – Posterior chamber



А



Б

Рис. 486. Дно глаза (А – общая проекция; Б – выделенный участок):

1 – Inferior oblique; 2 – Retinal vessels; 3 – Lateral rectus; 4 – Eyeball; 5 – Superior rectus; 6 – Levator palpebrae superioris; 7 – Superior oblique; Tendon; 8 – Medial rectus; 9 – Retrobulbar fat; Orbital fat body; 10 – Inferior rectus; 11 – Inferior temporal retinal arteriole; 12 – Inferior macular arteriole; 13 – Inferior macular venule; 14 – Fovea centralis; 15 – Macula; 16 – Optic disc; 17 – Superior macular venule; 18 – Superior macular arteriole; 19 – Superior temporal retinal venule; 20 – Superior temporal retinal arteriole; 21 – Superior nasal retinal venule; 22 – Superior nasal retinal arteriole; 23 – Medial retinal arteriole; 24 – Medial retinal venule; 25 – Inferior nasal retinal arteriole; 26 – Inferior nasal retinal venule; 27 – Inferior temporal retinal venule

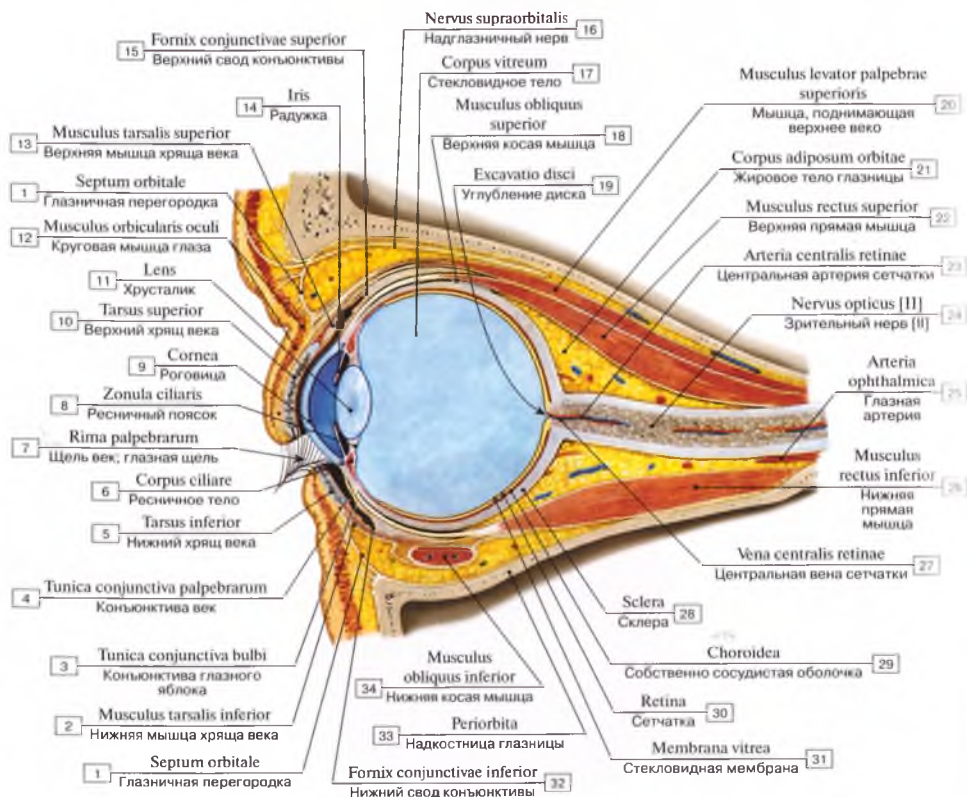


Рис. 487. Стекловидное тело:

1 – Orbital septum; 2 – Inferior tarsal muscle; 3 – Bulbar conjunctiva; 4 – Palpebral conjunctiva; 5 – Inferior tarsus; 6 – Ciliary body; 7 – Palpebral fissure; 8 – Ciliary zonule; 9 – Cornea; 10 – Superior tarsus; 11 – Lens; 12 – Orbicularis oculi; 13 – Superior tarsal muscle; 14 – Iris; 15 – Superior conjunctival fornix; 16 – Supra-orbital nerve; 17 – Vitreous body; 18 – Superior oblique; 19 – Depression of optic disc; 20 – Levator palpebrae superioris; 21 – Retrobulbar fat; 22 – Superior rectus; 23 – Central retinal artery; 24 – Optic nerve [II]; 25 – Ophthalmic artery; 26 – Inferior rectus; 27 – Central retinal vein; 28 – Sclera; 29 – Choroid; 30 – Retina; 31 – Vitreous membrane; 32 – Inferior conjunctival fornix; 33 – Periorbita; 34 – Inferior oblique

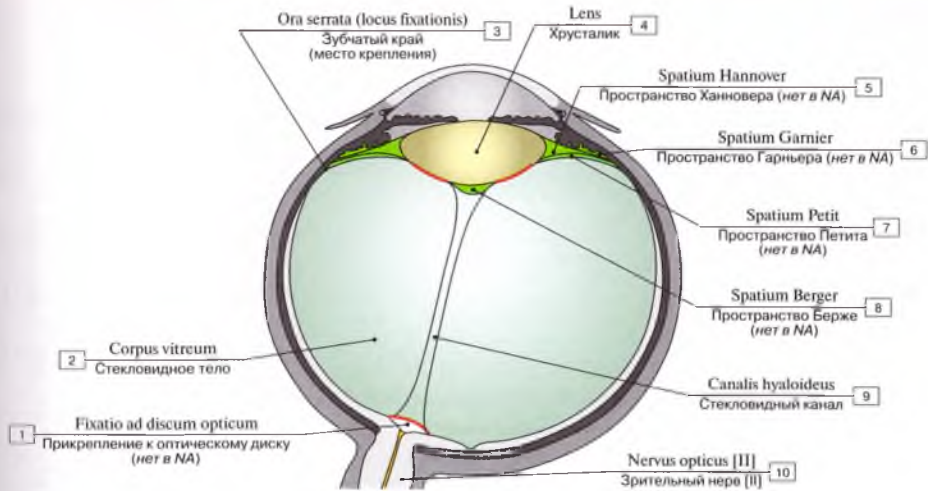


Рис. 488. Стекловидное тело (стекловидная жидкость):

1 – Attachment to optic disc (Martegiani ring); 2 – Vitreous body; 3 – Ora serrata (site of attachment); 4 – Lens; 5 – Hannover space; 6 – Garnier space; 7 – Petit space; 8 – Berger space; 9 – Hyaloid canal; 10 – Optic nerve [II]

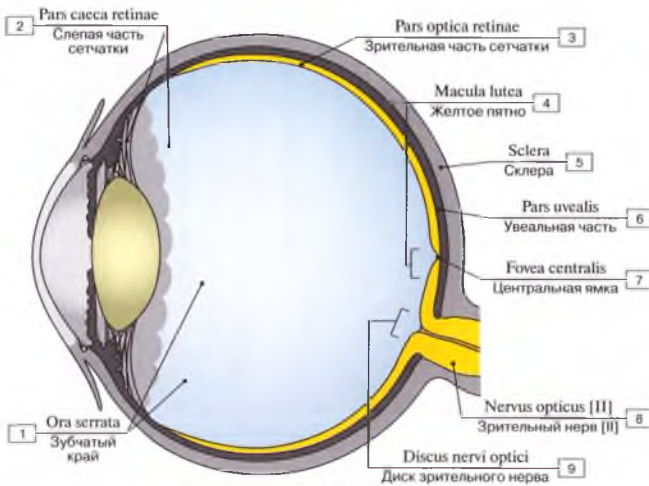


Рис. 489. Части сетчатки глаза:

1 – Ora serrata; 2 – Nonvisual retina; 3 – Optic part of retina; 4 – Macula; 5 – Sclera; 6 – Uveal part; 7 – Fovea centralis; 8 – Optic nerve [II]; 9 – Optic disc

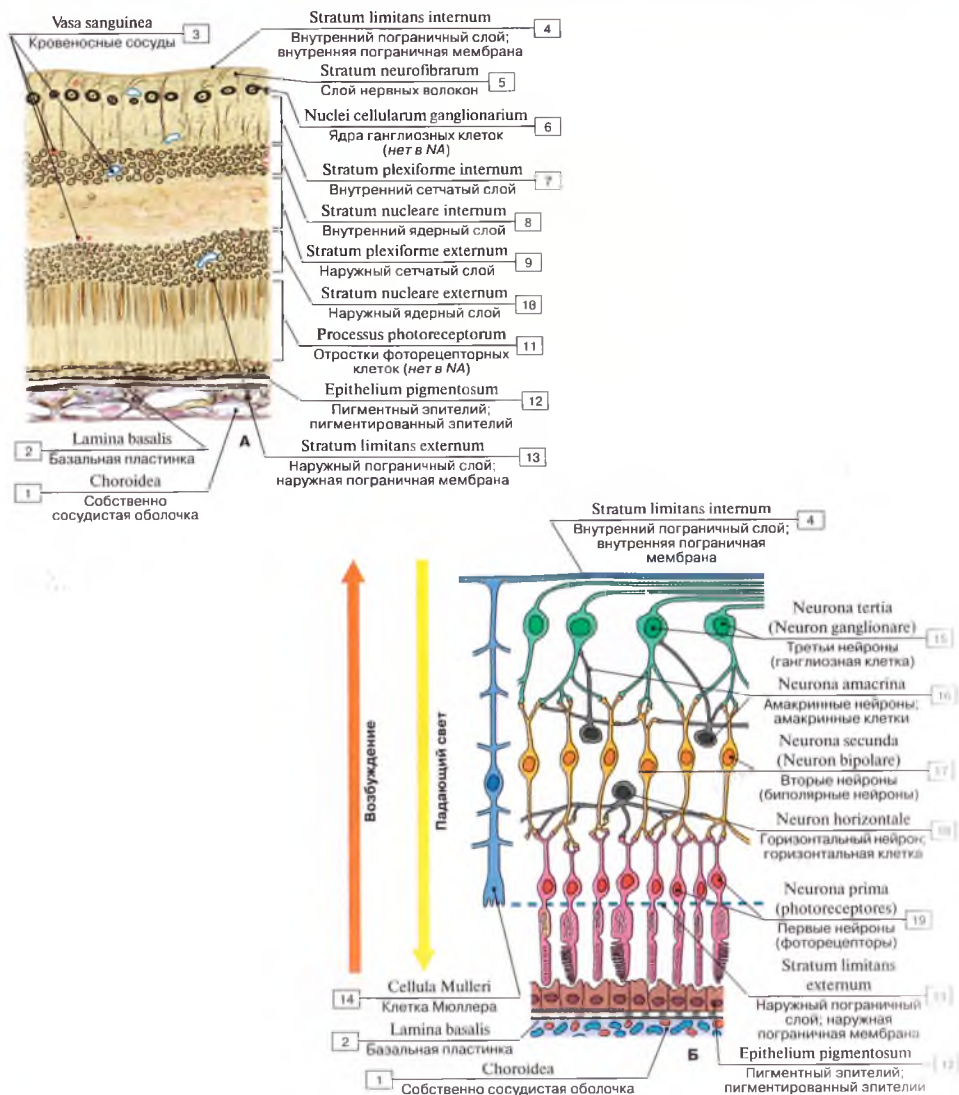


Рис. 490. Слои сетчатки (А), нейроны зрительного пути и их соединения (Б, схема):

1 – Choroid; 2 – Basal lamina; 3 – Blood vessels; 4 – Inner limiting layer; Inner limiting membrane; 5 – Layer of nerve fibres; 6 – Nuclei of ganglion cells; 7 – Internal plexiform layer; 8 – Inner nuclear layer; 9 – External plexiform layer; 10 – Outer nuclear layer; 11 – Processes of photoreceptor cells; 12 – Pigmented epithelium; 13 – Outer limiting layer; Outer limiting membrane; 14 – Muller cell; 15 – Third neurons (Ganglion cell); 16 – Amacrine cells; 17 – Second neurons (Bipolar cells); 18 – Fusiform horizontal cell; 19 – First neurons (photoreceptors).

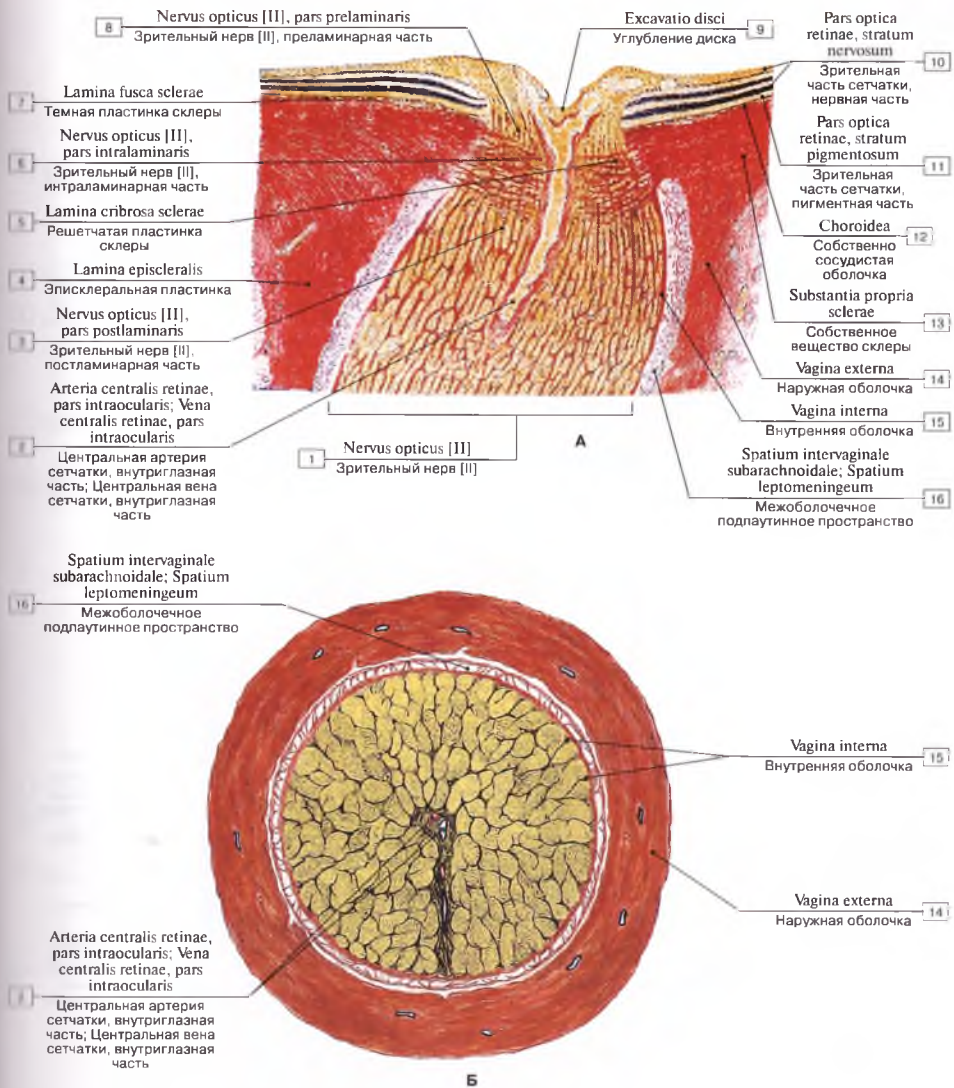


Рис. 491. Слепое пятно (А – продольный разрез; Б – поперечный разрез):

1 – Optic nerve [III]; 2 – Central retinal artery, intra-ocular part; Central retinal vein, intra-ocular part; 3 – Optic nerve [II], postlaminar part; 4 – Episcleral layer; 5 – Lamina cribrosa of sclera; 6 – Optic nerve [II], intralaminar part; 7 – Dark lamina of sclera; 8 – Optic nerve [II], prelaminar part; 9 – Depression of optic disc; Physiological cup; 10 – Optic part of retina, neural layer; 11 – Optic part of retina, pigmented layer; 12 – Choroid; 13 – Substantia propria; 14 – Outer sheath; 15 – Inner sheath; 16 – Subarachnoid space; Leptomeningeal space



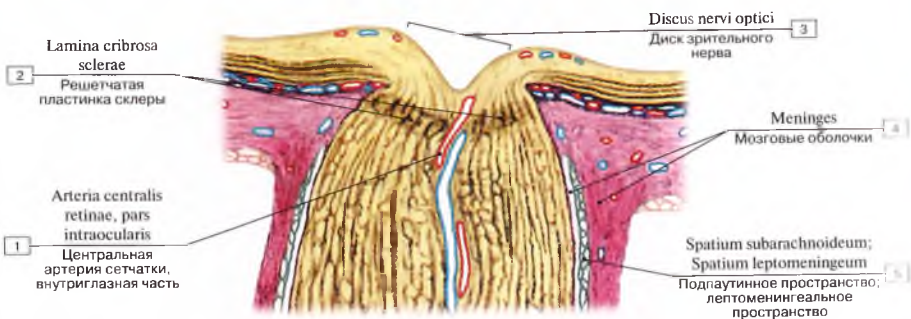


Рис. 492. Оптический диск (слепое пятно) и решетчатая пластинка склеры:

1 – Central retinal artery, intra-ocular part; 2 – Lamina cribrosa of sclera; 3 – Optic disc; 4 – Meninges; 5 – Subarachnoid space; Leptomeningeal space

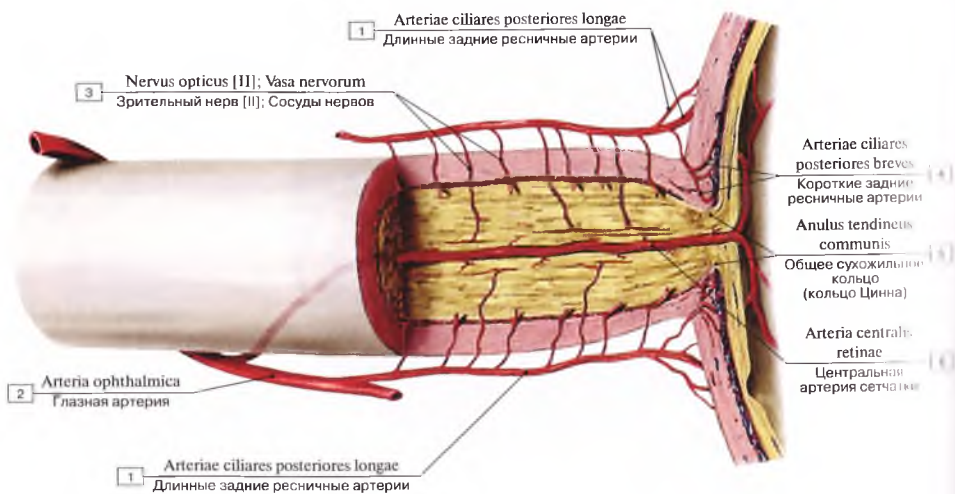


Рис. 493. Артерия глазного нерва:

1 – Long posterior ciliary arteries; 2 – Ophthalmic artery; 3 – Optic nerve [II]; Vessels of nerve; 4 – Short posterior ciliary arteries; 5 – Common annular tendon; 6 – Central retinal artery

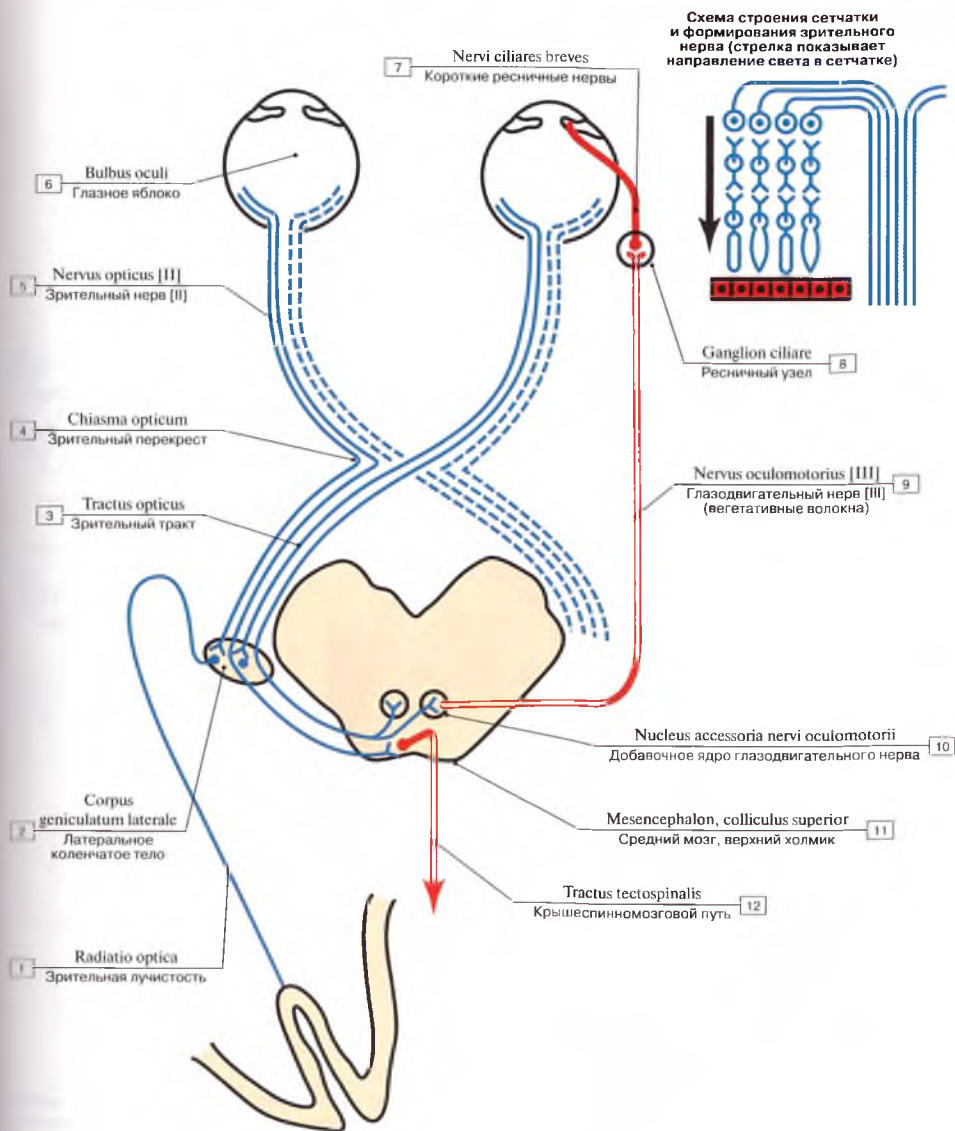


Рис. 494. Проводящий путь зрительного анализатора:

1 – Optic radiation; 2 – Lateral geniculate body; 3 – Optic tract; 4 – Optic chiasm; 5 – Optic nerve [II]; 6 – Eyeball; 7 – Short ciliary nerves; 8 – Ciliary ganglion; 9 – Oculomotor nerve [III]; 10 – Accessory nucleus of oculomotor nerve; 11 – Mesencephalon; Midbrain, superior colliculus; 12 – Tectospinal tract

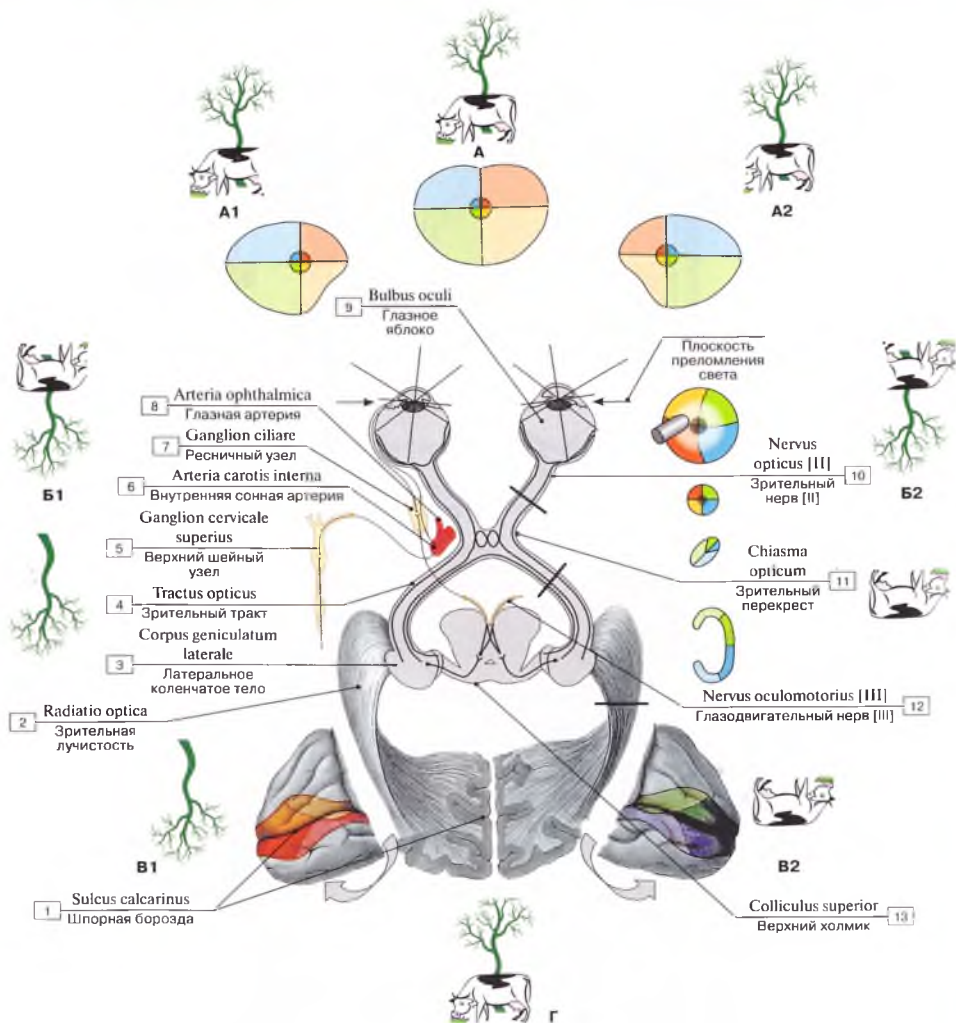


Рис. 495. Оптический путь (схема), вид сверху (А – общее поле зрения, А1 – поле зрения левого глаза, А2 – поле зрения правого глаза; В1 – проекция на левую сетчатку, В2 – проекция на правую сетчатку; В1 – проекция на кору левого полушария в области шпорной борозды, В2 – проекция на кору правого полушария в области шпорной борозды; Г – общее поле зрения как результат интегративных достижений мозга):

1 – Calcarine sulcus; 2 – Optic radiation; 3 – Lateral geniculate body; 4 – Optic tract; 5 – Superior cervical ganglion; 6 – Internal carotid artery; 7 – Ciliary ganglion; 8 – Ophthalmic artery; 9 – Eyeball; 10 – Optic nerve [II]; 11 – Optic chiasm; Optic chiasma; 12 – Oculomotor nerve [III]; 13 – Superior colliculus

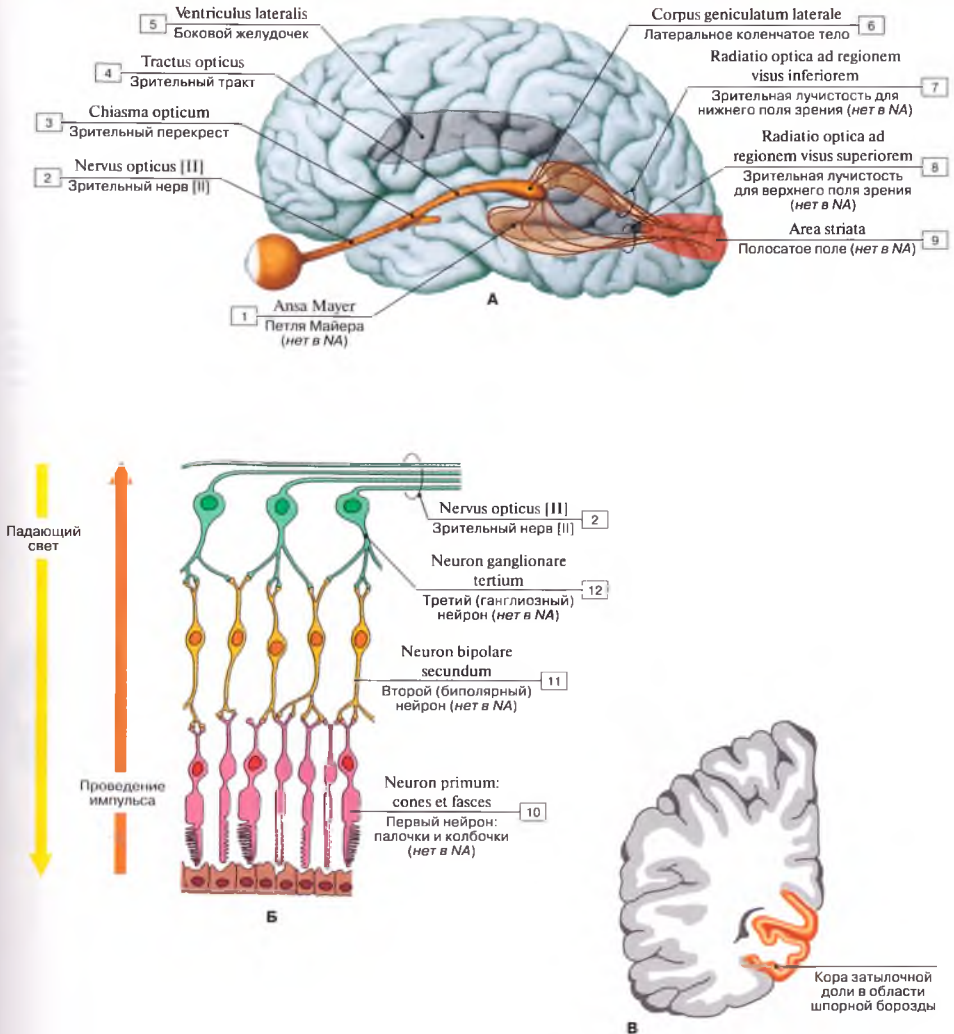


Рис. 496. Зрительный анализатор (А – общая схема; Б – сетчатка; В – корковый центр):

1 – Meyer's loop; 2 – Optic nerve [III]; 3 – Optic chiasma; Optic chiasma; 4 – Optic tract; 5 – Lateral ventricle; 6 – Lateral geniculate body; 7 – Optic radiation for lower visual field; 8 – Optic radiation for upper visual field; 9 – Striate area; 10 – First neuron: rods and cones; 11 – Second neuron: bipolar cells; 12 – Third neuron: ganglion cell

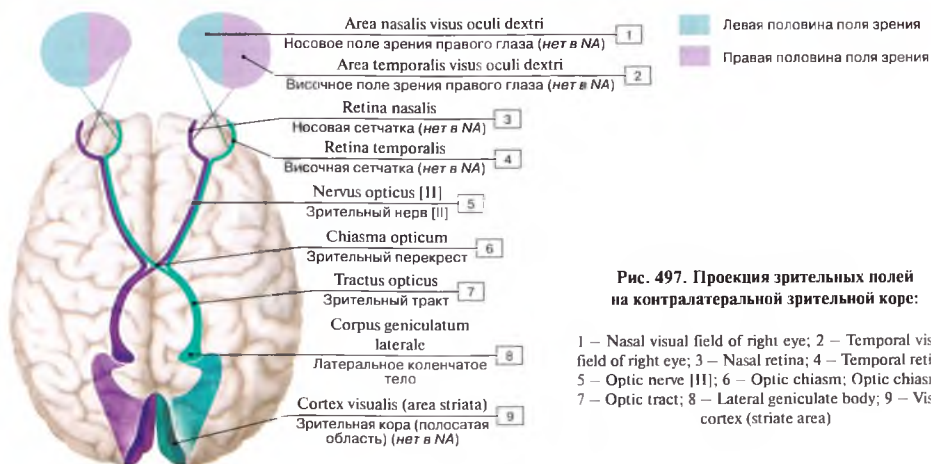


Рис. 497. Проекция зрительных полей на контралатеральной зрительной коре:

- 1 – Nasal visual field of right eye; 2 – Temporal visual field of right eye; 3 – Nasal retina; 4 – Temporal retina; 5 – Optic nerve [II]; 6 – Optic chiasm; Optic chiasm; 7 – Optic tract; 8 – Lateral geniculate body; 9 – Visual cortex (striate area)

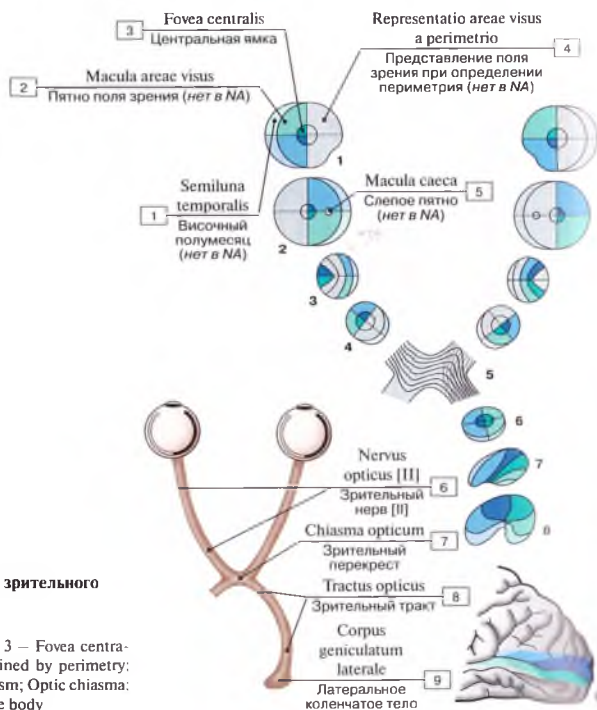


Рис. 498. Топография колленчатой части зрительного проводящего пути:

- 1 – Temporal crescent; 2 – Macular visual field; 3 – Fovea centralis; 4 – Representation of visual field as determined by perimetry; 5 – Blind spot; 6 – Optic nerve [II]; 7 – Optic chiasm; Optic chiasm; 8 – Optic tract; 9 – Lateral geniculate body

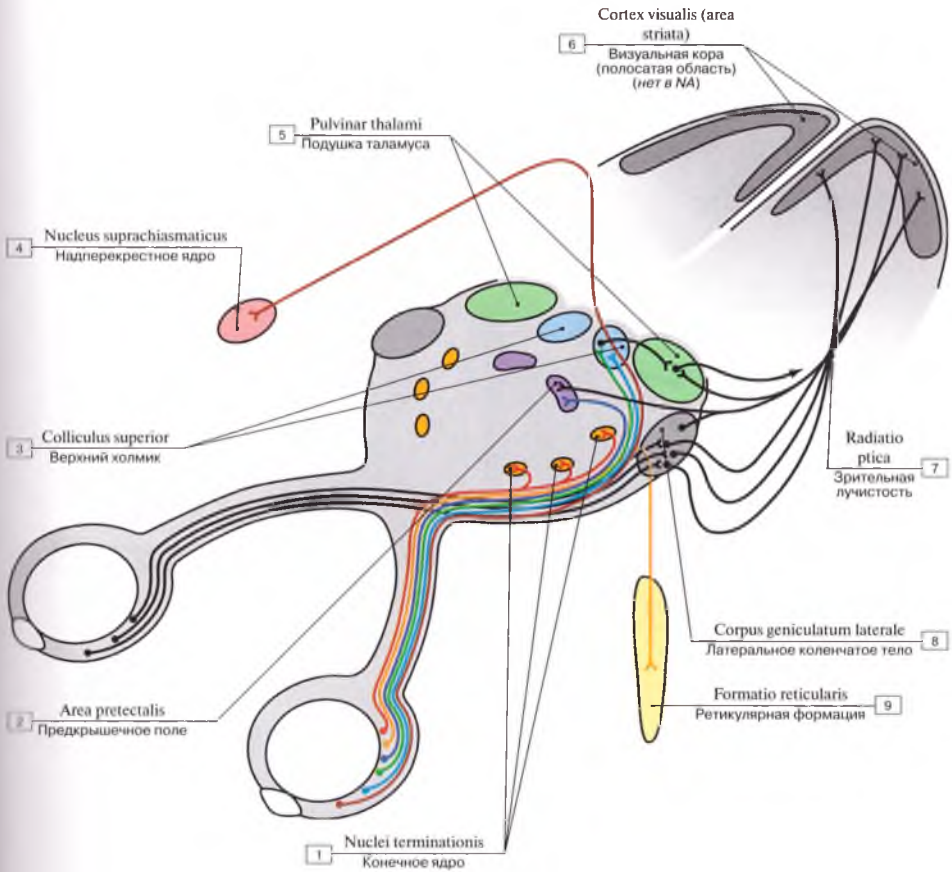


Рис. 499. Неколеничатая часть зрительного проводящего пути:

- 1 – Terminal nucleus; 2 – Pretectal area; 3 – Superior colliculus; 4 – Suprachiasmatic nucleus; 5 – Pulvinar; 6 – Visual cortex (striate area); 7 – Optic radiation; 8 – Lateral geniculate body; 9 – Reticular formation

- I – Зрачковый рефлекс  
 II – Вестибулоокулярный рефлекс  
 III – Рефлекс роговицы

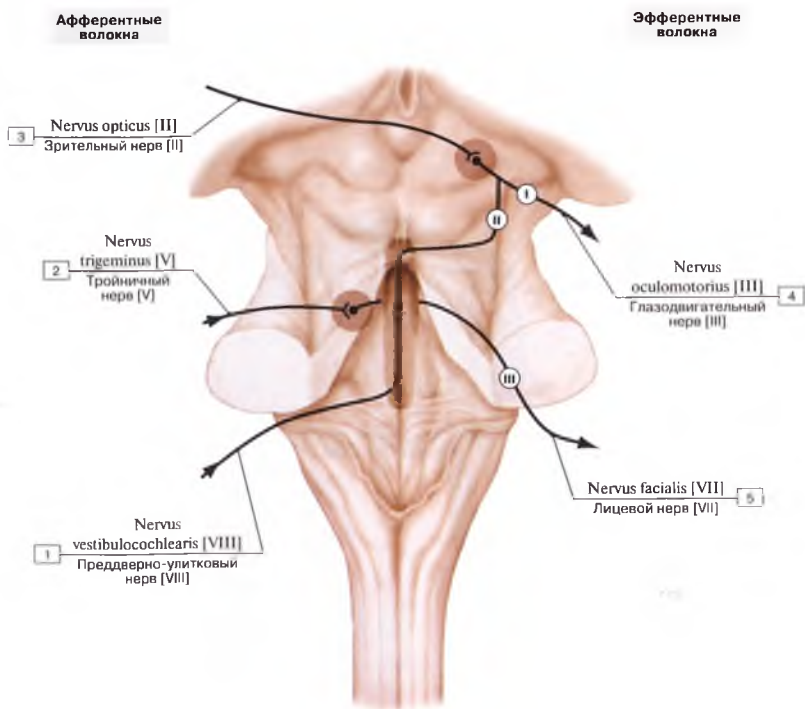


Рис. 500. Рефлексы ствола мозга:

1 – Vestibulocochlear nerve [VIII]; 2 – Trigeminal nerve [V]; 3 – Optic nerve [II]; 4 – Oculomotor nerve [III]; 5 – Facial nerve [VII]

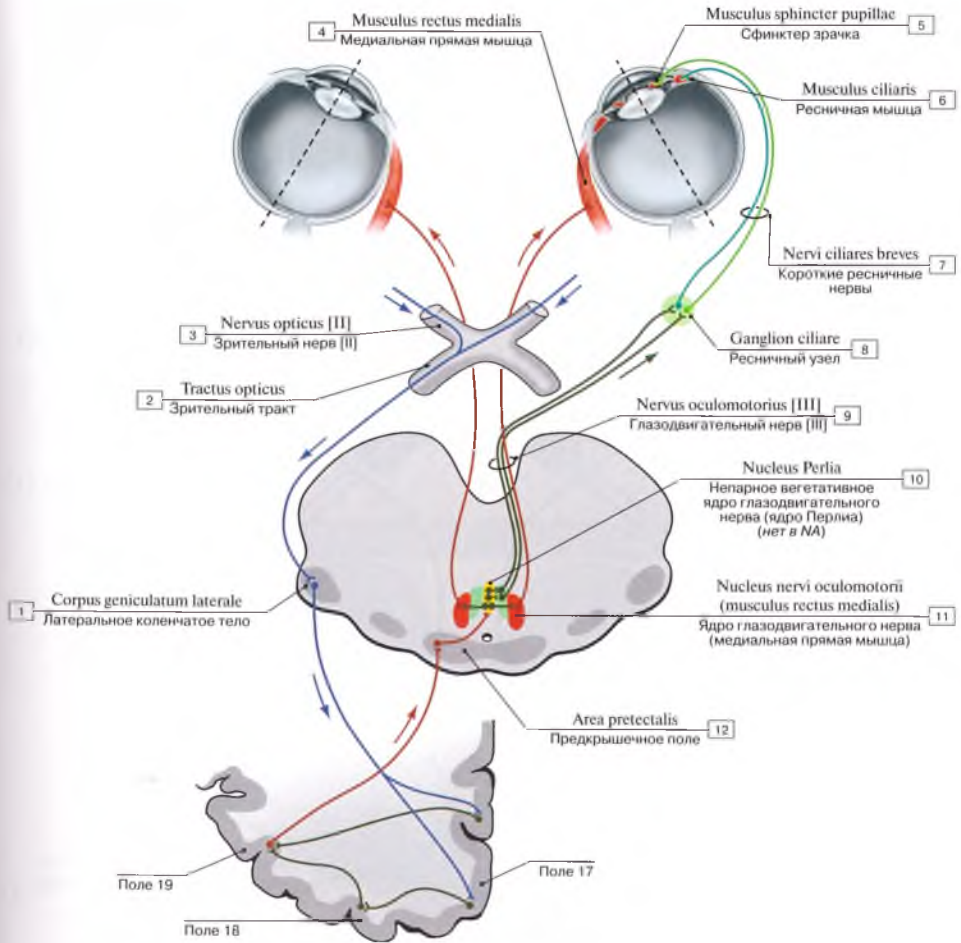


Рис. 501. Проводящие пути для функций конвергенции и аккомодации:

1 – Lateral geniculate body; 2 – Optic tract; 3 – Optic nerve [II]; 4 – Medial rectus; 5 – Sphincter pupillae; 6 – Ciliary muscle; 7 – Short ciliary nerves; 8 – Ciliary ganglion; 9 – Oculomotor nerve [III]; 10 – Perlia's nucleus; 11 – Nucleus of oculomotor nerve (medial rectus); 12 – Pretectal area

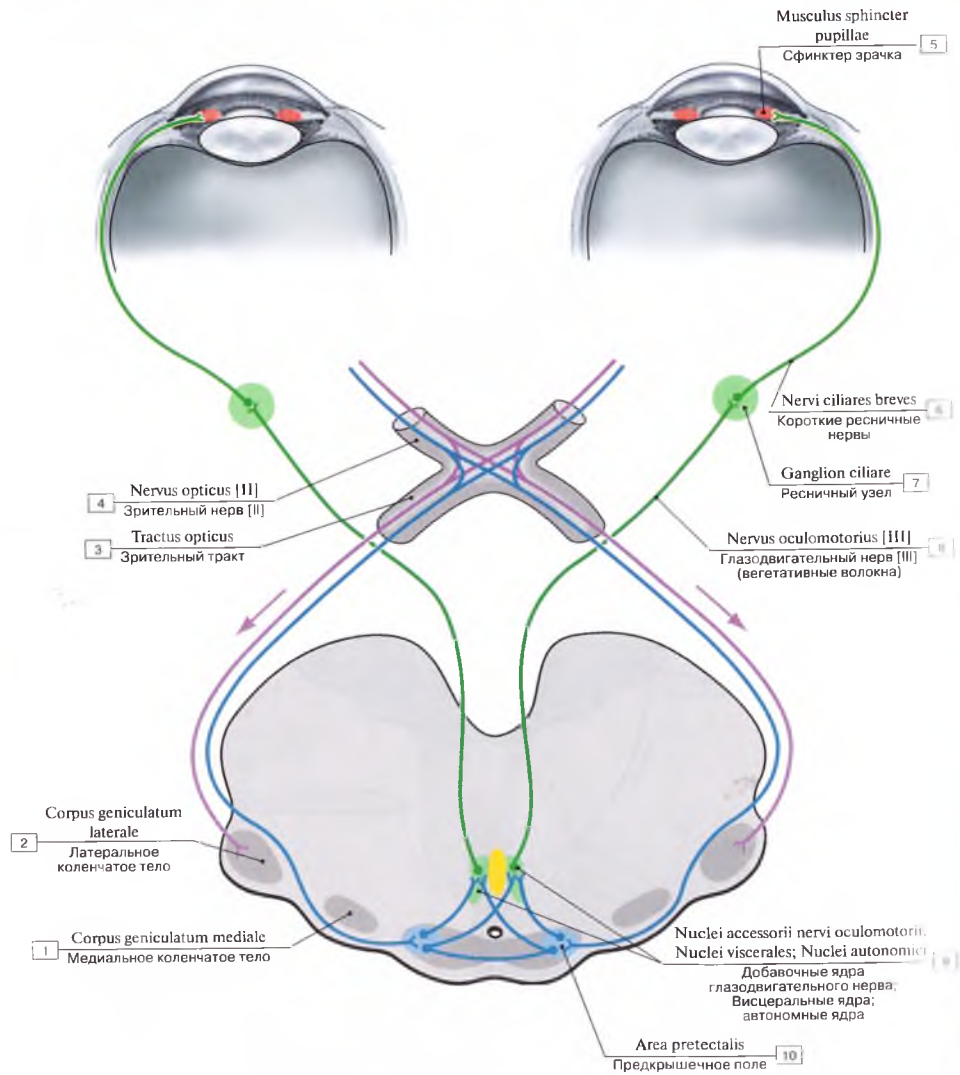


Рис. 502. Регуляция размера зрачка – световой рефлекс:

1 – Medial geniculate body; 2 – Lateral geniculate body; 3 – Optic tract; 4 – Optic nerve [II]; 5 – Sphincter pupillae; 6 – Short ciliary nerves; 7 – Ciliary ganglion; 8 – Oculomotor nerve [III]; 9 – Accessory nuclei of oculomotor nerve; 10 – Pretectal area

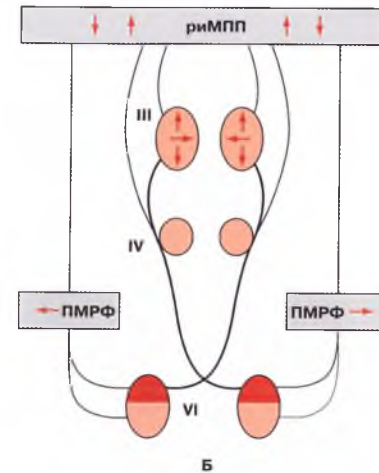
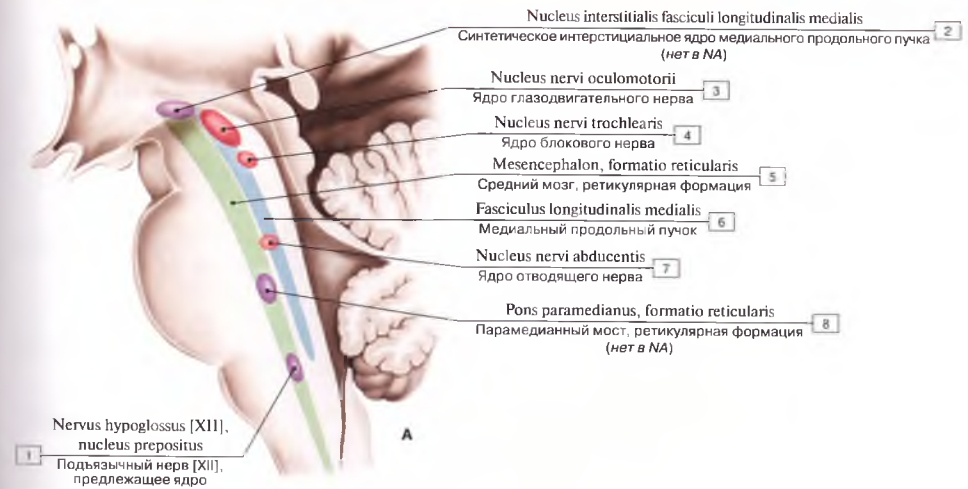


Рис. 503. Расположение ядер нервов, управляющих движениями глазодвигательных мышц в стволе мозга (А – сагиттальный разрез; Б – схема показывает организацию движения глаза):

1 – Hypoglossal nerve [XII], prepositus nucleus; 2 – Interstitial nucleus of medial longitudinal fasciculus; 3 – Nucleus of oculomotor nerve; 4 – Nucleus of trochlear nerve; 5 – Mesencephalon; Midbrain, reticular formation; 6 – Medial longitudinal fasciculus; 7 – Nucleus of abducens nerve; 8 – Paramedian pons, reticular formation



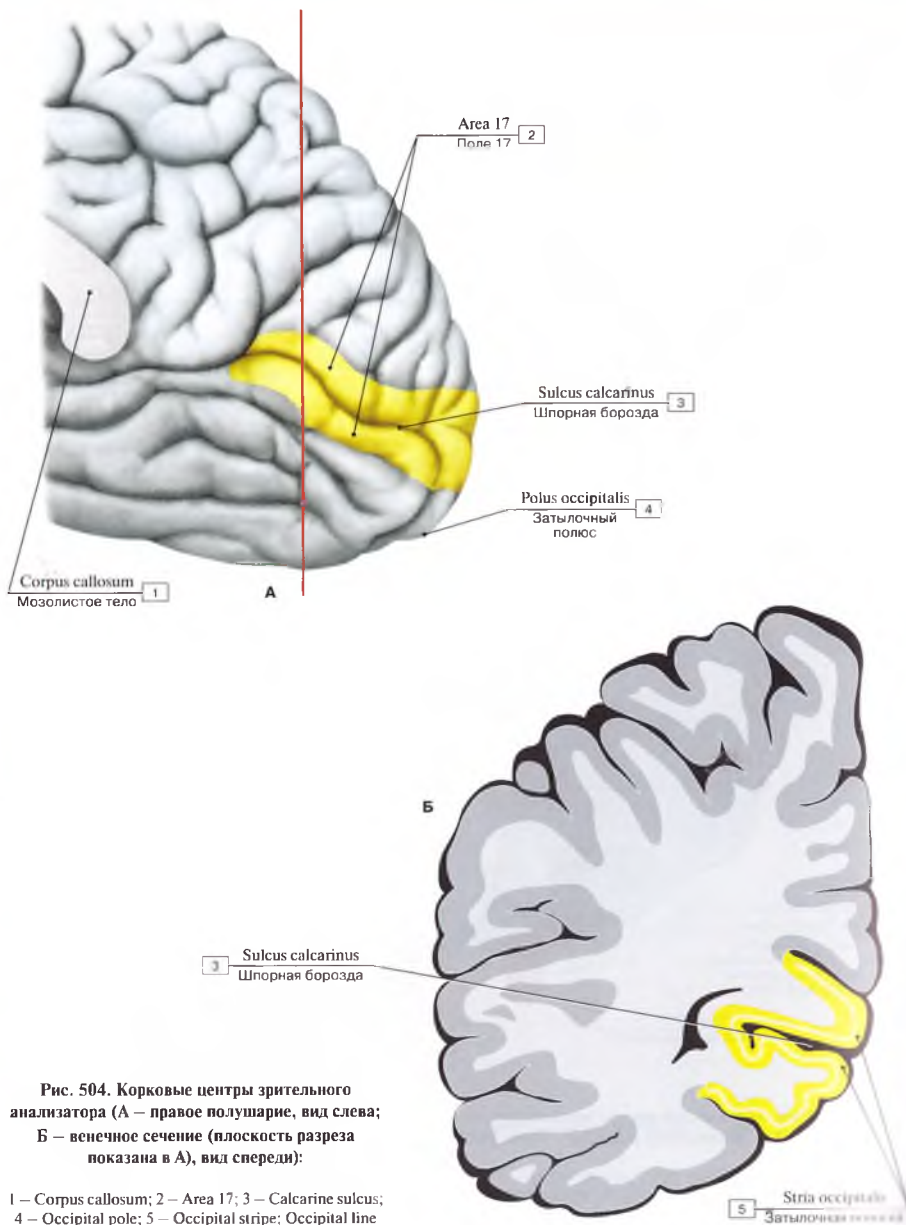


Рис. 504. Кортиковые центры зрительного анализатора (А – правое полушарие, вид слева; Б – венечное сечение (плоскость разреза показана в А), вид спереди):

1 – Corpus callosum; 2 – Area 17; 3 – Calcarine sulcus;  
4 – Occipital pole; 5 – Occipital stripe; Occipital line

ОРГАН СЛУХА И РАВНОВЕСИЯ

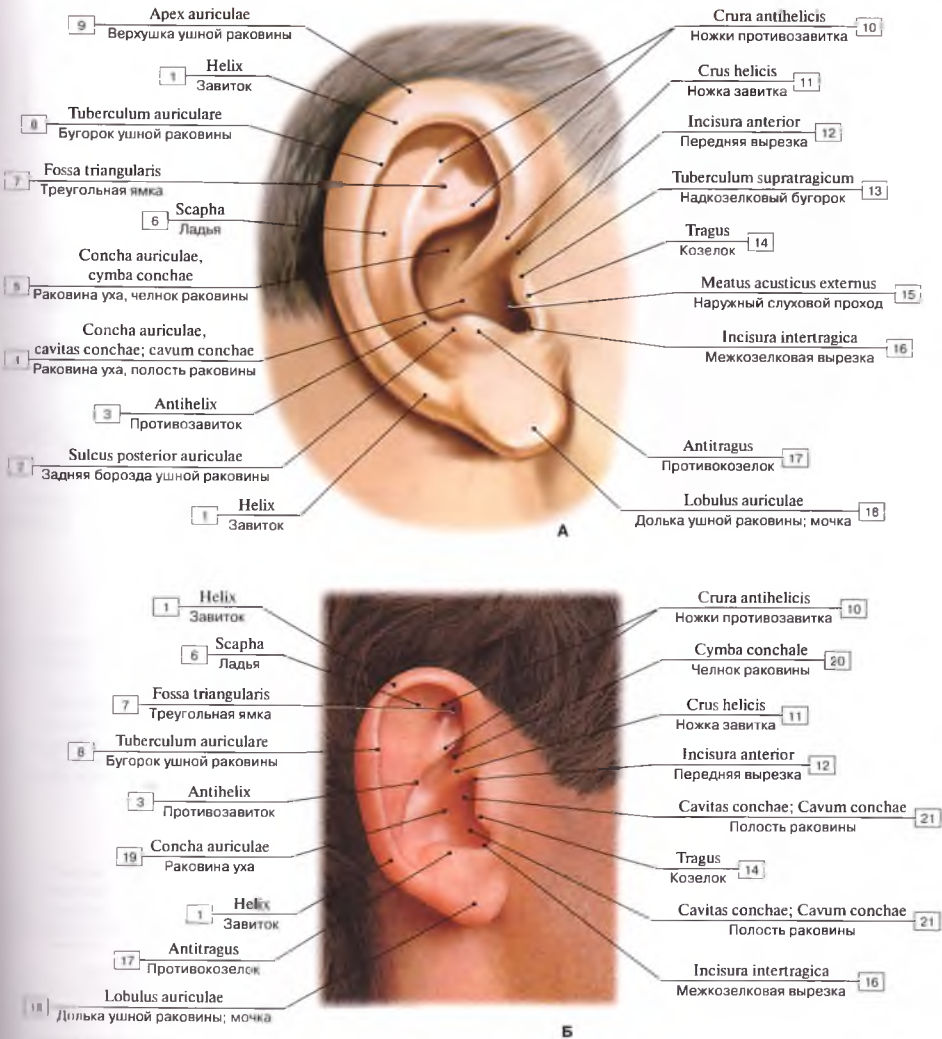


Рис. 505. Наружное ухо (А – схема; Б – фотография):

1 – Helix; 2 – Posterior auricular groove; 3 – Antihelix; 4 – Concha of auricle, cavity of concha; 5 – Concha of auricle, cymba conchae; 6 – Scapha; 7 – Triangular fossa; 8 – Auricular tubercle; 9 – Apex of auricle; Tip of ear; 10 – Crura of antihelix; 11 – Crus of helix; 12 – Anterior notch; 13 – Supratragic tubercle; 14 – Tragus; 15 – External acoustic meatus; 16 – Intertragic incisure; 17 – Antitragus; 18 – Lobule of auricle; Lobe of ear; 19 – Concha of auricle; 20 – Cymba conchae; 21 – Cavity of concha

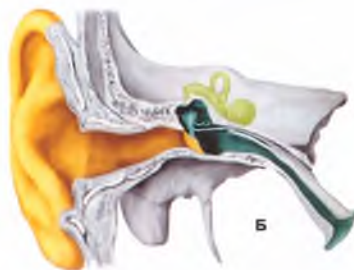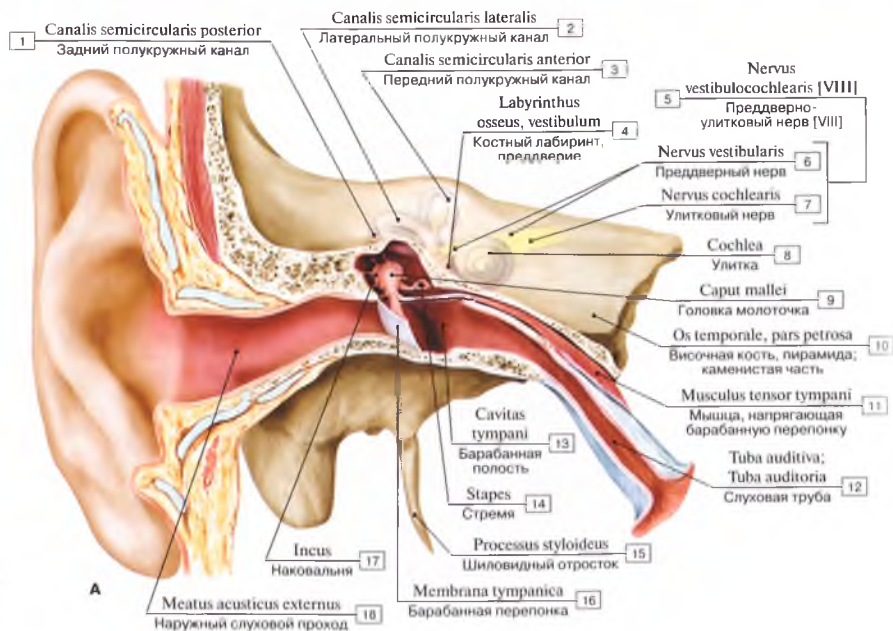


Рис. 506. Слуховой и вестибулярный аппараты в естественном положении (А – фронтальный разрез через правое ухо, вид спереди; Б – основные части слухового аппарата: наружное ухо (желтый цвет), среднее ухо (синий цвет) и внутреннее ухо (зеленый цвет):

1 – Posterior semicircular canal; 2 – Lateral semicircular canal; 3 – Anterior semicircular canal; 4 – Bony labyrinth, vestibule; 5 = 6 + 7 – Vestibulocochlear nerve [VIII]; 6 – Vestibular nerve; 7 – Cochlear nerve; 8 – Cochlea; 9 – Head of malleus; 10 – Temporal bone, petrous part; 11 – Tensor tympani; 12 – Pharyngotympanic tube; Auditory tube; 13 – Tympanic cavity; 14 – Stapes; 15 – Styloid process; 16 – Tympanic membrane; 17 – Incus; 18 – External acoustic meatus

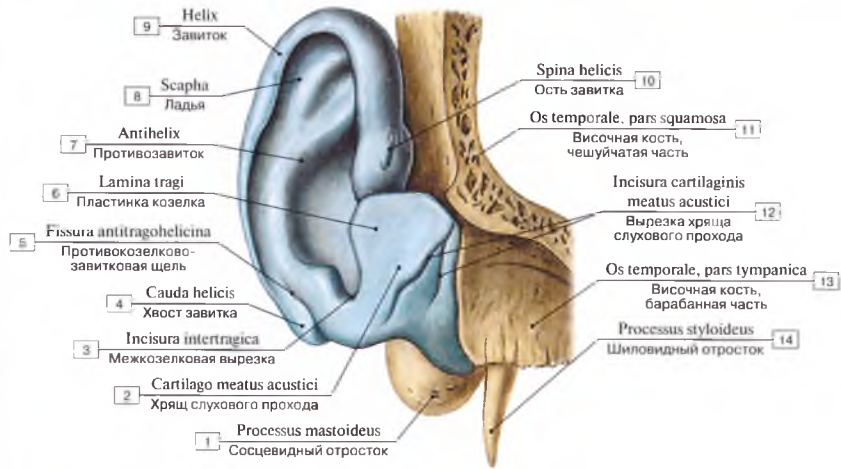


Рис. 507. Хрящ уха:

1 – Mastoid process; 2 – Cartilage of acoustic meatus; 3 – Intertragic incisure; Intertragic notch; 4 – Tail of helix; 5 – Fissura antitragohelicina; 6 – Tragal lamina; 7 – Antihelix; 8 – Scarpha; 9 – Helix; 10 – Spine of helix; 11 – Temporal bone, squamous part; 12 – Notch in cartilage of acoustic meatus; 13 – Temporal bone, tympanic part; 14 – Styloid process

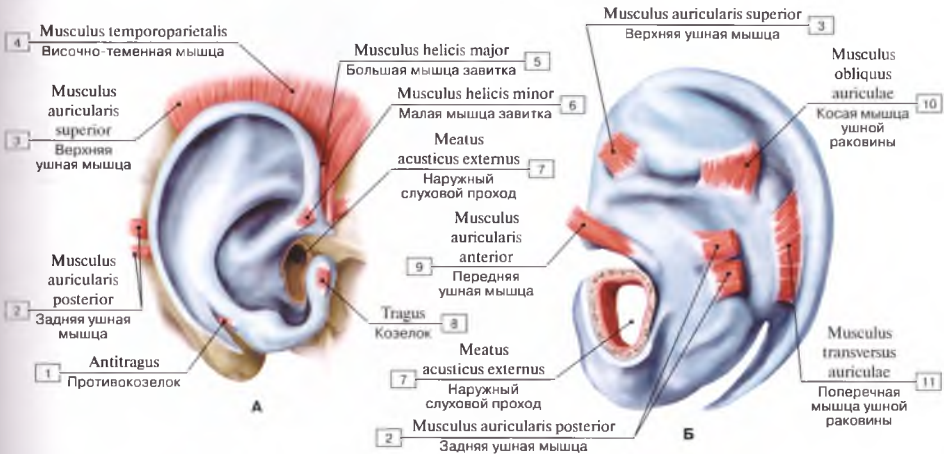


Рис. 508. Хрящи и мышцы ушной раковины (А – вид сбоку на наружную поверхность; Б – вид с медиальной стороны на заднюю поверхность правого уха):

1 – Antitragus; 2 – Auricularis posterior; 3 – Auricularis superior; 4 – Temporoparietalis; 5 – Helicis major; 6 – Helicis minor; 7 – External acoustic meatus; 8 – Tragus; 9 – Auricularis anterior; 10 – Oblique muscles of auricle; 11 – Transverse muscle of auricle

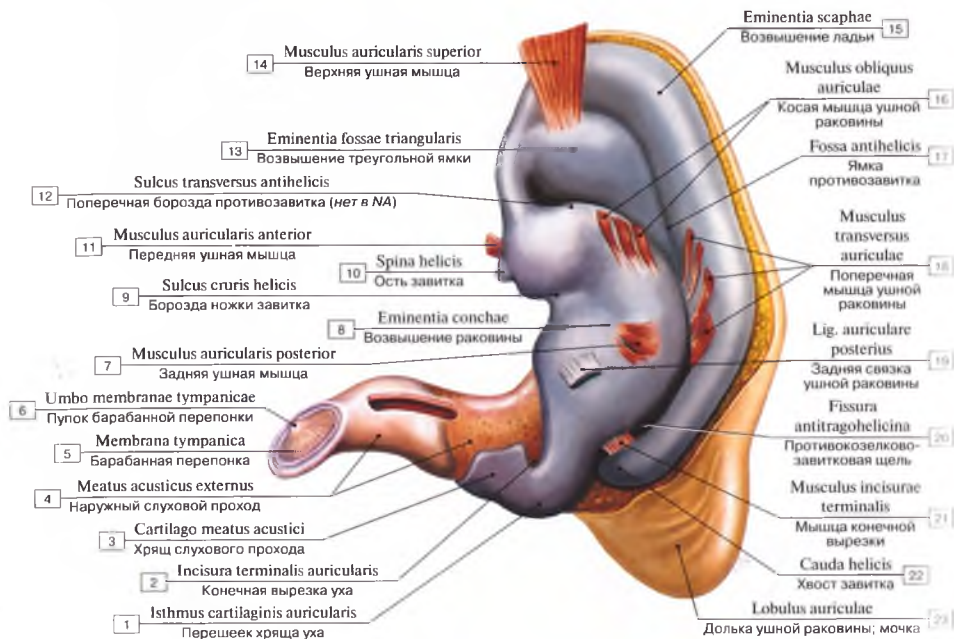


Рис. 509. Наружный слуховой проход:

1 – Isthmus of cartilaginous auricle; 2 – Terminal notch of auricle; 3 – Cartilage of acoustic meatus; 4 – External acoustic meatus; 5 – Tympanic membrane; 6 – Umbo of tympanic membrane; 7 – Auricularis posterior; 8 – Eminentia conchae; 9 – Groove of crus of helix; 10 – Spine of helix; 11 – Auricularis anterior; 12 – Transverse antihelical sulcus; 13 – Eminentia fossae triangularis; 14 – Auricularis superior; 15 – Eminentia scapulae; 16 – Oblique muscles of auricle; 17 – Fossa antihelica; Antihelical fossa; 18 – Transverse muscle of auricle; 19 – Posterior ligament of auricle; 20 – Fissura antitragohelicalis; 21 – Muscle of terminal notch; 22 – Tail of helix; 23 – Lobule of auricle; Lobe of ear

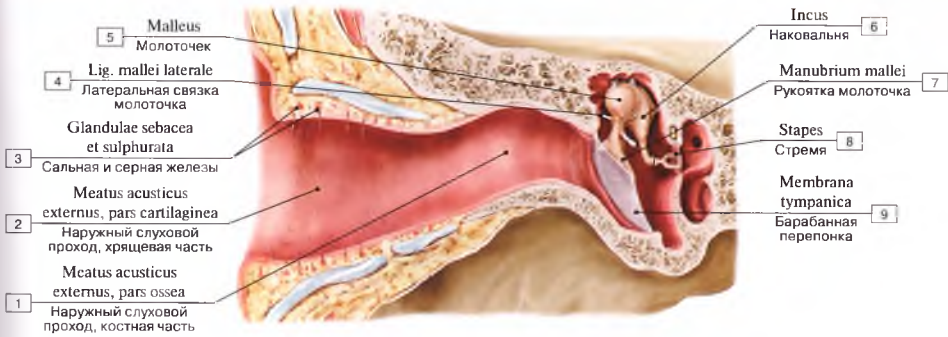


Рис. 510. Наружный слуховой проход, барабанная перепонка и барабанная полость:

1 – External acoustic meatus, bony part; 2 – External acoustic meatus, cartilaginous part; 3 – Sebaceous and cerumen glands; 4 – Lateral ligament of malleus; 5 – Malleus; 6 – Incus; 7 – Handle of malleus; 8 – Stapes; 9 – Tympanic membrane

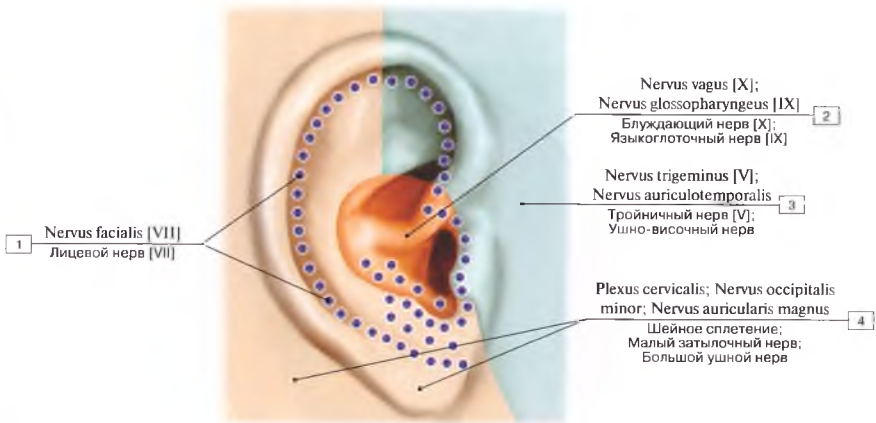


Рис. 511. Чувствительная иннервация наружного уха (правое ухо, вид сбоку):

1 – Facial nerve [VII]; 2 – Vagus nerve [X]; Glossopharyngeal nerve [IX]; 3 – Trigeminal nerve [V]; Auriculotemporal nerve; 4 – Cervical plexus; Lesser occipital nerve; Great auricular nerve

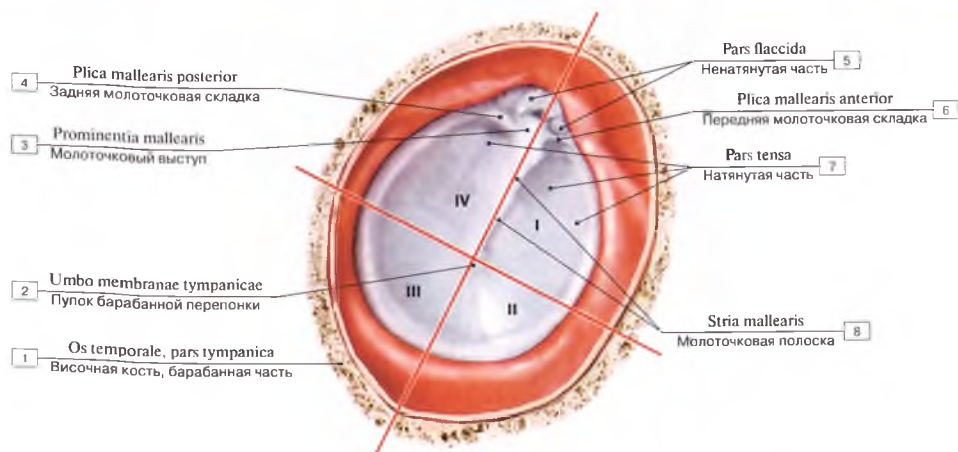


Рис. 512. Барабанная перепонка, правая, вид сбоку:

1 – Temporal bone, Tympanic part; 2 – Umbo of tympanic membrane; 3 – Malleolar prominence; 4 – Posterior fold of malleus; 5 – Pars flaccida; 6 – Anterior malleolar fold; 7 – Pars tensa; 8 – Malleolar stria

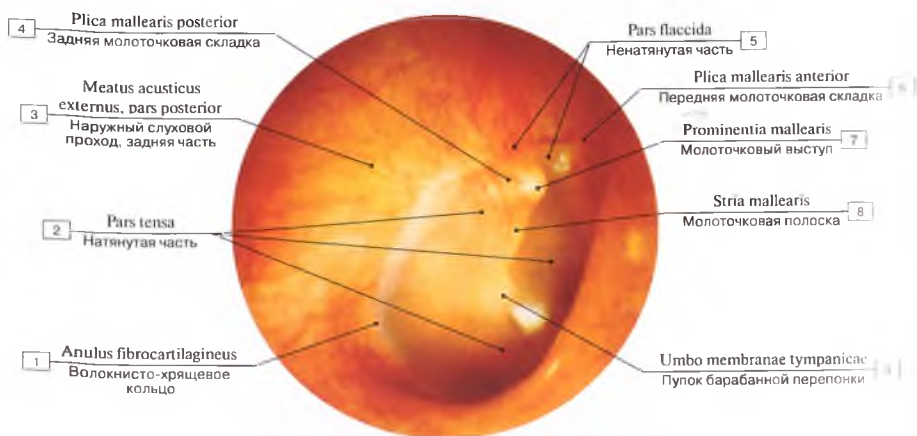


Рис. 513. Барабанная перепонка, вид с латеральной стороны:

1 – Fibrocartilaginous ring; 2 – Pars tensa; 3 – External acoustic meatus, posterior part; 4 – Posterior malleolar fold; 5 – Pars flaccida; 6 – Anterior fold of malleus; 7 – Malleolar prominence; 8 – Malleolar stria; 9 – Umbo of tympanic membrane

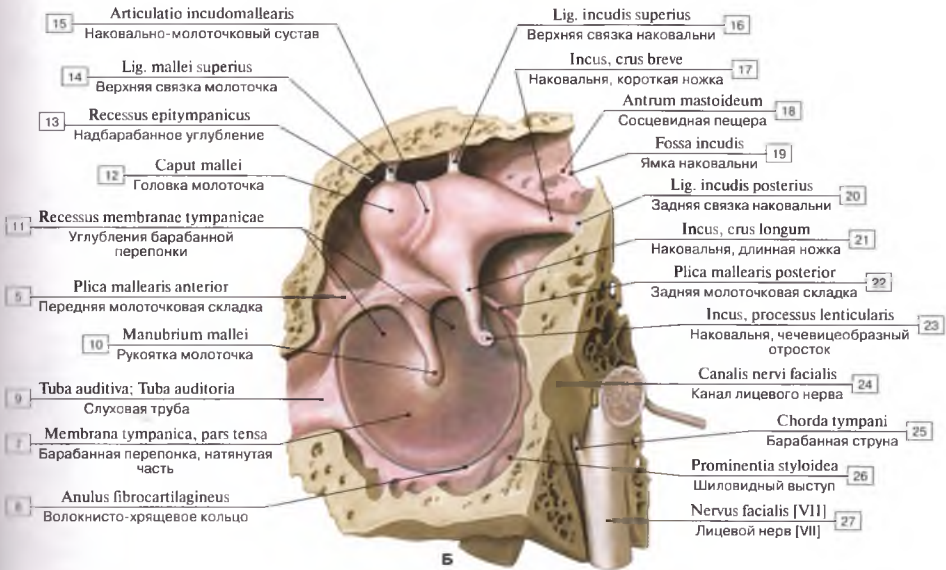
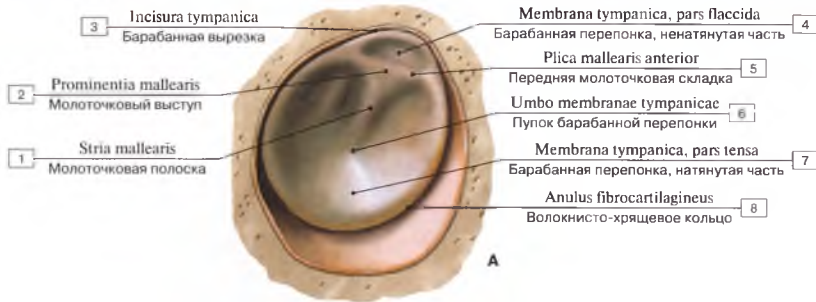


Рис. 514. Барабанная перепонка (А – правая, вид снаружи; Б – перепонка, молоточек и наковальня, правые, вид изнутри):

- 1 – Malleolar stria; 2 – Malleolar prominence; 3 – Tympanic notch; 4 – Tympanic membrane, pars flaccida; 5 – Anterior malleolar fold; 6 – Umbo of tympanic membrane; 7 – Tympanic membrane, pars tensa; 8 – Fibrocartilaginous ring; 9 – Pharyngotympanic tube; Auditory tube; 10 – Handle of malleus; 11 – Recesses of tympanic membrane; 12 – Head of malleus; 13 – Epitympanic recess; 14 – Superior ligament of malleus; 15 – Incudomalleal joint; 16 – Superior ligament of incus; 17 – Incus, short limb; 18 – Mastoid antrum; 19 – Fossa of incus; 20 – Posterior ligament of incus; 21 – Incus, long limb; 22 – Posterior fold of malleus; 23 – Incus, lenticularis process; 24 – Facial canal; 25 – Chorda tympani; 26 – Styloid prominence; 27 – Facial nerve [VII]



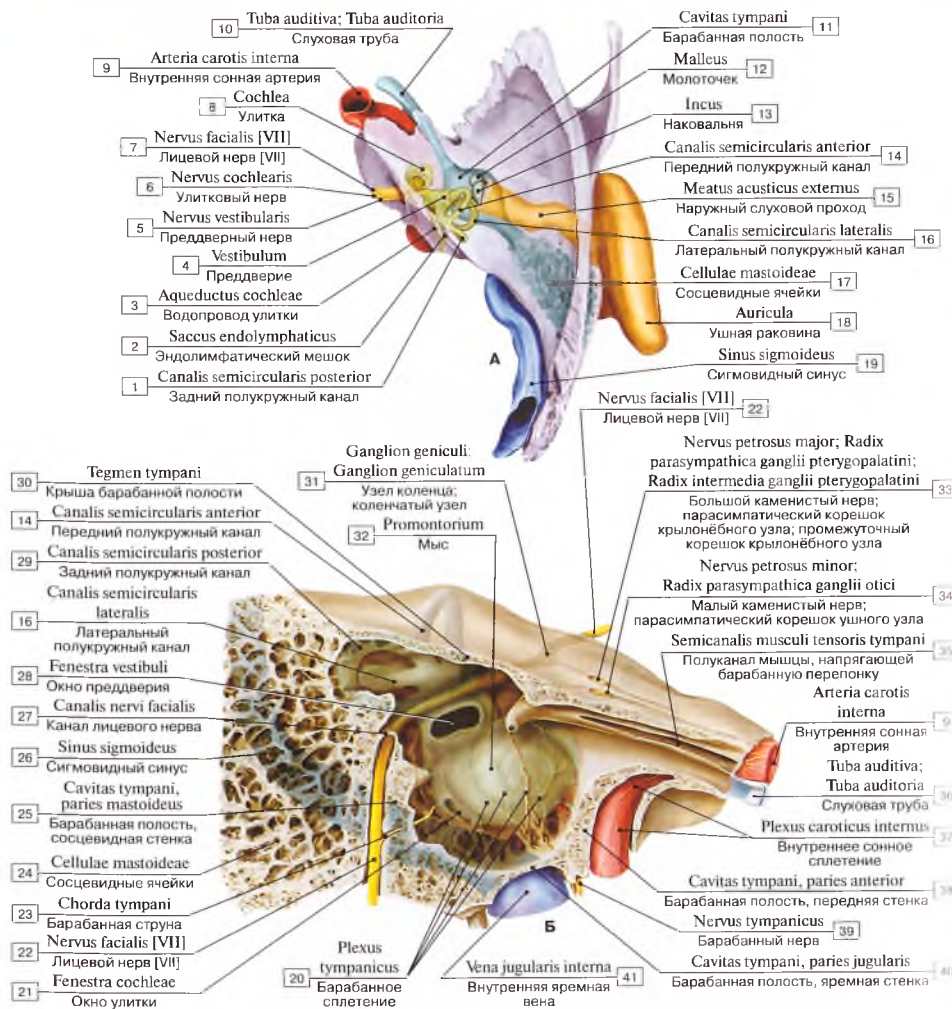


Рис. 515. Среднее ухо (А – горизонтальный распил, вид сверху; Б – сагиттальный распил):

1 – Posterior semicircular canal; 2 – Endolymphatic sac; 3 – Cochlear aqueduct; 4 – Vestibule; 5 – Vestibular nerve; 6 – Cochlear nerve; 7 – Facial nerve [VII]; 8 – Cochlea; 9 – Internal carotid artery; 10 – Pharyngotympanic tube; Auditory tube; 11 – Tympanic cavity; 12 – Malleus; 13 – Incus; 14 – Anterior semicircular canal; 15 – External acoustic meatus; 16 – Lateral semicircular canal; 17 – Mastoid cells; 18 – Auricle; Pinna; 19 – Sigmoid sinus; 20 – Tympanic cavity; 21 – Round window; 22 – Facial nerve [VII]; 23 – Chorda tympani; 24 – Mastoid cells; 25 – Tympanic cavity, mastoid wall; posterior wall; 26 – Sigmoid sinus; 27 – Facial canal; 28 – Oval window; 29 – Posterior semicircular canal; 30 – Tegmen tympani; 31 – Geniculate ganglion; 32 – Promontory; 33 – Greater petrosal nerve; Parasympathetic root of pterygopalatine ganglion; 34 – Lesser petrosal nerve; Parasympathetic root of otic ganglion; 35 – Canal for tensor tympani; 36 – Pharyngotympanic tube; Auditory tube; 37 – Internal carotid plexus; 38 – Tympanic cavity, anterior wall; 39 – Tympanic nerve; 40 – Tympanic cavity, jugular wall; floor; 41 – Internal jugular vein

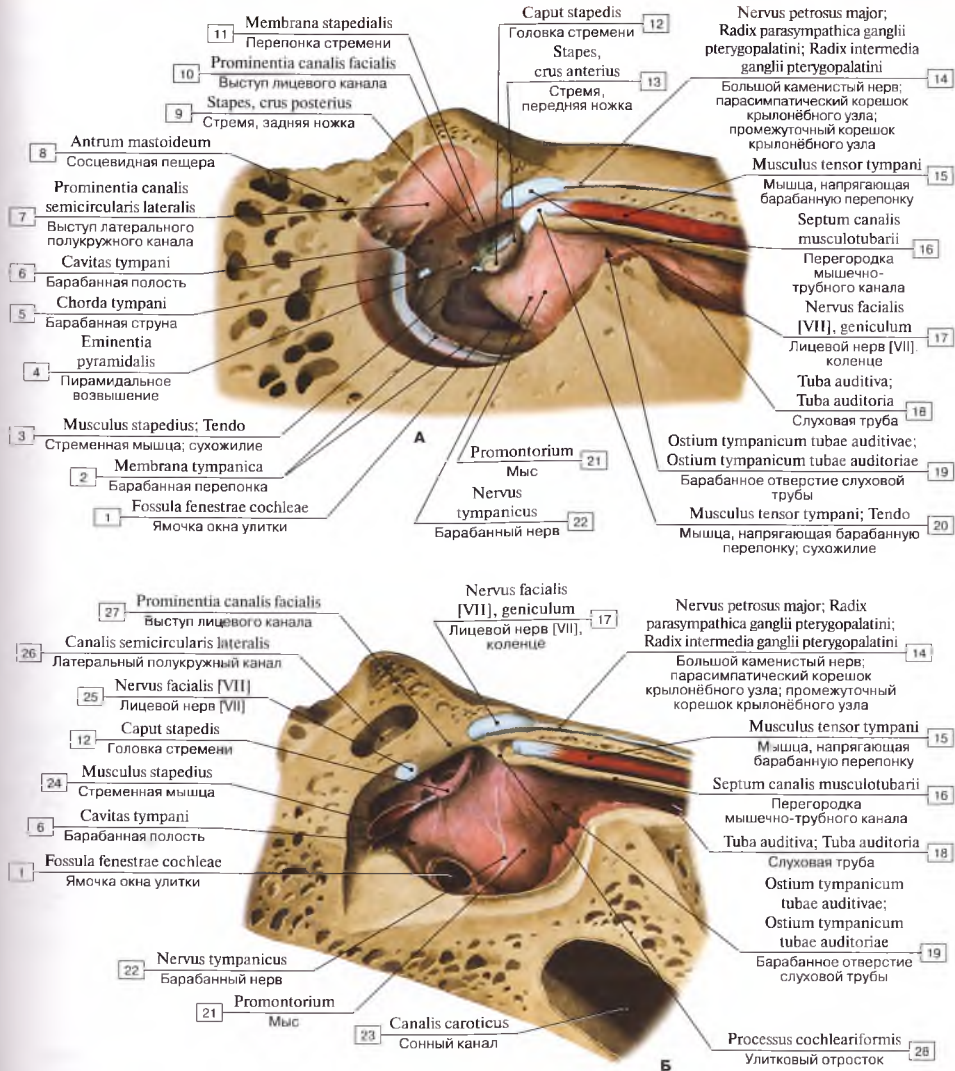


Рис. 516. Среднее ухо (А – барабанная полость и мышечно-трубный канал; Б – барабанная полость, медиальная стенка):

- 1 – Fossa of round window; 2 – Tympanic membrane; 3 – Stapedius; Tendon; 4 – Pyramidal eminence; 5 – Chorda tympani; 6 – Tympanic cavity; 7 – Prominence of lateral semicircular canal; 8 – Mastoid antrum; 9 – Stapes, posterior limb; 10 – Prominence of facial canal; 11 – Stapedial membrane; 12 – Head of stapes; 13 – Stapes, anterior limb; 14 – Greater petrosal nerve; Parasympathetic root of pterygopalatine ganglion; 15 – Tensor tympani; 16 – Septum of musculotubal canal; 17 – Facial nerve [VII], geniculum; 18 – Pharyngotympanic tube; Auditory tube; 19 – Tympanic opening; 20 – Tensor tympani; Tendon; 21 – Promontory; 22 – Tympanic nerve; 23 – Carotic canal; 24 – Stapedius; 25 – Facial nerve [VII]; 26 – Lateral semicircular canal; 27 – Prominence of facial canal; 28 – Processus cochleariformis

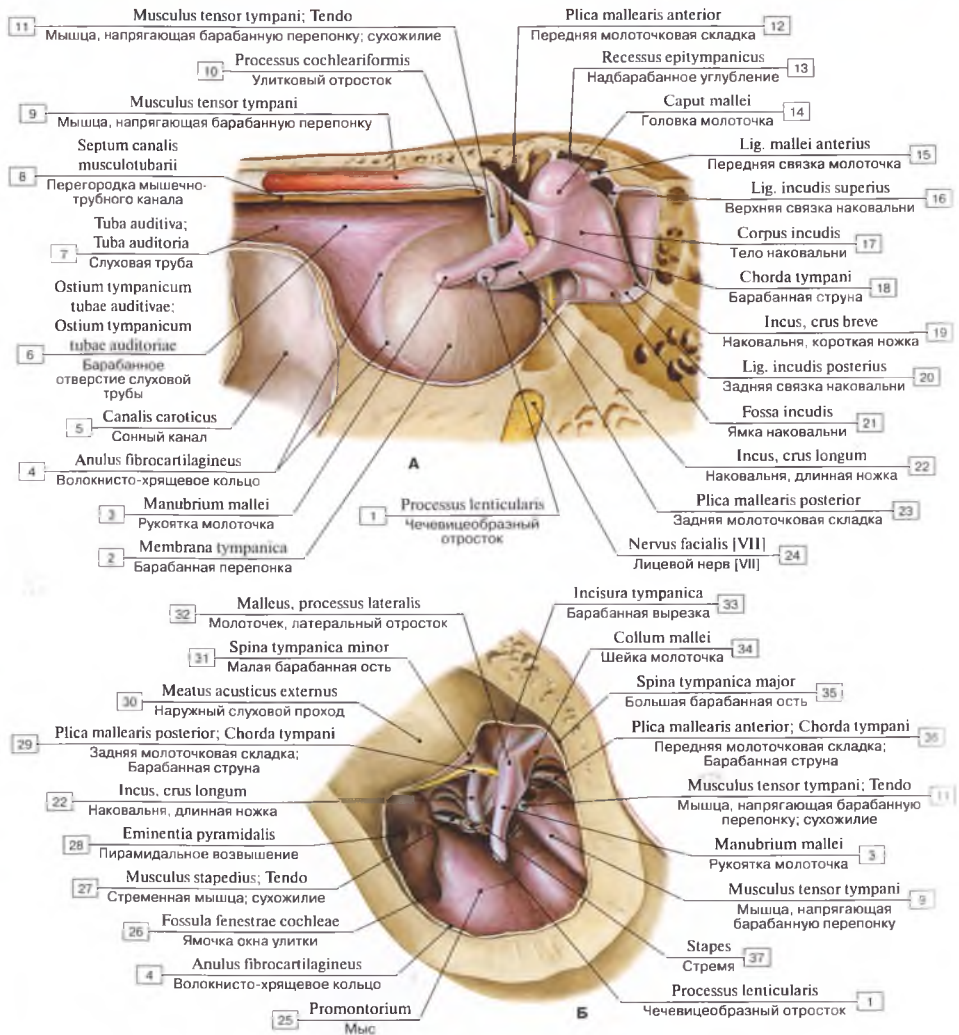


Рис. 517. Среднее ухо (А – латеральная стенка; Б – латеральная стенка после удаления барабанной перепонки):

1 – Lenticular process; 2 – Tympanic membrane; 3 – Handle of malleus; 4 – Fibrocartilaginous ring; 5 – Carotid canal; 6 – Tympanic opening; 7 – Pharyngotympanic tube; Auditory tube; 8 – Septum of musculotubal canal; 9 – Tensor tympani; 10 – Processus cochleariformis; 11 – Tensor tympani; Tendon; 12 – Anterior fold of malleus; 13 – Epitympanic recess; 14 – Head of malleus; 15 – Anterior ligament of malleus; 16 – Superior ligament of incus; 17 – Body of incus; 18 – Chorda tympani; 19 – Incus, short limb; 20 – Posterior ligament of incus; 21 – Fossa of incus; 22 – Incus, long limb; 23 – Posterior fold of malleus; 24 – Facial nerve [VII]; 25 – Promontory; 26 – Fossa of round window; 27 – Stapedius; Tendon; 28 – Pyramidal eminence; 29 – External acoustic meatus; 30 – External acoustic meatus; 31 – Lesser tympanic spine; 32 – Malleus, lateral process; 33 – Tympanic notch; 34 – Neck of malleus; 35 – Greater tympanic spine; 36 – Anterior malleolar fold; Chorda tympani; 37 – Stapes

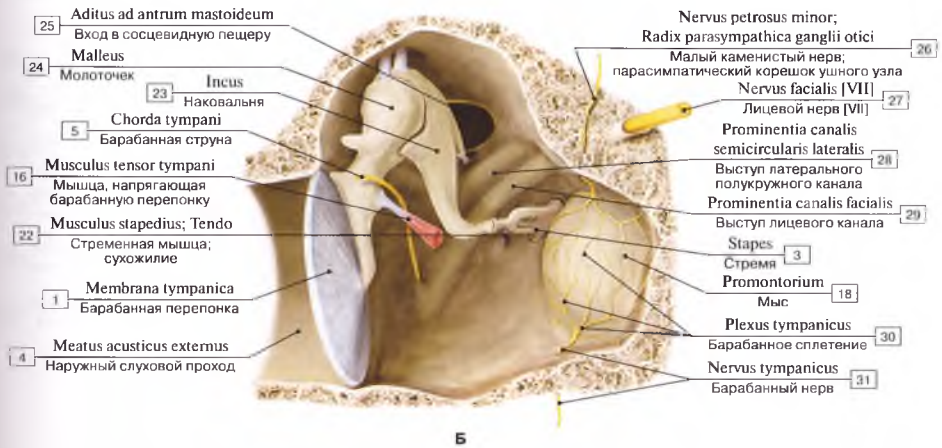
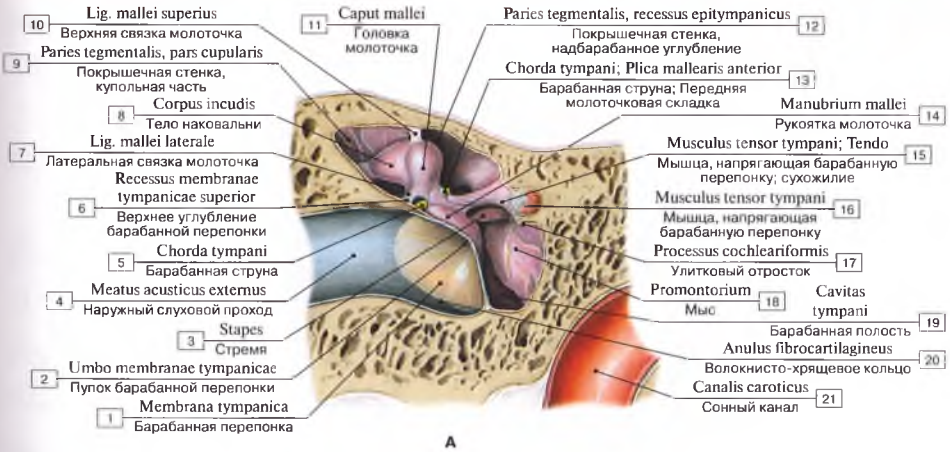


Рис. 518. Барабанная полость (А – среднее и внутреннее ухо в составе височной кости; Б – среднее ухо):

1 – Tympanic membrane; 2 – Umbo of tympanic membrane; 3 – Stapes; 4 – External acoustic meatus; 5 – Chorda tympani; 6 – Recesses of tympanic membrane; 7 – Lateral ligament of malleus; 8 – Body of incus; 9 – Tegmental wall; Tegmental roof, cupular part; 10 – Superior ligament of malleus; 11 – Head of malleus; 12 – Tegmental wall; Tegmental roof, epitympanic recess; 13 – Chorda tympani; Anterior fold of malleus; 14 – Handle of malleus; 15 – Tensor tympani; Tendon; 16 – Tensor tympani; 17 – Processus cochleariformis; 18 – Promontory; 19 – Tympanic cavity; 20 – Fibrocartilaginuous ring; 21 – Carotid canal; 22 – Stapedius; Tendon; 23 – Incus; 24 – Malleus; 25 – Aditus to mastoid antrum; 26 – Lesser petrosal nerve; Parasympathetic root of otic ganglion; 27 – Facial nerve [VII]; 28 – Prominence of lateral semicircular canal; 29 – Prominence of facial canal; 30 – Tympanic plexus; 31 – Tympanic nerve

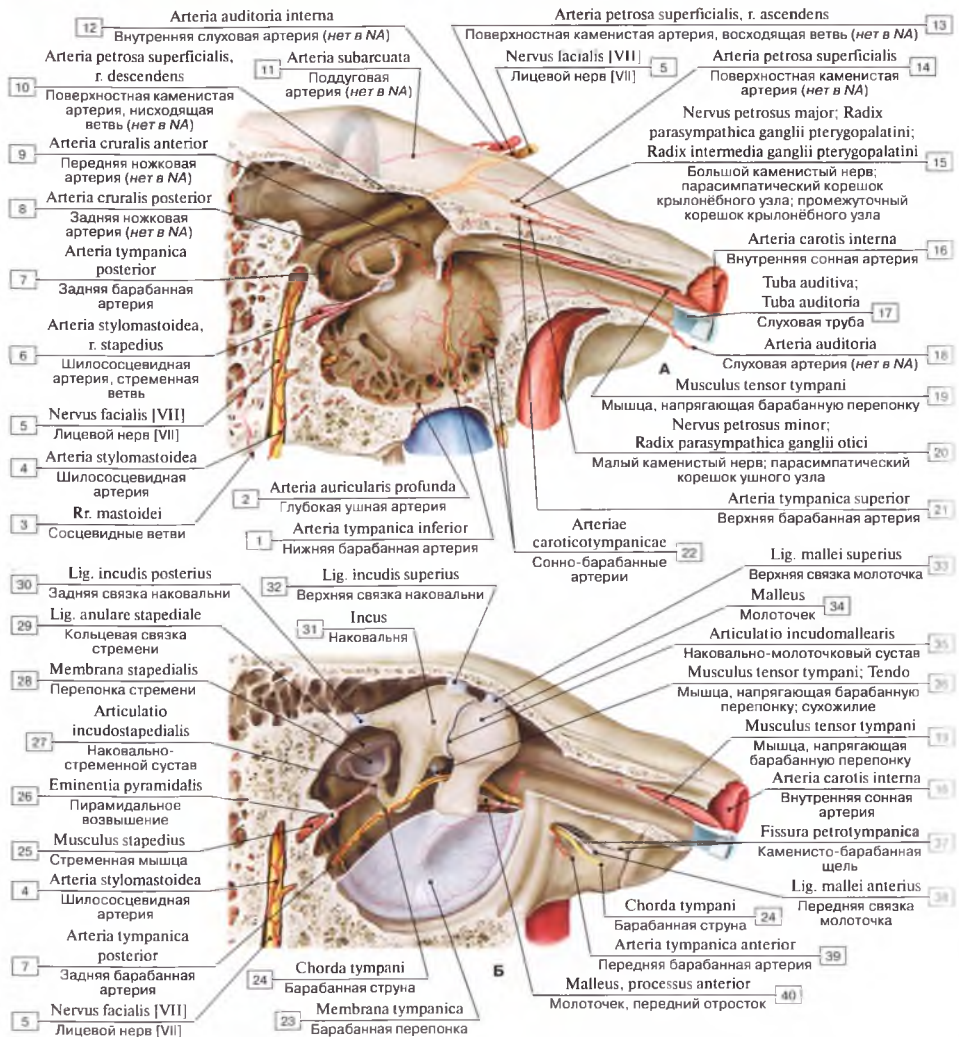
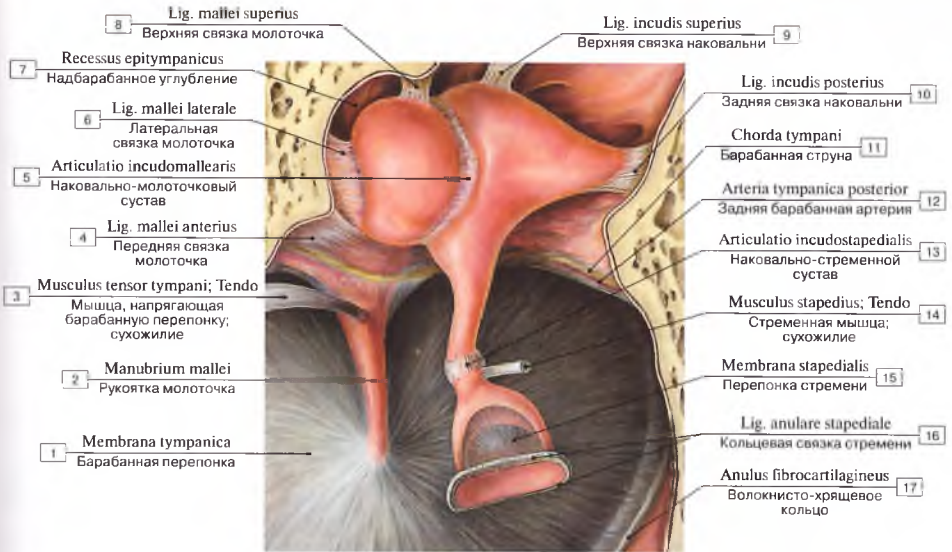
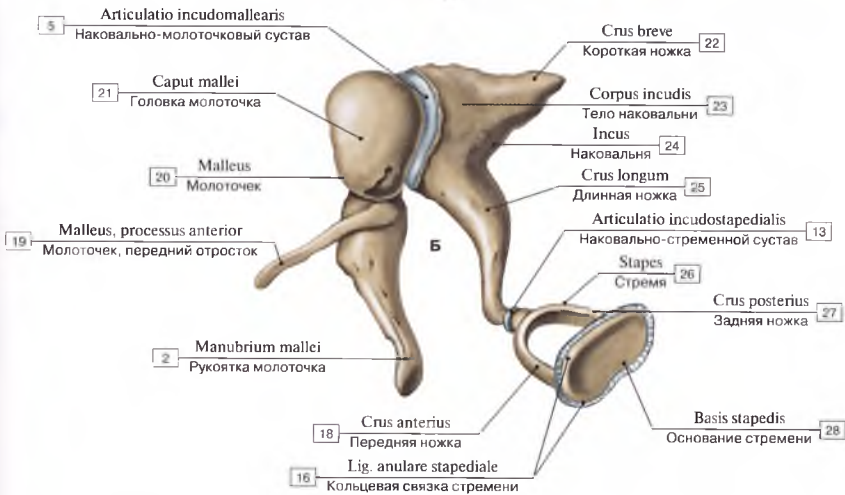


Рис. 519. Среднее ухо (А – кровоснабжение; Б – слуховые косточки):

1 – Inferior tympanic artery; 2 – Deep auricular artery; 3 – Mastoid branches; 4 – Stylomastoid artery; 5 – Facial nerve [VII]; 6 – Stylomastoid artery, stapediale branch; 7 – Posterior tympanic artery; 8 – Posterior crural artery; 9 – Anterior crural artery; 10 – Superficial petrosal artery, descending branch; 11 – Subarcuate artery; 12 – Internal auditory artery; 13 – Superficial petrosal artery, ascending branch; 14 – Superficial petrosal artery; 15 – Greater petrosal nerve; Parasympathetic root of pterygopalatine ganglion; 16 – Internal carotid artery; 17 – Pharyngotympanic tube; Auditory tube; 18 – Auditory artery; 19 – Tensor tympani; 20 – Lesser petrosal nerve; Parasympathetic root of otic ganglion; 21 – Superior tympanic artery; 22 – Caroticotympanic arteries; 23 – Tympanic membrane; 24 – Chorda tympani; 25 – Stapedius; 26 – Pyramidal eminence; 27 – Incudostapedial joint; 28 – Stapedial membrane; 29 – Anular ligament of stapes; 30 – Posterior ligament of incus; 31 – Incus; 32 – Superior ligament of incus; 33 – Superior ligament of malleus; 34 – Malleus; 35 – Incudomalleal joint; 36 – Tensor tympani; 37 – Petrotympanic fissure; 38 – Anterior ligament of malleus; 39 – Anterior tympanic artery; 40 – Malleus, anterior process



A



Б

Рис. 520. Суставы и связки слуховых косточек, покрытые слизистой оболочкой (А), слуховые косточки (схема) (Б):

1 – Tympanic membrane; 2 – Handle of malleus; 3 – Tensor tympani; Tendon; 4 – Anterior ligament of malleus; 5 – Incudomalleolar joint; 6 – Lateral ligament of malleus; 7 – Epitympanic recess; 8 – Superior ligament of malleus; 9 – Superior ligament of incus; 10 – Posterior ligament of incus; 11 – Chorda tympani; 12 – Posterior tympanic artery; 13 – Incudostapedial joint; 14 – Stapedius; Tendon; 15 – Stapedial membrane; 16 – Anular ligament of stapes; 17 – Fibrocartilagenous ring; 18 – Anterior limb; 19 – Malleus, anterior process; 20 – Malleus; 21 – Head of malleus; 22 – Short limb; 23 – Body of incus; 24 – Incus; 25 – Long limb; 26 – Stapes; 27 – Posterior limb; 28 – Base of stapes; Footplate

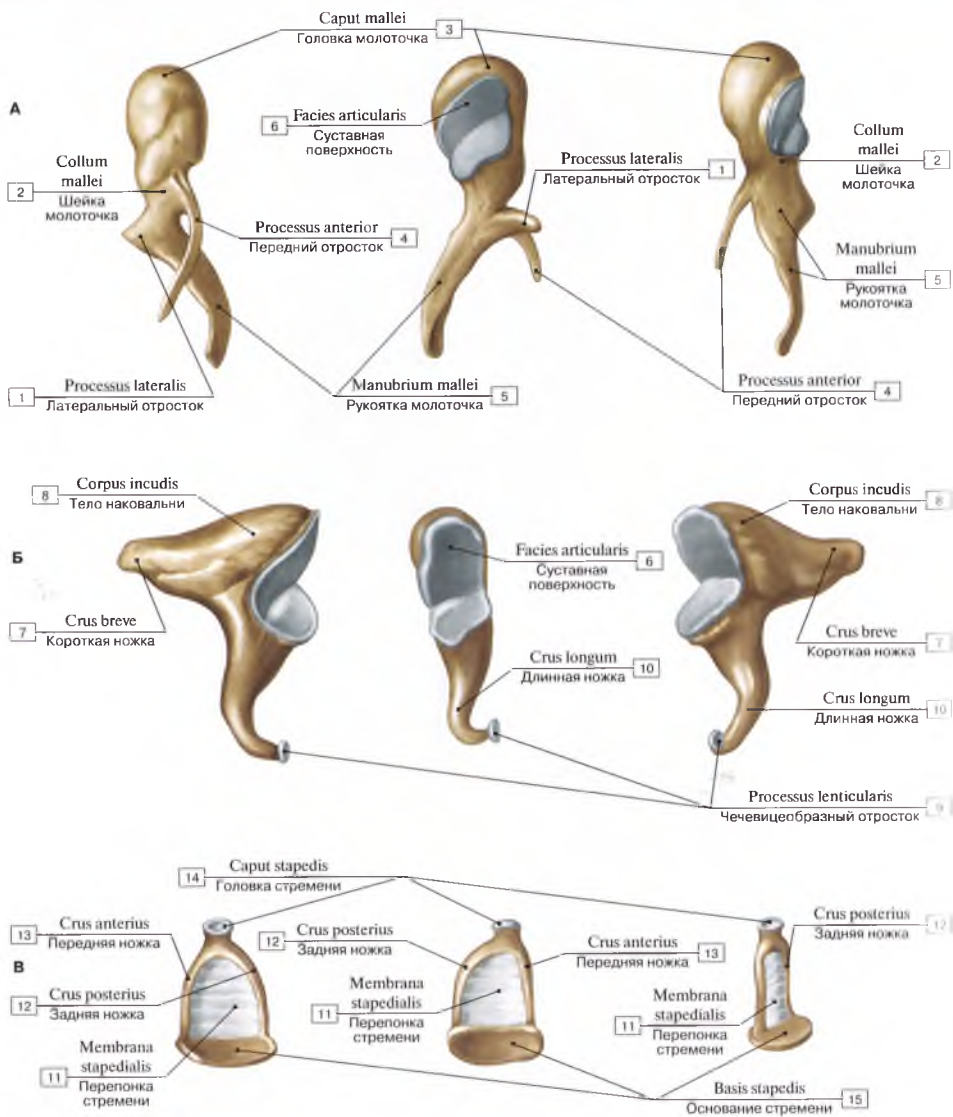


Рис. 521. Слуховые косточки в разных проекциях (А – молоточек; Б – наковальня; В – стремя):

1 – Lateral process; 2 – Neck of malleus; 3 – Head of malleus; 4 – Anterior process; 5 – Handle of malleus; 6 – Articular surface; 7 – Short limb; 8 – Body of incus; 9 – Lenticular process; 10 – Long limb; 11 – Stapedial membrane; 12 – Posterior limb; 13 – Anterior limb; 14 – Head of stapes; 15 – Base of stapes; Footplate

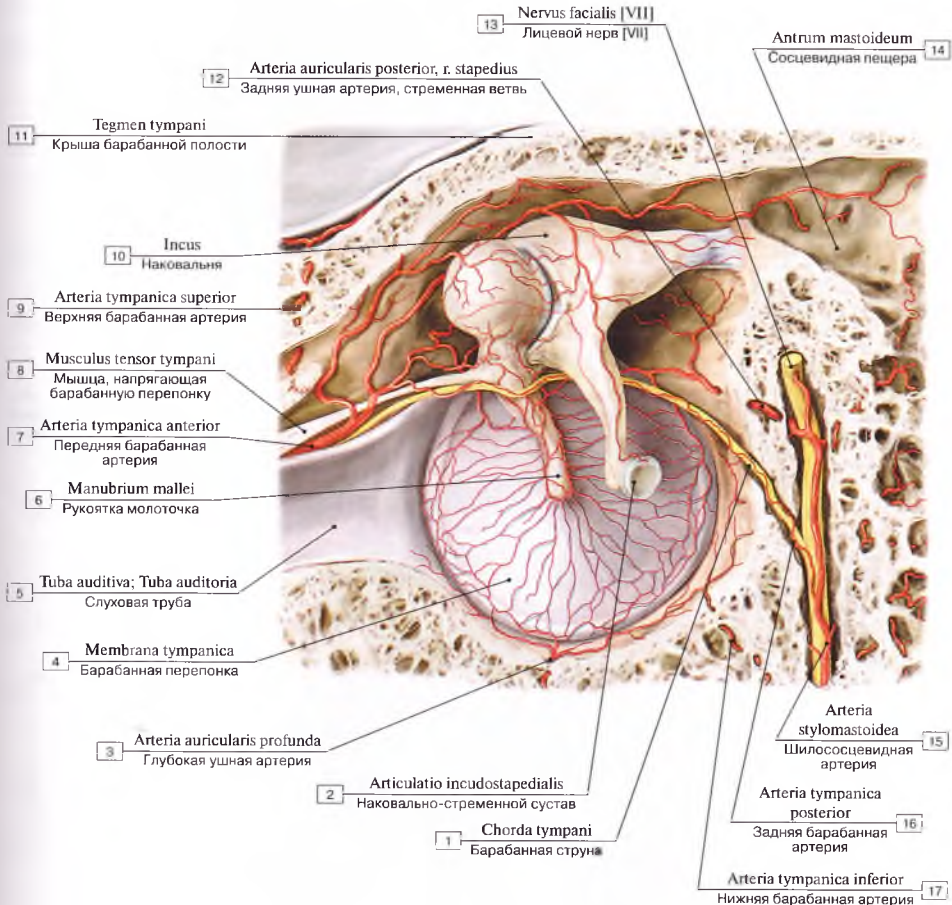


Рис. 522. Кровоснабжение слуховых косточек и барабанной перепонки:

1 – Chorda tympani; 2 – Incudostapedial joint; 3 – Deep auricular artery; 4 – Tympanic membrane; 5 – Pharyngotympanic tube; Auditory tube; 6 – Handle of malleus; 7 – Anterior tympanic artery; 8 – Tensor tympani; 9 – Superior tympanic artery; 10 – Incus; 11 – Tegmen tympani; 12 – Posterior auricular artery, stapelial branch; 13 – Facial nerve [VII]; 14 – Mastoid antrum; 15 – Stylomastoid artery; 16 – Posterior tympanic artery; 17 – Inferior tympanic artery



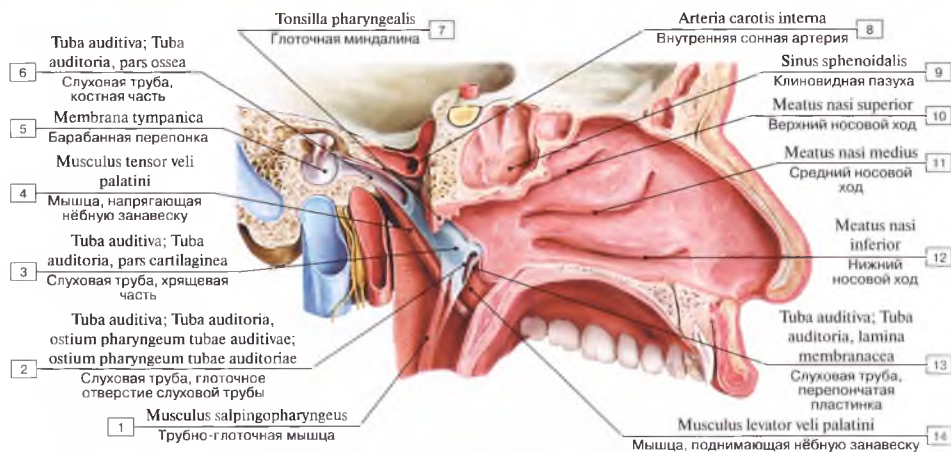


Рис. 523. Среднее ухо, сагиттальный распил:

1 – Salpingopharyngeus; 2 – Pharyngotympanic tube; Auditory tube, pharyngeal opening; 3 – Pharyngotympanic tube; Auditory tube, cartilaginous part; 4 – Tensor veli palatini; 5 – Tympanic membrane; 6 – Pharyngotympanic tube; Auditory tube, bony part; 7 – Pharyngeal tonsil; 8 – Internal carotid artery; 9 – Sphenoidal sinus; 10 – Superior nasal meatus; 11 – Middle nasal meatus; 12 – Inferior nasal meatus; 13 – Pharyngotympanic tube; Auditory tube, membranous lamina; 14 – Levator veli palatini

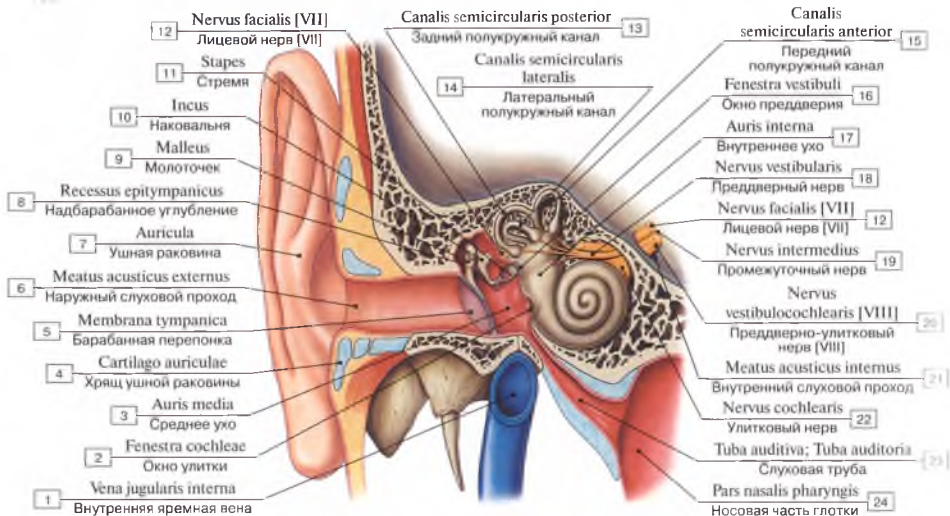


Рис. 524. Наружное, среднее и внутреннее ухо (схема):

1 – Internal jugular vein; 2 – Round window; 3 – Middle ear; 4 – Auricular cartilage; 5 – Tympanic membrane; 6 – External acoustic meatus; 7 – Auricle; Pinna; 8 – Epitympanic recess; 9 – Malleus; 10 – Incus; 11 – Stapes; 12 – Facial nerve [VII]; 13 – Posterior semicircular canal; 14 – Lateral semicircular canal; 15 – Anterior semicircular canal; 16 – Oval window; 17 – Internal ear; 18 – Vestibular nerve; 19 – Intermediate nerve; 20 – Vestibulocochlear nerve [VIII]; 21 – Internal acoustic meatus; 22 – Cochlear nerve; 23 – Pharyngotympanic tube; Auditory tube; 24 – Nasopharynx

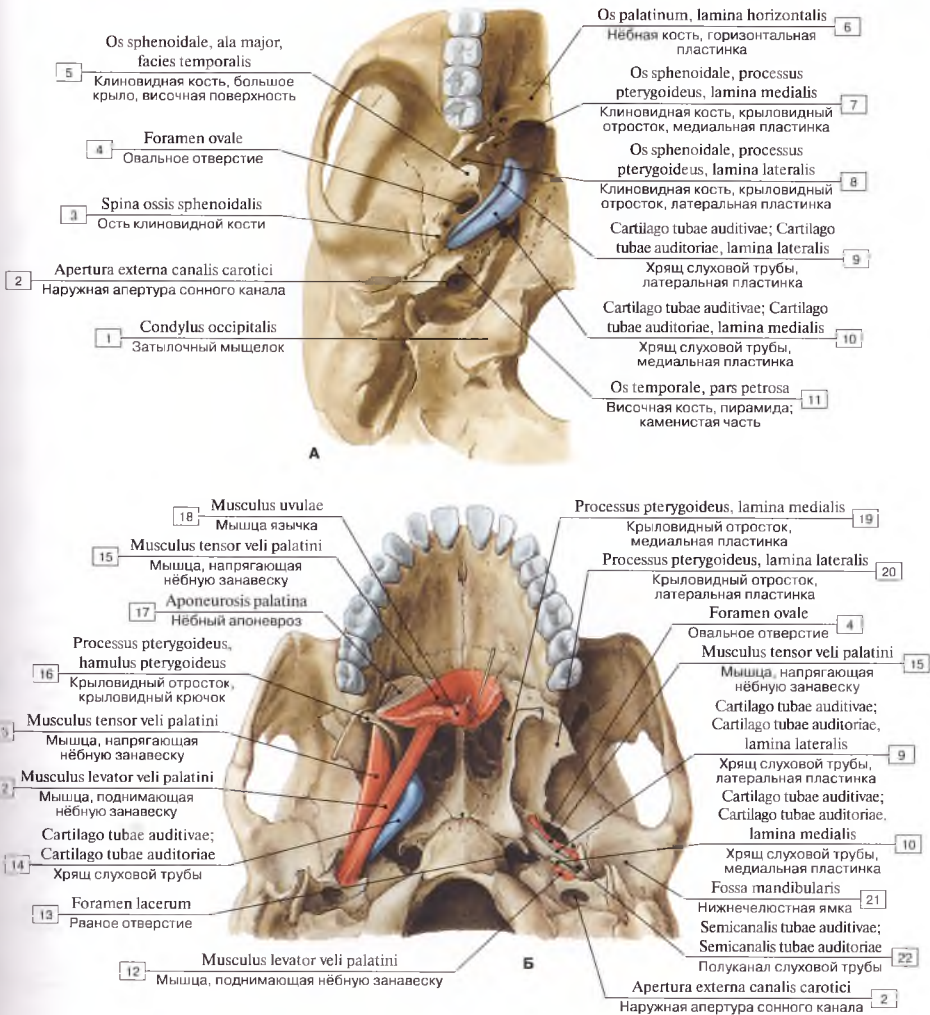


Рис. 525. Хрящ слуховой трубы (А – вид со стороны основания черепа; Б – мышцы, напрягающие и поднимающие небную занавеску и хрящ слуховой трубы):

- 1 – Occipital condyle; 2 – External opening of carotid canal; 3 – Spine of sphenoid bone; 4 – Foramen ovale; 5 – Sphenoid; Sphenoidal bone, greater wing, temporal surface; 6 – Palatine bone, horizontal plate; 7 – Sphenoid; Sphenoidal bone, pterygoid process, medial plate; 8 – Sphenoid; Sphenoidal bone, pterygoid process, lateral plate; 9 – Cartilage of tube, lateral lamina; 10 – Cartilage of tube, medial lamina; 11 – Temporal bone, petrous part; 12 – Levator veli palatini; 13 – Foramen lacerum; 14 – Cartilage of tube; 15 – Tensor veli palatini; 16 – Pterygoid process, pterygoid hamulus; 17 – Palatine aponeurosis; 18 – Musculus uvulae; 19 – Pterygoid process, medial plate; 20 – Pterygoid process, lateral plate; 21 – Mandibular fossa; 22 – Canal for pharyngotympanic tube; Canal for auditory tube

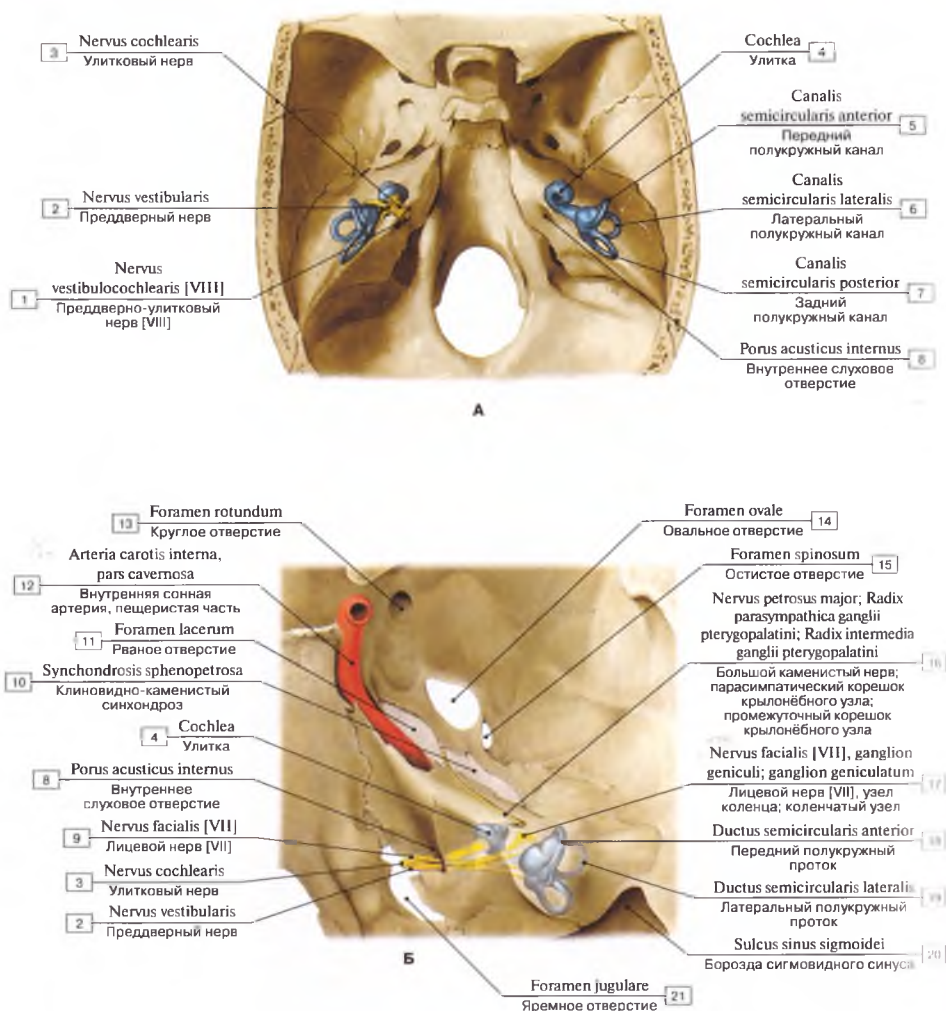


Рис. 526. Внутреннее ухо (А – с преддверно-улитковым нервом; Б – с лицевым и преддверно-улитковым нервами):

1 – Vestibulocochlear nerve [VIII]; 2 – Vestibular nerve; 3 – Cochlear nerve; 4 – Cochlea; 5 – Anterior semicircular canal; 6 – Lateral semicircular canal; 7 – Posterior semicircular canal; 8 – Internal acoustic opening; 9 – Facial nerve [VII]; 10 – Sphenopetrosal synchondrosis; 11 – Foramen lacerum; 12 – Internal carotid artery, cavernous part; 13 – Foramen rotundum; 14 – Foramen ovale; 15 – Foramen spinosum; 16 – Greater petrosal nerve; Parasympathetic root of pterygopalatine ganglion; 17 – Facial nerve [VII], geniculate ganglion; 18 – Anterior semicircular duct; 19 – Lateral semicircular duct; 20 – Groove for sigmoid sinus; 21 – Jugular foramen

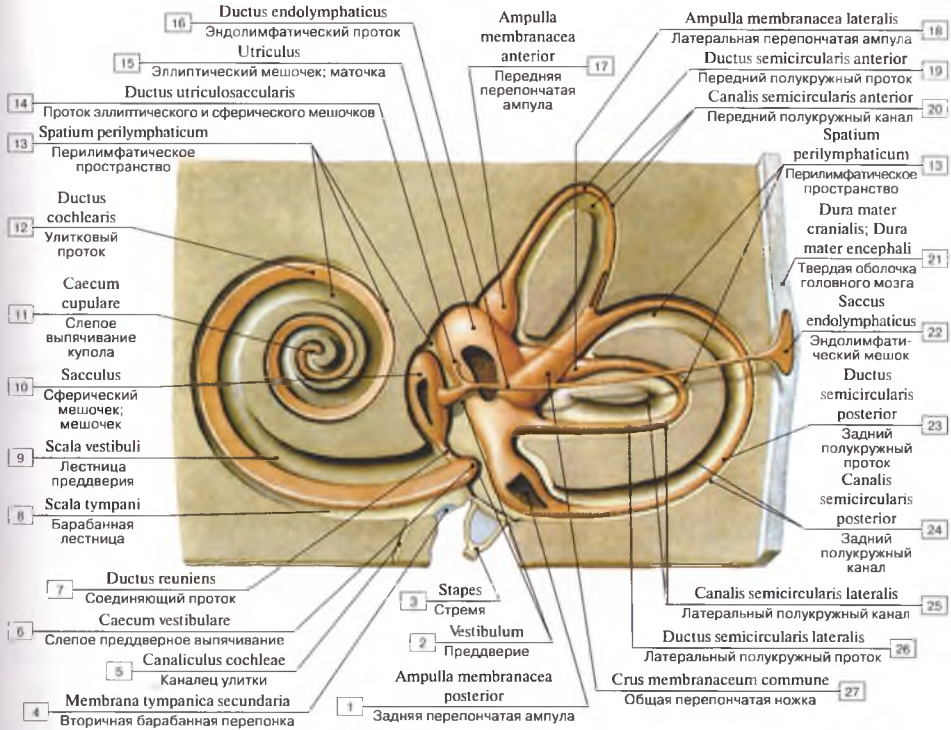


Рис. 527. Взаиморасположение костного и перепончатого лабиринтов (схема):

- 1 – Posterior membranous ampulla; 2 – Vestibule; 3 – Stapes; 4 – Secondary tympanic membrane; 5 – Cochlear canaliculus; 6 – Vestibular saccum; 7 – Ductus reuniens; 8 – Scala tympani; 9 – Scala vestibuli; 10 – Sacculle; 11 – Cupular caecum; 12 – Cochlear duct; 13 – Perilymphatic space; 14 – Utriculosacculus duct; 15 – Utricle; 16 – Endolymphatic duct; 17 – Anterior membranous ampulla; 18 – Lateral membranous ampulla; 19 – Anterior semicircular duct; 20 – Anterior semicircular canal; 21 – Cranial dura mater; 22 – Endolymphatic sac; 23 – Posterior semicircular duct; 24 – Posterior semicircular canal; 25 – Lateral semicircular canal; 26 – Lateral semicircular duct; 27 – Common membranous limb

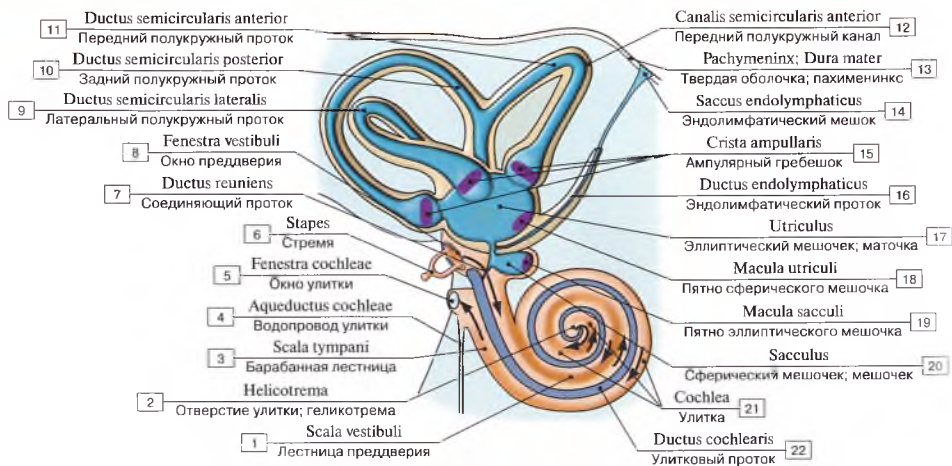


Рис. 528. Внутреннее ухо (схема, показано направление звуковой волны):

1 — Scala vestibuli; 2 — Helicotrema; 3 — Scala tympani; 4 — Cochlear aqueduct; 5 — Round window; 6 — Stapes; 7 — Ductus reuniens; 8 — Oval window; 9 — Lateral semicircular duct; 10 — Posterior semicircular duct; 11 — Anterior semicircular duct; 12 — Anterior semicircular canal; 13 — Pachymeninx; 14 — Endolymphatic sac; 15 — Ampullary crest; 16 — Endolymphatic duct; 17 — Utricle; 18 — Maculae of utricle; 19 — Maculae of saccule; 20 — Saccule; 21 — Cochlea; 22 — Cochlear duct

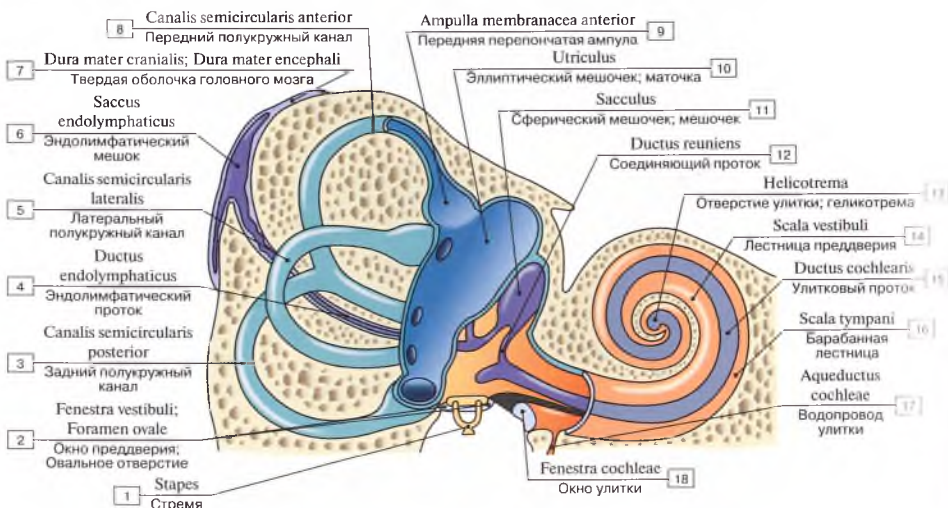


Рис. 529. Внутреннее ухо (схема, показан отток эндолимфы):

1 — Stapes; 2 — Oval window; Foramen ovale; 3 — Posterior semicircular canal; 4 — Endolymphatic duct; 5 — Lateral semicircular canal; 6 — Endolymphatic sac; 7 — Cranial dura mater; 8 — Anterior semicircular canal; 9 — Anterior membranous ampulla; 10 — Utricle; 11 — Saccule; 12 — Ductus reuniens; 13 — Helicotrema; 14 — Scala vestibuli; 15 — Cochlear duct; 16 — Scala tympani; 17 — Cochlear aqueduct; 18 — Round window

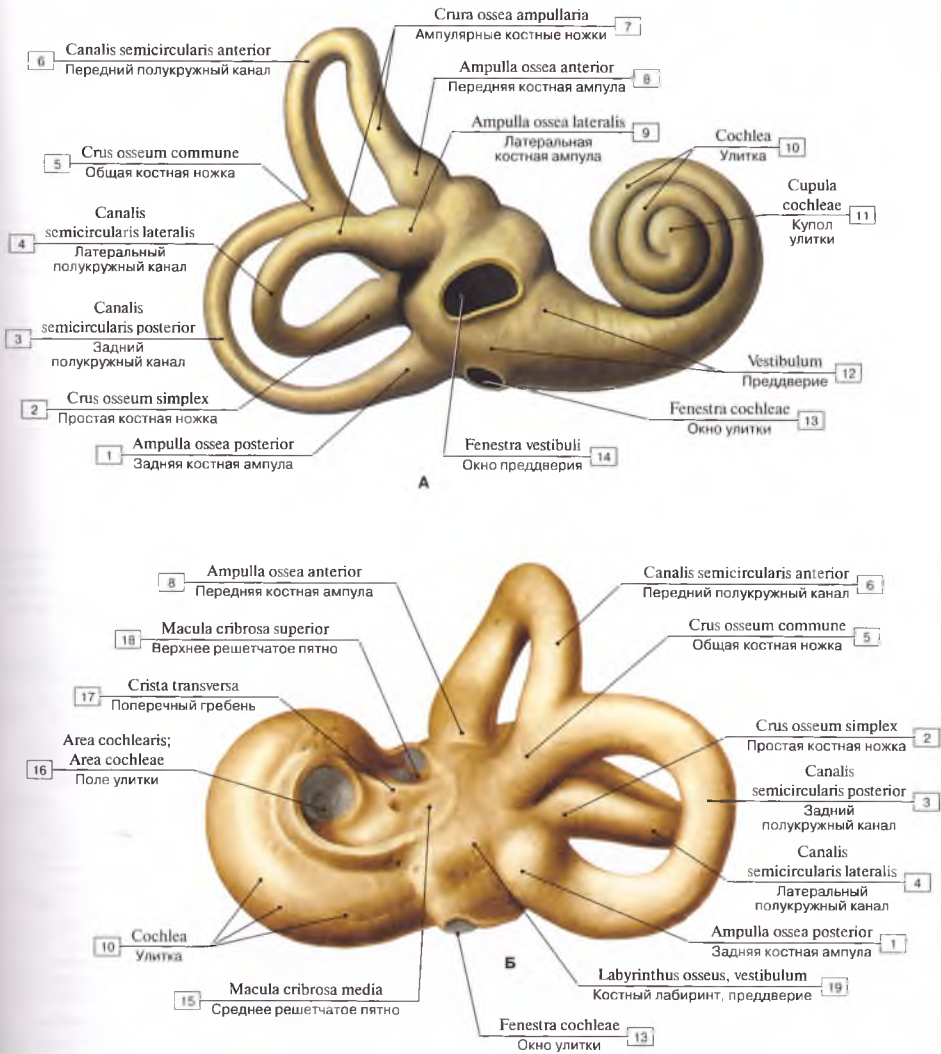


Рис. 530. Костный лабиринт

(А – вид с латеральной стороны и спереди (со стороны барабанной полости); Б – вид сзади);

- 1 – Anterior bony ampulla; 2 – Simple bony limb; 3 – Posterior semicircular canal; 4 – Lateral semicircular canal; 5 – Common bony limb; 6 – Anterior semicircular canal; 7 – Ampullary bony limbs; 8 – Anterior bony ampulla; 9 – Lateral bony ampulla; 10 – Cochlea; 11 – Cochlear cupula; 12 – Vestibule; 13 – Round window; 14 – Oval window; 15 – Macula cribrosa media; 16 – Cochlear area; 17 – Transverse crest; 18 – Macula cribrosa superior; 19 – Bony labyrinth, vestibule

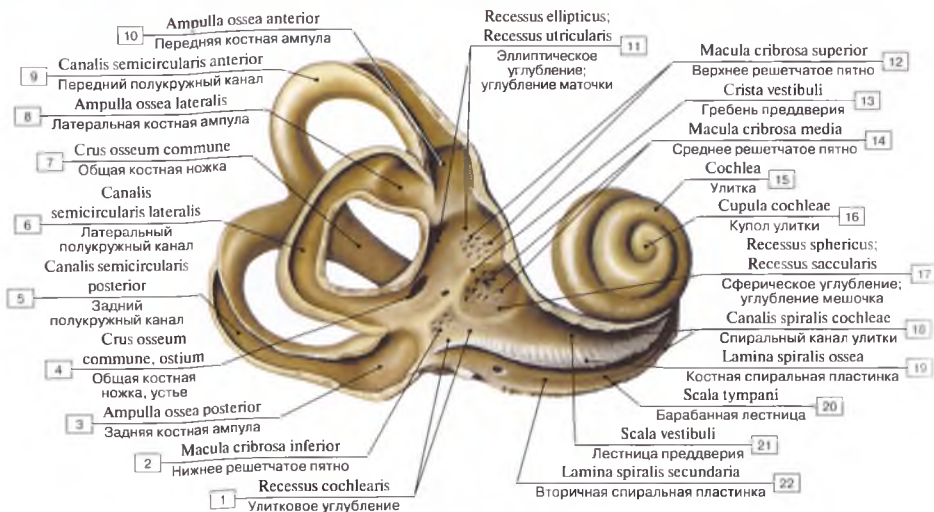


Рис. 531. Вскрытый костный лабиринт:

1 – Cochlear recess; 2 – Macula cribrosa inferior; 3 – Posterior bony ampulla; 4 – Common bony limb, mouth; 5 – Posterior semicircular canal; 6 – Lateral semicircular canal; 7 – Common bony limb; 8 – Lateral bony ampulla; 9 – Anterior semicircular canal; 10 – Anterior bony ampulla; 11 – Elliptical recess; Utricular recess; 12 – Macula cribrosa superior; 13 – Vestibular crest; 14 – Macula cribrosa media; 15 – Cochlea; 16 – Cochlear cupula; 17 – Spherical recess; Saccular recess; 18 – Spiral canal of cochlea; 19 – Osseous spiral lamina; 20 – Scala tympani; 21 – Scala vestibuli; 22 – Secondary spiral lamina

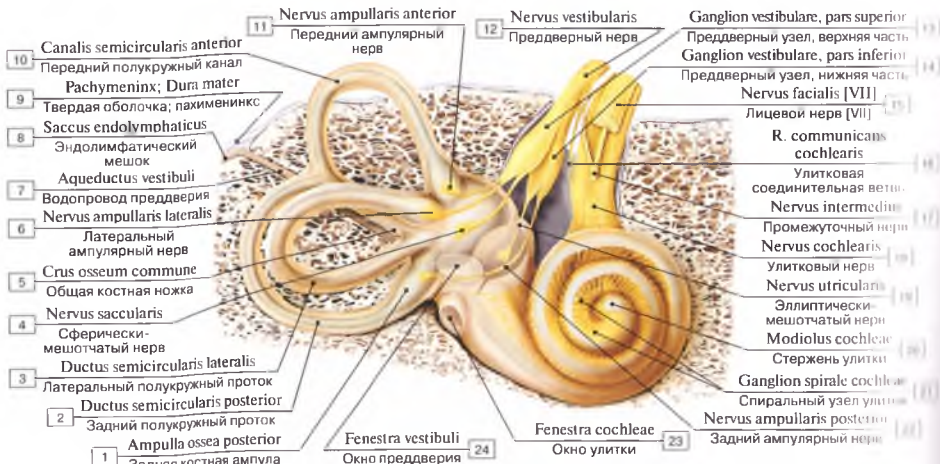


Рис. 532. Перепончатый лабиринт, правый, вид спереди:

1 – Posterior bony ampulla; 2 – Posterior semicircular duct; 3 – Lateral semicircular duct; 4 – Saccular nerve; 5 – Common bony limb; 6 – Lateral ampullary nerve; 7 – Vestibular aqueduct; 8 – Endolymphatic sac; 9 – Pachymeninx; Dura mater; 10 – Anterior semicircular canal; 11 – Anterior ampullary nerve; 12 – Vestibular nerve; 13 – Vestibular ganglion, superior part; 14 – Vestibular ganglion, inferior part; 15 – Facial nerve [VII]; 16 – Cochlear communicating branch; 17 – Intermediate nerve; 18 – Cochlear nerve; 19 – Utricular nerve; 20 – Modiolus; 21 – Spiral ganglion; 22 – Posterior ampullary nerve; 23 – Round window; 24 – Oval window

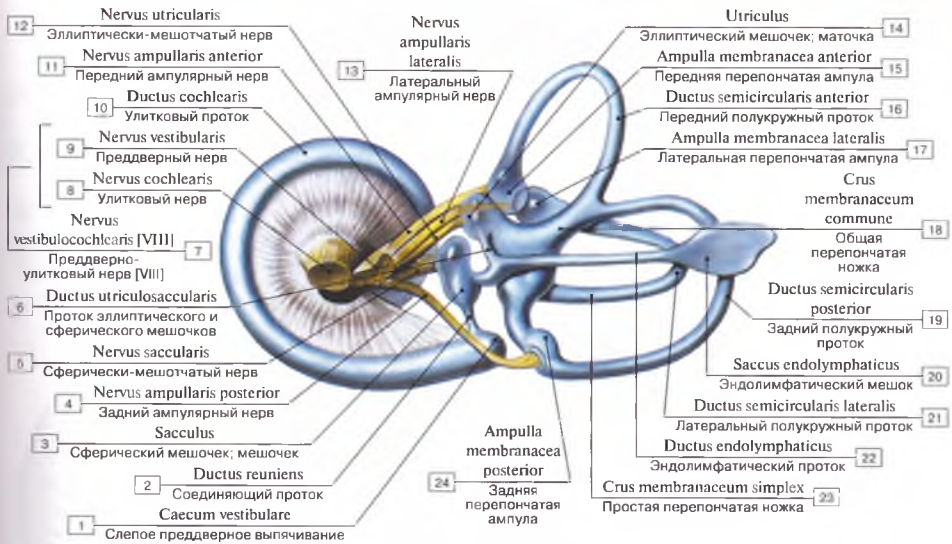


Рис. 533. Перепончатый лабиринт:

- 1 – Vestibular caecum; 2 – Ductus reuniens; 3 – Saccule; 4 – Posterior ampullary nerve; 5 – Saccular nerve; 6 – Utriculosaccular duct; 7 – 8 + 9 – Vestibular nerve; Cochlear nerve; 8 – Cochlear nerve; 9 – Vestibular nerve; 10 – Cochlear duct; 11 – Anterior ampullary nerve; 12 – Utricular nerve; 13 – Lateral ampullary nerve; 14 – Utricle; 15 – Anterior membranous ampulla; 16 – Anterior semicircular duct; 17 – Lateral membranous ampulla; 18 – Common membranous limb; 19 – Posterior semicircular duct; 20 – Endolymphatic sac; 21 – Lateral semicircular duct; 22 – Endolymphatic duct; 23 – Simple membranous limb; 24 – Posterior membranous ampulla

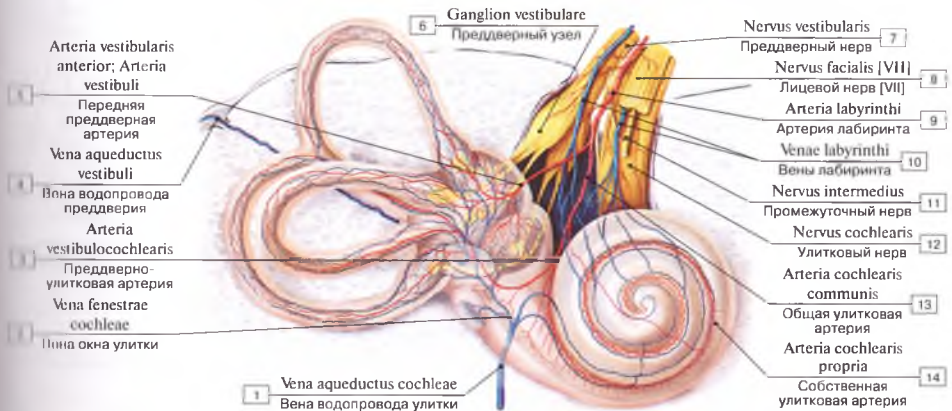


Рис. 534. Кровоснабжение лабиринта, правого:

- 1 – Vln of cochlear aqueduct; 2 – Vein of cochlear window; 3 – Vestibulocochlear artery; 4 – Vein of vestibular aqueduct; 5 – Anterior vestibular artery; 6 – Vestibular ganglion; 7 – Vestibular nerve; 8 – Facial nerve [VII]; 9 – Labyrinthine artery; 10 – Labyrinthine veins; 11 – Intermediate nerve; 12 – Cochlear nerve; 13 – Common cochlear artery; 14 – Proper cochlear artery



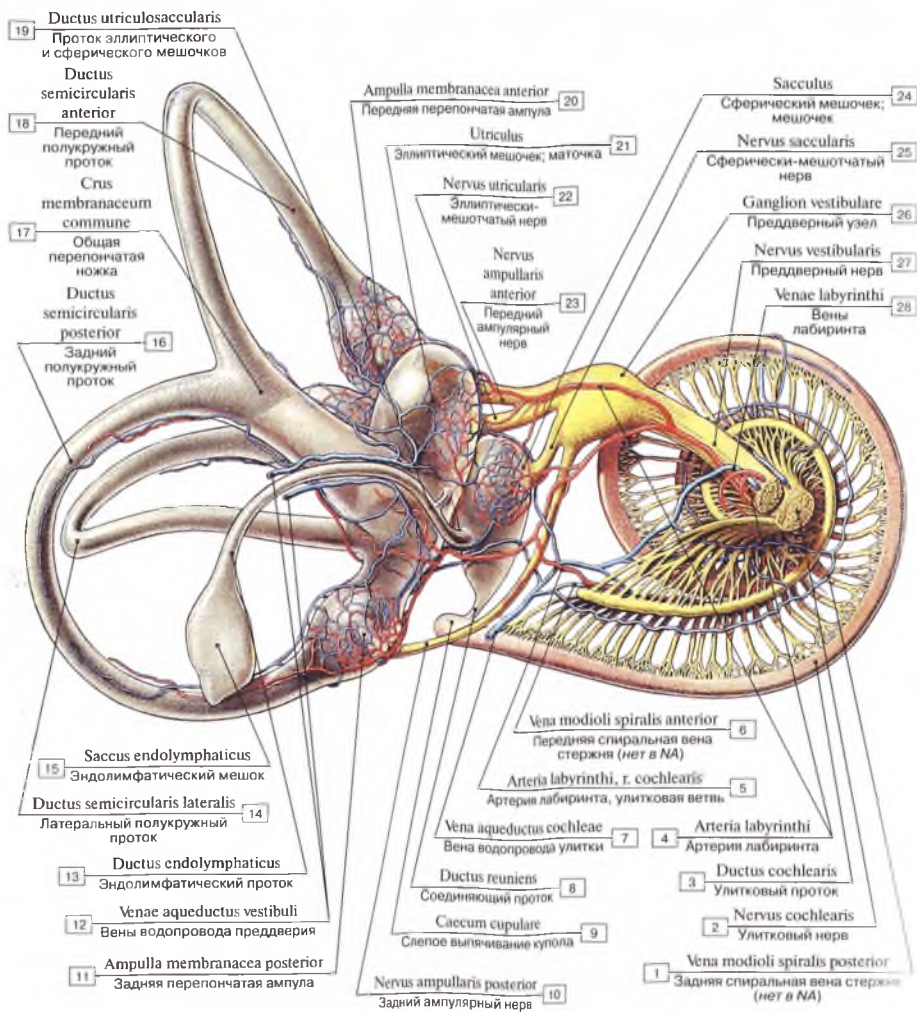


Рис. 535. Перепончатый лабиринт, левый:

1 – Posterior spiral modiolar vein; 2 – Cochlear nerve; 3 – Cochlear duct; 4 – Labyrinthine artery; 5 – Labyrinthine artery, cochlear branch; 6 – Anterior spiral modiolar vein; 7 – Vein of cochlear aqueduct; 8 – Ductus reuniens; 9 – Cupular caecum; 10 – Posterior ampullary nerve; 11 – Posterior membranous ampulla; 12 – Veins of vestibular aqueduct; 13 – Endolymphatic duct; 14 – Lateral semicircular duct; 15 – Endolymphatic sac; 16 – Posterior semicircular duct; 17 – Common membranous limb; 18 – Anterior semicircular duct; 19 – Utriculosaccular duct; 20 – Anterior membranous ampulla; 21 – Utricle; 22 – Utricular nerve; 23 – Anterior ampullary nerve; 24 – Sacculus; 25 – Sacculus nerve; 26 – Vestibular ganglion; 27 – Vestibular nerve; 28 – Labyrinthine veins

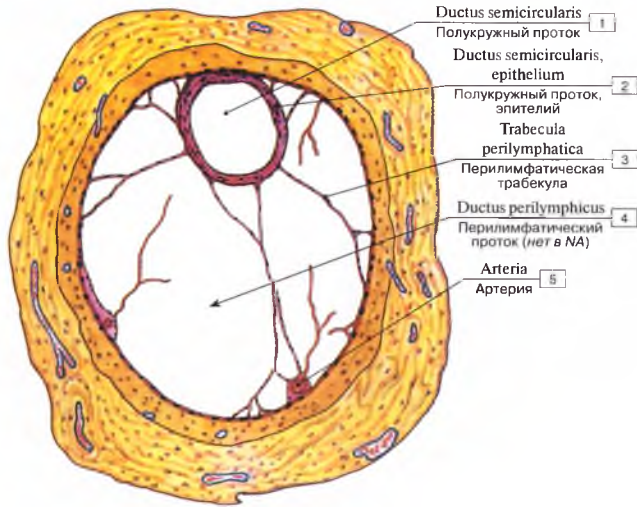


Рис. 536. Поперечный распил полукружного канала:

1 – Semicircular duct; 2 – Semicircular duct, epithelium; 3 – Perilymphatic trabecula; 4 – Perilymphatic duct; 5 – Artery

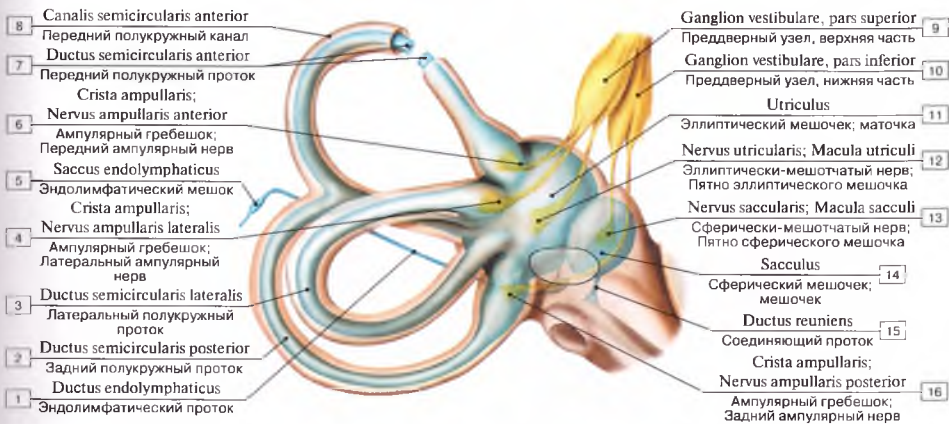


Рис. 537. Вестибулярный аппарат (схема):

1 – Endolymphatic duct; 2 – Posterior semicircular duct; 3 – Lateral semicircular duct; 4 – Ampullary crest; Lateral ampullary nerve; 5 – Endolymphatic sac; 6 – Ampullary crest; Anterior ampullary nerve; 7 – Anterior semicircular duct; 8 – Anterior semicircular canal; 9 – Vestibular ganglion, superior part; 10 – Vestibular ganglion, inferior part; 11 – Utricle; 12 – Utriclar nerve; Maculae of utricle; 13 – Saccular nerve; Maculae of saccule; 14 – Saccule; 15 – Ductus reuniens; 16 – Ampullary crest; Posterior ampullary nerve

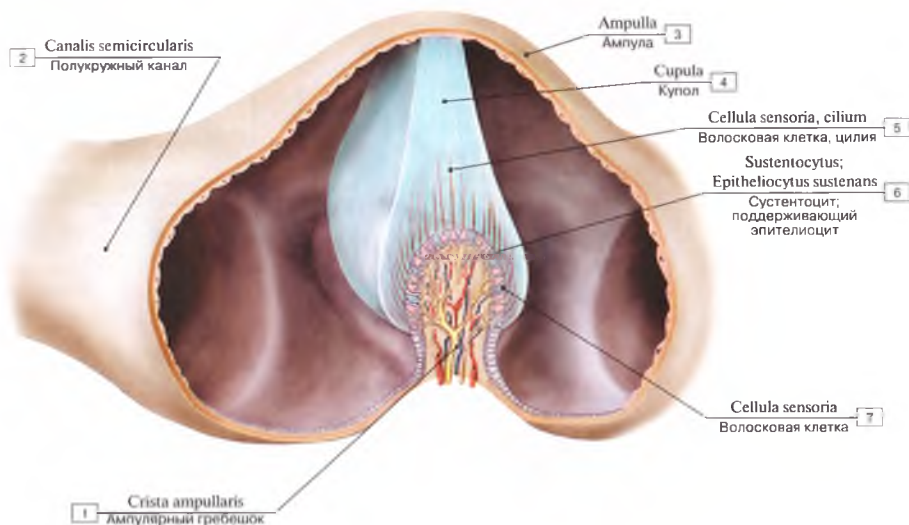


Рис. 538. Строение ампулы и ампулярного гребешка (поперечное сечение через ампулу полукружного канала):

1 – Ampullary crest; 2 – Semicircular canal; 3 – Ampulla; 4 – Cupula; 5 – Sensory cell, cilia; 6 – Nurse cell; Sustentocyte; Supporting epithelial cell; 7 – Sensory cell

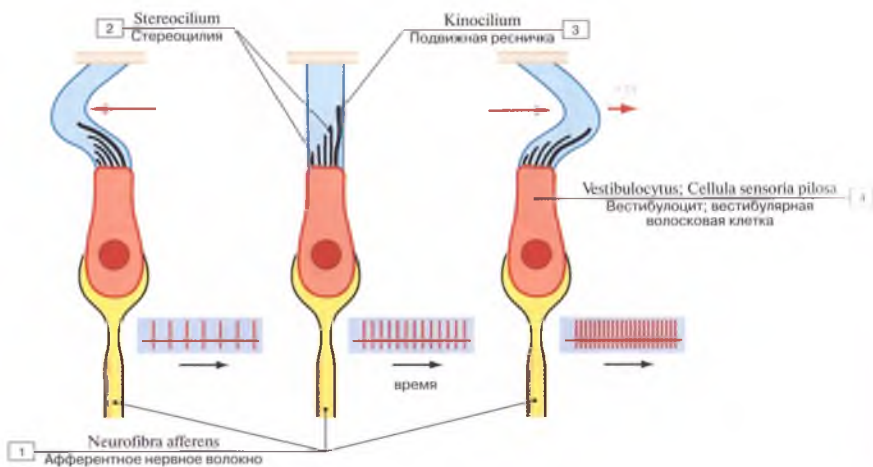


Рис. 539. Возбуждение волосковых клеток (схема):

1 – Afferent nerve fibre; 2 – Stereocilium; 3 – Kinocilium; 4 – Vestibular hair cell; Vestibular sensory cell

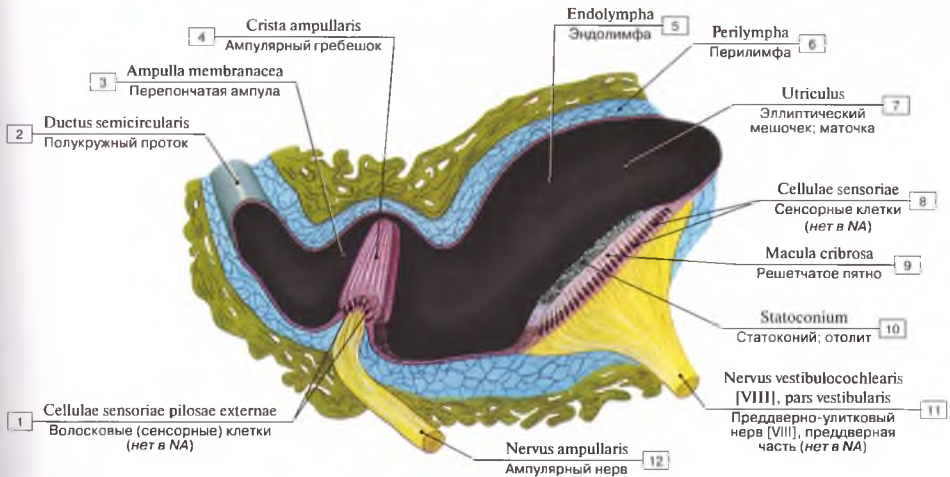


Рис. 540. Вестибулярная часть внутреннего уха:

- 1 – Hair (sensory) cells; 2 – Semicircular duct; 3 – Membranous ampulla; 4 – Ampullary crest; 5 – Endolymph; 6 – Perilymph; 7 – Utricle; 8 – Sensory cells; 9 – Macula cribrosa; 10 – Otolith; 11 – Vestibulocochlear nerve [VIII], vestibular part; 12 – Ampullary nerve

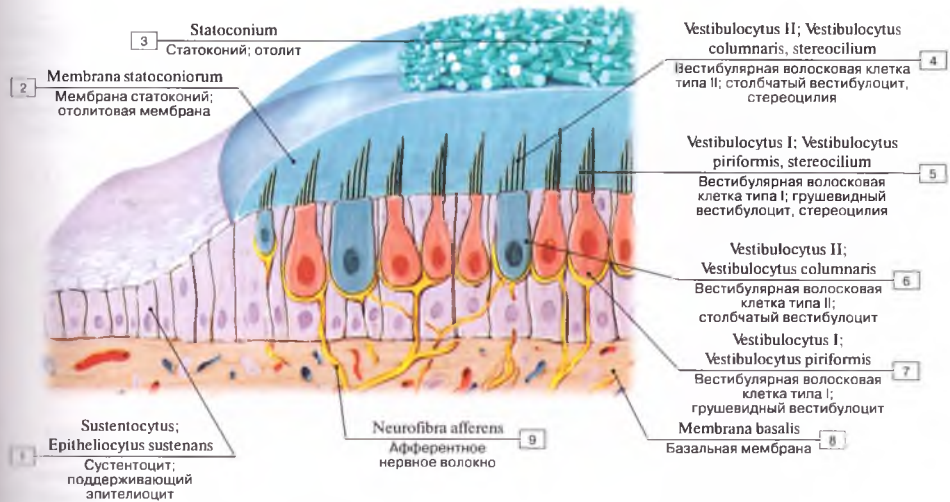


Рис. 541. Структура макул сферического и эллиптического мешочков:

- 1 – Supporting epithelial cell; 2 – Otolithic membrane; 3 – Otolith; 4 – Type II vestibular hair cell; Type II vestibular sensory cell, stereocilium; 5 – Type I vestibular hair cell; Type I vestibular sensory cell, stereocilium; 6 – Type II vestibular hair cell; Type II vestibular sensory cell; 7 – Type I vestibular hair cell; Type I vestibular sensory cell; 8 – Basal membrane; 9 – Afferent nerve fibre

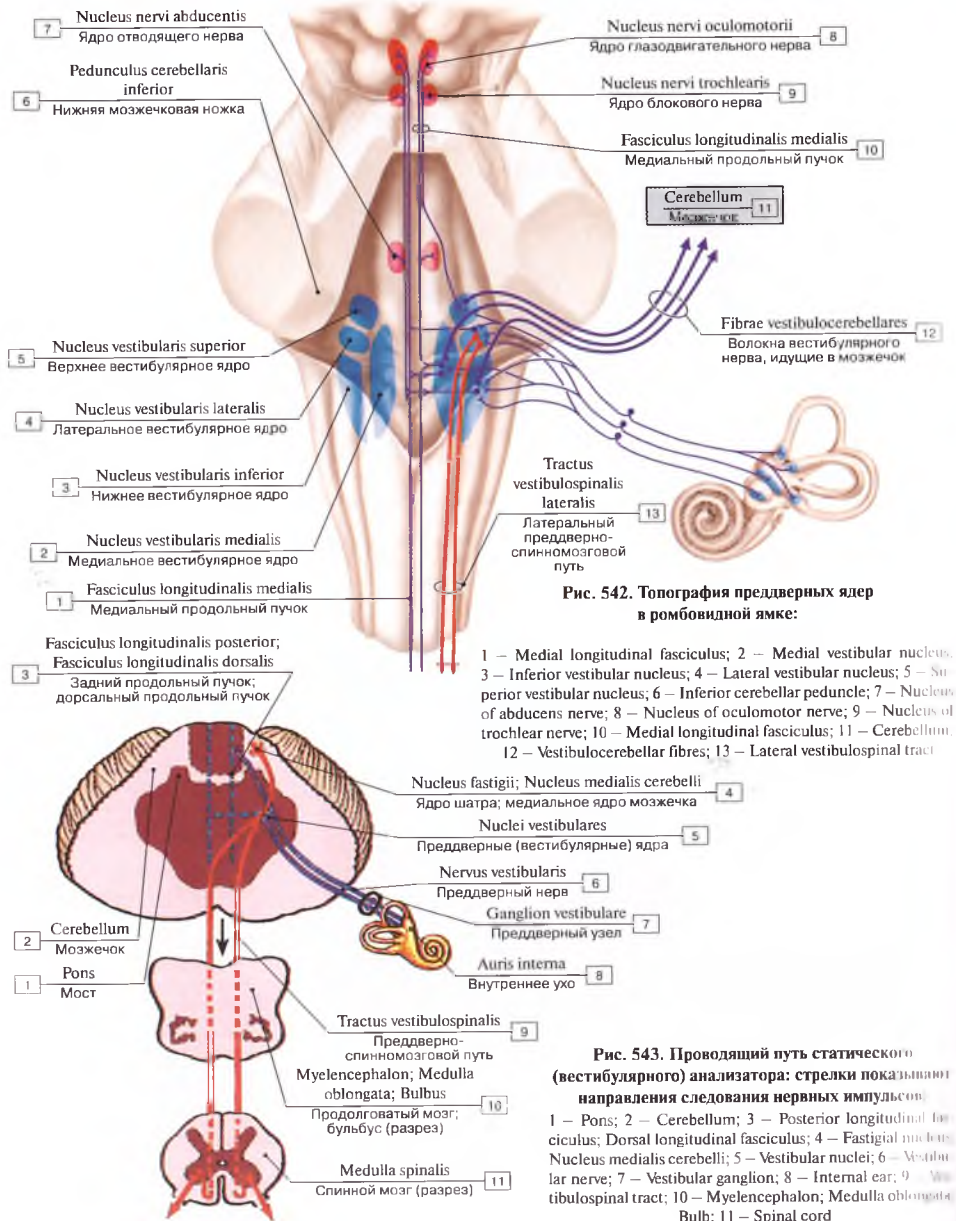


Рис. 542. Топография предверных ядер в ромбовидной ямке:

1 – Medial longitudinal fasciculus; 2 – Medial vestibular nucleus; 3 – Inferior vestibular nucleus; 4 – Lateral vestibular nucleus; 5 – Superior vestibular nucleus; 6 – Inferior cerebellar peduncle; 7 – Nucleus of abducens nerve; 8 – Nucleus of oculomotor nerve; 9 – Nucleus of trochlear nerve; 10 – Medial longitudinal fasciculus; 11 – Cerebellum; 12 – Vestibulocerebellar fibres; 13 – Lateral vestibulospinal tract.

Рис. 543. Проводящий путь статического анализатора (вестибулярного анализатора): стрелки показывают направления следования нервных импульсов.

1 – Pons; 2 – Cerebellum; 3 – Posterior longitudinal fasciculus; 4 – Fastigial nucleus; 5 – Vestibular nuclei; 6 – Vestibular nerve; 7 – Vestibular ganglion; 8 – Internal ear; 9 – Vestibulospinal tract; 10 – Myelencephalon; Medulla oblongata; Bulb; 11 – Spinal cord.

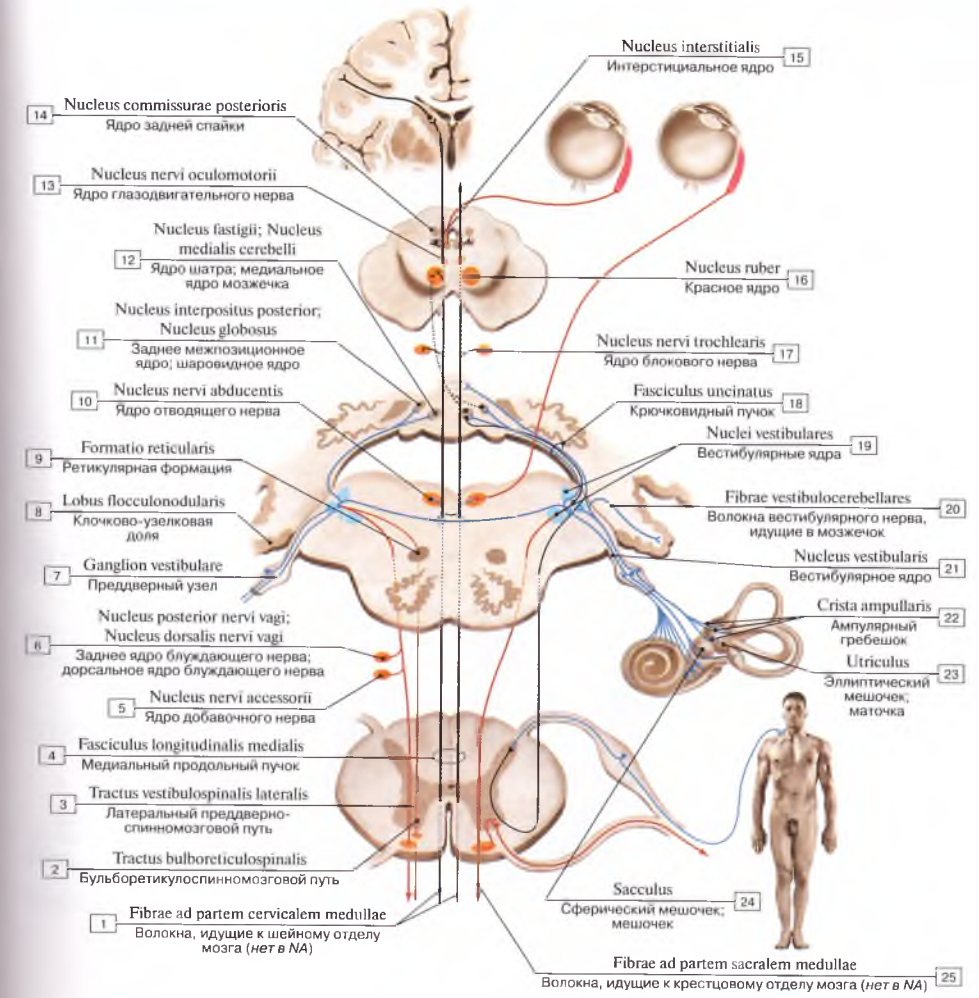


Рис. 544. Центральные связи вестибулярного нерва:

1 – Fibres to cervical cord; 2 – Reticulospinal tract; 3 – Lateral reticulospinal tract; 4 – Medial longitudinal fasciculus; 5 – Nucleus of accessory nerve; 6 – Posterior nucleus of vagus nerve; 7 – Vestibular ganglion; 8 – Nucleus of abducens nerve; 9 – Nucleus of trochlear nerve; 10 – Nucleus of posterior commissure; 11 – Interstitial nucleus; 12 – Nucleus of oculomotor nerve; 13 – Nucleus of oculomotor nerve; 14 – Nucleus of posterior commissure; 15 – Interstitial nucleus; 16 – Red nucleus; 17 – Nucleus of trochlear nerve; 18 – Uncinate fasciculus; 19 – Vestibular nuclei; 20 – Vestibulocerebellar fibres; 21 – Vestibular nucleus; 22 – Ampullary crest; 23 – Utricle; 24 – Saccule; 25 – Fibres to sacral cord.

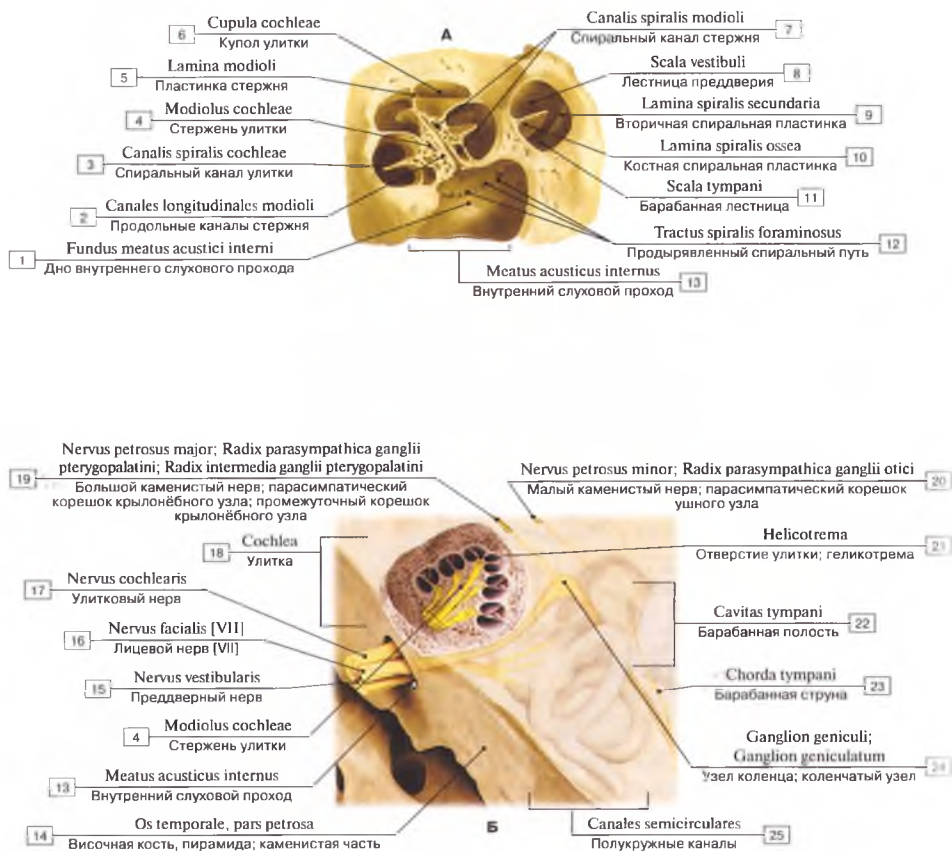


Рис. 545. Внутреннее ухо (А – спиральный канал улитки; Б – формирование преддверно-улиткового нерва):

1 – Fundus of internal acoustic meatus; 2 – Longitudinal canals of modiolus; 3 – Spiral canal of cochlea; 4 – Modiolus; 5 – Lamina of modiolus; 6 – Cochlear cupula; 7 – Spiral canal of modiolus; 8 – Scala vestibuli; 9 – Secondary spiral lamina; 10 – Osseous spiral lamina; 11 – Scala tympani; 12 – Tractus spiralis foraminosus; 13 – Internal acoustic meatus; 14 – Temporal bone, petrous part; 15 – Vestibular nerve; 16 – Facial nerve [VII]; 17 – Cochlear nerve; 18 – Cochlea; 19 – Greater petrosal nerve; Parasympathetic root of pterygopalatine ganglion; 20 – Lesser petrosal nerve; Parasympathetic root of otic ganglion; 21 – Helicotrema; 22 – Tympanic cavity; 23 – Chorda tympani; 24 – Geniculate ganglion; 25 – Semicircular canals

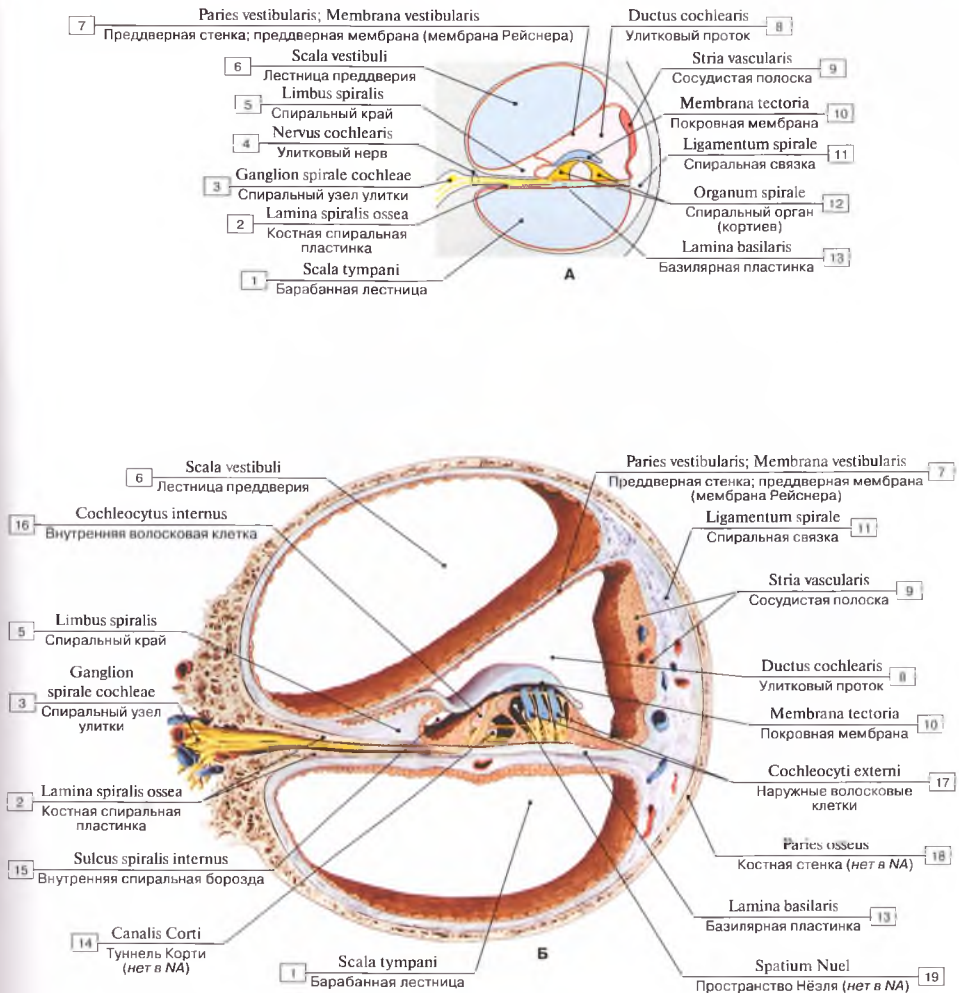


Рис. 546. Спиральный канал улитки (А – общая схема; Б – спиральный орган (кортиева):

1 – Scala tympani; 2 – Osseous spiral lamina; 3 – Spiral ganglion; 4 – Cochlear nerve; 5 – Spiral limbus; 6 – Scala vestibuli; 7 – Vestibular surface; Vestibular membrane; 8 – Cochlear duct; 9 – Stria vascularis; 10 – Tectorial membrane; 11 – Spiral ligament; 12 – Spiral organ; 13 – Basal lamina; 14 – Corti tunnel; 15 – Inner spiral sulcus; 16 – Inner hair cell; 17 – Outer hair cells; 18 – Bony wall; 19 – Nuel space

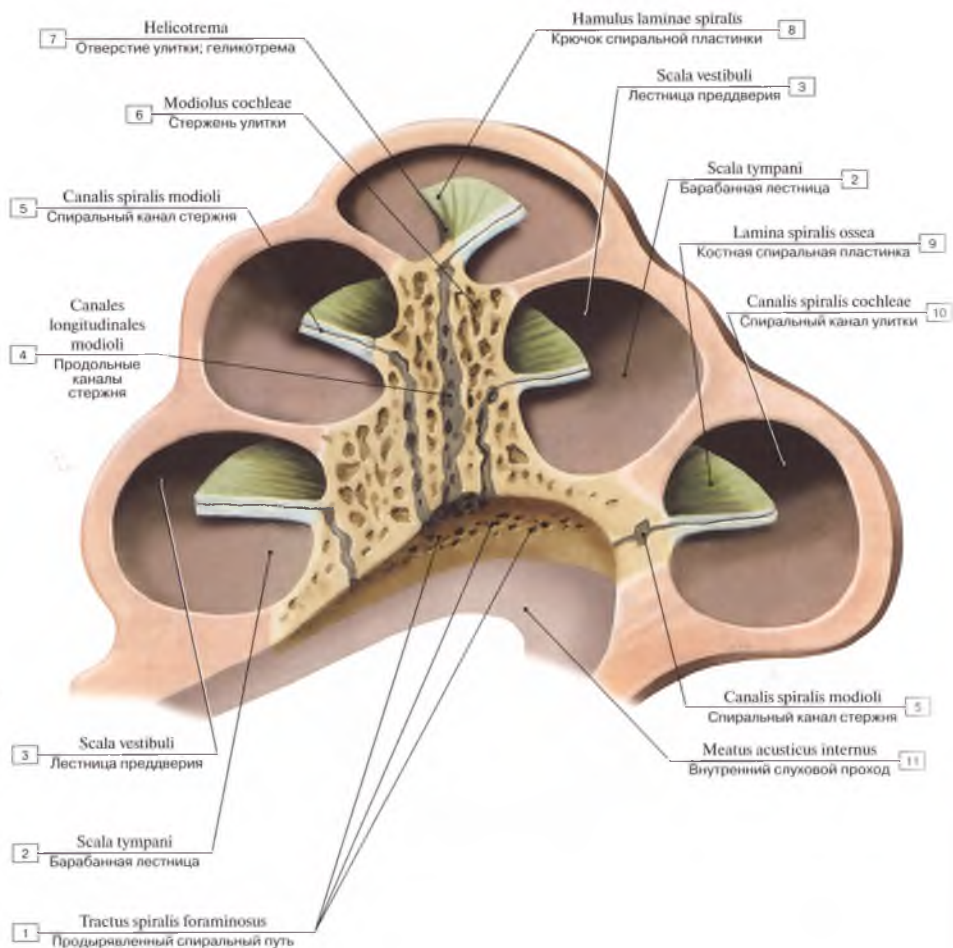


Рис. 547. Костная улитка, правая, срединный разрез:

1 – Tractus spiralis foraminosus; 2 – Scala tympani; 3 – Scala vestibuli; 4 – Longitudinal canals of modioli; 5 – Spiral canal of modioli; 6 – Modiolus; 7 – Helicotrema; 8 – Hamulus of spiral lamina; 9 – Osseous spiral lamina; 10 – Spiral canal of cochlea; 11 – Internal acoustic meatus



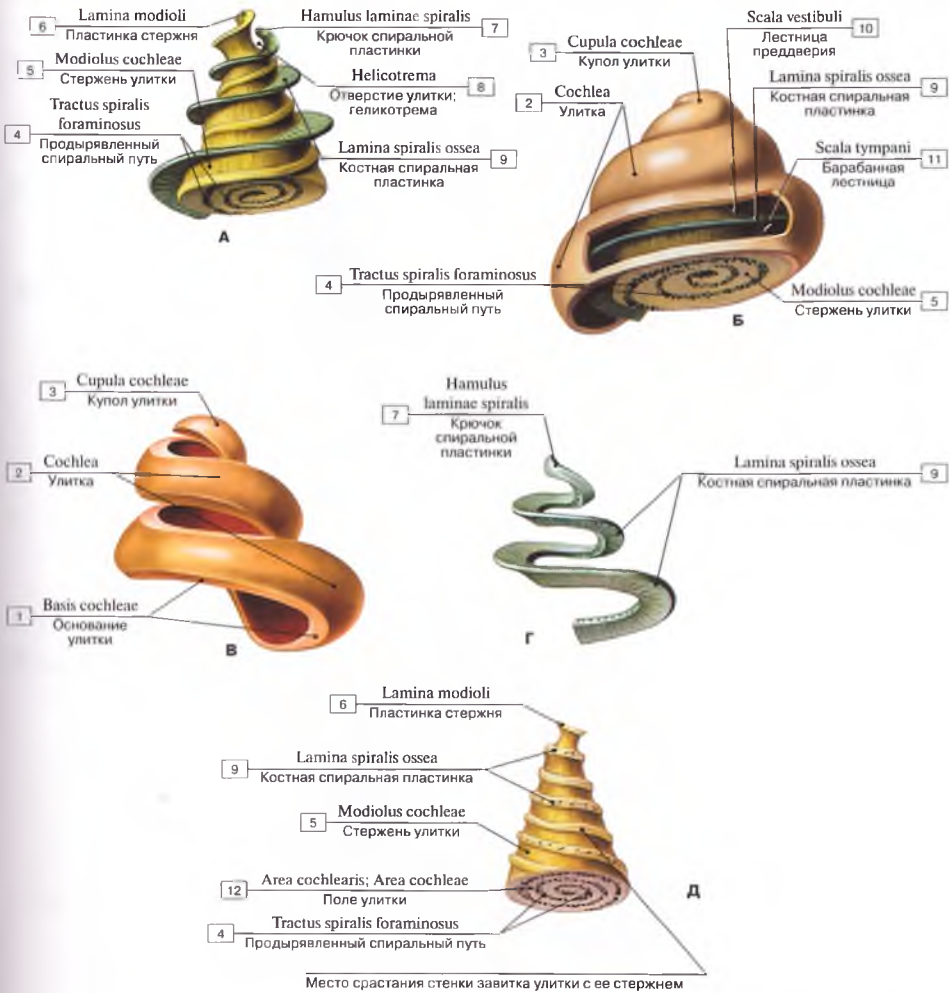


Рис. 548. Костная улитка (А, Б – стержень и костная спиральная пластинка улитки, полностью вскрыта (А), частично вскрыта (Б); В – стенка костной улитки; Г – костная спиральная пластинка улитки; Д – стержень улитки);

1 – Base of cochlea; 2 – Cochlea; 3 – Cochlear cupula; 4 – Tractus spiralis foraminosus; 5 – Modiolus; 6 – Lamina of modiolus; 7 – Hamulus of spiral lamina; 8 – Helicotrema; 9 – Osseous spiral lamina; 10 – Scala vestibuli; 11 – Scala tympani; 12 – Cochlear area

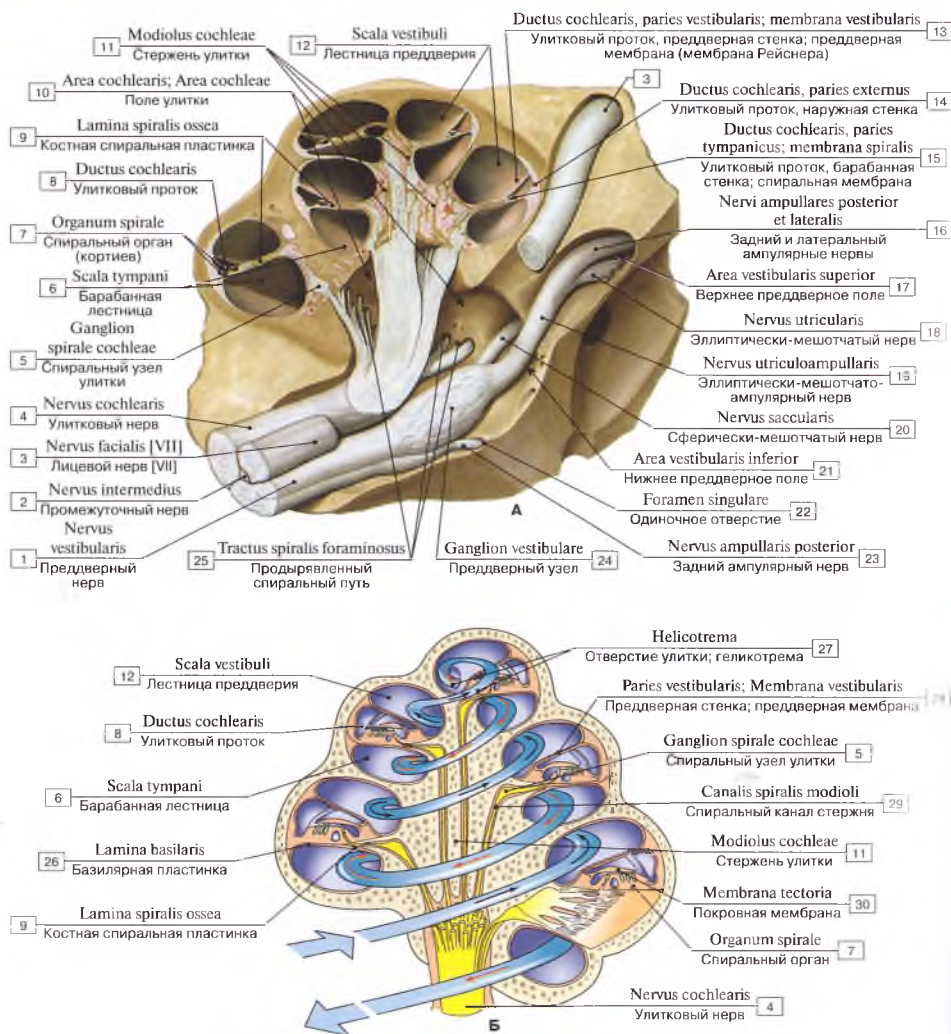


Рис. 549. Срединный распил правой улитки, костный и перепончатый лабиринты (А – строение; Б – схема направления витков):

1 – Vestibular nerve; 2 – Intermediate nerve; 3 – Facial nerve [VII]; 4 – Cochlear nerve; 5 – Spiral ganglion; 6 – Scala tympani; 7 – Spiral organ; 8 – Cochlear duct; 9 – Osseous spiral lamina; 10 – Cochlear area; 11 – Modiolus; 12 – Scala vestibuli; 13 – Cochlear duct, vestibular surface; vestibular membrane; 14 – Cochlear duct, external surface; 15 – Cochlear duct, tympanic surface; spiral membrane; 16 – Posterior and lateral ampullary nerves; 17 – Superior vestibular area; 18 – Utricular nerve; 19 – Utriculo-ampullary nerve; 20 – Sacculus nerve; 21 – Inferior vestibular area; 22 – Foramen singulare; 23 – Posterior ampullary nerve; 24 – Vestibular ganglion; 25 – Tractus spiralis foraminosus; 26 – Basilar lamina; 27 – Helicotrema; 28 – Vestibular surface; Vestibular membrane; 29 – Spiral canal of modiolus; 30 – Tectorial membrane

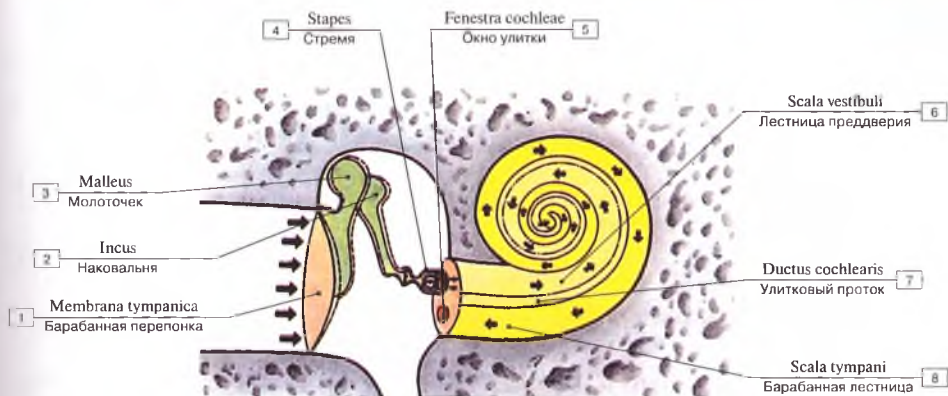


Рис. 550. Распространение звуковой волны (показано стрелками) в наружном, среднем и внутреннем ухе (схема):

1 – Tympanic membrane; 2 – Incus; 3 – Malleus; 4 – Stapes; 5 – Round window; 6 – Scala vestibuli; 7 – Cochlear duct; 8 – Scala tympani

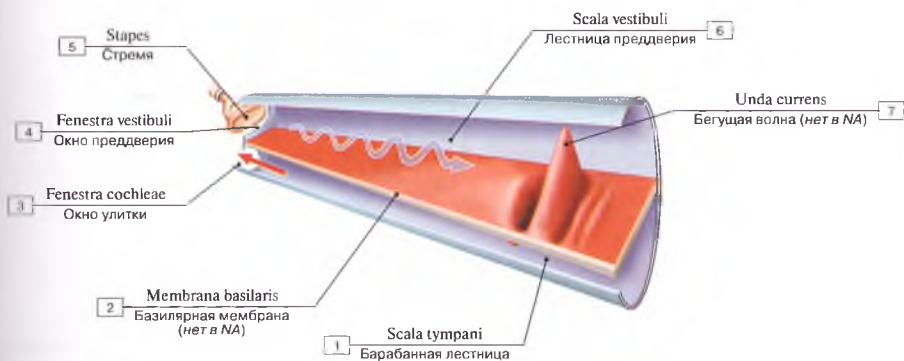


Рис. 551. Образование и распространение звуковой волны в улитке:

1 – Scala tympani; 2 – Basilar membrane; 3 – Round window; 4 – Oval window; 5 – Stapes; 6 – Scala vestibuli; 7 – Traveling wave

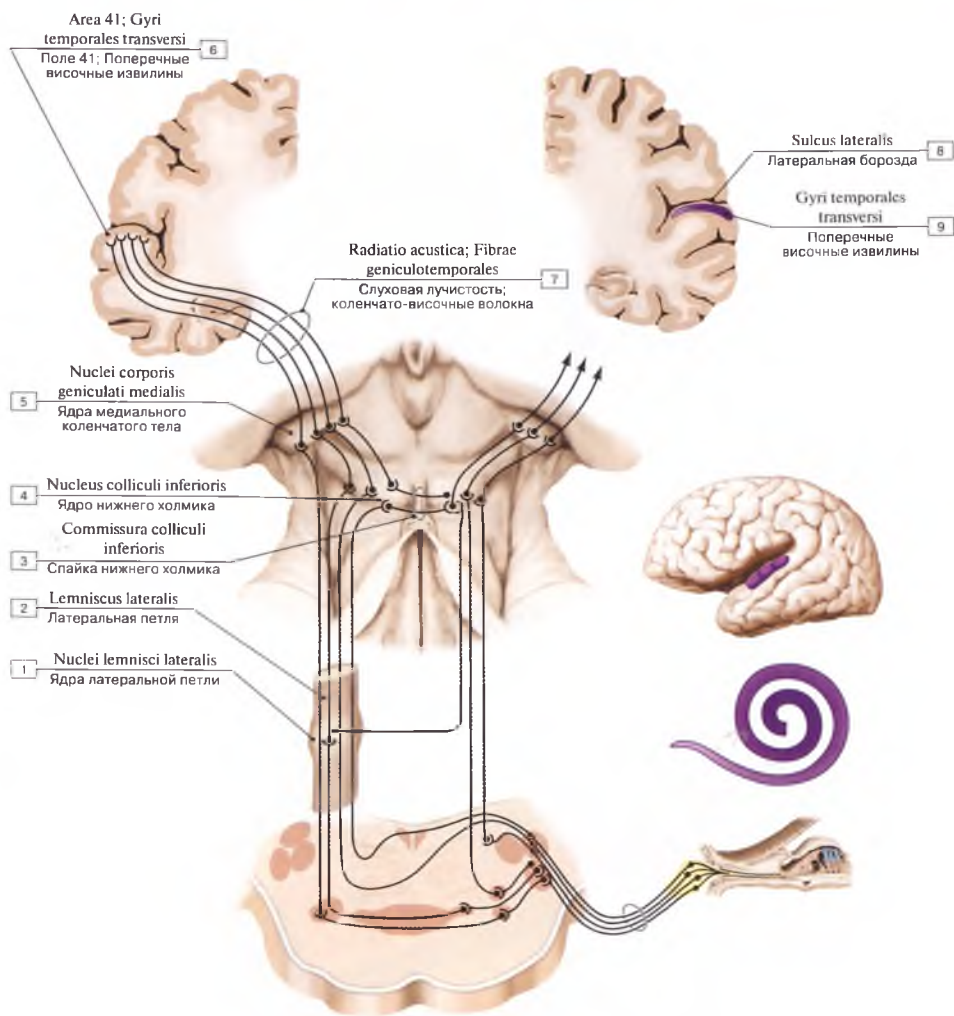


Рис. 552. Аfferентный слуховой путь левого уха:

1 – Nuclei of lateral lemniscus; 2 – Lateral lemniscus; 3 – Commissure of inferior colliculus; 4 – Nucleus of inferior colliculus; 5 – Nuclei of medial geniculate body; 6 – Area 41; Transverse temporal gyri; 7 – Acoustic radiation; Genuiculotemporal fibres; 8 – Lateral sulcus; 9 – Transverse temporal gyri

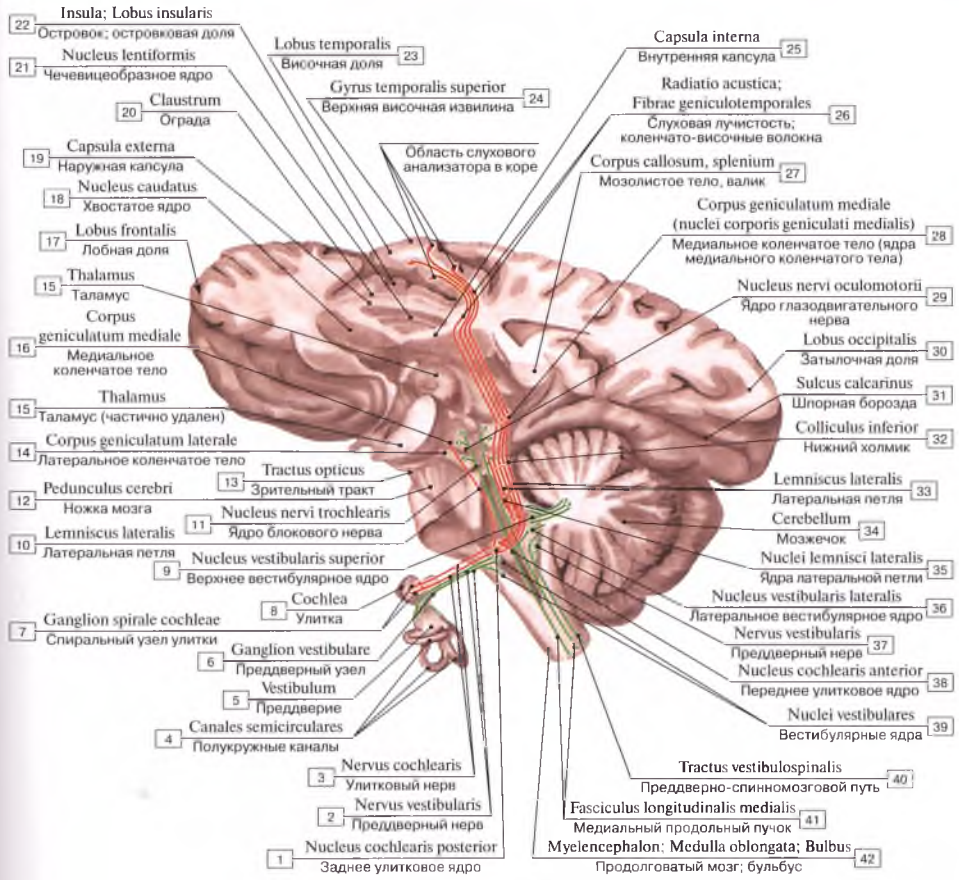


Рис. 553. Направление волокон слухового нерва (схема):

1 – Posterior cochlear nucleus; Dorsal cochlear nucleus; 2 – Vestibular nerve; 3 – Cochlear nerve; 4 – Semicircular canals; 5 – Vestibule; 6 – Vestibular ganglion; 7 – Spiral ganglion; 8 – Cochlea; 9 – Superior vestibular nucleus; 10 – Lateral lemniscus; 11 – Nucleus of trochlear nerve; 12 – Cerebral peduncle; 13 – Optic tract; 14 – Lateral geniculate body; 15 – Thalamus; Dorsal thalamus; 16 – Medial geniculate body; 17 – Frontal lobe; 18 – Caudate nucleus; 19 – External capsule; 20 – Claustrum; 21 – Lentiform nucleus; Lenticular nucleus; 22 – Insula; Insular lobe; 23 – Temporal lobe; 24 – Superior temporal gyrus; 25 – Internal capsule; 26 – Acoustic radiation; Geniculotemporal fibres; 27 – Corpus callosum; 28 – Medial geniculate body (medial geniculate nuclei); 29 – Nucleus of oculomotor nerve; 30 – Occipital lobe; 31 – Calcarine sulcus; 32 – Inferior colliculus; 33 – Lateral lemniscus; 34 – Cerebellum; 35 – Nuclei of lateral lemniscus; 36 – Lateral vestibular nucleus; 37 – Vestibular nerve; 38 – Anterior cochlear nucleus; Ventral cochlear nucleus; 39 – Vestibular nuclei; 40 – Vestibulospinal tract; 41 – Medial longitudinal fasciculus; 42 – Myelencephalon; Medulla oblongata; Bulb

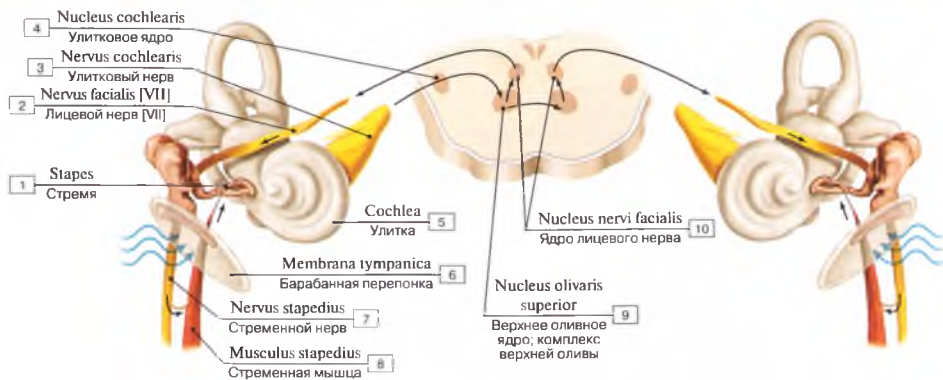


Рис. 554. Рефлекс стремечка:

1 – Stapes; 2 – Facial nerve [VII]; 3 – Cochlear nerve; 4 – Cochlear nucleus; 5 – Cochlea; 6 – Tympanic membrane; 7 – Nerve to stapedius; 8 – Stapedius; 9 – Superior olivary nucleus; Superior olivary complex; 10 – Motor nucleus of facial nerve

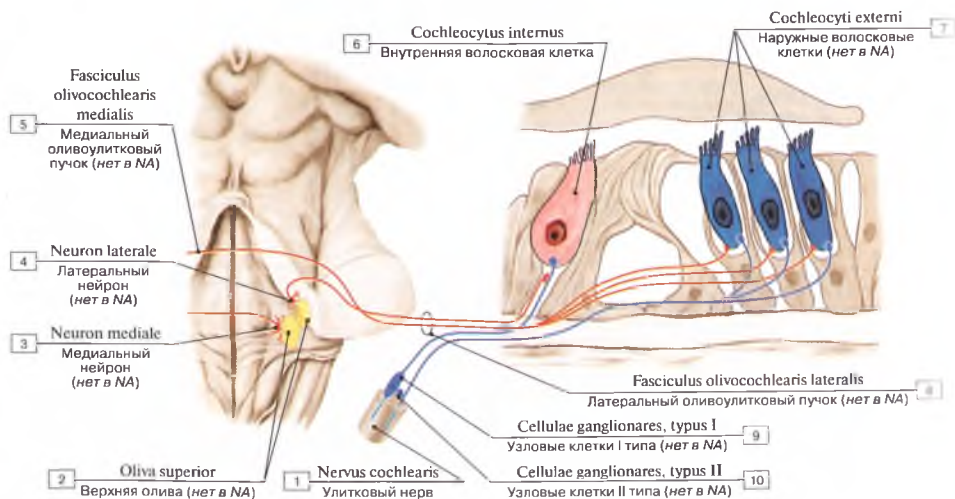


Рис. 555. Двигательные волокна от оливы к кортиеvu органу:

1 – Cochlear nerve; 2 – Superior olive; 3 – Medial neuron; 4 – Lateral neuron; 5 – Medial olivocochlear fascicle; 6 – Inner hair cell; 7 – Outer hair cells; 8 – Lateral olivocochlear fascicle; 9 – Type I ganglion cells; 10 – Type II ganglion cells

ОРГАН ВКУСА

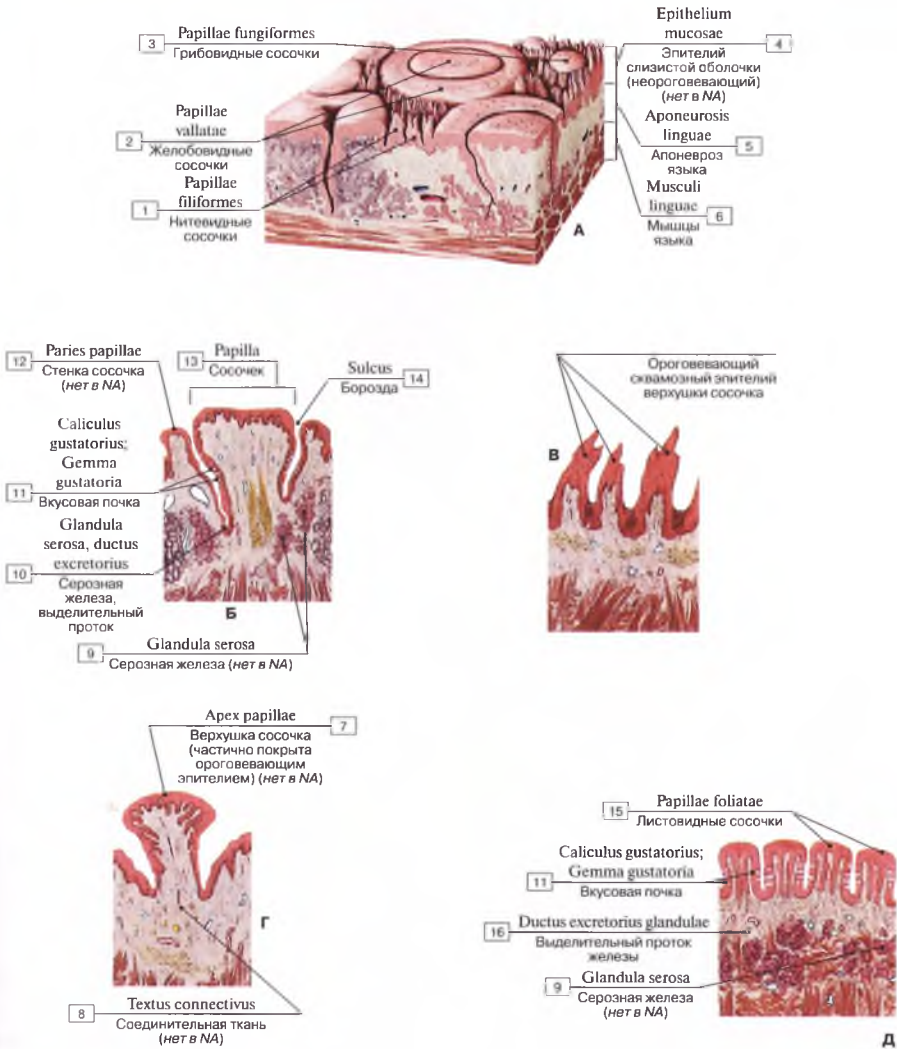


Рис. 556. Сосочки языка (А, Б – желобовидные; В – нитевидные; Г – грибовидный; Д – листовидные):

1 – Filiform papillae; 2 – Vallate papillae; 3 – Fungiform papillae; 4 – Epithelium mucosae; 5 – Lingual aponeurosis; 6 – Muscles of tongue; 7 – Tip of papilla; 8 – Connective tissue; 9 – Serous gland; 10 – Serous gland, excretory duct; 11 – Taste bud; 12 – Wall of papilla; 13 – Papilla; 14 – Sulcus; 15 – Foliolate papillae; 16 – Excretory duct of gland

## ОРГАН ОБОНЯНИЯ

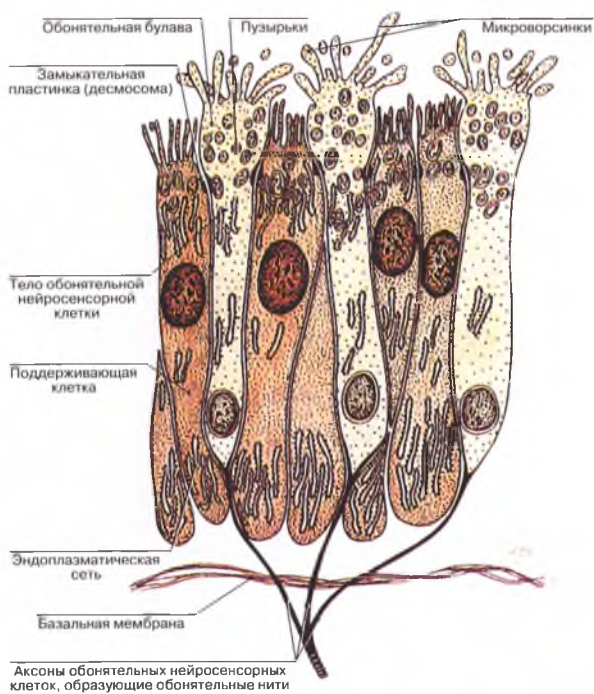


Рис. 561. Ультрамикроскопическое строение обонятельного эпителия (схема)



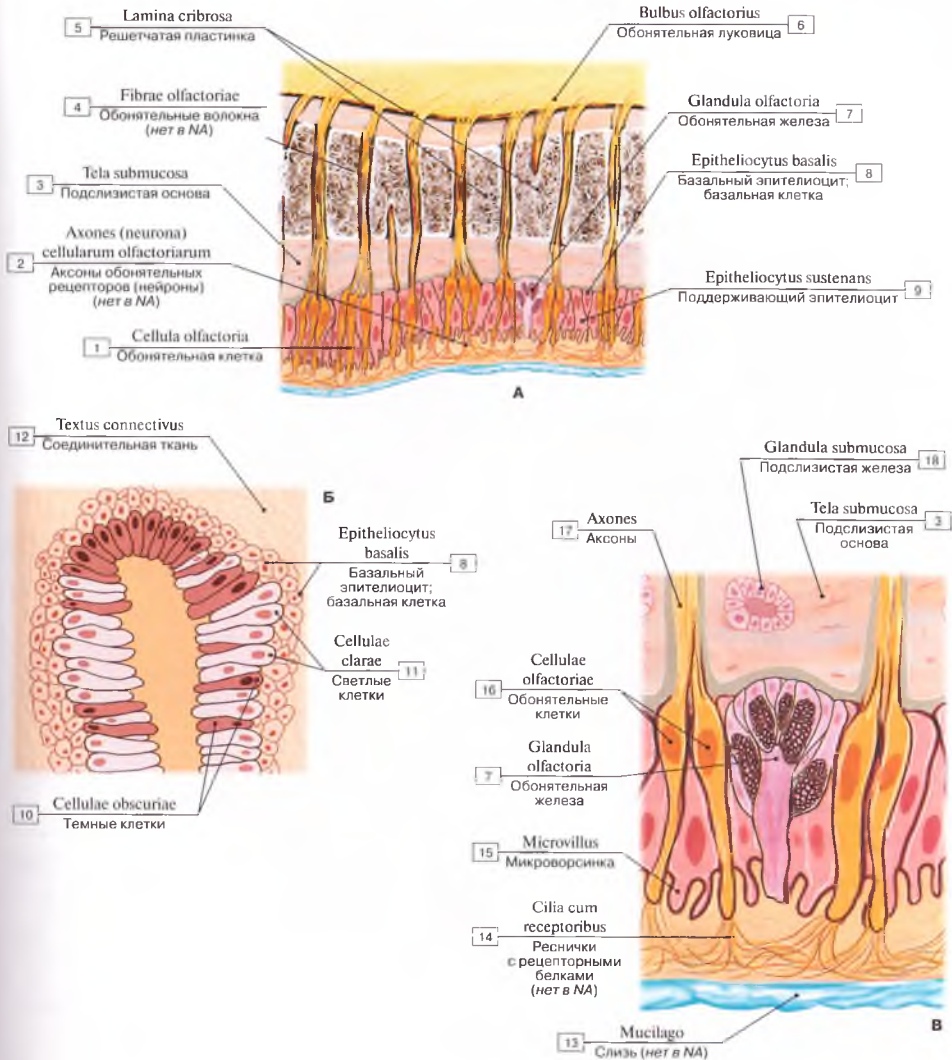


Рис. 562. Обонятельная выстилка вомероназального органа (А – обонятельный эпителий; Б – вомероназальный орган (схема); В – формирование обонятельных нервов):

- 1 – Olfactory cell; 2 – Axons of olfactory receptors (neurons); 3 – Submucosa; 4 – Olfactory fibres; 5 – Cribriform plate; 6 – Olfactory bulb; 7 – Olfactory gland; 8 – Basal cell; 9 – Supporting epithelial cell; 10 – Dark cells; 11 – Clear cells; 12 – Connective tissue; 13 – Mucus; 14 – Cilia with receptor proteins; 15 – Microvillus; 16 – Olfactory cells; 17 – Axons; 18 – Submucosa gland

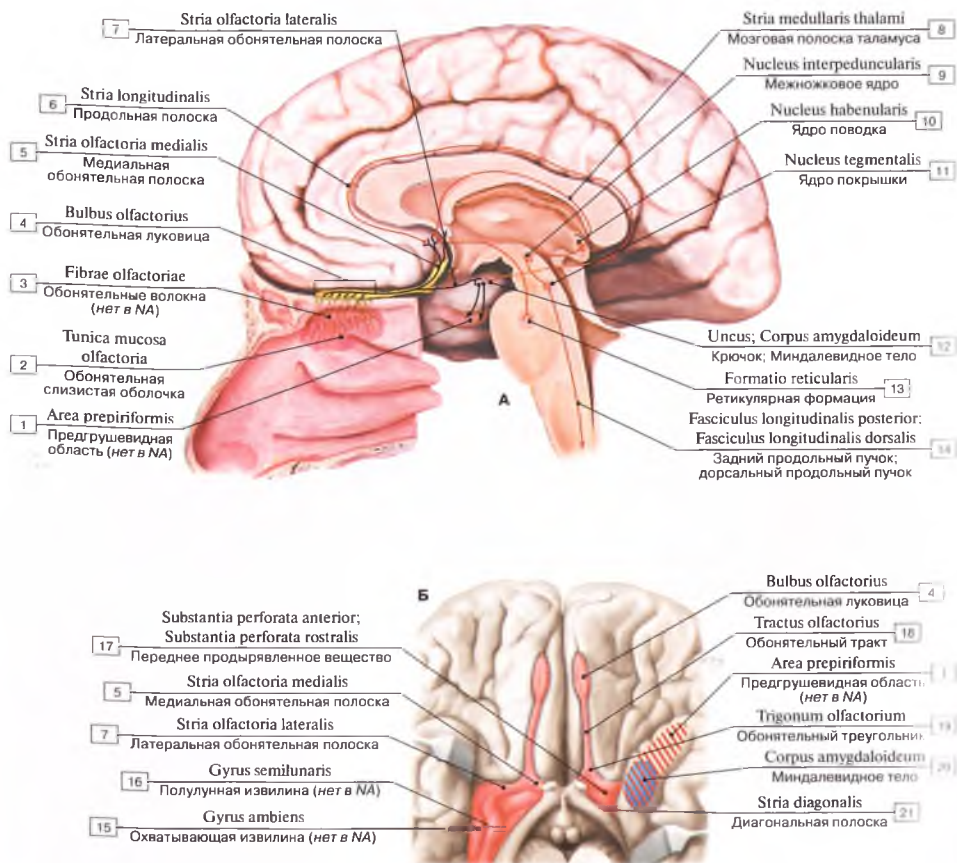


Рис. 563. Проводящий путь органа обоняния (А – сагиттальный разрез; Б – вид снизу):

1 – Prepiriform area; 2 – Olfactory mucosal membrane; 3 – Olfactory fibres; 4 – Olfactory bulb; 5 – Medial olfactory stria; 6 – Longitudinal stria; 7 – Lateral olfactory stria; 8 – Stria medullaris of thalamus; 9 – Interpeduncular nucleus; 10 – Habenular nucleus; 11 – Tegmental nucleus; 12 – Uncus; Amygdaloid body; Amygdaloid complex; 13 – Reticular formation; 14 – Posterior longitudinal fasciculus; Dorsal longitudinal fasciculus; 15 – Ambient gyrus; 16 – Semilunar gyrus; 17 – Anterior perforated substance; 18 – Olfactory tract; 19 – Olfactory trigone; 20 – Amygdaloid body; Amygdaloid complex; 21 – Diagonal band

ОБЩИЙ ПОКРОВ (КОЖА)

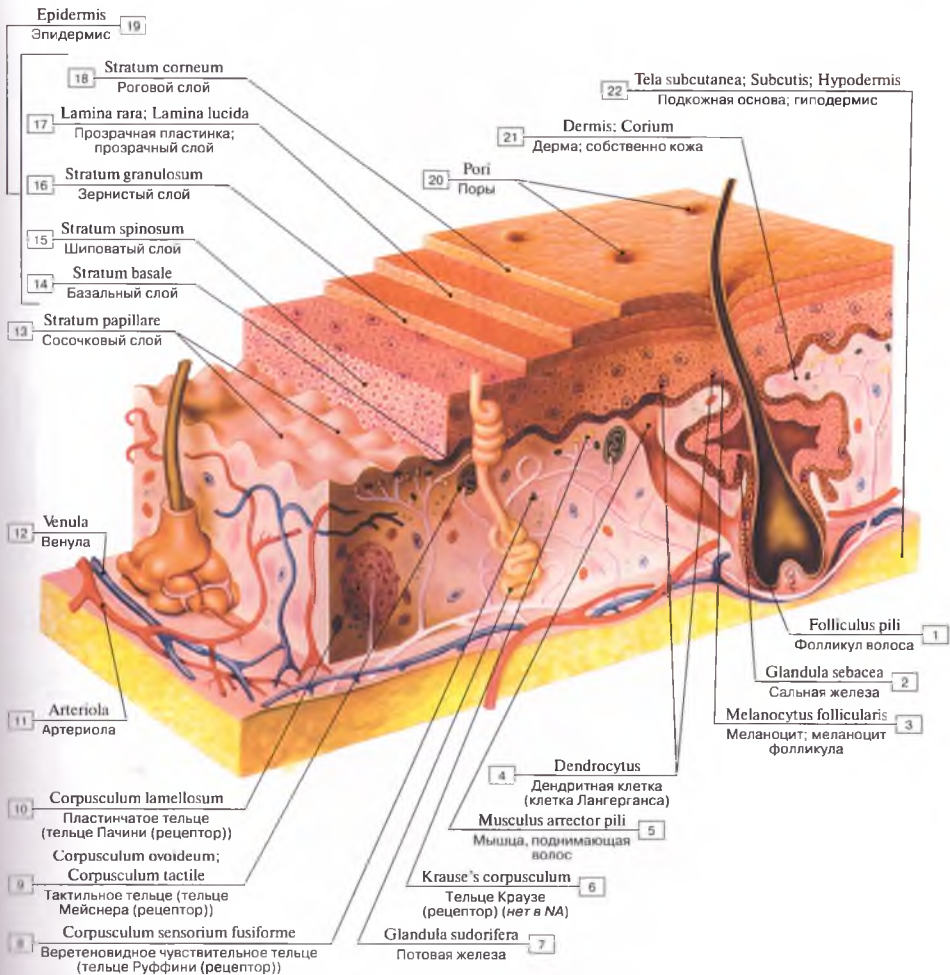


Рис. 564. Микроскопическая структура кожи:

1 – Hair follicle; 2 – Sebaceous gland; 3 – Melanocyte; 4 – Dendritic cell; 5 – Arrector muscle of hair; 6 – Krause's corpuscle; 7 – Sweat gland; 8 – Bulbous corpuscle; 9 – Tactile corpuscle; 10 – Lamellar corpuscle; 11 – Arteriole; 12 – Venule; 13 – Papillary dermis; 14 – Basal layer; 15 – Spiny layer; 16 – Granular layer; 17 – Clear layer; 18 – Stratum corneum; Horny layer; 19 = 14 + 15 + 16 + 17 + 18 – Epidermis; 20 – Pores; 21 – Dermis; Corium; 22 – Subcutaneous tissue

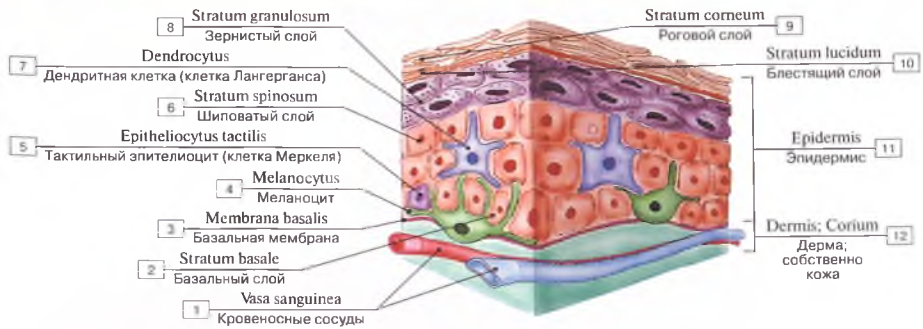


Рис. 565. Кожа:

1 — Blood vessels; 2 — Basal layer; 3 — Basement membrane; 4 — Melanocyte; 5 — Tactile epithelial cell; 6 — Spiny layer; 7 — Dendritic cell; 8 — Granular layer; 9 — Stratum corneum; Horny layer; 10 — Stratum lucidum; 11 — Epidermis; 12 — Dermis; Corium

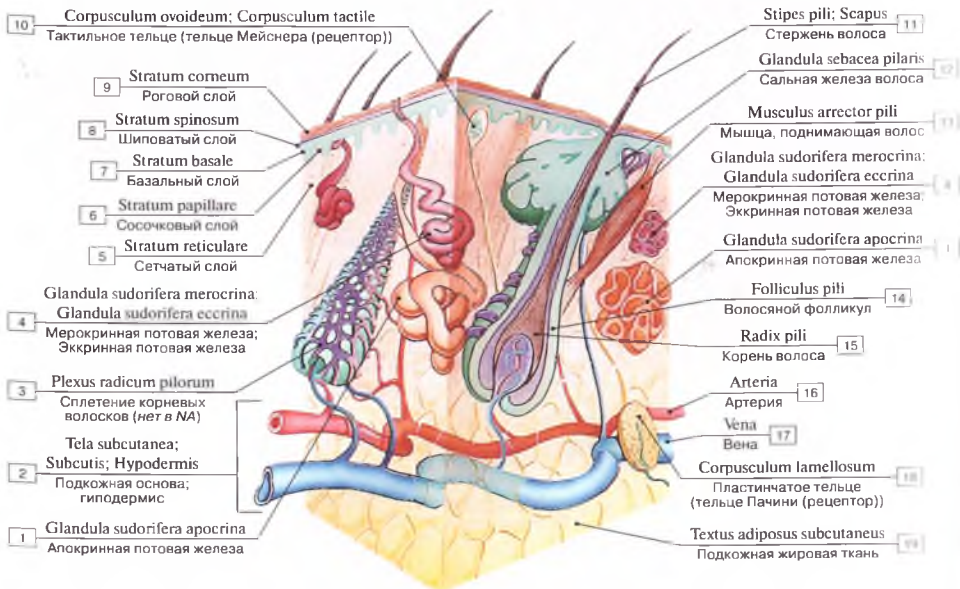


Рис. 566. Железы кожи:

1 — Apocrine sweat gland; 2 — Subcutaneous tissue; 3 — Plexus of root hair; 4 — Eccrine sweat gland; 5 — Plexiform layer; 6 — Papillary dermis; 7 — Basal layer; 8 — Spiny layer; 9 — Stratum corneum; Horny layer; 10 — Tactile corpuscle; 11 — Hair shaft; 12 — Hair sebaceous gland; 13 — Arrector pili muscle; 14 — Hair follicle; 15 — Hair root; 16 — Artery; 17 — Vein; 18 — Lamellar corpuscle; 19 — Subcutaneous adipose tissue

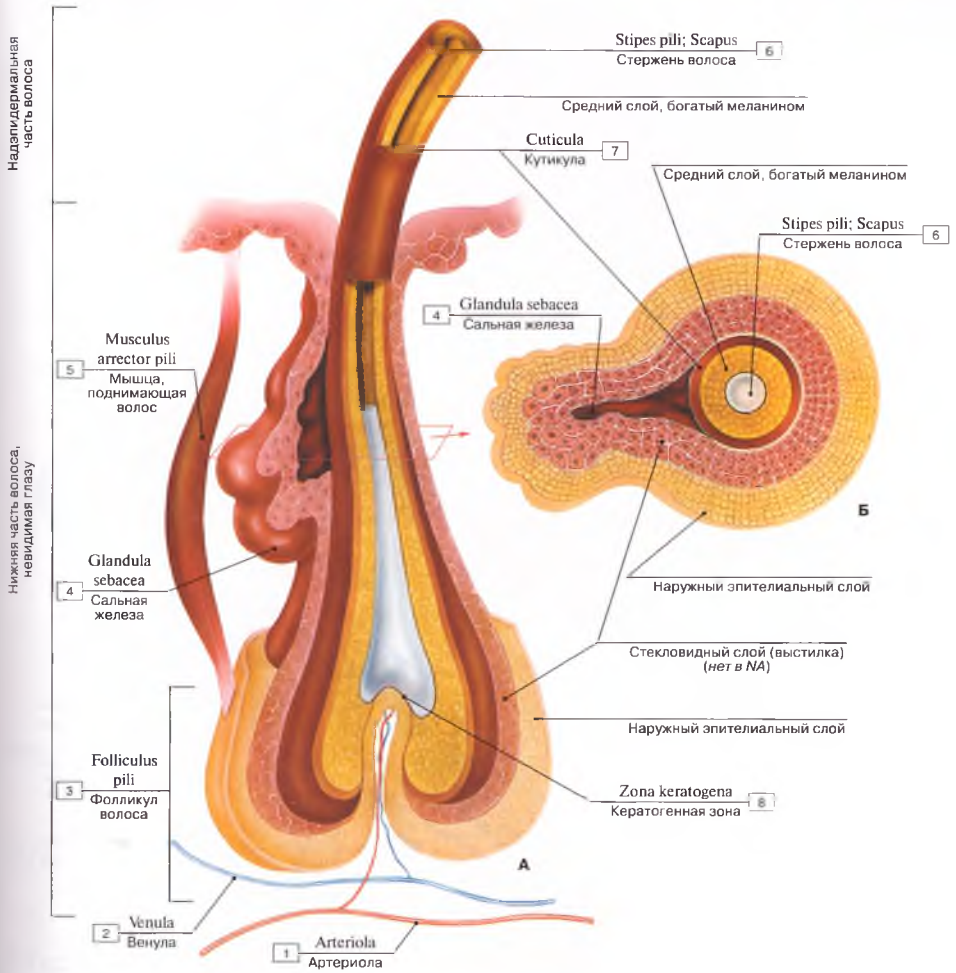


Рис. 567. Волосяной фолликул (А – продольный разрез; Б – поперечный разрез):

1 – Arteriole; 2 – Venule; 3 – Hair follicle; 4 – Sebaceous gland; 5 – Arrector muscle of hair; 6 – Hair shaft; 7 – Cuticle; 8 – Keratogenic zone

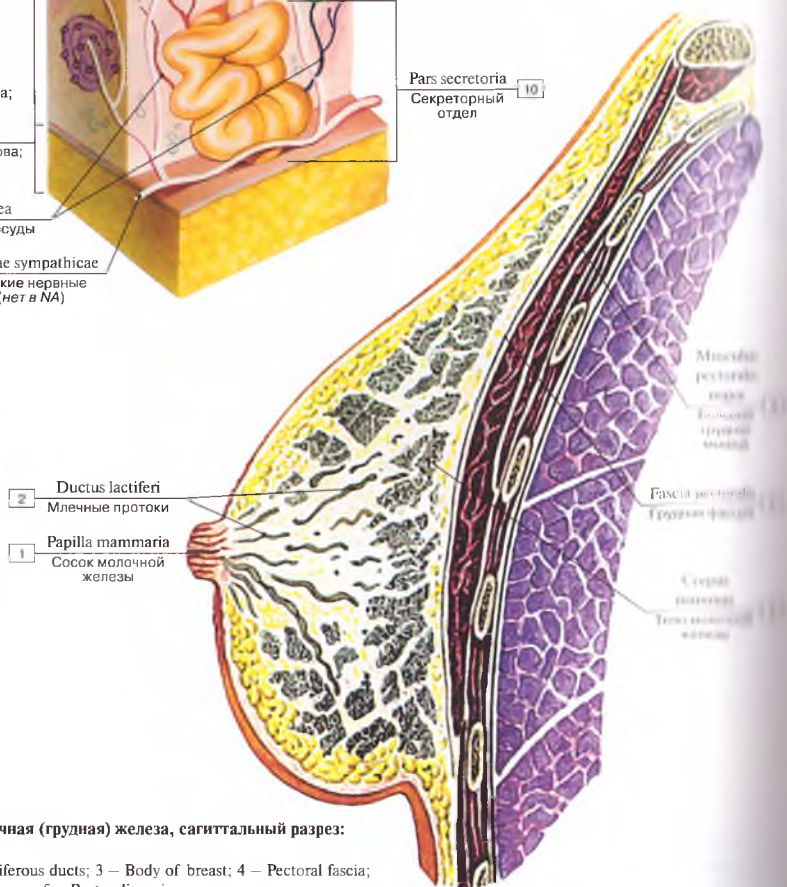
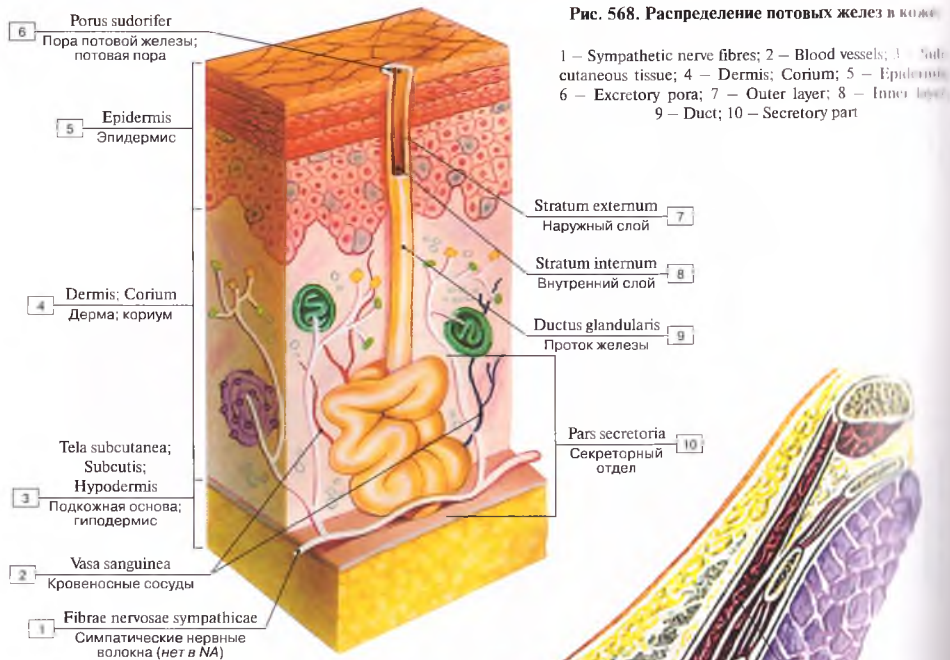


Рис. 569. Молочная (грудная) железа, сагиттальный разрез:

1 – Nipple; 2 – Lactiferous ducts; 3 – Body of breast; 4 – Pectoral fascia;  
5 – Pectoralis major



The page contains extremely faint, illegible text that is barely visible against the white background. The text appears to be organized into several paragraphs, but the characters and words are too light to be transcribed accurately. There are some very faint horizontal lines that might represent paragraph breaks or section dividers.



**Габриэль Лазаревич  
Билич**

Академик Российской академии естественных наук, академик Международной академии наук (Мюнхен), доктор медицинских наук, профессор. Автор 422 опубликованных научных работ, в том числе 20 учебников, 19 учебных пособий, 22 монографий.

**Основные издания:** Анатомия человека. Русско-латинский атлас. – М.: Оникс, 2006 (победитель III Общероссийского конкурса учебных изданий для вузов «Университетская книга», 2006; лауреат конкурса «Лучшие учебные издания» III Конгресса с международным участием «Медицинский форум», 2008); Анатомия человека: Учебник: в 2 т. – М.: Оникс, 1–8 изд.; Анатомия человека: в 3 т. – М.: ГЭОТАР-Медиа, 1–3 изд.; Биология. Полный курс: в 3 т. – М.: Оникс, 1–5 изд.; Биология. Универсальный атлас: в 2 т. – М.: Оникс, 2006 (лауреат конкурса «Лучшие учебные издания» III Конгресса с международным участием «Медицинский форум», 2008); Анатомия человека. Атлас: в 3 т. – М.: ГЭОТАР-Медиа, 2010–2012.



**Валерий Анатольевич  
Крыжановский**

Кандидат биологических наук, доцент. Автор 119 опубликованных научных работ, в том числе 7 учебников и учебных пособий.

**Основные издания:** Анатомия человека. Русско-латинский атлас. – М.: Оникс, 2006 (победитель III Общероссийского конкурса учебных изданий для вузов «Университетская книга», 2006; лауреат конкурса «Лучшие учебные издания» III Конгресса с международным участием «Медицинский форум», 2008); Биология. Полный курс: в 3 т. – М.: Оникс, 1–5 изд.; Биология. Универсальный атлас: в 2 т. – М.: Оникс, 2006 (лауреат конкурса «Лучшие учебные издания» III Конгресса с международным участием «Медицинский форум», 2008); Анатомия человека. Атлас: в 3 т. – М.: ГЭОТАР-Медиа, 2010–2012.



## ПРИГЛАШЕНИЕ К СОТРУДНИЧЕСТВУ

Издательская группа «ГЭОТАР-Медиа» приглашает к сотрудничеству авторов и редакторов медицинской литературы, литературы по ветеринарии и агротехнике.

**ИЗДАТЕЛЬСТВО СПЕЦИАЛИЗИРУЕТСЯ НА ВЫПУСКЕ** учебной литературы для вузов и колледжей, атласов, руководств для врачей, переводных изданий

По вопросам издания рукописей обращайтесь в отдел по работе с авторами.  
Тел.: (495) 921-39-07.

*Учебное издание*

**Билич** Габриэль Лазаревич  
**Крыжановский** Валерий Анатольевич

## АТЛАС АНАТОМИЯ ЧЕЛОВЕКА

**В 3 томах**  
**Том 3**

Авторы идеи *Б.И. Нигматулин, Г.Л. Билич, В.А. Крыжановский*  
Генеральный менеджер проекта *Б.И. Нигматулин*  
Зав. редакцией *С.А. Меренкова*  
Научные редакторы *С.С. Виноградова, А.В. Сокол*  
Корректоры *Е.А. Александрова, П.И. Куренков, Е.Д. Зоркова*  
Подготовка оригинал-макета *П.И. Куренков*  
Дизайн обложки *И.Е. Сорокин*

Подписано в печать 30.08.12. Формат 60×90<sup>1/16</sup>  
Бумага мелованная. Печать офсетная. Печ. л. 39,0.  
Тираж 1500 экз. Заказ № 11112

Издательская группа «ГЭОТАР-Медиа»  
115035, Москва, ул. Садовническая, 9, стр. 4  
тел./факс: (495) 921-39-07  
e-mail: info@geotar.ru, www.geotar.ru

Отпечатано в типографии:

 SPAUDA

Пр. Лайсвес 60,  
LT-05120 Вильнюс, Литва  
www.spauda.com

ISBN 978-5-9704-2349-3



9 785970 423493 >

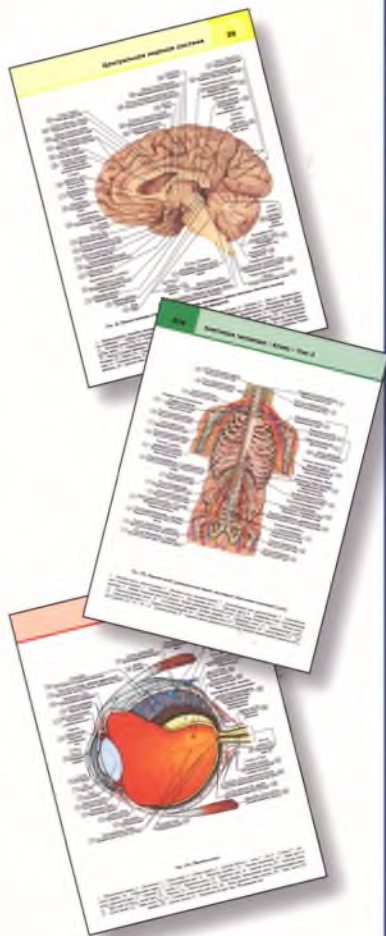
# АТЛАС

# АНАТОМИЯ ЧЕЛОВЕКА

Уникальный трехязычный (русско-латинско-английский) малоформатный атлас анатомии человека в трех томах составлен с учетом последних достижений мировой морфологической науки и методики преподавания нормальной анатомии человека в медицинских вузах. В нем представлены более 2500 иллюстраций по всем аппаратам, системам и органам человека. Атлас отличается от аналогичных изданий объемом и глубиной изложения материала, разнообразием оригинальных таблиц и высококачественных иллюстраций. Содержание атласа полностью соответствует программе по анатомии человека для медицинских вузов.

Атлас компактен, удобен для пользования, содержит исчерпывающий иллюстративный материал высокого качества.

Предназначен для студентов медицинских вузов и врачей всех специальностей. Будет полезен студентам, изучающим анатомию человека, научным работникам, преподавателям и аспирантам.



[www.geotar.ru](http://www.geotar.ru)  
[www.medknigaservis.ru](http://www.medknigaservis.ru)

ISBN 978-5-9704-2349-3



9 785970 423493 >